

بسم الله الرحمن الرحيم

**Sudan University of Science and Technology**  
**Collage of Graduate Studies**



**Evaluation of Brain MRI protocol in Diagnoses  
Of Acute Stroke**

تقييم بروتوكول تصوير الدماغ بالرنين المغناطيسي في تشخيص  
مرض السكتة الدماغية الحادة

**A thesis submitted For Partial Fulfillment for Requirement of M.Sc  
Degree in Diagnostic Radiologic Technology**

**Prepared by:**

**Esraa Mohamed Ismail Ali**

**Supervised by:**

**Dr.Aisma Ibrahim Ahmed Elamin**

**2016**

# الآية

قال تعالى:

(الَّذِينَ قَالَ لَهُمُ النَّاسُ إِنَّ النَّاسَ قَدْ جَمَعُوا لَكُمْ فَاخْشَوْهُمْ فَزَادَهُمْ  
إِيمَانًا وَقَالُوا حَسْبُنَا اللَّهُ وَنِعْمَ الْوَكِيلُ ﴿١٧٣﴾ فَانْقَلَبُوا بِنِعْمَةٍ مِّنَ اللَّهِ  
وَفَضْلٍ لَّمْ يَمْسَسْهُمْ سُوءٌ وَاتَّبَعُوا رِضْوَانِ اللَّهِ وَاللَّهُ ذُو فَضْلٍ  
عَظِيمٍ ﴿١٧٤﴾)

صدق الله العظيم

سورة ال عمران

الآية (١٧٣ - ١٧٤)

# **Dedication**

***This work is dedicated to my mother, who has been my  
constant source of***

***Inspiration and she passed me love of reading and respect  
for education and to my father , who giving me the driver  
and discipline to take any task with enthusiasm and***

***Determination***

***To my brother for their love and support***

***To my friends , whom without their support and  
encouraging this project would not have been made  
possible***

***To every one whom***

***Gave me abit of***

***Wise advice***

# My mother

My mother is precious woman She gave me life ,nurtured me shouted at me ,kissed me but most importantly love me unconditionally .

There are not enough words I can say to describe just how important my brother was to me,and what a powerful influence she continues to be

Mother , I love you

# ACKNOWLEDGEMENT

*with immense gratitude I acknowledge the support and help of my supervisor DR.Aisma Ibrahim Ahmed ElaminI consider it an honor to work with her ,with her encouragement, guidance and support from the subject. her belief that it was indeed possible to finish kept me going.*

- *A special thanks also to all the staff in the department technologists, nurses, and reception*
- *I cannot find words to express my gratitude to my friend , I share the credit of my work with them and I am indebted to my many colleagues who supported me.*
- *Lastly, offer my regards and blessings to all of those who supported me in any respect during the completion of the project*

## مستخلص البحث

في هذه الدراسة تم تصميم قواعد الرنين المغناطيسي في تقييم تشخيص السكتة الدماغية الحادة ونسبة حدوثها .  
أجريت هذه الدراسة في قسم الأشعة التشخيصية في وحدة الرنين في مستشفى الأمل الوطني في الفترة من ديسمبر ٢٠١٥ م إلى أبريل ٢٠١٦ م.  
أخذت عينة عشوائية ل (٣٠) مريض لتشخيص السكتة الدماغية الحادة ، وكانت الأعمار بين ٥٥-٧٥ سنة .  
أكثر فئة عمرية من المرضى الذين أصيبوا بالسكتة الدماغية الحادة كانت بالنسبة للذكور كان عددهم ١٨ ذكر، والإناث ١٢ أنثى .

الذكور أعمارهم ما بين ٥٥-٧٥ سنة والإناث ما بين ٤٠-٦٠ % على التوالي.  
من أكثر الأسباب التي تتضح على الذكور أكثر من الإناث بسبب التدخين ونسبته ٧٠% من المرضى . و ٣٠ منهم غير مدخنين .  
والسبب الثاني يظهر هذا المرض في الذكور بسبب الوزن والأوزان تتراوح ما بين ٧٦-٨٠ كيلو جرام.  
أكثر الأعراض والعلامات للمرض:

النزيف الدماغى ٣٠%.

فقر الدم بنسبة ٥٢%.

النزيف وفقر الدم ٦.٧%.

جملة القول أن النتيجة أثبتت أن الرنين المغناطيسي هو أفضل وسيلة لتشخيص السكتة الدماغية الحادة.

## Abstract

In this study the role of Magnetic resonance has been evaluated in diagnosis acute brain stroke and the percentage of happening.

This study do at the ray department the, MR unit at Alamal professorial hospital from December 2015 to April 2016.

It included random samples of 30 patients referred for Brain MRI in examination diagnosis of acute stroke, their age ranged from (55-75) years.

The most affected age group one ranged from 18 male and 12 female age (55-75) years (60% - 40%) respectively.

The most cases of appearance of male than female of smoker for 70% for patients smoker 30% for patient non smoker.

The second cases of stroke patients weight the most weight between (76 – 80) kg.

The most sings and symptoms of disease:

Hemorrhage 30%.

Ischemia 52%.

Hemorrhage and Ischemia 6.7%.

The result was established by account the number of MRI appearance and finding.

It can be said that the MRI is the best modality choice in diagnosis of acute stroke.

## Abbreviations

DWI	Diffusion – Weighted Imaging
CT	Computed Tomography
MRI	Magnetic Resonance Imaging
AVM	Ateriovenous Malformation
MS	Multiple Sclerosis
CVA	Cerbro Vascular Accident
CVI	Cerebro Vascular Insult
CSF	Cerebrospinal fluied
ACA	Anterior cerebral artery
MCA	Middle cerebral artery
PCA	Posterior cerebral artery
PICA	Posterior inferior cerebral artery
AICA	Anterior infer cerebral artery
AIS	Acute Ischemic stroke
MR	Magnetic resonance
ICH	Intracranial hemorrhage
SPSS	Statistical package for social sciences
RT	Right
LT	Left



## List of contents

Subject	page	
الآية	I	
Dedication	II	
Acknowledgement	IV	
Abstract	VI	
مستخلص البحث	V	
ABBREVIATIONS	VII	
List of contents	VIII	
LIST OF TABLES	IX	
List of Figure	X	
<b>CHAPTER ONE</b>		
1.1	Introduction	1-3
1.2	Problem Of theStudy	3
1.3	Justification	4
1.4	General Objectives	4
1.5	Thesis layout	5
<b>CHAPTER Two</b>		
2.1	Brain Anatomy	5
2.1.1	Hindbrain	6
2.1.2	Cerebellum	7
2.1.3	Midbrain	8
2.1.4	Forebrain	9
2.1.5	Cerebrum	10
2.1.6	Meninges	12
2.1.7	Cerebrospinal fluid	13
2.1.8	Arterial distribution	14
2.2	Pathophysiology	16
2.3	Imaging used in diagnosis of brain stroke	21
2.3.1	MRI principles	20
2.3.2	MRI contraindications	21
2.3.3	MRI IN stroke	24
2.3.4	MRI findings in acute stroke	28

<b>2.3.4.1</b>	<b>Sub-acute phase</b>	<b>28</b>
<b>2.3.4.2</b>	<b>Chronic phase</b>	<b>29</b>
<b>2.4</b>	<b>Previous studies</b>	<b>30</b>
<b>CHAPTER THREE</b>		
<b>3.1</b>	<b>Material</b>	<b>33</b>
<b>3.1.2</b>	<b>Machine Used</b>	<b>33</b>
<b>CHAPTER FOUR</b>		
	<b>Results</b>	<b>35</b>
<b>CHAPTER FIVE</b>		
<b>5.1</b>	<b>Discussion</b>	<b>47</b>
<b>5.2</b>	<b>Conclusion</b>	<b>50</b>
<b>5.3</b>	<b>Recommendation</b>	<b>52</b>
	<b>References</b>	<b>53</b>
	<b>APPENBICES</b>	

## List of Table

<b>Table no</b>	<b>Table</b>	<b>Page no</b>
<b>4.1</b>	<b>Illustratess the frequency of stroke patients according the page</b>	<b>35</b>
<b>4.2</b>	<b>Illustratess the frequency of stroke patients according to the gender</b>	<b>36</b>
<b>4.3</b>	<b>Illustratess the frequency of stroke patients according to the weight</b>	<b>37</b>
<b>4.4</b>	<b>Illustratess the correlation between stroke patienstand their habits</b>	<b>38</b>
<b>4.5</b>	<b>Illustratess the percentage of stroke patients according to the final diagnosis</b>	<b>39</b>
<b>4.6</b>	<b>Represents the frequency and percentage of common site of stroke</b>	<b>40</b>
<b>4.7</b>	<b>Show the effect of age on stroke patients</b>	<b>41</b>
<b>4.8</b>	<b>Shows the cross tabulation between final diagnosis and gender</b>	<b>42</b>
<b>4.9</b>	<b>Shows the cross tabulation between final diagnosis and gender</b>	<b>43</b>
<b>4.10</b>	<b>Shows the correlation between final diagnosis and underlining diseases</b>	<b>44</b>

## List of Figure

<b>Figure no</b>	<b>Figure</b>	<b>Page no</b>
<b>4.1</b>	<b>Illustratess the frequency of stroke patients according the page</b>	<b>35</b>
<b>4.2</b>	<b>Illustratess the frequency of stroke patients according to the gender</b>	<b>36</b>
<b>4.3</b>	<b>Illustratess the frequency of stroke patients according to the weight</b>	<b>37</b>
<b>4.4</b>	<b>Illustratess the correlation between stroke patient stand their habits</b>	<b>38</b>
<b>4.5</b>	<b>Illustratess the percentage of stroke patients according to the final diagnosis</b>	<b>39</b>
<b>4.6</b>	<b>Represents the frequency and percentage of common site of stroke</b>	<b>40</b>
<b>4.7</b>	<b>Show the effect of age on stroke patients</b>	<b>41</b>
<b>4.8</b>	<b>Shows the cross tabulation between final diagnosis and gender</b>	<b>42</b>
<b>4.9</b>	<b>Shows the cross tabulation between final diagnosis and gender</b>	<b>43</b>
<b>4.10</b>	<b>Shows the correlation between final diagnosis and underlining diseases</b>	<b>44</b>

# Chapter One

## Chapter One

### 1.1 Introduction:

Since the discovery of x-rays by W C Roentgen in 1895, medical imaging has contributed significantly to progress in medicine, diagnostic imaging has grown during the last 50 years from a state of infancy to a high level of maturity. And become having an important role in patient management, and especially radiologic diagnosis.

The application of magnetic resonance imaging(Herman2009).Has evolved rapidly since its clinical development in the early 1980s. Presently, examinations of the brain are the second most commonly requestedM R study following spine examinations (Radiology Dept Statistics, 2001) (Slichter 1978). MRI is becoming one of the most important diagnostic tools in clinical decision making for the treatment and management of acute and chronic stroke. Diffusion- weighted imaging (DWI) in which image contrast is based on water motion is remarkably sensitive to ischemic brain injury (i.e., within minutes) whereas other conventional imaging techniques such as CT and T1 and T2 MRI fail to detail such injury for at least a few hours, the anatomical mismatch between DWI and perfusion-weighted imaging (PWI) abnormality is indicative of tissue at risk (i.e., approximating the ischemic penumbra) that is potentially salvageable and is the primary target for therapeutic intervention .In addition to DWI and PWI, there are many exciting MRI

modalities (such as diffusion tensor imaging, blood– brain barrier permeability imaging, pH MRI (Slichter 1978).

Magnetic resonance imaging (MRI) is a test that uses a magnetic field and pulses of radio wave energy to take pictures of the head. In many cases, MRI gives information that can't be seen on an X-ray, ultrasound, or computed tomography (CT) scan. For an MRI of the head, lie head inside a special machine (scanner) that has a strong magnet. The MRI can show tissue damage or disease, such as infection or inflammation, or a tumor, stroke , or seizure . Information from an MRI can be saved and stored on a computer for more study. Photographs or films of certain views can also be made. In some cases, contrast material may be used during the MRI to show pictures of structures more clearly. The contrast may help show blood flow, look for some types of tumors, and show areas of inflammation (Marks et al 1996).

Magnetic resonance imaging (MRI) of the head is done to looking for the cause of headaches. Help diagnose a stroke or blood vessel problems in the head, problems with blood vessels may include an aneurysm or abnormal twisted blood vessels that are present at birth (this is called an arteriovenous malformation [AV]), check blood flow or blood clots to the brain, checking symptoms of a known or suspected head injury, check symptoms such as change in consciousness, confusion, or abnormal movements , these symptoms may be caused by brain diseases, such as Huntington's disease, multiple

sclerosis (MS) ,Parkinson's disease, or Alzheimer's disease,check for "water on the brain" (hydrocephaly) look for tumors , infections, an abscess, or conditions of the brain or brain stem, such as encephalitis or meningitis, check the eyes, the nerves from the eyes to the brain (optic nerves), the ears, and the nerves from the ears to the brain (auditory nerves), look for problems of the pituitary gland, investigate or follow a finding seen on another test (Nitz& W. R. 1999). In the United States amounting to approximately 795,000 people experiencing new or recurrent strokes per year. (D.Mozaffarian, V. L. Roger, et al 2013).

## **1.2 Problem of the study:**

Acute ischemic stroke is one of the leading causes of mortality and morbidity worldwide. Statistics from the American Heart Association estimate an average of 1 stroke every 40 seconds

Stroke patients had opposed way of treatment either coagulant or anti-coagulant in case of hemorrhage and infarction consequence. MRI examinations are answers the question concerning type of stroke location and size, although number of disease may happen in the brain and can be diagnosed in sectional studies but some of them can't be detected early so the study of the acute stroke with studding the anticoagulant factor related to the clinical findings which shown in brain MRI scanning .

### **1.3 Justification:**

Brain stroke is very common among patients referred to the radiological department in modern medical center in Sudan.

The percentages of brain stroke among the population of Khartoum city have not been extensively researched.

### **1.4 Objectives:**

#### **1.4.1 General objectives:**

To evaluate the role of MRI examination in diagnosis of acute stroke.

#### **1.4.2 Specific objectives:**

To find the best protocol in diagnosis stroke

To measure % percentage of ischemia to hemorrhage.

To identify the common site of stroke.

To correlate the finding with age & gender.



### **1.5. Thesis layout:**

Chapter one: Introduction, statement of the problem, objectives of the study, and thesis layout.

Chapter two: The literature review (Anatomy, Pathology, previous studies).

Chapter three: Methodology and data analysis.

Chapter four: Results

Chapter five: Discussion, Conclusions and Recommendations.

Appendix and References.

# **Chapter Two**

**Literature review**

## **Chapter Two**

### **Background**

#### **2.1 Brain anatomy:**

The brain is one of the most complex and magnificent organs in the human body. Our brain gives us awareness of ourselves and of our environment, processing a constant stream of sensory data. It controls our muscle movements, the secretions of our glands, and even our breathing and internal temperature , every creative thought, feeling, and plan is developed by our brain. The brain's neurons record the memory of every event in our lives .

There are different ways of dividing the brain anatomically into regions. a common method and divide the brain into three main regions based on embryonic development: the forebrain, midbrain and hindbrain , under these divisions:

The forebrain (or prosencephalon) is made up of our incredible cerebrum, thalamus, hypothalamus and pineal gland among other features, neuroanatomists call the cerebral area the telencephalon and use the term diencephalon (or interbrain) to refer to the area where our thalamus, hypothalamus and pineal gland reside .

The midbrain (or mesencephalon), located near the very center of the brain between the interbrain and the hindbrain, is composed of a portion of the brainstem .

The hindbrain (or rhombencephalon) consists of the remaining brainstem as well as our cerebellum and pons , neuroanatomists have a word to describe the brainstem sub-region of our hindbrain, calling it the myelencephalon, while they use the word metencephalon in reference to our cerebellum and pons collectively (Guyton, Arthur C.John 1996).

### **2.1.1 Hindbrain (rhombencephalon):**

Connecting the brain to the spinal cord, the brainstem is the most inferior portion of our brain. Many of the most basic survival functions of the brain are controlled by the brainstem.

The brainstem is made of three regions: the medulla oblongata, the pons, and the midbrain. A net-like structure of mixed gray and white matter known as the reticular formation is found in all three regions of the brainstem. The reticular formation controls muscle tone in the body and acts as the switch between consciousness and sleep in the brain (Afshar et al 1978).

The medulla oblongata is a roughly cylindrical mass of nervous tissue that connects to the spinal cord on its inferior border and to the pons on its superior border, the medulla contains mostly white matter that carries nerve signals ascending into the brain and descending into the spinal cord, within the medulla are several regions of gray matter that process involuntary body functions related to homeostasis, the

cardiovascular center of the medulla monitors blood pressure and oxygen levels and regulates heart rate to provide sufficient oxygen supplies to the body's tissues, the medullary rhythmicity center controls the rate of breathing to provide oxygen to the body, vomiting, sneezing, coughing, and swallowing reflexes are coordinated in this region of the brain as well, the pons is the region of the brainstem found superior to the medulla oblongata, inferior to the midbrain, and anterior to the cerebellum, together with the cerebellum, it forms what is called the metencephalon , about an inch long and somewhat larger and wider than the medulla, the pons acts as the bridge for nerve signals traveling to and from the cerebellum and carries signals between the superior regions of the brain and the medulla and spinal cord (Naidich et al 2009).

### **2.1.2Cerebellum:**

The cerebellum is a wrinkled, hemispherical region of the brain located posterior to the brainstem and inferior to the cerebrum , the outer layer of the cerebellum, known as the cerebellar cortex, is made of tightly folded gray matter that provides the processing power of the cerebellum , deep to the cerebellar cortex is a tree-shaped layer of white matter called the arbor vitae, which means 'tree of life' , the arbor vitae connects the processing regions of cerebellar cortex to the rest of the brain and body (Duvernoy& H.M 1999).

The cerebellum helps to control motor functions such as balance, posture, and coordination of complex muscle activities, and receives sensory inputs from the muscles and joints of the body and uses this information to keep the body balanced and to maintain posture. It also controls the timing and finesse of complex motor actions such as walking, writing, and speech (Duvernoy & H.M 1999).

### **2.1.3 MIDBRAIN (MESENCEPHALON):**

The midbrain also known as the mesencephalon, is the most superior region of the brainstem, found between the pons and the diencephalon, the midbrain can be further subdivided into 2 main regions: the tectum and the cerebral peduncles (Duvernoy & H.M 1999).

The tectum is the posterior region of the midbrain, containing relays for reflexes that involve auditory and visual information, the pupillary reflex (adjustment for light intensity), accommodation reflex (focus on near or far away objects), and startle reflexes are among the many reflexes relayed through this region, forming the anterior region of the midbrain, the cerebral peduncles contain many nerve tracts and the substantia nigra, nerve tracts passing through the cerebral peduncles connect regions of the cerebrum and thalamus to the spinal cord and lower regions of the brainstem, the substantia nigra is a region of dark melanin-containing neurons that is involved in the inhibition of movement, degeneration of the substantia nigra leads to a loss of motor control known as Parkinson's disease (Duvernoy & H.M 1999).

#### **2.1.4 FOREBRAIN (PROSENCEPHALON):**

Superior and anterior to the midbrain is the region known as the interbrain, or diencephalon , the thalamus, hypothalamus, and pineal glands make up the major regions of the diencephalon.

The thalamus consists of a pair of oval masses of gray matter inferior to the lateral ventricles and surrounding the third ventricle. Sensory neurons entering the brain from the peripheral nervous system form relays with neurons in the thalamus that continue on to the cerebral cortex. In this way the thalamus acts like the switchboard operator of the brain by routing sensory inputs to the correct regions of the cerebral cortex , the thalamus has an important role in learning by routing sensory information into processing and memory centers of the cerebrum (Woolsey et al 2003).The hypothalamus is a region of the brain located inferior to the thalamus and superior to the pituitary gland , the hypothalamus acts as the brain's control center for body temperature, hunger, thirst, blood pressure, heart rate, and the production of hormones , in response to changes in the condition of the body detected by sensory receptors, the hypothalamus sends signals to glands, smooth muscles, and the heart to counteract these changes , for example, in response to increases in body temperature, the hypothalamus stimulates the secretion of sweat by sweat glands in the skin , the hypothalamus also sends signals to the cerebral cortex to produce the feelings of hunger and thirst when the body is lacking food or water , these signals stimulate the

conscious mind to seek out food or water to correct this situation , also directly controls the pituitary gland by producing hormones , some of these hormones, such as oxytocin and antidiuretic hormone, are produced in the hypothalamus and stored in the posterior pituitary gland , other hormones, such as releasing and inhibiting hormones, are secreted into the blood to stimulate or inhibit hormone production in the anterior pituitary gland (Woolsey et al 2003).

The pineal gland is a small gland located posterior to the thalamus in a sub-region called the epithalamus ,the pineal gland produces the hormone melatonin. Light striking the retina of the eyes sends signals to inhibit the function of the pineal gland. In the dark, the pineal gland secretes melatonin, which has a sedative effect on the brain and helps to induce sleep. This function of the pineal gland helps to explain why darkness is sleep-inducing and light tends to disturb sleep. Babies produce large amounts of melatonin, allowing them to sleep as long as 16 hours per day. The pineal gland produces less melatonin as people age, resulting in difficulty sleeping during adulthood (Buren et al 1972).

### **2.1.5Cerebrum:**

The largest region of the human brain, our cerebrum controls higher brain functions such as language, logic, reasoning, and creativity , the cerebrum surrounds the diencephalon and is located superior to the cerebellum and brainstem ,a deep furrow known as the longitudinal fissure runs midsagittally down the center of the cerebrum, dividing the



cerebrum into the left and right hemispheres ,each hemisphere can be further divided into 4 lobes: frontal, parietal, temporal, and occipital ,the lobes are named for the skull bones that cover them ,the surface of the cerebrum is a convoluted layer of gray matter known as the cerebral cortex. Most of the processing of the cerebrum takes place within the cerebral cortex ,the bulges of cortex are called gyri (singular: gyrus) while the indentations are called sulci (singular: sulcus).

Deep to the cerebral cortex is a layer of cerebral white matter , white matter contains the connections between the regions of the cerebrum as well as between the cerebrum and the rest of the body ,a band of white matter called the corpus callosum connects the left and right hemispheres of the cerebrum and allows the hemispheres to communicate with each other (Schitzlein,Murtagh1990).

Deep within the cerebral white matter are several regions of gray matter that make up the basal nuclei and the limbic system , the basal nuclei, including the globus pallidus, striatum, and subthalamic nucleus, work together with the substantia nigra of the midbrain to regulate and control muscle movements , specifically, these regions help to control muscle tone, posture, and subconscious skeletal muscle , the limbic system is another group of deep gray matter regions, including the hippocampus and amygdala, which are involved in memory, survival, and emotions , the limbic system helps the body to react to emergency and highly emotional situations with fast,

almost involuntary actions (Schitzlein , Murtagh 1990).

### **2.1.6Meninges:**

Three layers of tissue, collectively known as the meninges, surround and protect the brain and spinal cord , the dura mater forms the leathery, outermost layer of the meninges , dense irregular connective tissue made of tough collagen fibers gives the dura mater its strength , the dura mater forms a pocket around the brain and spinal cord to hold the cerebrospinal fluid and prevent mechanical damage to the soft nervous tissue , the arachnoid mater is found lining the inside of the dura mater , much thinner and more delicate than the dura mater, it contains many thin fibers that connect the dura mater and pia mater, as its fibers resemble a spider web , beneath the arachnoid mater is a fluid-filled region known as the subarachnoid space , as the innermost of the meningeal layers, the pia mater rests directly on the surface of the brain and spinal cord. The pia mater's many blood vessels provide nutrients and oxygen to the nervous tissue of the brain , the pia mater also helps to regulate the flow of materials from the bloodstream and cerebrospinal fluid into nervous tissue (Morel et al 1997).

### **2.1.7 Cerebrospinal fluid :**

Cerebrospinal fluid (CSF) a clear fluid that surrounds the brain and spinal cord – provides many important functions to the central nervous system , rather than being firmly anchored to their surrounding bones, the brain and spinal cord float within the CSF. CSF fills the subarachnoid space and exerts pressure on the outside of the brain and spinal cord , the pressure of the CSF acts as a stabilizer and shock absorber for the brain and spinal cord as they float within the hollow spaces of the skull and vertebrae , inside of the brain, small CSF-filled cavities called ventricles expand under the pressure of CSF to lift and inflate the soft brain tissue , cerebrospinal fluid is produced in the brain by capillaries lined with ependymal cells known as choroid plexuses , blood plasma passing through the capillaries is filtered by the ependymal cells and released into the subarachnoid space as CSF , the CSF contains glucose, oxygen, and ions, which it helps to distribute throughout the nervous tissue. CSF also transports waste products away from nervous tissues , after circulating around the brain and spinal cord, CSF enters small structures known as arachnoid villi where it is reabsorbed into the bloodstream , arachnoid villi are finger-like extensions of the arachnoid mater that pass through the dura mater and into the superior sagittal sinus , the superior sagittal sinus is a vein that runs through the longitudinal fissure of the brain and carries blood and cerebrospinal fluid from the brain back to the heart , the brain is the most metabolically

active organ in the body , while representing only 2% of the body's mass, it requires 15-20% of the total resting cardiac output to provide the necessary glucose and oxygen for its metabolism (Orrison Jr., W.W 2008).

### **2.1.8 Arterial distributions:**

---

knowledge of cerebrovascular arterial anatomy and the territories supplied by the cerebral arteries is useful in determining which vessels are involved in acute stroke. Atypical patterns of brain ischemia that do not conform to specific vascular distributions may indicate a diagnosis other than ischemic stroke, such as venous infarction (Nowinski et al 2006).

In a simplified model, the cerebral hemispheres are supplied by 3 paired major arteries, specifically, the anterior, middle, and posterior cerebral arteries , the anterior and middle cerebral arteries carry the anterior circulation and arise from the supraclinoid internal carotid arteries , the anterior cerebral artery (ACA) supplies the medial portion of the frontal and parietal lobes and anterior portions of basal ganglia and anterior internal capsule ,the middle cerebral artery (MCA) supplies the lateral portions of the frontal and parietal lobes, as well as the anterior and lateral portions of the temporal lobes, and gives rise to perforating branches to the globuspallidus, putamen, and internal capsule, the (MCA) is the dominant source of vascular supply to the hemispheres,the

posterior cerebral arteries arise from the basilar artery and carry the posterior circulation the posterior cerebral artery (PCA) gives rise to perforating branches that supply the thalami and brainstem and the cortical branches to the posterior and medial temporal lobes and occipital lobes (Nowinski et al 2006).

The cerebellar hemispheres are supplied:-

Inferiorly by the posterior inferior cerebellar artery (PICA), arising from the vertebral artery

Superiorly by the superior cerebellar artery (Nowinski et al 2006).

Anterolaterally by the anterior inferior cerebellar artery (AICA), from the basilar artery (Nowinski et al 2006).

## **2.2 Pathophysiology:**

Stroke is defined as an "acute neurologic dysfunction of vascular origin with sudden (within seconds) or at least rapid (within hours) occurrence of symptoms and signs corresponding to the involvement of focal areas in the brain" (Goldstein et al 1989).

The two main types of stroke are ischemic and hemorrhagic, accounting for approximately 85% and 15%, respectively (Wise RJ et al 1999).

When an ischemic stroke occurs, the blood supply to the brain is interrupted, and brain cells are deprived of the glucose and oxygen they need to function , ischemic stroke is a complex entity with multiple etiologies and variable clinical manifestations , approximately 45% of ischemic strokes are caused by small or large artery thrombus, 20% are embolic in origin, and others have an unknown cause (Wise J et al 1999).

Acute ischemic stroke (AIS) is characterized by the sudden loss of blood circulation to an area of the brain, typically in a vascular territory, resulting in a corresponding loss of neurologic function , also previously called cerebrovascular accident (CVA) or stroke syndrome, stroke is a nonspecific state of brain injury with neuronal dysfunction that has several pathophysiologic causes. Strokes can be divided into 2 types: hemorrhagic or ischemic , acute ischemic stroke is caused by thrombotic or embolic occlusion of a cerebral artery , thrombosis can form in the

extra cranial and intracranial arteries when the intima is roughened and plaque forms along the injured vessel , the endothelial injury (roughing) permits platelets to adhere and aggregate, then coagulation is activated and thrombus develops at site of plaque , blood flow through the extra cranial and intracranial systems decreases, and the collateral circulation maintains function. When the compensatory mechanism of collateral circulation fails, perfusion is compromised, leading to decreased perfusion and cell death , during an embolic stroke, a clot travels from a distant source and lodges in cerebral vessels , micro emboli can break away from a sclerosed plaque in the carotid artery or from cardiac sources such as atrial fibrillation, patent foramen ovale, or a hypokinetic left ventricle , emboli in the form of blood, fat, or air can occur during surgical procedures, most commonly during cardiac surgery, but also after long bone surgeries (Heros 1994).

Less common causes of ischemic stroke include carotid dissection (Heros et al 1994).

And the presence of coagulopathies, such as those resulting from antiphospholipid antibodies (Siesjo BK 1989), other causes include arteritis, infection, and drug abuse, such as the use of cocaine (Siesjo BK 1989), while still not completely understood, the presence of periodontal disease and tooth loss is also an associated risk for ischemic stroke (Siesjo BK 1981).

As a thrombosis or emboli cause a decrease in blood supply to the brain tissue, events occur at the cellular level, referred to as the ischemic cascade, neurons and support cells require a careful balance of variables such as temperature, pH, nutrition, and waste removal in their environment to function optimally, intensive basic scientific research during the last two decades has given healthcare professionals an increased understanding of the ischemic cascade in the format of the precise environmental alterations involved in the pathophysiology of ischemic injury at the cellular level, understanding the ischemic cascade has led to the concept of a therapeutic time window for treatment possibilities, often, there is a core region of dead cells surrounded by an area of hypoperfused tissue, the hypoperfused area may be rescued; this area is referred to as the penumbra region (Fuster V. Stein B et al 1990). Neuroprotection is a broad term that refers to pharmacological and non-pharmacological treatments used to halt the cellular events in the ischemic cascade, forming the theoretical basis for many of the acute stroke therapies under study (Zivin JA 1991), as well as the rationale for intervening within a therapeutic time window following ischemic stroke. A stroke is referred to as a cerebrovascular accident (CVA), cerebrovascular insult (CVI), or colloquially brain attack is the loss of brain function due to a disturbance in the blood supply to the brain. This disturbance is due to either ischemia (lack of blood flow) or hemorrhage. As a result, the affected area of the brain cannot function normally,



which might result in an inability to move one or more limbs on one side of the body, failure to understand or formulate speech, or a vision impairment of one side of the visual field. Ischemia is caused by either blockage of a blood vessel via thrombosis or arterial embolism, or by cerebral hypo perfusion , hemorrhagic stroke is caused by bleeding of blood vessels of the brain, either directly into the brain parenchyma or into the subarachnoid surrounding brain tissue. Risk factors for stroke include old age, high blood pressure, previous stroke or transient (TIA), diabetes, high cholesterol, tobacco smoking and atrial fibrillation. High blood pressure is the most important modifiable risk factor of stroke (W. Hacke, M. Kaste, E. Bluhmki, et al 2008).

A stroke is a medical emergency and can cause permanent neurological damage or death. An ischemic stroke is occasionally treated in a hospital with thrombolysis (also known as a "clot buster"), and some hemorrhagic strokes benefit from neurosurgery , treatment to recover any lost function is termed stroke rehabilitation, ideally in a stroke unit and involving health professions such as speech and language therapy, physical therapy and occupational therapy , prevention of recurrence may involve the administration of antiplatelet drugs such as aspirin, control of high blood pressure, and the use of statins , some people may benefit from carotid endarterectomy and the use of anticoagulants. Stroke was the second most frequent cause of death worldwide in 2011, accounting for 6.2 million deaths (~11% of the total) , approximately 17

million people had a stroke in 2010 and 33 million people have previously had a stroke and were still alive. Between 1990 and 2010 the number of strokes decrease by approximately 10% in the developed world and increased by 10% in the developing world , overall two thirds of strokes occurred in those over 65 years old (Gorelick PB 2009).

(Zivin JA 1991).

## **2.3 imaging used in diagnosis of brain stroke**

### 2.3.1 X-ray.

### 2.3.2 CT

### **2.3.3 MRI principle**

Magnetic resonance (MR) is based upon the interaction between an applied magnetic field and a nucleus that possesses spin. Nuclear spin or, more precisely, nuclear spin angular momentum, is one of several intrinsic properties of an atom and its value depends on the precise atomic composition. Every element in the Periodic Table except argon and cerium has at least one naturally occurring isotope that possesses spin. Thus, in principle, nearly every element can be examined using MR, and the basic ideas of resonance absorption and relaxation are common to all of these elements. The precise details will vary from nucleus to nucleus and from system to system. Atoms consist of three fundamental particles: protons, which possess a positive charge; neutrons, which have no charge; and electrons, which have a negative charge. The protons and neutrons are located in the nucleus or core of an atom, whereas the electrons are located in shells orbital surrounding the nucleus (Chien, Daisy, and Robert R. Edelman. 1991).

The characteristic chemical reactions of elements depend upon the particular number of each of these particles. The properties most

commonly used to categorize elements are the atomic number and the atomic weight. The atomic number is the number of protons in the nucleus, and is the primary index used to differentiate between atoms. All atoms of an element have the same atomic number. The atomic weight is the sum of the number of protons and the number of neutrons. Atoms with the same atomic number but different atomic weights are called isotopes (Debatin et al 1998).

A third property of the nucleus is spin or intrinsic spin angular momentum, the nucleus can be considered to be constantly rotating about an axis at a constant rate or velocity (Nitz. 1999), this self-rotation axis is perpendicular to the direction of rotation, a limited number of values for the spin are found in nature; that is, the spin,  $I$ , is quantized to certain discrete values. These values depend on the atomic number and atomic weight of the particular nucleus (Nitz. 2002).

There are three groups of values for  $I$ : zero, half-integral values, and integral values. A nucleus has no spin ( $I = 0$ ) if it has an even number atomic weight and an even atomic number. Such a nucleus does not interact with an external magnetic field and cannot be studied using MR (Nitz. 2002).

A nucleus has an integral value for  $I$  (e.g., 1, 2, 3) if it has an even atomic weight and an odd atomic number. A nucleus has a half-integral value for  $I$  (e.g.,  $1/2$ ,  $3/2$ ,  $5/2$ ) if it has an odd atomic weight, the  $^1\text{H}$

nucleus, consisting of a single proton, is a natural choice for probing the body using MR techniques for several reasons, it has a spin of  $\frac{1}{2}$  and is the most abundant isotope for hydrogen, its response to an applied magnetic field is one of the largest found in nature. Finally, the human body is composed of tissues that contain primarily water and fat, both of which contain hydrogen (Nitz 2002).

In general, MR measurements are made on collections of similar spins rather than on an individual spin. It is useful to consider such a collection both as individual spins acting independently (a “microscopic” picture) and as a single entity (a “macroscopic” picture). For many concepts, the two pictures provide equivalent results, even though the microscopic picture is more complete. Conversion between the two pictures requires the principles of statistical mechanics, the macroscopic picture is sufficient for an adequate description. When necessary, the microscopic picture will be used (Mezrich & Reuben 1995).

Measurement techniques can be divided into 2D and 3D categories based on the volume of excited tissue that is used to generate the signal. The most common technique is 2D-multislice imaging, in which a narrow volume of tissue (typically  $< 10$  mm) is excited by a slice-selective RF pulse and generates the echo signal (Shaw & Derek. 1984).

### **2.3.2 MRI contraindications:**

MRI has some limitations, such as high cost, long scanning duration, and decreased sensitivity in the detection of subarachnoid hemorrhages , relative contraindications for MRI include the following: Metallic implants, Claustrophobia, Pacemakers ,MR-incompatible prosthetic heart valves, Contrast allergy ,Patients with metallic implants may have a variety of potential complications, such as heating and pacemaker malfunction and its consequences , for patients with a metallic implant, checking with the manufacturer regarding its MR compatibility is advisable if such information is not available elsewhere. claustrophobic patients may be unable to complete the sequence of MRI ,in selected patients, mild sedation or imaging in an open MR system may be attempted ,however, most open MR scanners provide lesser-quality images. rarely, patients may be allergic to the contrast agent (e.g., gadolinium) used in MRI ,in the presence of any of these contraindications, a regular radiograph may be indicated (Young 2000).

### **2.3.3 MRI in stroke:**

Magnetic resonance imaging (MRI) is increasingly being used in the diagnosis and management of acute ischemic stroke and is sensitive and relatively specific in detecting changes that occur after such strokes, advances in MRI include higher strength of magnetic field (1.5-3.0 T field strength) yielding better resolution of images, newer sequences of

images, and the advent of the open MRI for patients who are claustrophobic or overweight., inpatients may often continue to be monitored and receive treatment while undergoing MRI, because MRI-compatible electrocardiographic monitors, intravenous infusion pumps, and ventilators are available (Patel et al 2001).

The interest in MRI as a tool for acute stroke management lies not only in the capability of this technique to detect early ischemic with high sensitivity, but also in the breadth of the cerebrovascular pathology revealed by such imaging .MRI can delineate the presence, size, location, extent and effects of acute brain ischemia, identify the hypoperfused tissue that is at risk of infarction, and show additional features of the cerebrovascular pathology. MRI can also detect or exclude ICH with an accuracy comparable to CT. A full clinical stroke MRI study for acute stroke takes 15–20 min and is feasible even within a 3 hr thrombolysis time window. The additional diagnostic information obtained with MRI could result in improve- men’s in patient outcomes and cost-effectiveness.57–61 several large stroke centers rely on MRI to screen patients for thrombolytic and other interventional treatments ((Patel et al 2001).

When evaluating a patient with symptoms suggestive of stroke, the clinician must address several issues, notably whether the case represents an instance of acute cerebrovascular disease and, if so, whether the primary lesion is ischemic or hemorrhagic. The cause of the

stroke must be ascertained, along with the nature of the vessel pathology, the pattern and extent of the damage, and the acute intervention that is indicated. In addition, the clinician must decide which secondary prevention therapy is appropriate, and evaluate the patient's prognosis. Brain imaging provides an objective basis for the clinical inferences that direct individual patient management. An accurate diagnosis will determine whether a patient is treated with thrombolytic or other acute interventions, is admitted to a stroke unit, and/or is started on secondary prevention therapies, an error in diagnosis could deprive the patient of effective interventions or unnecessarily expose the individual to potentially harmful treatments (Kucinski et al 2003).

Brain imaging provides an objective basis for the clinical inferences that direct individual patient management in the acute stroke setting. A brain MRI scan is required for all patients with suspected stroke or transient ischemic attack. Thrombolytic therapy is arguably the most important aspect of acute stroke management; however, most decisions in acute stroke do not relate to this treatment. Stroke imaging must, therefore, provide information beyond the presence or absence of intracranial hemorrhage (ICH) and early evidence of a large infarct, gradient-recalled echo MRI show comparable accuracy in the diagnosis of acute ICH. Diffusion-weighted MRI is more sensitive than noncontrast CT for differentiation of acute ischemic stroke from



nonstroke conditions. Combined multimodal parenchymal, perfusion and vascular imaging with CT or MRI has the potential to identify patients with an ischemic penumbra that might be appropriate for acute reperfusion therapies (Leys et al 1992).

MRI identifies a broader range of acute and chronic cerebrovascular pathologies than does CT and, hence, could aid decisions about acute intervention, in-hospital management, and secondary prevention. Here, we present an overview of the diagnostic information that clinicians might gain from MRI in the setting of acute stroke (Wintermark et al 2009).

**The following are commonly used MRI techniques:**

T1-weighted imaging (T1-WI) in which cerebrospinal fluid (CSF) has a low signal intensity in relation to brain tissue

T2-weighted imaging (T2-WI) in which CSF has a high signal intensity in relation to brain tissue

Spin density-weighted imaging in which CSF has a density similar to brain tissue

Gradient echo imaging, which has the highest sensitivity in detecting early hemorrhagic changes

Diffusion-weighted imaging (DWI) in which the images reflect the microscopic random motion of water molecules

Perfusion-weighted imaging (PWI) in which thermodynamically weighted MR sequences are based on passage of MR contrast through brain tissue.

### **2.3.4 MRI Findings in acute stroke:**

#### **2.3.4.1 Acute phase (1-7 d)**

---

In this phase, edema increases, maximizing at 48-72 hours, and MRI signals become more prominent and well demarcated. The ischemic area continues to appear as an area of hypo intensity on T1-WI and as a hyper intense area on T2-WI. In addition, the mass effect can be appreciated in this phase, in contrast-enhanced images, the arterial enhancement usually persists throughout the acute phase, while the parenchymal enhancement is usually appreciated at the end of this phase in complete infarction, in incomplete infarction, the parenchymal enhancement is usually earlier, during this period, reperfusion occurs and hemorrhages can be observed, typically 24-48 hours after the onset of the stroke, usually, hemorrhages cause the "fogging" phenomenon, due to hemoglobin degradation products, that masks the infarction on T1-WI and T2-WI (Latchaw et al 2009).

#### **2.3.4.2 Sub acute phase (7-21 d)**

---

In this phase, the edema resolves and the mass effect becomes less appreciated; however, the infarcted areas still appear as a hypo intensity on T1-WI and as a hyper intensity on T2-WI, in contrast-enhanced

images, the arterial enhancement is usually resolved by this time, and the parenchymal enhancement typically persists throughout this phase, the cortical parenchymal enhancement is usually in a gyri form pattern, while the sub cortical enhancement is usually a homogenous central pattern (Latchaw et al 2009).

#### **2.3.4.3 Chronic phase (21 d)**

---

In this phase, the edema completely resolves, and the infarcted area still appears as a hypo intensity on T1-WI and as a hyper intensity on T2-WI. Because of tissue loss in the infarcted area by this time, exvacuo ventricular enlargement and widening of the cortical gyri and fissures take place, in contrast-enhanced images, parenchymal enhancement typically also persists throughout this phase; it usually disappears by 3-4 months (Latchaw et al 2009).

## 2.4 Previous studies:

In the study of (Idicula TT et al 2008). Show the Effect of Physiologic Derangement in Patients with Stroke Treated with Thrombolysis

From 1998 to 2006, we prospectively studied 127 patients who received intravenous thrombolysis for acute stroke. Following parameters were measured both before and after thrombolysis: body temperature, blood glucose and blood pressure. Stroke outcome was measured with mRS 3 months after the index stroke.

The mean body temperature before and after thrombolysis were  $36.5 \pm 0.660$  C and  $36.6 \pm 0.790$  C respectively. Body temperature before thrombolysis was not associated with outcome whereas high body temperature after thrombolysis was associated with poor outcome (OR 0.79,  $p = 0.5$ ; OR 2.84,  $p = 0.01$ ). The mean blood glucose before and after thrombolysis were  $6.7 \pm 1.9$  mmol/L and  $6.9 \pm 2.7$  mmol/L respectively. Blood glucose before thrombolysis was not associated with outcome whereas high blood glucose after thrombolysis was associated with poor outcome (OR 1.04,  $p = 0.08$ ; OR 1.33,  $p = 0.03$ ). The mean systolic blood pressure both before and after thrombolysis was  $156 \pm 23$  mm Hg and  $172 \pm 25$  mm Hg respectively. High systolic blood pressure both before and after thrombolysis was associated with poor outcome (OR 1.27,  $p = 0.025$ ; OR 1.22,  $p = 0.045$ ). The mean diastolic blood pressure before and after thrombolysis were

84±17 mm Hg and 97±16mm Hg respectively. Diastolic blood pressure both before and after thrombolysis was not associated with outcome.

In ischemic stroke patients, frequent monitoring of body temperature and blood glucose and the appropriate treatment of it, if elevated, are important during the phase following thrombolysis. However in the hyper-acute phase, before thrombolysis, reduction of high systolic BP is important.

Another previous studies of (Ann.Neurol. 1997). Who reveal that Diffusion-weighted magnetic resonance imaging detects ischemic injury within minutes after onset, and has been used to demonstrate drug efficacy in animal models of stroke. In 50 patients diagnosed with acute ischemic stroke (<24-hour duration) within the middle cerebral artery territory, lesion volume was measured by diffusion-weighted imaging. Thirty-four patients also had volumes measured by T2-weighted imaging chronically (median time, 7.5 weeks; mean, 15.9 weeks). Clinical severity was measured by the National Institutes of Health Stroke Scale Score and the Barthel index. Acute lesion volumes correlated with the acute stroke scale score ( $r = 0.56$ ), the chronic stroke scale score ( $r = 0.63$ ), and chronic lesion volumes ( $r = 0.84$ ). Chronic volumes correlated with the chronic stroke scale score ( $r = 0.86$ ) and the Barthel index ( $r = -0.60$ ). When only cortically based lesions were considered, the correlations relating acute lesion volume measured by diffusion-weighted imaging ( $r = 0.61$ ) and chronic lesion volume

measured by T2-weighted imaging ( $r = 0.90$ ) to the chronic stroke scale score were higher. These results provide evidence that lesion volumes determined by diffusion-weighted imaging acutely may be predictive of clinical severity and outcome, and may support a role for diffusion-weighted imaging in the assessment of acute stroke therapies in clinical trials.

# Chapter three

## Materials and Methods

## **Chapter three**

### **Materials and Methods**

#### **3.1 Materials**

##### **3.1.1 Patients**

The study consists of 30 patients, male and female, their age ranging from 40-80 year, they had different clinical symptoms all of them underwent MRI scan for brain, to differentiate cause of stroke, define size and involve arteries, infarct core and tissue at risk. child's and patient with brain tumor excluded from the study, all patients informed verbally to obtain their consent before recording their information's that used in this study.

##### **3.1.2 Machine used**

Machine used in this study MRI scanner PHILIPS (1.5tesla) and TOSHIBA (1.5 tesla).coil & any acessoreis.

Technique used

The following MRI technique was used:

T1-weighted imaging (T1-WI) in which cerebrospinal fluid (CSF) has a low signal intensity in relation to brain tissue

T2-weighted imaging (T2-WI) in which CSF has a high signal intensity in relation to brain tissue

Spin density-weighted imaging in which CSF has a density similar to brain tissue



Gradient echo imaging, which has the highest sensitivity in detecting early hemorrhagic changes

Diffusion-weighted imaging (DWI) in which the images reflect the microscopic random motion of water molecules TR-TE .slice thickness, slice gap.

### **Image Interpretation**

The data result collected from the result of MRI scan finding and supported the result by radiologist reports.

### **Study area:**

Khartoum City.Sudan

### **Data analysis**

All data wered entered and analysed using Microsoft Excel and statistical analysis soft wered statistical package for social sciences(SPSS) version 22 statistical analysis included description statistic of frequency tables, graphs, cross tabulation and t test was applied to compare the variables, the difference was considered significant when p-value is less or equal 0.05.

# **CHAPTER FOUR**

## **Results**

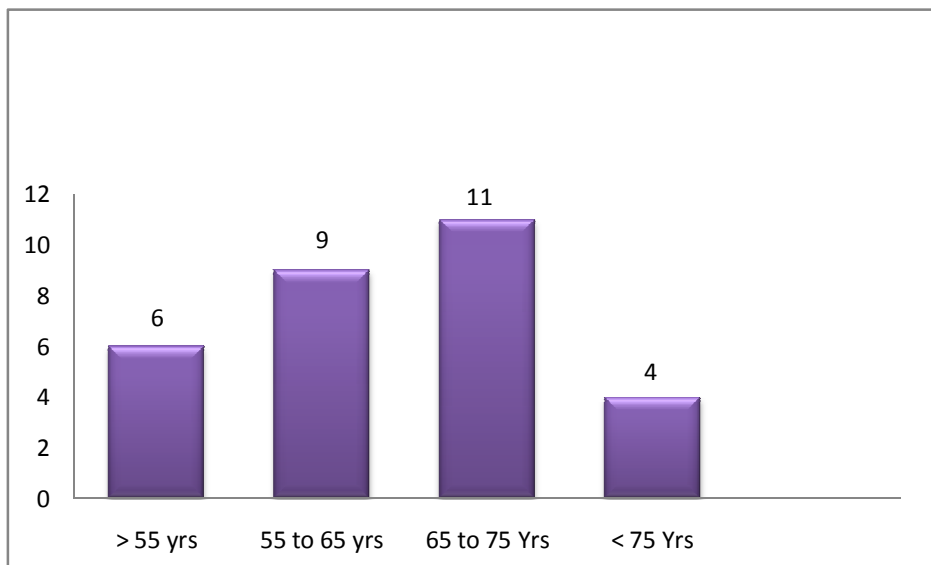
## CHAPTER FOUR

### Results

In the present study, a total number of 30 patients with stroke were studied to evaluate the role of MRI scanning in diagnosis stroke.

Table (4.1) illustrates the frequency of Stroke patient's according to the age.

Age	frequency
> 55 yrs	6
55 to 65 yrs	9
65 to 75 yrs	11
< 75	4
<b>Total</b>	<b>30</b>



Figures (4.1) illustrates the frequency of Stroke patient's according to the age.

Table (4.2) illustrates the frequency of Stroke patient's according to the gender.

<b>Gender</b>	<b>frequency</b>
Male	18
Female	12
<b>Total</b>	<b>30</b>

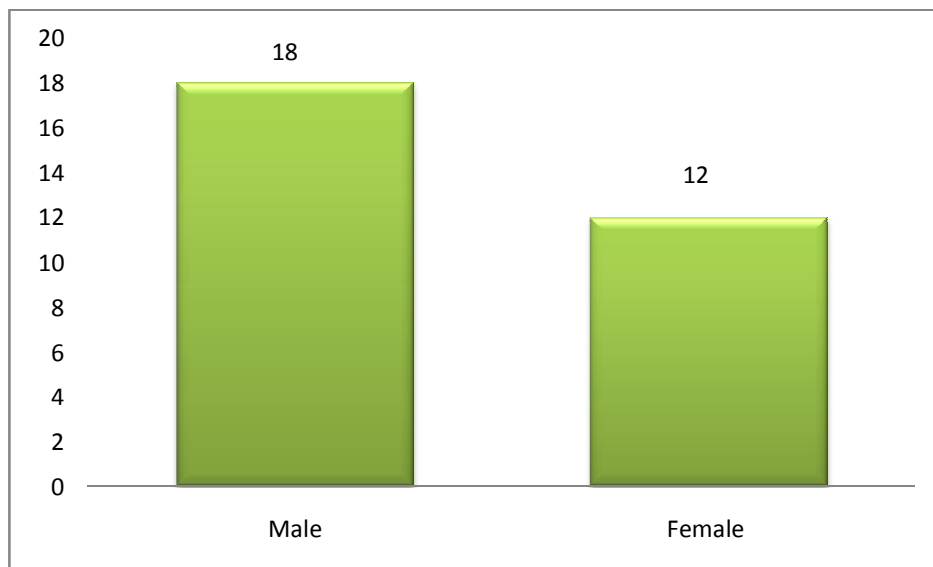


Figure (4.2) illustrates the frequency of Stroke patient's according to the gender.

Table (4.3) illustrates the frequency of Stroke patient's according to the weight.

<b>weight</b>	<b>frequency</b>
>76 kg	15
76 to 80 kg	10
< 80 kg	5
<b>Total</b>	<b>30</b>

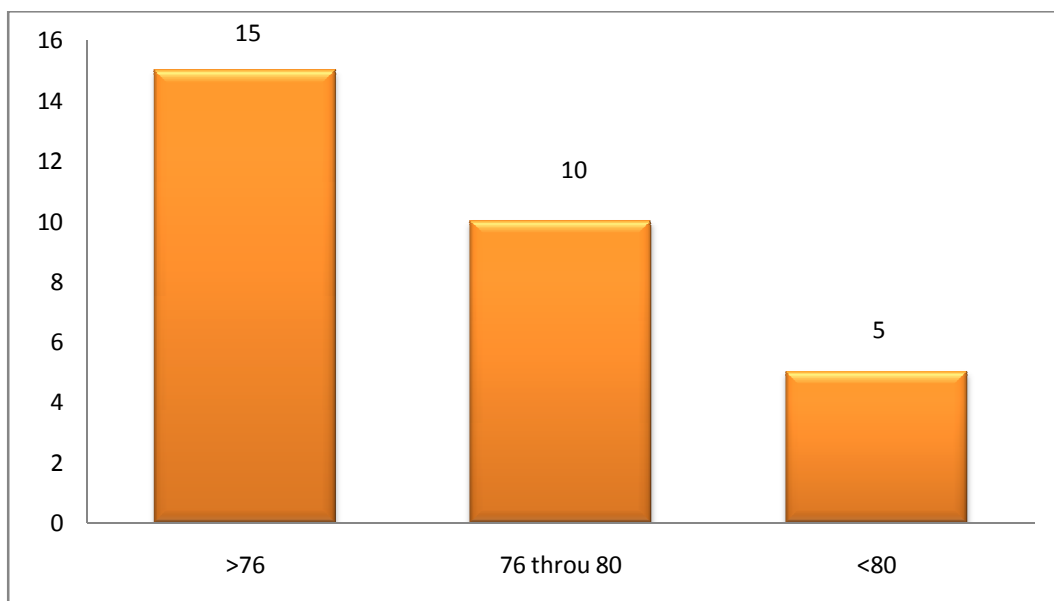


Figure (4.3) illustrates the frequency of Stroke patient's according to the weight.

Table (4.4) illustrates the correlation between Stroke patients and their habits.

<b>Habits</b>	<b>Frequency</b>	<b>Percentage %</b>
Smoker	21	70.0%
Non smoker	9	30.0 %
Total	30	100.0 %

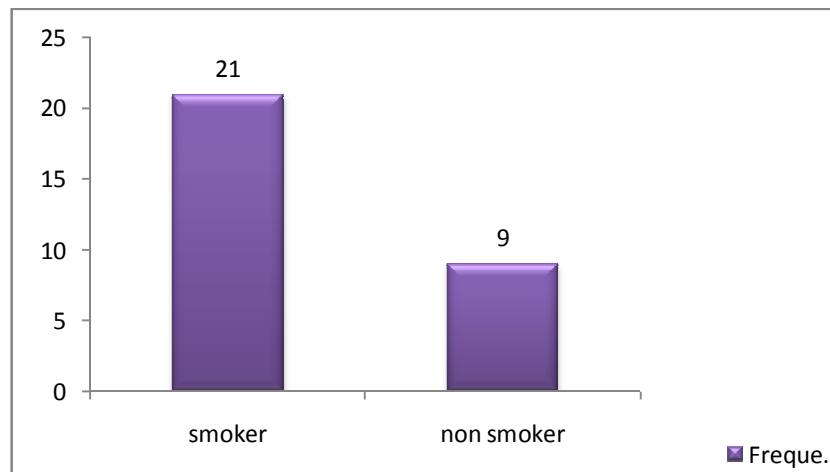


Figure (4.4.1) show the Frequency of Stroke patient's according to their habits.

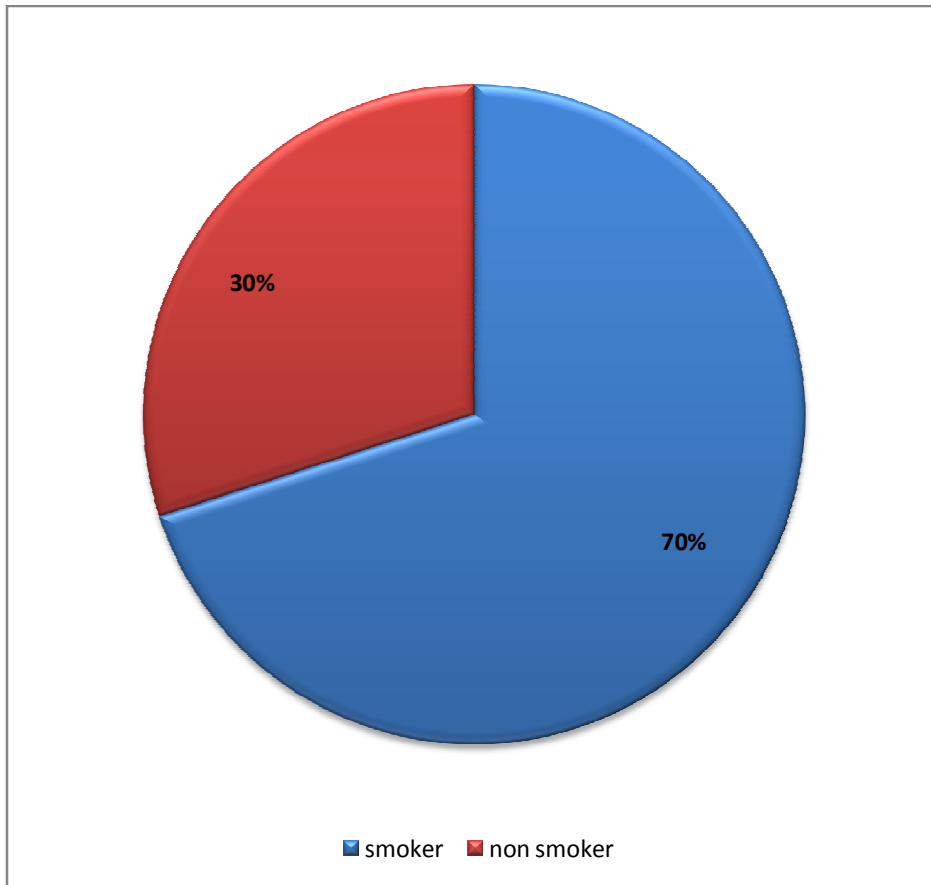


Figure (4.4.2) shows the Percentage % of Stroke patient's according to their Habits.

Table (4.5) illustrates the percentage % of Stroke patient's according to the final diagnosis.

<b>Final diagnosis</b>	<b>percentage %</b>
Heamorrhage	30 %
Ischemia	52 %
Heamorrhage and ischemia	6.7 %

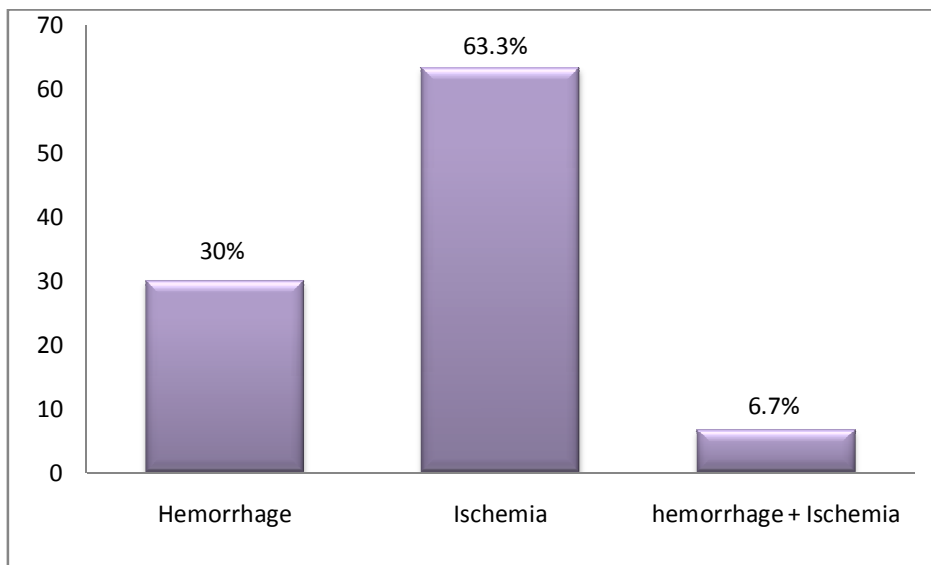


Figure (4.5) illustrates the percentage % of Stroke patient's according to the final diagnosis



Table (4.6) represents the frequency and percentage % of the common site of stroke.

<b>Site of stroke</b>	<b>frequency</b>	<b>Percentage%</b>
RT Anterior	2	6.7 %
RT Posterior	1	3.3 %
LT Anterior	2	6.7 %
LT Posterior	3	10.0 %
Preivenricular	19	63.3 %
LT Anterior + Preivenricular	2	6.7 %
LT Anterior + LT Posterior	1	3.3 %

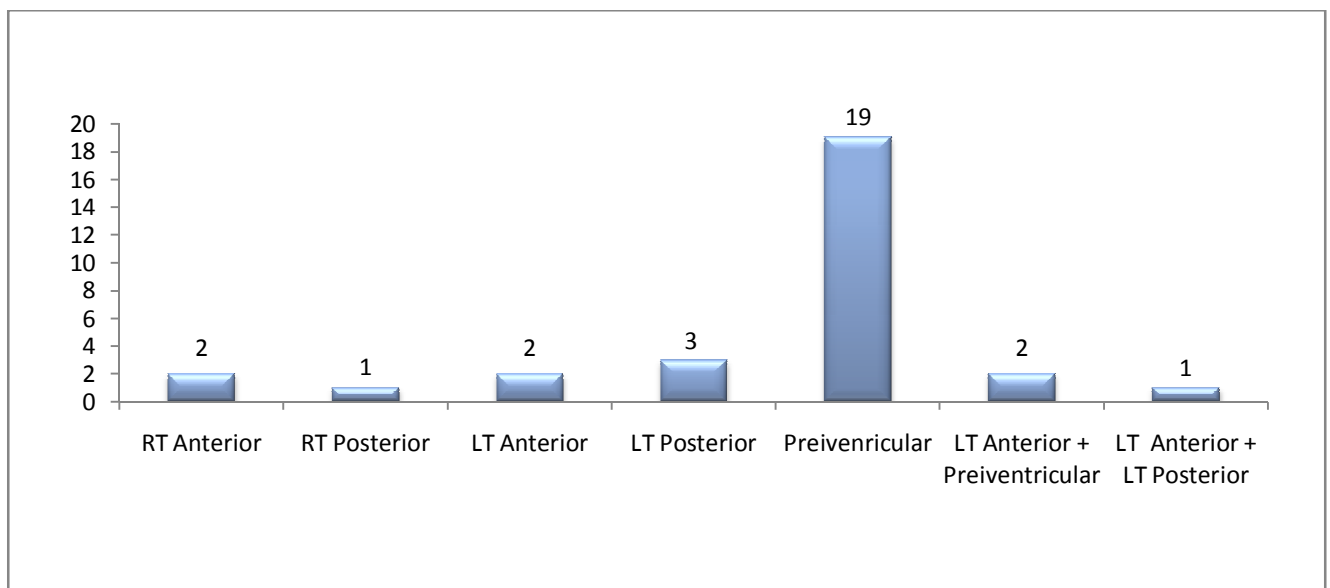


Figure (4.6.1) represents the frequency of the common site of stroke.

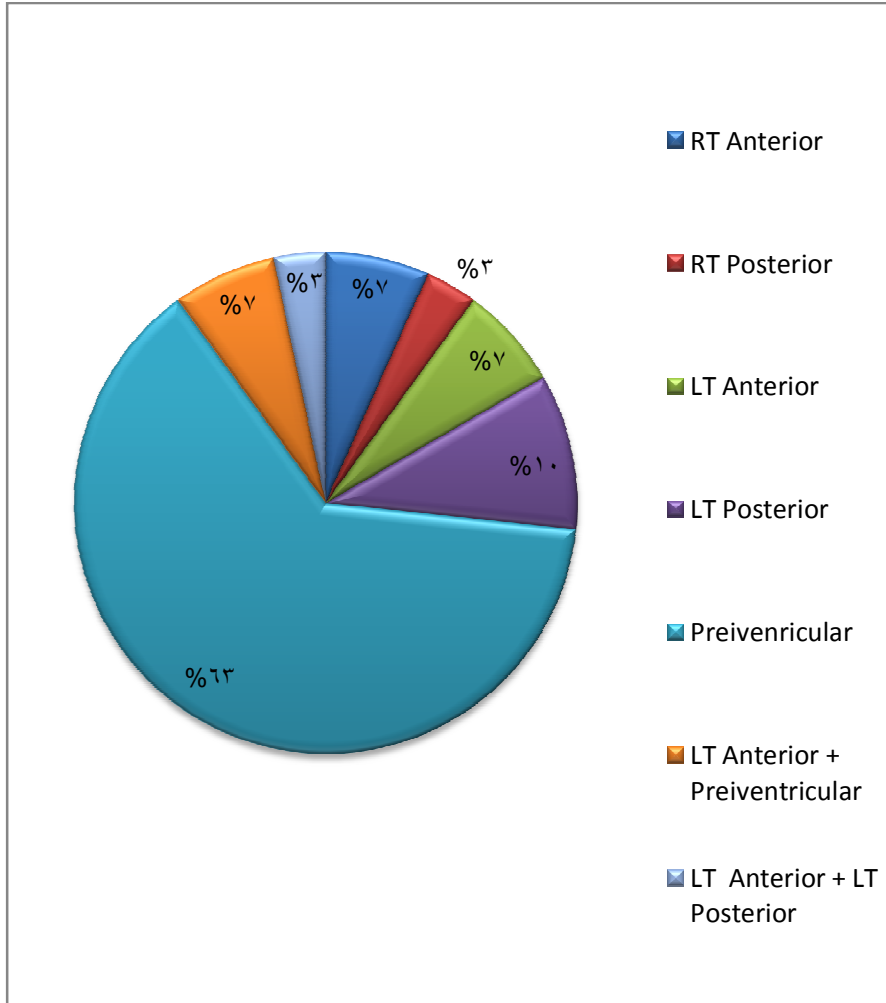
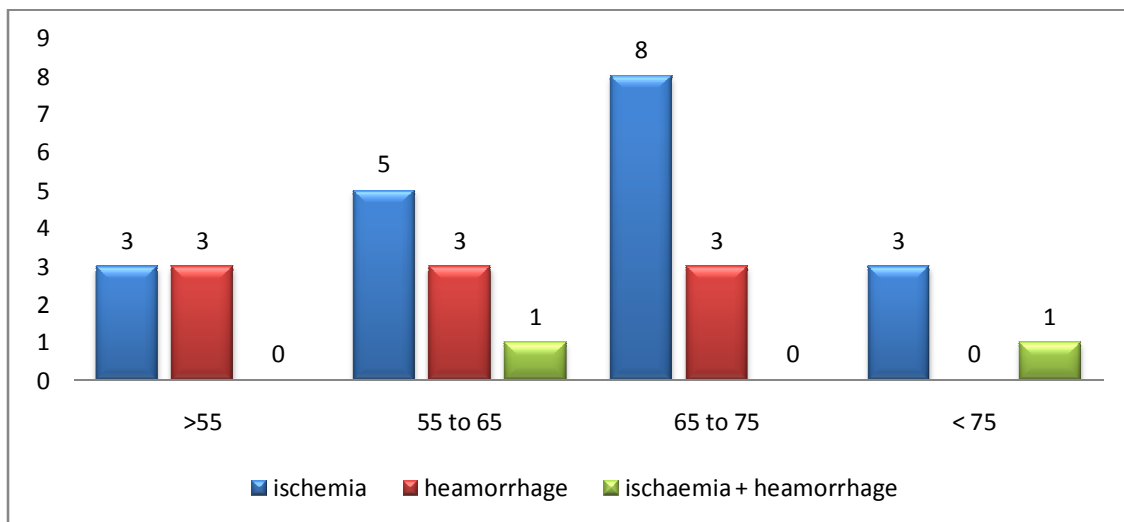


Figure (4.6.2) represent the percentage % of the common site of stroke.

Table (4.7) shows the effect of age onStroke patient's

(P value 0.426). (P. vlaue >0.05.)

Final Diagnosis * age Cross tabulation							
			age				Total
			>55	55-65	65-75	<75	
Final Diagnosis	Ischemia	Count	3	5	8	3	19
		% within Final Diagnosis	15.8%	26.3%	42.1%	15.8%	100.0%
		% within age	50.0%	55.6%	72.7%	75.0%	63.3%
	hemorrhage	Count	3	3	3	0	9
		% within Final Diagnosis	33.3%	33.3%	33.3%	0.0%	100.0%
		% within age	50.0%	33.3%	27.3%	0.0%	30.0%
	Ischemia+ Hemorrhage	Count	0	1	0	1	2
		% within Final Diagnosis	0.0%	50.0%	0.0%	50.0%	100.0%
		% within age	0.0%	11.1%	0.0%	25.0%	6.7%
Total		Count	6	9	11	4	30
		% within Final Diagnosis	20.0%	30.0%	36.7%	13.3%	100.0%
		% within age	100.0%	100.0%	100.0%	100.0%	100.0%



Figure(4.7) shows the effect of age onStroke patient's

Table (4.8) shows the Cross tabulation between final diagnosis and gender.

<b>Final Diagnosis * Gender Cross tabulation</b>				
		Gender		Total
		Male	Female	
Final Diagnosis	Ischemia	14	5	19
	hemorrhage	3	6	9
	Ischemia+ Hemorrhage	1	1	2
Total		18	12	30

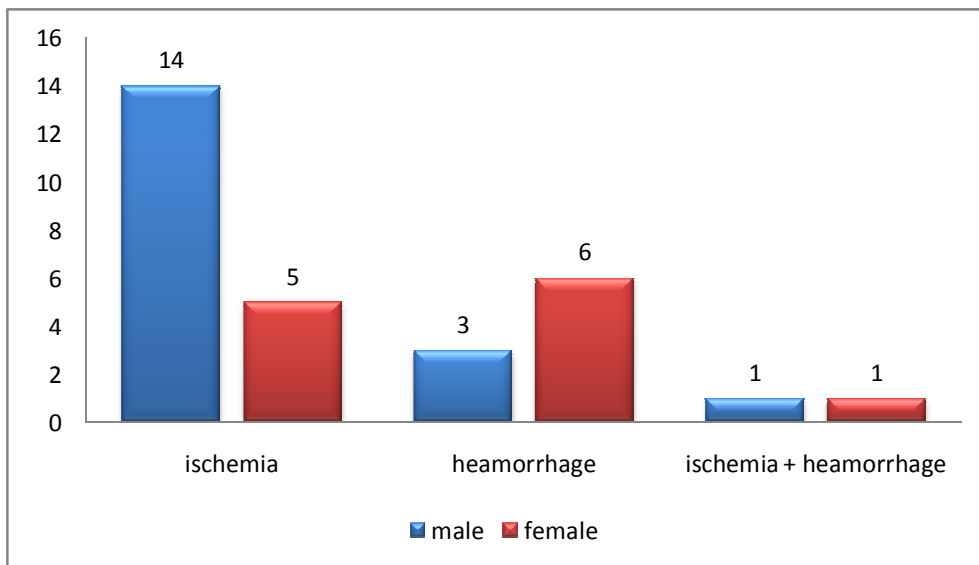


Figure (4.8) shows the Correlation between final diagnosis and gender.

Table (4.9) shows the Cross tabulation between final diagnosis and weight.

<b>Final Diagnosis * wt Cross tabulation</b>				
Final Diagnosis	wt			Total
	>76 kg	76 to 80 kg	<80kg	
Ischemia	7	8	4	19
hemorrhage	7	1	1	9
Ischemia+ Hemorrhage	1	1	0	2
Total	15	10	5	30

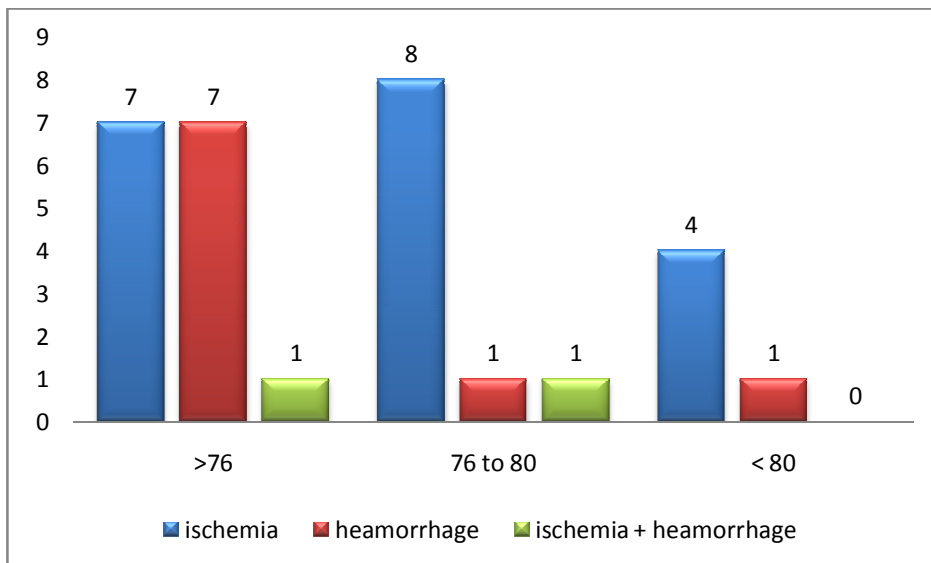


Figure (4.9) shows the frequency of weight on Stroke patient's

Table (4.10) shows the correlation between final diagnosis and underline diseases.

final diagnosis	Disease			Total
	DM	HT	DM + HT	
ischemia	1	11	7	19
hemorrhage	0	3	6	9
ischemia + hemorrhage	0	1	1	2
Total	1	15	14	30

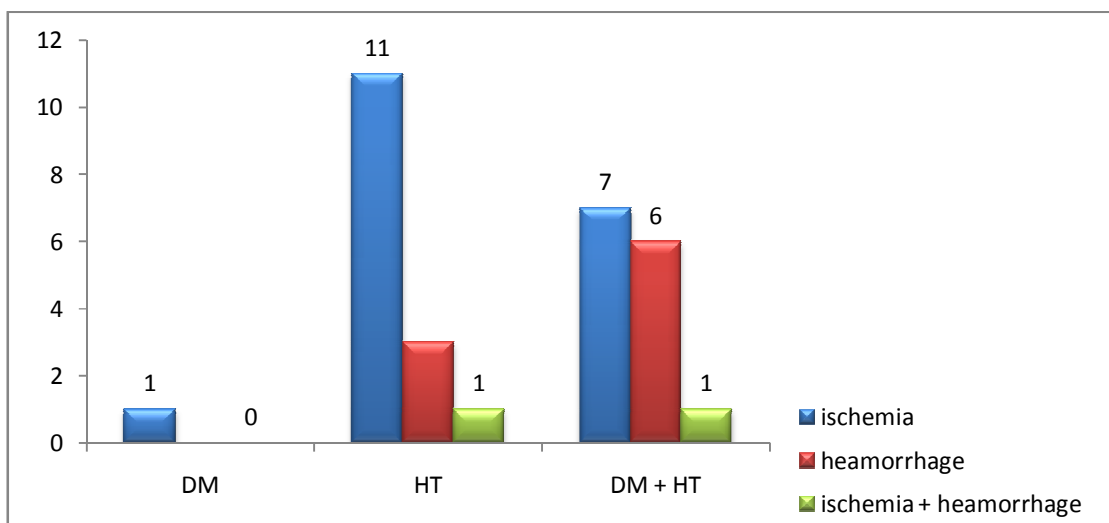


Figure (4.10) shows the correlation between final diagnosis and underline diseases.

# Chapter five

**Discussion, Conclusion and Recommendation**

## Chapter five

### 5.1 Discussion:

The preliminary investigations obtained from this study revealed that the stroke patient's participated in this study, patient's with old ages more affected than younger patient's, and this remarks are reported by (H. P. Adams Jr. et al 2007), who postulated that the risk of stroke rises significantly with age. After 55, it more than doubles with each passing decade. Each year, about 1 percent of people between ages 65 and 74 have a stroke and 5 to 8 percent of people in that age group who have had a TIA go on to stroke. Although risk associated with advancing age cannot be changed, it is an important factor in assessing stroke risk and planning preventive therapies.

The preliminary investigations obtained from this study revealed that the patients participated in this study, men's with being more affected than women's in regards with stroke disease, as our study including 18 males and 12 females, and this remarks are reported by (Kajstra J et al 1996), who postulated that the risk of stroke rises in males than females, among 1,110 patients, including 615 men and 505 women, a normal or near normal outcome at 90 days was found in 37.1% of men's vs. 36.0% of women's. but disagree with (Dr David M. Kent 2011). Who Saied In his pooled analysis of acute ischemic stroke, Stroke has a greater effect



on women than men because women have more events and are less likely to recover.

In this study data indicate that both obesity and weight gain in males and females are important risk factors for ischemic and total stroke but not hemorrhagic stroke. The relationship between obesity and total stroke depends on the distribution of stroke subtypes in the population. ,this result are in agreement with findings of(P. D. Schellinger 2010), on his study, including 403 ischemic strokes and 269 hemorrhagic strokes were documented,( $\geq 27$  kg/m<sup>2</sup>) had significantly increased risk of ischemic stroke, with relative risks (RRs) of 1.75 (95% confidence interval [CI], 1.17-2.59) for BMI of 27 to 28.9 kg/m<sup>2</sup>; 1.90 (95% CI, 1.28-2.82) for BMI of 29 to 31.9 kg/m<sup>2</sup>; and 2.37 (95% CI, 1.60-3.50) for BMI of 32 kg/m<sup>2</sup> or more (P for trend<.001), as compared with those with a BMI of less than 21 kg/m<sup>2</sup>.

The preliminary investigations obtained from this study revealed that the stroke patient's participated in this study, smoker patient's are more affected than non smokerpatient's, and this remarks are reported by(Lancaster T, Stead L (2005), who Saied Smoking facilitates atherosclerosis and appears to be a dependent risk factor for strokes that result from a clot. It also seems to be a risk for strokes that result from cerebral hemorrhage. Men in a community studied extensively for cardiovascular disease who smoked more than 40 cigarettes a day had twice the stroke risk of men who smoked fewer than 10. In a large

Harvard Medical School study of women, the number of cigarettes smoked was found to be directly related to stroke risk. Women smoking more than 25 cigarettes a day had a 2.7 times greater risk of stroke from a clot or embolus and a 9.8 times greater risk of a hemorrhagic stroke.

Data from both the Framingham Heart Study and the Honolulu Heart Study indicate that one can significantly reduce stroke risk by stopping smoking. Five years after they stop, smokers have a stroke risk equal to that of non- smokers (National Institute for Health and Clinical Excellence 2011).

In this study the result of final diagnosis in stroke patient's, revealed that the percentage of ischemia is more frequently than hemorrhage in the sample of study, where the ischemia was 63.3% and hemorrhage was 30%.

One of the most interesting observations obtained from this study is to identify the common site of stroke, the result show that the percentage of stroke in Preiventricular was 63.3% from total number of study sample.

## **5.2 Conclusion:**

Cerebral ischemia triggers an extremely complex set of pathophysiologic events. MRI provides information on almost all the elements taking part in this setting, from cerebral tissue itself to blood vessels and blood flow dynamics, and helps us to get a grasp of this dynamic process. The development of tissue and clinical-based prediction models relying on MRI not only provide the clinician with prognostic data, but also helps in optimizing patient selection of stroke therapies. The automated lesion- outlining and volume calculation software currently present in some clinical workstations is a major step forward in individualization of stroke care. However, despite its advantages, MRI by itself cannot supply all the information needed to make accurate predictions, and ideal prognostic models should consist of a combination of clinical and imaging data.

MRI allows accurate diagnosis of the infarct lesion, detection of cerebral arterial occlusion or significant stenosis with evaluation of actual collateral flow and may also display certain reversible ischemic changes. However, the main objective for MRI still remains: improvement of non-invasive rapid and accurate identification of brain tissue at risk for infarction, which may be salvaged by safe and effective reperfusion therapy.

MRI is better for detection of acute ischemia, and can detect acute and chronic hemorrhage; therefore it should be the preferred test for accurate diagnosis of patients with suspected acute stroke.

The greater overall sensitivity of MRI for acute stroke in this study is attributable to its electiveness for detection of acute ischemic stroke.

### **5.3 Recommendations**

1-Brain imaging should be performed immediately for people with acute stroke if any of the following apply: indications for thrombolysis or early anticoagulation treatment on anticoagulant treatment a known bleeding tendency, unexplained progressive or fluctuating symptoms, neck stiffness or fever, severe headache at onset of stroke symptoms.

2-For all people with acute stroke without indications for immediate brain imaging, scanning should be performed as soon as possible (at most within 12 hours of admission).

Patients with suspected stroke should be assessed for thrombolysis, receiving it if clinically indicated and be admitted directly to a specialist acute stroke unit.

3- All patients should have immediate access to a stroke physician to ensure patients get access to appropriate medical interventions.

4- Any patient, regardless of age or stroke severity, where treatment can be started within 3 hours of known symptom onset and who has been shown not to have an intracerebral hemorrhage or other contraindications should be considered for treatment using alteplase. Between 3 and 4.5 hours of known stroke symptom onset.

# Reference

## Reference

A. S. Go, D. Mozaffarian, V. L. Roger, et al., “Heart disease and stroke statistics—2013 update: a report from the American Heart Association,” *Circulation*, vol. 127, no. 1, pp. e6–e245, 2013.

Afshar, E., Watkins, E.S., Yap, J.C.: *Stereotactic Atlas of the Human Brainstem and Cerebellar Nuclei*. Raven, New York (1978).

*Ann Neurol*. 1997 Aug; 42(2):164-70.

Caplan LR. Stroke thrombolysis: slow progress. *Circulation*. 2006;114: 187–190.

Chien, Daisy, and Robert R. Edelman. 1991. Ultrafast Imaging Using Gradient Echoes. *Magnetic Resonance Quarterly* 7, 31–56.

Debatin, Jörg F., and Graeme C. McKinnon, eds. 1998. *Ultrafast MRI: Techniques and Applications*. Springer-Verlag, Heidelberg.

Dr David M. Kent, Institute for Clinical Research and Health Policy Studies, Tufts–New England Medical Center, 2011.

Duvernoy, H.M.: *The Human Brain. Surface, Three-Dimensional Sectional Anatomy with MRI, and Blood Supply*. Springer, New York (1999).

Fuster V, Stein B, Amboose JA et al. Atherosclerotic plaque rupture and thrombosis: evolving concepts. *Circulation* 1990; 82(supp II); 47-59. 40. Glaglov S, Zarins CB. What are the determinants of plaque instability and its consequences? *J VascSurg* 198; 9: 389-390.

Goldstein, Barnett, et al.,1989, p. 1412.

Gorelick PB. The burden and management of TIA and stroke in government-funded healthcare programs. *Am J Manag Care*. 2009 Jun;15(6 Suppl):S177-S184.

Guyton, Arthur C., and John D. Hall. 1996. *Textbook of Medical Physiology*, 9th ed. W. B. Saunders, Philadelphia.

H. P. Adams Jr., G. del Zoppo, M. J. Alberts, et al., “Guidelines for the early management of adults with ischemic stroke: a guideline from the American Heart Association/American Stroke Association Stroke Council, Clinical Cardiology Council, Cardiovascular Radiology and Intervention Council, and the Atherosclerotic Peripheral Vascular Disease and Quality of Care Outcomes in Research Interdisciplinary Working Groups: the American Academy of Neurology affirms the value of this guideline as an educational tool for neurologists,” *Stroke*, vol. 38, no. 5, pp. 1655–1711, 2007

Herman, G. T., *Fundamentals of computerized tomography: Image reconstruction from projection*, 2nd edition, Springer, 2009

Heros R. Stroke: early pathophysiology and treatment. *Stroke*. 1994;25:1877-1881.

Idicula TT, Waje-Andreassen U, Brogger J, Naess H, Lundstadsveen M.T, Thomassen L. *Journal of Stroke and Cerebrovascular Diseases*, Vol. 17, No. 3 (May-June), 2008: pp 141-146



Jorgensen HS, Nakayama H, Raaschou HO, Gam J, Olsen TS. "Silent infarction in acute stroke patients. Prevalence, localization, risk factors, and clinical significance: the Copenhagen Stroke Study." *Stroke* 1994 Jan;25(1):97-104

Kajstra J, Cheng W, Reiss K et al. Apoptotic and necrotic myocyte cell deaths are independent of variables to infarct size in rats. *Lab Invest.* 1996; 74:86-1

Kucinski, T., Koch, C. & Zeumer, H. In *Imaging in Stroke* (ed. Hennerici, M. G.) 19–42 (Remedica Publishing, London, 2003).

Lancaster T, Stead L (2005) Individual behavioural counselling for smoking cessation. *Cochrane Database of Systematic Reviews*

Latchaw, R. E. et al. Recommendations for imaging of acute ischemic stroke: a scientific statement from the American Heart Association. *Stroke* 40, 3646–3678 (2009).

Leys, D., Pruvo, J. P., Godefroy, O., Rondepierre, P. & Leclerc, X. Prevalence and significance of hyperdense middle cerebral artery in acute stroke. *Stroke* 23, 317–324 (1992).

Marks, Michael P., Alex de Crespigny, Daniel Lentz, Dieter R. Enzmann, Gregory W. Albers, and Michael E. Moseley. 1996. Acute and Chronic Stroke: Navigated Spin-Echo Diffusion-Weighted MR Imaging. *Radiology* 199, 403–408.

McNeil JJ, O Malley HM, Davis SM, Donnan GA. Risk factors for lacunar infarction syndromes. *Neurology* 1995;45: 1483-87.

Mezrich, Reuben 1995. A Perspective on K-Space. *Radiology* 195, 297–315; *Radiology* 199, 874–875

Morel, A., Magnin, M., Jeanmonod, D.: Multiarchitectonic and stereotactic atlas of the human thalamus. *J. Comp. Neurol.* 387, 588–630 (1997).

Naidich, T.P., Duvernoy, H.M., Delman, B.N., et al.: *Duvernoy's Atlas of the Human Brain Stem and Cerebellum: High-Field MRI, Surface Anatomy, Internal Structure, Vascularization and 3D Sectional Anatomy.* Springer, New York (2009)

National Institute for Health and Clinical Excellence 2011; PROGRESS Collaborative Group 2001

MR Imaging: Acronyms and Clinical Applications. *European Radiology* 9, 979–997.

Nitz, W. R. 2002. Fast and Ultrafast Non-echo-planar MR Imaging Techniques. *European Radiology* 12, 2855–2882.

Nowinski, W.L., Qian, G., BhanuPrakash, K.N., et al.: Analysis of ischemic stroke MR images by means of brain atlases of anatomy and blood supply territories. *AcadRadiol.* 13(8), 1025–1034 (2006).

Orrison Jr., W.W.: *Atlas of Brain Function*, 2nd ed. Thieme, New-York (2008).

P. D. Schellinger, R. N. Bryan, L. R. Caplan, et al., “Evidence-based guideline: the role of diffusion and perfusion MRI for the diagnosis of acute ischemic stroke: report of the Therapeutics and Technology Assessment Subcommittee of the American Academy of Neurology,” *Neurology*, vol. 75, no. 2, pp. 177–185, 2010

Patel, S. C. et al. Lack of clinical significance of early ischemic changes on MRI in acute stroke. *JAMA* 286, 2830–2838 (2001).

Schitzlein, H.N., Murtagh, F.R.: *Imaging Anatomy of the Head and Spine. A Photographic Color Atlas of MRI, CT, Gross, and Microscopic Anatomy in Axial, Coronal, and Sagittal Planes*, 2nd ed. Urban & Schwarzenberg, Baltimore (1990).

Shaw, Derek. 1984. *Fourier Transform N.M.R. Spectroscopy*, 2nd edition. Elsevier, Amsterdam, Netherlands.

Siesjo BK Free radicals and brain damage. *Cerebrovasc Brain Metab Rev.* 1989; 1:165-211

Siesjo BK Free radicals and brain damage. *Cerebrovasc Brain Metab Rev.* 1989; 1:165-211

Siesjö BK: Cell damage in the brain: a speculative synthesis. *J Cereb Blood Flow Metab.* 1981; 1:115-185.

Slichter, C.P. *Principles of Magnetic Resonance*, 2nd Edition, Springer-Verlag, New York, 1978.

Van Buren, J.M., Borke, R.C.: Variations and Connections of the Human Thalamus. Springer, Berlin (1972).

W. Hacke, M. Kaste, E. Bluhmki, et al., “Thrombolysis with alteplase 3 to 4.5 hours after acute ischemic stroke,” *The New England Journal of Medicine*, vol. 359, no. 13, pp. 1317–1329, 2008.

Wintermark, M. et al. Comparison of admission perfusion computed tomography and qualitative diffusion- and perfusion-weighted magnetic resonance imaging in acute stroke patients. *Stroke* 33, 2025–2031 (2009).

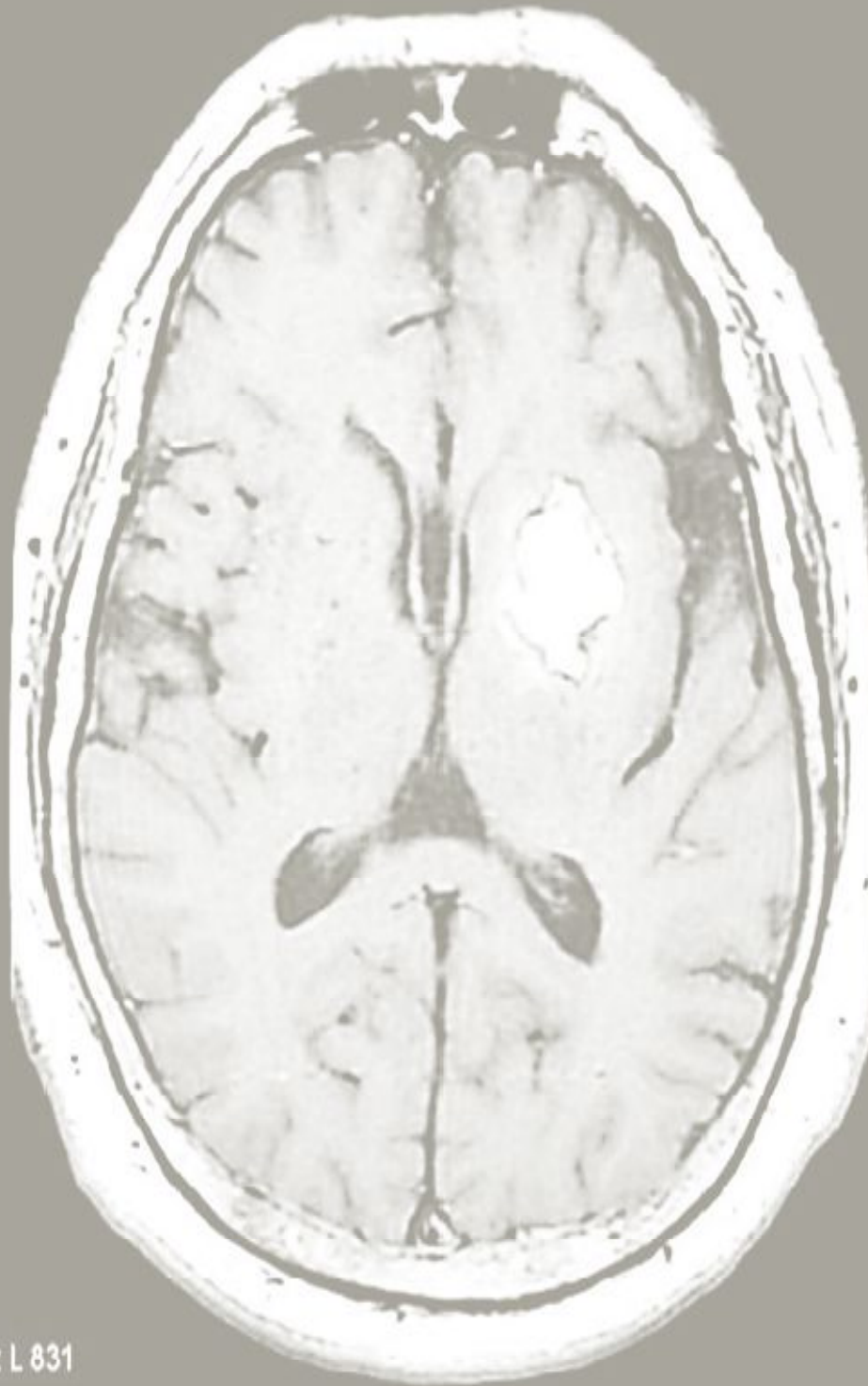Wise RJ, Bernardi S, Frackowiak RS, Legg NJ, Jones T. Serial observations on the pathophysiology of acute stroke: the transition from ischemia to infarction as reflected in regional oxygen extraction. *Brain*.

Woolsey, T.A., Hanaway, J., Mokhtar, H.G.: *The Brain Atlas: A Visual Guide to the Human Central Nervous System*, 2nd ed Wiley, New Jersey (2003).

Young, Ian R. 2000. Notes on Current Safety Issues in MRI. *NMR in Biomedicine* 13, 109–115.

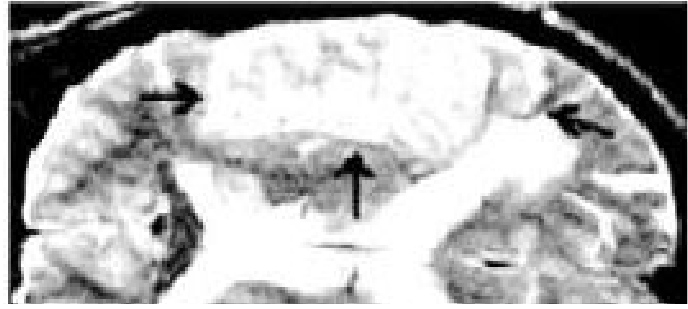Zivin JA, Choi DW. Stroke therapy. *Sci Med*. 1991;265:56-53.

13

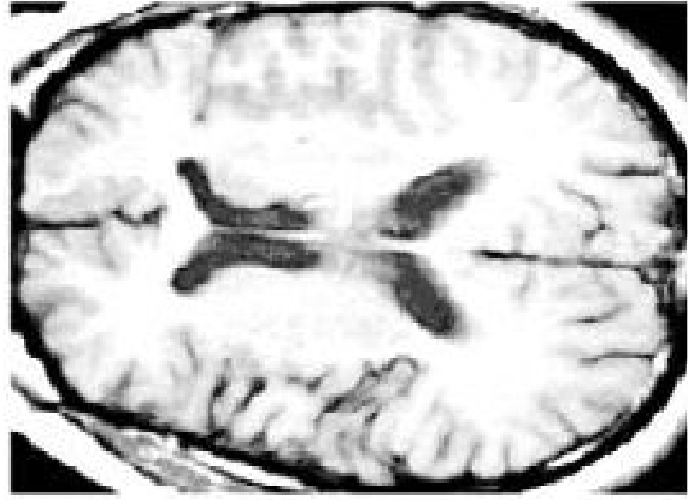

W 1542 : L 831

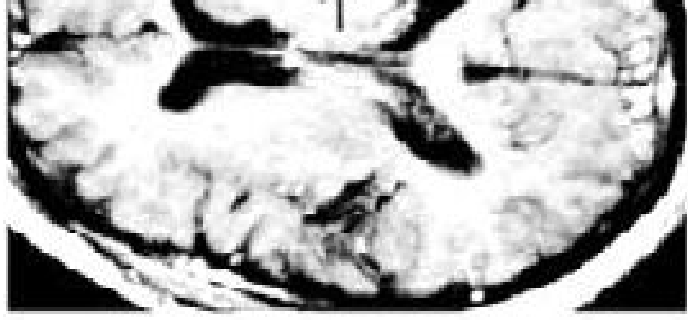# MRI of Acute Stroke



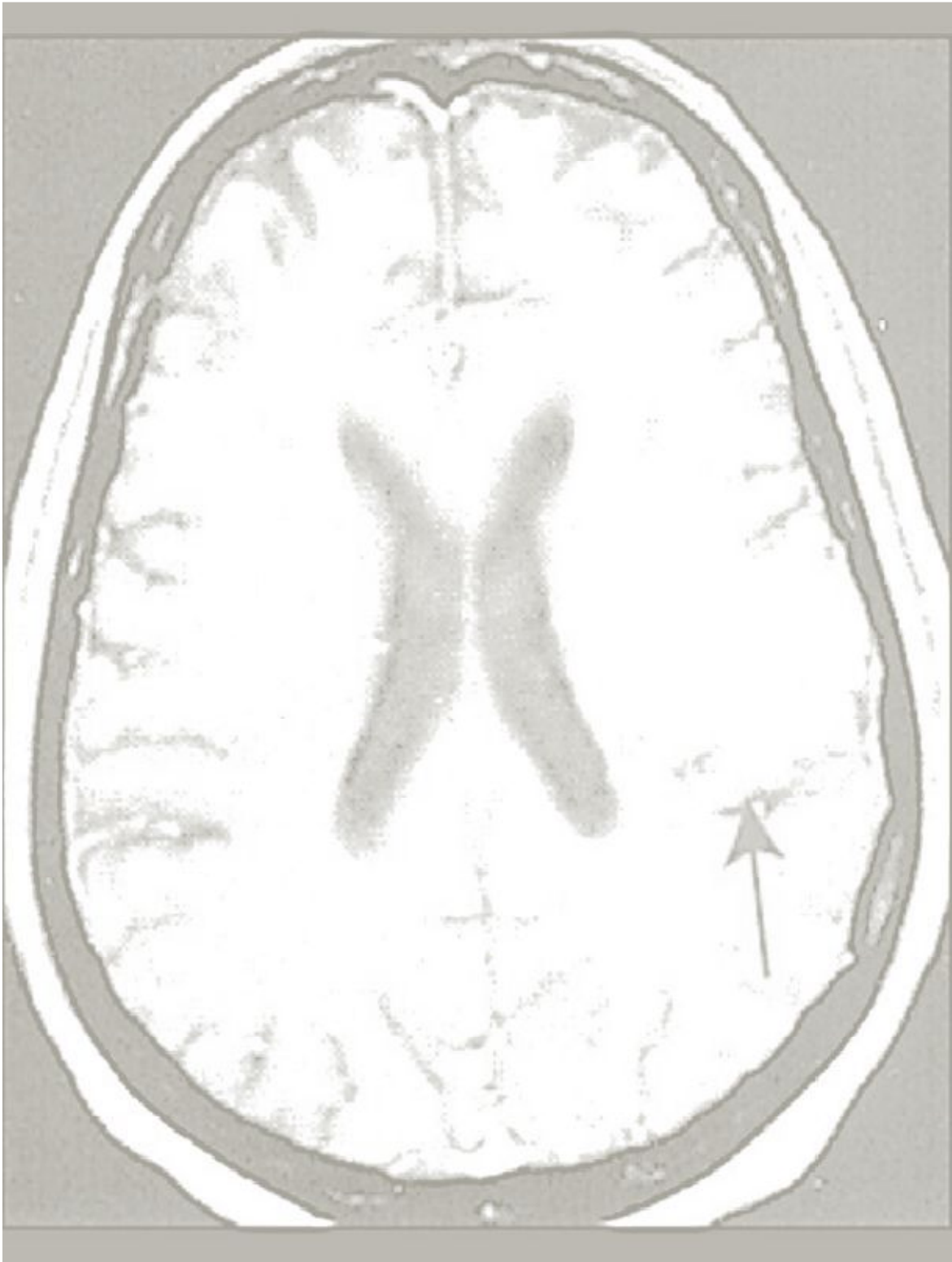
T2



T1-non



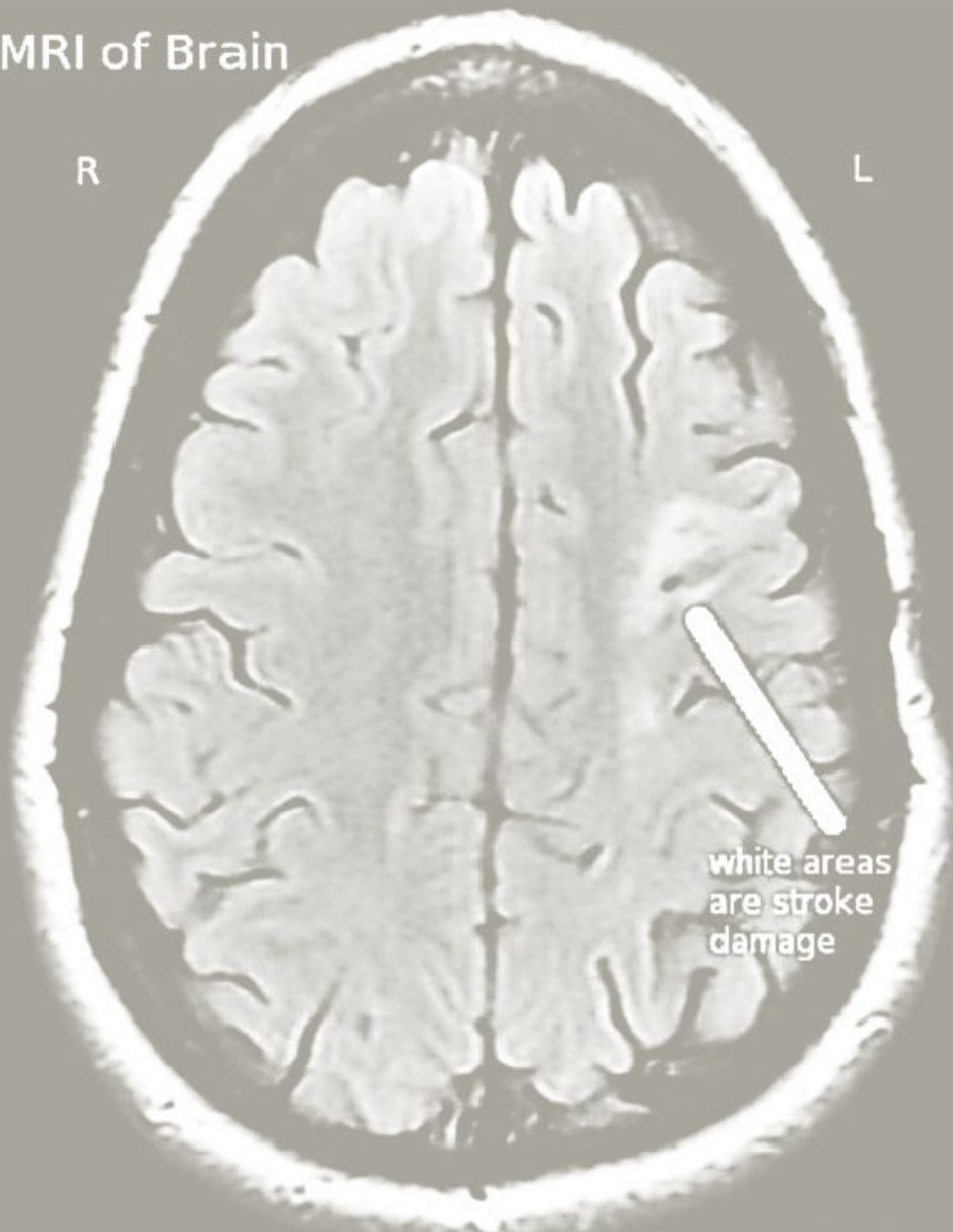
T1-gd



## MRI of Brain

R

L



white areas  
are stroke  
damage

Notice how much smaller than the right the left side is.