

Sudan university of science& technology

Collage of Graduate Studies

Chracterizaion of Gall Bladder Stones Using Ultra Sonography

توصيف حصاوي المرارة باستخدام التصوير بالموجات فوق الصوتية

Submitted for partial fulfillment for Requirement of m.sc. Degree in

Medical Diagnostic Ultrasound

By :

Thowiba Babiker Hamad Okair

Supervisor :

Dr .Asma Ibrahim Ahmed Elamin

Assistance prof

2016

Chapter One

introduction

Chapter two

Literature Review

Chapter three

Materials & Methods

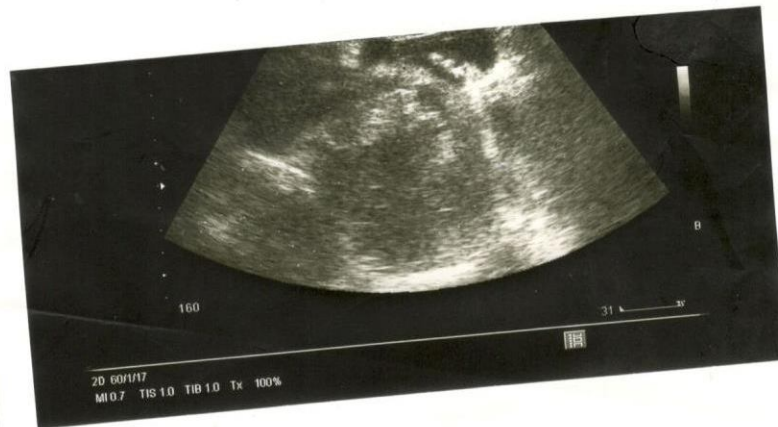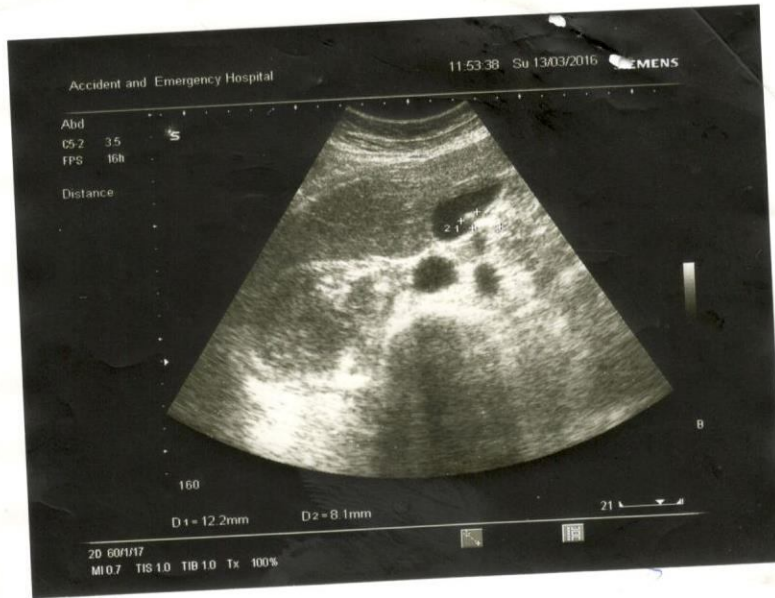
Chapter four

Results

Chapter Fives

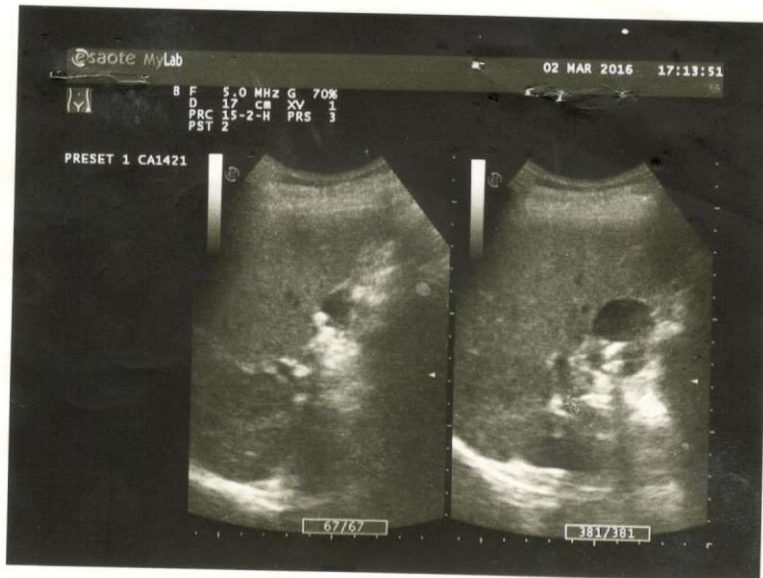Discussion, Conclusion and recommendations

Appendix(1) the related images

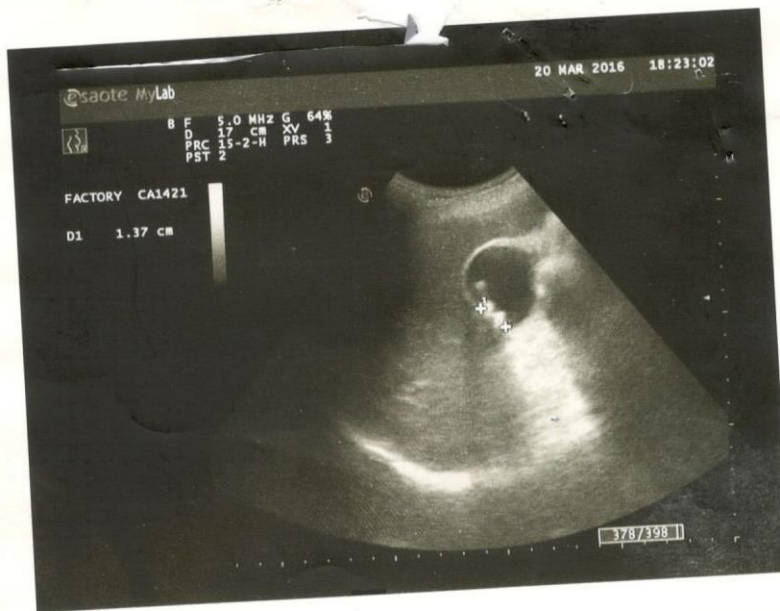


1_Through the right upper quaderant in 38 years old ,female with 63kg weight patient presented with epigastric pain demonstrated solitary gall stone ,normal gall thickening of gall bladder .severe tender ness in is noted in probing the gall bladder

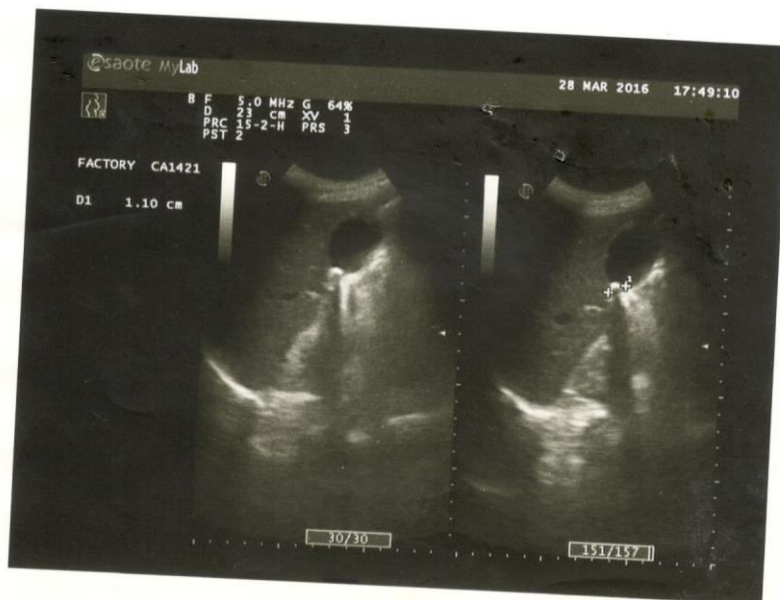fossa (murphy,s sign.pt presented with D.Mand hyper thyrodism.stone measured 1.2 mm and causing posterior acousting shadowing posteriorly.



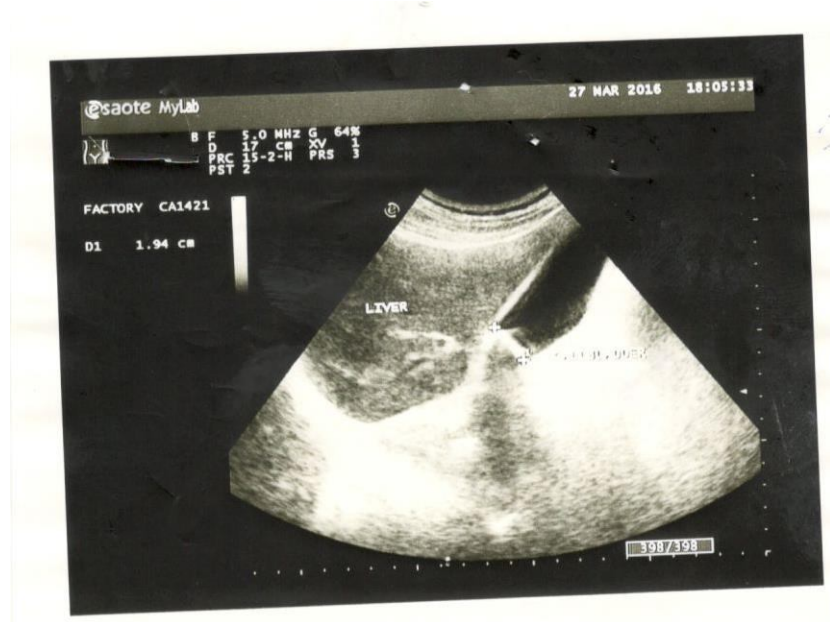
2-In 65 years old male pt with epigastric pain irradiated tp the back and right shoulder sonographically ,normalg.b size ,normal wall thickening with multiple calculi and posterior acoustic shadowing 12.2 mm and other is 8.1 mm pt is hypertensive and D.M with 63 kg weight .



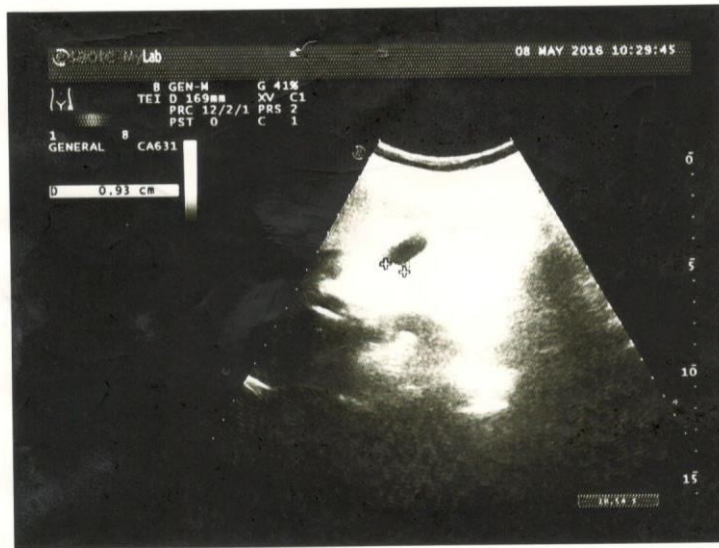3-In 51 .years old male of 79 kg weight presented with upper abdominal pain show multiple stones with posterior acoustic shadowing and normal g.b wall thikess. No perichole cystic fluid collection .Patient is hyper tensive .



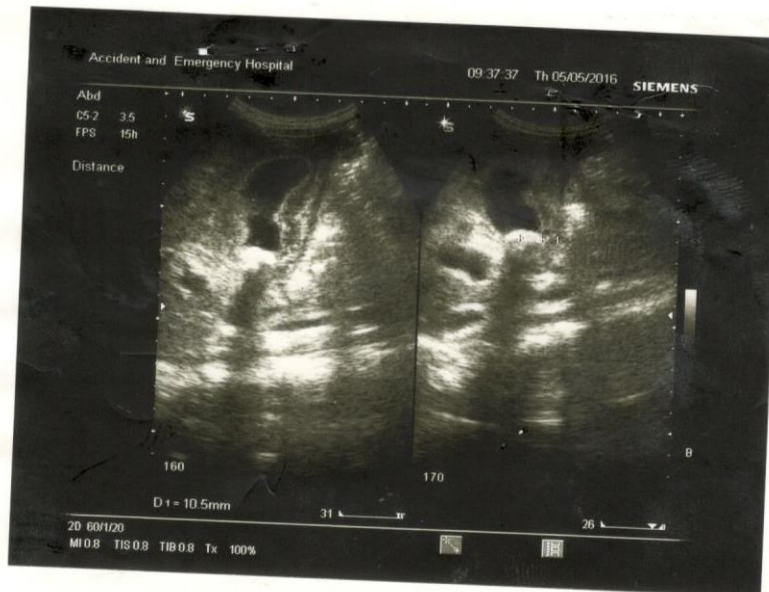4- In 52-years old male with right upper quadrant pain ,dyspepsia ,leucocytosis and HIV ,sonographically there is solitary stone measured 13mm in g.b neck causing posterior acoustic shadowing .Patient was 70 kg weight .



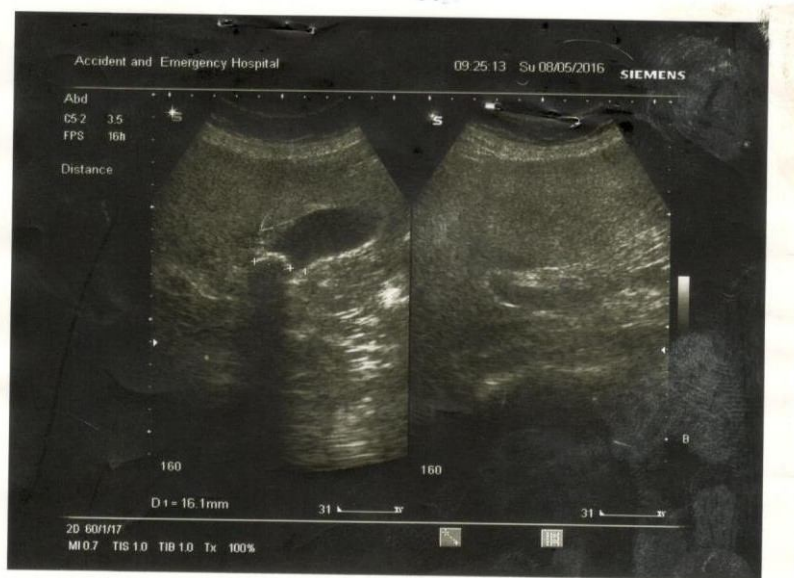5- In 79-years old male with 69kg ,pt complain of epigastric pain ,RUQ Pain and fatty food intolerance ,show an impacted stone in g.b neck measured 11m,with normal gall bladder wall thickening .Patient was Diabetes Mellitus and hypertensive .



6-Male of 75-years old presented with epigastric pain .longitudinal u/s scan revealed normal g.b size and 19.4 mm stone impacted at gall bladder neck patient have jaundice and Diabetis.Mellitus ,with 60kg weight .



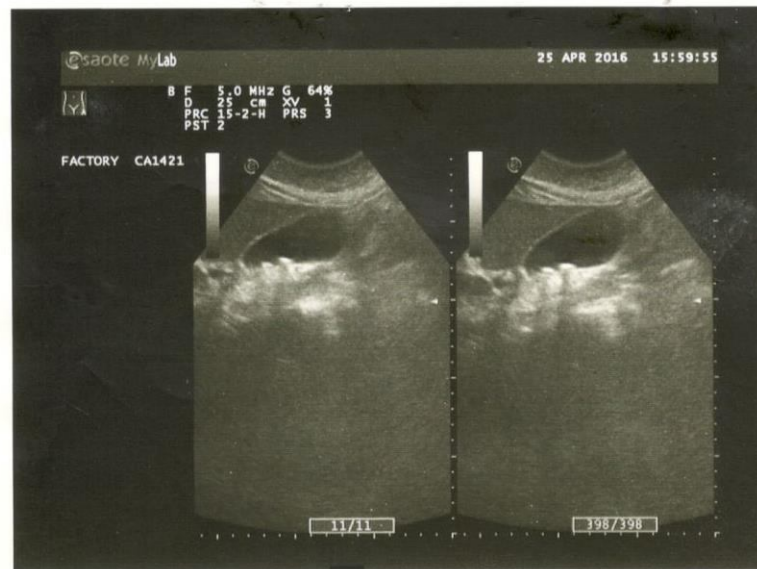
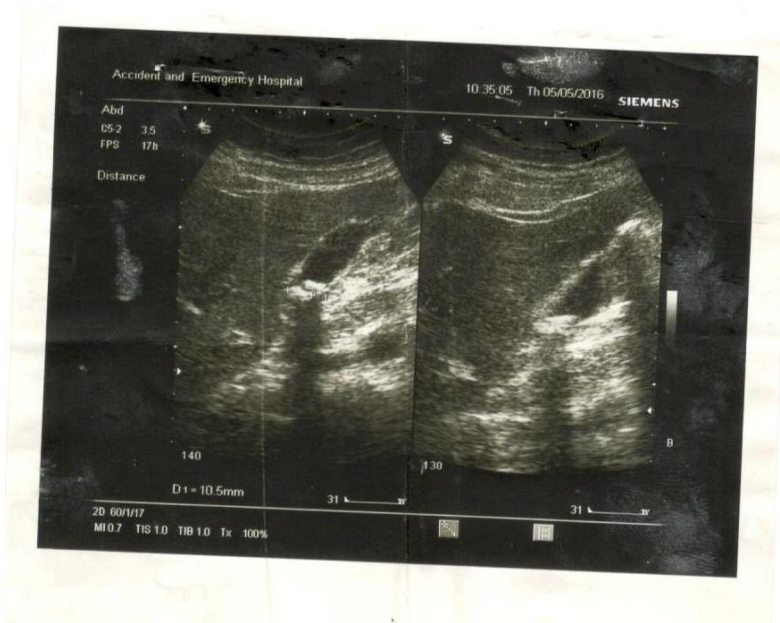7-Female pt of 73-years old ,90kg weight presented with sever RUQPain irradiated to right shoulder and fatty food intolerance longitudinal ultra sound scan show 0.93 cm stone impacted in gall bladder neck with no pericholecystic fluid collection .



8-longitudinal scan in female pt aged 53-years old ,72kg and HB+ve and DiabetisMellitus .patient t presented with vomiting,mild abdominal distention and tenderness in right hypo chonderium. gall containing 10.5 mm calculi impacted in gb neck .

9- Longitudinal and transverse scan in 43-years old and 70kg female that hospitalised for ciserean section and with multiple pregnancy .Sonographically gall bladder presented with 16mm stone with no gbwall thickening .She wsa complain

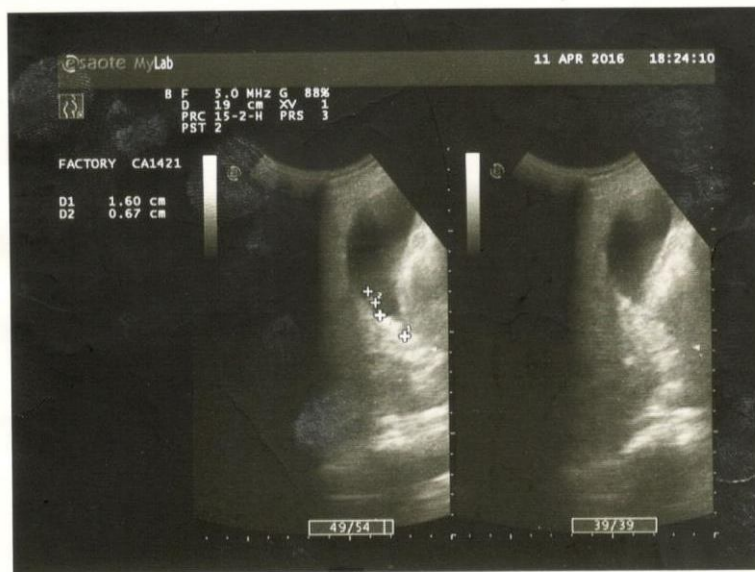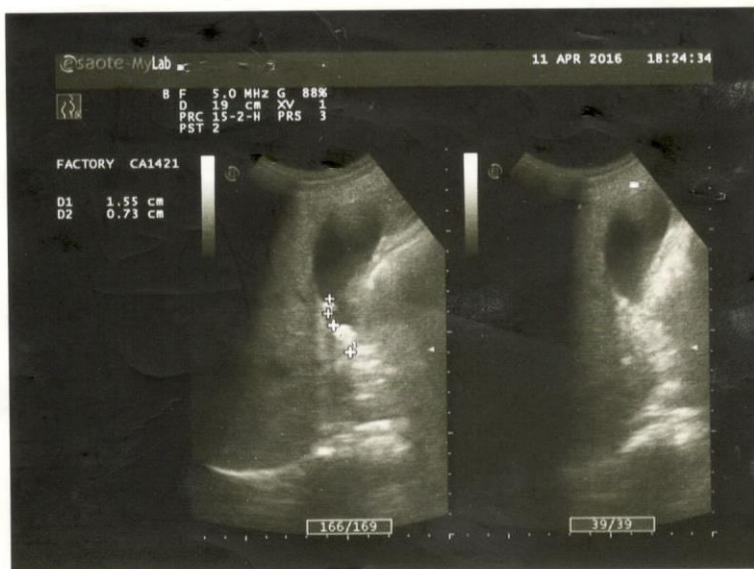of indigestion ,fatty food intolerance andRUQPain .Pt was diabetic and hpertensiv



10-Scanning of 39

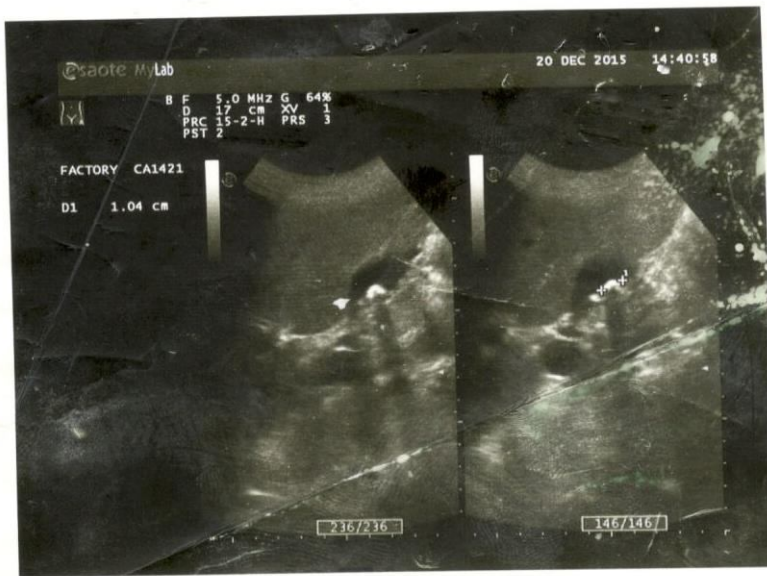-years

old female and 70kg weight ,ptcoplain of hyper thyrodism and HIV ,come with RUQPain ,nausea vomiting and +veMurphy,ssign.Sonographically there is 10.5 cm gall stone causing very strong acoustic shadowing .

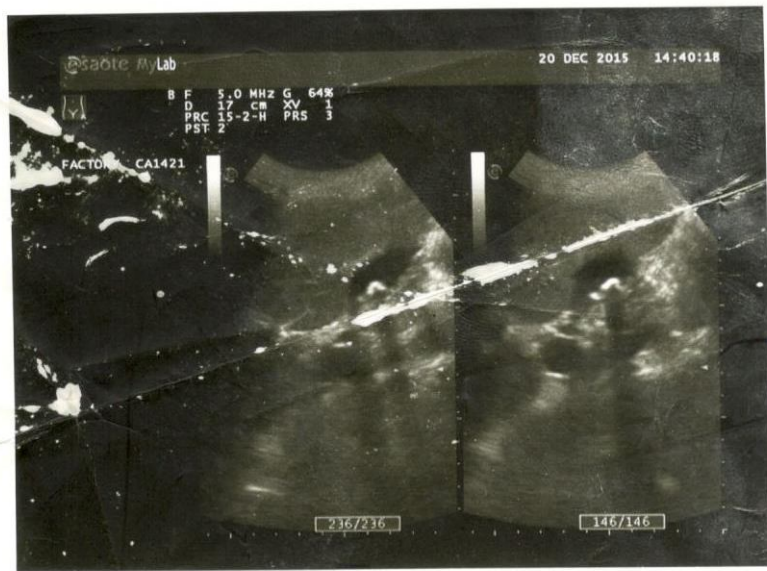



11-Scanning female

pt of 62-years old,57kg weight .pt presented with +veMurphy,s sign and severe tenderness when probing gb fossa.Pt have jaundice and hyper thyrodism.

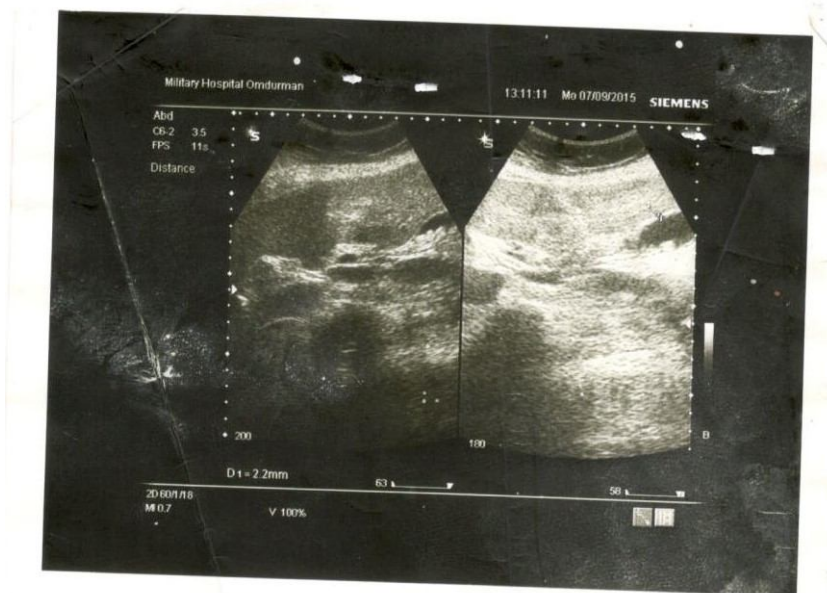

⑤





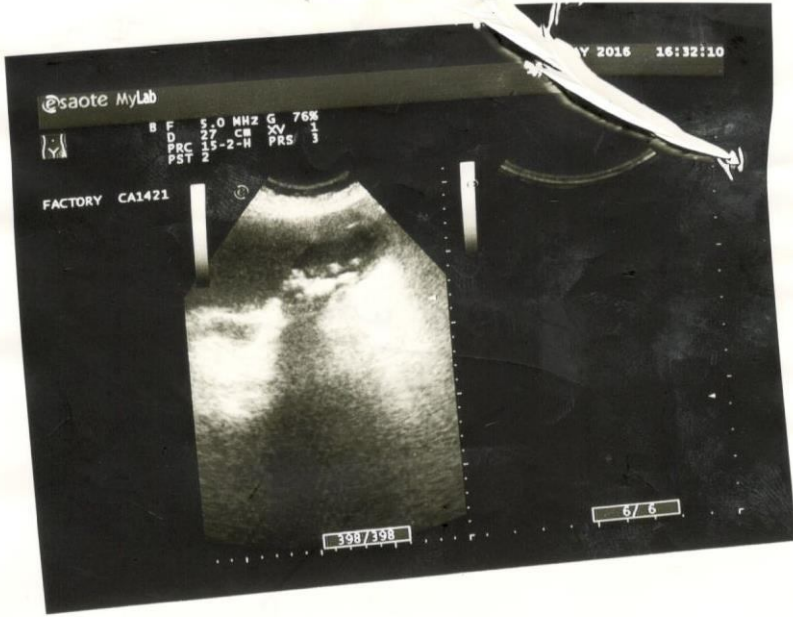
13-29-years old male with 87kg presented with RUQ Pain 1.4cm gall stone was noted on this diabetic pt



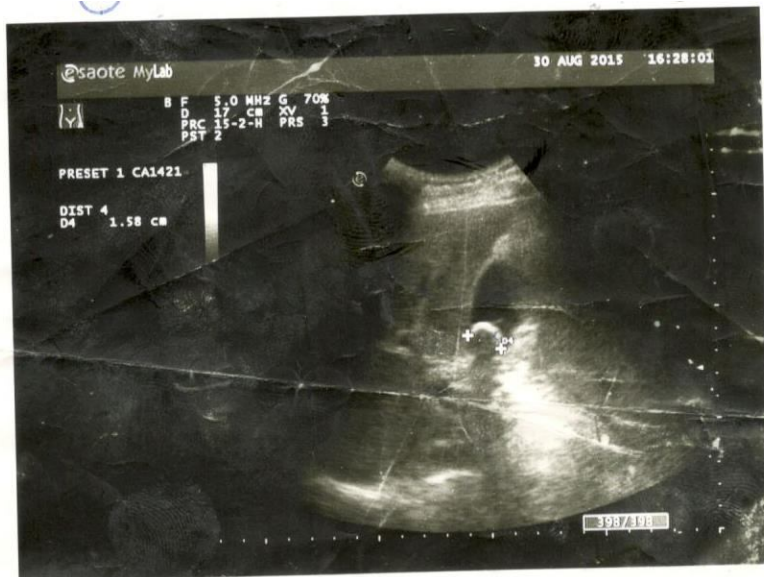14-scanning of 30-years old female patient t with 78kg weight ,pt presented with pain referred to the mid epigastrium and gall bladder dyspepsia ,gall bladder show 0.97 cm stone .Patient is already HIV.

15-Female of 42-years old and 72kg weight complain of nausea,vomiting ,gallb dyspepsia and RUQPain.2.2mm stone appear withgb wall thickening .

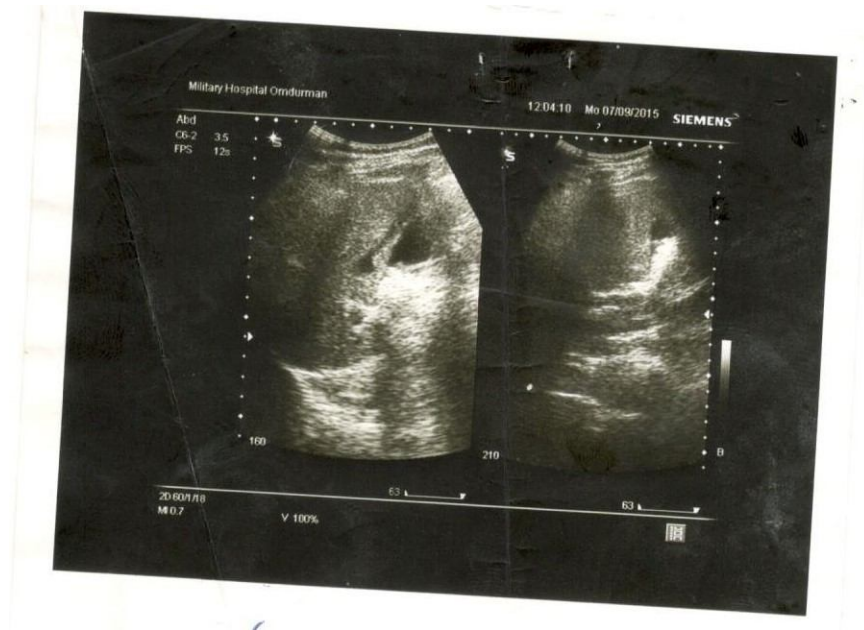
16-Male of 40years and 72kg reffered to u/s department with



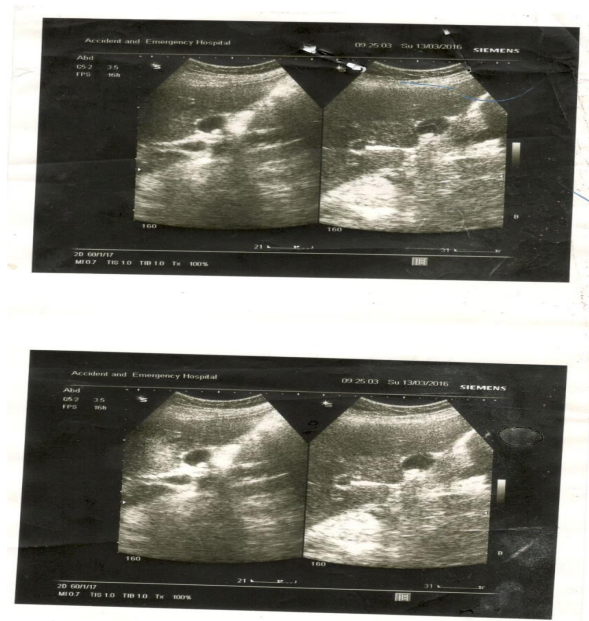abdominal colic fatty food intolerance .Sonographically 13.4 mm calculi appear in contracted gbcausin posterior acoustic shadowing in diabetic,htpertensive pt.



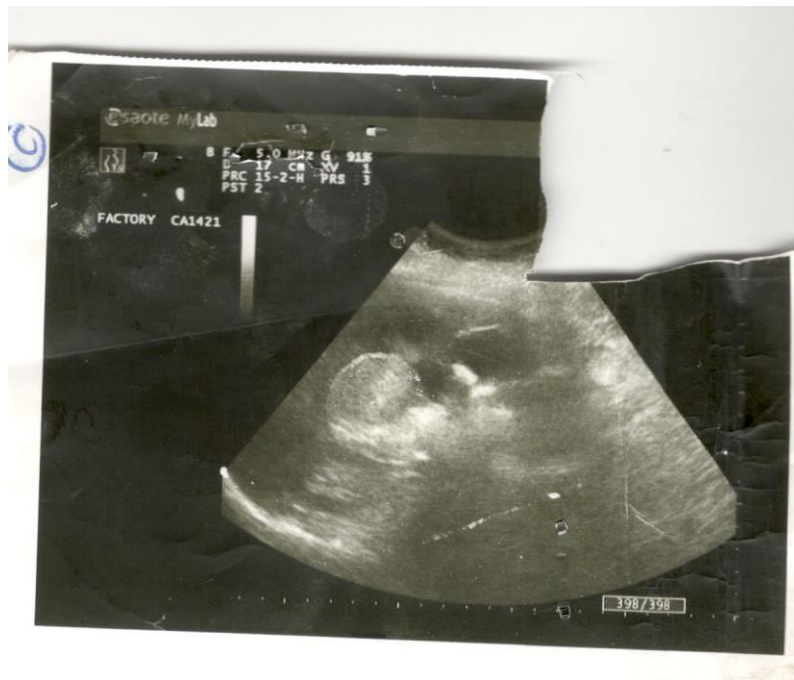17-Scanning of right upper quaderant area in 50years male with 82kg demonstrate multiple gb calculi causing posterior acoustic shadowing .Pt complain of RUQPain irradiated to right shoulder and scapula.



18-Female with 87kg and 49 years –old was scanned resulting in 1.5 cm gall stone causing posterior acoustic shadowing .Pt with multipplepregnancy .



19-Scanning of 40 yearsold - female of 60 kg weight complaning of nausea and vomiting demonstrated 5.4 mm stone impacted in gbneck.Pt was hyper thyrodism.



20_Female pt of 40years-old,60kg .Longitudinal scan of g.b showed 5.4cm stone impacted into gall bladder neck.Patient was complaining of nausea ,vomiting and RUQPain.

Appendix (2) Data sheet:

NO	Age	Gender	Weight	G.B.Stone	Symptoms	HIV	HTN	DM	H.T	Note
1	62	M	70	Solitary	Yellow discolorationof skin and sclera					Obstructive jaundice
2	67	F	70	Solitary	Vomiting	1				
3	29	F	88	Multiple	Biliarey					Diet
4	40	F	70	Solitary	Nausea-vomiting				1	
5	38	F	90	Multiple	Biliarey colic- nausea				1	
6	41	F	79	Solitary	Fatty food intolerance , pain in Rt shoulder and scapula					
7	32	F	60	Solitary	intolerance for fatty food , nausea – vomiting					

8	30	F	87	Solitary	R.U.Q pain				1	
9	49	F	70	Solitary	Rt U.Q. pain irradiated to Rt shoulder			1	1	
10	39	F	83	Solitary	Rt hypo chondrial pain, nausea - vomiting					
11	69	M	52	Solitary	Nausea – vomiting, epigastric pain					
12	29	F	80	Multiple	R.UQPain					Diet, estrogen therapy
13	45	F	92	Multiple	Indigestion - nausea -vomiting				1	Multiple pregnancy
14	30	F	89	Multiple	Biliary colic - indigestion, fatty food intolerance				1	
15	54	F	89	Multiple	Rt U.Q pain			1	1	

					irradiated to Rt shoulder& scapula					
1	37	F	89	Solitary	Rt U.Q pain Nausea – vomiting					Lap finding U/S finding
6	9	M		Solitary	Nausea -vomiting , abdominal colic					Sickle cell anemia
17	79	M	62		Rt Q.P refered to rt scapula & shoulder			1		Liver cirrhosis Alcoholic
18	69	M	79	Solitary	Rt u Q.P refered to scapula & shoulder					
19	52	F	60	Solitary	Nausea,epigastric pain					
20	39	F	69	Multiple	Fever chills , Rt U.Q pain epigastric pain					Cirrhosis
21	39	F	70	Multiple	Rt U.Q. pain biliary colic,					Multiple pregnancy

					nausea					
22	79	M	70	Solitary	Rt U.Q. pain with vomiting		1	1	1	
23	52	M	49	Solitary			1			Thalassemia
24	45	F	64	Solitary	G.B dyspepsia , Rt U.Q. pain					
25	38	F	63	Solitary	Epigastric pain			1	1	
26	40	F	60	Solitary	Nausea -vomiting , Rt U.Q. pain irradiated to shoulder				1	
27	49	F	87	Solitary	Pain referred to the mid epigastric area , nausea-vomiting					Multiple pregnancy
28	50	M	82	Multiple	Rt U.Q. pain irradiated to Rt shoulder and scapula		1	1		
29	40	M	72	Solitary	Fatty food		1	1	1	

					intolerance					
30	42	F	87	Multiple	Nausea -vomiting G.B dyspepsia					
31	29	F	78	Solitary	Pain referred to the mid epigstric – G.B dyspepsia	1				Carotid obstruction
32	29	M	87	Multiple	Nausea – vomiting RtU.Lt Q. pain			1		
33	62	F	57	Multiple	Saver pain and tendeness in Rthypochonderium +vmuprhy’s sign,				1	Jaundice
34	62	F	66	Multiple	Nausea, Rt.U.Q pain			1	1	
35	39	F	70	Solitary	Rt.U.Q pain, murphy’s sign, nausea and vomiting				1	
36	43	F	70	Solitary			1	1		Multi

										pregnancy
37	53	F	72	Solitary	Vomiting-mild abdominal distention – tenderness in R.U.Q.Pain		1			HB +ve
38	43	F	90	Solitary	Rt U.Q pain irradiated to Rt shoulder , fatty food intolerance			1		
39	75	M	60	Solitary	Epigastric pain			1		Jaundice
40	79	M	69	Solitary	Epigastric pain, Rt U.Q pain, food intolerance		1	1		
41	52	M	70	Solitary	Epigastric pain, Rt upper Q. pain irradiated to Rt shoulder	1				
42	51	M	79	Multiple	Upper abdominal		1			

					pain					
43	56	M	63	Multiple	Epigastric pain		1	1		
44	79	M	59	Multiple	Epigastric pain					Cirrhosis
45	42	F	72	Solitary	Epigastric pain					Clofibrate
46	40	F	85	Solitary	Upper abdominal pain		1			
47	39	F	90	Solitary	Epigastric pain, Rt upper Q. pain irradiated to Rt shoulder					
48	45	M	65	Multiple	Rt U.Q pain irradiated to Rt shoulder , fatty food intolerance			1		Cirrhosis
49	48	M	60	Multiple	Epigastric pain		1			
50	63	F	70	Solitary	Epigastric pain		1			