

# Chapter One

## 1.1 Introduction:

There is increasing interest in the radiological diagnosis of axillary lymph nodes in patients with breast cancer, especially in the preoperative diagnosis of metastatic nodes. Both CT (computed tomography) and MRI (magnetic resonance imaging) are cross-sectional imaging methods that produce high-quality images of the axilla. MRI also uses contrast enhancement profile, for example in imaging of breast lesions. Few studies have been published on this subject, but the latest have shown high sensitivity and specificity (CT and MR although, both CT and MRI are restricted to imaging only. US (ultrasound) is widely spread and is fast and accurate with high resolution. Sensitivity and specificity vary. Most importantly, there is the possibility of US-guided FNAB (fine-needle aspiration biopsy) of pathological nodes, which increases the specificity. Initial results with colour Doppler are promising, but a recent study has shown that the presence of colour Doppler flow signal is highly non-specific. Other parameters such as flow pattern and distribution may prove to be of value in this method. Today, the method of choice for the daily routine is US in conjunction with FNAB.

The cause of lymphadenopathy is often obvious: for example, the child who presents with a sore throat, tender cervical nodes and a positive rapid strep test, or the patient who presents with an infection of the hand and axillary lymphadenopathy. In other cases, the diagnosis is less clear. Lymphadenopathy may be the only clinical finding or one of several nonspecific findings, and the discovery of swollen lymph nodes will often raise the specter of serious illness such as lymphoma, acquired immunodeficiency syndrome or metastatic cancer. The physician's task is to efficiently differentiate the few patients with serious

illness from the many with self-limited disease. This reviews the evaluation of patients with a central clinical finding of lymphadenopathy, emphasizing the identification of patients with serious illness.

The body has approximately 600 lymph nodes, but only those in the submandibular, axillary or inguinal regions may normally be palpable in healthy people. Lymphadenopathy refers to nodes that are abnormal in size, consistency or number. There are various classifications of lymphadenopathy, but a simple and clinically useful system is to classify lymphadenopathy as "generalized" if lymph nodes are enlarged in two or more noncontiguous areas or "localized" if only one area is involved. Distinguishing between localized and generalized lymphadenopathy is important in formulating a differential diagnosis. In primary care patients with unexplained lymphadenopathy, approximately three fourths of patients will present with localized lymphadenopathy and one fourth with generalized lymphadenopathy Figure 1.

Our understanding of the epidemiology of lymphadenopathy in family practice is limited by the scarcity of relevant literature. Only one study<sup>4</sup> provides reliable population-based estimates. Findings from this Dutch study revealed a 0.6 percent annual incidence of unexplained lymphadenopathy in the general population. Of 2,556 patients in the study who presented with unexplained lymphadenopathy to their family physicians, 256 (10 percent) were referred to a subspecialist and 82 (3.2 percent) required a biopsy, but only 29 (1.1 percent) had a malignancy.

The algorithm in Figure 2 provides a diagnostic framework for the evaluation of lymphadenopathy. The algorithm emphasizes that a careful history and physical examination are the core of the evaluation. In most cases, a careful history and physical examination will identify a readily diagnosable cause of the lymphadenopathy, such as upper respiratory tract infection, pharyngitis, periodontal disease, conjunctivitis, lymphadenitis, tinea, insect bites, recent

immunization, cat-scratch disease or dermatitis, and no further assessment is necessary (see the "diagnostic" branch of the algorithm).

In other cases, a definitive diagnosis cannot be made on the basis of the history and physical examination alone; however, the clinical evaluation may strongly suggest a particular cause. Confirmatory testing should be performed in order to correctly identify the patient's illness (see the "suggestive" branch of the algorithm).

## **1.2 Problem of the study:**

The axillary (arm pit) lymph nodes filter and/or trap lymph from the arm, chestwall and breast. It is often difficult to feel normal axillary lymph nodes. Not all enlarged axillary lymph nodes feel the same. It is also important to mention that enlarged axillary lymph nodes are not necessarily a sign of cancer. However, we strongly advise you to consult with a medical provider if you are concerned about enlarged axillary lymph nodes.

## **1.3 -Objective of the study**

### **1.3.1 General objective**

To Characterize the enlargement of axillary lymph nodes

### **1.3.2 specific objectives**

- To measure the size of lymph node
- To evaluate the efficiency of ultrasound in diagnosing axillary lymph node
- To evaluate the axillary lymph node echogenicity and texture

- To correlate the findings with history of certain conditions, such as, hormonal therapy at any period of life.

-to compare the postoperative morbidity and socioeconomic impact of sentinel lymph node biopsy (SLNB) with axillary lymph node dissection (ALND) in patients with early stage breast cancer.

# Chapter Two

## Theoretical Back Round

### 2.1 Anatomy of axillary lymph node:

The **axillary lymph nodes** or **armpit lymph nodes** (20 to 30 in number) drain lymph vessels from the lateral quadrants of the breast, the superficial lymph vessels from the walls of the chest and the abdomen above the level of the navel, and the vessels from the upper limb. They are divided in several groups according to their location in the armpit. These lymph nodes are clinically significant in breast cancer, and metastases from the breast to the axillary lymph nodes are considered in the staging of the disease.

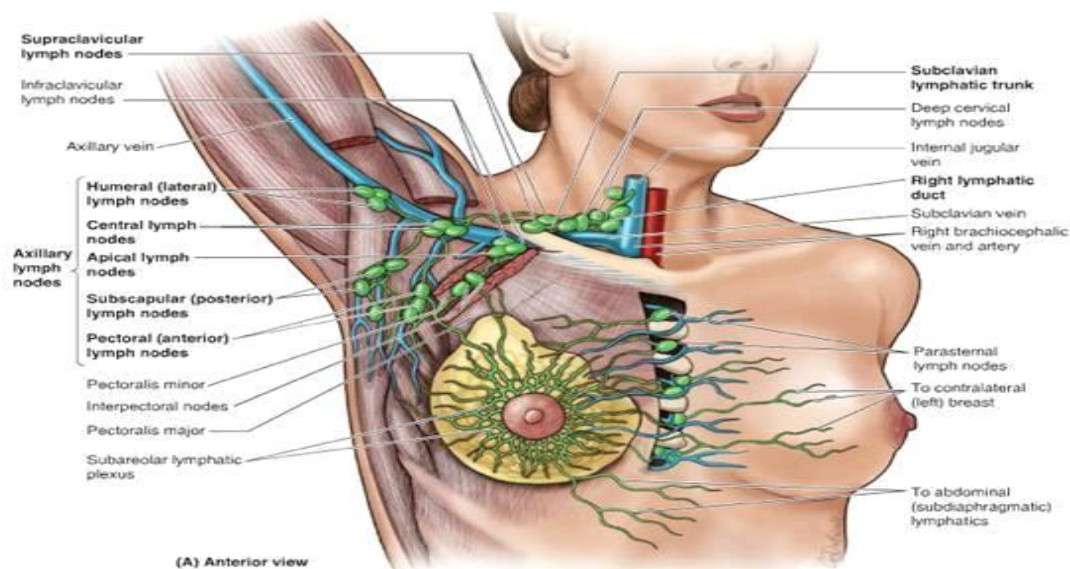


Figure 2.1(Anatomy of axillary lymph node)

## 2.1.2 Lymphatic drainage of the upper limb.

is via series of deep and superficial channels that ultimately drain into the axillary lymph nodes.

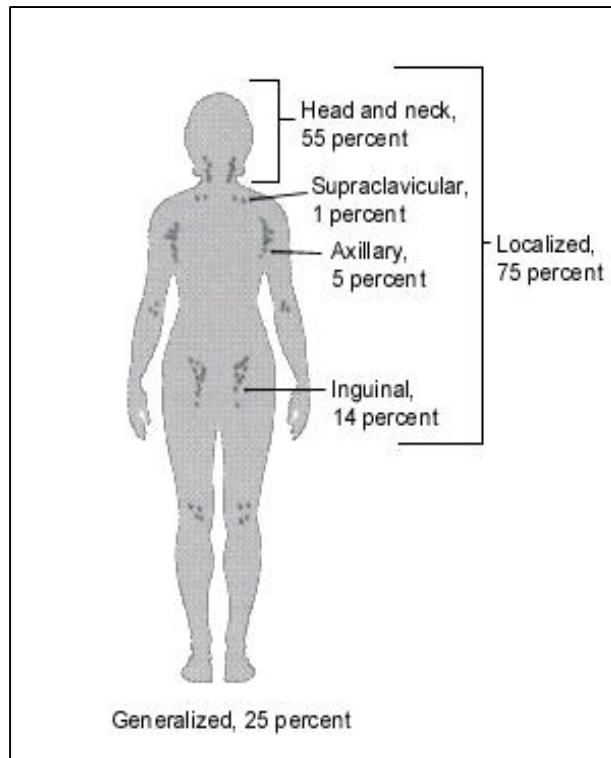
Lymph from the hand and forearm drain from lymphatic plexuses via superficial channels that accompany the basilic and cephalic veins to a series of nodes around the elbow:

### **superficial and deep cubital lymph nodes**

#### **epi/supratrochlear lymph node(s)**

one-to-five nodes lying medial to the brachial vein, just superior to the medial epicondyle of the humerus

There are also deep channels that accompany the arteries and drain via the occasional deep lymph node accompanying arteries in the forearm to the axillary nodes.



**Figure 2.2 Presentation of lymphadenopathy by anatomic site (in percentages).**

### **2.1.3 Anatomically it is divided into 6 groups:**

- **Anterior (pectoral) group:** Lying along the lower border of the pectoralis minor behind the pectoralis major, these nodes receive lymph vessels from the lateral quadrants of the breast and superficial vessels from the anterolateral abdominal wall above the level of the umbilicus.

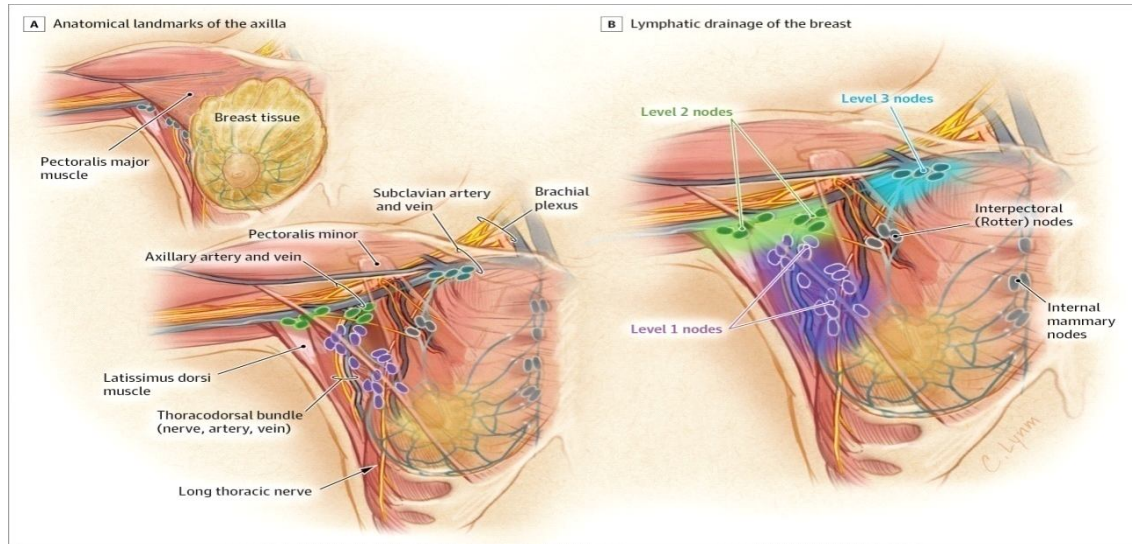
**2.1.3.1 Posterior (subscapular) group:** Lying in front of the subscapular muscle, these nodes receive superficial lymph vessels from the back, down as far as the level of the iliac crests.

**2.1.3.2 Lateral group:** Lying along the medial side of the axillary vein, these nodes receive most of the lymph vessels of the upper limb (except those superficial vessels draining the lateral side—see infraclavicular nodes, below).

**2.1.3.3 Central group:** Lying in the center of the axilla in the axillary fat, these nodes receive lymph from the above three groups.

**2.1.3.4 Infraclavicular (deltopectoral) group:** These nodes are not strictly axillary nodes because they are located outside the axilla. They lie in the groove between the deltoid and pectoralis major muscles and receive superficial lymph vessels from the lateral side of the hand, forearm, and arm.

**2.1.3.5 Apical group:** Lying at the apex of the axilla at the lateral border of the 1st rib, these nodes receive the efferent lymph vessels from all the other axillary nodes.



**Figure 2.3 (Apical group)**

## **2.2 Axillary lymph node enlargement**

**2.2.1 Location:** Located in the axillae (arm pits).

**2.2.2 Lymphatic drainage:** Arm, thoracic wall, breast.

**2.2.3 Common causes:** Infections, cat-scratch disease, lymphoma, breast cancer, silicone implants, brucellosis, melanoma Some of the causes of axillary lymphadenopathy

### **2.2.3.1 Bacterial**

localized infection, possibly somewhere in the arm or breast draining into the glands of the armpit, or infection within the armpit itself

cat scratch disease

ascending lymphangitis

lymphadenitis, lymphangitis



### **2.2.3.2 Viral**

infectious mononucleosis

chickenpox

herpes zoster (shingles)

HIV disease (AIDS)

### **2.2.3.3 Malignant**

Hodgkin's lymphoma

non-Hodgkin's lymphoma

leukemia

Breast cancer

Lung cancer

### **2.2.3.4 Fungal**

sporotrichosis

### **2.2.3.5 Antigenic**

smallpox vaccination

typhoid vaccine

measles, mumps, rubella vaccine (rare)

allergic reaction possibly caused by sulfa drugs, iodine, or penicillin

## **Lymph Node Enlargement:**

### **2.2.4 Causes of generalized lymphadenopathy**

Editors

Note:

Generalized lymphadenopathy is always a puzzling entity. The presence of fever

may suggest an infectious cause or lymphoma. The presence of rash may suggest an infectious or autoimmune process. Request a full blood count to exclude hematological causes. A lymph node biopsy is needed if the picture is suggestive of lymphoma.

Essentially 5 broad etiologic categories lead to lymph node enlargement (Ghirardelli, 1999).<sup>(6)</sup>

An immune response to infective agents (eg, bacteria, virus, fungus)

Inflammatory cells in infections involving the lymph node

Infiltration of neoplastic cells carried to the node by lymphatic or blood circulation (metastasis)

Localized neoplastic proliferation of lymphocytes or macrophages (eg, leukemia, lymphoma)

Infiltration of macrophages filled with metabolite deposits (eg, storage disorders)

### **2.2.5 Infections**

Infectious mononucleosis.

Cytomegalovirus may cause a syndrome similar to infectious mononucleosis.

TB: In a child with tuberculosis, generalized lymphadenopathy may indicate hematogenous spread of tubercle bacilli.

Brucellosis may accompany chronic or intermittent lymphadenopathy.

Salmonella infection can correspond to generalized adenopathy.

Tularemia may be accompanied by regional or generalized adenopathy, most commonly cervical, with local tenderness, pain, and fever.

Bubonic plague is caused by *Y pestis*.

## **2.2.6 Immunologic or connective tissue disorders**

Juvenile rheumatoid arthritis should be considered in unexplained fever and persistent lymphadenopathy in a child.

Serum sickness can correspond with generalized tender lymphadenopathy.

Chronic graft versus host disease.

## **2.2.7 Primary disease of lymphoid or reticuloendothelial tissue**

Acute leukemia

Hodgkin disease

Non-Hodgkin lymphoma

Lymphosarcoma

Nonendemic Burkitt tumor

Nasopharyngeal rhabdomyosarcoma

Neuroblastoma

Reticulum cell sarcoma

Malignant histiocytosis or histiocytic lymphoma

Thyroid carcinoma, chronic lymphocytic thyroiditis

Histiocytosis X

Benign sinus histiocytosis

Angioimmunoblastic or immunoblastic lymphadenopathy

Chronic pseudolymphomatous lymphadenopathy (chronic benign lymphadenopathy)

## **2.2.8 Immunodeficiency syndromes**

Acquired immunodeficiency syndrome

Chronic granulomatous disease of childhood

Hyperimmunoglobulin E (Job) syndrome

## **2.2.9 Metabolic and storage diseases**

Gaucher disease

Histiocytosis X

Cystinosis

Niemann-Pick disease

## **2.2.10 Hematopoietic diseases**

Thalassemia

Congenital hemolytic anemia

Autoimmune hemolytic anemia

Sickle cell anemia

## **2.2.11 Other disorders**

Sarcoidosis demonstrate either generalized or hilar lymphadenopathy.

Drug: mesantoin, hydantoin use may produce lymphadenopathy as an adverse effect.

Castleman disease or benign giant lymph node hyperplasia may cause lymphadenopathy in the mediastinum, abdomen, neck, or axilla.

Kawasaki disease.

History:

The physician should consider four key points when compiling a patient's history. First, are there localizing symptoms or signs to suggest infection or neoplasm in a specific site? Second, are there constitutional symptoms such as fever, weight loss, fatigue or night sweats to suggest disorders such as tuberculosis, lymphoma, collagen vascular diseases, unrecognized infection or malignancy? Third, are there epidemiologic clues such as occupational exposures, recent travel or high-risk behaviors that suggest specific disorders? Fourth, is the patient taking a medication that may cause lymphadenopathy? Some medications are known to specifically cause lymphadenopathy (e.g.,

phenytoin [Dilantin]), while others, such as cephalosporins, penicillins or sulfonamides, are more likely to cause a serum sickness-like syndrome with fever, arthralgias and rash in addition to lymphadenopathy (Table 1).

<b>TABLE 2.1</b>	
<b>Medications That May Cause Lymphadenopathy</b>	
<b>Allopurinol (Zyloprim)</b>	<b>Penicillin</b>
<b>Atenolol (Tenormin)</b>	<b>Phenytoin (Dilantin)</b>
<b>Captopril (Capozide)</b>	<b>Primidone (Mysoline)</b>
<b>Carbamazepine (Tegretol)</b>	<b>Pyrimethamine (Daraprim)</b>
<b>Cephalosporins</b>	<b>Quinidine</b>
<b>Gold</b>	<b>Sulfonamides</b>
<b>Hydralazine (Apresoline)</b>	<b>Sulindac (Clinoril)</b>
<p><b>Adapted with permission from Pangalis GA, Vassilakopoulos TP, Boussiotis VA, Fessas P. Clinical approach to lymphadenopathy. SeminOncol 1993; 20:570-82.</b></p>	

### **2.3 Axillary lymph node metastases in breast cancer preoperative detection with US**

The importance of axillary node status in the prognosis of breast cancer led the authors to conduct a prospective study comparing the value of clinical

examination with ultrasound (US) performed by a transpectoral approach. All 50 patients examined underwent axillary dissection. Sensitivity was 45.4% for clinical examination versus 72.7% for US. US provides valuable information for breast cancers treated solely by irradiation, after insufficient dissection, and for large tumors not amenable to primary surgery. When the nodal region is treated by surgery and/or radiotherapy, local monitoring with US appears unnecessary owing to the low incidence of nodal recurrence.

### **2.3.1 Morbidity following Sentinel Lymph Node Biopsy versus Axillary Lymph Node Dissection for Patients with Breast Carcinoma**

Axillary lymph node dissection (ALND) in patients with breast carcinoma is performed mainly for staging purposes and to determine the need for adjuvant treatment. Furthermore, it plays a role in local tumor control in the axilla, whereas its impact on disease free survival or overall survival has yet to be determined. The routine performance of axillary dissection in patients with breast carcinoma has been questioned due to the relatively high postoperative morbidity rate resulting from the procedure and because most patients are treated with adjuvant therapy irrespective of their lymph node status. The morbidity associated with ALND has led to a search for new methods that can stage the axilla accurately but are associated with minor postoperative sequelae. Preliminary studies have shown that sentinel lymph node (SLN) biopsy may stage the axilla accurately. SLN biopsy is cost effective, is associated with a shorter postoperative time, and should decrease morbidity compared.

### **2.3.2 Imaging of Axillary Lymph Nodes**

In breast imaging, the role of axillary imaging has undergone change during the past decade. In earlier years, interest in axillary imaging was limited because pathological lymph nodes found in the axilla were not considered to have any implications for the therapy of the patient. Today, with therapy becoming more refined and with the advent of the sentinel node technique, radiological diagnosis of pathological lymph nodes has become increasingly important, especially preoperative diagnosis. In a breast-imaging center today, the mammographer has access to US (ultrasound), and probably to CT (computed tomography) and MRI (magnetic resonance imaging). This article presents an overview of axillary imaging from my horizon as a clinical radiologist/mammographer in a breast-imaging centre with about 4 000 referred (only) patients per year. In mammography, lymph nodes are visible on standard projections, and it is possible to differentiate between normal and pathological nodes. Normal nodes are common and moderately attenuated, the fatty hilus being seen as a low attenuated part. Normal nodes can vary in size, from a few millimetres to several centimetres. Pathological nodes are of greater density than normal nodes, and the hilus disappears. The form also becomes more expansive—oval to round—but the size is not necessarily increased. However, in the standard projections, only part of the axilla can be seen, and during exposure of the mammogram, pathological nodes can be pushed outside the mammographic image. Mammography is therefore not a reliable method in axillary lymph node imaging. Computed tomography of the axillae can be done, but is seldom indicated as a separate examination. When CTscanning of the thorax is carried out, the axillary regions are included. The arms are preferably hyperadducted, to avoid streak artefacts. The axillae are readily seen, and the lymph nodes clearly visible, lying in the axillary fat. Pathological

nodes appear as enlarged focal densities, possibly confluent. Earlier, the normal size was limited to one centimetre, and in a study from 1991 the sensitivity was 50% and the specificity 75%, but the negative predictive value (NPV) was low. In a recent study the criterion was one or more nodular lesions of at least 5 mm in diameter of a short axis. Lymph nodes replaced at the center by fat were not considered to be pathologic, even if they were greater than 5 mm in diameter of the short axis. This improved the results, the sensitivity for involved nodes being 93.8% and the specificity 82.1%; the NPV also improved. CT is useful in a subgroup of patients where lesions are large and invasion in the thoracic wall is suspected. Evaluation of inflammatory cancer and the monitoring of responses to therapy can also be carried out using CT. When the axilla cannot be palpated, owing to previous treatment, CT can again be of value.

One of the advantages of using CT is that there is a large field of view, so abnormalities can be detected in both of the axillae, but also in the mediastinum, the lungs, the parasternal nodes, the periclavicular nodes and the skeleton. No contrast media are needed. A disadvantage is that the criterion for pathological nodes is limited to the size of the nodes. Magnetic resonance imaging is becoming an increasingly valuable tool in selected groups of breast cancer patients. Normally, the examination is conducted with the patient in the prone position, with special breast coils in place. This facilitates the imaging of the mammary tissue, and few studies have been published on MRI with the focus on the axilla. In a study published in 1990, Moore et al. showed that MRI provides a working diagnosis in patients with arm oedema or neurological symptoms. Fibrosis was found in 21 patients and tumour recurrence in 10, both detected by MRI (n=35). Histopathological confirmation was available in only 3 patients, but corroborative evidence suggests that the MRI interpretation was correct in the remaining patients. In a later study from 1996, by Heiberg et al. 83 lesions in 56 patients



scheduled for breast biopsy were studied. Some of the patients had the axilla included in the dynamic scanning. Eight lymph nodes in 3 patients with lymph node metastases were seen to enhance rapidly to more than 90%, two of which were intramammary. One benign lymph node enhanced rapidly to 112% and on histologic examination was found to be dermatopathic lymphadenitis. The enhancement profiles of metastatic lymph nodes were similar to those of primary cancer, but the number was very low. In a study by Mumtaz et al special attention was given to the axillary nodes. This study was designed to investigate the accuracy of contrast-enhanced MR imaging in the locoregional staging of symptomatic primary breast cancer. A short inversion time–inversion recovery sequence was obtained to evaluate the axilla. The criteria for abnormal (likely to be malignant) nodes were: size greater than 5 mm, higher than soft tissue intensity on short inversion time–inversion recovery images, and enhancement with gadolinium dimeglumine. MR imaging–histopathologic correlation was possible in 75 axillae. In this subgroup of patients, using these specific criteria, MR imaging was found to have a sensitivity of 90% and a specificity of 82% in the diagnosis of involved axillary nodes, but there was poor correlation between the total number of malignant nodes visible on MR imaging and the pathological analysis. Present limitations are largely caused by the breast coil design, and the associated cardiac flow artefact. Mussurakis et al. used another approach in their study, where they developed a model that determines the risk of axillary node involvement on the basis of patient age and two MRI variables, reflecting that tumour neovascularization is connected to contrast enhancement; 24% of the patients (n=51) were correctly identified as having a less than 5% or greater than 95% probability of having positive nodes. In this study there was no imaging of the axilla. MRI has the advantage of imaging in different planes, not only axial, but also coronal and sagittal. Contrast enhancement is necessary to detect breast

lesions, and to help differentiate malignant from benign lesions. Malignant breast lesions tend to be enhanced more rapidly than benign lesions. This can also be true of the imaging of lymph nodes. A special surface coil for dedicated axillary imaging is probably necessary to obtain a sufficient number of detailed images. However, when a pathological node is detected, cytological verification is still necessary, although needle biopsy in the axilla is not routinely performed with MR guidance. Although ultrasound has long been the first method in radiological examination of the axilla, it has not been considered as especially important. But, in breast imaging, ultrasound has gained acceptance, and today it is an important adjunct to mammography. A breast-imaging centre should have its own ultrasound equipment. Today, many have presented studies about the role of ultrasound in breast imaging, and also in imaging of the axilla. The development has progressed towards handheld high resolution transducers with a frequency of at least 7.5 MHz. An US examination of a patient with breast cancer should include the ipsilateral axilla, in order to detect any pathological lymph nodes. Technically, the examination is fairly simple and quick. Normal nodes are frequently not visible, but with modern equipment some normal nodes can be detected, or parts of them, in many patients. The criteria for pathological nodes include not only the size, but also the form and the internal structure. The size, however, has been shown to be of limited value. An in vitro correlation between ultrasound and histopathology examination of lymph nodes was made by Feu et al.). The normal node has a thin hypoechogenic cortex in the periphery and an echogenic hilus. If there is a pronounced fatty part in the centre, this becomes hypoechogenic, and a thin echogenic border (the T-line) remains between the cortex and the centre. Pathological nodes tend to become more rounded, therefore a length to width ratio ( $l/w$ ) of less than 1.5 increases suspicion of metastasis, whereas  $l/w \geq 2.0$  indicates that a node is benign. Eccentric enlargement with focal thickening of the cortex, at

least doubling, is a strong indicator of malignant transformation. Compression of the hilus, and especially the absence of the hilus, is highly suggestive of malignancy. Concentric enlargement can be seen in reactive changes in a node. But, there is an overlap between reactive nodes and metastatic nodes. If a pathological node has irregular margins, perinodal extension of carcinoma can be suspected. US can be valuable when used with palpation. Any palpable lesion can be directly imaged with US, in order to detect and differentiate between pathological lymph nodes and other lesions. There can, for instance, be aberrant breast tissue, lipoma, atheroma, or rarer lesions such as nerve tumours or calcified aneurysm. In studies in recent years, evaluation of sensitivity and specificity has been relatively high, with sensitivity ranging from 70 to 90% and specificity up to between 90% and 100% (9, 14–19). Of course, the criteria are important and can have an effect on results. For example, in the study by Bonnema et al., when echo pattern was the only criterion, sensitivity and specificity were 36 and 95%, respectively. If the criterion had been size  $\geq 5$  mm, the sensitivity and specificity would have changed to 87 and 56%, respectively. The sensitivity of fine-needle aspiration biopsy (FNAB) was 80% and the specificity 100%. It should be noted that this was for breast cancer patients without palpable nodes at clinical examination. Doppler, especially colour Doppler, is a useful tool in differentiating between pathological lymph nodes and serpiginous vessels. Earlier results demonstrating colour Doppler flow signals in lymph node metastases were considered promising, but later, colour Doppler flow signals in both benign and malignant nodes were shown to be non-specific. However, this is a developing field of investigation, and other parameters such as pattern, distribution and angioarchitecture may prove to be of value in association with this technique (22–24). Fine-needle aspiration biopsy (FNAB) is necessary to confirm that an image diagnosis of a metastatic lymph node is correct. FNAB should be done under

image control, i.e. US-guided FNAB, for exact guidance in order to obtain a sample from the most suspect part of a node, which is usually part of the thickened cortex . The node selected for sampling can be mobile, making real time US guidance necessary. US guidance is also helpful when a node is situated close to the lung, to avoid entering the pleural cavity and inducing a pneumothorax, or when a node is situated close to a vessel. Furthermore, and most important, FNAB increases the specificity .Rissanen et al. have shown that USguided FNAB is of value in recurrence after mastectomy . In this study, a quarter of the lesions were situated in the axilla.

## **2.4 Diagnosis:**

### **2.4.1 Palpation**

This method has a low sensitivity and specificity 60-70%; however, is the first step in the evaluation of lymph node enlargement.

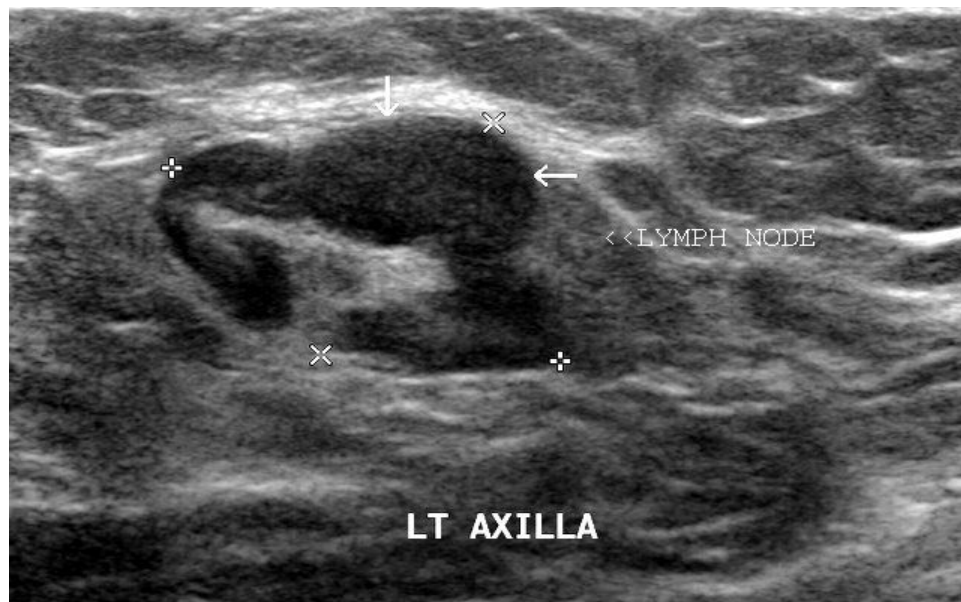
### **2.4.2 Ultrasonography**

Ultrasound is a useful imaging modality in assessment of lymphnodes. Distribution of nodes, grey scale and power Doppler sonographic features are useful to identify the cause of cervical lymphadenopathy. Useful grey scale features include size, shape, status of echogenic hilus, echogenicity, micronodular appearance, intranodal necrosis and calcification. Adjacent soft tissue edema and matting are particularly useful to identify tuberculosis. Useful power Doppler features include vascular pattern and displacement of vascularity.

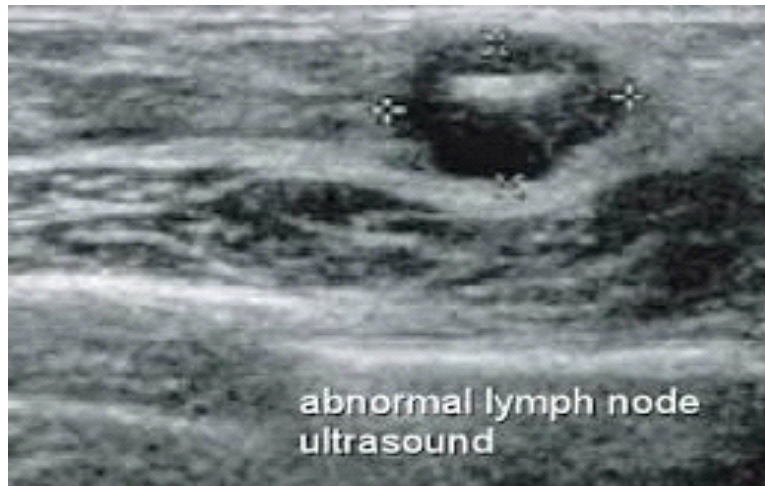Ultrasonography can be combined with fine needle aspiration cytology in which a sample of cells from the lymph node is aspirated using a needle and examined under the microscope.

### 2.4.2.1 Sonographer Positioning

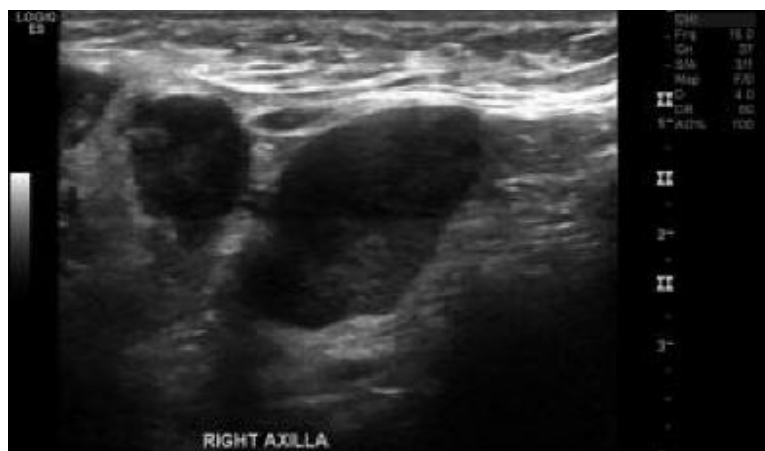
Position the patient close to the edge of the ultrasound couch. Move the machine in close so that you do not have to stretch to reach the control panel. This will assist in reducing fatigue of the upper arm/neck ...etc, by decreasing the amount it is necessary to abduct the scanning arm. You will have to ‘invade the patient’s personal space’ to be sufficiently close for this to be effective. The arm can be supported with a 45-degree sponge wedge. The sponge can carry the weight of the arm rather than having to hold the arm in constant abduction (figure 13). It is a position that can be adopted for all scanning and can reduce some of the physical stresses of scanning.



(Diagram 2.1) Normal breast –axillary lymph node

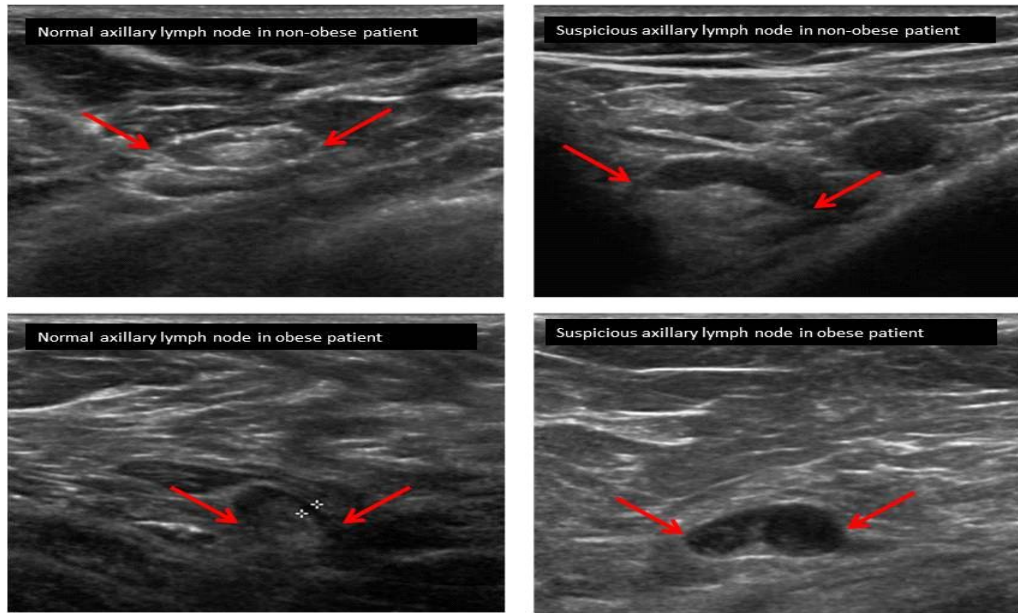


**(Diagram 2.2) Lymph node enlargement due to breast cancer**




**(Diagram 2.3) Ultrasound image of the right axilla showing enlarged lymph nodes with generalised hypoechoicity**

Obesity can change lymph nodes, including the way they look in imaging studies, and make physical examination of underarm lymph nodes more challenging. The Mayo study found that higher body weight didn't muddy ultrasounds of the axillary lymph nodes in overweight or obese cancer patients, and that their ultrasounds had better specificity and accuracy than those of thinner women, meaning that when ultrasound showed no suspicious lymph nodes, it was likelier to be correct.



**(Diagram 2.4) Lymph Node Ultrasounds More Accurate in Obese Breast Cancer Patients, Mayo Clinic Study Finds**



**(Diagram 2.5)** 9 o'clock position of the left breast and an enlarged lymph node in the left axilla.

### **2.4.3 CT scan**

CT scans can detect the presence of enlarged axillary lymph nodes with a short-axis diameter of 5 mm or greater.

## **2.5 Epidemiology and statistics**

The study provides reliable population-based estimates. Findings from this Dutch study revealed a 0.6 percent annual incidence of unexplained lymphadenopathy in the general population.

## **2.6 Clinical features of abnormal lymph node enlargement**

Abnormal lymph node enlargement tends to commonly result from infection / immune response, cancer and less commonly due to infiltration of macrophages filled with metabolite deposits (e.g., storage disorders).

Infected Lymph nodes tend to be firm, tender, enlarged and warm. Inflammation can spread to the overlying skin, causing it to appear reddened.

Lymph nodes harboring malignant disease tend to be firm, non-tender, matted (i.e., stuck to each other), fixed (i.e., not freely mobile but rather stuck down to underlying tissue), and increase in size over time.

Sometimes, following infection lymph nodes occasionally remain permanently enlarged, though they should be non-tender, small (less than 1 cm), have a rubbery consistency and none of the characteristics described for malignancy or for infection. These are also known as 'Shotty Lymph nodes'.

Little information exists to suggest that a specific diagnosis can be based on node size. However, in one series [4] of 213 adults with unexplained lymphadenopathy, no patient with a lymph node smaller than 1 cm<sup>2</sup> had cancer, while cancer was present in 8 percent of those with nodes from 1 cm<sup>2</sup> to 2.25 cm<sup>2</sup> in size, and in 38 percent of those with nodes larger than 2.25 cm<sup>2</sup>. These studies were performed in referral centers, and conclusions may not apply in primary care settings.



Enlarged axillary lymph nodes in case of breast carcinoma patients are not always due to metastases and can be reactive in nature. Very rarely enlarged axillary lymph nodes may be due to reactivated dormant axillary tubercular lymphadenitis. A case of infiltrating ductal carcinoma of breast along with metastasis to axillary lymph node harboring primary tubercular granuloma in the same lymph node is being reported due to rarity.

Axillary lymph node metastasis without breast involvement from ovarian cancer and not appreciably high SUV in PET, the possibility of metastasis at the axillary lymph node in patients with known primary ovarian cancer must be considered. Also, when a solitary axillary lesion is detected in a patient with ovarian cancer, accurate diagnosis by pathologic confirmation with ultrasonography-guided biopsy is essential, because axillary lymph node metastasis is an important factor for choice of treatment.

# CHAPTER THREE

## 3.1 MATERIALS AND METHOD

### 3.1.1 Area of the study:

This research will be studied in UAE , Dubai, Preventive Medicine Department

### 3.1.2 Study Population:

Women, aged between 40-80 yrs

### 3.1.3 Duration:

March 2012- January 2015

### 3.1.4 Sample volume:

(50 cases)

### 3.1.5 Imaging methods:

This research will be implemented by an ultrasound machine includes Transducer options 7-10MHz 2D Wide Band Linear Probe. Documented images will be printed .All patients will be investigated and requested by authorized person.

### 3.1.6 Equipment selection

- Transducer: A high frequency, between 7 -10 MHz linear array probe should be used.

### 3.1.7 Scanning directions:

- Radial scanning
- Transverse scanning
- Longitudinal scanning

### **3.1.8 Criteria of Radiographic assessment:**

The first line for radiographic assessment is mammogram. A mammogram is basically an x-ray exam that produces images of the internal structures of the breasts. Mammography is the gold standard in breast imaging, since it is the most accurate method in evaluating the entire breast. Through mammography, cancer or other problems before a lump becomes large enough to be felt can be detected, as well as diagnosis of other breast problems can also be done.

It is recommended that all women should have a screening mammogram every two years starting at age 40 and earlier if there is a family history of breast cancer. ([www.emirateshospital.ae/services/medical-tests/mammograms/](http://www.emirateshospital.ae/services/medical-tests/mammograms/))

If the mammogram is abnormal the client will be advised to do further mammogram views such as magnify a specific area to get a more detailed picture or repeat the same views from the screening mammogram because those images weren't clear enough. And based on the diagnose the client will be referred to do ultrasound.

### **3.1.9 Axillary Lymph node Ultra sound**

#### **3.1.9.1 Role of ultrasound:**

Ultrasound is a valuable diagnostic tool in assessing the following indications:

- Investigating a palpable lump
- Mammography abnormality
- Follow up of known lesion
- Infection or mastitis

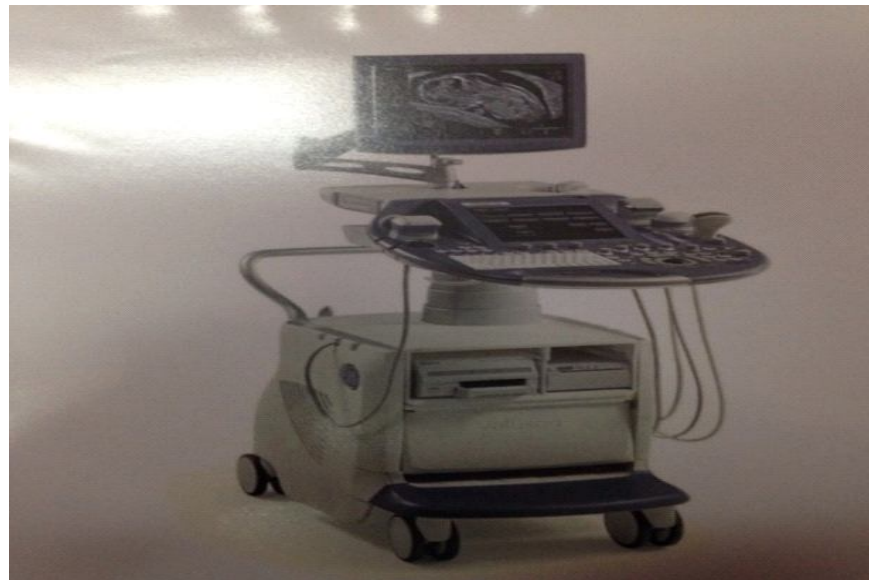
Ultrasound increasingly enlisted as part of a comprehensive screening program alongside mammography

### **3-1.9.2 Limitations:**

- Extremely large, mobile breasts will be difficult to scan thoroughly.
- Post injury, surgery or biopsy, the resultant hematoma will reduce detail and may obscure pathology.

### **3.1.9.3 Equipment selection and technique:**

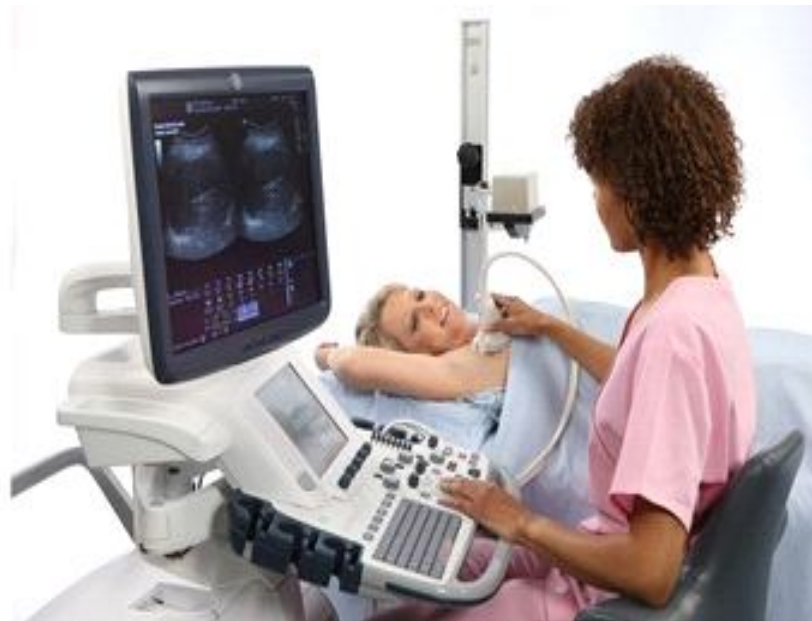GE Voluson E8 Expert Ultrasound System 2007 were used for this study, breast u/s requires a high frequency transducer 7-10 MHz , Ideally a wide footprint probe. A lower frequency transducer may be required for the larger attenuative breasts, inflammatory masses and the axilla. The use of a standoff may be required for nipple, superficial/or skin lesions. Low PRF color and spectral Doppler capabilities for assessing vascularity of lesions (figure 3.1).



**Figure3.1 GE ultra sound machine**

### **3.1.9.4 Patient Positioning:**

The side to be examined is raised with the patient's hand behind their head (figure 3.2). The breast needs to be spread evenly across the chest wall to allow for a uniform depth of field and to reduce breast thickness. The reduced thickness allows optimization of focusing. The degree of obliquity required varies with the size and position of the breast on the chest wall. Placing the ipsilateral hand behind the head will assist in spreading the breast further. This also allows access to the axilla. (Griffiths, T. 2000).



(figure 3.2) Patient Positioning

### **3.1.9.5 Data Collection**

In this study all data were collected from patients came to Preventive Medicine Department in Dubai for the National Program of Breast Cancer Early Detection.

### **3.1.9.6 Data Analysis**

Sample data was analyzed by SPSS version 21, all patient were divided into groups according to the cause of the axillary lymph node enlargement.

## CHAPTER FOUR

### Results

In 50 patients aged between 40 to 80 years had presented to Preventive medicine department, found that 29 (58 %) of the sample have axillary lymph node enlargement due to cancer with its different types, while 10(20%) have lymph node enlargement due to hematopoietic disease (Thalassemia), also it's been found that 4 (8%) of lymph node enlargement was due to Lymphoma, while 6 (12%) who had breast implants had lymph node enlargement due to infection, while 1 (2%) patient had lymph node enlargement due to chest Tuberculosis (TB).

(Table No 4.1)Table shows all Patients have axillary lymph node enlargement due to Cancer:

Age	Patient No	Diagnosis	Size
40 – 50	13	lymph node enlargement due to Malignant	< 3
50 – 60	8	lymph node enlargement due to P. malignant	> 3
60 – 70	3	lymph node enlargement due to Highly malignant	< 3
70 – 80	5	lymph node enlargement due to malignant	< 3

(Table 4.2)Patients have axillary lymph node enlargement due to Thalassemia:

Age	Patient No	Diagnosis
40 – 50	8	enlargement due to Thalassemia
50 – 60	2	enlargement due to Thalassemia
60 – 70	0	
70 – 80	0	

(Table 4.3) Patients have axillary lymph node enlargement due to infection(breast implant).

Age	Patient No	Diagnosis
40 – 50	6	Infection (breast implant)
50 – 60	3	Infection (breast implant)
60 – 70	1	
70 – 80	0	

(Table 4.4) Patients have axillary lymph node enlargement due to Lymphoma.

Age	Patient No	Diagnosis
40 – 50	0	
50 – 60	3	Lymphoma
60 – 70	1	Lymphoma
70 – 80	0	

(Table 4.5) Patients have axillary lymph node enlargement due to TB.

Age	Patient No	Diagnosis
40 – 50	1	Chest Tuberculosis (TB)

(Table 4.6) Following table shows all the results:

Cause	Patient No	Percentage
Breast Cancer	29	58%
Hematopoietic Disease (Thalassemia)	10	20%
Lymphoma	4	8%
Implants	6	12%
Tuberculosis	1	2%
Total	50	100%



# CHAPTER FIVE

## 5.1 Discussion

Not all cases of breast cancer result in enlarged axillary lymph nodes. However, the observation of enlarged axillary lymph nodes is a strong signal that breast cancer may be at a more advanced stage. The detection of cancer in the lymph nodes is one of three central determinants breast cancer doctors consider to evaluate the stage of a breast cancer. The other two are the size of breast cancer and whether it has spread to other area. In primary care settings, patients 40 years of age and older with unexplained lymphadenopathy have about a 4 percent risk of cancer versus a 0.4 percent risk in patients younger than age 40. I assessed the usefulness of ultrasonography as a complement to mammography in screening in detecting size lymph node appearance in breast in order to reach the correct diagnosis.

Mammography is currently the sole acceptable technique for lymphnode screening for breast cancer. Ultrasonography can be combined with fine needle aspiration cytology in which a sample of cells from the lymph node is aspirated using a needle and examined under the microscope.

Findings from a Dutch study revealed that only 10 percent of patients with unexplained adenopathy required referral to a subspecialist, 3 percent required a biopsy and only 1 percent had a malignancy.

Ultrasound is a useful imaging modality in assessment of lymph nodes. Distribution of nodes, grey scale and power Doppler sonographic features are useful to identify the cause of axillary lymphadenopathy. Useful grey scale features include size, shape, status of echogenic hilus, echogenicity, micronodular appearance, intranodal necrosis and calcification. Adjacent soft tissue edema and

matting are particularly useful to identify tuberculosis. Useful power Doppler features include vascular pattern and displacement of vascularity.

In this research we have tested 50 subjects who did mammograms and then they have been sent to do ultrasound to exclude any suspicious, according to our results we find that there were aged between 40 to 80 years had presented to Preventive medicine department, found that 29 (58 %) of the sample have axillary lymph node enlargement due to cancer with its different types, while 10(20%) have lymph node enlargement due to hematopoietic disease (Thalassemia), also it's been found that 4 (8%) of lymph node enlargement was due to Lymphoma, while 6 (12%) who had breast implants had lymph node enlargement due to infection, while 1 (2%) patient had lymph node enlargement due to chest Tuberculosis (TB).

## **5.2 conclusion;**

Lymph nodes are filters in the lymphatic system that sieve out infectious material as well as toxins that come via the lymphatic channels. These may be affected commonly by certain diseases or conditions.

Abnormal lymph node enlargement tends to commonly result from infection / immune response, cancer and less commonly due to infiltration of macrophages filled with metabolite deposits (e.g., storage disorders).

This study showed results of subjects that had mammography and ultrasonography. The final diagnose was approved by ultrasonography which was advised to do further tests such as Biopsy.

## **5-3 Recommendation:**

- Breast self-exam (BSE) is an option for women starting in their 20s. Women should be told about the benefits and limitations of BSE.
- Mammogram screening every two years for women at age of 40years and above.

- Ultrasound screening for young women to avoid the mammogram radiation.
- Women should report any breast changes to their health professional right away
- If it persists after a period of observation then the patient should seek medical attention which may require further investigations using .

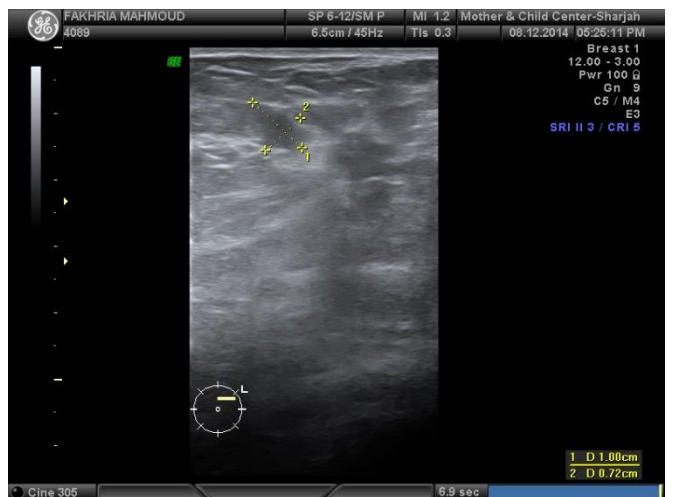
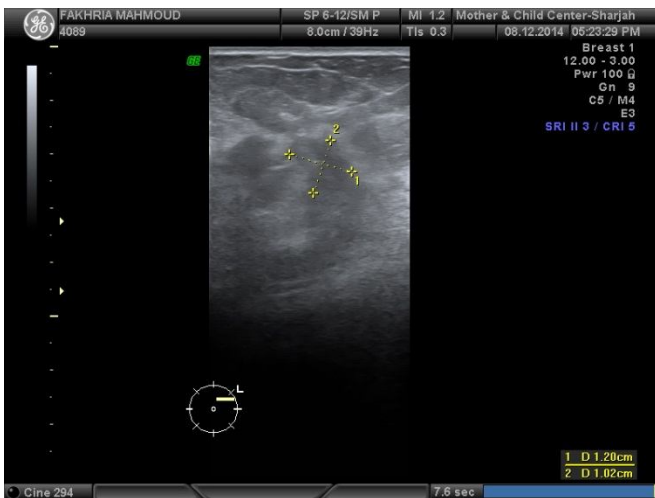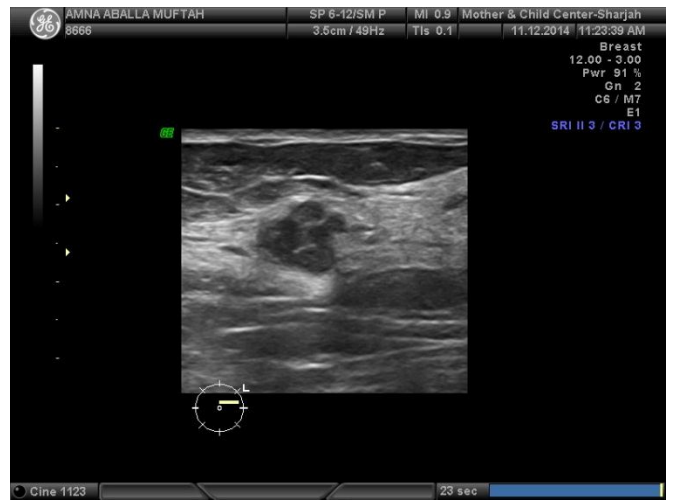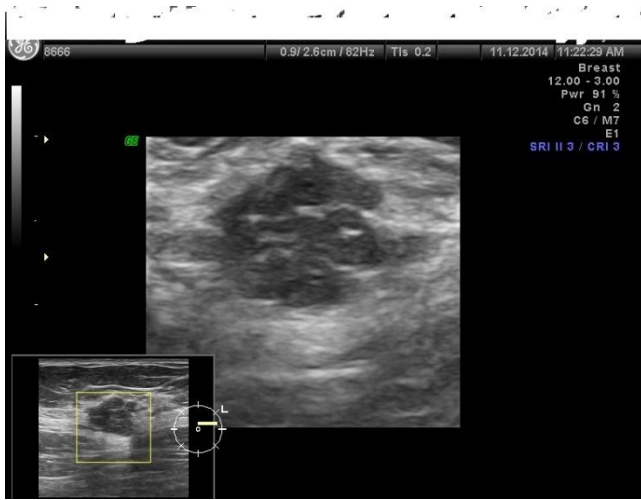
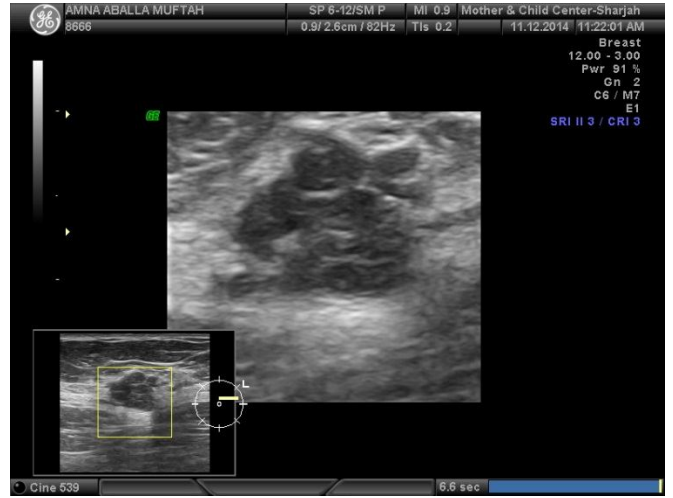
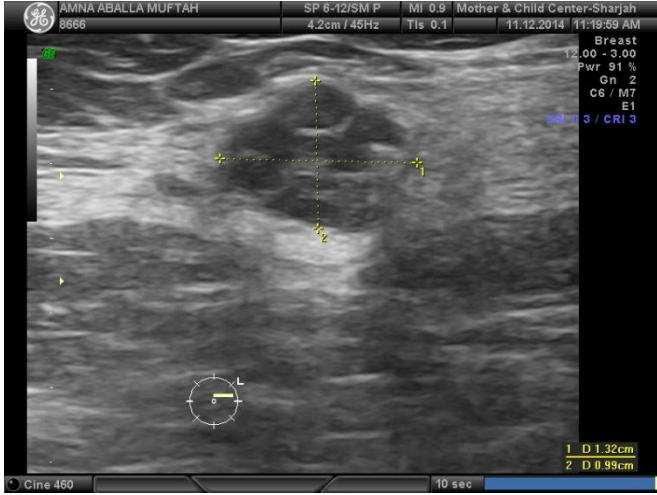## References:

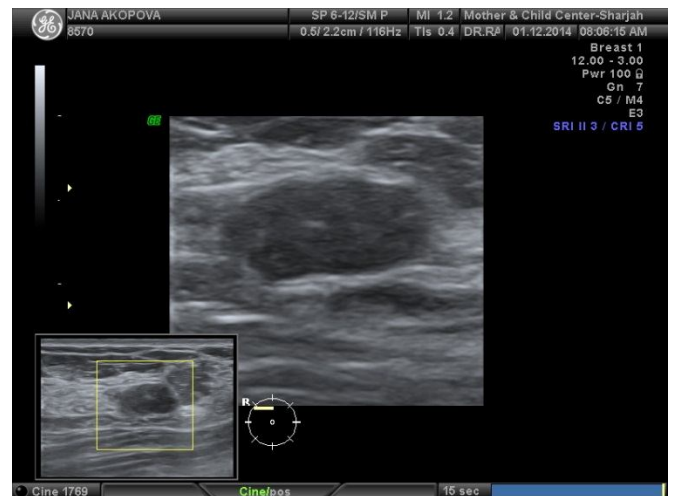
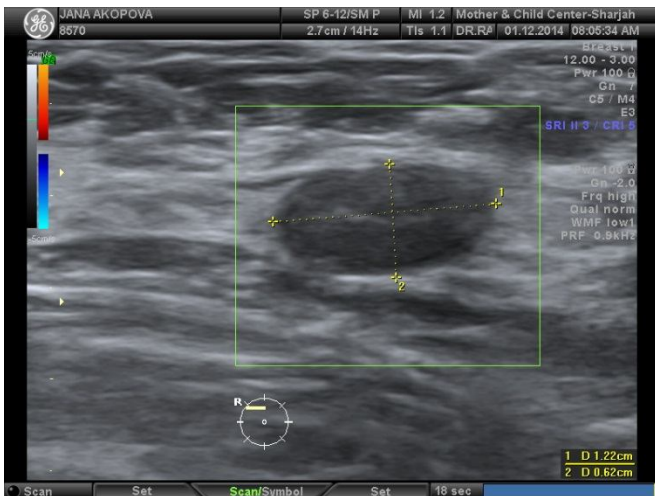
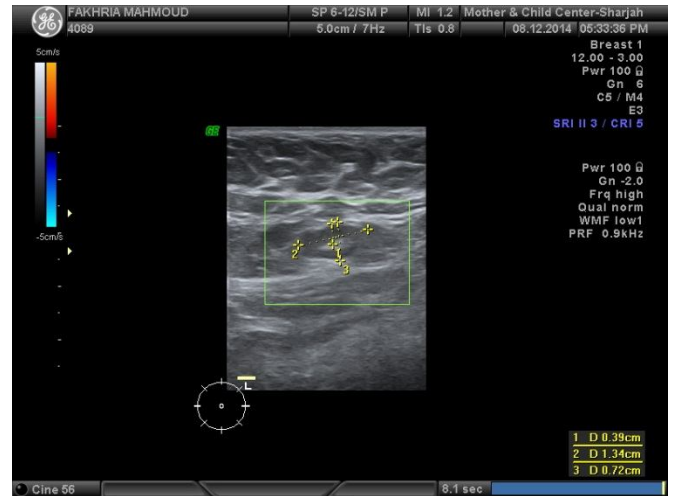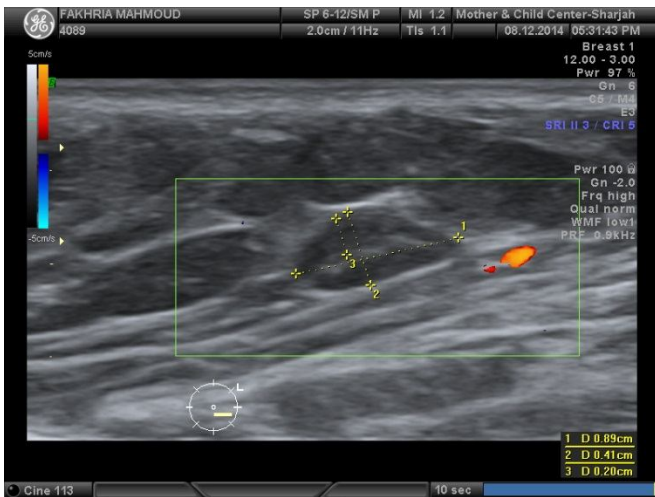
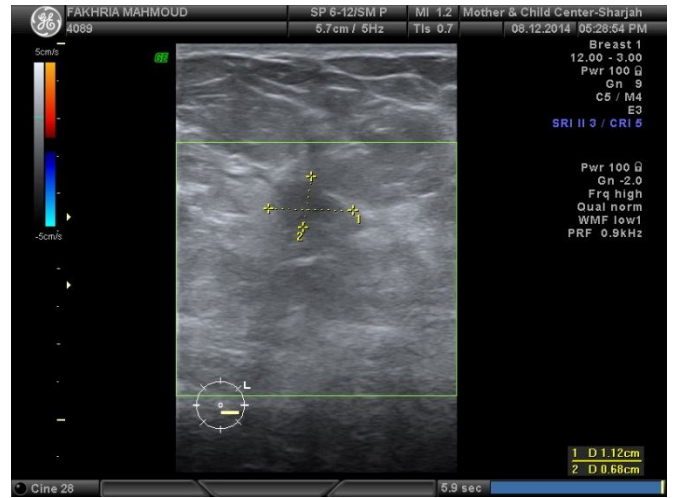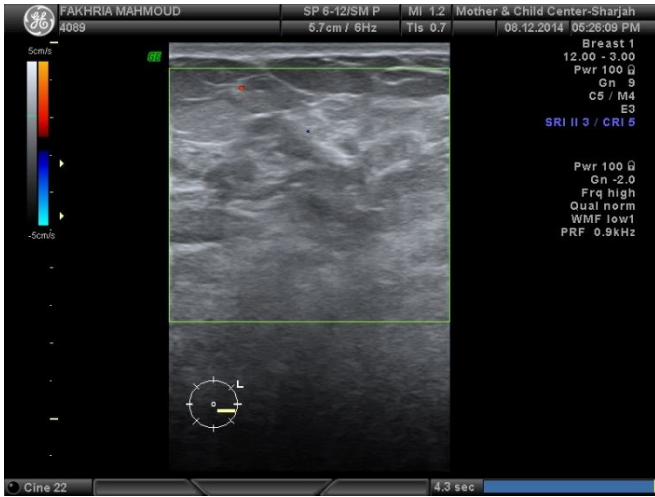
- Allhiser JN, McKnight TA, Shank JC. 1981 Lymphadenopathy in a family practice.
- Bennett JC, Plum F, eds. 1996 Cecil textbook of medicine. 20th ed. Philadelphia: Saunders,
- Fijten GH, Blijham GH. 1988 Unexplained lymphadenopathy in family practice. An evaluation of the probability of malignant causes and the effectiveness of physicians' workup..
- Ghirardelli ML, Jemos V, Gobbi PG: 1999 Diagnostic approach to lymph node enlargement. Haematologica
- Goroll AH, May LA, Mulley AG Jr. 1987 Primary care medicine: office evaluation and management of the adult patient..
- Lee Y, Terry R, Lukes RJ. 1980 Lymph node biopsy for diagnosis: a statistical study. J Surg Oncol.
- Libman H. 1987 Generalized lymphadenopathy..
- Morland B. 1995 Lymphadenopathy. Arch Dis Child.
- Paauw DS, Wenrich MD, Curtis JR, Carline JD, Ramsey PG. 1995 Ability of primary care physicians to recognize physical findings associated with HIV infection..
- Pangalis GA, Vassilakopoulos TP, Boussiotis VA, Fessas P 1993. Clinical approach to lymphadenopathy. Semin Oncol.
- Pangalis GA, Vassilakopoulos TP, Boussiotis VA, Fessas P 1993. Clinical approach to lymphadenopathy. Semin Oncol.
- Sapira JD 1990. The art and science of bedside diagnosis. Baltimore: Urban & Schwarzenberg,
- Slap GB, Brooks JS, Schwartz JS 1984. When to perform biopsies of enlarged peripheral lymph nodes in young patients.

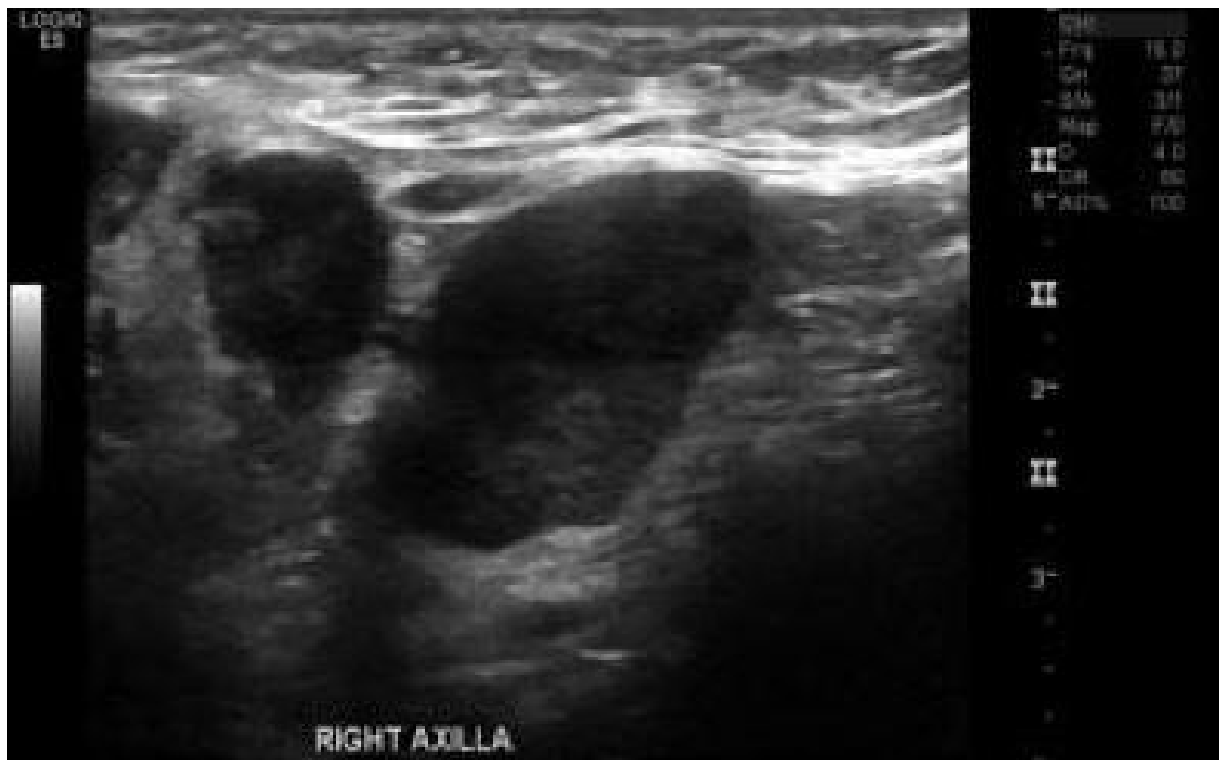
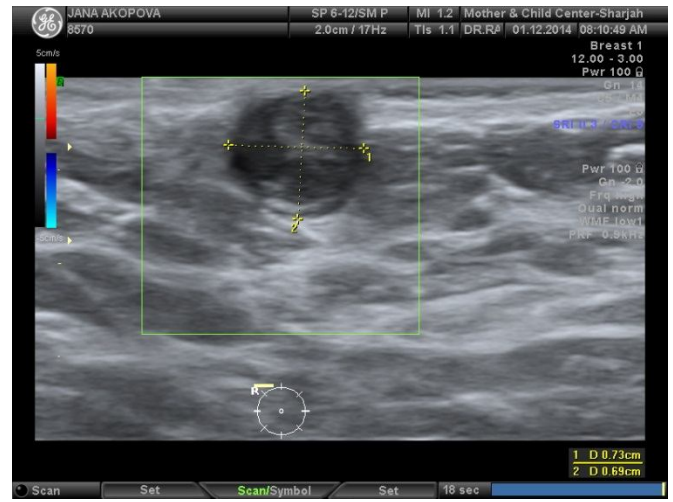
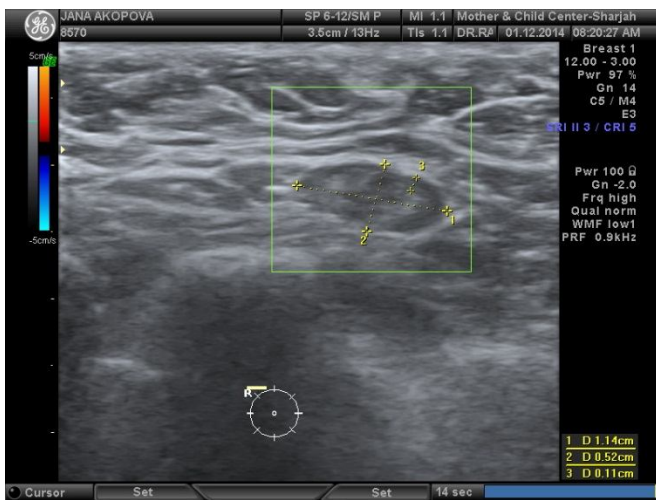
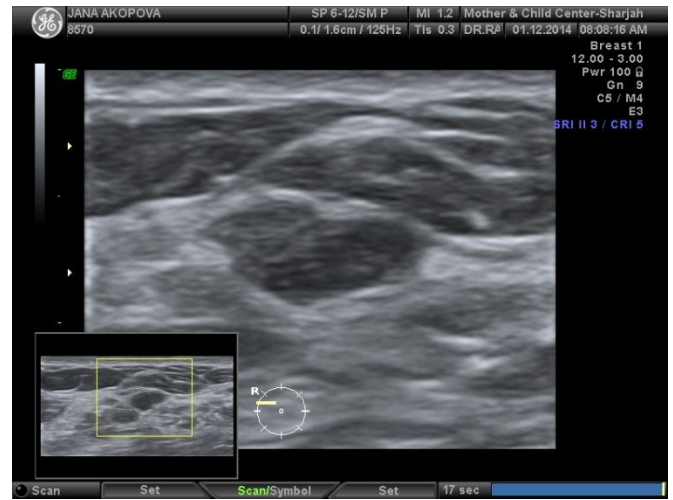
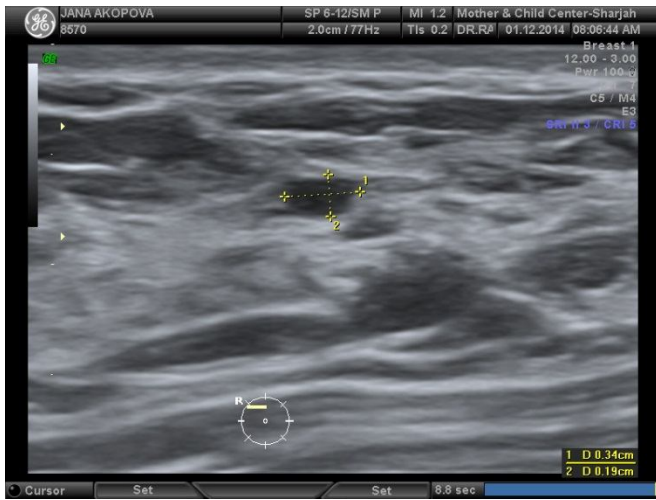
Williamson HA Jr.1985 Lymphadenopathy in a family practice: a descriptive study of 249 cases.

Appendix: ultrasound image showing Axillary lymph node Enlargement for different age(40-80)year

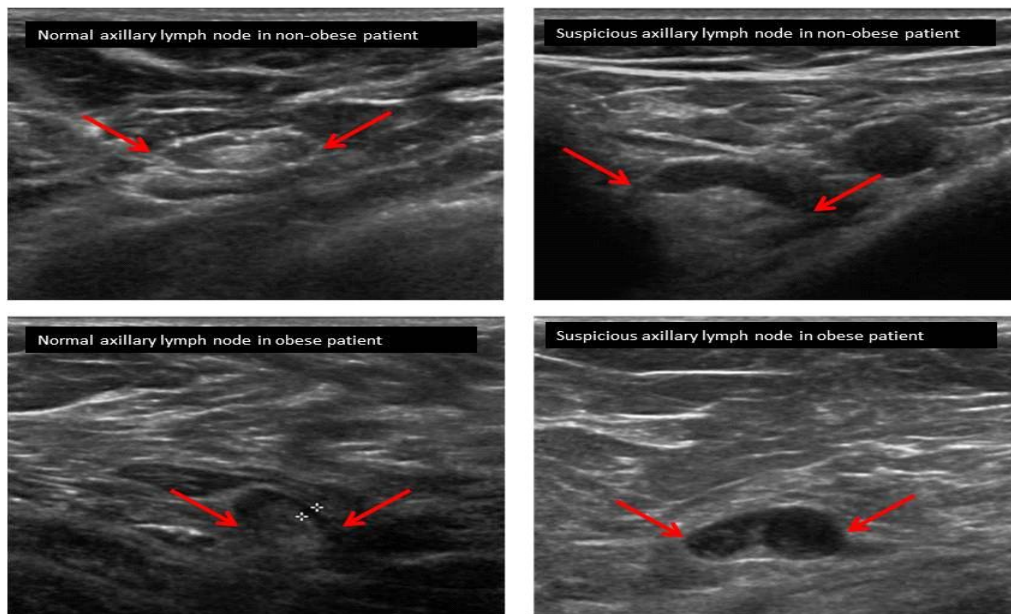
# Sample collected



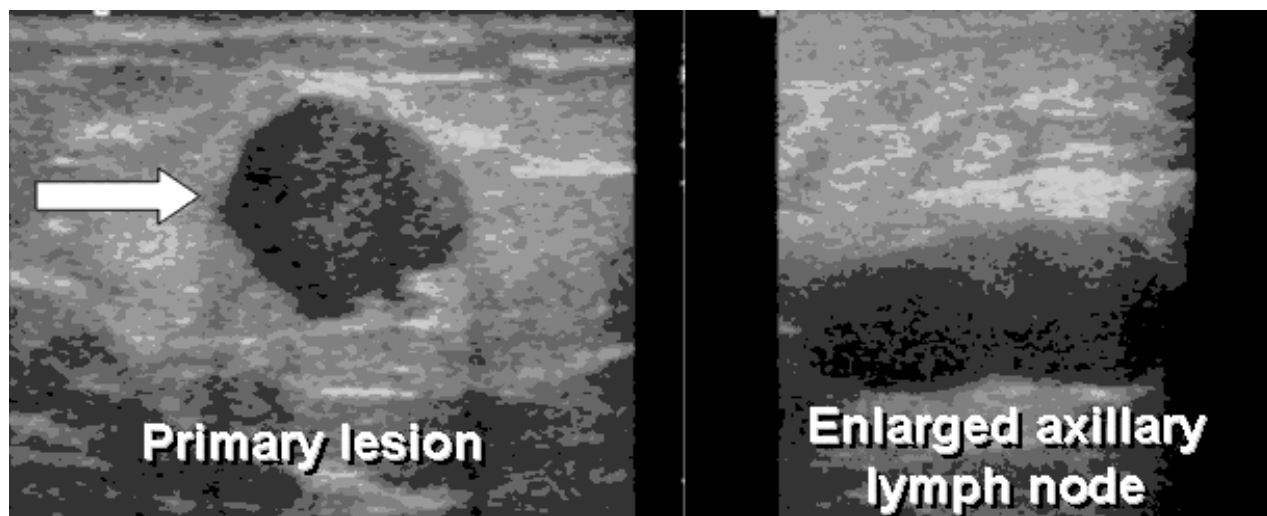








## Lymph Node Ultrasounds More Accurate in Obese Breast Cancer Patients, Mayo Clinic Study Finds



9 o'clock position of the left breast and an enlarged lymph node in the left axilla.

## Data Table

Following table shows all the results:

Cause	Patient No	Percentage
Breast Cancer	29	58%
Hematopoietic Disease (Thalassemia)	10	20%
Lymphoma	4	8%
Implants	6	12%
Tuberculosis	1	2%
Total	50	100%