



بِسْمِ اللَّهِ الرَّحْمَنِ الرَّحِيمِ



Sudan University of Science and Technology

College of Graduate Studies

**Study of Renal stones using Ultrasonography and
laboratory investigations**

دراسة حضاوي الكلي باستخدام الموجات فوق الصوتية والفحوصات المعملية

A Thesis submitted in partial fulfillment for the requirement
of M.Sc degree in medical diagnostic Ultrasound

by:

Dalal Jamal Badawi Mohammed

Supervisor:

Dr. Ikhlas Abdelaziz Hassan

2016

الآية

قال تعالى:

(قُلْ لَوْ كَانَ الْبَحْرُ مِدَادًا لِكَلِمَاتِ رَبِّي
لَنَفِدَ الْبَحْرُ قَبْلَ أَنْ تَنْفَدَ كَلِمَاتُ رَبِّي وَلَوْ
جِئْنَا بِمِثْلِهِ مَدَدًا)

سورة الكهف الآية (109)

Dedication

*To who they given me great love , support
and source of inspiration. Deeply
thankful to them without them this project
would not have been made possible*

To my Mather

To my Father

To my Husband

Acknowledgment:

All thanks my almighty God Allah to give me power to do this work, I am so grateful.

Thanks for encouraged and challenged given me to end this research could not have been written without my supervisor ,

DR. Ekhlal Abd -Elaziz

My thanks and gratitude also to all my teachers who learn me to get this point of success and to my friend Abeer Musa .

I would like to thanks all people who help me and contributed to this program .

Thanks to my college and all ultrasound department in Omdawanban and Ribat University who helped me to collecting data and information

Abstract:

The study was conducted in Omdawanban and Ribat University Hospitals ,during period (May 2016- November 2016) to a study of renal stones using Ultrasonography and laboratory investigation , detect the accuracy of ultrasonography in diagnosing renal stone, diagnose renal stone using urine sample and detect any obstructive changes . Materials and methods are observational descriptive study , the study was collected from 50patients ranged between (5 to 70 years old) both sex, came to U/S department with pus and RBCs in their urine ,suspected renal stone male(31) and female(19)patient ,all patients evaluated with ultrasound following international scanning gilded line and protocol using from 3.5 to 6 MHz . The variable collected from patient include gender, age, clinical sign and symptom ,lab investigation RBCs, Pus ,Ca-oxalate, amorphous ,and finding renal U/S, the collection according include all above variable data. The result majority of the sample were males greater than female , male 31(62%)and female 19 (38%) that agree with(lemon 2014),the most affected age group range between 30-39 years(30%)and left side more affected than right side by (42%) that similar with Mushira 2013 . The most symptom was lion pain 41 (82%) patient. Lab investigation RBCs 32 (64%) patient is greater than other .finding renal u/s examined show renal stone 31 (62%), renal stone with hydronephrosis 10(20%) , renal with deposit crystal 5(10%) ,and normal renal no stone 4(8%).

The study concluded that the renal ultrasound and urinalysis were very important to diagnosed renal stone.

المستخلص

اجريت هذه الدراسة في كل من مستشفى ام ضوآبان ومستشفى الرباط الجامعي في الفتره من مايو 2016 الي نوفمبر 2016.

شملت الدراسة خمسين مريضا يعانون من حصاوي الكلي وذلك باستخدام الموجات فوق الصوتية وتحليل البول.

هدفت الدراسة لتشخيص حصاوي الكلي بالموجات فوق الصوتية مقارنة ب تحليل البول .

تصميم الدراسة هو دراسه وصفية,تم اجراء فحص الموجات فوق الصوتية وفحص البول لكل من الرجال(31)مريض والنساء(19) مريضة , المتوقع اصابتهم بمرص حصاوي الكلي . البيانات التي تم استخدمت ف هذه الدراسة:العمر, النوع, الاعراض والعلامات السريرية, وتحليل البول. الموجات فوق الصوتيه للكلي تم جمعها وتحليلها. اظهرت النتائج ان عدد الرجال اكثر من عدد النساء(%42) وذلك يتفق مع دراسة (ليمون 2014),والرجال 31(62%), والنساء 19 (38%)وان اكثر فئة عمرية متأثرة بحصاوي الكلي هم من 30 الي 39 سنة بنسبة (30%) وذلك مشابهة لدراسة سابقة (مشيرة 2013) ووجود ان كلية المصابة بالحصاوي هي الشمال اكثر اليمين بنسبة (42%). واكثر الاعراض هي الم في الخاصرة بجانب العמוד الفقري 41 (82%) مريض بالنسبة للاعراض الاخرى. كل المرضى تم فحصهم بواسطة جهاز الموجات فوق الصوتية تبعا للبرتوكول العالمي المتفق عليه وتبعاً لذلك اظهرت الموجات فوق الصوتية لوجود حصاوي الكلي(31) (%62)مريض , ووجود حصاوي الكلي مع الالتهاب 10 (20%)مريض, ووجود املاح معدنية ف الكلي 5 (10%)مريض , وظهور طبيعي للكلي 4 (8%).

خلصت الدراسة ان الموجات فوق الصوتية وفحص البول من اهم الفحوصات التي تساعد في تشخيص حصاوي الكلي.

Abbreviation:

U/S: Ultrasound

RBCs: Red Blood Cell

MHz: Mega Hertz

R t: Right

L t: Left

UPJ: Ureteropelvic junction

PCS: Pelvic Calycial System

List of contents

Title	Page No.
الإية	I
Dedication	II
Acknowledgement	III
Content	IV
Abbreviations	V
Abstract	VI
Abstract in Arabic	VII
Chapter one	
Introduction	
1.1 Introduction	1
1.2 Problem of study	3
1.3 Objective of study	3
1.4 Thesis out line	3
Chapter two	
Literature Review	
2.1.1 Anatomy	4
2.1.1.1 External anatomy of kidney	5
2.1.1.2 Internal anatomy of kidney	6
2.1.1.3 Ureter	8
2.1.1.4 Urinary bladder	10
2.1.1.5 Urethra	12
2.1.1.6 The blood system of kidney	13

2.1.1.7 lymph supply	14
2.1.1.8 Nerve supply of kidney	14
2.1.2 Physiology	14
2.1.3 Pathology	14
2.1.3.1 Renal ectopic	14
2.1.3.2 Renal abscess	15
2.1.3.3 Renal duplex collecting system	16
2.1.3.4 Renal stone	16
2.1.4 Renal stone in ultrasound	17
2.1.5 Ultrasound machine.	17
2.1.6 Preparation of the patient	17
2.1.7 Setting correct gain	17
2.1.8 After care of patient	18
2.1.9 Normal appearance of kidney ultrasound	18
2.2 Previous study	19
Chapter three	
Materials and Methods	
3.1 Materials	21
3.1.1 Study population	21
3.1.2 Ultrasound machine	21
3.2 Methods	21
3.2.1 Position of patient	21
3.2.2 Study variable	22
3.2.3 Data collection	22
3.2.4 Image interpretation	22

3.2.5 Data analysis	22
Ethical consolidation	22
Chapter four	
Result	
Result	23
Chapter five	
Discussion , Conclusion & Recommendation	
5.1 Discussion	30
5.2 Conclusion	32
2.3 Recommendation	33
References	34
Appendices	
Appendix(A)	35
Appendix(B)	36

List of tables

Table No	Item	No page
2.1	Demonstrate gender frequency distribution among the sample	23
2.2	Demonstrate age frequency distribution among sample	24
2.3	Demonstrate sign and symptom frequency distribution among sample	25
2.4	Demonstrate site of pain frequency distribution among sample	26
2.5	Demonstrate lab investigation urine exam frequency distribution among sample	27
2.6	Demonstrate kidney ultrasound finding frequency distribution among sample	28
2.7	Demonstrate site of stone frequency distribution among sample	29
2.8	Demonstrate relation between ultrasound finding and urine finding RBCs.	30
2.9	Demonstrate relation between ultrasound finding and urine finding and urine finding pus	33
2.10	Demonstrate relation between ultrasound finding and urine finding and urine finding CA –oxalate	36
2.11	Demonstrate relation between ultrasound finding and urine finding and urine finding amorphous	38

List of figures

No	Item	No page
2.1	Shows anatomy of urinary tract	4
2.2	Shows anatomy of kidney	6
2.3	Shows anatomy of Nephron(renal tubule)	7
2.3.1	Shows anatomy of Nephron (renal tubule)	8
2.4	Shows anatomy of ureter	10
2.5	Shows anatomy of urinary bladder	11
2.6	Shows anatomy vasculature of kidney	13
2.7	Shows pelvic kidney ultrasound	15
2.8	Shows fungus ball of kidney ultrasound	15
2.9	Shows duplex collecting system of kidney ultrasound	16
2.10	Show renal ultrasound	17

Chapter one

Chapter one

1.1Introduction:

Kidney stones have plagued humans since the earliest records of civilization. Scientists have even found evidence of kidney stone in an Egyptian mummy estimated to be more than 7000-year-old. Unfortunately, kidney stones are one of the most common disorders of the urinary tract(STEIN Urology2015)

Most patients with kidney experience pain often severe that is localized on one side of the flank. In very rare cases, pain occurs in the middle of the abdomen. Most kidney stones cause blood in the urine that can only be seen with a microscope (called microscopic hematuria).(www.labtest.online.org)

Renal stone is usually believed to be due to crystallization of minerals inside urine, which act as the nidus for more sedimentation and finally the formation of a stone within the kidney. Stones are due to abnormal collection of certain chemicals .There are several different types they form for a variety of reasons it grouped into four different families, based on their chemical composition:Calcium oxalate ,Struvite , Uric acid ,Cysteine.Within the kidney may be referred to as renal calculi, or nephrolithiasis. They are most often made of calcium oxalate they are calcium stones ,Struvite stones ,uric acid stones, cysteine stones, calcium Stones - Calcium containing stones represent approximately 75-80% of all stones, calcium oxalate stones – 60%,calcium phosphate stones – 20% and mixed calcium oxalate and phosphate stones – 20%(www.pdrhealth .com)

Ultrasound is become the best, easier ,the most image examination in nephrology noninvasive ,use of high frequency (inaudible) sound to generate images. Ultrasound image has more features like minimal scan

time, low cost imaging, flexible and reduced exposure to harmful radiation. Sensitivities of 12% to 96% for the ultrasound detection of calculi have been reported. This wide discrepancy is a result of differing definitions (renal or ureteral), composition, and sizes of stone. Reported a 96% ultrasound sensitivity for renal stone detection, which was slightly inferior to the 1988 gold standard. Stone greater than 5 mm were detected with 100% sensitivity by ultrasound (Middleton et al) .

Renal ultrasonography examination of kidneys because has good anatomical detail. Kidney stone in ultrasound image detection will be seen as an echogenic focus that produces posterior acoustic shadowing this shadow depend on size should seen in tow view long axis and short axis views . (palmer 2011)

A urinalysis is critically important to detect the presence of harmful chemical or substance in urine and able to detect substance such as blood ,crystal ,glucose and pus cell (Louis, 2005)

Hematuria is defined as presence of red blood cells in urine. It can be characterized as either “gross” (visible to the naked eye) or “microscopic”(visible only under the microscope) . It consider marker of infection, stone disease. (Simons teddon, 2014). Pus is the whitish or yellowish definite some type of infection The medical term of pusin urine pyuria the most common reason is existence of urinary tract infection(Louis 2005).

Crystals. Common crystal seen even in health patient included calcium oxalate. Triple phosphate crystals and amorphous phosphates.(www.labtest .online.org)

1.2 Problem of study:

Renal failure is now days are day talk because of it is effect on families and patient , can avoid that by simple urine test and abdominal U/S.Early discover and treatment will save the kidney and patient life . this lead to reduce the disease.

1.3 Objectives:

1.3.1 Main Objectives:

To Evaluate Renal stone using Ultrasonography compared with Microscopic laboratory finding

1.3.2 Specific Objectives:

- To detect the accuracy of ultrasonography in diagnosing renal stone.
- To diagnose renal stone using urine sample.
- To identify renal stone by RBCs and pus in urine investigation.
- To correlate between RBs in urine and renal ultrasound to diagnose renal stone

1.4 Thesis out line:

This study consists of five chambers: Chapter one, which is introduction, deal with theoretical frame work of study. It present the statement of the study problem, objective of the study. Chapter two is divided into two sections, section one deal with theoretical background (anatomy, physiology and pathology). And section two deals with literature review (previous studies). Chapter three discusses the materials and method. Chapter four includes result presentation. Finally Chapter five includes the discussion, conclusion, recommendations references and appendices.

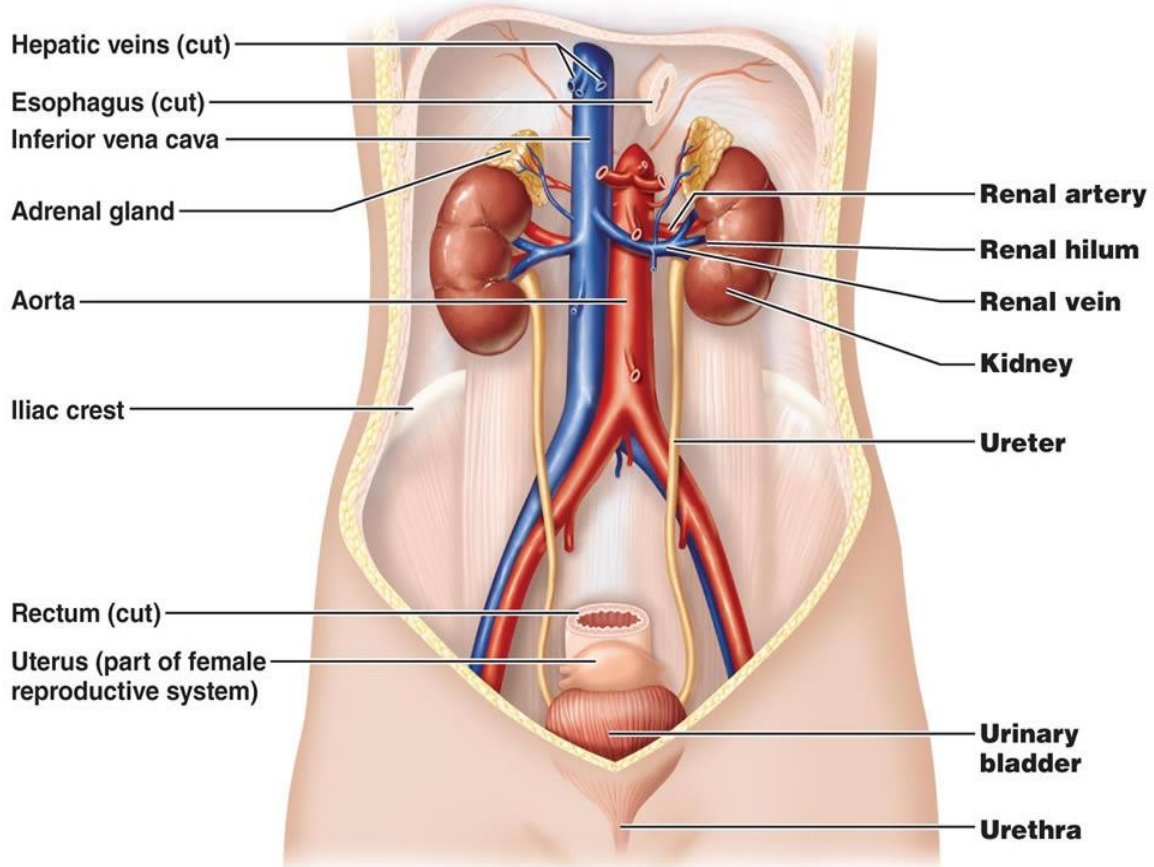
Chapter Two
Literature Review

Chapter two
Literature Review

2.1 Theoretical back ground

2.1.1Anatomy:

The urinary system consists of two kidneys, two ureters, one urinary bladder, and one urethra .After the kidneys filter blood plasma; they return most of the water and solutes to the bloodstream. The remaining water and solutes constitute urine, which passes through the ureters and is stored in the urinary bladder until it is excreted from the body through the urethra.



© 2013 Pearson Education, Inc.

Figure (2:1) Shows: Anatomy of urinary system(www.google.com)

2.1.1 .1 External anatomy of the kidney:

The paired kidneys are bean-shaped organs located just above the waist between the peritoneum and the posterior wall of the abdomen. Because their position is posterior to the peritoneum of the abdominal cavity, they are said to be retroperitoneal organs. The kidneys are located between the levels of the last thoracic and third lumbar vertebrae, a position where they are partially protected by the eleventh and twelfth pairs of ribs. The right kidney is slightly lower than the left because the liver occupies considerable space on the right side superior to the kidney.

A typical adult kidney long is 10–12 cm (4–5 in.) , wide 5–7 cm (2–3 in.) , thick 3 cm (1 in.) And has a mass of 135–150 g.

The concave medial border of each kidney faces the vertebral column. Near the center of the concave border is an indentation called the renal hilum through which the ureter emerges from the kidney along with blood vessels, lymphatic vessels, and nerves.

Three layers of tissue surround each kidney:

The deep layer, the renal capsule is a smooth, transparent sheet of dense irregular connective tissue that is continuous with the outer coat of the ureter. It serves as a barrier against trauma and helps maintain the shape of the kidney.

The middle layer, the adipose capsule, is a mass of fatty tissue surrounding the renal capsule. It also protects the kidney from trauma and holds it firmly in place within the abdominal cavity.

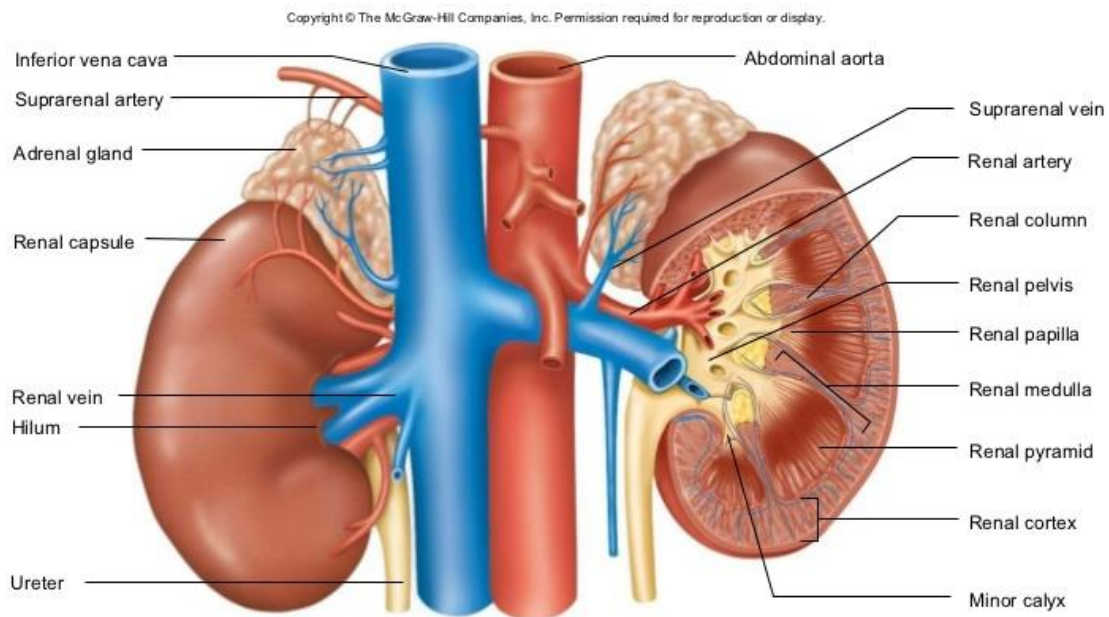
The superficial layer, the renal fascia, is another thin layer of dense irregular connective tissue that anchors the kidney to the surrounding structures and to the abdominal wall. On the anterior surface of the kidneys, the renal fascia is deep to the peritoneum.

2.1.1.2 Internal Anatomy of the Kidneys:

A frontal section through the kidney reveals two distinct regions:

A superficial called the renal cortex and a deep called the renal medulla. The renal medulla consists of several cone-shaped renal pyramids. The base (wider end) of each pyramid faces the renal cortex, and its apex (narrower end), called a renal papilla, points toward the renal hilum. The renal cortex is the smooth textured area extending from the renal capsule to the bases of the renal pyramids and into the spaces between them. It is divided into an outer cortical zone and an inner juxtamedullary zone.

Those portions of the renal cortex that extend between renal pyramids are called renal columns. A renal lobe consists of a renal pyramid, its overlying area of renal cortex, and one-half of each adjacent renal column.



9

Figure (2:2) shows: Anatomy of the kidney(www.infovisual.info)

Together, the renal cortex and renal pyramids of the renal medulla constitute the parenchyma (functional portion) of the kidney. Within the parenchyma are the functional units of the kidney about 1 million microscopic structures called nephrons. Urine formed by the nephrons drains into large papillary ducts, which extend through the renal papillae of the pyramids. The papillary ducts drain into cuplike structures called minor and major calyces cups. Each kidney has 8 to 18 minor calyces and 2 or 3 major calyces.

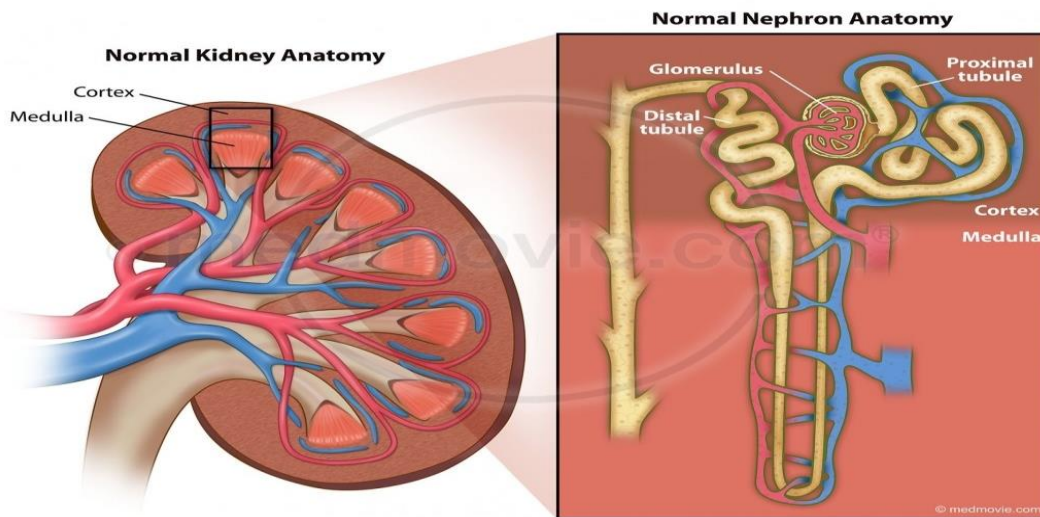


Figure (2:3) Show: Anatomy of Nephron (renal tubule)(

www.preheath.com).

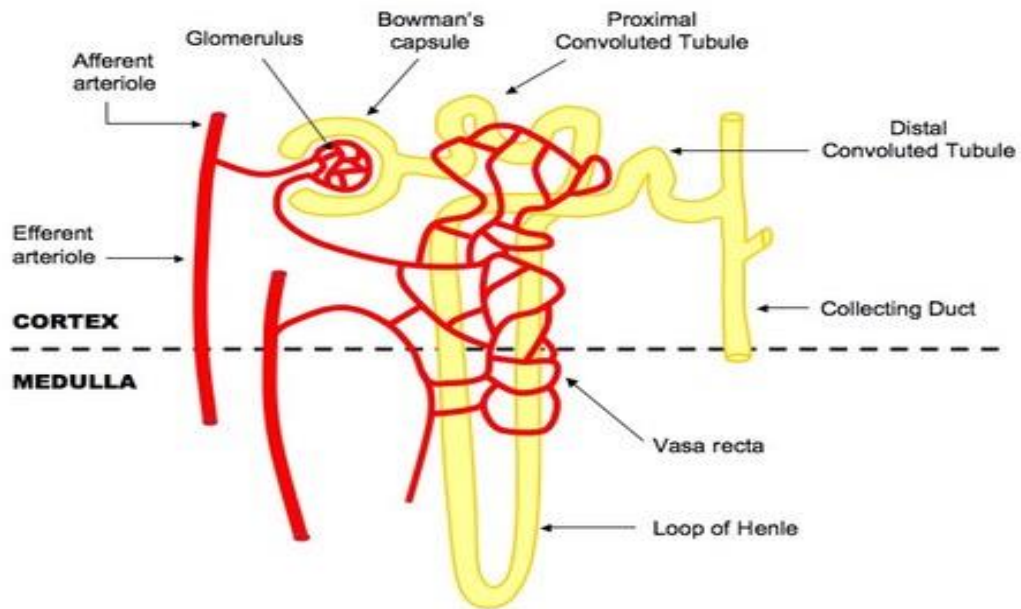


Figure (2:3.1) Shows: Anatomy of Nephron (renal tubule)(www.preheath.com).

A minor calyx receives urine from the papillary ducts of one renal papilla and delivers it to a major calyx. From the major calyces, urine drains into a single large cavity called the renal pelvis and then out through the ureter to the urinary bladder.

The hilum expands into a cavity within the kidney called the renal sinus, which contains part of the renal pelvis, the calyces, and branches of the renal blood vessels and nerves. Adipose tissue helps stabilize the position of these structures in the renal sinus.

2.1.1. 3Ureters:

Each of the two ureters transports urine from the renal pelvis of one kidney to the urinary bladder.

The ureters are 25–30 cm (10–12 in.) long and are thick walled, narrow tubes that vary in diameter from 1 mm to 10 mm along their course between the renal pelvis and the urinary bladder like the kidneys, the ureters are

retroperitoneal. At the base of the urinary bladder the ureters curve medially and pass obliquely through the wall of the posterior aspect of the urinary bladder. Even though there is no anatomical valve at the opening of each ureter into the urinary bladder.

Three layers of tissue form the wall of the ureters:

The deepest coat, the mucosa, is a mucous membrane with transitional epithelium and an underlying lamina propria of areolar connective tissue with considerable collagen, elastic fibers, and lymphatic tissue.

Throughout most of the length of the ureters the intermediate coat, the muscularis, is composed of inner longitudinal and outer circular layers of smooth muscle fibers. The muscularis of the distal third of the ureters also contains an outer layer of longitudinal muscle fibers. Thus, the muscularis in the distal third of the ureter is inner longitudinal, middle circular, and outer longitudinal.

The superficial coat of the ureters is the adventitia, a layer of areolar connective tissue containing blood vessels, lymphatic vessels, and nerves that serve the muscularis and mucosa. The adventitia blends in with surrounding connective tissue and anchors the ureters in place.

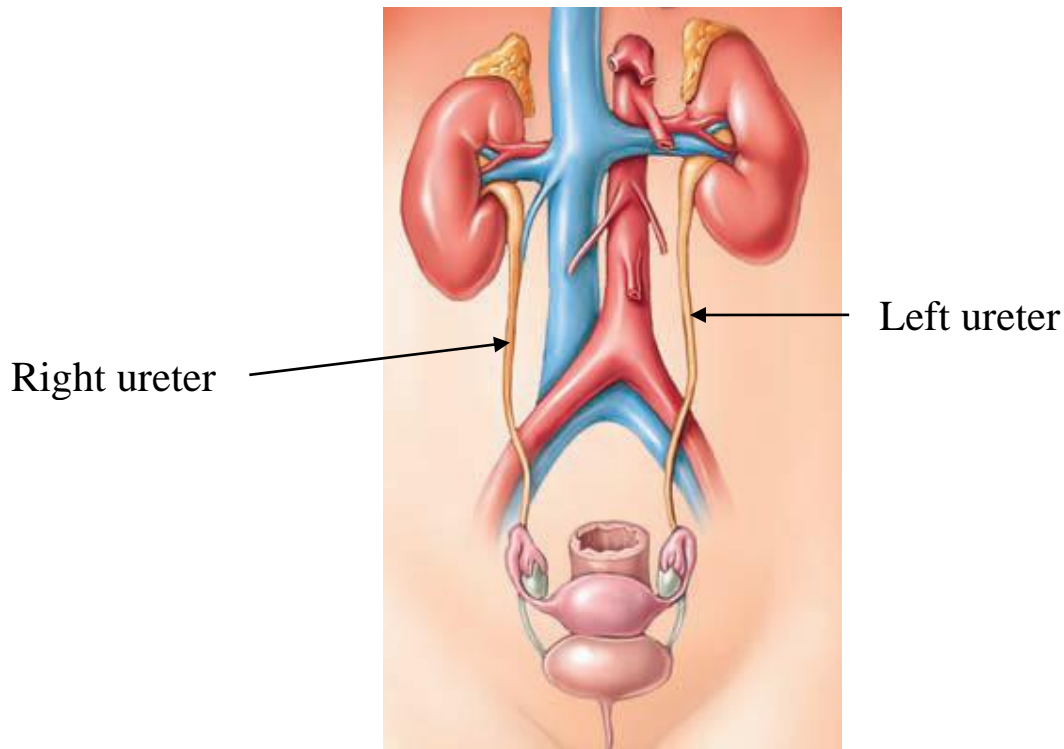


Figure 2.4 Show: Anatomy of ureters

2.1.1.4 Urinary Bladder:

The urinary bladder is a hollow, distensible muscular organ situated in the pelvic cavity posterior to the pubic symphysis. In males, it is directly anterior to the rectum; in females, it is anterior to the vagina and inferior to the uterus.

Folds of the peritoneum hold the urinary bladder in position.

When slightly distended due to the accumulation of urine, the urinary bladder is spherical. When it is empty, it collapses. As urine volume increases, it becomes pear-shaped and rises into the abdominal cavity. Urinary bladder capacity averages 700–800 ml. It is smaller in females because the uterus occupies the space just superior to the urinary bladder.

In the floor of the urinary bladder is a small triangular area called the trigon.

The two posterior corners of the trigons contain the two ureteral openings; the opening into the urethra, the internal urethral orifice, lies in the anterior corner. Because its mucosa is firmly bound to the muscularis, the trigons has a smooth appearance.

Three coats make up the wall of the urinary bladder:

The deepest is the mucosa, a mucous membrane composed of transitional epithelium and an underlying lamina propria similar to that of the ureters. Rugae (the folds in the mucosa) are also present to permit expansion of the urinary bladder. Surrounding the mucosa is the intermediate muscularis, also called the detrusor muscle which consists of three layers of smooth muscle fibers: the inner longitudinal, middle circular, and outer longitudinal layers. Around the opening to the urethra the circular fibers form an internal urethral sphincter; inferior to it is the external urethral sphincter, which is composed of skeletal muscle and is a modification of the deep muscles of the perineum. The most superficial coat of the urinary bladder on the posterior and inferior surfaces is the adventitia, a layer of areolar connective tissue that is continuous with that of the ureters. Over the superior surface of the urinary bladder is the serosa, a layer of visceral peritoneum.

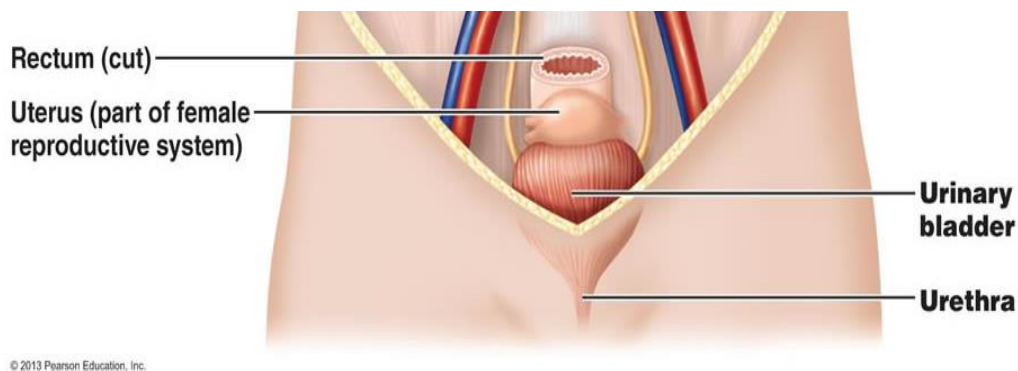


Figure (2.5) Show :Anatomy urinarybladder (www.google.com)

2.1.1.5 Urethra:

The urethra is a small tube leading from the internal urethral orifice in the floor of the urinary bladder to the exterior of the body. In both males and females, the urethra is the terminal portion of the urinary system and the passageway for discharging urine from the body.

In males, the urethra also extends from the internal urethral orifice to the exterior, but its length and passage through the body are considerably different than in females. The male urethra first passes through the prostate, then through the deep muscles of the perineum, and finally through the penis, a distance of about 20 cm (8 in.). It discharges semen (fluid that contains sperm) as well.

The male urethra, which also consists of a deep mucosa and a superficial muscularis, is subdivided into three anatomical regions:

- (1) The prostatic urethra passes through the prostate.
- (2) The membranous (intermediate) urethra, the shortest portion, passes through the deep muscles of the perineum.
- (3) The spongy urethra, the longest portion, passes through the penis.

In females, the urethra lies directly posterior to the pubic symphysis, is directed obliquely, inferiorly, and anteriorly, and has a length of 4 cm (1.5 in.)

The opening of the urethra to the exterior, the external urethral orifice, is located between the clitoris and the vaginal opening. The wall of the female urethra consists of a deep mucosa and a superficial muscularis. The mucosa is a mucous membrane composed of epithelium and lamina propria (areolar connective tissue with elastic fibers and a plexus of veins).

The muscularis consists of circularly arranged smooth muscle fibers and is continuous with that of the urinary bladder.

2.1.1.6 The blood supply of the kidney:

The renal artery arises from the aorta at the level of the 2nd lumbar vertebra. Each renal artery usually divides into five **segmental arteries** that enter the hilum of the kidney. They are distributed to different segments or areas of the kidney. **Lobar arteries** arise from each segmental artery, one for each renal pyramid. Before entering the renal substance, each lobar artery gives off two or three **interlobular arteries**. The interlobular arteries run toward the cortex on each side of the renal pyramid. At the junction of the cortex and the medulla, the interlobular arteries give off the **arcuate arteries**, which arch over the bases of the pyramids. The arcuate arteries give off several **interlobular arteries** that ascend in the cortex. The **afferent glomerular arterioles** arise as branches of the interlobular arteries.

The renal vein emerges from the hilum in front of the renal artery and drains into the inferior vena cava.

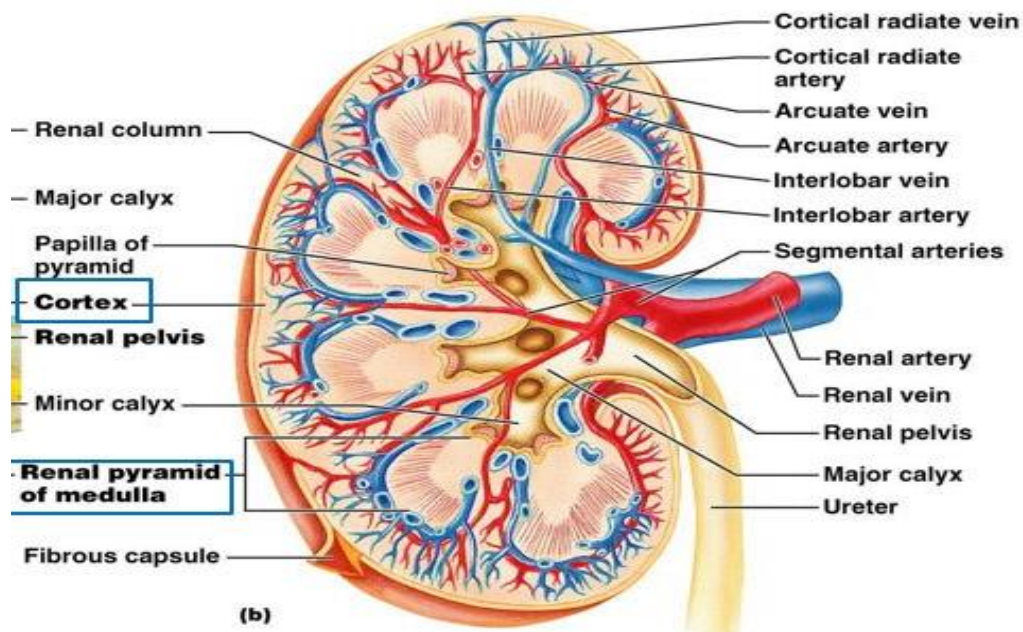


Figure (2.6) Show vasculature of the kidney (www.infovisual.info)

2.1.1.7 Lymph Drainage of the kidney:

Lymph drains to the lateral aortic lymph nodes around the origin of the renal artery.

2.1.1.8 Nerve Supply

The nerve supply is the renal sympathetic plexus. The afferent fibers that travel through the renal plexus enter the spinal cord in the 10th, 11th, and 12th thoracic nerves.

2.1.2 Physiology:

1. multiple function of the kidneys

Regulate blood volume ,help regulate blood pressure, Synthesize glucose ,Release erythropoietin ,Participate in vitamin D synthesis, antidiuretic hormone (ADH),Excrete wastes by forming urine.

2. The ureters transport urine from the kidneys to the urinary bladder.

3. The urinary bladder stores urine.

4. The urethra discharges urine from the body.

2.1.3 Pathology:

Some of Pathology of renal system:-

2.1.3.1 Renal Ectopic:

Is congenital anomaly in which a kidney fail to ascend to its normal position .is usually found in pelvis and its associated with congenitally short ureter .can located anywhere in abdomen and rare in thorax.

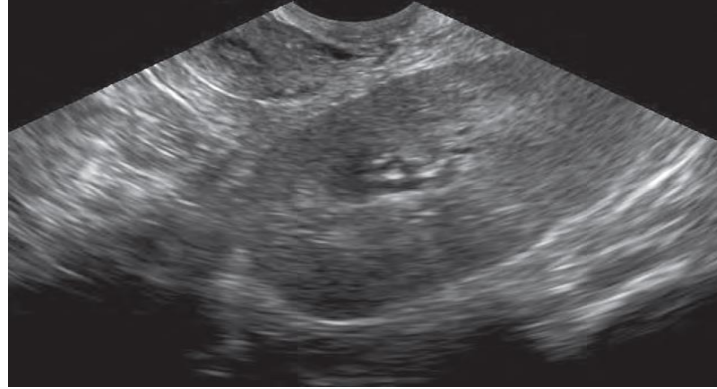


Figure (2.7) Show : **pelvic kidney**. Transverse sonogram demonstrates a left pelvic kidney posterior to the uterus. (Diagnostic ultrasound. Carol M. Rumack .et al.4th edition 2011)

2.1.3.2: Renal abscess:

Is pus containing cavity that is surrounded by inflamed tissue resulting from suppuration in localized infection like *Candida albicans* is fungal Infection the most common fungal agent that affects the urinary tract. Renal parenchymal involvement ,typically manifested by small parenchymal abscesses, occurs in the context of diffuse systemic involvement. The abscesses may calcify over time.

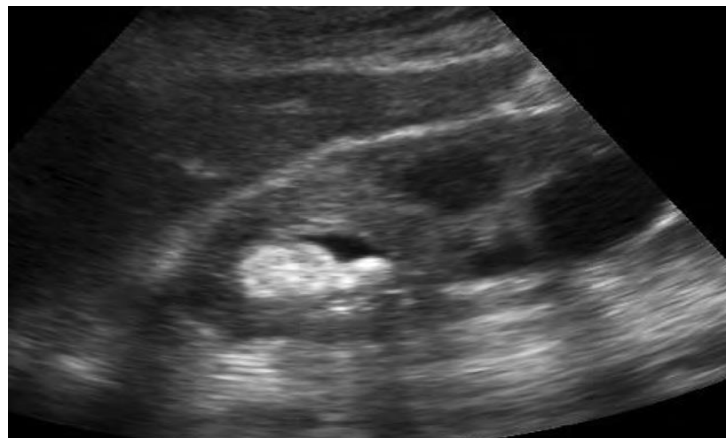


Figure 2.8 Shows fungus ball. Sagittal sonogram shows anechoic soft tissue mass within a dilated upper-pole cortex. .(Diagnostic ultrasound. Carol M. Rumack .et al.4th edition 2011)

2.1.3.3 Renal duplex collecting system

Duplex collecting system is the most common congenital anomaly of the urinary tract, with a reported incidence of 0.5% to 10% of all live births. The degree of duplication is variable. Duplication is complete when there are two separate collecting systems and two separate ureters, each with their own ureteral orifice. Duplication is incomplete when the ureters join and enter the bladder through a single ureteral orifice.

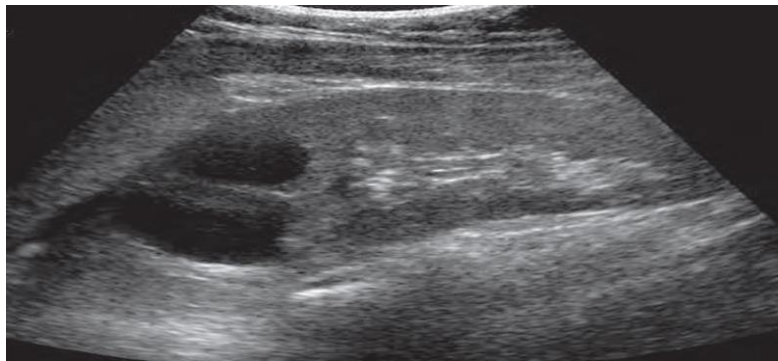


Figure (2.9) Show duplex collecting system. Sagittal sonogram shows an upper-pole cystic collecting system dilation and cortical thinning.

(Diagnostic ultrasound. Carol M. Rumack .et al.4th edition 2011)

2.1.3.4 Renal stone:

Kidney stones are common urinary tract problem . They may be solitary or multiple and vary in size .can cause obstruction .hard, solid particles that form in the urinary tract. If a stone (even a small one) blocks the flow of urine, excruciating pain may result, and prompt medical treatment may be needed.

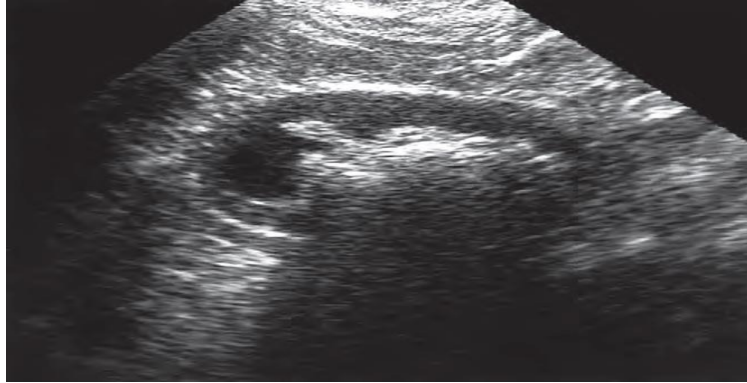


Figure (2.10) Show : **Large stag horn stone** with severe upper-pole caliectasis..(Diagnostic ultrasound. Carol M. Rumack .et al.4th edition 2011)

2.1.4 Renal Stone in ultrasound:

Will be seen as an echogenic focus that produces posterior acoustic shadowing in ultrasound image. Should be seen in two views long axis and short axis views.

2.1.5 The ultrasound machine use for exam:

U/S machine in Omdawanban was used machine use dmindary – dp-6600 convex transducer (3 to 5) MHz

U/S machine in Ribat University Hospital was used Siemens Sonoline G20 real time with convex transducer(2-6) MHz

That with facility of computerized reporting system will used.

2.1.6 Preparation of the patient:

Non and start with the patient lying on his /her back (supine) cover the right upper abdomen liberally with coupling agent.

2.1.7 Setting the correct gain:

Start by placing the transducer over the right , left upper abdomen . Angle the beam as necessary and adjust the gain to obtain the best image of the renal parenchyma.

2.1.8 After care of patient:

Make patient comfortable and alleviate his or her fears if apprehensive about the examination.

Explain the procedure calmly because his full co-operation is needed.

2.1.9 Ultrasonography normal appearance:

The cortex of the normal kidney is slightly hypoechoic when compared to the adjacent liver parenchyma, although this is age-dependent. In young people it may be of similar echogenicity and in the elderly it is not unusual for it to be comparatively hyperechoic and thin. The medullary pyramids are seen as regularly spaced, echo-poor triangular structures between the cortex and the renal sinus. The tiny reflective structures often seen at the margins of the pyramids are echoes from the arcuate arteries which branch around the pyramids. The renal sinus containing the PCS is hyperechoic due to sinus fat which surrounds the vessels. The main artery and vein can be readily demonstrated at the renal hilum and should not be confused with a mild degree of PCS dilatation.

2.2 Previous studies :

MushiraS.Ahmed (2013) . studied that male affected more than female with ratio 2:1 .most common age group between 20_ 40 years and 56%have renal stone and were 44% renal stone with hydronephrosis.

Omer .Idam (2007) . studied that ultrasound investigation the best and main modality for detection urolithiasis by 90% of examine case .

Islam Hashim (2014) .studied that ultrasound found almost normal kidney size ,with mean volume 103 for right kidney and 11 for the left kidney . with only 18% above normal upper limit , and most likely the enlargement contributed to inflammatory process .22% patient have renal stone ,8% in right kidney , 10 % in left kidney ,and 4 % bilateral, 18 % have hydronephrosis , 6% in each side and 6% bilaterally .56% of hydronephrotic patient have renal stone.

(Ljünghall and Hedstrand 1975; Norlin et al. 1976).Studied that the incidence of urinary stone disease in the western world is increasing: 6%–15% of males and 4%–5% of females can expect to suffer from the condition at some time during their lives.

(Chirag Dave, MD2016). Studied that renal ultrasonography works best in the setting of relatively large stones within the renal pelvis or kidney and sometimes at the UPJ. Whether the stones are radiolucent or radio-opaque does not matter because an ultrasound image is based strictly on density, not on calcium content.

Lemon etal (2014) . Studied that urinary stone may abstract urine flow at any point of urinary tract leading to complication such as hydronephrosis and urinary stasis with subsequent infection. Kidney stone .Male affected more 1:10 than female .

Andrew et al (2010) studied limitation to ultrasound in detection and measurement of urinary tract stone which done to evaluate differences in stone measurement using U/S.

Chapter three
Materials and methods

Chapter three

Materials and methods

This study is performed in ultrasound department and microscopic laboratory in Omdawanban and Ribat University Hospital during May 2016 to November 2016.

3.1 Materials:

3.1.1 Study population:

Fifty patients of both sex were examined by high resolution B-mode ultrasonography of the kidney scanning protocols and urine examination with exclude pregnant women and diabetic patient.

3.1.2 Ultrasound machine:

U/S machine in Omdawanban was used Mindary – dp-6600 convex transducer (3 - 5) MHz

U/S machine in Ribat University Hospital was used Siemens Sonoline G20 real time with convex transducer (2- 6) MHz

That with facility of computerized reporting system will used.

3.2 Methods:

3.2.1 Position of the patient:

Patient lying supine left lateral oblique ,right lateral decubitus .

Scanning procedure : spirit out gel in upper side of abdomen ,to scan the right kidney can be seen best using the liver as an acoustic window . scanning is always done in deep suspended inspiration ask the patient to take a deep breath and hold the breath in the patient must be relax and breath normally . transducer moved smoothly along the costal margin , aligning slightly toward the lateral edge of the liver start with longitudinal scan over the right upper abdomen and then follow with a transverse scan .Locate the

upper pole of the kidney top look .rotate the transducer to join the upper and lower poles then transducer moved cephalic to caudal position the kidney in center of screen .beam angled slightly from side to side sweeping through the long section of the kidney .To do transvers section angulation and position of transducer in long section rotated 90 maintaining angulation.

To visualize the left kidney , apply coupling agent to the left upper abdomen scan the left kidney in similar sequence.

3.2.2 Study variable:

The variable that collected from patient include gender , age , clinical sign and symptom , lab investigation urine, finding ultrasound.

3.2.3 Data collection:

Data collected according to work sheet (appendix) include all above variable data.

3.2.4 Image interpretation:

The image was exam by technologist in Omdawanban and Ribat University Hospital.

3.2.5 Data analysis :

The data first summarized into master sheet and then analyzed , by using SPSS(Statistical Package of the Social Science)

Ethical consolidation:

No identification or individual details were published.

No information or patient details will be disclosed or used for reasons

Chapter four

Results

Chapter four

The result

Results this study was 50 patient with suspected Renal stone the following this table and figure frequency shows summary of the result including gender , age ,symptoms , lab investigation ,finding ultrasound.

Frequency Table

Table No (4.1) demonstrates: Gender frequency distribution among the sample

Gender	Frequency	Percent
Male	31	62.0
Female	19	38.0
Total	50	100.0

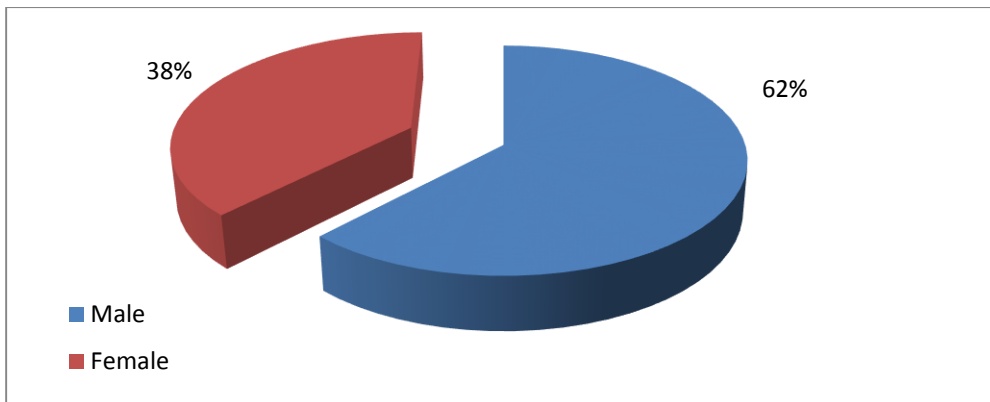


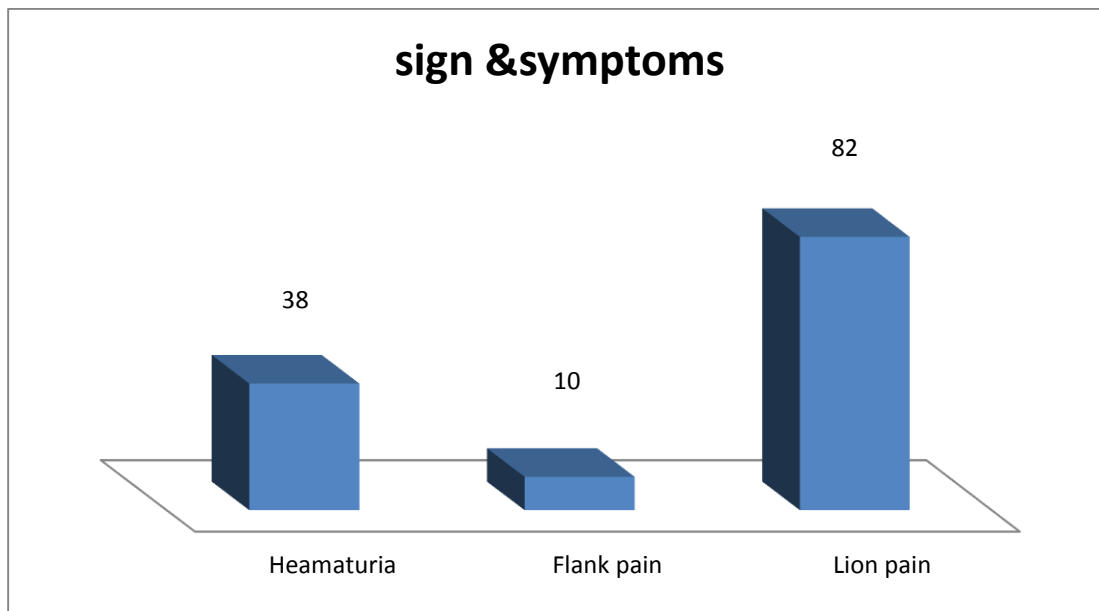
Figure (4.1)shows :gender distribution among the sample

Table No(4.2) demonstrates: age frequency distribution among the sampling

Age	Frequency	Percent
10 – 19	1	2.0
20 – 29	10	20.0
30 – 39	15	30.0
40 – 49	10	20.0
50 – 59	6	12.0
Higher than 60	8	16.0
Total	50	100.0

Table No (4.3) demonstrates: Sign and Symptom frequency distribution among the sample

Sign & symptom	frequency	Percent
Lion pain	41	82.0
Flank pain	5	10.0
Hematuria	19	38.0



Figure(4.3) shows : Sign and symptom distribution among the sample

Table (4.4) demonstrates: site of pain distribution among the sample

Site of pain	frequency	Percent
Right	16	32
Left	21	42
Both	13	26

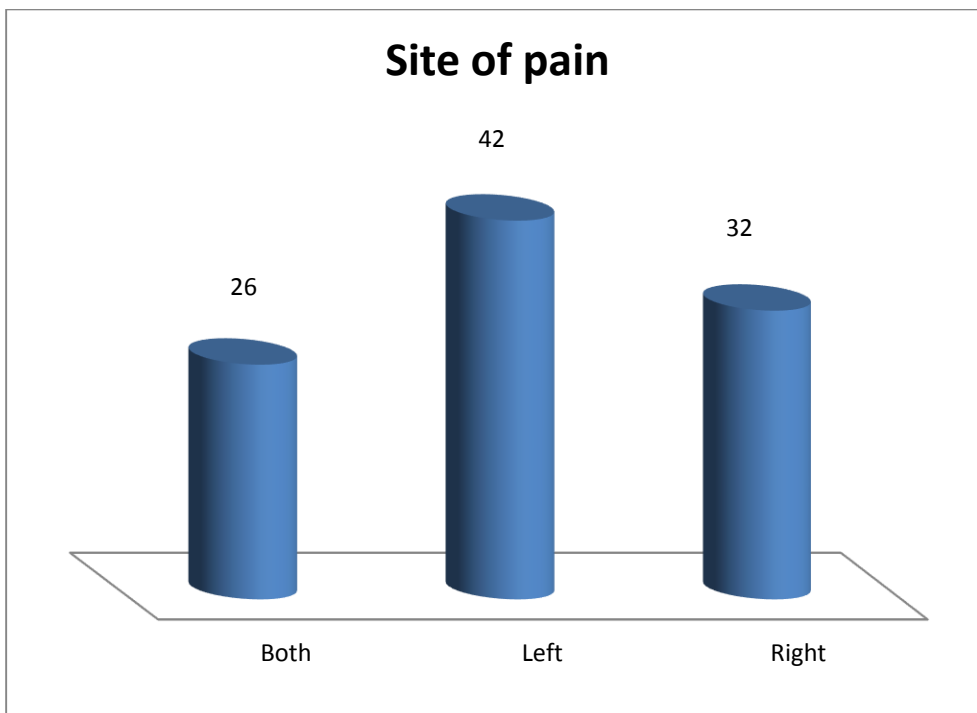


Figure (4.5) shows: Site of pain distribution among the sample

Table No (4.5) demonstrates: lab investigation urine exam frequency distribution among the sample

Lab investigation urine exam	Frequency	Percent
RBCs	32	64.0
Pus	19	38.0
Ca –oxalate	7	14.0
Amorphous	2	4.0

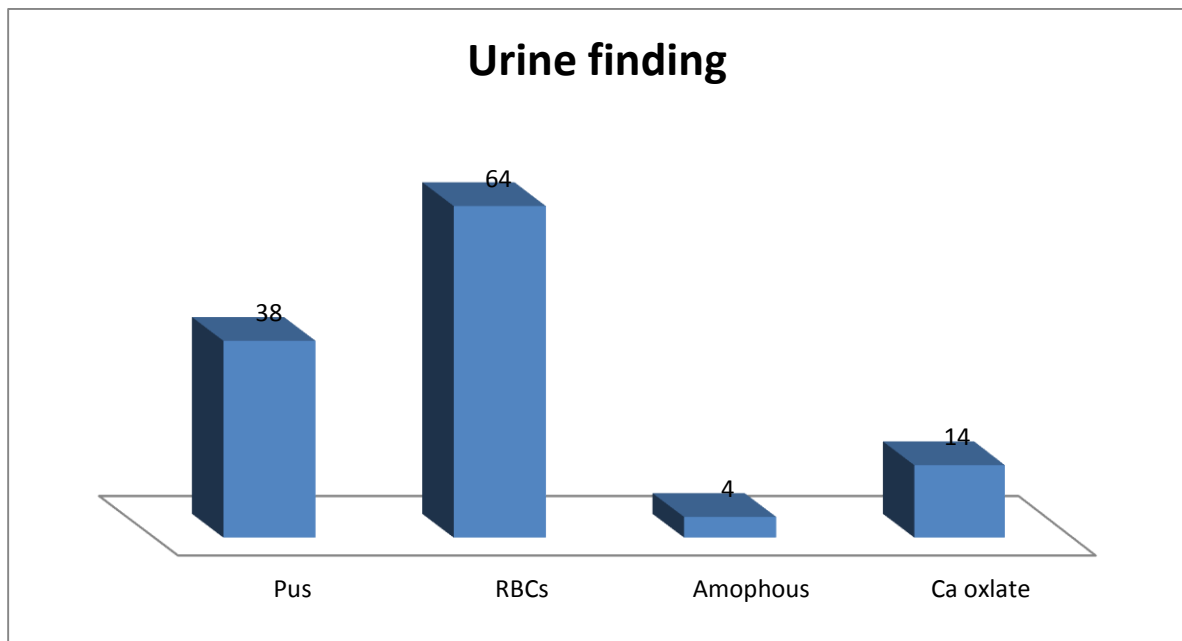


Figure (4.5) shows: lab investigation urine exam distribution among the sample

Table No (4.6) demonstrates: kidney ultrasound finding frequency distribution among the sample

Kidney Ultrasound finding	frequency	Percent
Stone	31	62.0
Stone with hydronephrosis	10	20.0
Deposit crystal	5	10.0
No stone	4	8.0

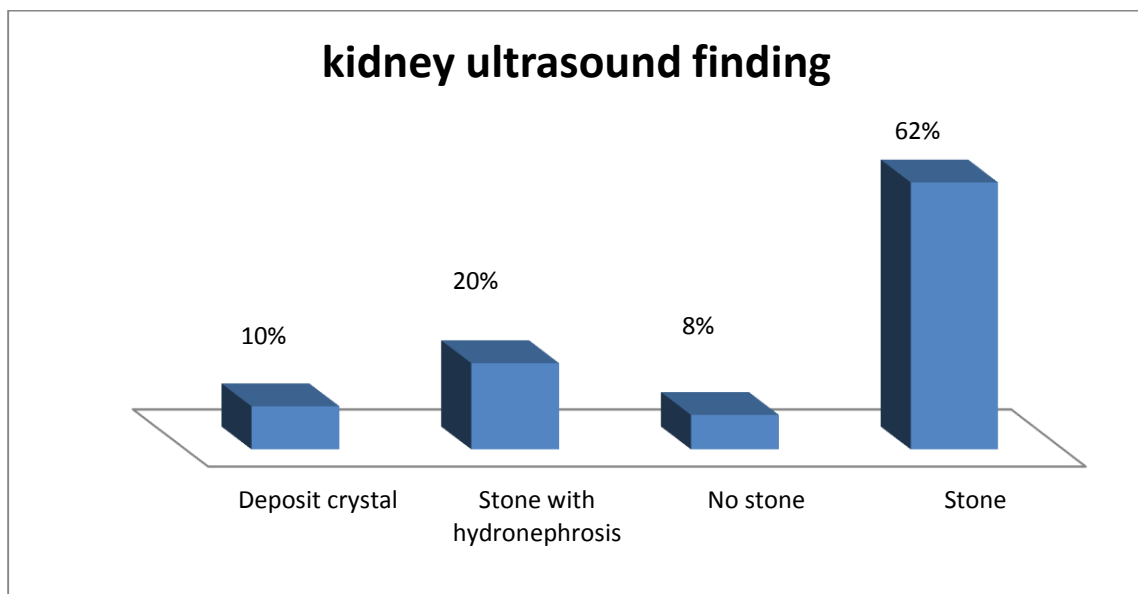


Figure (4.6) shows : kidney ultrasound distribution among the sample

Table No (4.7) demonstrates: Site of stone frequency distribution among the sample

Site of stone	Frequency	Percent
Right	13	26.0
Left	21	42.0
Both	7	14.0

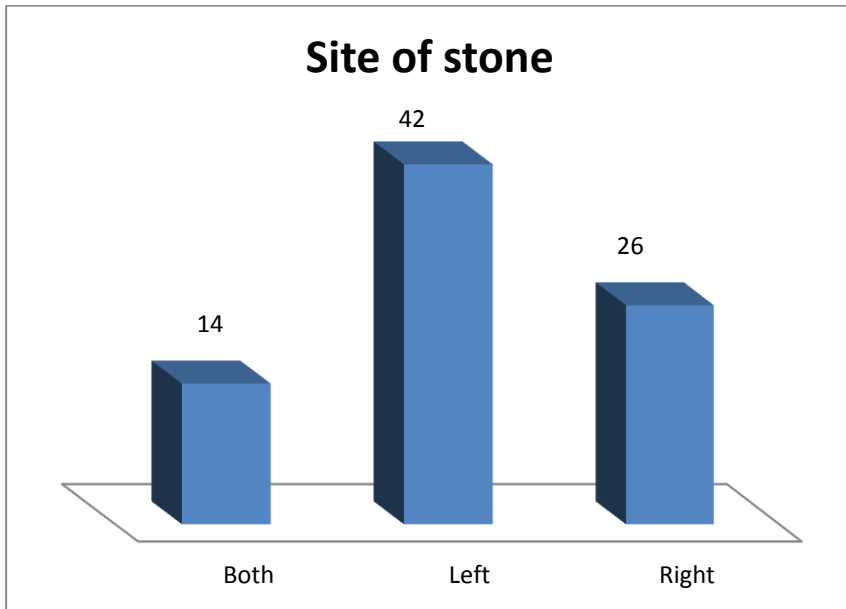


Figure (4.7) shows: site of stone distribution among the sample

Chapter five

Discussion, Conclusion and Recommendation

Chapter five

Discussion, Conclusion and Recommendations

5.1 Discussion

On this study of 50 patient came to ultrasound department for renal ultrasound were suspected renal stone . the study found that number of male 31 which was 62%,higher than female 19which was 38%according to the table no(4.1)agree with previous study (Lemon etal 2014)

The study found more affected age between (30- 39)years old which was (30%).according to the table no (4.2)

On the studding the sign and symptom (lion pain) on table (4.3)was grater one 41 patient which was (82%). But with hematuria there was only 19patient which was (38%) and flank pain 5 patient which was (10%).

Lab investigation founded RBCs 32 (64 %) , pus 19 patient (38%), ca-oxalate 7 patient (14%), amorphous 2 patient (4%) according to the table no (4.5)

The study found also in the table no (4.6) renalstone31 (62%)patient , renal stone with hydronephrosis 10 (20%)Patient, renal deposit crystal 5 (10%), normal renal no stone 8 (4%).

Table (4.7) the study found site of stone right renal stone 13pataient(26%), left renal stone 21 patient (42%), both renal stone 7pateint (14%).

The result proved the left kidney affected more than right kidney by (42%)

The study found the correlation between RBCs and finding ultrasound . Alternative hypothesis there is no relationship between RBCs and finding

renal ultrasound .And significant value is .032 which is low significant , so we accept the null hypothesis .That is mean there is relationship between RBCs and finding renal ultrasound .

The study found the correlation between pus and finding renal ultrasound .Alternative hypothesis there is relationship between pus and finding renal ultrasound .And significant value is .078 which is high significant , so we reject the null hypothesis .That is mean there is no relationship between pus and finding renal ultrasound

The study found the correlation between ca- oxalate and finding renal ultrasound .Alternative hypothesis there is no relationship between ca oxalate and finding renal ultrasound .And significant value is .000 which is low significant , so we accept the null hypothesis .That is mean there is relationship between ca – oxalate and finding renal ultrasound

The study found the correlation between amorphous and finding renal. Alternative hypothesis there is no relationship between pus and finding renal ultrasound .And significant value is .040 which is low significant , so we accept the null hypothesis .That is mean there is relationship between amorphous and finding renal ultrasound

5.2 Conclusion

The study concluded that:

1. 31(62%) patient have renal stone
2. 10 (20%) patient have renal stone with hydronephrosis,
3. 5(10%)patient have deposit crystal and 4(8%) have normal renal .
4. The result proved the male which were (62%) affected by renal stone more than female(38%) .
5. The affected group by U/S are (30-29) years old by (30%)
6. The left kidney affected by stone more than right by (42%)
7. The study found correlation ship between RBCs and Kidney stone .
8. This study showed that the U/S and urinalysis are useful in diagnosis of renal stone .

5.3 Recommendations

Continuous education is important for improve in this study.

When patient got symptom must go to the doctor and to department for check up normal kidney or not .spicily both investigation are safely, easily to do it , there no harmful and important thing they are cheaper.

Further studies should be done to evaluate the accuracy of Ultrasound should be first method of choice to detection renal stone.

Ultrasound in detecting the causes as well as complication of the RBCs and pyuria in kidney.

I recommended the usage of CT KUB to clarify site, size, component and exactly number of stone

REFERENCES:

Carol A Krebs . 1993.VishanUltrasound. Atlas of Disease Processe.

Carol M. Rumack etal , 2011, DIAGNOSTIC ULTRASOUND , 4th edition.

Jane A Bates , 2004, Abdominal Ultrasound ,How , Why , and When,
2ndedition,Churchillivingstone ,London,166-171

P . E .S .Palmer. .Manual of diagnostic ultrasound . 2011,

Ross and Wilson , ,2001, Anatomy and Physiology in Health and Illness ,9th
edition.

Tor tora , Bryan Derrickson , 2009 , Principles of Anatomy and
Physiology ,12th edition.

www.google.com

www.health.com

www.infovisual.info

www.labtest.online.org

www.medicinehealthy.com

www.nhsc.hrsa.gov.National.

www.pdrhealth.com

Appendices

Appendix A

Evaluation Renal stone using Ultrasonography compared with Microscopic laboratory findings

1. Name :

2. Gender:

3. Age:

4. presenting complaint:

1. Symptomatic: no symptomatic:

In case of symptomatic patient : symptom are:

Lion pain: flank pain: hematuria:

2. Site of pain:

Right: left : both:

5. Ultrasound finding:

Stone : no stone: stone with hydronephrosis:

deposit crystal:

6. Site of stone :

Right: left : both:

7. Urine finding:

Ca oxalate: amorphous: RBCs:

Pus :

Appendix B

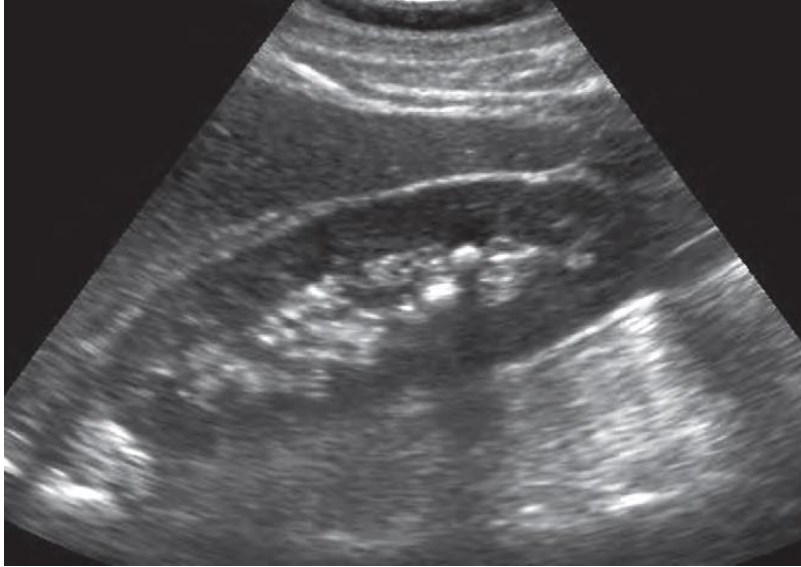


Image (1) : Demonstrate the Rt Renal stone and RBCs in urine of female 35years old

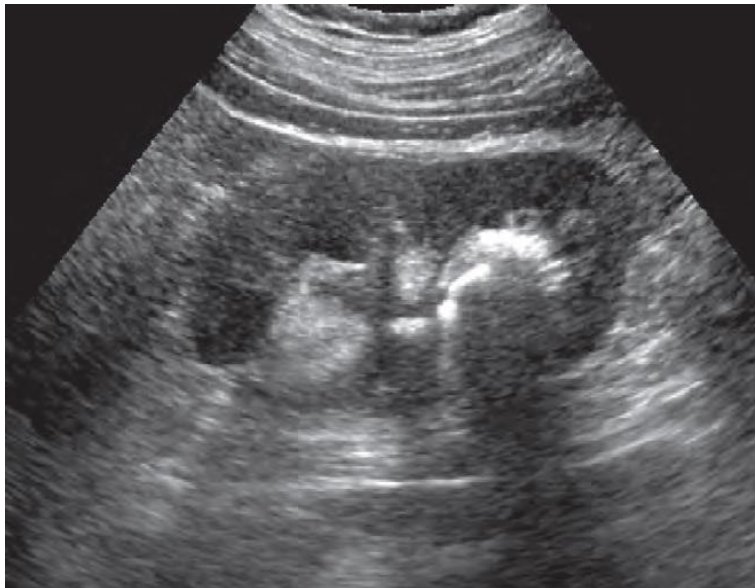

Image No(2): Demonstrate the Rt renal stone associated mild hydronephrosis and pus in urine of female 45 years old with RBS and calcium oxalate.

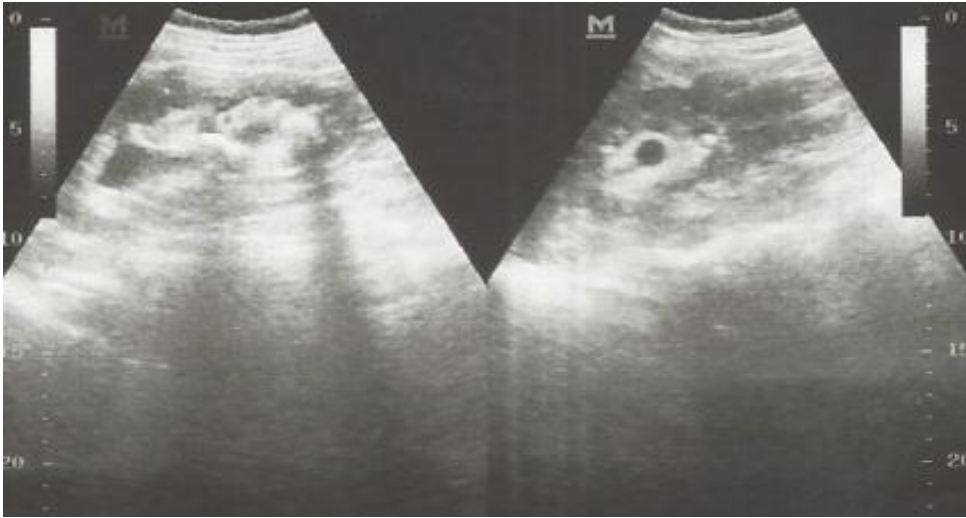
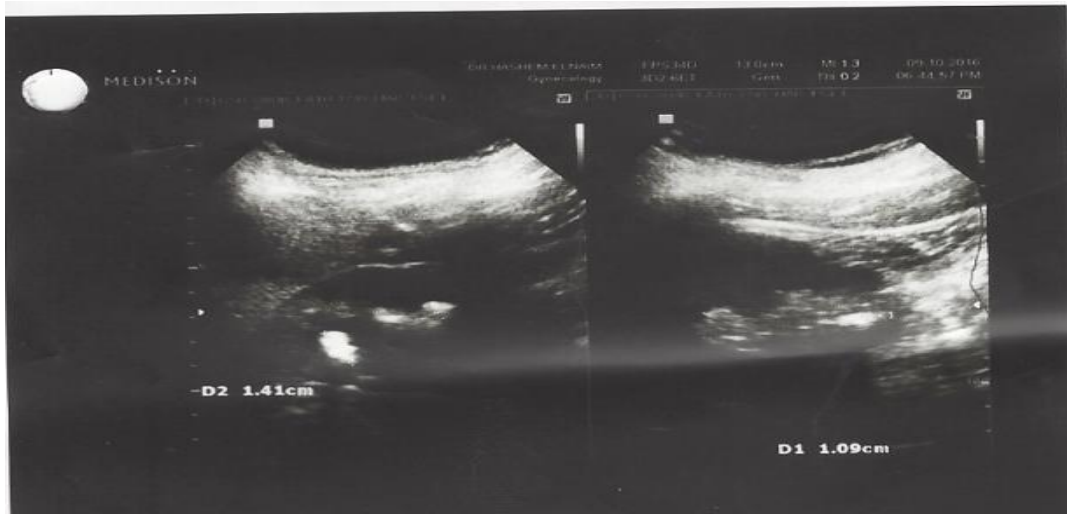


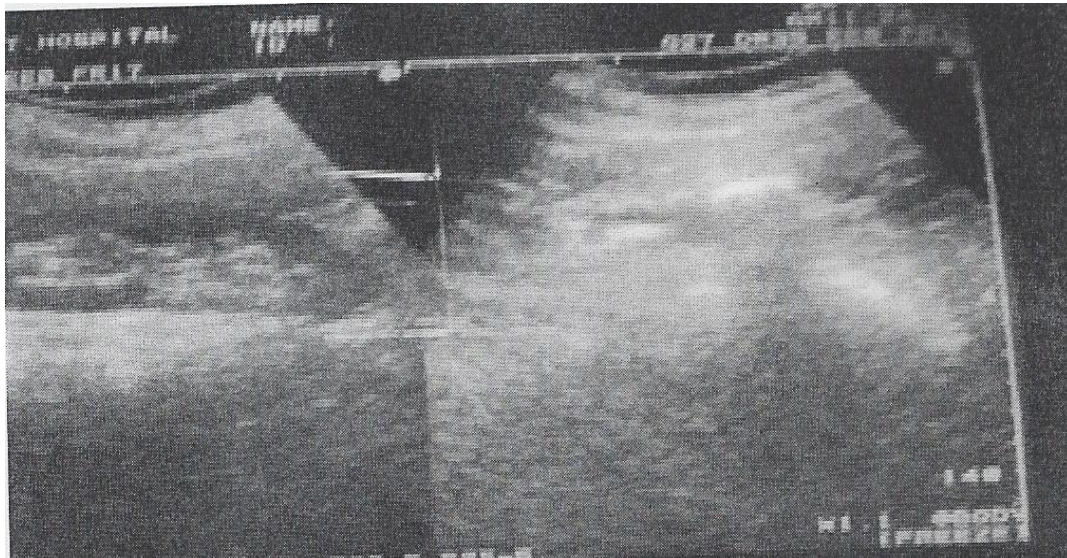
Image No(3): Demonstrate the with Multiple renal stone with associated hydronephrosis and amorphous ,RBCs in urine of male 50 years old .

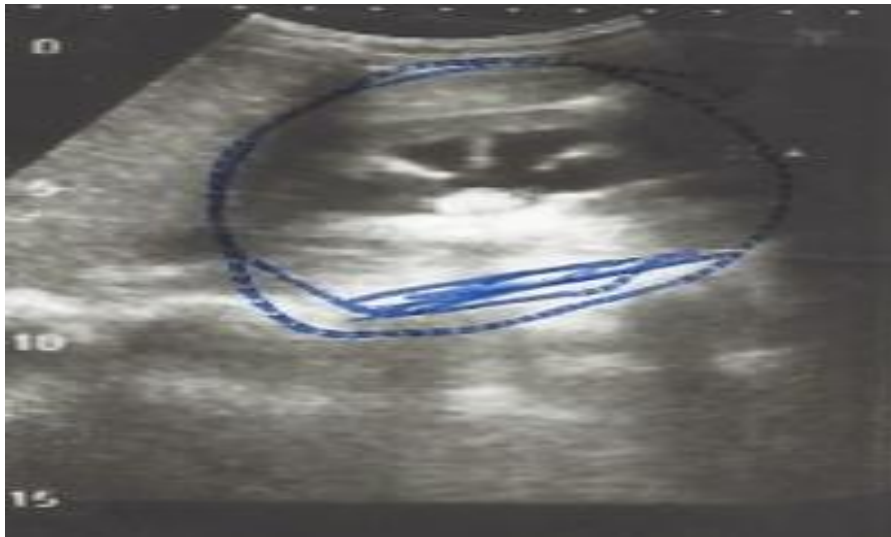

Image No(4) : Demonstrate the Rt renal stone associated mild hydronephrosis and Pus ,RBCs in urine of female 42 years old



ImageNo(5): Demonstrate the Rt & Lt renal stone and RBCs in urine of male 33 years old



ImageNo(6): Demonstrate the multiple Lt renal associated mild hydronephrosis with ca-oxalate and pus in urine of female 42 years old

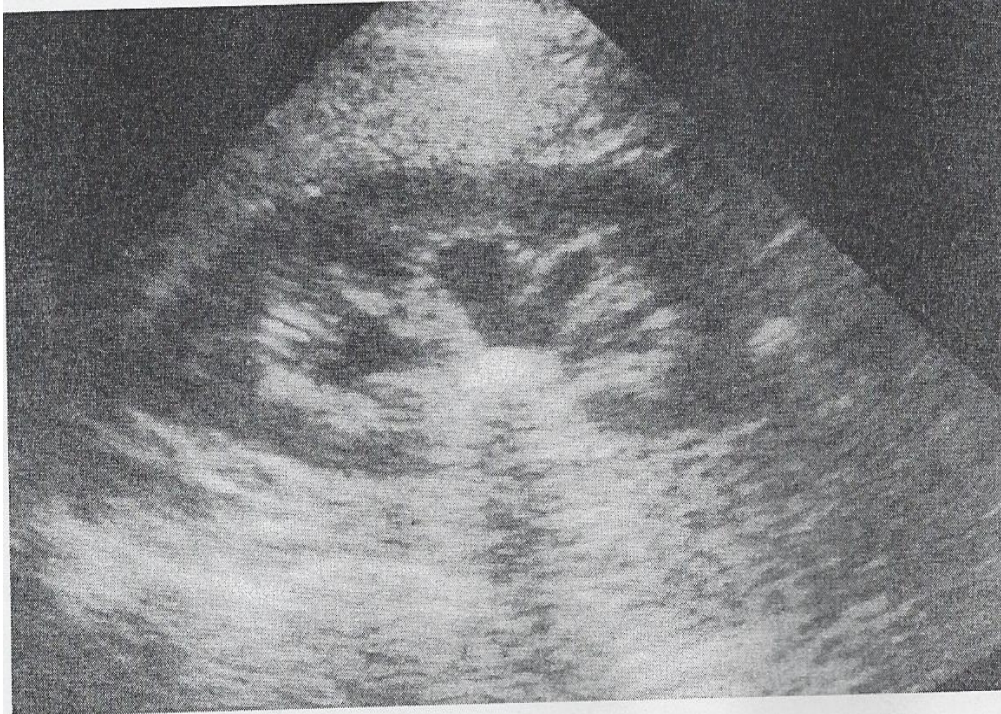
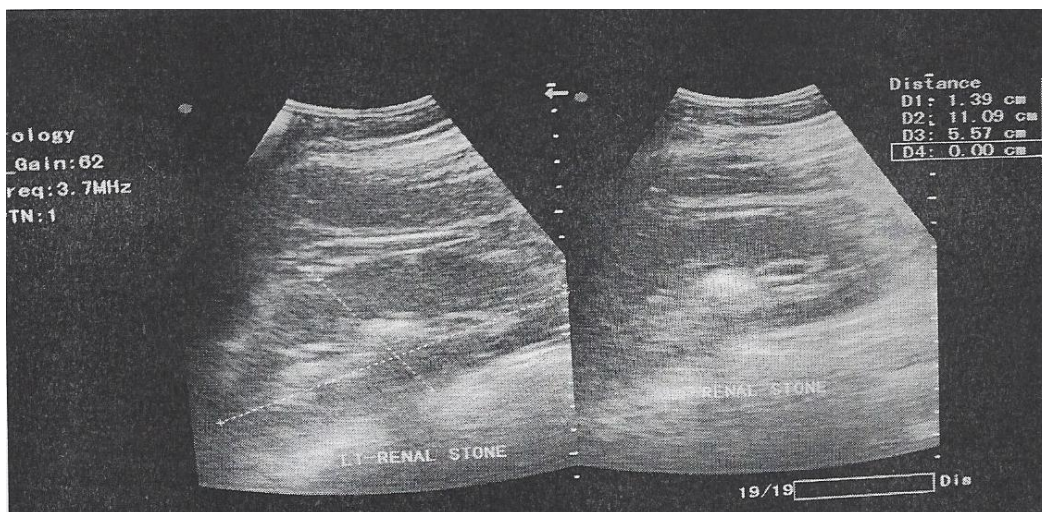


Image No(7) : Demonstrate the Lt renal stone with mild hydronephrosis and RBCs, pus in urine of female 30 years old



IamgeNo (8) : Demonstrate the with Rt , Lt renal stone and RBCs in urine of male 37 years old

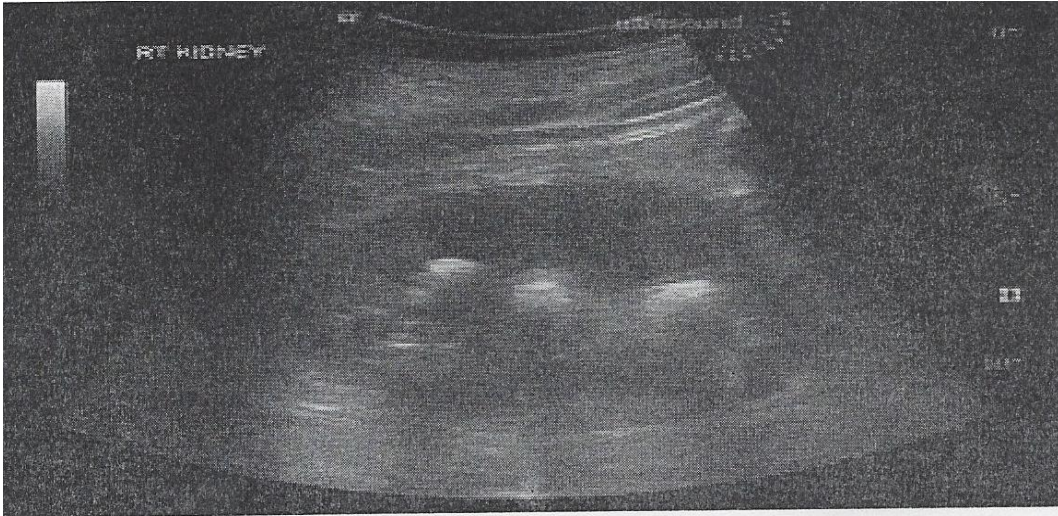

Image No(9): Demonstrate the Rt multiple stone with RBCs in urine of female 35 years old