

Appendices:

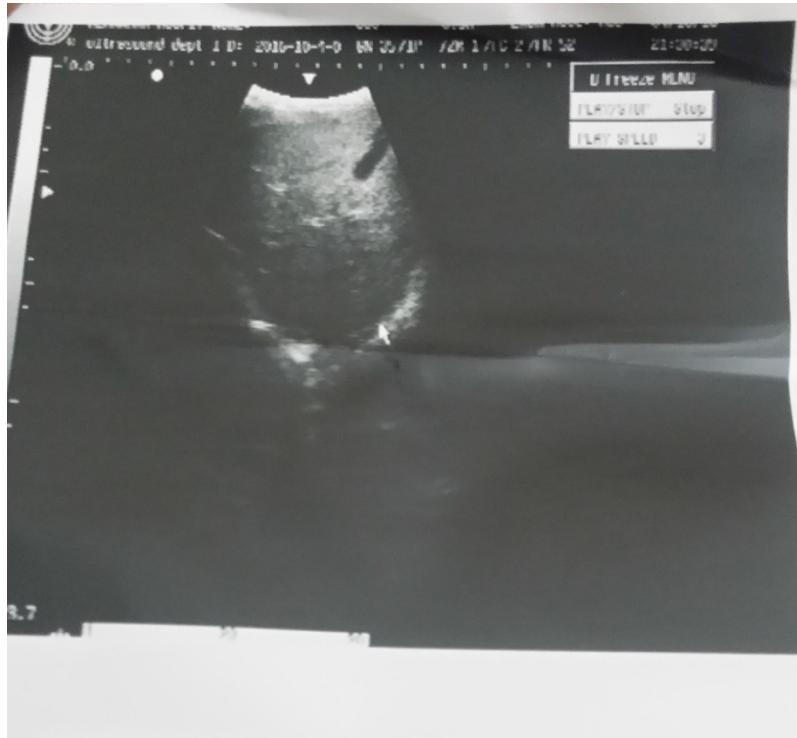

Image (1) Longitudinal scan diabetic patient show no gallstone




Image (2) Longitudinal scan diabetic patient show no gallstone

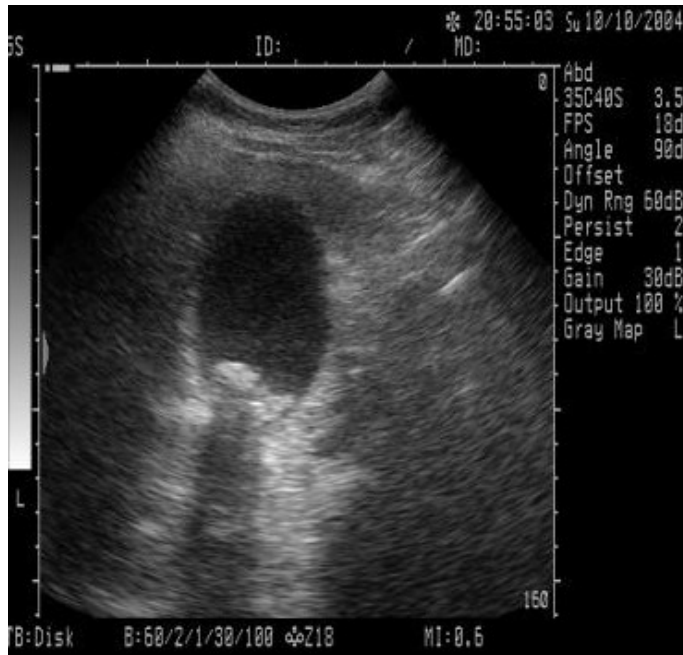

Image (3) Longitudinal scan non-diabetic patient show gallstone

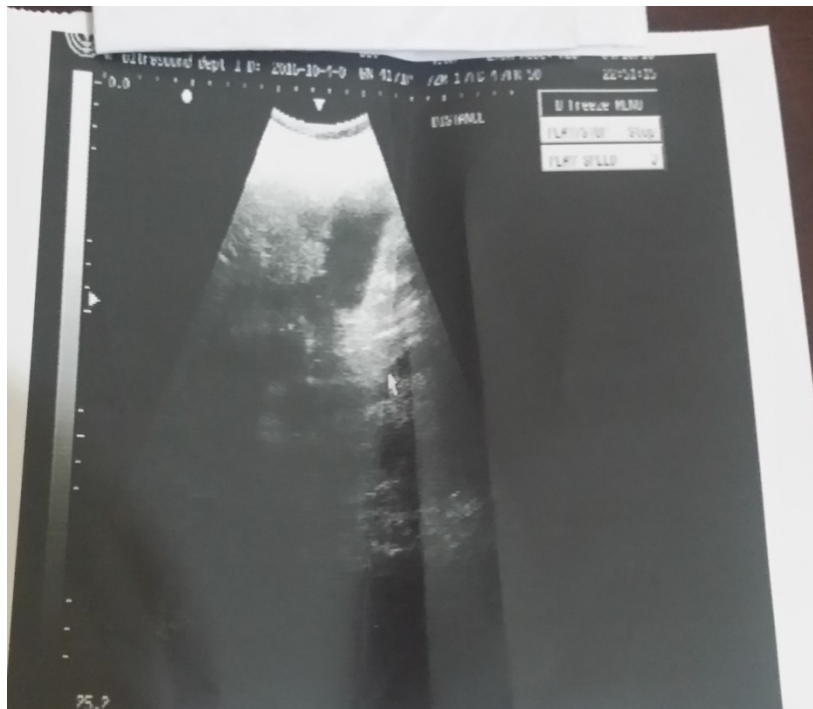

Image (4) Longitudinal scan non-diabetic patient show no gallstone

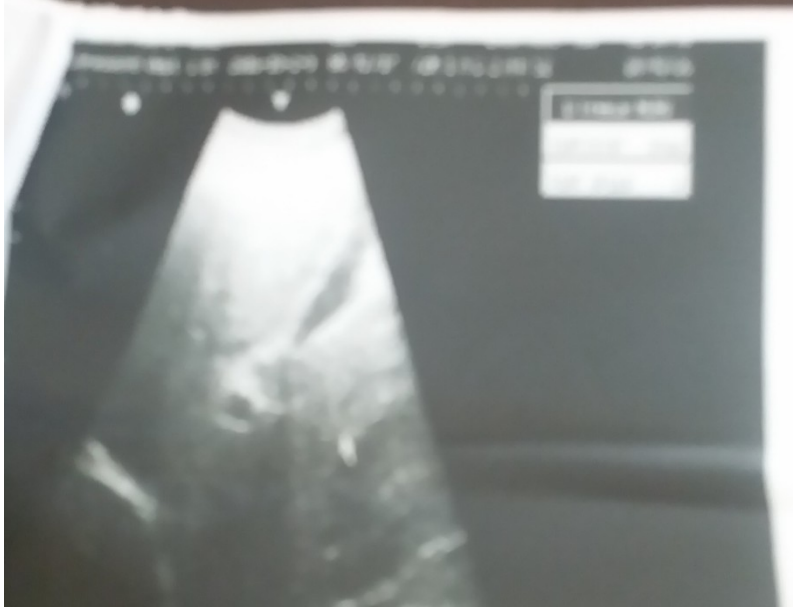

Image (5) Longitudinal scan diabetic patient show no gallstone

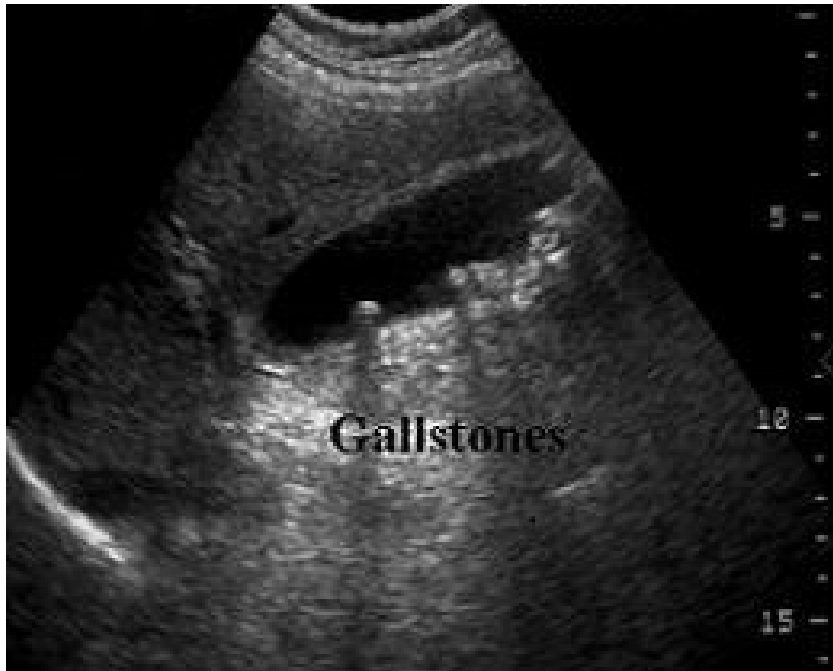

Image (6) show transverse scan with gallstones in diabetic patient

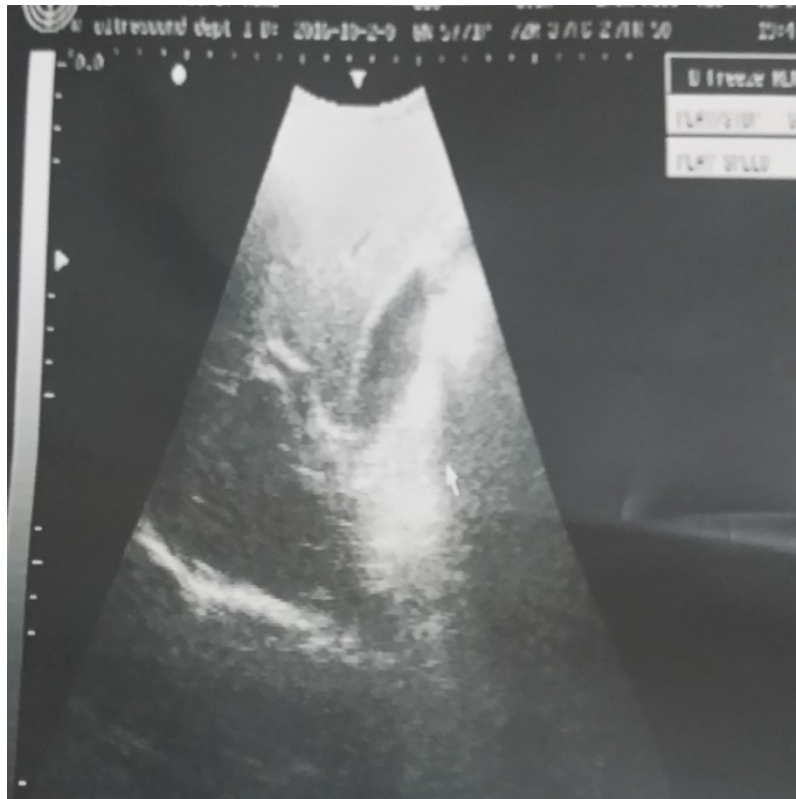

Image (7) Longitudinal scan diabetic patient show no gallstone