

بسم الله الرحمن الرحيم

**Sudan University of Science and Technology**  
**College of Graduate Studies**

**Estimation of Gestational Age by Measuring Bi-parietal Diameter  
and Femur length In Second Trimester**

تقدير عمر الجنين بقياس عظم الرأس وطول عظم الفخذ في الفترة الثانية من الحمل

*A thesis submitted for partial fulfillment of the requirement of MSc in  
medical Diagnostic Ultrasound*

**By**

**Zein Alabdeen Mahmoud Mohammed**

**Supervisor**

**Dr. Asma Ibrahim Ahmed**

**2016**

# الآية

بسم الله الرحمن الرحيم

قال تعالى:

(يَرْفَعُ اللَّهُ الَّذِينَ آمَنُوا مِنْكُمْ وَالَّذِينَ أُوتُوا الْعِلْمَ دَرَجَاتٍ وَاللَّهُ بِمَا تَعْمَلُونَ خَبِيرٌ) (11)

سورة المجادلة - الآية (11)

# DEDICATION

**To my parents, my family**

**My colleagues and my friends**

**With ever lasting appreciation.**

## **Acknowledgements**

Firstly I would like to express my deepest gratitude to **Dr:- Asma Ibrahim Ahmed & also** I would like to thank the clinical staff , Obstetricians and Sonologists who helps me to achieve this work.

Thanks also extended to the pregnancies who took patience for accomplishing the ultrasound investigation.

## **ABSTRACT**

This study was done in Khartoum North Teaching Hospital in the period first of April 2016 to September 2016 . The study was a prospective cross\_ sectional research . The aim of the study to determine which is the better estimator of gestational age in the second trimester between femur length and bi-parietal diameter , The study population consisted of 50 normal pregnant women they were randomly selected in second trimester and Scan by real time ultrasound machine.

The data were analysed & the result of this study there was no significant difference between the mean of gestational age estimates from femoral length (FL) and bi-parietal diameter (BPD) , and also found that the average of BPD and FL is more accurate than the BPD or FL separately .

The study recommended that all pregnant women in second trimester must be follow up by US to confirm the GA and to evaluate expected date of delivery . To confirm E.D.D using average of FL & BPD rather than BPD or FL separately.

Using another different methods for measuring to estimate gestational age during pregnancy or in second trimester for pregnant women..

## خلاصة البحث

أجريت هذه الدراسة في مستشفى الخرطوم بحري التعليمي في الفترة من شهر أبريل 2016 حتى سبتمبر 2016 وهي دراسة مقطعية وكان الهدف منها تقدير عمر الجنين بقياس عظم الرأس وطول عظم الفخذ وأجريت هذه الدراسة على حوالي (50) من النساء الحوامل من غير أي علة مرضية وقد كانت العينة عشوائية وكانت نتيجة الدراسة من خلال التحليل كالأتي :-

أثبتت هذه الدراسة أن هنالك فرق بسيط جدا لتقدير عمر الجنين بواسطة عظم الفخذ وعظم الرأس ، كما أثبتت الدراسة بأن متوسط قياس عمر الجنين بواسطة عظم الفخذ وعظم الرأس أدق من كل منهما على حده مقارنة بيوم الولادة المتوقع .  
وأوصت الدراسة الدراسة بأن يجب عمل متابعة بالموجات فوق الصوتية لكل النساء الحوامل لتقدير عمر الجنين وتاريخ الولادة المتوقعة وكما أوصت الدراسة بإيجاد وسائل أخرى لتقدير عمر الجنين .

## CONTENTS

الآية	1
Dedication	II
Aknowledgement	III
Abstract(English)	IV
Abstrac(Arabic)	V
List of Figure	VI
List of abbreviations	VII
Contents	VIII
<b>CHAPTER ONE: INTRODUCTION</b>	
1.1. Introduction	1
1.2. Problem of the study	2
1.3. Objectives	2
1.3.1.General objectives	2
1.3.2. Specific objectives	2
<b>CHAPTER TWO: LITERURE REVIEW</b>	
2.1.Fetal Embryology	3
2.2.Fetal Anatomy and Physiology	8
2.3. Fetal Pathology	17
2.4 Ultrasound Physics	18
2.5 .Estimation of gestational age (Fetal biometry)	19
2.6. Pervious study	26

<b>CHAPTER THREE: MATERIALS AND METHODs</b>	
3.1. Material and Methods	30
<b>CHAPTER FOUR: RESULTS AND ANAIYSIS</b>	
4.1. Results and Analysis	34
<b>CHAPTER FIVE: DISCUSSION-CONCLUSION and RECOMMENDATION</b>	
5.1. Discussion	38
5.2. Conclusion	40
5.3. Recommendation	41
5.4. References	42
5.5. Appendices	



## LIST OF FIGURES

<b>Figure</b>	<b>Page Numbers</b>
Figure(2-1) Shows how to demonstrate BPD	<b>22</b>
Figure(2-2) Shows transverse cut of BPD	<b>23</b>
Figure(2-3) Shows how to demonstrate FL	<b>24</b>
Figure(2-4) Shows axial cut of FL	<b>25</b>
Figure(4-1) Shows the age group of pregnant women	<b>34</b>
Figure(4-2) shows distribution of parity	<b>35</b>
Figure(4-3) shows correlation between BPD & GA	<b>36</b>
Figure(4-4) Shows correlation between Fl& GA	<b>36</b>
Figure(4-5) Shows correlation between BPD&FL with LMP	<b>37</b>

## LIST OF APPREVIATIONS

Abbreviations	Medical words
AC	Abdominal Circumference
BPM	Beat per minute
BPD	Bi- Parietal Diameter
CSP	Cavum Septum pellicidum
CSF	Cerebrospinal Fluid
CRL	Crown Rump length
D	Day
EDD	Expected Date of Delivery
FL	Femur Length
GA	Gestational Age
GS	Gestational Sac
HC	Head Circumference
IVC	Inferior Vena Cava
IUGR	Intra Uterine Growth Restriction
IGF	Insulin growth factor
KW	Kidney width
LMP	Last Menstrual period
LBW	Low birth weight
MDS	Mean sac diameter
OBS	Obstetric
OFD	Occipito Frontal Diameter
OBD	Out door-Patient
TCD	Transverse Cerebellar Diameter
SPSS	Statistical Computer Analysis

L/ S ratio	Sphingomyeline ratio
US	Ultra Sound
W	Week
YS	Yolk Sac Diameter

## Chapter One

### 1.1. Introduction

A normal pregnancy last for 9 month, 40 weeks , or 280 days. However , it may last up to 42 weeks. As a result, typically the first trimester is defined as weeks 1 through 12 , the second trimester is defined as weeks 13 through 26 , and the third trimester is defined as weeks 27 through 42. Fetal biometry measurements. In the first trimester include yolk sac – crown rump length and nuchal translucency and in the second and third trimester include abdominal circumference – head circumference – femur length and bi parietal diameter. Femur length Measured at the long axis of the femoral shaft when the ultrasound beam is perpendicular to the shaft. Bi-parietal diameter Measured from the outer edge of the proximal skull to the inner edge of the distal skull at the level of the third ventricle , thalamus , cavum septum pellucidum , and falx cerebri(Steven. 2011).

The BPD has traditionally been the most widely used ultrasound parameter in the estimation of gestational age. Although more recent data suggest that head circumference (HC) should be used in preference to BPD for dating purposes , the BPD is easy to obtain and , on a routine basis , is more accurate than the crown–rump length. A single optimal measurement of the BPD will predict the gestational age to within  $\pm 5$  days. It is more accurate at predicting the date of delivery than an optimal menstrual history. This last point has justified its use in all pregnancies(Trish and Basky , 2004).

Femur length measurement is as accurate as the BPD in the prediction of gestational age. It is useful in confirming the gestational age estimated from BPD or HC measurements and can often be obtained when fetal position prevents measurement of the BPD or HC. As examination of intracranial anatomy is an important part of all ultrasound examinations , measurement of femur length

should not replace that of the BPD or HC as the sole predictor of gestational age. The femur can be measured from 12 weeks to term (Trish and Basky , 2004). Fetal biometry with the help of ultrasound scanning provides the most reliable and important information about the fetal growth and wellbeing. A wealth of important and relevant factors is gathered covering the fetal anatomy , physiology and fatal behavior. A good scanning ultrasound machine and an experienced hand are essential for obtaining maximum advantage (Pakistan Jornal of Medical Science).

### **. 1.2. Problem of the study:-**

Main problems to determine which is the better estimator of gestational age in the second trimester between femur length and bi-parietal diameter .

### **1.3. Objectives:-**

#### **1.3.1.General objectives:-**

Estimation of Gestational Age by Measuring Bi-parietal Diameter and Femur length In the Second Trimester

#### **1.3.2. Specific objectives:-**

- To assess the accuracy measurement in the second trimester using BPD and FL.
- To correlate gestational age between BPD and FL.

## Chapter Two

### 2.1. Embryology

#### 2.1.1 Fertilization and Implantation (Stages 1–3)

Embryonic development commences with fertilization between a sperm and a secondary oocyte . The fertilization process requires about 24 hours and results in the formation of a zygote– a diploid cell with 46 chromosomes containing genetic material from both parents. This takes place in the ampulla of the uterine tube(Enid and Diane , 2014)..

The embryo's sex is determined at fertilization. An X chromosome-bearing sperm produces an XX zygote , which normally develops into a female , whereas fertilization by a Y chromosome-bearing sperm produces an XY zygote , which normally develops into a male. (Enid and Diane , 2014).

The zygote passes down the uterine tube and undergoes rapid mitotic cell divisions , termed cleavage. These divisions result in smaller cells – the blasto-meres.Three days later , after the developing embryo enters the uterine cavity , Compaction occurs , resulting in a solid sphere of 12–16 cells to form the morula .At 4 days , hollow spaces appear inside the compact morula and fluid soon passes into these cavities , allowing one large space to form and thus converting the morula into the blasto cyst (blastocyst hatching). The blasto cyst cavity separates the cells into an outer cell layer , the trophoblast , which gives rise to the placenta , and a group of centrally located cells , the inner cell mass , which gives rise to both embryo and extra embryonic tissue (Enid and Diane , 2014).

The zona pellucida hatches on day 5 and the blasto cyst attaches to the endometrial epithelium. The trophoblastic cells then start to invade the endometrium.*Implantation:* of the blastocyst usually takes place on day 7 in the mid portion of the body of the uterus , slightly more frequently on the posterior than on the anterior wall(Enid and Diane , 2014).

*Gastrulation:* Changes occur in the developing embryo as the bi-laminar embryonic disc is converted into a tri-laminar embryonic disc composed of three germ layers(Enid and Diane , 2014).

The process of germ layer formation , called gastrulation , is the beginning of embryogenesis (formation of the embryo) , Gastrulation begins at the end of the 1<sup>st</sup> week with the appearance of the hypoblast; it continues during the 2<sup>nd</sup> week with the formation of the epiblast and is completed during the 3<sup>rd</sup> week with the formation of intra embryonic mesoderm by the primitive streak. The three primary germ layers are called ectoderm , mesoderm , and endoderm. As the embryo develops , these layers give rise to the tissues and organs of the embryo.The blastocyst begins to become attached to the uterine lining (the endometrium).Implantation includes dissolution of the zonapellucida and adhesion between the blastocyst and the endometrium , trophoblastic penetration , and migration of the blastocyst through the endometrium. Implantation occurs by the intrusion of trophoblastic extensions , which penetrate between apparently intact endometrial cells (Enid and Diane , 2014).

### **2.1.2. Second Week of Development (Stages 4 and 5)**

During the 2<sup>nd</sup> week , a bi-laminar embryonic disc forms , amniotic and primary yolk sac cavities develop , and there are two layers of trophoblast.

The two-layered disc separates the blastocyst cavity into two unequal parts (a smaller amniotic cavity and a larger primary yolk cavity). The thick layer of embryonic cells bordering the amniotic cavity is called the epiblast and a thin layer bordering the primary yolk cavity is called the hypoblast.

.The trophoblast differentiates into two layers , an inner cyto trophoblast and an outer syncytio trophoblast . The trophoblast continues to penetrate deeper into the endometrium. At the end of the 2<sup>nd</sup> week , the site of implantation is recognized as

a small elevated area of endometrium having a central pore filled with a blood clot (Enid and Diane , 2014).

### **2.1.3.Third Week of Development (Stages 6–9)**

Formation of the primitive streak and three germ layers (ectoderm , mesoderm , and endoderm) . occurs during the 3rd week.

The primitive streak results from a proliferation of ectodermal cells at the caudal end of the embryonal disc. Cells at the primitive streak proliferate to form the embryonic endoderm and mesoderm. The cephalic end of the primitive streak is the primitive node , and this cord of cells is the noto-chord (Enid and Diane , 2014).

Thickening of ectodermal cells gives rise to the neural plate , the first appearance of the nervous system , which becomes depressed below the surface along the long axis of the embryo to form the neural groove . The neural groove deepens and its margins elevate to form the neural folds . The fusion is completed during the 4<sup>th</sup> week of development. The neural tube ultimately will give rise to the central nervous system. The cephalic end will dilate to form the forebrain , midbrain , and hindbrain. The remainder of the neural tube will become the spinal cord (Enid and Diane , 2014).The mesoderm on either side of the midline of the embryo (the parax-ial mesoderm) undergoes segmentation , forming somites . The first pair of somites arises in the cervical region of the embryo at approximately day 20 of development. From there new somites appear in craniocaudal sequence , approximately three per day , until 42–44 pairs are present at the end of week 5. There are 4 occipital , 8 cervical , 12 thoracic , 5 lumbar 5 sacral , and 8–10 coccygeal pairs.The first occipital and the last 5–7 coccygeal somites later disappear , while the remainder form the axial skeleton. During this period of development , the age of the embryo is expressed in the number of somites . Each somite differentiates into bones , cartilage , and ligaments of the vertebral column



as well as into skeletal voluntary muscles , dermis , and subcutaneous tissue of the skin. The intermediate mesoderm and the lateral mesoderm give rise to portions of the urogenital system. The lateral plate mesoderm is involved in the development of pericardial , pleural , and peritoneal cavities as well as the muscle of the diaphragm (Enid and Diane , 2014).

Mesoderm also forms a primitive cardiovascular system during the 3<sup>rd</sup> week of development. Blood vessel formation begins in the extra embryonic meso-derm of the yolk sac , the connecting stalk , and the chorion. Embryonic vessels develop 2 days later. The linkage of the primitive heart tube with blood vessels takes place toward the end of week 3 , after which blood circulation begins. The beating heart tube begins at 17–19 days the embryo changes shape from a disc to a tube with a cranial and a caudal end and the third germ layer , the endoderm , becomes incorporated into the interior of the embryo. The formation of chorionic villi takes place in the 3<sup>rd</sup> week. The cytotrophoblast cells of the chorionic villi penetrate the layer of syncytio trophoblast to form a cyto trophoblastic shell , which attaches the chorionic sac to the endometrial tissues(Enid and Diane , 2014).

#### **2.1.4. Fourth Week of Development (Stages 10–12: Up to Day 28 , End of Blastogenesis)**

At this stage , the embryo measures 2–5 mm . At stage 10 , the embryo (at 22–24 days) is almost straight and has between 4 and 12 somites that produce conspicuous surface elevations. The neural tube is closed between the somites but is widely open at the rostral and caudal neuropore . The first and second pairs of branchial arches become visible. During stage 11 , a slight curve is produced by folding of the head and tail. The heart produces a large ventral prominence. The rostral neuropore continues to close and optic vesicles are formed .In stage 12 , three pairs of branchial arches complete closure of the rostral hemisphere and recognizable upper-limb buds on the ventral lateral body wall appear. The otic pits

and the Primordia of the inner ears become visible. Growth of the forebrain produces an enlargement of the head, and further folding of the embryo in the longitudinal plane results in a C-shaped curvature. Narrowing of the connection between the embryo and the yolk sac produces a body stalk containing one umbilical vein and two umbilical arteries (Enid and Diane, 2014).

#### **2.1.5. Fifth Week of Development (Stages 13–15)**

At this stage, the embryo measures 5–10 mm in length. Rapid head growth occurs, caused mainly by rapid development of the brain. The upper limbs begin to show differentiation as the hand plates develop toward the end of this week. The fourth pair of branchial arches and the lower-limb buds are present by 28–32 days of development. Lens placodes of the eyes are visible on the sides of the head. The attenuated tail with its somites is a characteristic feature at the beginning of week 5 (Enid and Diane, 2014).

#### **2.1.6. Sixth Week of Development (Stages 16 and 17)**

The crown–rump (CR) length of the embryo in this time period is 10–14 mm. At stage 16 nasal pits face ventrally, retinal pigment becomes visible, auricular hillocks appear, and the foot plate is formed. In stage 17, the C-shape of the embryo is still present. Development of finger rays and basic facial-structure formation advances. The upper lip appears when medial nasal prominences and maxillary prominences merge. The nostrils become clearly defined and the eyes are directed more anteriorly (Enid and Diane, 2014).

#### **2.1.7. Seventh Week of Development (Stages 18 and 19)**

At the end of the 7th week, the embryo attains a CR length of 20 mm. The head continues to enlarge rapidly and the trunk straightens. Elbow regions can be recognized on upper limbs, toe rays appear on the lower limbs, and the nipples become visible. Physiological herniation of the intestinal tract into the umbilical

cord occurs . The intestinal loops normally return to the abdomen by the end of the 10<sup>th</sup> week(Enid and Diane , 2014) .

### **2.1.8. Eighth Week of Development (Stages 20–23)**

At this stage , the fingers are distinct but are still webbed . There are notches between the toe rays , and a scalp vascular plexus appears. Toward the end of week 8 , the fingers become free and longer and the development of hands and feet approach each other. The head becomes more rounded and shows typical human characteristics. The embryo has a CR length of 20 mm at the beginning of the 8<sup>th</sup> week and is 30 mm in CR length at the end of the 8<sup>th</sup> week. All major organ systems are formed by the end of the 8<sup>th</sup> week – the completion of blastogenesis , organogenesis , and embryonic development. Then the fetal period begins(Enid and Diane , 2014).

### **2.2. Fetal Anatomy & Physiology**

The skull or fetal head consists of eight cranial bones .These bones are connected by structures known as sutures .Fetal sutures may be noted during a routine sonographic examination as hypoechoic spaces between the bones. Because of the flexibility of sutures , the fetal cranial bones remain slightly mobile until delivery to facilitate the passage of the skull through the birth canal. Premature fusion of the sutures is termed craniosynostosis. Consequently , craniosynostosis leads to an irregular-shaped skull. Spaces that exist between the forming fetal bones are referred to as fontanelles , or “soft spots”. Several fontanelles persist in the postnatal period and into infancy. Fontanelles are often utilized as sonographic windows during neurosonographic examinations to evaluate newborns for intracranial hemorrhage or suspected brain anomalies. The anterior fontanel , when completely filled with bone , is referred to as the bregma , whereas the posterior fontanel is referred to as the lambda. The foramen magnum is the opening in the base of the cranium through which the spinal cord travels. Midline

fetal brain anatomy and those structures that lie on both sides of the midline should be routinely evaluated during an obstetric sonogram. These structures will be discussed in the following sections (Steven , 2011).

### **2.2.1. The Cerebrum**

The brain can be divided into two main parts , the cerebrum and the cerebellum. The cerebrum is the largest part of the brain. The normal cerebrum contains multiple sulci and gyri. There are six cerebral lobes: the frontal lobe , two temporal lobes , two parietal lobes , and the occipital lobe. The cerebrum can be further divided into a right and left hemisphere by the inter hemispheric fissure. The falx cerebri , a double fold of dura mater , is located within the inter hemispheric fissure and can readily be noted on a fetal sonogram as an echogenic linear formation coursing through the midline of the fetal brain. The cerebral hemispheres are linked in the midline by the corpus callosum , a thick band of tissue that provides communication between right and left halves of the brain.

The meninges are three protective tissues layers that cover the brain and the spinal cord. The innermost layer of the meninges is the pia mater , the middle layer is the arachnoid membrane , and the dense , outermost layer is the dura mater. (Steven , 2011).

### **2.2.2. The Corpus Callosum**

The corpus callosum forms late in gestation , but should be completely intact between 18 and 20 weeks. As stated earlier , the corpus callosum connects the two lobes of the cerebrum. The corpus callosum consists of four parts. Fetal development of the corpus callosum is from anterior to posterior. Thus , the rostrum , genu , body , and splenium develop , respectively. The sonographic appearance of the corpus callosum is that of an echogenic band of tissue within the midline of the brain connecting the two cerebral hemispheres (Steven , 2011) .

### **2.2.3. The Ventricular System**

The ventricular system is composed of four ventricles , whose primary function is to provide cushioning for the brain. Each ventricle is lined by a membrane called the ependyma. The paired lateral ventricles are located on both sides of the falx cerebri within the cerebral hemispheres. They are frequently referred to as right and left ventricles but may also be called the first and second ventricles. The divisions of lateral ventricles , called the horns of the lateral ventricles , like the lobes of the cerebrum correlate with the adjacent cranial bones. Thus , each lateral ventricle consists of a frontal , temporal , and occipital horn. In addition to the horns , the lateral ventricle also has a segment referred to as the body , which is located between the frontal and occipital horns. The point at which the body , temporal horn , and occipital horn meet is the trigone or atrium of the lateral ventricle. Within the atria of both lateral ventricles lies the echogenic configuration of the choroid plexus , the mass of cells responsible for cerebrospinal fluid (CSF) production in the fetus (Steven , 2011).

Choroid plexus may also be found in the roof of the third and fourth ventricles. Each lateral ventricle communicates with the third ventricle in the midline of the brain at the foramen of Monro , or the paired inter ventricular foramina. The third ventricle is located between the two lobes of the thalamus. Essentially , part of the thalamus , the inter thalamic adhesion , passes through the third ventricle and can be visualized when enlarged or surrounded by CSF. The third ventricle connects to the fourth ventricle inferiorly by means of a long , tube like structure called the aqueduct of Sylvius , or the cerebral aqueduct. The fourth ventricle is located anterior to the cerebellum within the midline of the brain. The fourth ventricle has three apertures or openings through which CSF travels. There are two lateral apertures that are also referred to as the foramina of Luschka. These two apertures allow CSF to travel from the fourth ventricle to the subarachnoid space around the brain. Another opening of the fourth ventricle , located in the midline , is the

median aperture , which is also referred to as the foramen of Magendie. This opening allows CSF to pass from the fourth ventricle to the cisterna magna and subarachnoid space (Steven , 2011).

#### **2.2.4. The Creation , Flow , and Reabsorption of Cerebrospinal Fluid**

The greater part of CSF is produced by the cells of the choroid plexus that are located within the trigone of the lateral ventricles. CSF moves from the lateral ventricles into the third ventricle via the foramina of Monro. From the third ventricle , CSF travels to the fourth ventricle through the cerebral aqueduct. Once in the fourth ventricle , the fluid can either exit through the median aperture or the lateral apertures. CSF also flows inferiorly and around the spinal cord. Arachnoid granulations , also referred to as arachnoid villi , are responsible for the reabsorption of CSF into the venous system. This process occurs at the superior sagittal sinus , located along the superior surface of the cerebrum within its midline (Steven , 2011).

#### **2.2.5. The Cisterna Magna**

The cisterna magna , located in the posterior fossa of the cranium , is the largest cistern in the head. On sonography , the cisterna magna appears as an anechoic , fluid-filled space , posterior to the cerebellum , between the cerebellar vermis and the interior surface of the occipital bone. It is considered common to find some small septations within the cisterna magna (Steven , 2011).

#### **2.2.6. The Cerebellum;-**

The cerebellum is located in the posterior fossa of the cranium. The cerebellum consists of two hemispheres , right and left , that are coupled at the midline by the cerebellar vermis. The cerebellar tonsils , named for their shape , are located on the undersurface of the cerebellum and become distorted with spina bifida and Arnold–Chiari malformations. The normal cerebellum is a dumbbell-shaped or figure eight-shaped structure noted in the posterior cranium of the fetus. The two

hemispheres of the cerebellum should be symmetric , although Hypoplasia of one cerebellar hemi-sphere can occur , resulting in the hypoplastic hemi-sphere appearing smaller than normal(Steven , 2011).

### **2.2.7. The Fetal Heart**

The embryonic heart begins as two tubes. These two tubes ultimately fuse and fold to form into four chambers , two atria and two ventricles. The heart begins to contract at 36 to 37 days of gestation. It is initially recognized by its motion , which can be seen adjacent to the secondary yolk sac , often before an embryo is distinguishable. A heart rate using M-mode should be sonographically obtainable with endovaginal imaging when the crown rump length measures 4 to 5 mm.

During a biophysical profile assessment in the third trimester , an average fetal heart rate is 140 beats per minute (bpm) , with a range of 110 to 180 bpm considered normal after the first trimester. An elevation in fetal heart rate is termed tachycardia , whereas a decrease is referred to as bradycardia(Steven , 2011).

The heart , which is fully formed by 10 weeks. The normal fetal heart will fill approximately one third of the fetal chest , with its apex forming a 45-degree angle with the fetal spine. The chamber closest to the fetal spine is the left atrium. The four-chamber view can be used to evaluate the separation of the chambers , structures called septums. The two atria are separated by the atrial septum and the two ventricles are separated by the ventricular septum. The ventricular septum should be uninterrupted and of equal thickness to the left ventricular wall , whereas the atrial septum is open only at the foramen ovale. Within the right ventricle can be seen the moderator band , a normal structure that appears as an echogenic focus. The left ventricle has much smoother walls as compared with the right. Between the right ventricle and right atrium , one should visualize the tricuspid valve , and between the left ventricle and left atrium , the

mitral pulmonary artery normally criss-cross each other. There are several other features that should be assessed while imaging the outflow tracts (Steven , 2011).

### **2.2.8. Fetal Lung Development and Function**

The lungs develop in early embryogenesis. However , functional fetal lung tissue does not typically exist until after 25 weeks. Fetal lung maturity can be assessed using the lecithin to sphingomyelin ratio (L/S ratio). An amniocentesis is performed for this test , and the laboratory findings indicate the levels of lecithin and sphingomyelin within the amniotic fluid. Normally , as the lungs mature , the level of lecithin increases , whereas the level of sphingomyelin decreases (Steven , 2011).

### **2.2.9. The Placenta**

The placenta is a vital organ to the fetus during pregnancy. It normally weighs between 450 and 550 g and has a diameter of 16 to 20 cm. The placenta is derived from both fetal and maternal cells. The decidua Basalis , the maternal contribution of the placenta , is the endometrium beneath the developing placenta. The chorion frondosum , the portion derived from the blastocyst and containing the chorionic villi , is the fetal contribution to the placenta. The placenta consists of approximately 10 to 30 cotyledons , which are groups or lobes of chorionic villi. The placenta produces human chorionic gonadotropin , which maintains the corpus luteum of the ovary. In later pregnancy , the placenta also produces estrogen and progesterone , taking over that function from the corpus luteum. One major function of the placenta is to act as an excretory organ for the fetus , performing imperative exchanges of waste products and gases with valuable nutrients and oxygen from the mother. The placenta effectively becomes the means of respiration for the fetus (Steven , 2011).



A definitive placenta may not be identified sonographically until after 10 to 12 weeks. It will appear as an echogenic thickening surrounding part of the gestational sac. As the pregnancy progresses , the placenta becomes more defined.

The placenta consists of three parts: (i) the chorionic plate , (ii) the placental substance , and (iii) the basal layer. The chorionic plate is the element of the placenta closest to the fetus. The basal layer is the area adjacent to the uterus. The placental substance contains the functional parts of the placenta and is located between the chorionic plate and the basal layer (Steven , 2011).

There are several normal variants seen within the placental substance that can distort the typical homogenous appearance of this organ. Venous lakes , also referred to as maternal lakes or placental lakes , are pools of maternal blood within the placental substance. They appear as anechoic or hypoechoic areas , and may contain swirling blood. These are of little clinical significance. The shape of the placenta may vary as well. A bilobed placenta consists of two separate discs of equal size. There may also be an accessory lobe or succenturiate lobe of the placenta , which are additional smaller lobes located separate from the main segment of the placenta. Also , a circumvallate placenta is an abnormally shaped placenta caused by the membranes inserting inward from the edge of the placenta , producing a curled-up placental contour. A circumvallate placenta may lead to vaginal bleeding and placental abruption , among other complications (Steven , 2011).

Calcifications may be noted within the placenta and indentations may be seen within the basal and chorionic plates with advancing gestation. Grading of the placenta has been performed in the past to predict fetal lung maturity by assessing these indentations and calcifications (Steven , 2011).

The thickness of the placenta should be evaluated with sonography. It should not exceed 4 cm. Both a thick or large placenta , termed placentomegaly , and a thin

placenta are associated with maternal and/or fetal abnormalities (Steven M , 2011).

*Functions of the Placenta:* Gas transfer , excretory function , Water balance , pH maintenance , Hormone production , Defensive barrier (Steven , 2011).

### **2.2.10. Fetal Circulation**

It is important for sonographers to have a basic appreciation for fetal circulation. The normal umbilical cord contains two arteries and one vein. The vein , entering at the umbilicus , brings oxygen-rich blood from the placenta to the fetus. The umbilical vein travels superiorly where it connects to the left portal vein. Half of the blood goes to the liver through the left portal vein , whereas the other half is shunted directly into the inferior vena cava (IVC) via a small branch of the umbilical vein called the ductus venosus. The blood that was taken to the liver is used to oxygenate the liver and is then returned back to the IVC by the hepatic veins (Steven , 2011).

The existing oxygen-rich blood in the IVC travels up to the heart and enters the right atrium. Blood can then travel across the foramen ovale , an opening in the lower middle third of the atrial septum and into the left atrium , or it can enter the right ventricle through the tricuspid valve. The blood then leaves the right ventricle through the main pulmonary artery. The main pulmonary artery bifurcates into right and left , thus allowing a small amount of blood to travel to the respective lung. Blood from the right ventricle can also flow through the ductus arteriosus and into the descending aorta (Steven , 2011).

The blood returning from the lungs through the pulmonary veins enters into the left atrium. Blood then travels from the left atrium into the left ventricle via the mitral valve. From the left ventricle it travels to the ascending aorta and into the aortic arch , where it exits into the brachio cephalic artery , left common carotid artery , and left sub clavian artery on its way to the thorax , upper extremities , and head.

The blood will return from the head and upper torso via the superior vena cava to the right atrium. The blood that flows through the ductus arteriosus and into the descending aorta travels inferiorly to either exit the abdomen via the umbilical arteries or travels to the abdomen and lower extremities to replenish those regions. Therefore , the umbilical arteries return the deoxygenated blood from the fetus back to the placenta(Steven , 2011).

### **2.2.11. Placental Localization**

With the exception of women undergoing chorion villus sampling , accurate assessment of placental position is not necessary when examining the first trimester uterus. Because of positional changes of the body of the uterus in early pregnancy , the placental site can change relative to the internal os. We therefore do not recommend reporting placental position in normal circumstances until the routine 20–22 week scan (Trish and Basky , 2004).

The placenta is best identified by scanning the uterus longitudinally and is easily recognized by its more echogenic pattern compared with that of the underlying myometrium. Careful inspection will demonstrate the chorionic plate as a bright linear echo between the homogeneous echoes of the body of the placenta and the amniotic fluid . The actual internal os might be difficult to identify trans abdominally but its position can be assumed by visualizing the slight dimple at the upper end of the cervical canal. The cervical canal is best imaged by placing the probe in the midline , with its lower end just above the symphysis , slight dextro rotation may be necessary. The cervical canal lies directly posterior to the bladder , typically at about 45° to the horizontal (Trish and Basky , 2004).

The placenta can be fundal , anterior , posterior or lateral , in which case it will be visualized on both the anterior and posterior walls of the uterus.It might lie completely within the upper part of the uterus , with its lower edge >5 cm from the internal os such a position is usually described as ‘upper’ or ‘not low’. If the

leading edge of the placenta lies within 5 cm of the internal os and/or appears to cover the internal os then its position should be described as ‘low’ and/or ‘covering the os’. The term ‘placenta praevia’ should only be used after 28 weeks ( Trish and Basky , 2004).

It is unnecessary to ask women to attend with a full bladder at the time of the 20–22 week scan as the majority will have an obviously fundal placenta. It is frequently possible to visualize the lower placental edge and the internal os , thus making the diagnosis of a low-lying placenta possible even with a partially filled bladder. If such views are suboptimal and a low-lying placenta is suspected , then a trans vaginal examination should be performed or the woman should be scanned with a full bladder(Trish and Basky , 2004).

## **2.3. Fetal Pathology**

### **2.3.1. Intrauterine Growth Retardation**

Estimation of fetal maturity is the most accurate method of estimating gestation age by ultra-sonographic measurements of crown–rump length during the first trimester. From the first trimester through 34 weeks , the bi-parietal diameter is accurate to within 10 days. Other measurements used in the 2<sup>nd</sup> and 3<sup>rd</sup> trimesters include fetal abdominal diameter and femur length. Low birth weight (LBW) is a worldwide problem usually defined as birth Weight < 2 , 500 g , irrespective of gestational age. It is associated with increased peri natal morbidity and is used as a marker of increased neonatal risk. It is not an ideal marker of fetal growth and development and combines both prematurity and various degrees of growth retardation. Morbidity is associated with LBW and growth retardation. Twenty-one million LBW infants are born each year internationally , 90% in developing countries Insulin growth factor (IGF) II is essential for organogenesis and early fetal growth. IGF-I is essential for late fetal growth. IGF-I is low in intra uterine growth retardation (IUGR) infants (Enid and Diane , 2014).

*There are two types of IUGR: symmetric (proportionate) and asymmetric (disproportionate)* In the symmetric type , the head is reduced in size to the same extent as the body; in the asymmetric type , the head is normal in size and only the body is small. Symmetric growth retardation is seen early in development; asymmetric growth retardation usually is not manifested until after 20 weeks gestation (Enid and Diane , 2014).

Timing of the insult to the fetus predisposes to the type of growth retardation: early insults usually result in symmetric growth retardation , probably by restricting fetal cellular hyperplasia. Third trimester insults that restrict cellular hypertrophy usually result in asymmetric growth retardation. Utero placental insufficiency and other similar insults result in stresses on the fetus that cause the fetus to redistribute blood flow , maintaining perfusion of the head , heart , and adrenal glands. Particularly severe insults to the fetus may cause asymmetric growth retardation to progress to symmetric growth retardation , as redistribution of blood flow fails to maintain growth of the head(Enid and Diane , 2014).

#### **2.4.Ultrasound Physics**

Ultrasound is very high frequency (high pitch) sound. Human ears can detect sound with frequencies lying between 20 Hz and 20 kHz. Middle C in music has a frequency of about 500 Hz and each octave represents a doubling of that frequency. Although some animals , such as bats and dolphins , can generate and receive sounds at frequencies higher than 20 kHz , this is normally taken to be the limit of sound. Mechanical vibrations at frequencies above 20 kHz are defined as ultrasound. Medical imaging uses frequencies that are much higher than 20 kHz; the range normally used is from 3 to 15 MHz. These frequencies do not occur in nature and it is only within the last 50 years that the technology has existed to both generate and detect this type of ultrasound wave in a practical way(Trish and Basky , 2004).

**2.4.1 To obtain maximum information from any obstetric ultrasound examination , the following three points should be observed:-**

1. the ultrasound equipment should be suited to the required examination and should be functioning correctly
2. the woman should be properly prepared
3. you , as the operator , should be confident in your abilities to perform the examination (Trish and Basky , 2004).

**2.4.2 Real-time equipment currently available varies greatly in size , shape and complexity , but will contain five basic components:-**

1. the probe , in which the transducer is housed
2. the control panel
3. the freeze frame
4. measuring facilities
5. a means of storing images.

Current equipment provides 2D or three-dimensional (3D) information. Three-dimensional imaging in real time , known as four-dimensional (4D) imaging , is now becoming available. As almost all obstetric ultrasound examinations and the vast majority of gynecological ultrasound examinations are performed at the present time using 2D imaging (Trish and Basky , 2004).

**2.5 .Estimation of gestational age (Fetal biometry)**

Accurate knowledge of gestational age (age of unborn baby) is key for , care , planning , critical interpretation and successful management of all pregnancies. Failure can result in iatrogenic prematurity or post maturity , both of which are associated with increased peri nata lmortality and morbidity. Initially the dating of pregnancy was based on the first day of last menstrual period) ina regular 28 day menstrual cycle. But this method for dating the pregnancy is unreliable in those

women who do not exactly recall their menstrual history. Since the introduction of diagnostic ultrasound , more reliable methods to date the pregnancy have been developed. In early pregnancy , these are Gestational sac diameter and volume and Crown-Rump length (CRL) measurements. In second trimester most commonly used biometric parameters for estimating gestational age are Bi-parietal diameter and Femur length (Egley et al1986) and other used parameters are transverse cerebellar diameter (Chavez et al2)Scapular measurement(Dilmen et al)Fetal kidney length (Ansari et al4) , Fetal renal volume(Fauchonet et al5).Fetal kidney size (Kyosun Kim et al61995) , multiple fetal parameters(Hadlock et al71987). Hence , the present study is undertaken to assess gestational age in second and third trimesters with the help of sonographic measurements of Bi-parietal diameter , Femur length , Head circumference & abdominal circumference.

### **2.5.1. Gestational Sac (Weeks 4 to 5)**

The first definitive sonographic sign of an intra uterine pregnancy is identification of the gestational sac within the decidualized endometrium. The blastocyst is the developmental stage of the conceptus that implants into the uterine cavity. The blastocyst gives rise to the gestational sac , or chorionic sac. The early gestational sac appears as a small , anechoic sphere within the decidualized endometrium. It will grow at a rate of 1 mm per day in early pregnancy. The intradecidual sign denotes the appearance of the small gestational sac in the uterine cavity surrounded by the thickened , echogenic endometrium. The intra decidual sign can be misdiagnosed , as it may resemble the pseudo gestational sac of an ectopic pregnancy. To differentiate an intrauterine gestational sac from the pseudo gestational sac , sonographers can assess the endometrium for evidence of the double sac sign or double decidual sign. The double sac sign denotes the typical appearance of the two distinct layers of decidua , the decidua capsularis (inner layer) and decidua

parietalis (outer layer) , separated by the anechoic fluid-filled uterine cavity (Steven , 2011).

The measurement of the gestational sac is the earliest sonographic measurement that can be obtained to date the pregnancy .A mean sac diameter (MSD) is achieved by adding the measurements of the length , width , and the height of the gestational sac and dividing by 3. The gestational sac measurement is a relatively accurate form of dating that can be used until a fetal pole is sonographically recognized. Although modern ultrasound equipment calculates the MSD for sonographers , there is also a simple formula that can be used. By adding 30 to the MSD (measurement in mm) , sonographers can obtain an estimate for the gestational age in days. When the gestational sac seems visually disproportional to the size of the embryo , that is , too small or too large compared to the size of the embryo , an MSD measurement can be exceedingly beneficial in determining if asymmetry truly exists. An irregularly shaped gestational sac can be a sign of impending pregnancy failure (Steven , 2011).

### **2.5.2. Crown Rump Length (CRL)**

The most accurate sonographic measurement of pregnancy is the crown rump length. The crown rump length can be taken when a fetal pole is identified and should not include the yolk sac or fetal limb buds within the measurement. This measurement can be taken throughout the first trimester , and typically until second-trimester bio-metric measurements can be obtained secondary Yolk Sac (5.5 weeks) , (Steven , 2011).

### **2.5.3. Yolk sac diameter (YS)**

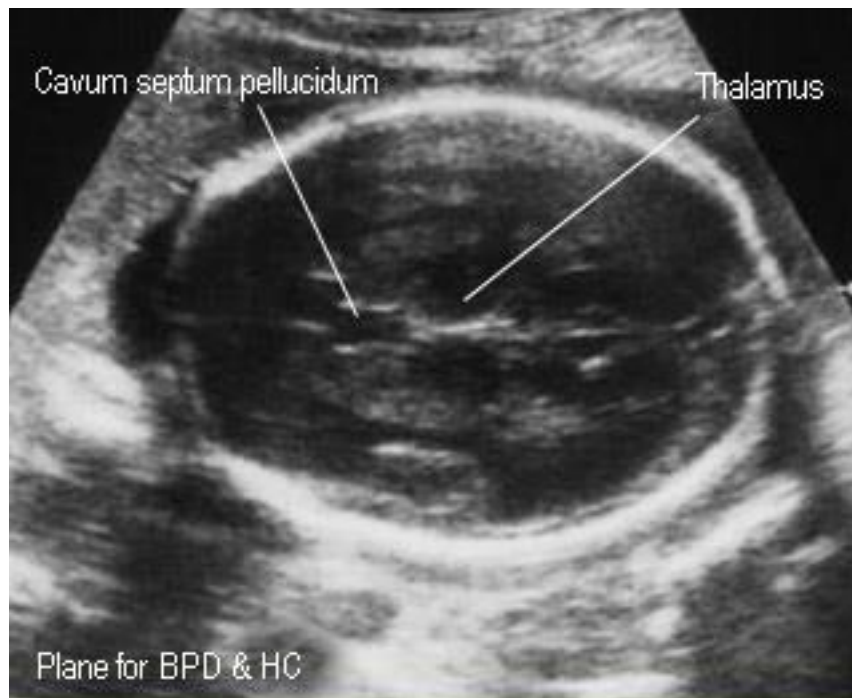
The first structure seen with sonography within the gestational sac is the secondary yolk sac . It appears within the gestational sac as a round , anechoic structure surrounded by a thin , echogenic rim. It is located within the chorionic cavity , between the amnion and chorion. The yolk sac produces alpha-fetoprotein and



plays an important role in angiogenesis and hemato poiesis during early embryologic development. It is connected to the embryo by the Vitelline duct , also referred to as the omphalo mesenteric duct , which contains one artery and one vein. It may be visualized during a first-trimester sonographic examination It is important to evaluate the appearance of the yolk sac , as a yolk sac that is echogenic , abnormally shaped , or calcified carries an increased risk for ensuing embryonic demise(Steven , 2011).

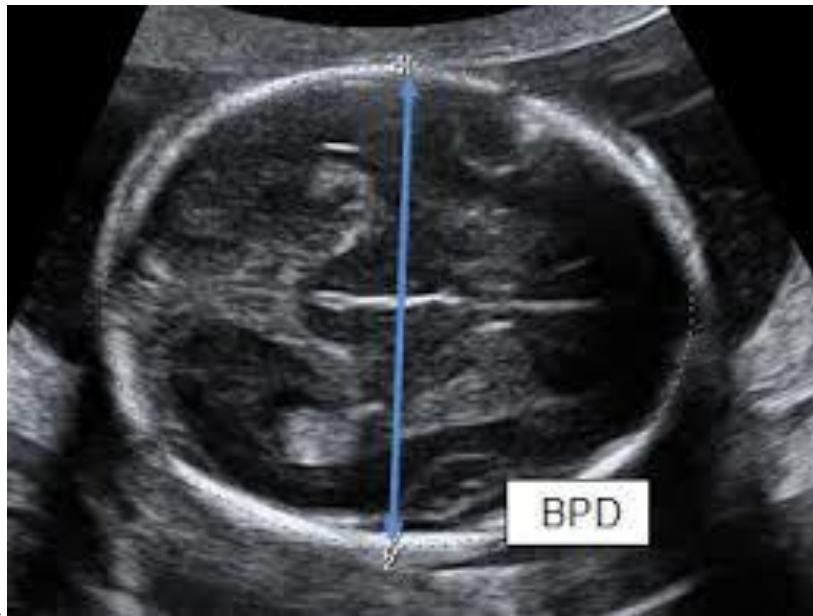#### **2.5.4. Bi-parietal Diameter(BPD)**

The bi-parietal diameter (BPD) measurement of the fetal head can be taken after the first trimester has ended , typically starting between 13 and 14 weeks.The BPD is obtained in the axial plane at the level of the CSP , thalamus , and falx cerebri. This is the same level as the third ventricle , which may be seen between the two lobes of the thalamus (Steven , 2011).



.Figure (2-1) shows how to demonstrate BPD

[www. Gestational.net](http://www.Gestational.net)



.Figure (2-2) shows transeverse cut of BPD

www. Gestational.net

### **2.5.5. Femur Length (FL)**

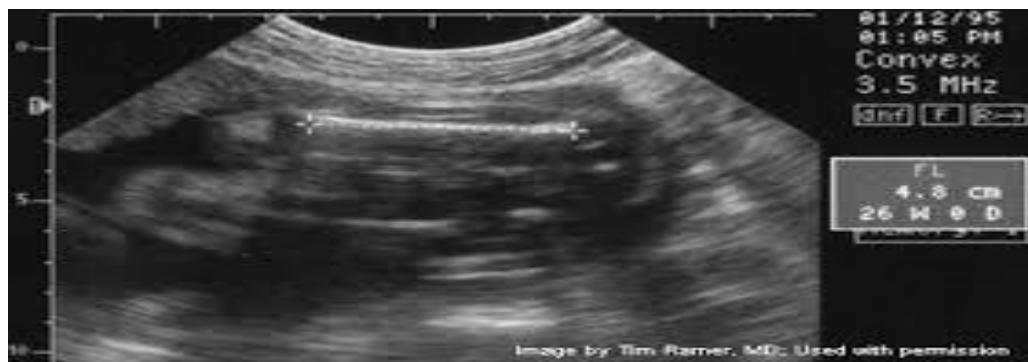This measurement is as accurate as the BPD in the prediction of gestational age. It is useful in confirming the gestational age estimated from BPD or HC measurements and can often be obtained when fetal position prevents measurement of the BPD or HC. As examination of intra cranial anatomy is an important part of all ultrasound examinations , measurement of femur length should not replace that of the BPD or HC as the sole predictor of gestational age. The femur can be measured from 12 weeks to term (Trish and Basky , 2004).

Measuring the femur is ideally undertaken after the AC has been measured. Slide the probe caudally from the AC section until the iliac bones are visualized. At this point , a cross-section of one or both femurs is usually seen. The upper femur should be selected for measurement. The lower femur is frequently difficult to image clearly because of acoustic shadowing from fetal structures anterior to it .Keeping the echo from the anterior femur in view , rotate the probe slowly until the full length of the femur is obtained. You might need to make a Small sliding

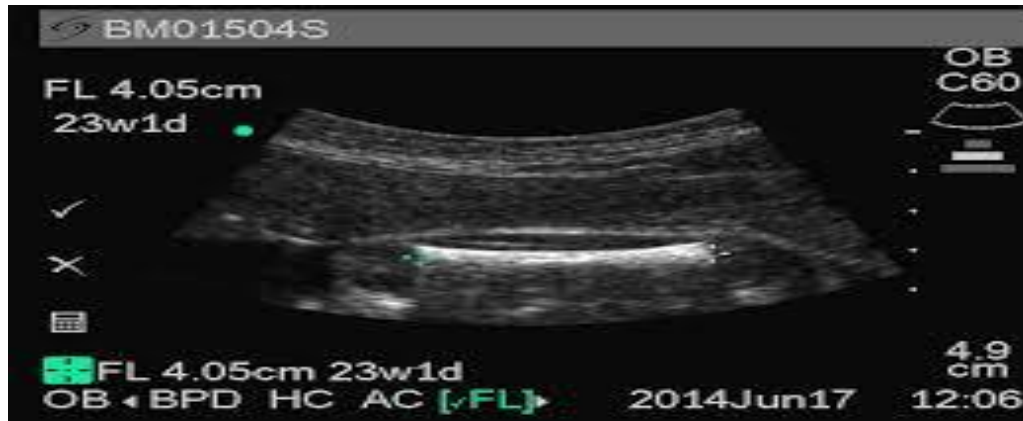
movement after each rotational movement to bring the probe back onto the femur. To ensure that you have the full length of the femur and that your section is not oblique, soft tissue should be visible beyond both ends of the femur and the bone should not appear to merge with the skin of the thigh at any point. The end-points of the femur are often difficult to define when the femur is imaged lying horizontally but are much easier to define when the bone lies at a slight angle (5–15° to the horizontal). The angle of the bone relative to the horizontal can be manipulated by dipping one end of the probe gently into the maternal abdomen (Trish and Basky, 2004).

The measurement of the femur is made from the center of the 'U' shape at each end of the bone. This represents the length of the metaphysis. It is good practice to obtain measurements from three separate images of the same femur. These should be within 1 mm of each other (Trish and Basky, 2004).

Femur length measured at the long axis of the femoral shaft when the ultrasound beam is perpendicular to the shaft (Steven, 2011).



**Figure (2-3) shows how to demonstrate Femur Length**



**Figure (2-4) shows Axial cut of Femur Length**

www. Gestational.net

### **2.5.6. Abdominal circumference (AC)**

Measured in an axial plane , and taken around the abdomen at the level of the umbilical vein and fetal stomach. Other structures that may be seen include the transverse thoracic spine , left adrenal gland , and fetal gallbladder (Steven , 2011).

### **2.5.7. Head Circumference**

The head circumference (HC) measurement can be taken at the same time of gestation and at the same level of the cranium as the BPD. Thus , the HC is obtained in the axial plane at the level of the CSP , thalamus , falx cerebri , and a measurement around the entire cranium is obtained. This is the same level as the third ventricle , which may be seen between the two lobes of the thalamus. The cranial bones must be symmetric on both sides of the head. The HC can also be obtained by measuring the occipito frontal diameter (OFD) and taking an outer-to-outer diameter measurement at the level of the BPD. Some authors suggest that the HC measurement is typically more accurate than BPD because this measurement is independent of the fetal head shape , consequently providing a more consistent parameter for estimating gestational age (Steven , 2011).

.

### **2.5.8. Occipito frontal Diameter**

The OFD is obtained at the same level of the BPD and HC. The OFD is measured from the outside of the occipital bone to outside of the frontal bone , along the midline of the fetal cranium. The OFD may also be called the fronto occipital diameter. It can be added to the BPD and multiplied by 1.57 to obtain a HC as well(Steven , 2011).

### **2.5.9. Lateral Ventricle Measurement**

The diameter of the lateral ventricle can be easily measured with sonography. The lateral ventricle is measured in the trans axial plane at the level of the atrium .The atrium of the lateral ventricle is the optimal site for measuring the lateral ventricle , because it is the first region where ventricular enlargement occurs. The calipers are placed at the level of the glomus of the choroid plexus.The normal lateral ventricle does not typically measure more than 10 mm at the level of the atrium (Steven , 2011).

## **2.6. Previous studies**

Chris , 2014 studied An Assessment of the Use of Femoral Length and Bi-parietal Diameter in the Estimation of Gestational age In Second and third trimester Gestation in Edo Women in Benin City. This study seeks to investigate assessment of gestational age (GA) between the ultrasonic measurement of femoral length (FL) and bi-parietal diameter (BPD) in Edo women. The aim of this study was to determine if any significant difference exists between gestational ages (GA) estimate from femoral length (FL) and bi-parietal diameter (BPD) , also aimed to determine which is the better estimator of gestational age in the second and third trimester between femur length and bi-parietal diameter and to develop model for the estimation of gestational age using combine index of femur length and bi-parietal diameter. The study population consisted of 116 pregnant Edo women

between 14 weeks and 40 weeks of gestation who were certain of the beginning of the last menses. The data were presented as mean and standard deviation; data were analysed using student t-test. The core findings of this research was that there was no significant difference between the mean of gestational age estimates from femoral length (FL) and bi-parietal diameter ( $P>0.05$ ), and the model that incorporate femoral length and bi-parietal diameter to estimate gestational age, accounts for 86.3% of the accuracy in gestational age measurement ( $R^2=0.863$ ) (Chris, 2014).

Kumar, et al, 2015 studied Estimation of Fetal Gestational Age in Second & Third Trimesters from Ultra sonographic Measurements of Different Fetal Biometric Parameters. The study was carried out to assess fetal gestational age with the help of ultra sonographic measurements of different fetal biometric parameters [i.e. Bi-parietal diameter (BPD), Femur length (FL), Abdominal circumference (AC)] and Fetal kidney width (KW), in 199 women with singleton uncomplicated pregnancies attending the O.P.D for routine ultrasound fetal biometry in western Uttar Pradesh (UP). Above fetal parameters were measured biweekly, between 18 and 38 weeks of gestation. Linear regression models for estimation of gestational age were derived from above fetal biometric parameters. The linear regression model for estimating fetal gestational age is femur length, abdominal circumference, fetal kidney width and bi-parietal diameter in that order with standard error of  $\pm 3.85$ ,  $\pm 4.85$ ,  $\pm 5.81$  and  $\pm 8.75$  days respectively (Kumar, et al, 2015).

Moawia, et al, 2014 studied the reliability of bi-parietal diameter and femoral length in estimation the gestational age using ultra sonography. Assessment of fetal gestational age with ultrasound provides high accuracy and reliability, as ultrasound is safe, easy operating and cheap. Objectives: to predict the GA with BPD and FL, to derive equations from linear regression analysis of GA with BPD

and FL this could be applied to determine the fetal GA , to compare between BPD and FL. Methods: there were 100 normal pregnancies (singleton) had been selected for the study during the second and third trimesters.

They were scanned with ultrasound using 3.5 MHz probe applying the obstetrics protocol to measure the fetal biometrics. The length of femoral diaphysis was measured from upper end to lower end excluding epiphysis. The bi-parietal diameter was measured from the fetal skull when being in oval shape; two thalami should be equal in size. The diameter was drawn from inner to outer margins of the skull perpendicular to the thalami. Results: statistical tests such as correlation and linear regression had been used to get the correlation coefficients and linear equations. There was a strong positive correlation between gestational age and femoral length and bi-parietal diameter ( $r = 0.97$  ,  $r = 0.98$ ). The estimation of gestational age from bi-parietal diameter could be calculated from the equation  $GA = 3.385 + 0.359BPD$  , and the estimation of gestational age could be calculated from the equation  $GA = 7.890 + 0.388FL$ . The most accurate equation to estimate the fetal gestational age was derived from the equation  $GA = 4.970 + 0.157FL + 0.218BPD$ . Conclusion: The estimation of gestational age with fetal bi-parietal diameter and femoral length still remain the most common measurements to assess the fetal growth. Evaluation of gestational age with bi-parietal diameter and femoral length joined together is more accurate than bi-parietal diameter and femoral length when used separately (Moawia , et al , 2014).

Khuwaja , et al , 2016 studied Estimation of Gestational Age Through Various Parameters. Estimating gestational age is essential to ensure proper progress of labor and growth of the fetus. It is also important to identify growth restriction in fetus and do early interventions to avoid complications. Use of sonographic parameters is hence an important component of the management of pregnancy. This review aims to highlight parameters that can estimate gestational age during

intra-uterine life. *Methods:* Published literature in English was retrieved through searches of PubMed or MEDLINE , CINAHL , and the Cochrane Library in 2010 using appropriate controlled vocabulary through key words (Ultrasound , Head circumference , Abdominal circumference , Bi-parietal diameter , Trans cerebellar diameter). *Findings:* Fetal biometry came into existence in 1980s and during this only a few parameters were considered as standard measurements which include crown-rump length , bi-parietal diameter , head circumference , femur length and abdominal circumference. Lastly , fetal transverse cerebellar diameter (TCD) came into being and is the most widely accepted and used parameter for fetal growth due to its reliability. This method is especially of benefit when intrauterine growth restriction is suspected. It has a statistically significant relationship with gestational age and has a sensitivity and specificity of more than 90%. *Conclusion:* Accurate measurement of fetal growth is essential to monitor the health of fetus and identify problems in early phase and intervene. Multiple parameters have been identified to estimate the gestational age including , bi-parietal diameter , head circumference , abdominal circumference , crown-rump length and fetal transverse cerebellar diameter (TCD) (Khuwaja , et al , 2016).



## Chapter Three

### MATERIALS AND METHODS

#### **3-1: Materials of the study:**

**3.1.1:** Ultrasound system :Mindray pc-6 diagnostic ultrasound system which has major machine three probes , with full US department facilities , and coupling jell.

**3-1-2:** Personal computer.

**3-1-3:** Measurement equipments for BPD , and FL in the second trimester.

#### **3-2-1: Study design:**

This is cross sectional descriptive study , carried out in order to state the estimation of the GA in the second trimester by BPD & FL.

#### **3-2-2: Study area:**

Khartoum North Teaching Hospital OBS& GYNE department.

#### **3-2-3: study duration:**

This study is conducted at duration from April- to September 2016.

#### **3.2.4 Population of the study :**

Pregnant woman at second trimester was present to ultrasound department at the area and the time of the study.

#### **3.2.5 Sampling of the study:**

They are 50 cases from pregnant women in the second trimester for gestational age.

(i) Inclusion criteria:

- Normal singleton pregnant woman...
- Regular menstrual cycle and certain last menstrual period date.

(ii) Exclusions criteria:

- Multiple pregnancy
- Fetuses diagnosed to have congenital anomalies.
- Maternal medical illness known to affect fetal size (renal disease-Hypertension)

### **3-2-6: Sampling:**

The sample size of this study is consisted of 50cases , and they were randomly selected.

### **3-2-7: Scanning technique:**

It's by (TAUS) , which done through the following steps:

#### **3.2.8: Patient Preparation for an Obstetric Sonogram and Patient care :-**

Both trans vaginal ( TV) and trans abdominal (TA) imaging may be utilized to evaluate the gravid uterus. Although both techniques have their limitations , they often work well in conjunction with each other.

In the early first trimester , if TA imaging is used , the patient should have a distended urinary bladder to better visualize not only the uterus , but also the adnexa (Steven , 2011).

TV imaging is most often the technique used to imagine the early pregnancy , as it offers superior resolution. An empty maternal bladder is needed for this exam. Second and third trimester sonographic examinations also require an empty maternal bladder (Steven , 2011).

First trimester sonograms may require the use of a 5- to 10-MHz or higher TV transducer to better visualize intrauterine structures and the adnexa. Typically , a 3- to5-MHz TA transducer will allow sufficient penetration in most pregnant patients , while providing sufficient resolution. These frequency ranges will

vary among ultrasound equipment. Obese patients may require the use of lower frequency transducers for additional penetration. (Steven , 2011).

All transducers and transducer cords should be cleaned after performing an obstetric sonogram to prevent the spread of disease. TV transducers should be soaked in a disinfecting solution and the manufacturer's specified instructions should be followed. Since TV imaging requires that the transducer be placed into the vagina , a probe cover should be placed on the transducer and it should be inserted into the vagina using sterile jelly as a lubricant (Steven , 2011). .

### **3.2.9 : Preparation for the procedure:-**

- You should wear loose-fitting , two-piece outfit for the examination.
- Only the lower abdominal area needs to be exposed during this procedure.
- In early pregnancy U/S full bladder is necessary.
- In trans vaginal U/S empty bladder is necessary.

### **3.2.10 : Laboratory Findings Relevant To Obstetric Sonography;-**

The Triple and Quadruple Screen . The triple screen is a maternal blood test performed between 15 and 20 gestational weeks. It includes human chorionic gonadotropin (hCG) , maternal serum alphaFetoprotein (MSAFP) , and estriol.

The quadruple screen adds an additional analysis of inhibin A .

Atypical laboratory findings can be associated with abnormal pregnancies. (Steven, 2011).

### **3.2.11 : Early First Trimester Screening :-**

Some medical institutions provide an earlier test than the customary triple screen offered during the second trimester. This test can be performed between 11 and 14 gestational weeks. It is an analysis of maternal blood levels of hCG and pregnancy-associated plasma protein A ( PAPP-A) , combined with fetal nuchal translucency (NT) measurements obtained with sonography(Steven , 2011).

### **3.2.12 : Data Collection :**

The data was collected by clinical data sheet, ultrasound images and data storage.

### **3.2.13 : Data analysis :**

Data was collected from fifty (50) women at the second trimester sonographic fetal bio-metries measurements were performed for head(BPD) , femur length and compared with previous study. Statistical computer analysis (SPSS) was performed by completely randomized block design with each patient representing a block of related measurement.

### **3.2.14: Ethical consideration:**

Permissions were taken from the patients before doing scans , and they were informed about the study , and accept it. Also the patients get sure that thier details will not be exposed. Before that permissions were taken from the head mangers of the hospitals.

## Chapter Four

### 4.1 Results & Analysis

Age Period	Frequency	Percentage
16-20	15	30%
21-25	11	22%
26-30	17	34%
31-35	5	10%
36-40	2	4%

Table (4.1) shows age distribution

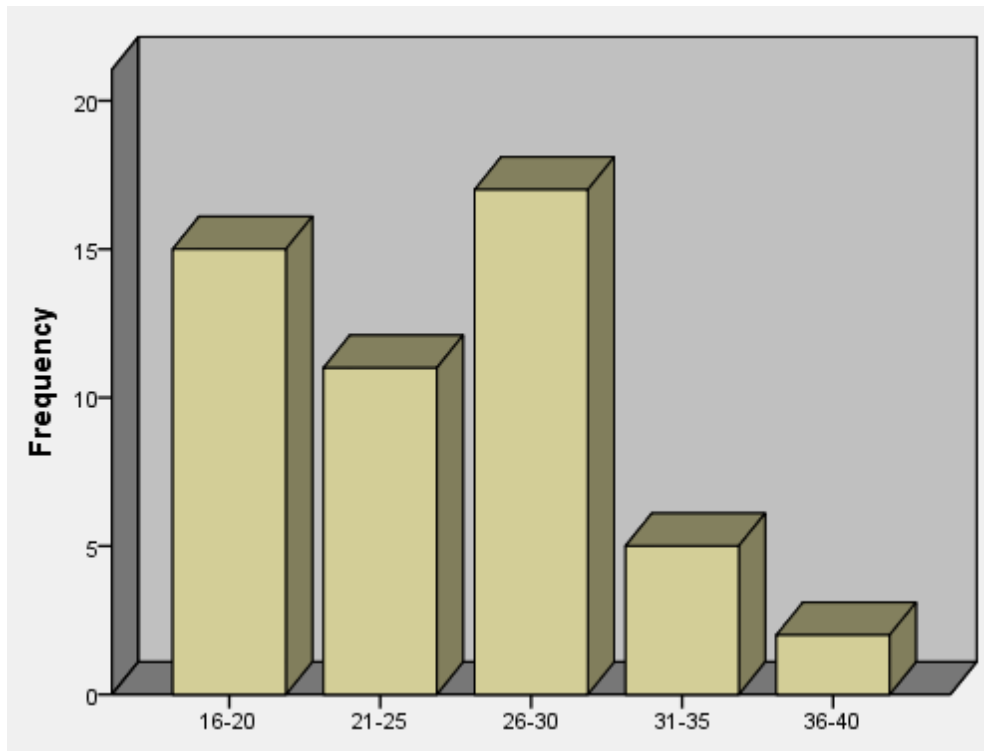
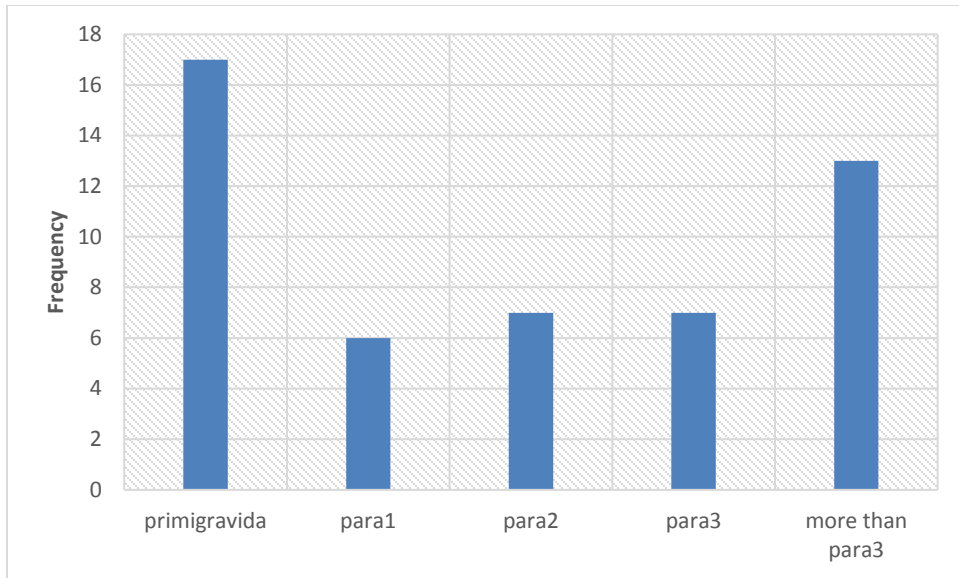
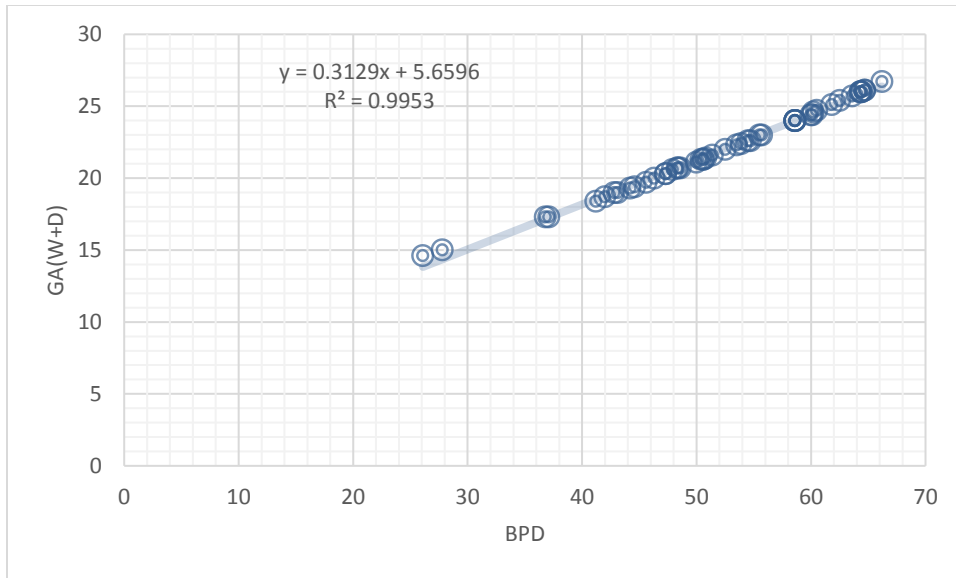


Figure (4.1) shows age group distribution



**Figure (4.2) the distribution of parity**



Figure(4-3) shows correlation between BPD per mm with GA per weeks and the result of correlation 0.99 which mean its very strong reaction

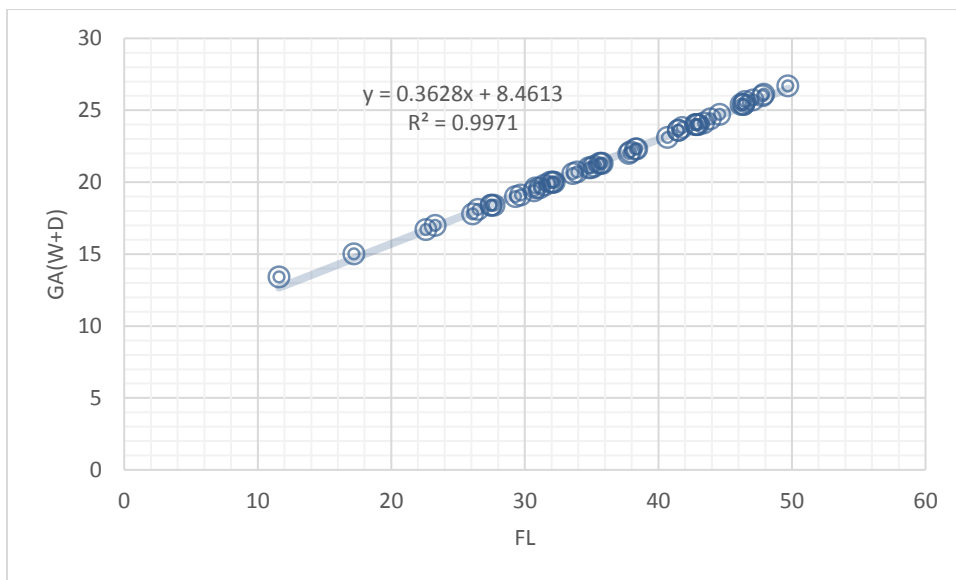


Figure (4-4) shows GA per weeks & Femur length per mm and the reaction is very strong.

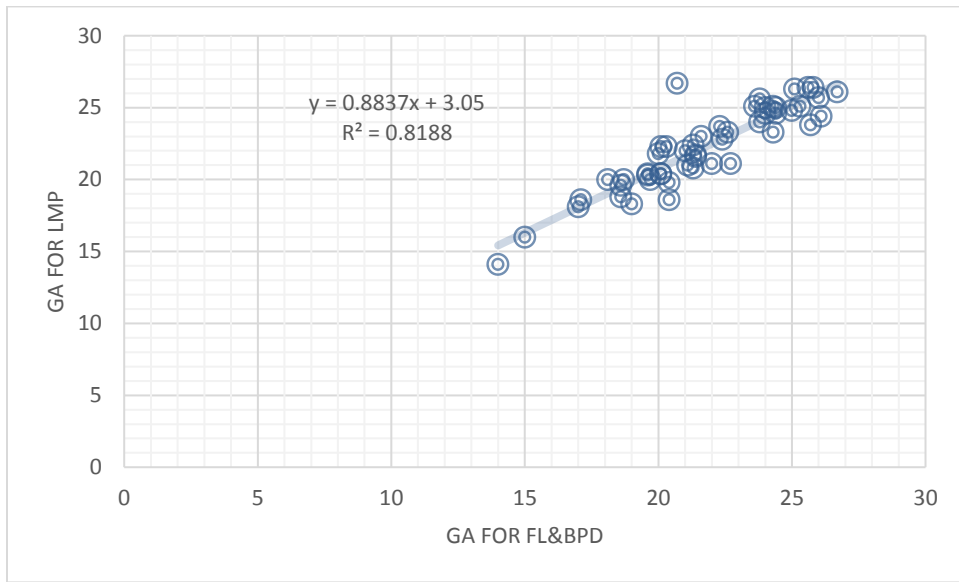


Figure (4.5) shows correlation between GA per weeks for FL&BPD(mm) and GA per weeks for LMP per (mm) and the reaction is very strong.



## Chapter Five

### 5.1. Discussion:

This study was carried out among the fifty patients , They were scanned at Khartoum North Teaching Hospital Obs & Gyne Department.

The study showed 34% were primigravida , 12% women had para one , 14 % para two , 14 % of women had para three , and 26% had more than three parity.

The mean age of women in the study group found to be 24.8 years showed that the age group with largest number of subject was 26\_30 age group there were 17 women) , 31\_35 age group there were 5 women , , 21\_25 age group there were 11 women , 36\_40 age group there were 2 women , 16\_20 age group there were 15 women , respectively which between them represents 34% , 10% , 22% , 4% , 30% of the study group.

correlation between BPD per mm with GA per weeks and the result of correlation 0.995 which mean its very strong reaction , and GA per weeks & Femur length per mm and result of correlation 0.997 and the reaction is very strong. From this study there was no significant difference between the BPD and FL in second trimester. And correlation between GA per weeks for FL& BPD (mm) and GA per weeks for LMP per (mm) and the reaction is very strong 0.82 .The estimation of the gestational age was calculated by using two parameters (BPD & FL) .

Previous study of Chris , 2014 in chapter two suggests that there was no significant difference between the mean of gestational age estimates from femoral length FL and bi-parietal diameter ( $P>0.05$ ) , in the second trimester , And this study confirmed that so , I was agree with him .

Previous study of Kumar , et al , 2015 studied Estimation of Fetal Gestational Age in Second & Third Trimesters from and the linear regression

model for estimating fetal gestational age is femur length , and bi-parietal diameter in that order with standard error of  $\pm 3.85$  and  $\pm 8.75$  days respectively , and I was not agree with him because there was significant difference between estimation of GA from BPD and FL in second trimester..

Previous study of Moawia , et al , 2014. Suggests that there was a strong positive correlation between gestational age and femoral length and bi-parietal diameter ( $r = 0.97$  ,  $r = 0.98$ ).And evaluation of gestational age with bi-parietal diameter and femoral length joined together is more accurate than bi-parietal diameter and femoral length when used separately .And this research confirmed that.

Previous study of (Khuwaja , et al , 2016. Suggests that A few parameters were considered as standard measurements which include crown-rump length , bi-parietal diameter , head circumference , femur length and abdominal circumference , And also this research confirmed that.

## **5.2. Conclusion:**

From this study there was a little variation between ultrasound measurement of BPD & FL in estimation of gestational age in the second trimester. This study suggests that average of femur length and BPD is more accurate to estimate gestational age than femur length or BPD separately

### **5.3. Recommendation:**

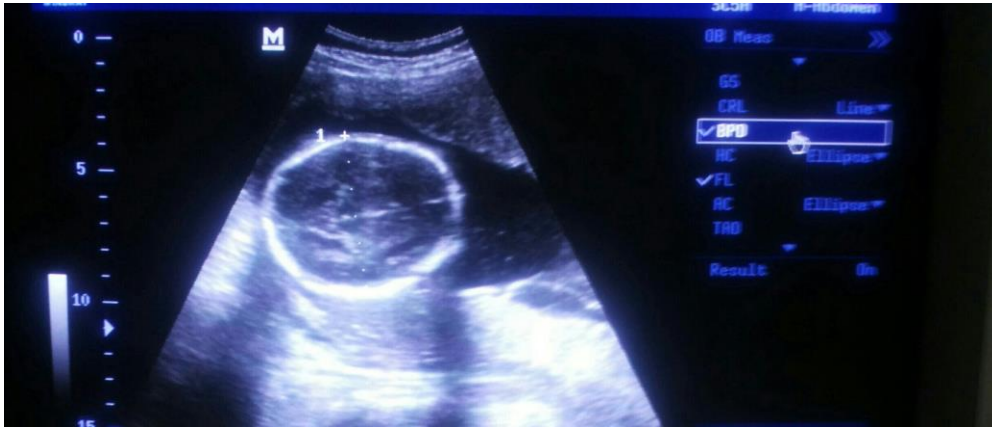- 1- All pregnant women in second trimester must be follow up by US to confirm the gestational age and to evaluate expected date of delivery.
- 2- To confirm E.D.D using average of FL & BPD rather than BPD or FL separately.
- 3- Using another different methods for measuring to estimate gestational age during pregnancy or in second trimester for pregnant women..

## REFERENCES

- Chawanpaiboon S. et al. Reference centile chart for transverse cerebellar diameter (TCD) in Thai fetuses throughout gestation (2006)
- Citation: Sumera Aziz Ali. , et al. “Estimation of Gestational Age Through Various Parameters:A Narrative Review”*ECGynaecology* 3.4(2016): 323-330
- \*Deter RL, Harrist RB. Assessment of normal fetal growth. In:Chervena FA , Isaacson GC , Campbell S , Editors. *Ultrasound in Obstetrics and Gynecology*.1993; 85 :361
- \*Deter RL. Evaluation of quantitative obstetrical ultrasound studies. In: Deter RL , Harrist RB , Birnholz JC , Haldlock FP , Churchill Living Stone 1986; 15-30 .
- Embryo and Fetal Pathology , COLOR ATLAS WITH ULTRASOUND CORRELATION
- ExaminationReview for Ultrasound: Abdomen &Obstetrics and Gynecology2011.
- \*Egley CC , Seeds JW , Cefalo RC. Femur length versus biparietal diameter for estimating gestational age in the third trimester. *AMJ Perinatol*. 1986;3 (2);77-9
- Fetal transcerebellar diameter measurement with particular emphasis in the
- Gardosi, J. Gierson R.T. (1998). Routine ultrasound in the method of choice for dating pregnancy. *Journal of obstetrics and gynaecology* 105: 933-936 .
- Hall, M.H. Carr-Hill, R.A. (1985). The significance of uncertain gestation for obstetric outcome. *British Journal of obstetrics and Gynaecology* 92:452-460..

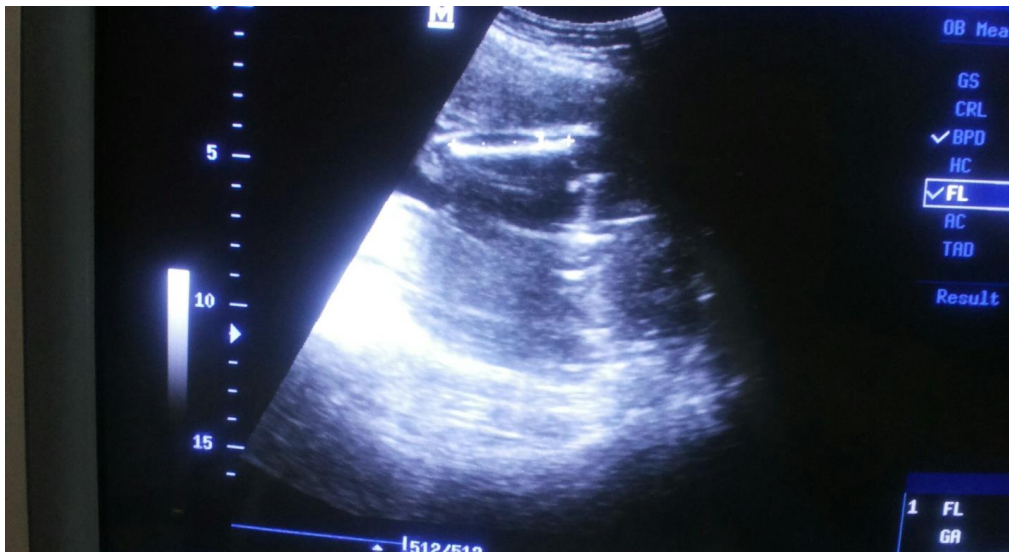
- International Journal of Pharmaceutical and Medical Research Volume 2 Issue –2 April 2014
- Journal of Gynecology and Obstetrics 2014; 2(6): 112-115 Published online November 20, 2014 (<http://www.sciencepublishinggroup.com/j/jgo>) doi: 10.11648/j.jgo.20140206.17. Journal of Institute of Medicine, 32.1 (2010): 19-23.
- Journal of Institute of Medicine, 32.1 (2010): 19-23. Joshi BR. “Fetal trans cerebellar diameter nomogram in Nepalese population”.
- Obstetric Ultrasound HOW , WHY AND WHEN , Third Edition 2004
- Pak J Med Sci October - December 2006 Vol. 22 No. 4 503-508
- Third trimester: a reliable predictor of gestational age. Am J Obstetric & Gynaecology 2004; 191:979-84.
- [www.Google.com](http://www.Google.com)
- [www.innovativepublication.com](http://www.innovativepublication.com)
- .2.Chavez MR , Ananth CV , Smulian JC , Yeo L , Oyelese Y , Vintzileos AM.

## 5.5. APPENDICES

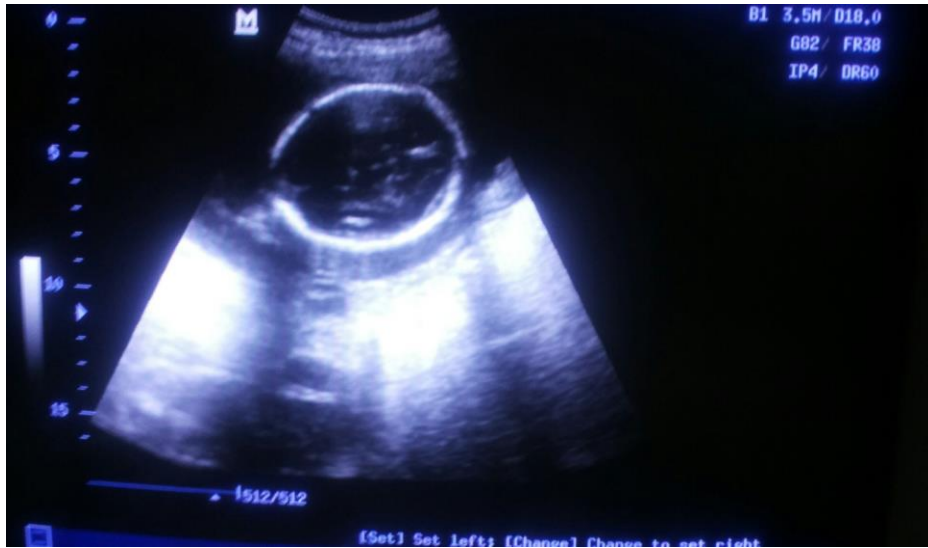

**Image (1) shows 25 years old pregnant female her GA by BPD is = 23weeks+  
4days**

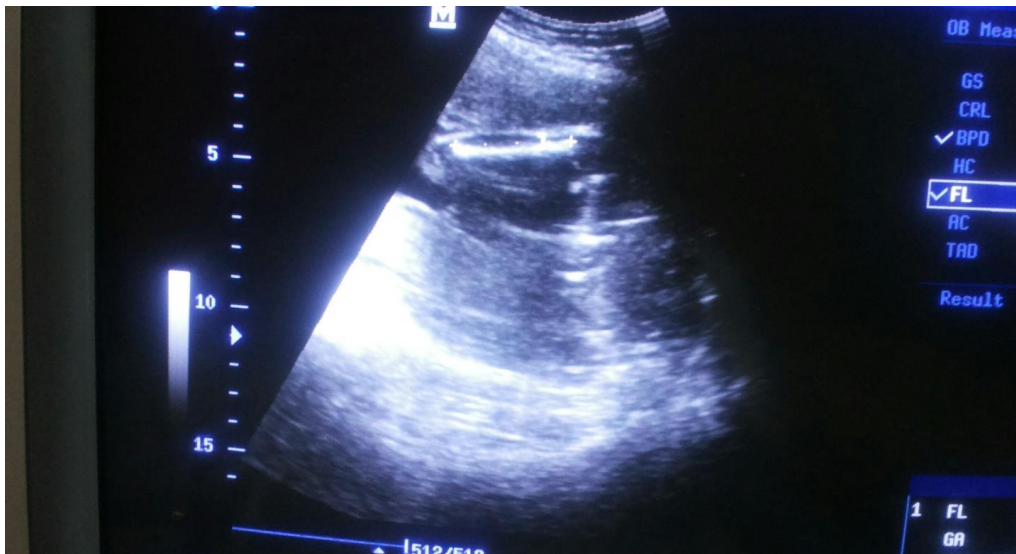
**EDD= 23\_1\_2017**



**Image (2) shows 30 years old pregnant female her GA by Femur Length=  
22weeks , EDD = 30\_1\_2017**



**Image (3) shows 20 years pregnant female and her GA by BPD=  
22weeks+4days  
EDD= 27\_1\_2017**



**Image (5) shows 25 years old pregnant female and her GA by Femur Length=  
22weeks, EDD= 30-1-2017**