Chapter One

1.1 Introduction:

The most prominent feature in the floor of the posterior cranial fossa is the foramen magnum in the occipital bones, this wide communication between the posterior cranial fossa and the vertebral canal, vertebral arteries and the spinal accessory nerve. Anteriorly the apical ligament of the dense and membrane tectoria are in it. Its wider posterior part contains the medulla oblongata and spinal cord continued. Anterior to its transverse diameter it is narrowed by the two occipital condyles. (Standring. et. al, 2008)

Foramen magnum (FM) is the oval shape opening located at the base of the skull, and bordered by the basilar, squamous, and two lateral parts of the occipital bone. The FM, as a transition zone between spine and skull, plays a vital role as a landmark because of its close association to key structures such as the brain and the spinal cord.(Boni. et. al, 2009).

Since the FM includes specific neuroanatomical structures and their lesions in that region which require particularly microsurgical intervention, choosing and establishing the most suitable surgical techniques need a careful planning mainly based on the FM size to refrain from any neurological injury. (Venkatesh. et. al, 2005). Moreover, intradural and extradural tumors, common congenital abnormalities such as FM syndrome produced by atlanto-occipital assimilation, and cerebellar tissue herniations which invaginated into the FM may lead to neural compression and even death are commonly met pathological disorders in this region. (Fatma Hayat Erdil .et al, 2010)

Computed tomographic scan is noninvasive modality for the imaging the skull base. Since this procedure is widely done, this modality was preferred. (Surwase, et. al., 2013)

Because of the dense bone of the base of skull beam-hardening artifacts are often seen in images of the posterior fossa, thin slices can help to reduce these artifacts and produce high spatial rsolution.

Reviewing published literature, identified many study concerning CT measurements of the foramen magnum in unidentified skulls, and reported studying 3D CT measurements of the foramen magnum with a resultant sex discriminant.

The cranial base is such a complex structure that it is only studied morphometrically. The sites where a number of vital structures have their entrance or exits are very important for clinical application. Therefore the assessment of these morphometrics is helpful for surgical approaches for reaching lesions in the middle and posterior part of cranial base.

(Cicekcibasi, et al, 2004)

The study of diameters of foramen magnum is interesting due to the important relations of the foramen magnum and also its contents.

Dimensions of the foramen magnum have clinical importance because the vital structures that pass through it may suffer compression. It has also been noted that longer antero-posterior dimension of foramen magnum permitted greater contralateral surgical exposure for condylar resection. So, anatomic and radiologic values of foramen magnum dimensions and their relation to gender have been the objectives of several studies. (Murshed et al,2003).

The anatomic and radiologic values have been the objectives of several studies. (Murshed et al, 2003). Recent advances in microsurgical technique and more wide spread use of the operating microscope have now enabled surgeons to approach previously in operable deep seated lesions of the skull base. It is therefore necessary that the clinicians should have athorough knowledge of anatomy of this region for

evaluation of various disease processes affecting this region (Laine FJ, et al 1990).

FM evaluations are very significant in not only to establish the most suitable operational procedures, but also to find valuable data for unidentified sex assessment and determination and individuality in forensic medicine.(Fatma Hayat Erdil .et al, 2010).

Determining the biological sex of unknown skeletal remains is an important aspect of medico-legal investigations seeking to establish the identity of a deceased individual. (Gapert, et al 2008).

Anthropologists are often faced with the task of assigning sex to remains that are incomplete, fragmented or damaged as may result from incidents such as mass disasters, airplane crashes, fire, explosions or physical violence (Teixeira,1982).

Comprised remains will affect the accuracy of sex estimation and thus necessitate the development of reliable sexing criteria based on isolated bony elements (Holland 1986).

The foramen magnum has attracted considerable interest for the purposes of sex determination (Uthman, et al., 2012).

The robusticity of the occipital bone and the relatively protected anatomical position of the foramen magnum beneath adepth of soft tissue may make it less vulnerable to fragmentation, or to the effects of inhumation and taphonomic processes in comparison to other cranial and facial bones (Holland 1989).

1.2 Problem of the Study:

The FM clinically importance since vital structures that pass through it which may suffer compression; such as in cases of FM achondroplasia and FM brain herniation as well as in a transcondylar surgical approach to the FM, when resection of tumors; removal of bony structures such as the occipital condyle (OC) may result in injury to the vascular structures and lower cranial nerves and result in craniocervical instability. Hence, knowledge of FM area‘s anatomy is of extreme importance for treating lesion and help the surgeon regarding selection best surgical approach and expected changes in the anatomy of these critical structures.

There is no specific characterization of the morphology and dimensions of the FM as standard in Sudanese population; so this study is obtain to study the anatomical variation of the FM for forensics, anthropologic and surgical purposes.

1.3 Objectives:

1.3.1 General objectives:

To measure the foramen magnum in Adult Sudanese using computed tomography.

1.3.2 Specific objectives

- To measure the foramen magnum size and dimensions.
- To characterize the foramen magnum shape and contour.
- To determine the correlation between the FM shape and size with gender.
- To find out an index for the FM for Sudanese compared to the other populations.

Chapter Two
Literature Review

2.1. Study no. one

2.1.1 Introduction

The foramen Magnum(FM) (Latin: 'great hole') is a large opening in the occipital bone of the cranium. Its transverse diameter is rather less than one third of the distance between the mastoid processes. The anterior border of the foramen magnum is formed by basilar process of the occipital bone, the lateral border by the left and right ex- occipitalis and posterior border is formed by the supraoccipital part of the occipital bone (Scheuer L, Black S. The juvenile skeleton. Elsevier, London, 2004).

The dimensions of the FM have clinical importance because the vital structures that pass through it may suffer compression such as in cases of FM achondroplasia (Hecht TJ, Horton WA, Reid CS, et al. Growth of the foramen magnum 1989) and FM brain herniation (Reich JB, Sierra J, Camp W, et al. 1993). In neurosurgical practice, the transcondylar approach is commonly used to access the lesions which are ventral to the brainstem and cervicomedullary junction. It was reported that understanding the bony anatomy of the condylar region is important for this approach (Muthukumar N, Swaminathan R, Venkatesh G, Bhanumathy SP 2005). The knowledge of foramen magnum diameters is needed to determine some malformations such as Arnold Chiari syndrome, which shows expansion of transverse diameter(Sgouros S, Goldin HJ, Hockely AD, Wake MJ, et 1999). In a computerized tomographic study of Catalina & Herrera ,dimensions of the foramen magnum of 63 achondroplastic individuals were compared to standards established for

nonachondroplastic individuals. The size of the foramen magnum in patients with achondroplasia was small at all ages, particularly in those with serious neurological problems (Catalina – Herrera CJ.1987). Furthermore, Wanebo et al.(Wanebo JE, Chicoine MR.2001). stated that longer FM antero-posterior dimensions permitted greater contralateral surgical exposure for condylar resection.

The diameters and area of the foramen magnum are greater in males than in females, hence its dimensions can be used to determine sex in the medicolegal conditions, especially in the following circumstances, such as explosions, aircraft accidents and war fare injuries (Sgouros S, Goldin HJ, Hockely AD, Wake MJ 1999& Gunay Y, Altinkok M 2000). So it is obvious that, FM evaluations are very important in not only to establish the most proper operational techniques, but also to obtain useful data for unknown sex estimation and determination and identity in forensic medicine. Present study was embarked on to examine the dimensions of foramen magnum.

2.1.2 Discussion

The dimensions of the foramen magnum are clinically important because vital structures passing through it. In present study the average antero-posterior diameter of the foramen magnum was 33.7mm(range 26-40mm) and the transverse diameter was 28.29mm(range 21.5-33.5).The mean surface area of foramen magnum was 755.37mm². Muthukumar & Swaminathan observed that the average antero-posterior length of the foramen magnum was 33.3 mm (range 27–39 mm) and the transverse diameter was 27.9mm (range 23–32 mm)[5]. There is statistically significant difference between present study and observation done by Muthukumar and Swaminathan ($p<0.01$).

Tubbs RS found that the mean anteroposterior diameter was 3.1cm , and the mean horizontal diameter was 2.7 cm and the mean surface area of the foramen magnum was 558 mm²(Tubbs RS, Griessenauer CJ, Loukas M, Shoja MM, Cohen-Gadol AA. Morphometric analysis of the foramen magnum: an anatomic study.Neurosurgery. 2010 Feb;66(2):385-8).

In Catalina-Herrera's anatomic study of the FM , the diameters were 35.2 mm for the sagittal and 30.3mm for the transverse diameter(Catalina – Herrera CJ. Study of the anatomic metric values of the foramen magnum and its relation to sex. Acta Anat 1987;130:344-347). Catalina-Herrera found that the means of the FM area in male and

female skulls were 888.4 mm^2 and 801 mm^2. Berge and Bergmann reported an average sagittal diameter of 34 mm and an average transverse diameter of 29 mm(Berge JK,Bergmann RA. 2001.

In a study done on skulls of Karnataka the mean longitudinal diameter of foramen magnum in male was 33.4mm and female was 33.1mm and by CT Imaging method in male was 38.5mm and female was 35.2mm. The mean transverse diameter of foramen magnum in male was 28.5mm and female was 27.3mm and by CT Imaging method in male was 29.1mm and female was 27.6mm(Muralidhar PS, Magi M. Morphometrics 2014, Vol 2(1):249-55). Philipp Gruber, in his study on skulls from western Europe found the sagittal diameter ranges 30 mm to 43 mm with mean of 36.6mm. The transverse diameter ranges from 25 mm to 39mm with the mean of 31.1mm(Gruber, P., Henneberg, M., Böni, T. and Rühli, F. J. (2009). In the Morphometric analysis of the foramen magnum in human skulls of brazilian individual in relation to gender Manoel, C. found that mean antero-posterior diameter of foramen magnum was 35.7 mm in male and 35.1mm in female. The transverse diameter was 30.3mm in male, 29.4mm in female(Manoel C, Prado FB, Caria PHF, Groppo FC.2009).

Wanebo & Chicoine(Wanebo JE, Chicoine MR. 2001), in their study on cadaveric CT images measurements, found that the mean area of the FM is 820.0 ± 100.0 mm2, the

mean length (SD) 36.0 ± 2.0 mm and the mean width (TD) 32.0 ± 2.0 mm.

Fatima Hayat Erdil studied fifty-four cranial CT scans obtained from the archives of Department of Radiology and observed that mean antero-posterior diameter of the foramen magnum was 35.58mm and transverse diameter was 29.84mm.The mean antero-posterior diameter in male and female was 30.75mm and 29.98mm respectively. The mean transverse diameter in male and female was 36.95mm and 34.41mm respectively. There was a significant difference between the anteroposterior diameter of male and female

Cases(Fatma Hayat Erdil, Vedat Sabancýoðullarý, Mehmet Çimen, Oktay Iþýk: Morphometric Analysis of the Foramen Magnum by Computed Tomography: Erciyes Medical Journal,2010;32(3):167-170). Günay Y, Altinkök M.;the mean of foramen magnum area was 909.91mm² males, 819.01mm² in females which was significant(p value<0.001)(Gunay Y, Altinkok M. 2000).

Since the FM includes specific neuroanatomic structures(Williams PL, Warwick R. Gray.s 1989, Coin CG, Malkasian DR. Foramen magnum. In Newton TH. Potts DG, editors. Radiology of the Skull and Brain. : The Skull. Vol 1, book 1 St. Louis: Mosby; 1971) and lesions occupied in that area which need especially microsurgical intervention(Coin CG, Malkasian DR. Foramen magnum1971), choosing and establishing the most appropriate surgical techniques require a meticulous

planning mainly based on the FM sizes to refrain from any neurological impairment(Coin CG, Malkasian DR. Foramen magnum1971. p. 275-286, George B, Lot G, Boissonnet H. 1997). In addition, it is quite difficult to detect many pathological situations not only by neurological examination but also needs support with the radiological findings(Coin CG, Malkasian DR. 1998).

2.1.3 Conclusion

The knowledge of diameters of the foramen magnum are needed to determine radiological malformations (Arnold Chiari's syndrome) and prior to cutting off of foramen magnum or posterior cranial fossa lesions, or sex determination of skulls. So the knowledge of dimensions of foramen magnum are important for neurosurgeons, radiologist as well as anthropologists.

2.2. Study no. two

2.2.1 Anatomy and physiology of base of skull

2.2.1.1 Foramen Magnum

In anatomy, the foramen magnum (Latin: "great hole") is a large opening in the occipital bone of the cranium. The foramen magnum is a large oval aperture with its long diameter antero-posterior; it is wider behind than in front where it is encroached upon by the condyles. (Figure 2.5) . It transmits the medulla oblongata and its membranes, the accessory nerves, the vertebral arteries, the anterior and posterior spinal arteries, and the membrana tectoria and alar ligaments. (Lieberman DE, et al 1999).

In humans, the foramen magnum is farther underneath the head than in great apes. Thus in humans, the neck muscles do not need to be as robust in order to hold the head upright. Comparisons of the position of the foramen magnum in early hominid species are useful to determine how comfortable particular species was when walking on two limbs (bipedality) rather than four.

The location of the foramen magnum plays a crucial role in our understanding of human evolution. Usually, the location of the foramen magnum is linked to bipedal behavior. Due to the thickness of the cranial base and its relatively protected anatomical position, this area of skull tends to withstand both physical insults and inhu- mation somewhat more successfully than many other areas of the cranium. (Jain D, et al 2014).

The foramen magnum (FM) is an important landmark of the base of skull and is of particular interest to many fields of medicine. (Gruber P, et al 2009). Variations of the shape of FM have got diagnostic, clinical and radiological importance.(Murshed K.A.,et al,2003). Also there exists some correlation between the shape of FM and ancestry of an individual. The dimensions of FM have clinical importance because the vital structures that pass through it may suffer compression as in cases of FM achondroplasia. (Hecht JT et al 1989, Reich JB et al 1993).

Foramen magnum is about 3cm wide by 3.5cm anteroposteriorly.(Premalatha Gogi et al 2014, Romanes GJ et al 1981). It is located midwaybetween and on a level

with mastoid processes. The foramen magnum is surrounded by different parts of the occipital bone, squamous part lies behind and above, basilar part in front and a condylar part on either side (Oliveira Ed, et al 1985, Rhoton AL.2000).

On each side its antero-lateral margin is encroached by occipital condyles, hence the foramen magnum is narrow anteriorly. The anterior edge of the foramen magnum is slightly thickened and lies between the anterior ends of the condyles. The posterior half of the foramen magnum is thin and semicircular. Upper ends of anterior and posterior atlanto-occipital membranes are attached to the anterior and posterior margins of the foramen magnum respectively, and their lower ends are attached to the superior surface of anterior and posterior arches of the atlas respectively. (Romanes GJ et al 1981)

The foramen magnum is a wide communication between posterior cranial fossa and the vertebral canal.

The narrow anterior part of the foramen magnum has apical ligament of dens, upper fasciculus of the cruciate ligament and membrana tectoria; both are attached to the upper surface of basioccipital bone infront of the foramen magnum. Its wide posterior part contains the medulla oblongata and its meninges. In subarachnoid space spinal rami of the accessory nerve and vertebral arteries, with their sympathetic plexus, ascend into the cranium; the posterior spinal arteries descend posterolateral to the brain stem, where as anterior spinal artery descends

anteromedian to brain stem. The cerebellar tonsils may project into the foramen magnum. (Bannister, et al1995).

Relations of foramen magnum, anteriorly - basilar part of occipital bone, Anterolaterally - occipital condyles, hypoglossal canal, jugular foramen Posteriorly - squamous part of occipital bone with the internal occipital crest. (Drake. 2010).

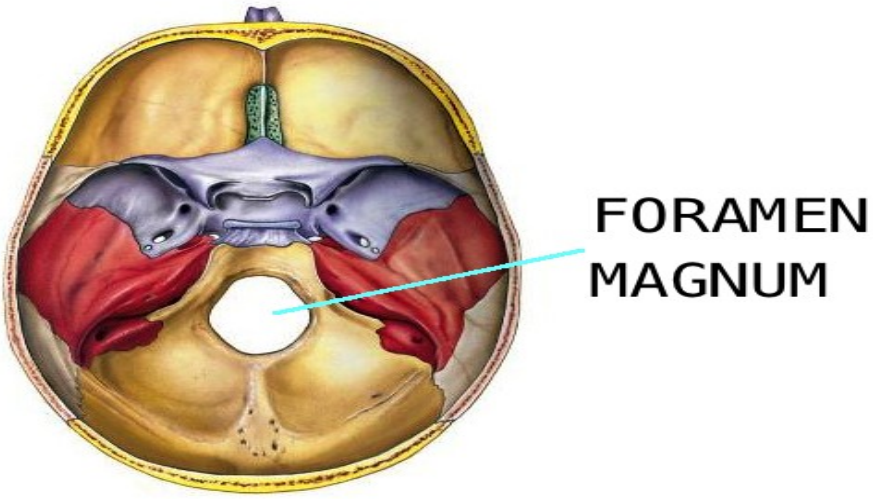

Figure 2.5. Sopererior view of the cranial base shows the foramen magnum. (Stephanie 2010)

2.2.1.1.1 The viatal structures pass through the foramen magnum:

2.2.1.1.1.1 The medulla oblongata (or simply medulla)

Is the most caudal part of the brainstem and sits between the pons inferiorly and spinal cord superiorly. It is the transition from the spinal cord to the brain. The medulla contains the vital autonomic cardiovascular and respiratory centers controlling heart rate, blood pressure, and breathing. It is composed of grey matter, cranial

nerve (CN) nuclei IX-to-XII, and white matter tracts (DSc SSP.2011, Grossman RI, et al 2003).

The medulla is approximately 3cm in length and 2cm in greatest diameter (DSc SSP.2011). The caudal border of the medulla is the 1st cervical spinal nerves. The superior broad part of the medulla joins the pons. (DSc SSP.2011, Grossman RI, et al 2003). Medulla is separated into two main parts: ventral (anterior) medulla which contains the olive, pyramidal tracts, and CN 9-12 rootlets, and tegmentum (dorsal) medulla which contain the CN nuclei and white matter tracts.

Ventral medulla: Pyramids are paired structures located at the medial aspect of ventral medulla and flank the anterior median fissure. It contains the the corticospinal tracts. At the caudal end of pyramids the corticospinal tracts decussate (DSc SSP.2011, Grossman RI, et al 2003). Olivary bodies are paired structures located at lateral aspect of ventral medulla, lateral to the pyramids. They are separated from the pyramids by an anterolateral sulcus (pre-olivary sulcus). There is also a post-olivary sulcus lateral to the olivary bodies. Olivary bodies contain the superior and larger inferior olivary nuclei (DSc SSP.2011).

Medulla tegmentum**:** The dorsal aspect of the medulla contains the posterior median sulcus (most dorsal medial sulcus) and more lateral posterolateral sulcus. Between these sulci are the fasciculus gracilis and nuclei forming gracilis tubercle at the midline and fasciculus cuneatus

and nuclei forming cuneate tubercle more laterally (DSc SSP.2011, Grossman RI, et al 2003).

The superior dorsal aspect of medulla forms the floor of the inferior 4th ventricle. It is occupied by the inferior cerebellar peduncle situated between the lower parts of the fourth ventricle. The inferior dorsal and lateral aspect of the medulla is surrounded by the cisterna magna (posterior cerebellomedullary cistern), and lateral cerebellomedullary cistern (DSc SSP.2011, Grossman RI, et al 2003).

The median aperture (foramen of Magendie) and the more superior lateral apertures (foramina of Luschka) open at the level of the pons, with the canals projecting to the level of the medulla region and terminating into the cistern magna and lateral cerebellomedullary cistern respectively(Rogers L.2008) .

2.2.1.1.1.2 The meninges

Is a collective term for the three membranes that cover the brain and spinal cord, cerebral meninges surround the brain and is made up of three layers (from outermost to innermost): dura mater, arachnoid mater and pia mater. The dura mater can also be known as pachymeninx. The arachnoid mater and pia mater are collectively known as the leptomeninges. (Strominger NL et al 2012).

The spinal meninges are similar but have some important differences.

The meninges function to protect the brain but also provides a framework for blood vessels, nerves, lymphatics and CSF (Ovalle WK,.et al 2013).

2.2.1.1.1.3 The spinal accessory nerve

Also called accessory nerve, is the eleventh cranial nerve (CN XI) and is composed of two parts, the cranial part and the spinal part. The cranial part (accessory portion) is the smaller of the two. Its fibers arise from the cells of the nucleus ambiguus and emerge as four or five delicate rootlets from the side of the medulla oblongata, below the roots of the vagus. It runs laterally to the jugular foramen, where it interchanges fibers with the spinal portion or becomes united to it for a short distance. (Wilson 2002)

The spinal part (spinal portion) is firm in texture, and its fibers arise from the ventral horn cells in the cord between C1 and C5 of the cervical plexus.

The fibres emerge from the cord laterally between the anterior and posterior spinal nerve roots to form a single trunk, which ascends into the skull through the foramen magnum. (Waxman S, et al 2003).

2.2.1.1.1.4 The vertebral arteries (VA)

The vertebral artery (VA) arises from the subclavian artery, ascends in the neck to supply the posterior fossa and occipital lobes as well as provides segmental vertebral and spinal column blood supply. (Cloud GC, et al 2003)

The origin of the VA is usually from the posterior superior part of the subclavian arteries bilaterally, although the origin can be variable:

- Brachiocephalic artery (on the right)
- Aortic arch: 6% of cases

The VA is normally 3-5 mm in diameter and the ostium is the most common site of stenosis.

When the origin is from the arch, then it is common for the artery to enter the foramen transversarium at a level higher than normal (C5 instead of C6). (Satti SR, et al 2007).

The duramater around the FM is supplied by the anterior and posterior meningeal branches of the vertebral artery, and the meningeal branches of the ascending pharyngeal and occipital arteries.

2.2.1.1.1.5 The venous structures

The venous structures in the region of the FM are divided into three groups:

-Extraduralveins (extraspinal& intraspinalpart)

-Intradural (neural) veins

-Dural venous sinuses (superior petrosal, marginal & occipital).

The three groups anastomose through bridging and emissary veins.

2.3 Study no. three

2.3.1 Characterization of Foramen Magnum

The foramen magnum (FM) is an important anatomical region of the skull base and is of significance for anatomy, anthropology and other medical fields. The transcondylar approach has been used in surgeries to access lesions in areas close to the foramen magnum (FM) and is performed directly through the occipital condyle (OC).

This study aims to characterize the foramen magnum shape and contour and determine of the different anatomical variations through the use of reconstructed helical CT images. For verify the morphological characteristics of the (FM) for gender determination in Sudanese individuals by measuring the saggital, transverse diameter, area, circumference and characterizing its shape, and to characterize the anatomical variations related to the (OC) measurements.

A total of 241 Sudanese patients (147 males and 94 females) with mean ages were 40.96±15.21, 41.02±14.32 years respectively were examined using reformatted axial CT and three-dimensional CT, between September 2012 and July 2014, referred to the Radiology Department in the Ibn ALhythm Medical Center, Khartoum, Sudan The foramen magnum shapes were determined as a round shape in 55(22.9%) of the cases, oval in 115 (47.8%), irregular in 36(14.8%) and arrow head in 35(14.5%), the mean sagittal and transverse diameters of the foramen

magnum were determined as 34.0±2.98 mm and 29.3±2.44 mm respectively. Area of the (FM) was 770.0±111.09 and Circumference of the (FM) was 104.1±11.55, a significant difference between genders were detected at p-value =0.05.

Characteristics of the head, and measures related to the (FM) and right and left occipital condyles were examined. The results showed no significant difference between the measurements obtained in the right and in left sides. The (OC) morphometric parameters had significant relationship with (FM) antroposterior and transverse diameters. The study revealed a significant difference between the two genders with no significant relations between (OC) and head characteristics. The data obtained by three-dimensional CT images are important in assessing the morphometric variations of (OC) for Sudanese patients. As the (OC) is the main bony eminences impeded the anterolateral surface of the brainstem, neurosurgeons should be familiar with variations of the (OC) and structures surrounding the (FM) in order to

achieve the safest surgical procedure. knowledge of FM area‘s anatomy is of extreme importance for treating lesion and help the surgeon regarding selection best surgical approach and expected changes in the anatomy of these critical structures and resection of tumors; removal of bony structures such as the occipital condyle (OC) may result in injury to the vascular structures and

lower cranial nerves and result in craniocervical instability. (Alamin MS, et al 2015).

2.3.2 Discussion:

Since the FM includes specific neuroanatomical structures and their lesions in that region which require particularly microsurgical intervention, choosing and establishing the most suitable surgical techniques need a careful planning mainly based on the FM size to refrain from any neurological injury (Muthukumar,et al ,2005).

The difference in the FM morphology from various reports indicates racial variability. (Chet Han et al 2012) but the irregular shape of FM is highlighted by the developmental cranial anomalies (Furtado SV et al 2010).

The FM is most common described as oval in shape. In a study of 200 skulls, Zaidi and Dayal reported that oval FMs were found in 128 (64%) skulls (Zaidi et al 1988), Radhakrishna et al, study revealed, 39% with oval shape, Gupta Chandni et al., reported that oval FMs in 35%, Sindel et al. and Lang et al. reported that this shape was not found in more than 18.94% and 22.35%, respectively, of their samples (Sindel et al 1989, Lang et al 1983). In present study a total of four shape categories were identified, Round Oval, Arrowhead, and Irregular, oval-shaped FM, was the morphological type of most frequently found in Sudanese; (Zaidi SH et al 1988, Espinoza et al. 2011, Radhakrishna et al. 2012, Avci et al. 2011) reported similar findings.

The variations have been attributed, among some authors due to different factors such as sexual dimorphism (Ukoha U et al 2011), types of population (Krıshnamurthy A et al 2012), and ethnic groups (Espinoza E et al 2011). The oval morphological types of FM substituted 115 (47.8%) of the sample and the rounded proceeded 55(29.49%) , other types with their respective frequencies of occurrence have been found as arrow head shape in 36 (14.8%) and the irregular shape achieved 35(14.5%),similar findings were described by many authors (Chethan P et al 2012 , Natsis K et al 2013).

The Pearson's chi-square test (P-value 0.171) revealed that there is no association between foramen magnum shape and gender in the study.

The comparison of the morphometric analysis obtained in this study with the results of other studies had the following results: the length of the foramen magnum sudnese (35.2 ± 2.68) was lower than some population studied , which was the of Brazilian male skulls (36.5 ± 0.29) , Turkish (37.2 ± 3.43) Murshed, Cicekcibasi and Tuncer (2003), Spanish (36.2 ± 0.3) Herrera (1987), and English populations (35.91 ± 2.41) Gapert, Black and Last (2008), and Indian population (35.5 ± 2.8) Routal, Pal, Bhagwat et al. (1984). Also is lower measure for the female skulls (32.17 ± 2.44) than Brazilian population (35.1 ± 0.33), Turkish (34.6 ± 3.16) Murshed, Cicekcibasi and Tuncer (2003), Spanish (34.30 ± 0) Herrera (1987),

Indian (32.0 ± 2.8) Routal, Pal, Bhagwat et al. (1984), and English populations (34.71 ± 1.91) Gapert, Black and Last (2008).

Regarding the width of the foramen magnum, the values of the Sudanese male skull(30.25 ± 2.33) same of Brazilian male skulls (30.3 ± 0.20) and were higher than those of the Indians (29.6 ± 1.9) Routal, Pal, Bhagwat et al. (1984) only and lower than the Turkish (31.6 ± 2.99) Murshed, Cicekcibasi and Tuncer (2003), Spanish (31.1 ± 0.3) (HERRERA, 1987), and English populations (30.51 ± 1.77) Gapert, Black and Last (2008). Also near to be the same (27.89± 1.78) measure for the female skulls of the Indian (27.1 ± 1.6) Routal, Pal, Bhagwat et al. (1984) and measure lower than and Turkish populations (29.3 ± 2.19) Murshed, Cicekcibasi and Tuncer (2003) and lower than Spanish (29.6 ± 0.3) Herrera (1987), English populations (29.36 ± 1.96) Gapert, Black and Last (2008), and Brazilian (29.5± 0.23).

In this study, the results were 42.1 and 39.5 mm as the maximum sagittal and transverse diameter, respectively, in male subjects, and 38.3 and 32.8 mm, respectively for female subjects. The minimum values were 28.70 and 24.6 mm for the sagittal and transverse diameters in male subjects, and 25.8 and 23 mm for the same parameters in female subjects. The mean in males was 35.20±2.68 mm for the sagittal diameter and 30.25±2.33 mm for the transverse. In females, the mean was 32.17±2.44 mm and 27.89±1.78 mm, respectively.

In foramen magnum length and width measurement, but slightly near to (AT Uthman, NH 2011) measurements who was studied Iraqy population. Lastly in the agreement to present study they stated that there was significant sex difference in quantified parameters indicating that the foramen magnum is larger in males. The (FM) measurements, including length and width and its correlation with the occipital condyles characteristics, including right occipital condyle length (LRC), left occipital condyle length (LLC), maximum distance between occipital condyles (MDC), minimum distance between occipital condyles (MnLC), maximum internal distance of the occipital condyles (Mic), were found to be significant at p=0.01, and no significant relations were detected between right and left occipital condyle maximum width (WRC, WLC) with the length and width of the foramen magnum (LFM,WFM).

2.3.2.3 Foramen magnum area and circumference:

Regarding FMC, the mean values were greater in males than in females (108.84 mm ±11.04 mm vs 96.63 mm ± 8.84 mm). To our knowledge, the study of (AT Uthman, NH 2011) was the first that used this measurement variable and no literature has previously discussed it. In the present study the area of the foramen magnum of male skulls (819.84 mm2) Table(4.5) was significantly larger than female skulls (692.13 mm2) the mean area of the foramen magnum of males in present study was similar to the observations made by (Routal , et al 1984) on Gujarati

male skulls (819.0mm2), However it was lower than the observations made by Catalina Herrera , on Spain white male skulls (888.4 mm2) and Gunay on Turkey male skulls (909.9mm2), and show greater measurement from that found by (Muralidhar P Shepur et al ,2014) (748.6mm2) and (Sayee, et al 1987) on male skulls of Karnataka (769.0mm2).

The mean area of the foramen magnum of female skulls (692.13 mm2) it was lower in comparison with observations of Catalina Herrera, on Spain white female skulls (801.0mm2) and Gunay on Turkey female skulls (819.0mm2). (Sayee, et al 1987) on Karnataka female skulls (746.0 mm2) and (Routal, et al 1984) on Gujarti female skulls (771.0mm2). Muralidhar P Shepur et al (711.1 mm2).

2.3.2.4 Foramen magnum transverse and saggital diameter of the head

Regarding craniometric measurements, there was a highly significant statistical difference in head width measurements between genders, in the study of Deshmukh and Devershi (Deshmukh et al 2006) measured head width using sliding vernier calipers directly on the crania, which resulted in mean values of 131mm±0.49 mm for males and 127 mm± 0.49 mm for females. (AT Uthman,NH 2011) study which is first and only study using CT in craniometric measurements assessing head width diameter for gender determination , measured TDH, 143 mm ± 6.49mm for male and 137 mm

± 4.2mm .These values were higher than those recorded in the present 121.45mm ± 10.89mm, for male and 115.29mm ±6.50 mm for female.

Current measured 155.39 mm ± 8.76 mm, for male and 147.02 mm ±8.86 mm for female, Table (4.5), for SHD which there is no previous literature in this case, with statistically significant differences existed between males and females.

The sex determination is of great value in forensic medicine as well as in anthropology. Therefore the corroborate that the sagital and transverse diameters of the FM are of great value for this determination and the correlation between the area and circumference of the FM is of highly significance with the transverse and sagital diameter of the head and FM **2.3.3 Conclusion**

To conclude, the present study regarding morphometry of foramen magnum was in agreement with earlier studies done so far, hence it shows diameters of foramen magnum were greater in males than in females. FM measurements are valuable in studying sexual dimorphism in forensic investigations with high significant difference was observed between sexes. The area and circumference of FM varies in relation with gender and ethnicity group. However, it should be noted that sex differences in the dimensions of the FM and the variations should be taken into concern during the performance of clinical and radiological diagnostics and during surgical approach. Current study results show the shape of the

foramen magnum is not indicative of a specific ancestral group; and gender; however, the oval shape is predominated and followed by round one , arrow head and irregular shape respectively .

Measurements of the Occipital condyles diameter and protrusion contribute to the shape and size of FM diameter, considering the vital structures that pass through FM.

Most of the data obtained in CT corroborate previous studies and are important parameters in the evaluation of morphometric variations of presurgical preparation in regard to the transcondylar approach, thus helping to reduce the risk of neurovascular injury during the procedure.

Computed tomographic scan is noninvasive modality for the imaging the skull base. Since this procedure is widely done, this modality was preferred. CT/3D CT can be accurately used in further investigations to provide basis for anthropometric and forensic issues Current study findings may consider as reference for Sudanese, and the measurements may describe the normal morphological variants of FM for Sudanese. Since the anatomy of the FM is of interest to many radiological fields. The radiologists must have knowledge of normal anatomy of skull base to determine the presence of abnormality and to help in surgical planning. The information gained from the present study will be of useful to all of the medical and radiological fields.

Chapter Three
Materials and Methods

3.1 Materials

3.1.1 Subject and study sample

A prospective study of 100 consecutive Sudanese patients (64 were males and 36 females age range between 20 - 70 years, FM dimensions tend to stabilize after the second decade of life , were enrolled in the study , between October 2015 and January 2016.

They were referred to the Radiology Department in the Dar Al Elaj Specialized Hospital, Khartoum, Sudan, in which the patients subjected to CT Brian for different clinical indications. Patients with previous trauma, surgery or pathology in the region of the FM were excluded, because disorders involving skull base may distort the normal Anatomy of skull base, and patient who have sound health of adult age whose skeletal growth is complete were included.

All patients examined on a multislice CT scanner (Brilliance Philips 64 slice). The scan is performed with the patient in the supine position, It is very important to ensure that there is no rotation or tilt of head in order to demonstrate any bilateral asymmetry, the protocol used for routine head scanning from base of skull through apex,

with kVp of 120 and 200 mAs, slice thickness is depending on the structure being scanned, thin data and bone require slice thickness of 5mm and 2mm for reformatted images. Because of the dense bone of the base of skull beam-hardening artifacts are often seen in images of the posterior fossa, thin slices can help to reduce these artifacts.

Helical mode is primarily used for studies that require 3D reformations.

All FM measurements were taken from reformatted images (3D volume rendering), by the measurement function available in the CT system (brilliance Philips 64 slice).

3.2 Data Collection & Analysis

3.2.1 Data collection

The Data were collected using the following variables: age, Gender, as well as the measurements relating to foramen magnum.

All measurements, of the Foramen Magnum(FM) and in (mm) were taken as follows :

❖ **Foramen Magnum(FM) measurements :**

Length of the foramen magnum (LFM): is the distance taken in a straight line from the end of the anterior border (basion) through the center of the foramen magnum until the end of the posterior border toward the median sagittal plane(Antero posterior diameter)

Width of foramen magnum (WFM) - is the distance in a straight line from the end of the border right side, with the concavity stronger through the center of the foramen

magnum to the opposite end of the lateral border of concavity more pronounced, with transverse direction (transverse diameter). (appendix A, image :1)

The of foramen magnum area and circumference, both area and foramen magnum were measured by tracing the bony border in the 3D volume rendering.

3.2.2 Statistical analysis

The data obtained were analyzed statistically by computing descriptive statistics like Mean, ± SD values and Percentages, with an independent Test,ANOVA test, and by correlation analysis using an IBM SPSS Statistics software package (Inc., Chicago, Illinois version 16).

Chapter Four
Results

Table 4.1: Distribution of the study sample according to (Gender)

Gender	Frequency	Percent
Male	53	53%
Female	47	47%
Total	100	100%

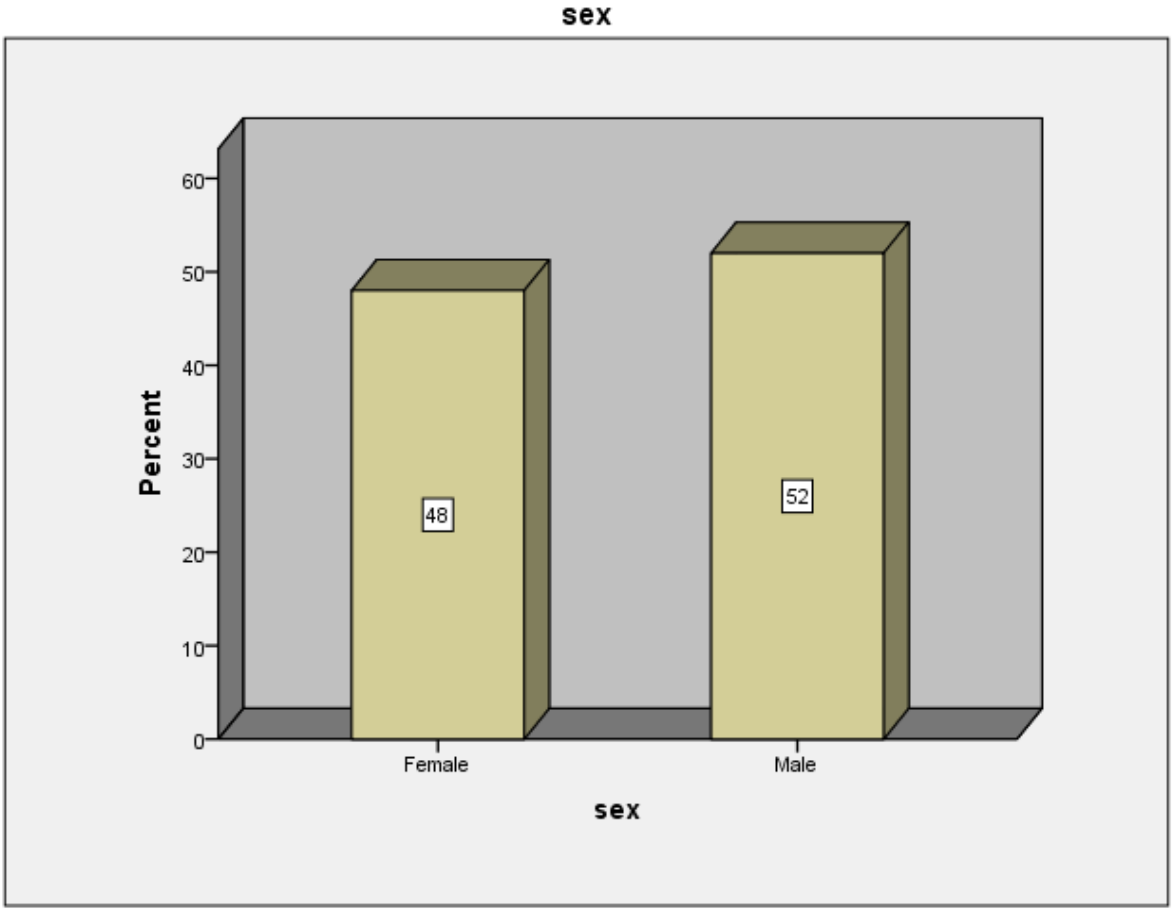

Figure4.1: Distribution of the study sample according to (Gender)

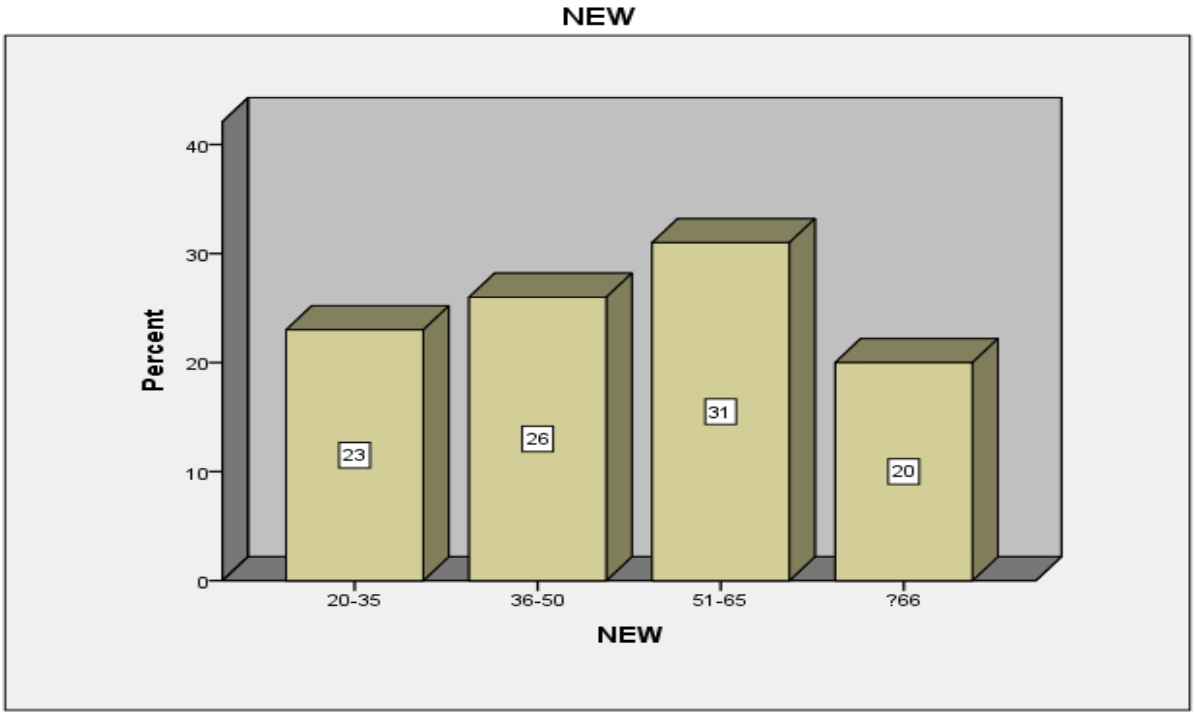

Figure 4.2: Distribution of the study sample according to (Age group)

Table 4.2: The Sudanese foramen magnum morphology, frequency and percentages.

	Frequency	Percent (%)
Round	17	16%
Ovale	53	56%
Arrow Head	15	15%
Irregular	15	13%
Total	100	100%

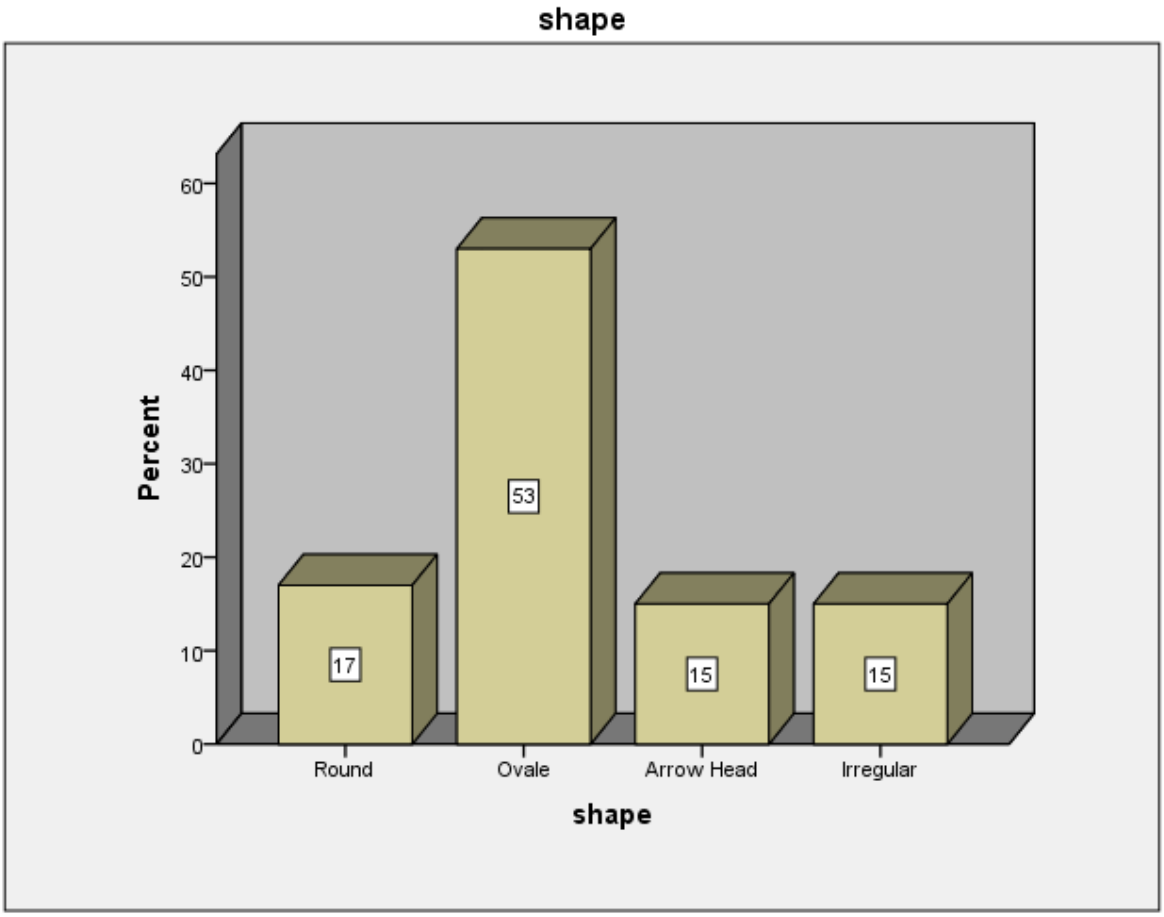

Figure 4.3: The Sudanese foramen magnum morphology, frequency and percentages.

Table 4.3: General Statistics

		Age	Sex	LFM	WFM	shape
N	Valid	100	100	100	100	100
	Missing	0	0	0	0	0
Mean		49.69	.52	35.371	28.568	2.28
Std. Deviation		15.526	.502	2.4932	2.4829	.922
Variance		241.065	.252	6.216	6.165	.850
Minimum		20	0	30.0	24.1	1
Maximum		70	1	39.9	36.5	4

Table 4.4: general statistic for male

	LFM	WFM	shape
N	52	52	52
.Missing	0	0	0
Mean	35.394	28.837	2.13
Std. Deviation	2.7356	2.7087	.864
Variance	7.483	7.337	.746
Minimum	30.0	24.1	1
Maximum	39.9	36.5	4

Table 4.5: statistics according to the Shape of FM in male

	Frequency	Percent	Valid Percent	Cumulative Percent
Round	11	21.2	21.2	21.2
Ovale	28	53.8	53.8	75.0
Arrow Head	8	15.4	15.4	90.4
Irregular	5	9.6	9.6	100.0
Total	52	100.0	100.0	

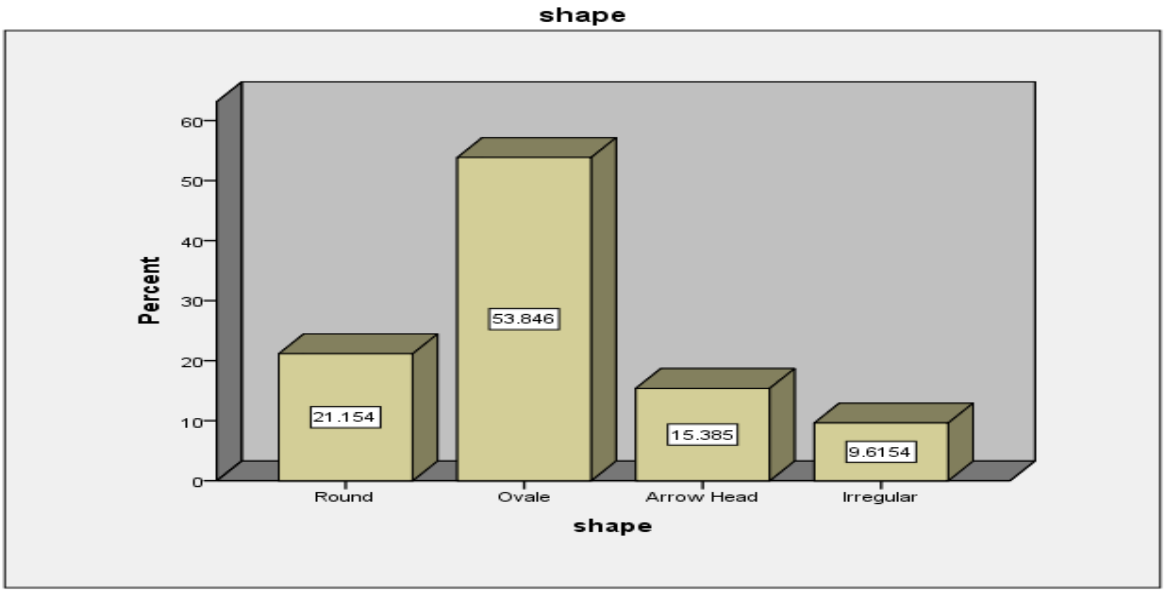

Figure 4.4: The adult male Sudanese foramen magnum morphology, frequency and percentages.

Table 4.6: general statistic for female

	LFM	WFM	Shape	
N		48	48	48
,,,,Missing		0	0	0
Mean	34.346	28.277		2.44
Std. Deviation	2.2299	2.2041		.965
Variance	4.972	4.858		.932
Minimum	30.0	24.5		1
Maximum	39.4	35.0		4

Table 4.7: statistics according to the Shape of FM in female

	Frequency	Percent	Valid Percent	Cumulative Percent	
	Round	6	12.5	12.5	12.5
	Ovale	25	52.1	52.1	64.6
	Arrow Head	7	14.6	14.6	79.2
	Irregular	10	20.8	20.8	100.0
	Total	48	100.0	100.0	

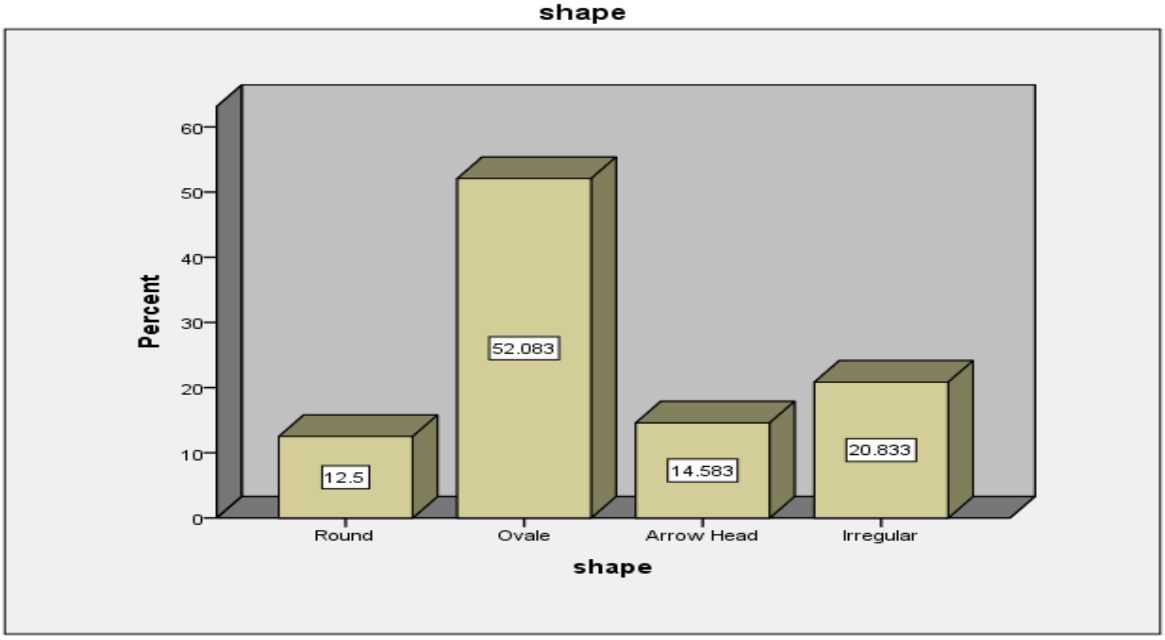

Figure 4.5: The adult male Sudanese foramen magnum morphology, frequency and percentages.

Chapter Five

5.1 Discussion:

5.1.1 Foramen magnum length and width:

The comparison of the morphometric analysis obtained in this study with the results of other studies had the following results: the length of the foramen magnum Sudanese (35.37±2.49) was upper than the length of the South Gujarat skulls (33.7mm±2.23) and was lower than some population studied ,which was the of Brazilian male skulls (36.5 ± 0.29) , Turkish (37.2 ± 3.43) Murshed, Cicekcibasi and Tuncer (2003), Spanish (36.2 ± 0.3) Herrera (1987), and English populations (35.91 ± 2.41) Gapert, Black and Last (2008), and Indian population (35.5 ± 2.8) Routal, Pal, Bhagwat et al. (1984). Also is lower measure for the female skulls (34.35± 2.23) than Brazilian

population (35.1 ± 0.33), Turkish (34.6 ± 3.16) Murshed, Cicekcibasi and Tuncer (2003), and English populations (34.71 ± 1.91) Gapert, Black and Last (2008).

Regarding the width of the foramen magnum, the values of the Sudanese male skull(35.39±2.74) were higher than those of the of Brazilian male skulls (30.3 ± 0.20) ,Indians (29.6 ± 1.9) Routal, Pal, Bhagwat et al. (1984) , Turkish (31.6 ± 2.99) Murshed, Cicekcibasi , Tuncer (2003), Spanish (31.1 ± 0.3) (HERRERA, 1987), and English populations (30.51 ± 1.77) Gapert, Black and Last (2008) , Indian (27.1 ± 1.6) Routal, Pal, Bhagwat et , Turkish populations (29.3 ± 2.19) Murshed, Cicekcibasi , Spanish (29.6 ± 0.3) Herrera (1987), English populations (29.36 ± 1.96) Gapert, Black and Last (2008), and Brazilian (29.5± 0.23). In this study, the results were 39.9 and 36.5 mm as the maximum sagittal and transverse diameter, respectively, in male subjects, and 39.4 and 35.0 mm, respectively for female subjects.

The minimum values were 30.0 and 24.1mm for the sagittal and transverse diameters in male subjects, and 30 and 24.5 mm for the same parameters in female subjects. The mean in males was (35.39 ± 274) mm for the sagittal diameter and (28.84 ± 2.71) mm for the transverse. In females, the mean was (34.45 ± 2.23) mm and (28.28 ± 2.20) mm, respectively. Table (4.5)

5.1.2 Foramen magnum shape:

Since the FM includes specific neuroanatomical structures and their lesions in that region which require particularly

microsurgical intervention, choosing and establishing the most suitable surgical techniques need a careful planning mainly based on the FM size to refrain from any neurological injury (Muthukumar,et al ,2005).

The difference in the FM morphology from various reports indicates racial variability. (Chet Han et al 2012) but the irregular shape of FM is highlighted by the developmental cranial anomalies (Furtado SV 2010).

The FM is most common described as oval in shape. In a study of 200 skulls, Zaidi and Dayal reported that oval FMs were found in 128 (64%) skulls (Zaidi et al 1988), Radhakrishna et al, study revealed, 39% with oval shape, Gupta Chandni et al., reported that oval FMs in 35%, Sindel et al. and Lang et al. reported that this shape was not found in more than 18.94% and 22.35%, respectively, of their samples (Sindel et al 1989, Lang et al 1983).

In present study a total of four shape categories were identified, Round Oval, Arrowhead, and Irregular, oval-shaped FM, was the morphological type of most frequently found in Sudanese; (Zaidi SH et al 1988, Espinoza et al. 2011, Radhakrishna et al. 2012, Avci et al. 2011) reported similar findings. The variations have been attributed, among some authors due to different factors such as sexual dimorphism (Ukoha U et al 2011), types of population (Krıshnamurthy A et al 2012), and ethnic groups (Espinoza E et al 2011). The oval morphological types of FM substituted 53 (53%) of the sample and the rounded proceeded 17(17%) , other types with their

respective frequencies of occurrence have been found as arrow head shape in 15 (15%) and the irregular shape achieved 15(15%), near to be the same were described by (Alamen MS 2015)

5.2 Conclusion

The dimensions of FM have clinical importance because the vital structures that pass through it may suffer compression as in cases of FM achondroplasia. To conclude, the present study regarding morphometry of foramen magnum was in agreement with earlier studies done so far, hence it shows diameters of foramen magnum were greater in males than in females.

FM measurements are valuable in studying sex dimorphism in forensic investigations with high significant difference was observed between sexes.

However, it should be noted that sex differences in the dimensions of the FM and the variations should be taken into concern during the performance of clinical and radiological diagnostics and during surgical approach.

Current study results show the shape of the foramen magnum is not indicative of a specific ancestral group; and gender; however, the oval shape is predominated and followed by round one , arrow head and irregular shape have equal incident percentage.

The radiological and anatomical measurements indicated that the radiological assessment greatly helps to organize the preoperative preparation.

Computed tomographic scan is noninvasive modality for the imaging the

skull base. Since this procedure is widely done, this modality was preferred.

CT/3D CT can be accurately used in further investigations to provide basis for anthropometric and forensic issues.

Current study findings may consider as reference for Sudanese, and the measurements may describe the normal morphological variants of FM for Sudanese. Since the anatomy of the FM is of interest to many radiological fields.

The radiologists must have knowledge of normal anatomy of skull base to determine the presence of abnormality and to help in surgical planning.

The information gained from the present study will be of useful to all of the medical and radiological fields.

5.3 Recommendation

1. Large sample size studies for future.
2. a few studies have been performed in different parts of the world on the size and shape of CC reporting different findings about it, there is no documented data regarding anatomical characteristics of CC in the Sudanese population.
3. Further studies should be performed in order to estimate differences among various ethnicity/races especially in Sudan and to establish the normal standard data in Sudanese population.

References

Berge JK,Bergmann RA. 2001. Variation in size and in symmetry of the foramina of the human skull. Clin Anat **14**: 406–413.

Catalina – Herrera CJ 1987. Study of the anatomic metric values of the foramen magnum and its relation to sex. Acta Anat;130:344-347.

Coin CG, Malkasian DR1971. Foramen magnum. In Newton TH. Potts DG, editors. Radiology of the Skull and Brain. : The Skull. Vol 1, book 1 St. Louis: Mosby; p. 275-286.

Coin CG, Malkasian DR1971. Foramen magnum. In Newton TH. Potts DG, editors. Radiology of the Skull and Brain. : The Skull. Vol 1, book 1 St. Louis: Mosby p. 275-286.

Gruber, P., Henneberg, M., Böni, T. and Rühli, F. J. (2009), Variability of Human Foramen Magnum Size. Anat Rec; 292:1713-19.

Manoel C, Prado FB, Caria PHF, Groppo FC2009. Morphometric analysis of the foramen magnum in human skulls of brazilian individuals: its relation to gender.

Muralidhar PS, Magi M 2014. MORPHOMETRIC ANALYSIS OF FORAMEN MAGNUM. Int J Anat Res, Vol 2(1):249-55.

Ropper AH1993. MRI demonstration of the major features of herniation. J Neurol Neurosurg Psychiatry 56: 932-5.

RS1992.. Clinical Anatomy for Medical Student. 4th edition. Boston; Little, Brown and Company: p. 808-812.

Saldinger P, Dvorak J, Rahn BA, Perren SM. (1990) Histology of the alar and transverse ligaments. Spine; 15:257–261.

Sgouros S, Goldin HJ, Hockely AD, Wake MJ1999, et al.Intracranial volume change in childhood. J Neurosurg;91:610-616.

Wanebo JE, Chicoine MR. Quantitative analysis of the transcondylar approach to the foramen magnum. Neurosurgery;49: 934-41, 2001.

Williams PL, Warwick R. Gray.s1989 Anatomy. Xnd edition. New York: Churchil Livingstone .p.342-361.

Ünal F, Kýrýþ T, Ýzgi N, Önal Ç, Tükel T1998. Mukopolisakkaridozlarýn nöroþirürjikal komplikasyonlarý. Ýstanbul Týp Fakültesi Mecmuasý 61:1.

Appendices:

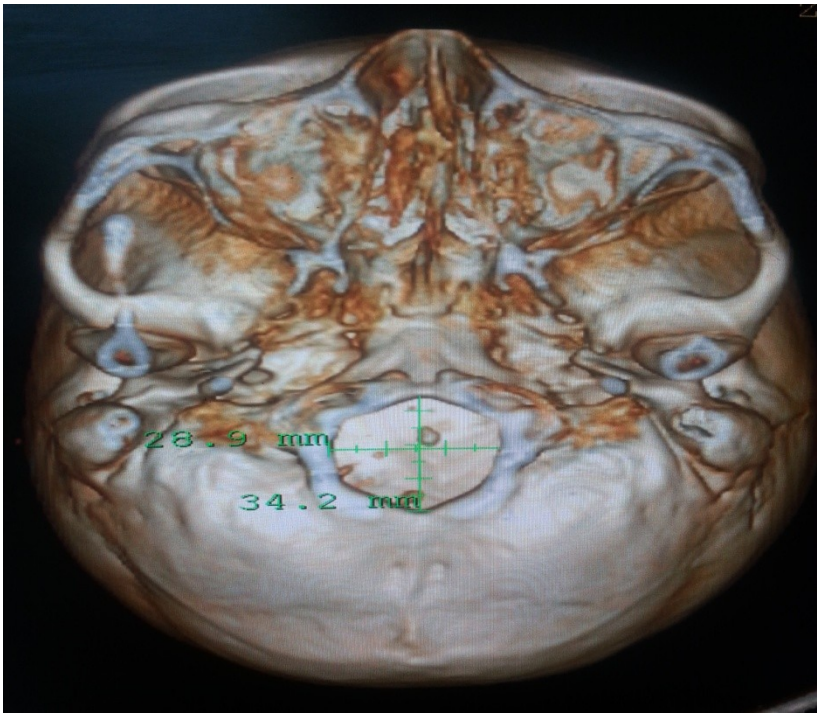

Figure1: 38y mail his FM measurement LFM 34.2 and WFM 28.4

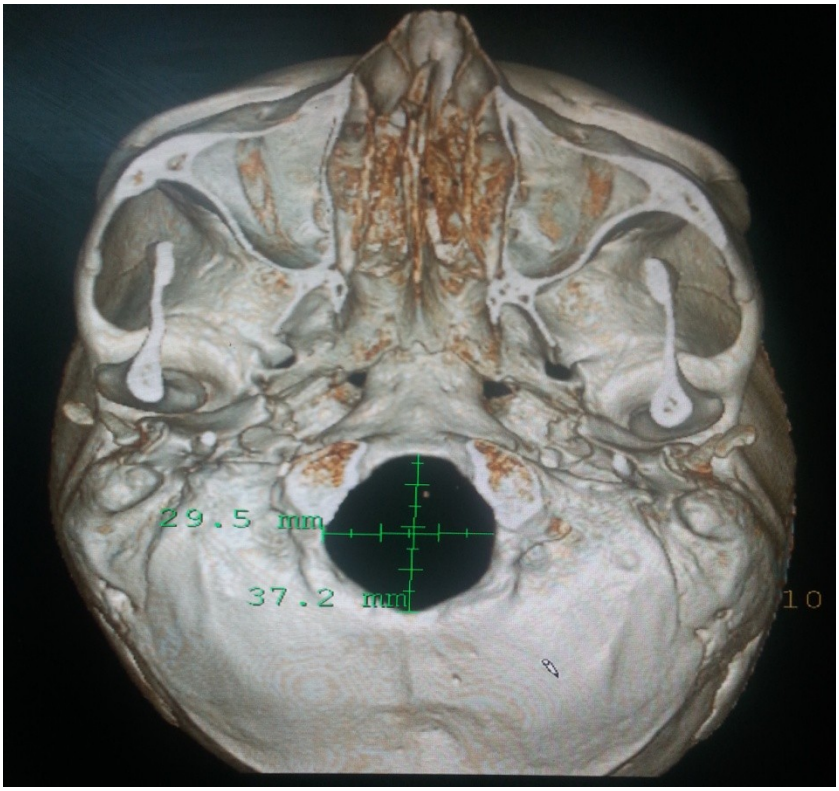

Figure2: 50y mail his FM measurement LFM 37.2 and WFM 29.5

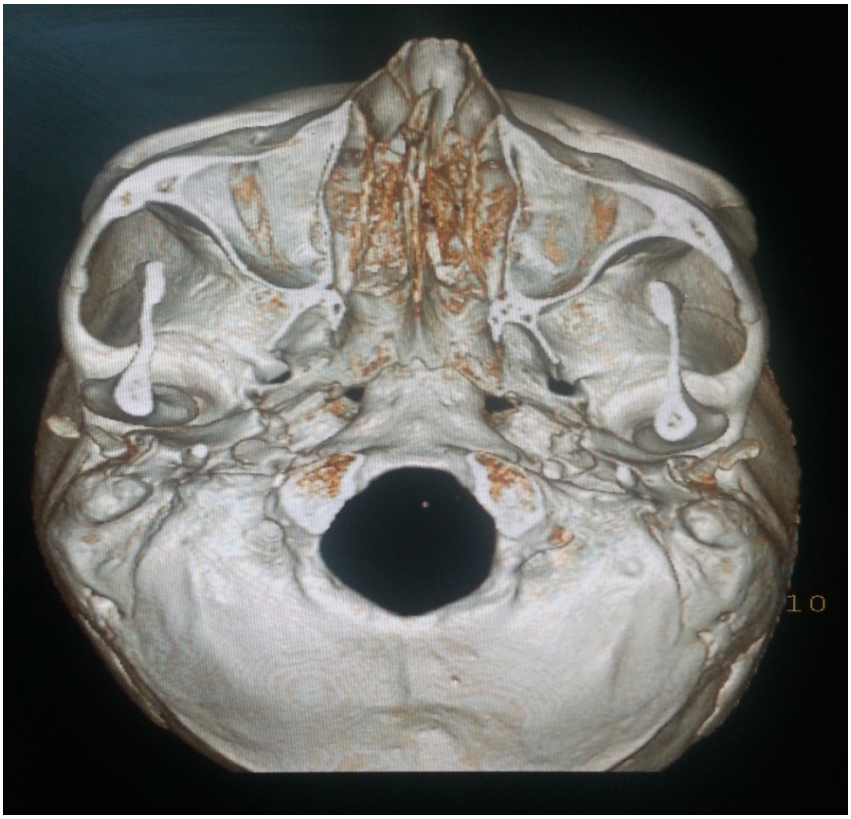

Figure3: 25y female have FM round in shape

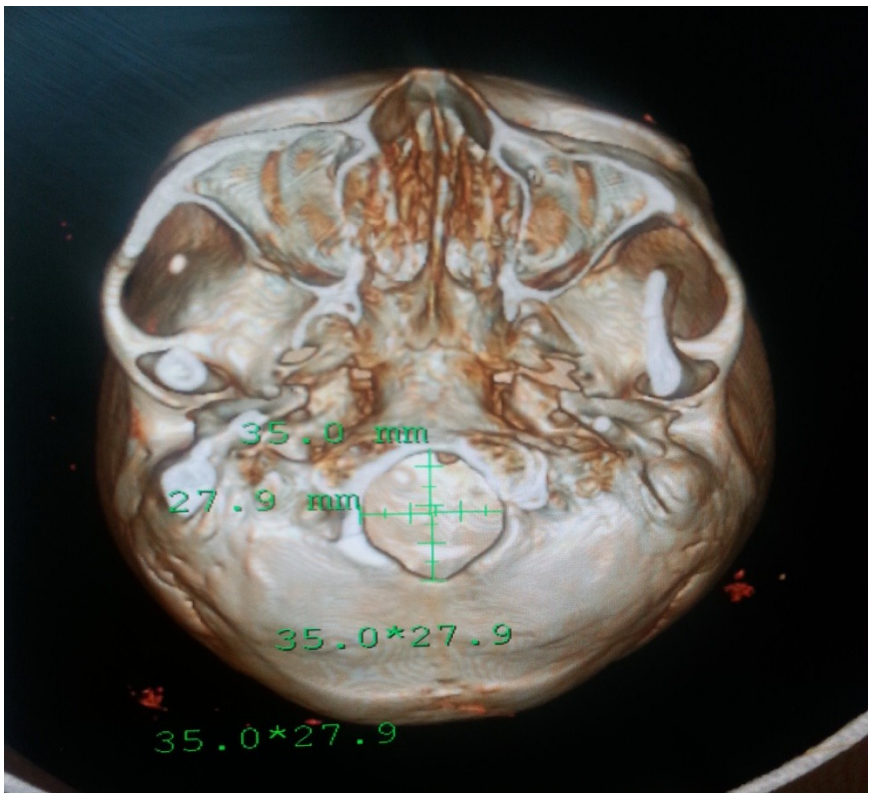

Figure4: 49y female her FM measurement is LFM 37.2 and WFM 29.5

DATA COLLECTION SHEET

NO.	gender	Age	LFM	WFM	Shape
1					
2					
3					
4					
5					
6					
7					
8					
9					
10					