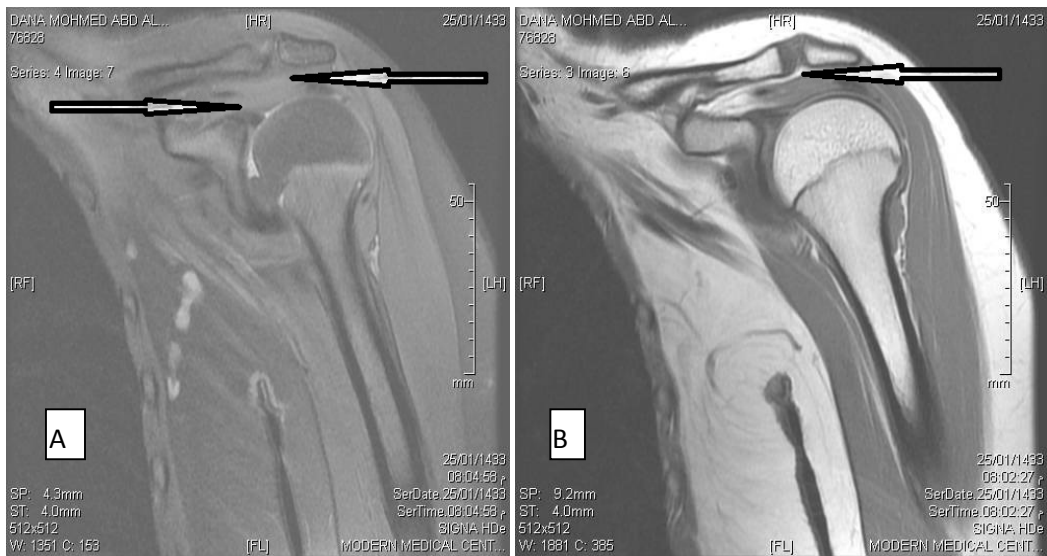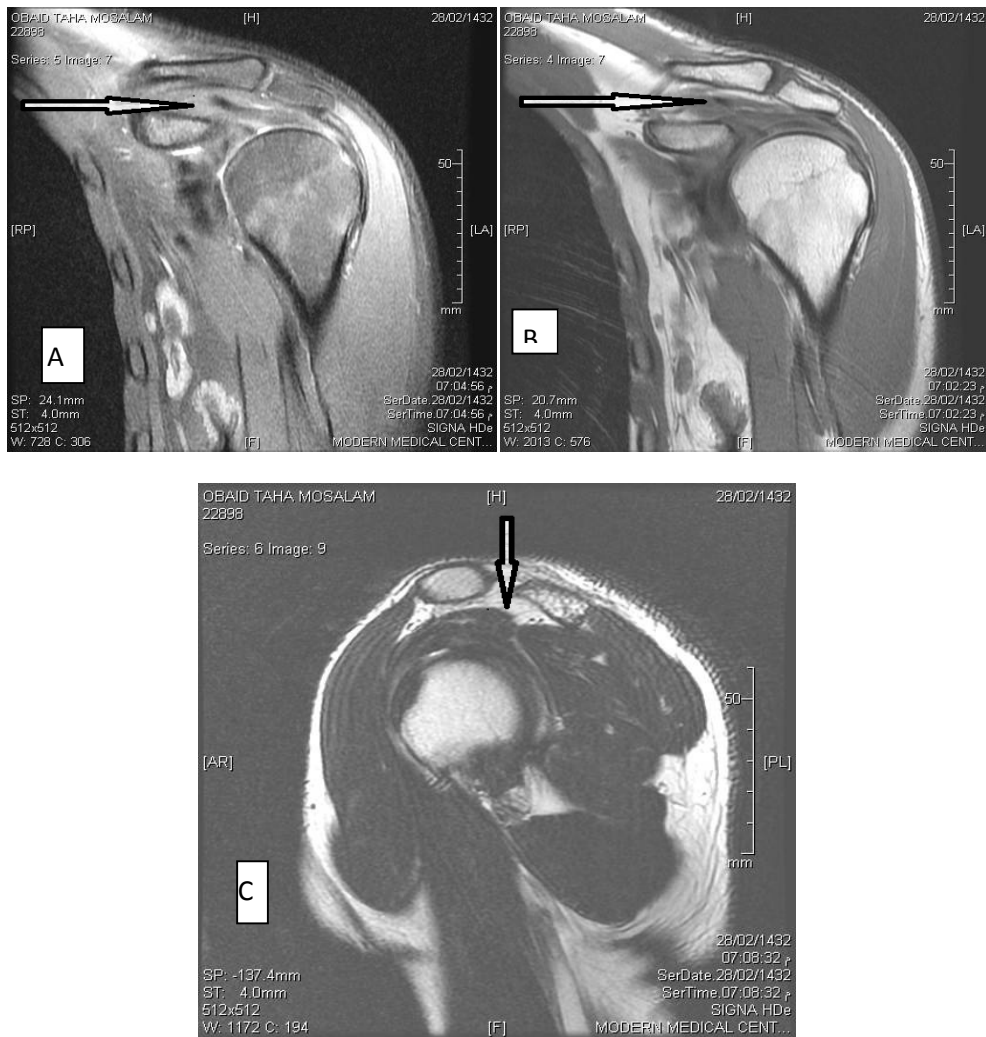


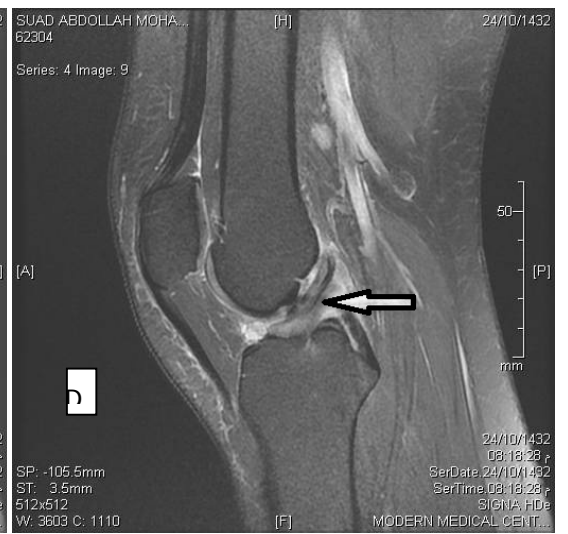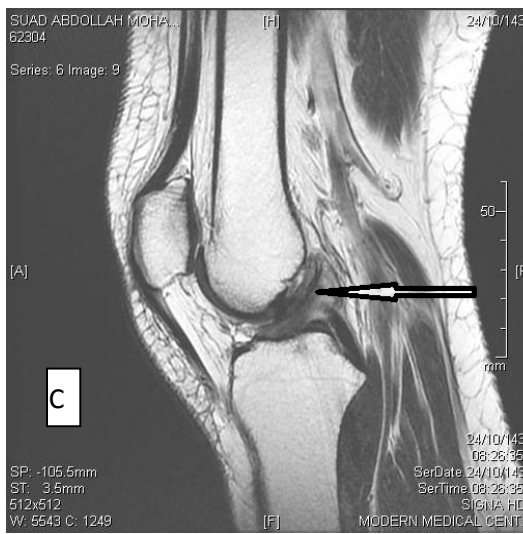
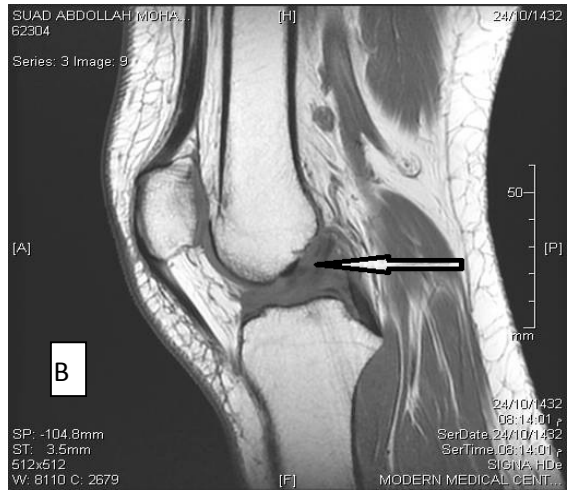
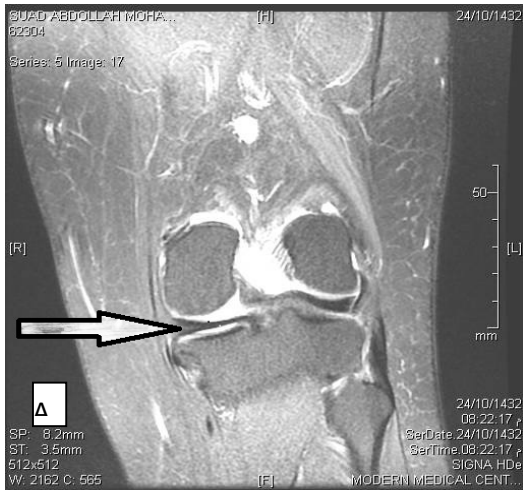




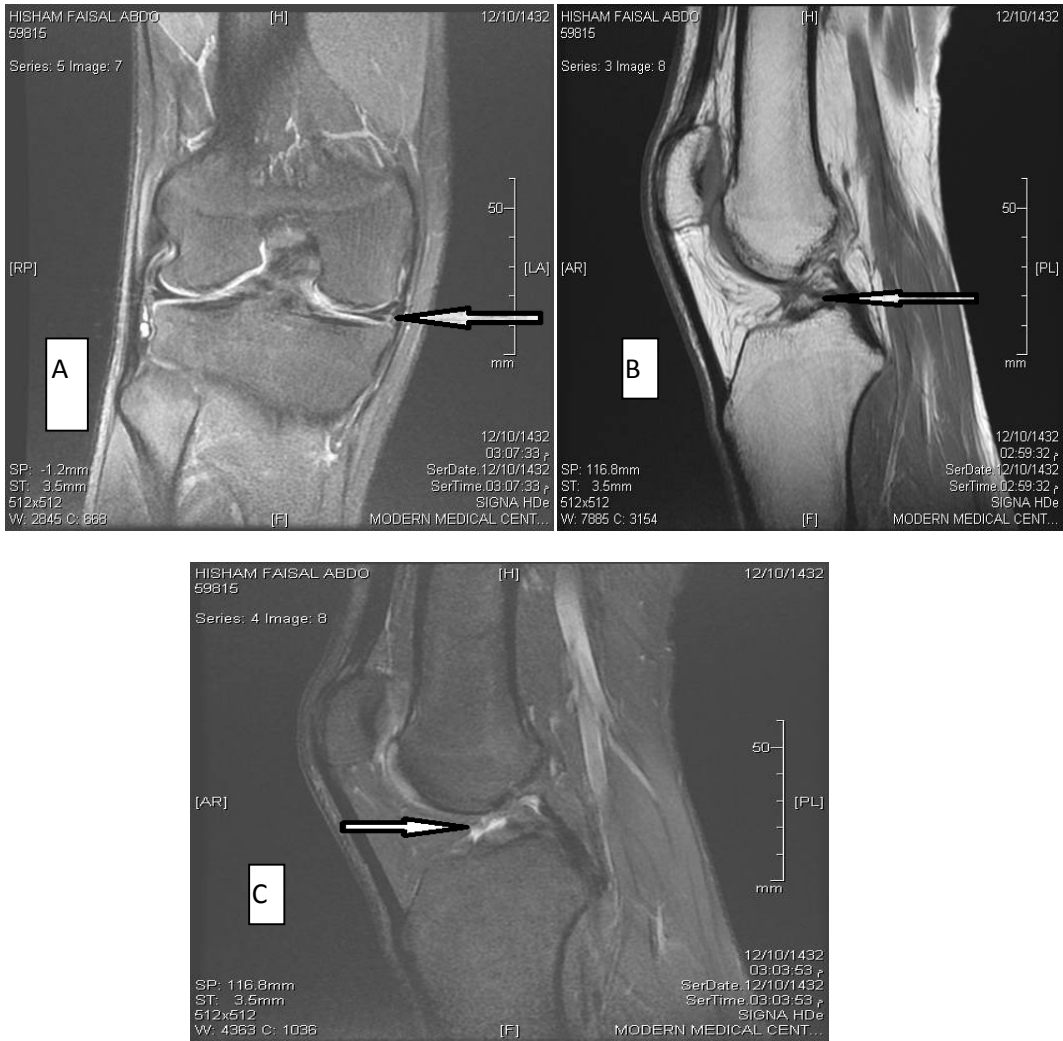
Appendix(2):female 16 years old Left shoulder showing in(A): coronal PD fat sat Rotator cuff Tear(SST)(Lt arrow) & anterior glenoid labrum torn(Bankrt legion) (Rt arrow) ((B): coronal T1 FSE Rotator cuff Tear(SST)with Synovil effusion (arrow)



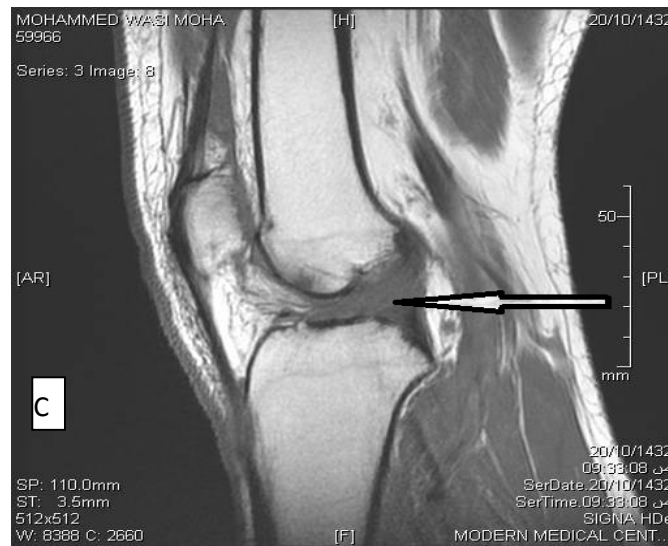
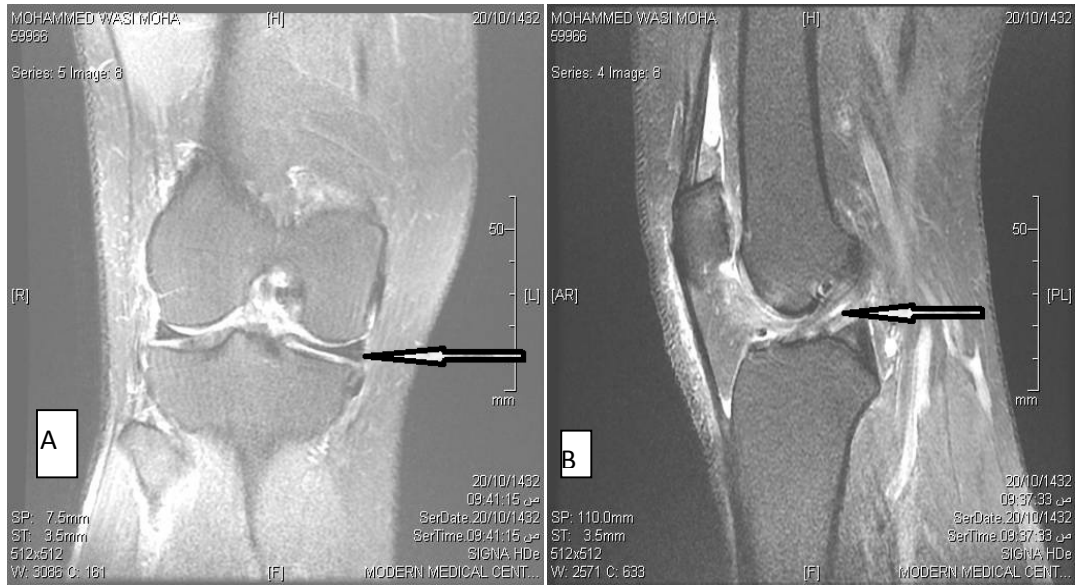Appendix(3):male 29 years old Left shoulder showing in(A): coronal PD fat sat Rotator cuff Tear(SST) (arrow) ((B): coronal T1 FSE Rotator cuff Tear(SST) (arrow)(C): SagittalT2 trFSE Rotator cuff Tear(SST)(arrow)



Appendix(4):female 37 years old Left knee showing in(A): coronal PD fat sat FSE Medial meniscal tear grade II (arrow) ((B): sagittal T1SE ACL partial tear(arrow)(C): SagittalT2 trFSE ACL partial tear (arrow) (D): sagittal PD fat sat FSE ACL partial tear (arrow)



Appendix(5):male 19 years old Right knee showing in(A): coronal PD fat sat FSE Medial meniscal tear grade III (arrow) ((B): sagittal T1SE ACL complete tear(arrow)(C): sagittal PD fat sat FSE ACL complete tear (arrow)



Appendix(6):male 59 years old Right knee showing in(A): coronal PD fat sat FSE Medial meniscal tear grade II (arrow) (B): sagittal PD fat sat FSE ACL partial tear (arrow) (C): sagittal T1SE ACL partial tear(arrow)

