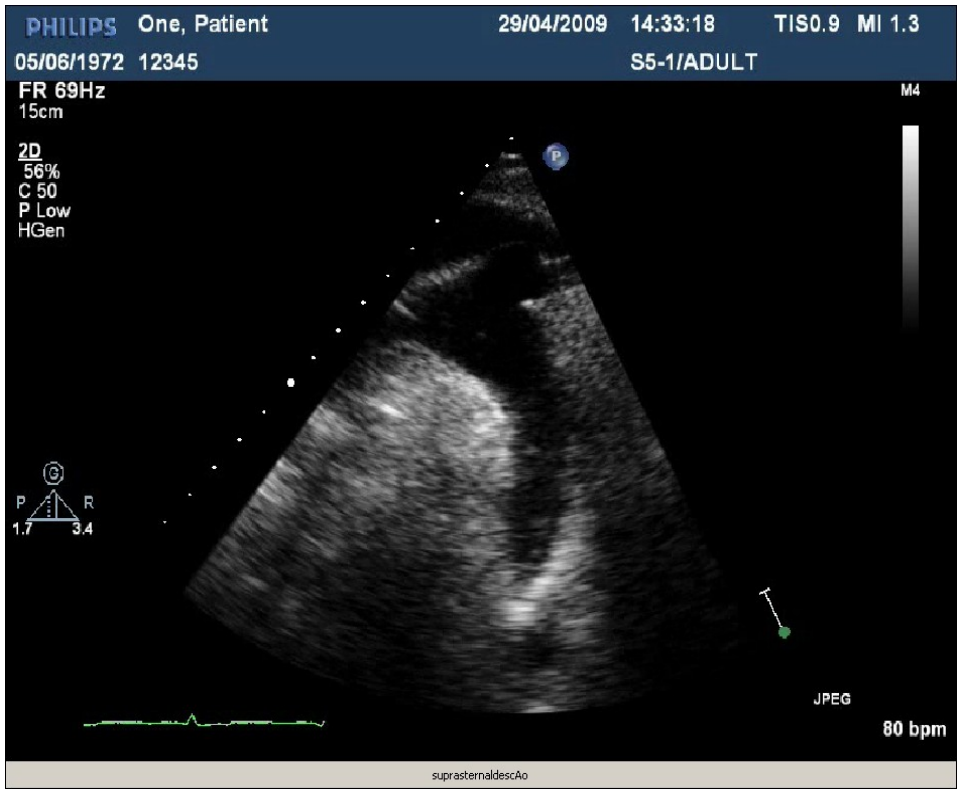

Chapter one

: Introduction-1

An echocardiogram is a scan which gives a detailed view of the structures of the heart, and which can show how well heart is working , the scan uses a probe that sends out sound waves, which are reflected back by the muscles and tissues in the heart. These reflected waves are picked up by the probe and translated into images on a screen.

((Paul Leeson and et al 2007

Echocardiograms can show if the heart is working as well as it should. they are particularly useful for revealing if heart have an enlarged left side or problems with the heart valves. They can also be used to investigate the causes and effects of heart murmurs and heart attacks . An echocardiogram is a painless test that takes roughly 20-25 minutes. It can be carried out in one of two ways. if the sonographer is looking for an enlarged heart muscle or

heart valve problems, the probe is normally placed on the chest , Lubricating jell will be put on chest and a small probe will be moved around on the chest, moving the probe around will give different views of the heart, if the sonographer is looking for more detailed information about how heart is working, a small probe will be passed down on throat so that it lies behind the heart , this means that the sonographer will have a much clear view, patient will receive a sedative and/or local anaesthetic for this procedure, but it should not require an overnight stay in hospital , the probe is going to be placed on patient chest, patient do not need to do anything beforehand (no preparation),this can be helpful to investigate the heart condition of hypertensive patients. Hypertension or Arterial blood pressure is "normal" when the systolic pressure is(90-119) mmHg and the diastolic pressure is 60-79 mmHg. When the arterial pressure is ≥120/80 mmHg, a person is said to be prehypertensive or hypertensive. Mean arterial pressure is also elevated in hypertension, but it is not usually measured in people. In past years, the diastolic value was emphasized in assessing hypertension. However, elevations in systolic pressure ("systolic hypertension") are also associated with increased incidence of coronary and cerebrovascular disease (e.g., stroke). Therefore, now recognize that both systolic and diastolic pressure values are important to note. According to U.S. national guidelines (JNC 7 Report and JNC 8 Report), the following represents (different stages of hypertension. **(Paul A & et al 2014**

: Statement of the proplem -1-2

Hypertension is a disease that affect heart espically left ventricle so that patients have hypertension need follow-up to this important organ s , this study to assess the

effect of hypertension in the left ventricle using ultrasound
. as safety as available good diagnosis

: Research Objectives 1-3

: General objective 1-3-1

To assess the left ventricle of the heart in hypertensive patients using ultrasound (echocardiography).

: Specific objectives 1-3-2

- To asses left ventricle hypertrophy in hypertensive patients.
- To assess the different in left ventricular ejection fraction in hypertensive patients .
- To descript the relation between LVH and duration time of disease in hypertensive patients .

: Significant of the study 1-4

The study help in early diagnosis of heart (LV) changes in hypertensive patients to avoid any complications lead to heart attack .

: overview of the study -1-5

- .**Chapter one** : Introduction and objectives
- **Chapter two** : literature review , anatomy and physiology of the heart , pathology in hypertensive patient ,and normal sonographic appearance of heart , others Imaging modalities .
- . **Chapter three :** Materials and methods
- . **Chapter four :** Results presentation
- **Chpter five** : Discussion , Conclusion and Recommendations as well as Referanses used in this research .

Chapter two

((Literature review

: Anatomy of the heart 2-1

The heart weighs between 7 and 15 ounces (200 to 425 grams) and is a little larger than the size of your fist. By the end of a long life, a person's heart may have beat (expanded and contracted) more than 3.5 billion times. In fact, each day, the average heart beats 100,000 times, , pumping about 2,000 gallons (7,571 liters) of blood

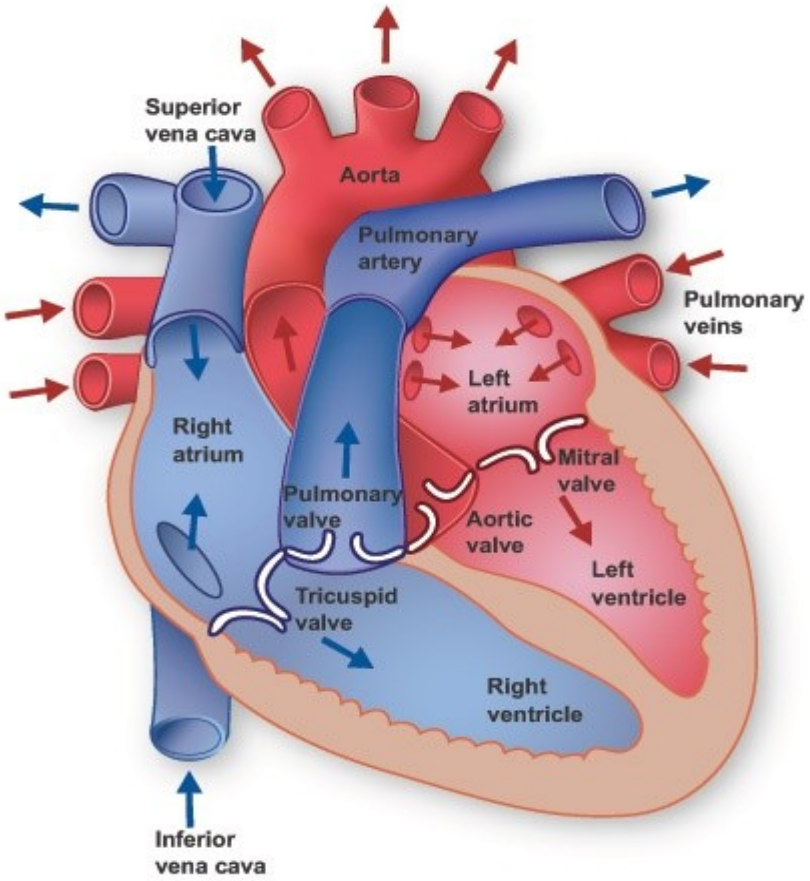

FIG (2-1) coronal section of the heart showing heart chamber , valves and greater vessels . (Peter libby , et-al (1997

The heart is located between the lungs in the middle of chest, behind and slightly to the left of the breastbone (sternum). A double-layered membrane called the pericardium surrounds the heart like a sac. The outer layer of the pericardium surrounds the roots of the heart's major blood vessels and is attached by ligaments to the spinal column, diaphragm, and other parts of the body. The inner layer of the pericardium is attached to the heart muscle. A coating of fluid separates the two layers of .membrane, letting the heart move as it beats

The heart has 4 chambers. The upper chambers are called the left and right atria, and the lower chambers are called the left and right ventricles. A wall of muscle called

the septum separates the left and right atria and the left and right ventricles. The left ventricle is the largest and strongest chamber in the heart. The left ventricle's chamber walls are only about a half-inch thick, but they have enough force to push blood through the aortic valve (and into the human body . **(Michael Ronaldo 1976**

: 2-1-1The Heart Valves

Four valves regulate blood flow through your heart, the tricuspid valve regulates blood flow between the right ,atrium and right ventricle

the pulmonary valve controls blood flow from the right ventricle into the pulmonary arteries, which carry blood to ,your lungs to pick up oxygen

the mitral valve lets oxygen-rich blood from your lungs pass from the left atrium into the left ventricle , the aortic valve opens the way for oxygen-rich blood to pass from the left ventricle into the aorta, the body's largest artery . (**(Michael Ronaldo 1976**

: Blood supply to the heart 2-1-2

Coronary circulation is the circulation of blood in the blood vessels of the heart muscle (myocardium). The vessels that deliver oxygen-rich blood to the myocardium are known as coronary arteries. The vessels that remove the deoxygenated blood from the heart muscle are known as cardiac veins. These include the great cardiac vein, the middle cardiac vein, the small cardiac vein and .the anterior cardiac veins

As the left and right coronary arteries run on the surface of the heart, they can be called epicardial coronary arteries. These arteries, when healthy, are capable of

autoregulation to maintain coronary blood flow at levels appropriate to the needs of the heart muscle. These relatively narrow vessels are commonly affected by atherosclerosis and can become blocked, causing angina or a heart attack .The coronary arteries that run deep within the myocardium are referred to as .subendocardial

The coronary arteries are classified as "end circulation", since they represent the only source of blood supply to the myocardium; there is very little redundant blood supply, which is why blockage of these vessels can be so critical . ((**Michael Ronaldo 1976**

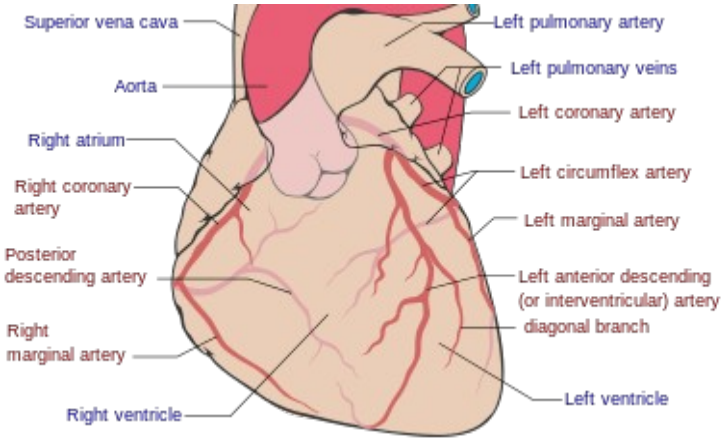

Figer (2-2) shows blood vessels that supply heart.

((**Michael Ronaldo 1976**

: Physiology of the heart 2-2

The normal heart is a strong muscle that beats about 100,000 times a day to pump blood through the body. The blood carries oxygen and nutrients to tissues and organs and waste products to the kidneys and liver. The blood travels through a large network of blood vessels known as the circulatory system. This system includes the arteries, veins, and lungs. The heart responds to the body’s needs

and adjusts its rate of pumping to meet the body's requirements. The heart consists of four chambers that work together . Right and left atria – these are the small upper chambers . Right and left ventricles – these are the larger, lower chambers. The right ventricle pumps blood out of the heart to the lungs, and the left ventricle pumps blood to the rest of the body. The left ventricle is the heart's main pumping chamber. Blood Flow During each heartbeat, the right side of the heart receives blood from your body and then sends it to the lungs to pick up oxygen. The left side of the heart receives the blood from the lungs and then sends the blood to the rest of the body to deliver oxygen . How the Heart's Electrical System Works The heart has an electrical system that causes it to beat and pump blood in a smooth and regular way . Special cells in the heart start electrical signals, these signals then travel along pathways through the heart and cause it to beat. During a normal heartbeat, an electrical signal is first made in a group of cells called the sinus node (SA node). The signal then spreads like a wave through both of the upper chambers of the heart (the atria) and travels to another group of cells called the atrioventricular node (AV node). The AV node serves as an electrical filter between the upper and lower chambers (ventricles) of the heart. After a pause, the electrical signal spreads through the ventricles. In a healthy heart, the heart beats once and pumps blood for each electrical signal that starts in the SA node. A normal heart rate is generally between 60 and 100 beats per minute, but will vary based on age and how active a person is .**(Michael**

(**Ronaldo 1976**

A single cardiac cycle of cardiac activity can be divided into two basic phases diastole and systole : diastole represents the period of time when the ventricles are relaxed (not contracting).Throughout most of this period, blood is passively flowing from the left atrium (LA) and

right atrium (RA) into the left ventricle (LV) and right ventricle (RV), respectively. The blood flows through atrioventricular valves (mitral and tricuspid) that separate the atria from the ventricles. The RA receives venous blood from the body through the superior vena cava (SVC) and inferior vena cava (IVC). The LA receives oxygenated blood from lungs through four pulmonary veins that enter the LA. At the end of diastole, both atria contract, which propels an additional amount of blood into the ventricles.

((Michael Ronaldo 1976

Systole represents the time during which the left and right ventricles contract and eject blood into the aorta and pulmonary artery, respectively. During systole, the aortic and pulmonic valves open to permit ejection into the aorta and pulmonary artery. The atrioventricular valves are closed during systole, therefore no blood is entering the ventricles; however, blood continues to enter the atria though the vena cava and pulmonary veins. uncontrolled high blood pressure (HTN) can damage your heart in a number of ways, such as hinder the movement of blood through the chambers of the heart , Coronary artery disease , Enlarged left heart and Heart failure .**(Michael**

(Ronaldo 1976

The cardiovascular system is made up of : heart; lungs;

arteries and veins, and it is under the control of the autonomic nervous system (sympathetic and parasympathetic). In a healthy individual with a healthy heart, heart rate is dictated by the body's needs. If an individual is resting then organs, muscles and tissues require a reduced amount of blood and oxygen . **(Michael**

(Ronaldo 1976

When the individual becomes active then the organs,

muscles and tissues require an increasing amount of blood

and oxygen, resulting in raised blood pressure and an increase in heart rate and respirations. These responses are all involuntary, under the direct control of the autonomic nervous system. If the individual remains reasonably healthy with no cardiac complications then the cardiovascular system will continue to work just like this

(for life. **(Michael Ronaldo 1976**

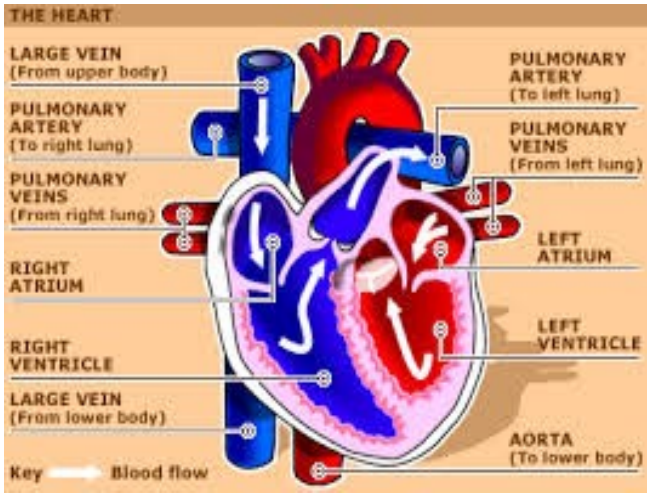

Fig 2-3 shows circulation of blood in heart.

((Michael Ronaldo 1976

: Pathology of heart 2-3

Heart disease, any disorder of the heart. Examples include coronary heart disease, congenital heart disease, and pulmonary heart disease, as well as rheumatic heart disease , hypertension, inflammation of the heart muscle (myocarditis) or of its inner or outer membrane (endocarditis , pericarditis), and heart valve disease. Abnormalities of the heart's natural pacemaker or of the nerves that conduct its impulses cause arrhythmias. Some connective tissue diseases (notably systemic lupus erythematosus, rheumatoid arthritis, and scleroderma) can

.affect the heart. Heart failure may result from many of these disorders

: Coronary heart disease 2-3-1

Also called coronary artery disease or ischemic heart disease ,

disease characterized by an inadequate supply of oxygen-

rich blood to the heartmuscle (myocardium) because of narrowing or blocking of a coronary artery by fatty plaques . If the oxygen depletion is extreme, the effect may be a myocardial infarction (heart attack). If the deprivation is insufficient to cause infarction (death of a section of heartmuscle), the effect may be angina pectoris (pain or discomfort in the chest). Both conditions can be fatal because they can lead to heart failure or ventricular fibrillation. The latter, characterized by an uncontrolled and uncoordinated contraction of the ventricles (the lower chambers of the heart), can induce sudden death. ((Douglas L.Mann MD 2014

A variety of risk factors have been associated with coronary heart disease; examples include high blood pressure, elevated blood cholesterol levels, smoking, obesity, diabetes, unhealthy diet, and family history of early coronary heart disease (i.e., diagnosed in middle age). Individuals with hereditary conditions such as familial hypercholesterolemia (a disorder in which the body's tissues are incapable of removing cholesterol from the .bloodstream) also are at increased risk

Coronary artery bypass surgery (also known as coronary artery bypass grafting) or angioplasty may be necessary if medications and diet and lifestyle changes, such as frequent exercise and cessation of smoking, are not (effective . (Douglas L.Mann MD 2014

: (Left Ventricular Hypertrophy (LVH 2-3-2

Left ventricular hypertrophy (LVH) is a condition in which the muscle wall of heart's left pumping chamber (ventricle) becomes thickened (hypertrophy), other conditions, such as heart attack, valve disease and dilated cardiomyopathy, can cause the heart (or the heart cavity)

to get bigger. This is not the same as LVH (Douglas L.Mann MD 2014).

Causes of LVH , the heart is a muscle. And so, like other muscles, it gets bigger if it is worked hard over time. Several health conditions cause your heart to work harder than normal. The most common cause of LVH is high blood pressure (hypertension). Other causes include athletic hypertrophy (a condition related to exercise), valve disease, hypertrophic cardiomyopathy (HOCM), and congenital heart disease.

Some patients have no symptoms related to LVH. The condition usually develops over time, and most symptoms occur when the condition causes complications. The most common symptoms of LVH are, Feeling short of breath ,Chest pain, especially after activity ,Feeling dizzy or fainting ,Rapid heartbeat, or a pounding or fluttering sensation in the chest **.**(Douglas L.Mann MD 2014)

Left ventricular hypertrophy may be first noticed on an electrocardiogram . If the doctor sees evidence of LVH on the ECG, that will have an echocardiogram to determine if patient have the condition.

An echocardiogram is the most common way to determine if a patient has LVH. This test allows the doctor to measure the walls of the ventricle. A measurement greater than 1.5 cm is considered enlarged. Patients with athletic hypertrophy usually have a measurement less than 1.5 cm, and the wall returns to normal size after exercising. If you do not have any of the typical causes of LVH and have a family history of HOCM, your doctor may determine that you have HOCM, **LVH** caused by high blood pressure is treated by controlling your blood pressure. This is done with lifestyle changes and medications, when needed.

There is ongoing debate about whether some medications for high blood pressure can cause LVH to improve. ((Douglas L.Mann MD 2014

: Valvular heart disease 2-3-3

Valvular heart disease is characterized by damage to or a defect in one of the four heart valves: the mitral, aortic, .tricuspid or pulmonary

The mitral and tricuspid valves control the flow of blood between the atria and the ventricles (the upper and lower chambers of the heart). The pulmonary valve controls the flow of blood from the heart to the lungs, and the aortic valve governs blood flow between the heart and the aorta, and thereby the blood vessels to the rest of the body. The mitral and aortic valves are the ones most frequently affected by valvular heart disease. (Douglas L.Mann MD (2014

Normally functioning valves ensure that blood flows with proper force in the proper direction at the proper time. In valvular heart disease, the valves become too narrow and hardened (stenotic) to open fully, or are unable to close .(completely (incompetent) (Douglas L.Mann MD 2014

A stenotic valve forces blood to back up in the adjacent heart chamber, while an incompetent valve allows blood to leak back into the chamber it previously exited. To compensate for poor pumping action, the heart muscle enlarges and thickens, thereby losing elasticity and efficiency. In addition, in some cases, blood pooling in the chambers of the heart has a greater tendency to clot, increasing the risk of stroke or pulmonary embolism .((Douglas L.Mann MD 2014

The severity of valvular heart disease varies. In mild cases there may be no symptoms, while in advanced cases, valvular heart disease may lead to congestive heart failure and other complications. Treatment depends upon the extent of the disease,

Valve disease symptoms can occur suddenly, depending upon how quickly the disease develops. If it advances slowly, then your heart may adjust and you may not notice the onset of any symptoms easily. Additionally, the severity of the symptoms does not necessarily correlate to the severity of the valve disease. That is, you could have no symptoms at all, but have severe valve disease. Conversely, severe symptoms could arise from even a small valve leak, many of the symptoms are similar to those associated with congestive heart failure, such as shortness of breath and wheezing after limited physical exertion and swelling of the feet, ankles, hands or abdomen (edema). Other symptoms including Palpitations, chest pain (may be mild)Fatigue. Dizziness or fainting (with aortic stenosis) Fever (with bacterial endocarditis) Rapid weight gain . (Douglas L.Mann MD (2014

There are many different types of valve disease; some types can be present at birth (congenital), while others may be acquired later in life heart valve tissue may degenerate with age rheumatic fever may cause valvular heart disease. Bacterial endocarditis, an infection of the inner lining of the heart muscle and heart valves (endocardium), is a cause of valvular heart disease.High blood pressure and atherosclerosis may damage the aortic valve. A heart attack may damage the muscles that control the heart valves. Other disorders such as carcinoid tumors, rheumatoid arthritis, systemic lupus erythematosus, or syphilis may damage one or more heart valves. Methysergide, a medication used to treat migraine

headaches, and some diet drugs may promote valvular heart disease. Radiation therapy (used to treat cancer) may be associated with valvular heart disease . (Douglas L.Mann MD 2014)

2-3-4 Heart Failure :

The term "heart failure" makes it sound like the heart is no longer working at all and there's nothing that can be done. Actually, heart failure means that the heart isn't pumping as well as it should be(Douglas L.Mann MD 2014).

Your body depends on the heart's pumping action to deliver oxygen- and nutrient-rich blood to the body's cells. When the cells are nourished properly, the body can function normally.

With heart failure, the weakened heart can't supply the cells with enough blood. This results in fatigue and shortness of breath and some people have coughing. Everyday activities such as walking, climbing stairs or carrying groceries can become very difficult.(Douglas L.Mann MD 2014)

2-3-4-1 The Progression From Hypertension to Congestive Heart Failure :

Hypertension was the most common risk factor for chronic heart failure (CHF), and it contributed a large proportion of heart failure cases in this population-based sample. Preventive strategies directed toward earlier and more aggressive blood pressure control are likely to offer

the greatest promise for reducing the incidence of CHF (and its associated mortality. (Simon 2013

: Diastolic dysfunction 2-3-5

Diastolic dysfunction refers to an abnormality in how the heart fills with blood during diastole. The heart muscles do not relax in a normal manner and the heart may fill too slowly, asynchronously or with an elevation in filling pressure only , there are two phases in a heartbeat or a cardiac cycle. Systole refers to when the heart muscles squeeze to compress the heart and pump blood into the arteries and diastole is the phase where the heart expands in order to allow blood in to fill the ventricles.diastolic dysfunction ,blood from the lungs is carried into the left ventricle by the pulmonary vein and blood from other parts of the body is carried into the right ventricle. When the heart is functioning normally, blood from the lungs passes into the left atrium via the pulmonary vein and into the left ventricle. However, if the ventricle wall does not relax properly or is thick and stiff, the ventricle does not fill in the usual manner and blood is drawn back into the (atrium and eventually into the lungs. (Simon 2013

The abnormal stiffening of the ventricular wall and subsequent inadequate ventricular filling is referred to as diastolic dysfunction and when this leads to blood building up in other organs such as the lungs, diastolic heart failure (is diagnosed. (Simon 2013

This diastolic dysfunction raises the pressure gradient of blood in the pulmonary vessels (PHTN), which causes fluid or transudate to leak from these vessels into the lung alveoli, causing pulmonary edema. This condition impairs oxygenation of blood in the lungs, causing shortness of

breath and even death if the condition is not detected and treated promptly. (Simon 2013)

2-3-6 Systolic dysfunction :

Systolic dysfunction is characterized by a decrease in myocardial contractility. A reduction in the left ventricular ejection fraction (LVEF) results when myocardial contractility is decreased throughout the left ventricle. Cardiac output is maintained in two ways: left ventricular enlargement results in a higher stroke volume, and the Frank-Starling relationship (an increase in contractility in response to an increase in stretch). However, these compensatory mechanisms are eventually exceeded and cardiac output decreases, resulting in the physiologic manifestations of heart failure , the left heart cannot pump with enough force to push a sufficient amount of blood into the systemic circulation. This leads to fluid backing up into the lungs and pulmonary congestion. Systolic dysfunction is a characteristic of dilated cardiomyopathy (DCM). It is also seen in some patients with hypertrophic cardiomyopathy (HCM) who develop progressive left ventricular dilatation and a decrease in LVEF. In general terms, systolic dysfunction is defined as an LVEF less than 40% .(Simon 2013)

2-3-7 Myocardial ischemia :

Myocardial ischemia occurs when blood flow to your heart is reduced, preventing it from receiving enough oxygen. The reduced blood flow is usually the result of a partial or complete blockage of your heart's arteries (coronary arteries).

Myocardial ischemia, also called cardiac ischemia, can damage your heart muscle, reducing its ability to pump efficiently. A sudden, severe blockage of a coronary artery

can lead to a heart attack. Myocardial ischemia might also .cause serious abnormal heart rhythms

Treatment for myocardial ischemia involves improving blood flow to the heart muscle. Treatment may include medications, a procedure to open blocked arteries or .bypass surgery

Making heart-healthy lifestyle choices is important in treating and preventing myocardial ischemia , (Simon (2013

2.3.8 : Cardiomyopathy

Is a condition where the heart muscle is abnormal. The

main types of cardiomyopathy include dilated, hypertrophic and restrictive cardiomyopathy. Cardiomyopathy makes it harder for your heart to pump and deliver blood to the rest of your body. Cardiomyopathy can lead to heart failure ,symptoms of cardiomyopathy in the early stages, people with cardiomyopathy may not have any signs and symptoms. But as the condition advances, signs and symptoms usually appear. Cardiomyopathy signs and symptoms may include ,breathlessness with exertion or even at rest ,swelling of the legs, ankles and feet ,bloating of the abdomen due to fluid buildup ,cough while lying down ,fatigue ,irregular heartbeats that feel rapid, pounding or fluttering ,chest pain And dizziness, lightheadedness and fainting (Simon . (2013

2-4 : Normal sonographic appearance of heart

At rest or stress echocardiogram at rest , this done by the following views parasternal views right or left

,apical views ,sub costal views ,suprasternal views and (transoesophageal views. (Bonita Anderson 2007

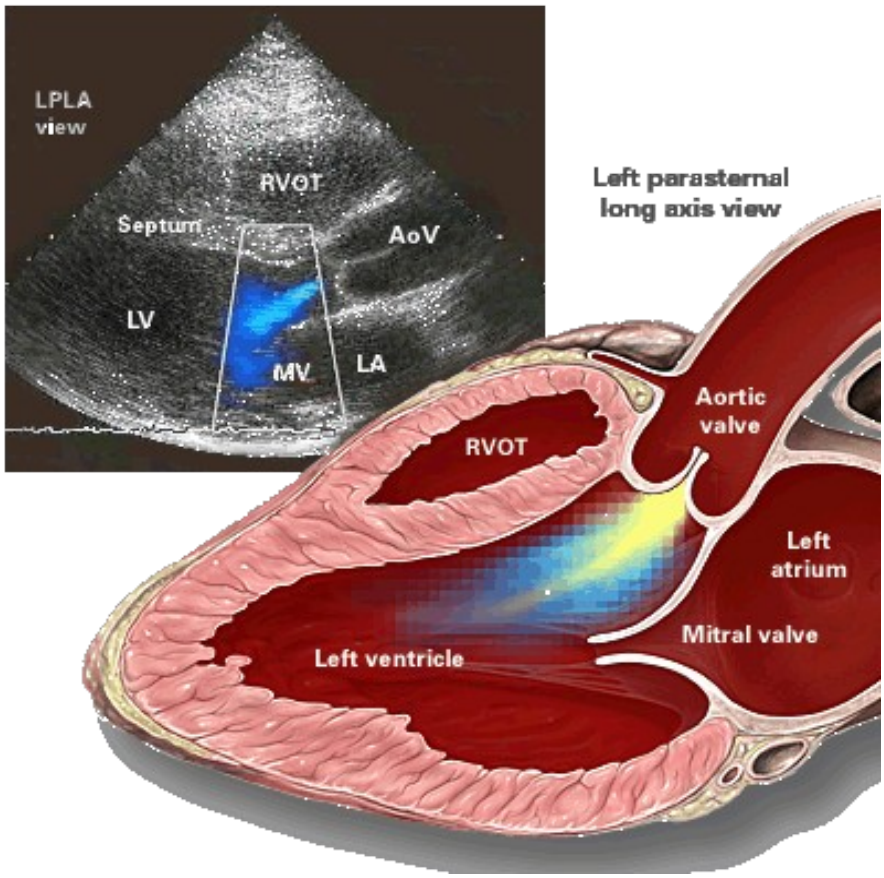

Fig 2-4 showing left parasternal view of heart. (Bonita (Anderson 2007

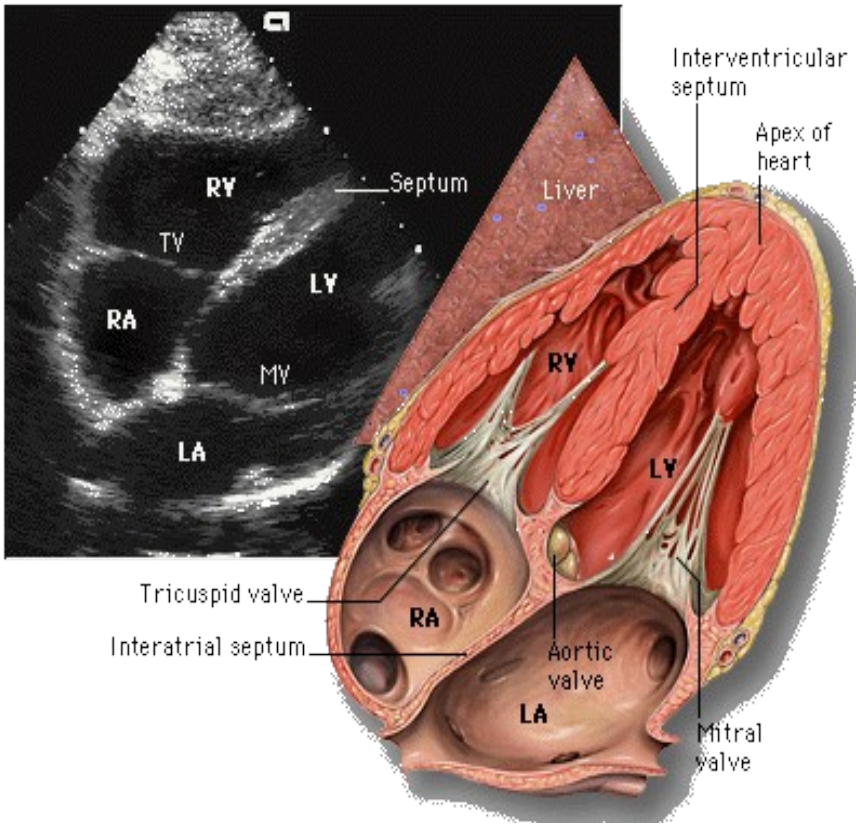

Fig 2-5 showing Sub–Costal view4Chamber (View(SC4CH) .(Bonita Anderson 2007

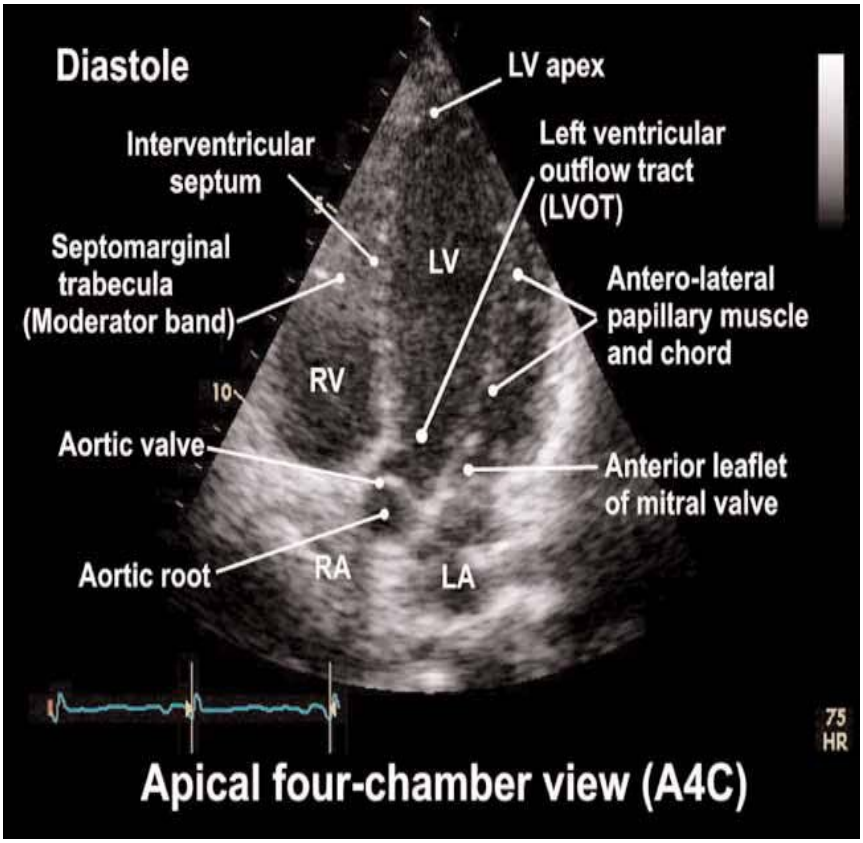

Fig 2-6 showing Apical four-chamber view. (Bonita

(Anderson 2007

Suprasternal View. Fig 2-7 showing image of echocardiography by

(Bonita Anderson 2007)

Normal cardiac measurement using M-MODE 2-4 : ECHO

: Parameter normal range 2-4-1

Table 2-1 Showing the normal parametal range of heart (structure. (Bonita Anderson 2007

Structure	Range
Aortic rote	mm 20-40
Lt atrium	19-40mm
LVDD	35-56mm
LVSD	22-40mm
IVS	6-11mm
LVPW	6-11mm
FS	30-40%
EF	55-75%

: Previous study 2-5

(Study(1

María A Martinez , etal 2003 their study conclude , 250 patients recently diagnosed with mild hypertension underwent clinical evaluation including electrocardiography (ECG), microalbuminuria measurement, 24-h blood pressure monitoring and ECHO. Level of cardiovascular risk was stratified, initially using

routine procedures including ECG to assess target organ .damage and then again after detection of LVH by ECHO

The result show The frequency of echocardiographic LVH was 32%, substantially higher than that detected by ECG (9%). Initial cardiovascular risk stratification yielded the following results: 30% low risk, 49% medium risk, 16% high risk, and 5% very high risk subjects. The detection of LVH by ECHO provoked a significant change in the risk strata distribution, particularly in those patients initially classified as being at medium risk. In this group, 40% of subjects were reclassified as high risk subjects according to ECHO information. The new classification was as follows: 23% low risk, 30% medium risk, 42% high risk, and 5% very high risk subjects.and their Conclusions show a substantial proportion of mildly hypertensive patients presenting in primary care have LVH determined by ECHO. There results suggest that this procedure could significantly improve cardiovascular risk stratification in those patients with multiple risk factors, but no evidence of target organ damage by routine investigations. Am J Hypertens 2003;16:556–563 @ 2003 American Journal of .Hypertension, Ltd

:(Study (2

Thomas H, etal 2015 their study conclude Hypertension remains a major contributor to the global burden of disease. The measurement of blood pressure continues to have pitfalls related to both physiological aspects and acute variation. As the left ventricle (LV) remains one of the main target organs of hypertension, and echocardiographic measures of structure and function carry prognostic information in this setting, the development of a consensus position on the use of echocardiography in this setting is important. Recent developments in the assessment of LV hypertrophy and LV systolic and diastolic function have prompted the

preparation of this document. The focus of this work is on the cardiovascular responses to hypertension rather than the diagnosis of secondary hypertension. Sections address the pathophysiology of the cardiac and vascular responses to hypertension, measurement of LV mass, geometry, and function, as well as effects of treatment .

Investigations done to diagnosis heart and left 2-5 : ventricle

: (Convential x-ray (Chest X Ray 2-5-1

A chest x ray creates pictures of the organs and structures inside the chest, such as heart, lungs, and blood vessels, a chest x ray can reveal signs of heart failure,left ventricle dilatation , as well as lung disorders and other causes of symptoms not related to chronic heart disease , a chest X-ray usually is taken after placement of such medical devices to make sure everything is positioned correctly like pacemaker leads(Jamie Weir et al 2003).

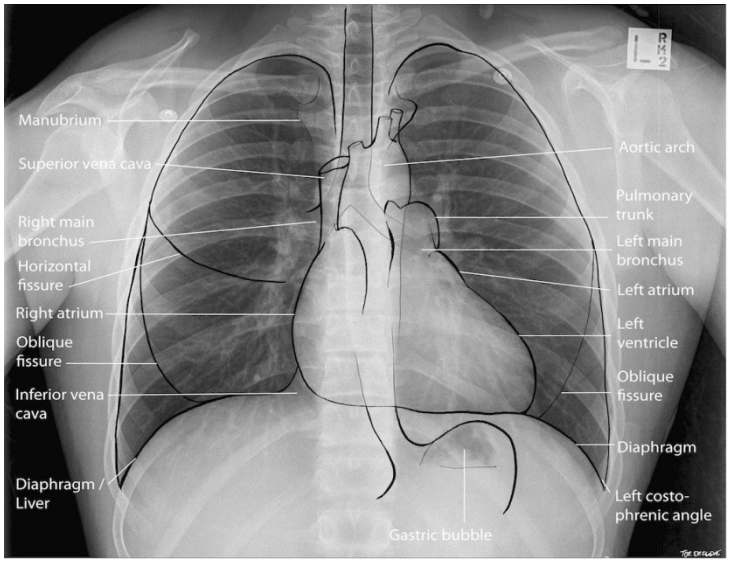

Figer 2-8 show normal structures of chest x-ray .((Jamie Weir et al 2003

2-5-2 Coronary Angiography and Cardiac Catheterization

The recommenation of coronary angiography if other tests or factors show that the patient likely to have CHD. This test uses dye and special x rays to show the insides of your coronary arteries. To get the dye into the coronary arteries that will use a procedure called cardiac catheterization , a thin, flexible tube called a catheter is put into a blood vessel in the patient arm, groin , or neck. The tube is threaded into your coronary arteries, and the dye is released into your bloodstream , Special x rays views are taken while the dye is flowing through the coronary arteries. The dye lets the doctor study the flow of blood through the heart and blood vessels, Cardiac catheterization usually is done in a hospital. Patient are awake during the procedure. It usually causes little or no .pain

Fig 2-9 shows the procedure of catheterization in groin (regon.(William E Brant MD and Clyde Helms MD2007

: Magnetic resonance imaging 2-5-3

MRI can help in diagnose many different heart conditions, includingTissue damage from a heart attack, reduced blood flow in the heart muscle to help determine whether heart artery blockages are the cause of your chest pain (angina) Problems in the aorta the heart's main artery such as a tear, aneurysm (bulge), or narrowing Diseases of the pericardium such as constrictive pericarditis , heart muscle diseases, such as heart failure or enlargement of the heart, and abnormal growths such as cancerous tumors , heart valve disorders, such as regurgitation, and congenital heart problems and the success of surgical repair .mri may be used instead of other tests that use ionizing radiation or iodine-containing contrast dyes, or both, such as X-ray, angiograms, computed tomography (CT) scans. Using MRI to look at blood vessels and how blood flows through them is called magnetic resonance angiography (MRA). Unlike a traditional X-ray angiogram,

this procedure doesn’t require inserting a catheter into the .patients arteries

MRI techniques can also be used to measure heart function or how much blood the left ventricle can pump .(out to the body. (Jamie Weir et al 2003

: Heart Disease and the Heart CT Scan 2-5-4

A heart computerized tomography (CT) scan, also called calcium-score screening heart scan, is a test used to detect calcium deposits found in atherosclerotic plaque in the coronary arteries of heart disease patients. State-of-the-art computerized tomography (CT) methods, such as this one, are the most effective way to detect coronary calcification fromatherosclerosis, before symptoms develop. More coronary calciummeans more coronary atherosclerosis, suggesting a greater likelihood of significant narrowing somewhere in the coronary system and a higher risk of future cardiovascular .problems

Using the calcium-score screening heart scan to evaluate .risk for future coronary artery disease

Because there are certain forms of coronary disease, such as "soft plaque" atherosclerosis, that escape detection during this CT scan, it is important to remember that this test is not absolute in predicting your risk for a life- .threatening event, such as a heart attack

Patient also may need a coronary CT angiogram (CTA) to look directly at the arteries of the heart. With the CTA, pictures of the coronary arteries are made. This is

regularly performed in addition to a heart CT scan now(Jamie Weir et al 2003).

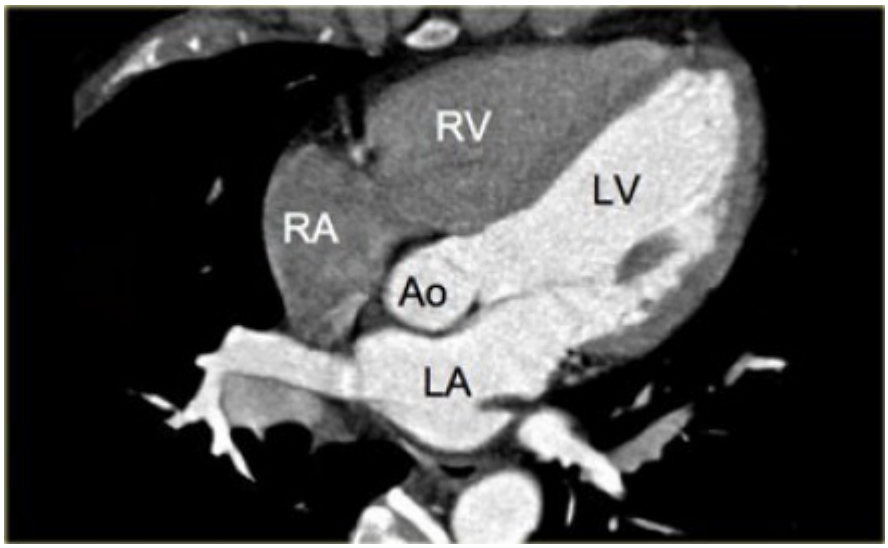

Fig(2-10) shows CT scan image 5- heart chamber view(Jamie Weir et al 2003).

: Echocardiography studies 2-5-5

Ultrasonography uses high-frequency (ultrasound) waves bounced off internal structures to produce a moving image. It uses no x-rays. Ultrasonography of the heart called **echocardiography** is one of the most widely used procedures for diagnosing heart disorders because it is noninvasive, harmless, relatively inexpensive, and widely available and because it provides excellent images. Ultrasonography is also used in the diagnosis of disorders affecting blood vessels in other parts of the body.

Echocardiography can be used to detect abnormalities in heart wall motion and to measure the volume of blood being pumped from the heart with each beat. This procedure can also detect abnormalities in the heart's structure, such as defective heart valves, birth defects, and enlargement of the heart's walls or chambers, as occurs in people with high blood pressure, heart failure, or impairment of the heart's muscular walls (cardiomyopathy). Echocardiography can also be used to

detect pericardial effusion, in which fluid accumulates between the two layers of the sac that envelops the heart (pericardium), and constrictive pericarditis, in which scar tissue forms throughout the pericardium. It also detects dissection of the aorta, a spontaneous tearing within the .(layers of the wall of the aorta (Susan K. DeWi, 2002

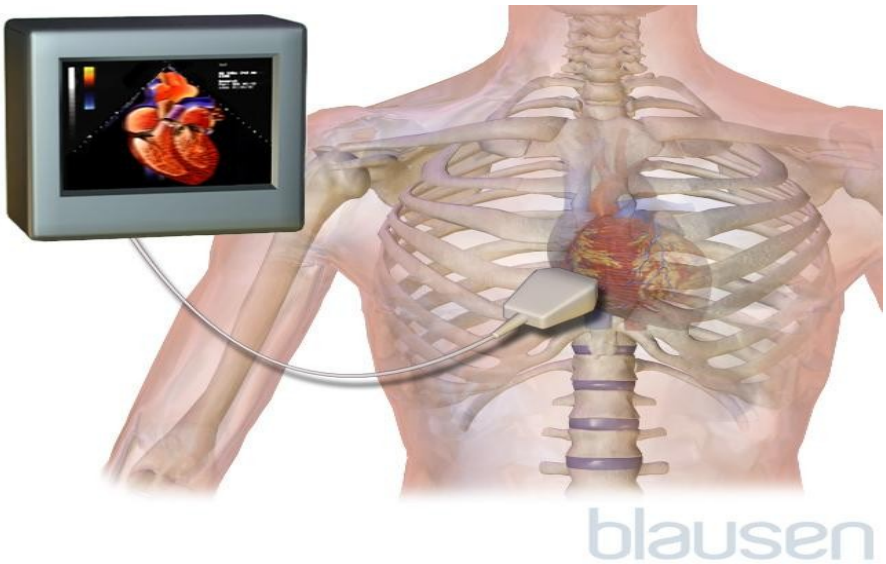

Fig 2-11 shows diagram how echo taken . (Susan K. DeWi, (2002

The main types of ultrasonography are two-dimensional, three-dimensional, Doppler, and color Doppler. Two-dimensional ultrasonography, the most widely used technique, produces realistic two-dimensional images in computer-generated "slices." Stacking the slices together .can re-create a three-dimensional structure

Doppler ultrasonography shows the direction and velocity of blood flow and thus can detect turbulent flow due to narrowing or blockage of blood vessels. Color Doppler ultrasonography shows the different rates of blood flow in different colors. Doppler ultrasonography and color Doppler ultrasonography are commonly used to help diagnose disorders affecting the heart and the arteries

and veins in the trunk, legs, and arms. Because these procedures can show the direction and rate of blood flow in the chambers and blood vessels of the heart, they enable sonographer to evaluate the structure and function of these parts. For example, sonographers can determine if the heart valves open and close properly, if and how much they leak when closed, and if blood flows normally. Abnormal connections between an artery and a .vein or between heart chambers can also be detected

The ultrasound waves are emitted by a probe that both emits and detects ultrasound waves (transducer). Most often, the transducer is handheld and placed on the chest over the heart. The examiner places gel on the chest under the transducer to help transmit the sound waves into the chest. the transducer is connected to a computer that displays an image on a monitor and stores the image digitally. By varying the placement and angle of the transducer, doctors can view the heart and nearby major blood vessels from various angles and thus get an accurate picture of heart structure and function. Echocardiography is painless and takes 20 to 30 .(minutes(Susan K. DeWi, 2002

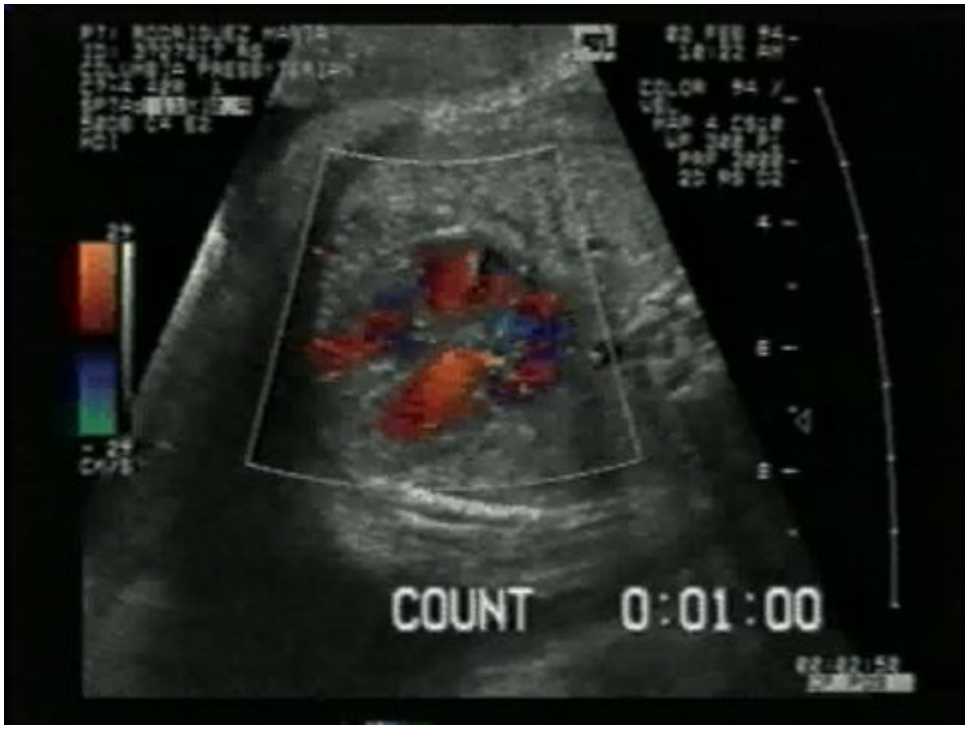

Fig 2-12 shows 2D -Color Doppler Echocardiography. (

(William E Brant MD and Clyde Helms MD2007

If sonographers need to obtain greater clarity or to analyze the aorta or structures at the back of the heart (particularly the left atrium or left ventricle), transesophageal echocardiography can be used. For this procedure, a transducer is passed down the person's throat into the esophagus so that the transducer lies just behind the heart. Transesophageal echocardiography is also used when regular echocardiography is difficult to do because of obesity, lung disorders, or other technical problems. (Susan K. DeWi, 2002)

Fig 2-13 showing Modern echocardiography machine

Chapter three

((Material and methods

The study was conducted in **Sudan Heart Centre** in Khartoum city in may 2014 to October 2015, the aim of the study is to assess the role of echocardiography in diagnoss the problem of heart mainly the left ventricle .

: Material &tools -3-1

-: Sampling 3-1-1

hypertensive patients aged between (23-88 years, 27 50

.(male 23 female

: inclusive criteria 3-1-2

. Hypertensive patients

: Exclusive criteria 3-1-3

.All cardiac patient not hypertensive

: Tools &equipments 3-1-4

An echocardiography machine **MY LAB 50CARDIOVASCULAR XVISION esaote –Italy** , with Doppler and M-mode capability is used , the probe is of sector type (2.5-6.5 MHZ) and ultrasound gel is applied to transducer to prevent the attenuation or artifact ,

. machine connected with thermal printer and papers

Fig (3-1) : echocardiography machine in sudan heart centre

: Methods -3-2

: Technique 3-2-1

: preparation 3-2-1-1

Patient for echocardiography not need preparation except small point you must be done it like cutting of chest hair in male patient or apply excessive amount of gel .

: 3-2-1-2Position of patient

The patient lie supine and rotated slightly to the left , the patient relaxed , lying comfortably and breathing quietly .lubricate the area of chest in heart by gell , hair anywhere on the chest will trap air bubbles so apply coupling agent generously .

: scanning technique 3-2-1-3

Start with Long axis plane (LAX) This plane runs from the right shoulder to the left hip and cuts the left side of the heart along its long axis , the LA / LV/ & AO are imaged with MV & AV , the coronary sinus is imaged in cross section at the atrioventricular groove , the pericardial space is normally visible in systole as a capillary space posterior to LV. And then scan the Short axis palne (SAX) this is perpendicular to LAX. It runs from the left shoulder to the right hip and cuts the heart in cross section , cross sectional images from the apex to the base of the heart can be imaged by serial tilt of the transducer infero- superiorly , three section are important of (SAX) continue scan to(Apex 4- chamber .view) This is perpendicular to the other planes

The transducer is shifted to the apex of heart .the plane runs parallel to the sternum and the chest wall towards the right shoulder . This plane cuts all the 4-chambers (LA, LV,RA,RV) & AV, MV & TV of the heart and from this posision of transducer uoy can generate . other views 5chamber & 2 chamber and 3 chamber

: Image interpretations 3-2-4

Interpretation images appropriate fall area s , both normal and abnormal , should be recorded . Variation from normal size should be accompanied by measurements , images should be labeled with patient identification , examination date and side (right &left) of anatomic ultrasound printer using thermal paper , . CD, DVD ,PAC5

:Data analysis 3-2-5

All data were entered and analysed using Microsoft excel and statistical package for social science (SPSS) version 30 statistical analysis included description . statstics of frequency tables , graphs cross tabulation

Chapter four

:Results

This study was carried out on 50 hypertensive patients complaining of chest pain and short ness of breathing and other indications , where examined with the following results according to the age , gender . ,indication , duration of disease and ultrasound finding

Table (4-1) showing age distributions

Percent	Frequency	Age groups
6.0	3	less than 25
8.0	4	25-40
12.0	6	41-55
46.0	23	56-70
28.0	14	-71
100.0	50	Total

Graph (4-1) frequency and percent distributions
Age group

Table (4-2) frequency and percent of undication

Indication	Frequency	Percent ((Frequ./50
Chest Pain	35	% 70
SOB	27	54%
Dizziness	7	% 14

Palpitation	15	30%
Others	8	% 16

Graph (4-2) percent distributions of indications . in hypertensive patients

Table (4-3) frequency and percent of gender

Gender	Frequency	Percent
Male	27	54%
Female	23	46%
Total	50	100%

Graph (4-3) percent distributions of gender

Table (4-4) frequency and percent of duration of hypertensive in years

Duration of hypertensive	Frequency	% Percent
1-10	**33**	**66.0**
11-20	**12**	**24.0**
21-30	**3**	**6.0**
31-40	**2**	**4.0**
Total	**50**	**100.0**

Graph (4-4) percent of duration of hypertensive

Table (4-5) frequency and percent of grade of LVH

LVH grades	Frequency	Percent
Mild	3	6%
moderate	19	38%
Sever	7	14%
None	21	42%

Graph (4-5) show the percentage of stage of LVH in .Hypertensive patients

Table (4-6) frequency and percent of EF of LV in Hypertensive patients

EF groups	Frequency	Percent
Less than 40	20	40%
41-60	15	30%
61-70	15	30%

Graph (4-6) show the percentage of EF of LV in Hypertensive patients

Table (4-7) shows Cross tabulation between Age*LVH

Total	LVH					Age groups	
	server	modrate	mild	None			
3	1	0	0	2	Count	less than 25	Age
100.0%	33.3%	0%.	0%.	66.7%	within Age %		
6.0%	14.3%	0%.	0%.	9.5%	within LVH %		
6.0%	2.0%	0%.	0%.	4.0%	of Total %		
4	1	0	2	1	Count	25-40	
100.0%	25.0%	0%.	50.0%	25.0%	within Age %		
8.0%	14.3%	0%.	66.7%	4.8%	within LVH %		
8.0%	2.0%	0%.	4.0%	2.0%	of Total %		
6	0	2	0	4	Count	41-55	
100.0%	0%.	33.3%	0%.	66.7%	within Age %		
12.0%	0%.	10.5%	0%.	19.0%	within LVH %		
12.0%	0%.	4.0%	0%.	8.0%	of Total %		
23	2	11	0	10	Count	56-70	
100.0%	8.7%	47.8%	0%.	43.5%	within Age %		
46.0%	28.6%	57.9%	0%.	47.6%	within LVH %		
46.0%	4.0%	22.0%	0%.	20.0%	of Total %		
14	3	6	1	4	Count	greter than 71	
100.0%	21.4%	42.9%	7.1%	28.6%	within Age %		
28.0%	42.9%	31.6%	33.3%	19.0%	within LVH %		
28.0%	6.0%	12.0%	2.0%	8.0%	of Total %		
50	7	19	3	21	Count	Total	
100.0%	14.0%	38.0%	6.0%	42.0%	within Age %		
100.0%	100.0%	100.0%	100.0%	100.0%	within LVH %		
100.0%	14.0%	38.0%	6.0%	42.0%	of Total %		

Cross tabulation between Age*duration Table (4-8) shows

Total	Duration						
	31-40	21-30	11-20	1-10			
3	**0**	**0**	**1**	**2**	**Count**	less than 25	Age
100.0%	**0%.**	**0%.**	**33.3%**	**66.7%**	**within Age %**		
6.0%	**0%.**	**0%.**	**8.3%**	**6.1%**	**within % duration**		
6.0%	**0%.**	**0%.**	**2.0%**	**4.0%**	**of Total %**		
4	**0**	**0**	**2**	**2**	**Count**	25-40	
100.0%	**0%.**	**0%.**	**50.0%**	**50.0%**	**within Age %**		
8.0%	**0%.**	**0%.**	**16.7%**	**6.1%**	**within % duration**		
8.0%	**0%.**	**0%.**	**4.0%**	**4.0%**	**of Total %**		
6	**0**	**1**	**1**	**4**	**Count**	41-55	
100.0%	**0%.**	**16.7%**	**16.7%**	**66.7%**	**within Age %**		
12.0%	**0%.**	**33.3%**	**8.3%**	**12.1%**	**within % duration**		
12.0%	**0%.**	**2.0%**	**2.0%**	**8.0%**	**of Total %**		
23	**2**	**2**	**3**	**16**	**Count**	56-70	
100.0%	**8.7%**	**8.7%**	**13.0%**	**69.6%**	**within Age %**		
46.0%	**100.0%**	**66.7%**	**25.0%**	**48.5%**	**within % duration**		
46.0%	**4.0%**	**4.0%**	**6.0%**	**32.0%**	**of Total %**		
14	**0**	**0**	**5**	**9**	**Count**	greter than 71	
100.0%	**0%.**	**0%.**	**35.7%**	**64.3%**	**within Age %**		
28.0%	**0%.**	**0%.**	**41.7%**	**27.3%**	**within % duration**		
28.0%	**0%.**	**0%.**	**10.0%**	**18.0%**	**of Total %**		
50	**2**	**3**	**12**	**33**	**Count**	Total	
100.0%	**4.0%**	**6.0%**	**24.0%**	**66.0%**	**within Age %**		
100.0%	**100.0%**	**100.0%**	**100.0%**	**100.0%**	**within % duration**		
100.0%	**4.0%**	**6.0%**	**24.0%**	**66.0%**	**of Total %**		

Table (4-9) shows Cross tabulation between Age*EF

Total	EF					
	61-70	41-60	less than 40			
3	0	2	1	Count	less than 25	Age
100.0%	0%.	66.7%	33.3%	within Age %		
6.0%	0%.	13.3%	5.0%	within EF %		
6.0%	0%.	4.0%	2.0%	of Total %		
4	3	0	1	Count	25-40	
100.0%	75.0%	0%.	25.0%	within Age %		
8.0%	20.0%	0%.	5.0%	within EF %		
8.0%	6.0%	0%.	2.0%	of Total %		
6	2	0	4	Count	41-55	
100.0%	33.3%	0%.	66.7%	within Age %		
12.0%	13.3%	0%.	20.0%	within EF %		
12.0%	4.0%	0%.	8.0%	of Total %		
23	7	8	8	Count	56-70	
100.0%	30.4%	34.8%	34.8%	within Age %		
46.0%	46.7%	53.3%	40.0%	within EF %		
46.0%	14.0%	16.0%	16.0%	of Total %		
14	3	5	6	Count	greter than 71	
100.0%	21.4%	35.7%	42.9%	within Age %		
28.0%	20.0%	33.3%	30.0%	within EF %		
28.0%	6.0%	10.0%	12.0%	of Total %		
50	15	15	20	Count	Total	
100.0%	30.0%	30.0%	40.0%	within Age %		
100.0%	100.0%	100.0%	100.0%	within EF %		
100.0%	30.0%	30.0%	40.0%	of Total %		

Cross tabulation between Gender*Duration shows (4-10)Table

Total	Duration					
	31-40	21-30	11-20	1-10		
27	2	2	5	18	Count	M gende
100.0%	7.4%	7.4%	18.5%	66.7%	within gender %	
54.0%	100.0%	66.7%	41.7%	54.5%	within duration %	
54.0%	4.0%	4.0%	10.0%	36.0%	of Total %	
23	0	1	7	15	Count	f
100.0%	0%.	4.3%	30.4%	65.2%	within gender %	
46.0%	0%.	33.3%	58.3%	45.5%	within duration %	
46.0%	0%.	2.0%	14.0%	30.0%	of Total %	
50	2	3	12	33	Count	Total
100.0%	4.0%	6.0%	24.0%	66.0%	within gender %	
100.0%	100.0%	100.0%	100.0%	100.0%	within duration %	
100.0%	4.0%	6.0%	24.0%	66.0%	of Total %	

Cross tabulation between Gender*LVH shows (4-11)Table

Total	LVH						
	server	modrate	mild	None			
27	4	8	2	13	Count	m	Gender
100.0%	14.8%	29.6%	7.4%	48.1%	within gender %		
54.0%	57.1%	42.1%	66.7%	61.9%	within LVH %		
54.0%	8.0%	16.0%	4.0%	26.0%	of Total %		
23	3	11	1	8	Count	f	
100.0%	13.0%	47.8%	4.3%	34.8%	within gender %		
46.0%	42.9%	57.9%	33.3%	38.1%	within LVH %		
46.0%	6.0%	22.0%	2.0%	16.0%	of Total %		
50	7	19	3	21	Count	Total	
100.0%	14.0%	38.0%	6.0%	42.0%	within gender %		
100.0%	100.0%	100.0%	100.0%	100.0%	within LVH %		
100.0%	14.0%	38.0%	6.0%	42.0%	of Total %		

Cross tabulation between Gender*EF shows (4-12)Table

Total	EF					
	61-70	41-60	less than 40			
27	9	6	12	Count	m	Gender
100.0%	33.3%	22.2%	44.4%	within gender %		
54.0%	60.0%	40.0%	60.0%	within EF %		
54.0%	18.0%	12.0%	24.0%	of Total %		
23	6	9	8	Count	f	
100.0%	26.1%	39.1%	34.8%	within gender %		
46.0%	40.0%	60.0%	40.0%	within EF %		
46.0%	12.0%	18.0%	16.0%	of Total %		
50	15	15	20	Count	Total	
100.0%	30.0%	30.0%	40.0%	within gender %		
100.0%	100.0%	100.0%	100.0%	within EF %		
100.0%	30.0%	30.0%	40.0%	of Total %		

Table (4-13) shows Correlation Gender*LVH

.Approx. Sig	Approx. T[b]	Asymp. Std. Error[a]	Value		
397[c].	854.	140.	122.	Pearson's R	Interval by In
415[c].	822.	141.	118.	Spearman Correlation	Ordinal by O
			50		N of Valid C

Table (4-14) shows Correlation Gender*EF

.Approx. Sig	Approx. T[b]	Asymp. Std. Error[a]	Value		
920[c].	100.	140.	014.	Pearson's R	Interval by In
878[c].	154.	141.	022.	Spearman Correlation	Ordinal by O
			50		N of Valid C

Table (4-15) shows Correlation Age*EF

.Approx. Sig	Approx. T[b]	Asymp. Std. Error[a]	Value		
664[c].	-437.-	133.	-063.-	Pearson's R	Interval by Interval
651[c].	-455.-	141.	-066.-	Spearman Correlation	Ordinal by Ordinal
			50	N of Valid Cases	

Table (4-16) shows Correlation Age* LVH

.Approx. Sig	Approx. T[b]	Asymp. Std. Error[a]	Value		
265[c].	1.128	155.	161.	Pearson's R	Interval by Interval
182[c].	1.355	147.	192.	Spearman Correlation	Ordinal by Ordinal
			50		N of Valid Cases

Chapter five

: Discussion 5-1

From the collective finding data of this study that the more effected age between 56-70year as show in table ((4-1 .

with distribution of 27 male (54%) and 23 female (46%) that explain in table (4-3) .

The indication frequency show that the chest pain 35 (70% of patients having chest pain and other symptoms), shortness of breathing in 27 patients (54% of patients) , palpitation 15 patients with(30% from all patients) as shows in table (4-2) .

The duration of hypertension with patient find the hypertension in between (1-10 year) by frequency 33 patients (66% of patients) that in table (4-4) .

There is 29 patients having LVH with 58% of total number of sample and the grade of LVH mild 3 patients (6% of patients) , moderate 19 patients (38%) , severe 7 patients (14%) and there is 21 patients not having LVH with (42 % of patiens having hypertension) as shows in table (4-5).

The effect of HTN in the EF showed in (less than 40 % EF) having frequency of 20 patients (40% of total sample) and 15 patients in (41-60) % and (61-70)% by 30% for two <.<<

5-2 Conclusions :

The study concluded an echocardiography availability , relatively low cost and absence of ionizing radiation or need to contrast material , echocardiography has an important in evaluation of heart diseases , structure and morphology especially in left ventricle at attacked .Awareness of normal and pathological sonographic appearance of heart and attention to technique will able echocardiographers to make optimal used of imaging modality . hypertension have effect heart especially left ventricle that cause hypertrophy and some others abnormalities

Left ventricle hypertrophy in hypertensive patients it is organic change in morphology of left ventricle wall .thickness affect the cardiac out put

5-3 Recommendations :

1- Further studies with more sample

2- In all emergency hospital there must be modren echocardiography machine with new accessories and with qualified trained echo cardiographer .

3- Any hypertensive patient must do echocardiography to monitoring and observation of heart and left ventricle changes .

: Referances

Michael Ronald Elson Dean , 1976 Basic Anatomy and **-1--**

. Physiology for Radiographers

Douglas L. Mann MD, Douglas P. Zipes MD , Peter Libby MD -2-

PhD (,Robert O. Bonow MD MS,2014 , Braunwald's Heart Disease

. 10th edition .22-50- 251,

Simon Suvarna , 2013, cardiac patholog -3-

-Bonita Anderson, normal echocardiography 2007 -4

William E Brant MD and Clyde Helms MD 4th edition 2007-5-

.Fundamentals of Diagnostic Radiology - Volume 4

Jamie Weir , Peter H. Abrahams , Jonathan D. -6 -

Spratt , Lonie R Salkowski, 3rd edition 2003 Imaging Atlas of

. Human Anatom

Susan K. DeWi, 2002 ,Echocardiography From a **- 7-**

. Sonographer's Perspective , 5th Edition

SAM KADDOURA , 2002 , Echo Made Easy , first edition ,- 8 -

. Churchill Living stone ,china ,165-168

JHONE JIRGIS JHODAH ,2012, JHONS NOTE IN APPLIED -9-

ANATOMY , Khartoum

http://www.bloodpressureuk.org/BloodPressureandyou/Medicaltests/Echocardiogram

http://www.texasheart.org/HIC/Anatomy/anatomy2.cfm -

-
http://nottingham.ac.uk/nursing/practice/resources/cardiology/function/index.php

-
http://www.mvcardiology.com/docs/education/NormalHeartFunction.pdf

-
http://www.hopkinsmedicine.org/heart_vascular_institute/conditions_treatments/conditions/valvular_heart_disease.html

http://jama.jamanetwork.com/article.aspx?articleid=402794

http://www.medscape.com/viewarticle/558296_2