

Chapter one

Introduction

Chapter One

1.1 Introduction

Congenital cardiac malformations are broadly defined as those cardiac anomalies that are present at birth. The ideally suitable imaging technique is echocardiography due to wide range of imaging planes which allow the demonstration of cardiac structures anatomical relationships that can aid in the diagnosis of simple and complex congenital malformations (Feigenbaum et al,2005).

Congenital heart disease is one of the commonest human malformations, affecting 6 per 1000 live births. They account for 10% of infant deaths and about 50% of deaths from malformations (Au Harb M et al,1994)

Acyanotic congenital lesions account for 70% of all congenital heart disease, the most common of which, as isolated lesions, are ventricular septal defects (most common), patent ductus arteriosus, atrial septal defect and pulmonic stenosis (Keith JE et al ,1967).

Approximately eight out of 1,000 infants are born with some type of congenital heart defect. VSD 30-50%, PDA 10%, ASD 7%,PS 7%, Coarctation 6%, AS 5%, TGA 5%, AV canal defects 3%.

Most ultrasound systems combine 2-D imaging and CW and PW Doppler and are referred to as Duplex system.

The Sequential Segmental Approach is a newer nomenclature approach has remarkably simplified the classification of congenital heart disease. It is based on following the blood flow into the heart (systemic venous and pulmonary venous), through the heart (the atrioventricular valves and ventricles) and then out the great vessels (semilunar valves and great vessels). This nomenclature system is extraordinarily helpful to those conducting echocardiographic examinations as it forms a systematic guide for verification that all the pertinent chambers and valves and their relationships have been documented. The system is dependent on a few words that are very important in

describing the various lesions: Connection refers to the sequence of anatomic structures (Au Harb M et al,1994).

Acquisition of a series of carefully annotated high-resolution images that follow the traditional echocardiographic protocol. Echocardiographic imaging of complex congenital heart disease can be overwhelming if a system of serial image acquisition is not used. Thus, sequential chamber analysis is prescribed as the system of choice; once adopted, chamber analysis proceeds very quickly.

Sequential chamber analysis as described by the authors provides the backbone for accurate diagnosis in pediatric and adult congenital heart disease and begins by establishing sidedness or situs of the abdominal viscera (Benjamin W. Eidem et al ,2010).

Echocardiography is also useful for estimating shunt size by examining the degree of volume overload of the left atrium and left ventricle; in the absence of associated lesions, the extent of the increased dimensions is a good reflection of the size of the left-to-right shunt (Sam Richmond, Christopher Wren et.al,2002).

Views for Congenital Heart Disease, as with acquired heart disease, the standard apical, parasternal, and subcostal views are used for the majority of recordings. In addition, emphasis is placed on certain views that are particularly rewarding. For example, the subcostal approaches identify the interatrial septum and the relationships of the atrial and ventricular septum to the atrioventricular valves. Suprasternal views are good for examination of the great vessels and the aortic arch. All views obviously must be utilized. In small children, lack of attenuation from the rib cage permits routine imaging with high frequency transducers such as 5MHz or higher(Sam Richmond, Christopher Wren et.al,2002).

The Doppler echo allows estimation of pressures in the RV, PA, and LV using the flow velocity of certain valvular or shunt jets. Estimation of PA pressure is particularly important in pediatric patients (Jae K.Oh et al, 2006).

1.2 Problem of the study

Pediatrics Acyanotic Congenital Cardiac Malformations account about 70% of all congenital cardiac defects. The concern over these defects is necessitated by the fact that, although most of these lesions commonly are of no impact on patients, but a number of them can have grave outcome if clinical evaluation report did not herald this fatality, because some patients may be asymptomatic which will lead to delayed diagnosis. So neonates, infants, and children's; merit further evaluation by another diagnostic , reliable, accurate tool ;echocardiography.

1.3 Objectives of the study

1.3.1 General objective

The general objective of this study;

Study of Saudi Pediatrics Acyanotic Congenital Cardiac Malformations using Echocardiography.

1.3.2 Specific objectives

- To assess the prevalence and incidence of Acyanotic Congenital Cardiac Malformations in Saudi children.
- To correlate between Echocardiographic findings and clinical findings.
- To assess the heart structures changes in each defect (LV, RV, LA, RA, MV,...) .

1.4 Significance of the study

The present study should lead to improve outcomes of the pediatrics acyanotic congenital cardiac malformations among neonates, infants and children; by using echocardiography, in order to determine the appropriate early diagnosis and proper treatment to improve health for pediatrics in Saudi Arabia.

1.5 Overview of study

This study consisted of five chapters. Chapter one is an introduction which includes; problem and objective of the study. Chapter two is a literature review which includes; Anatomy, Physiology, Pathology and previous studies. Chapter three is about research methodology. In Chapter four the results are presented and Chapter five includes; discussion, conclusions and recommendations.

Chapter Two

Literature Review

Chapter Two

Theoretical Background

2.1 Normal Anatomy of the Heart

A fundamental Understanding of cardiac anatomy forms the cornerstone of diagnostic pediatric cardiology and is a prerequisite for the proper interpretation of clinical cardiovascular imaging.

In this chapter, cardiac anatomy is presented segmentally, with an emphasis on comparisons between analogous right-sided and left-sided structures. Although standard and commonly accepted anatomic terminology is used, anglicized forms are also provided in parentheses' ”for example, crista terminalis (terminal crest).

Mediastinum

General Features

In keeping with their embryonic origins as midline structures, the heart and great vessels occupy the midthorax, within the mediastinum. The anatomic borders of the mediastinum are as follows:

- Anteriorly, the sternum and its adjacent ribs
- Posteriorly, the vertebral column and its adjacent ribs
- Laterally, the medial aspects of the parietal pleuras (pleurae)
- Superiorly, the plane of the first rib
- Inferiorly, the diaphragm

The mediastinum, in turn, is divided into four regions (Fig 2.1). The heart, aortic arch, and descending thoracic aorta are located in the middle, superior, and posterior regions, respectively. Also located within the mediastinum are the esophagus, trachea, right and left main bronchi, thymus, lymph nodes, autonomic nerves, thoracic duct, and small vessels (including bronchial, esophageal, azygos, and hemiazygos) (David G. Nichols,et al,2006).

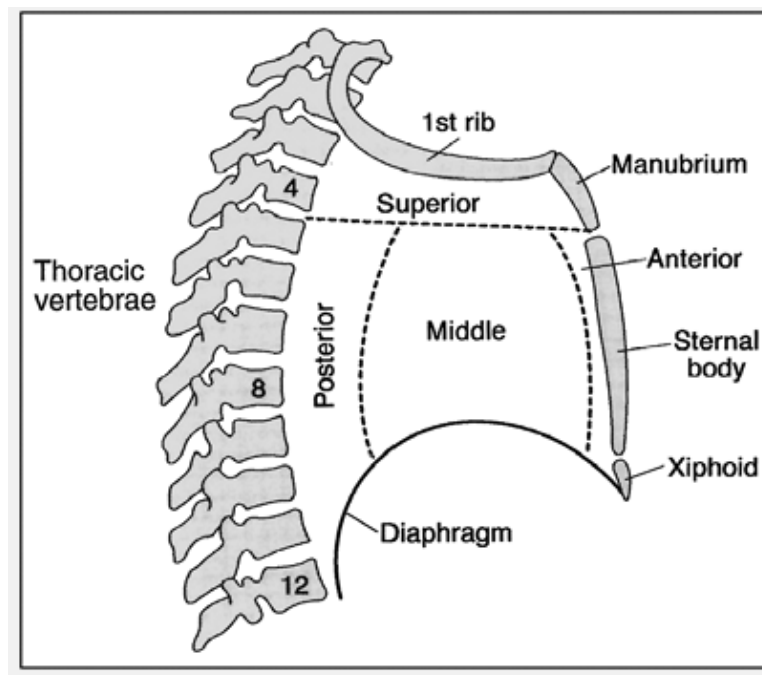


FIG 2. 1 Mediastinum, shown schematically. Viewed from a right lateral perspective, the mediastinum has four divisions

Pericardium

General Features

The pericardium both covers the heart, as the epicardium, and surrounds it, as the parietal pericardium, much like a fluid-filled balloon covers a fist that is pressed into it. Between the two layers, within the pericardial sac, serous pericardial fluid (25 mL in adults) serves to lubricate the heart and allow its relatively friction-free movement within the chest. In addition, the parietal pericardium limits the diastolic dimensions of the heart.

2.2 Position of the Heart

Description of the normal interrelationships of the chambers within the heart, and the location of the heart itself within the chest as following;

- ☞ The heart normally occupies the middle compartment of the mediastinum, with two-thirds of its bulk to the left of the midline (Fig 2.2).
- ☞ The long axis shows a considerable obliquity relative to the long axis of the body, extending roughly along a line drawn through the right shoulder to the left hemidiaphragm.
- ☞ Despite this discrepancy between the planes of the body and those of the heart, the cardiac structures should still be described relative to the bodily coordinates, that is, in attitudinally appropriate orientation, although this basic rule of anatomy has not always been followed. (Cook AC, et al, 2002).
- ☞ Usually described in terms of a triangle, the true shape of the heart as projecting to the frontal surface is more trapezoidal, with horizontal upper and lower borders, a more or less vertical right border just outside the edge of the sternum and a sloping left border extending out to the

apex in the fifth intercostal space (Fig 2.3). The most instructive single plane to be found within the heart is the so-called base (Robert H. Anderson, et al, 2010).

The normal position of the heart in the left hemithorax, with the apex directed to the left, levocardia, is so usual that it is often left unstated. The term dextrocardia (Calcaterra G, et al, 1979, Huhta JC et al, 1982, Nachlieli T et al, 1992) is mostly used to describe a heart occupying the right hemithorax, although some authors prefer to distinguish dextrocardia from dextroversion. In that case, dextroversion means that the heart is in the right chest while dextrocardia means that the heart is in the right chest and that the apex is also pointed to the right. In mesocardia (Lev M, et al, 1971) the heart is in the midline. Although dextrocardia can occur with a functionally normal heart, abnormalities of segmental relationships and connections are much more frequent than in the normally positioned heart.

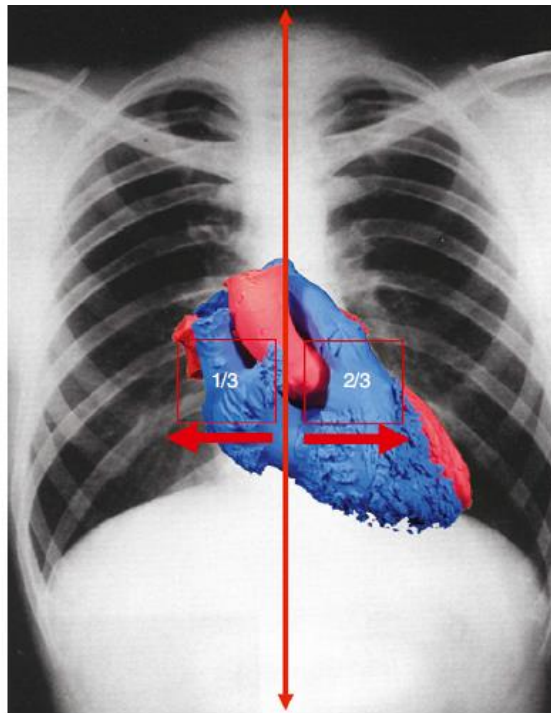


FIG 2.2

As shown by this cast of a normal heart superimposed on the frontal chest radiograph, the heart is a mediastinal structure with two-thirds of its bulk positioned to the left of the midline.

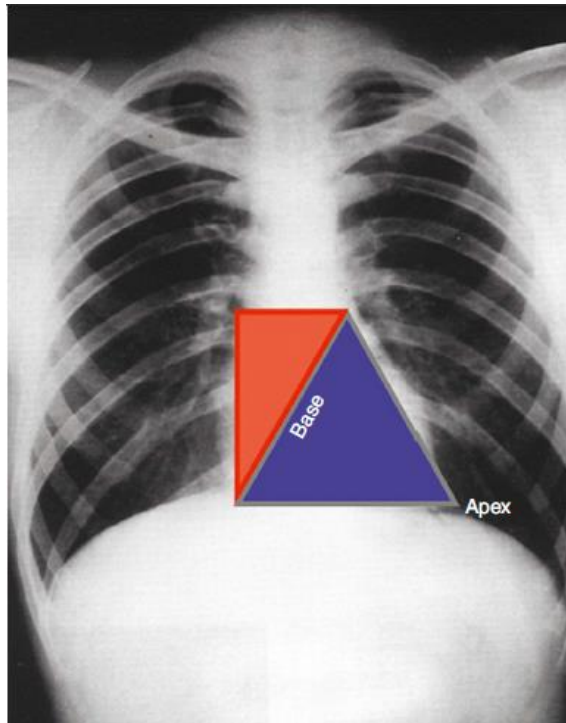


FIG 2.3

In considering the arrangement of the cardiac silhouette as seen in frontal projection as shown in Figure 2-1, it can best be likened to a trapezium, with a longer inferior border adjacent to the diaphragm. The trapezium itself can then be broken down into atrial (red) and ventricular (blue) triangles, with the ventricular triangle having its own base and apex, the latter corresponding with the cardiac apex

2.3 External Topography of the Heart

2.3.1 General Features

The atrioventricular groove (sulcus) defines the plane of the base of the heart, which contains the four cardiac valves. The anterior and inferior interventricular grooves indicate the plane of the ventricular septum. Normally, the two ventricles are similar in size and the atria are appreciably smaller than the ventricles. Along the surface of the heart, the right and circumflex coronary arteries travel in the right and left atrioventricular grooves, respectively, and the left anterior and posterior descending coronary arteries course along the anterior and inferior interventricular grooves, respectively. Thus, by external inspection alone, surgeons and pathologists can assess the location of the coronary arteries and the presence of hypoplastic or dilated chambers (Hugh D. Allen, et al,2008).

2.3.2 Chambers and Great Vessels

To properly interpret the various cardiac imaging modalities, one must understand not only the normal size and shape of the cardiac chambers and great vessels but also their relative positions three-dimensionally.

In this regard, only the right atrium is anatomically named correctly. It is truly a right lateral chamber, whereas the left atrium lies in the midline posteriorly and is not a left-sided structure.

The right ventricle is a right anterior chamber, and the left ventricle is a left posterior structure.

Although not striking, the atria are located slightly superiorly relative to the ventricles. Positionally, the aorta arises posteriorly, inferiorly, and to the right of the main pulmonary artery.

In patients with congenitally malformed hearts, the relative sizes and positions of the cardiac chambers and great vessels may vary considerably from normal (David G. Nichols, et al,2006).

2.4 Atria

2.4.1 General Features

- ☞ The right and left atria serve as receiving chambers for blood returning from the systemic and pulmonary venous systems, respectively.
- ☞ They also have an endocrine function, particularly the right atrium. In the setting of right atrial dilation or congestive heart failure, atrial natriuretic peptide is released from secretory granules within myocytes, as part of the cardiorenal system for sodium and body fluid homeostasis(David G. Nichols,et al,2006).
- ☞ Atria are chambers interposed between the great veins and an atrio ventricular valve.
- ☞ Occasionally, it may exist either between the great veins and an adjacent atrium, as in tricuspid atresia or cor triatriatum (triatrial heart), or between an atrium and an atrioventricular valve, as in total anomalous pulmonary venous connection.
- ☞ Triatrial hearts can be described as having a subdivided left atrium, a double-chamber left atrium, or an accessory left atrial chamber.
- ☞ Rarely, the right atrium is subdivided by an enlarged valve of the inferior vena cava(David G. Nichols, et al,2006).

2.4.2 Right Atrium

- The morphologic right atrium is characterized by connections from the caeve and coronary sinus and by connections to one or both atrioventricular valves, with drainage into one or both ventricles.
- Its septal surface is defined by an inter atrial portion, with the limbus and valve of the fossa ovalis (oval fossa), and by an atrioventricular portion.
- The free wall harbors not only a large pyramidal appendage, but also a crista terminalis (terminal crest) and numerous pectinate muscles outside the appendage (Sharma S, et al, 1988).
- The terminal crest forms a boundary between the smooth-walled posterior aspect of the free wall, derived from the sinus venosus, and the muscular anterior aspect, derived from the embryologic right atrium.

2.4.3 Left Atrium

- In contrast, the morphologic left atrium has neither a crista terminalis nor pectinate muscles.
- Its appendage is more finger-shaped than pyramidal, with several small outpouchings or lobes.
- The main body of the left atrium is smooth walled, like the common pulmonary vein from which it is derived, and only the appendage remains as a remnant of the embryologic atrium.
- The left side of the atrial septum is entirely interatrial. Its smooth surface is interrupted only by a crescentic rim that forms the residual border of the ostium secundum. (David G. Nichols, et al, 2006).

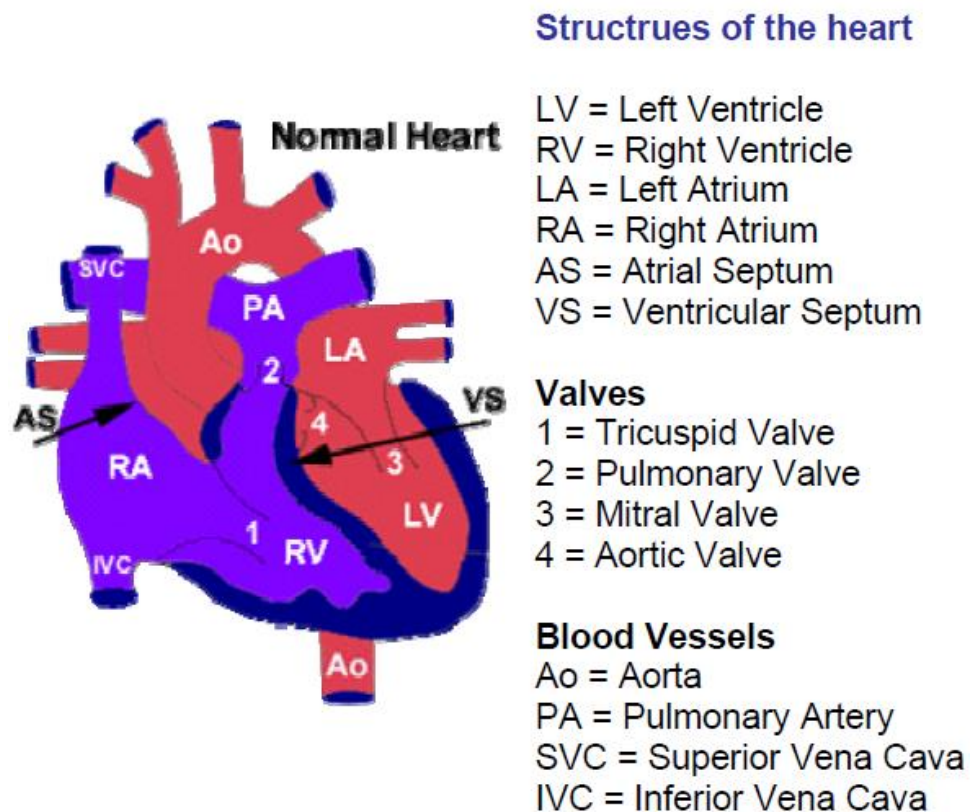


FIG 2.4 Structures of the Heart

2.4.4 Atrial Septum

- ☞ When viewed from the right, the septum has an interatrial component (between the right and left atria) and an atrioventricular component (between the right atrium and left ventricle).
- ☞ The interatrial portion is relatively small, and its most prominent feature is the fossa ovalis (oval fossa) (Sweeney LJ, et al,1979).
- ☞ This consists of a horseshoe-shaped muscular the limbus (limb), which forms a pathway for internodal conduction and a central sheet of thin fibrous tissue the valve of the fossa ovalis.

Note:

In adolescents and adults, the limbus averages 4 to 8 mm in thickness, and the valve is about 1 mm thick.

**Embryologically, the valve of the fossa ovalis represents the first septum that develops (septum primum), and the limbus represents the second septum that forms (septum secundum) (David G. Nichols, et al, 2006).

2.5 Atrioventricular Valves

Definition

Atrioventricular valves are fibrous tissue flaps that not only connect the atria to the ventricles but also serve to separate them electrically.

- Because the valves tend to travel with their respective ventricles, a morphologic tricuspid valve almost invariably connects to a morphologic right ventricle, and a morphologic mitral valve connects to a morphologic left ventricle.
- In normal hearts, viewed in a four-chamber format, the tricuspid valve ring attaches to the septum more apically than does the mitral annulus (Fig 2.5).
- Identification of this arrangement by clinical imaging allows determination not only of atrioventricular valve morphology, but also of ventricular morphology.

2.5.1 Tricuspid Valve

- ☞ The normal tricuspid valve consists of three leaflets, three major commissures, and three papillary muscles. Although its annulus is elliptical, the shape of its orifice at the midleaflet (or midventricular) level is more triangular.
- ☞ The septal tricuspid leaflet has numerous direct cordal insertions along the ventricular septum, and the anterior leaflet forms an intracavitary curtain that separates the inflow and outflow tracts.
- ☞ Additionally, the tricuspid and pulmonary valves are separated by the muscular right ventricular outflow tract (infundibulum or conus).

2.5.2 Mitral Valve

- ☞ Like the tricuspid valve, the mitral valve has an elliptical annulus and an intracavitary anterior leaflet that separates the inflow and outflow tracts.
- ☞ However, the mitral valve has only two leaflets, two major commissures, and two papillary muscle groups rather than three, and because the papillary muscles attach to the left ventricular free wall, there are normally no septal insertions of tendinous cords.
- ☞ Moreover, in contrast to the muscular separation that exists between the tricuspid and pulmonary valves, the mitral annulus is in direct continuity with the aortic valve ring, such that the anterior mitral leaflet forms a part of the left ventricular outflow tract.

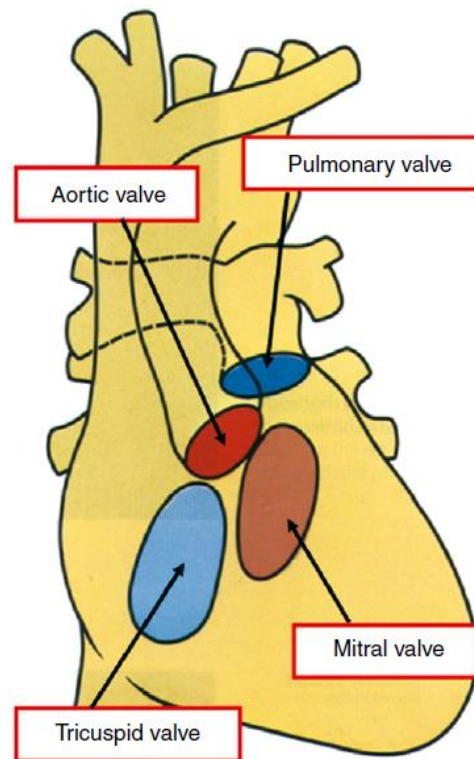


FIG 2.5

The positions of the valves are shown within the cardiac silhouette,
as seen in the frontal projection

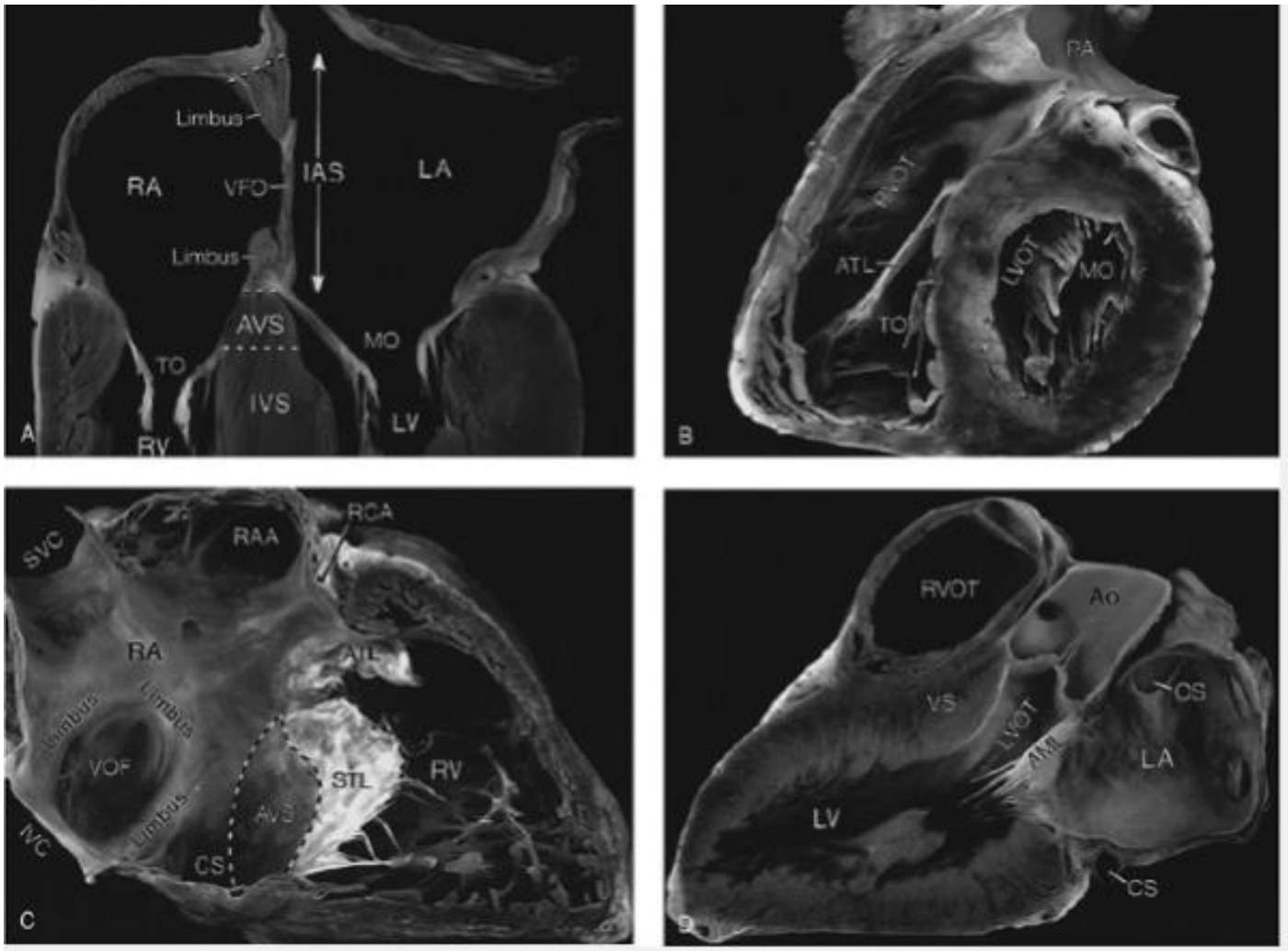


FIG 2.6

Characteristic anatomic features of atria, atrioventricular valves, and ventricles in four specimens of normal hearts. A: The atrioventricular septum and the more apical attachment of the tricuspid valve ring, compared with the mitral valve, are best evaluated in a four-chamber view. B: The triangular tricuspid orifice and elliptical mitral orifice, at midleaflet level, are shown in a short-axis view, as are the septal insertions of tendinous cords from the septal tricuspid leaflet. C and D: Right-sided and left-sided features can readily be compared between a two-chamber view of the right heart (C) and a long-axis view of the left heart (D).

2.6 Ventricles

2.6.1 General Features

- ☞ Normally, a ventricle receives blood through an atrioventricular valve from an atrium and pumps it across a semilunar valve into a great artery.
- ☞ Because all four cardiac valves lie in the same plane, at the base of the heart, blood entering and exiting a ventricle follows a V-shaped course.
- ☞ During ventricular systole, both the base apex length and the short-axis diameter decrease and not only expel blood from the chamber but also assist closure of the atrioventricular valve by decreasing its annular size.
- ☞ It is important to note that the right ventricle in fetuses and neonates differs from that in older persons. during fetal life, the presence of a patent ductus arteriosus is associated with equalization of aortic and pulmonary artery pressures and a state of physiologic pulmonary hypertension.
- ☞ Thus, during fetal and neonatal life, right ventricular hypertrophy is evident and the thickness of the right ventricle is similar to that of the left (David G. Nichols, et al, 2006).

2.6.2 The Ventricular Septum

The septal structures separating the ventricular cavities are made up almost exclusively of muscle, albeit that the small interventricular component of the membranous septum is also, self-evidently, a ventricular septal component.

This fibrous component, in fact, can be considered as the central part of the septum, with the muscular septum radiating out from this point to separate the ventricular cavities.

The muscular septum separates the inlet of the right ventricle mostly from the outlet of the left (Siew Yen Ho ,et al,2005).

TABLE 2.1 COMPARISON OF RIGHT-SIDED AND LEFT-SIDED ANATOMIC FRACTURES OF CARDIAC SEGMENTS

Right atrium	Left atrium
Limbus of fossa ovalis (limb of oval fossa)	Ostium secundum
Large pyramidal appendage	Small fingerlike appendage
Crista terminalis (terminal crest)	No crista terminalis
Pectinate muscles	No pectinate muscles
Receives venae cavae and coronary sinus	Receives pulmonary veins
Tricuspid valve	Mitral valve
Low septal annular attachment	High septal annular attachment
Septal cordal attachments	No septal cordal attachments
Triangular orifice (midleaflet level)	Elliptical orifice (midleaflet level)
Three leaflets and commissures	Two leaflets and commissures
Three papillary muscles	Two large papillary muscles
Empties into right ventricle	Empties into left ventricle
Right ventricle	Left ventricle
Tricuspid-pulmonary discontinuity	Mitral-aortic continuity
Muscular outflow tract	Muscular-valvular outflow tract
Septal and parietal bands	No septal or parietal band
Large apical trabeculations	Small apical trabeculations
Coarse septal surface	Smooth upper septal surface
Crescentic in cross sections	Circular in cross section
Thin free wall (3-5 mm)	Thick free wall (12 -15 mm)
Receives tricuspid valve	Receives mitral valve
Pulmonary valve	Aortic valve
Empties into main pulmonary artery	Empties into ascending aorta

2.7 BLOOD SUPPLY TO THE HEART

2.7.1 The Coronary Arteries

- ☞ The coronary arteries are the first branches of the aorta, usually taking their origin within the bulbous expansions of the aortic root proximal to the sinutubular junction known as the aortic sinuses of Valsalva.
- ☞ As already discussed, there are two major coronary arteries and three aortic sinuses (see Fig 2.7).
- ☞ Almost without exception, the arteries arise from one or the other of the sinuses closest to the pulmonary trunk, these being the adjacent or facing sinuses.
- ☞ In most normal individuals, one artery arises from each of these facing sinuses, permitting them to be named the right coronary and left coronary sinuses, respectively (see Fig2.8).
- ☞ It is useful, nonetheless, to have a convention for naming the sinuses that works irrespective of the origin of the coronary arteries, and irrespective of the relationship of the aorta to the pulmonary trunk.
- ☞ This is provided by observing the aortic sinuses from the point of the non-facing sinus, and looking towards the pulmonary trunk (see Fig.5) (Robert H. Anderson, et al, 2010).

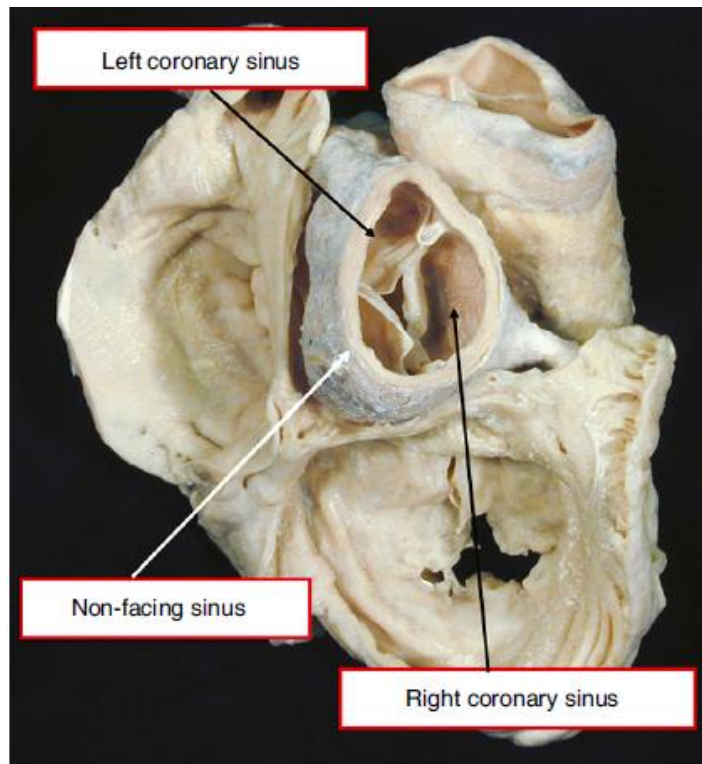


FIG 2.7

This dissection of the short axis of the heart, shown from its atrial aspect, shows how the coronary sinuses, and the leaflets of the aortic valve, can be described as right coronary, left coronary and non-facing. In almost all instances the non-facing sinus does not give rise to a coronary artery, so it can also be described as the non-coronary sinus.

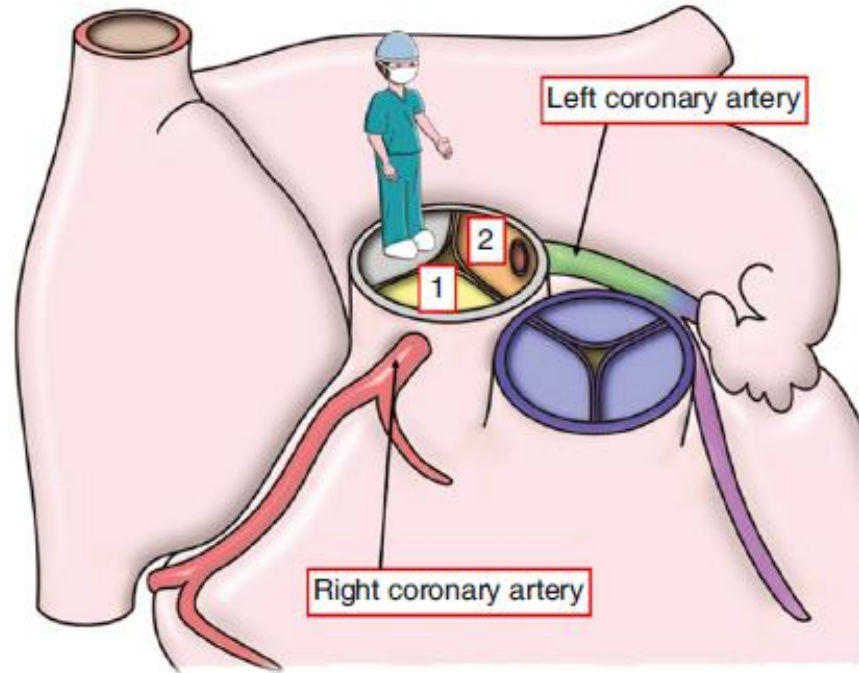


FIG 2.8

When an observer views the aortic sinuses from the non-facing sinus looking towards the pulmonary trunk, then, irrespective of the relationship of the great arteries, one aortic sinus is always to the left hand and the other to the right hand. In the normal situation, the sinus to the right hand, known as 1, gives rise to the right coronary artery, while the sinus to the left hand, known as 2, gives rise to the main stem of the left coronary artery.

2.7.1 The Coronary Veins

- ☞ The venous return from the heart is, for the most part, collected by the major cardiac veins, which run alongside the coronary arteries in the interventricular and atrioventricular grooves.
- ☞ The largest vein, termed the great cardiac vein, accompanies the anterior interventricular artery, turning beneath the left atrial appendage to join the coronary sinus.
- ☞ The junction between vein and sinus is the point of entrance of the oblique vein of the left atrium, or the vein of Marshall, which usually corresponds with the site of a prominent venous valve, the valve of Vieussens.
- ☞ The coronary sinus then runs within the left atrioventricular groove to the right atrium (Fig 2.9).
- ☞ As it enters the right atrium, it collects the middle cardiac vein, which accompanies the inferior interventricular artery, and the small cardiac vein, which runs in the right atrioventricular groove.
- ☞ Further smaller veins usually drain into the sinus as it courses within the left atrioventricular groove.
- ☞ When there is a persistent left superior caval vein, it usually drains into the coronary sinus along the route normally occupied by the oblique vein.
- ☞ An additional series of veins, the minor cardiac veins, usually three to four in number, drain the blood from the anterior surface of the right ventricle.

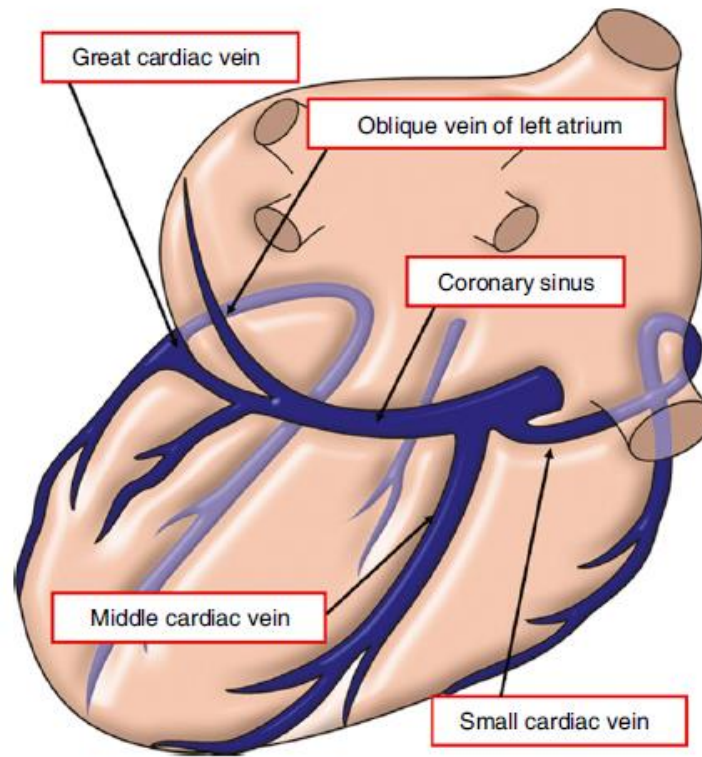


FIG 2.9

Coronary Veins

Show that the coronary sinus then runs within the left atrioventricular groove to the right atrium

2.8 The Cardiovascular System Physiology

The cardiovascular system comprises of the heart, blood, blood vessels and lymphatic system.

- Circulate blood throughout entire body for; Transport of oxygen to cells, Transport of CO₂ away from cells, Transport of nutrients (glucose) to cells, Movement of immune system components (cells, antibodies), Transport of endocrine gland secretions.

Regulates; pH (concentration of hydrogen ions), body temperature, salts, water content in the cells

Protection; Blood prevents loss by clotting and combats toxins,

Lymphatic;As blood is the main transport system to the body, so it may also bring bacteria to the tissues. The lymphatic system is the protective system that picks up materials, cleanses them of waste products and toxins, and returns them to the blood. Although it is described as a separate system, it is really part of the vascular system, being intertwined with the blood circulation.

This function by ; Heart is pump, Arteries and veins are main tubes (plumbing), Arteries Away from Heart, Veins to Heart, Diffusion happens in capillaries (oxygen, CO₂, glucose diffuses in or out of blood).

The Heart: The heart is the pump responsible for maintaining adequate circulation of oxygenated blood around the vascular network of the body. It has four-chambers:

Right Atrium (forms most of posterior of heart);Receives O₂-poor blood from body via IVC, SVC, Coronary sinus. Right Ventricle; Receives O₂-poor blood from right atrium through tricuspid valve,

and Pumps blood to lungs via Pulmonary Semilunar Valve in pulmonary trunk. Left Atrium: Receives O₂-rich blood from 4 Pulmonary Veins.

Left Ventricle: (forms apex of heart); Receives blood from Left Atrium via bicuspid valve, and Pumps blood into aorta via Aortic Semilunar Valve to body.

Semilunar valves main function is to prevent backflow in large arteries, Pulmonary Semilunar Valve lies between Rt Ventricle and Pulmonary Trunk, Aortic Semilunar Valve between the Left Ventricle and Aorta

The circulation is divided into two principle systems known as the general or systemic circulation that is the portion of the cardiovascular system which carries oxygenated blood away from the heart, to the body, and returns deoxygenated blood back to the heart. And Pulmonary circulation is the portion of the cardiovascular system which carries oxygen-depleted blood away from the heart, to the lungs, and returns oxygenated blood back to the heart (Anne Waugh, et al, 2001).

2.8.1 Blood

The fluid that surrounds tissue cells throughout the body is called interstitial fluid and is serviced by blood transporting oxygen and nutrients to it whilst lymph removes toxins and waste products. Blood forms about 79% of the body weight consisting of Plasma, Corpuscles and Platelets. Erythrocyte (red blood cells) transport oxygen and carbon dioxide, leucocytes (white blood cells), produced in red bone marrow (myeloid tissue), and lymphocytes fight infection and thrombocyte (platelet) are essential to blood clotting at the site of an injury. Plasma is a clear slightly alkaline yellow fluid in which the following are dissolved - blood, proteins, salts, waste materials, gases,

enzymes, hormones and vitamins. The blood has three main functions, transport, regulation, and protection.

2.9 Pathophysiology of A cyanotic Congenital Cardiac Malformations

Hemodynamic principles

There are four hemodynamic principles describe the pathophysiology of these common conditions: Communication at ventricular or great vessel level, communication at atrial level, Obstructions. Valvar insufficiency (regurgitation). In addition, pulmonary hypertension leads to characteristic clinical and laboratory findings.

The most common acyanotic Cardiac malformations are classified as following:

With Normal Pulmonary blood flow: Valvular Lesions: 1) PS 2) AS 3)MR 4) TR

Vascular Lesions: 1) COA 2) Coronary anaomalies.

Myocardial disease: 1)Endocardial fibroelastosis. 2) Metabolic diseases

With Increase Pulmonary blood flow: Common shunt lesions: 1) VSD 2) ASD 3) PDA

Uncommon shunt lesions: 1) AVSD 2) Coronary AVF

An understanding of the anatomy and pathophysiology of the congenital cardiac lesion under consideration allows one to determine the preoperative care or resuscitation needed and to predict the expected postoperative recovery.

Children with acyanotic heart disease may have one (or more) of three basic defects: (1) left-to-right shunts (e.g., atrial septal defect, ventricular septal defect); (Kitzman DW, et al, 1988) defects of ventricular inflow or outflow (e.g., mitral stenosis, aortic valve disease, aortic coarctation); and (Harmon JV Jr, et al, 1987) primary myocardial dysfunction (e.g., cardiomyopathy) (Table 2.2).

These lesions may lead to decreased systemic oxygen delivery by causing maldistribution of flow with excessive pulmonary blood flow (Q_p) and diminished systemic blood flow (Q_s) ($Q_p: Q_s > 1$), by impairing oxygenation of blood in the lungs caused by increased intra- and extravascular lung water, and by decreasing ejection of blood from the systemic ventricle (David G. Nichols, et al, 2006).

Table 2.2 Mechanism of Decreased Systemic O₂ Delivery in Various Types of Acyanotic Heart Disease

Mechanism	ACYANOTIC LESION CATEGORY		
	Left-to-Right Shunt	Inflow/Outflow Obstruction	Myocardial Dysfunction
Decreased contractility		*	*
Pulmonary edema and V/Q mismatch	*	*	*
Maldistribution of flow ($Q_p:Q_s > 1$)	*		

V/Q, ventilation/perfusion.

2.9.1 Maldistribution of Flow: $Q_p:Q_s > 1$

In infants with left-to-right shunts, pulmonary blood flow (Q_p) increases as pulmonary vascular resistance (R_p) decreases from the high levels present perinatally. If Q_p is sufficiently increased, pulmonary artery pressure may also increase, particularly with left-to-right shunts distal to the tricuspid valve, such as a large VSD or aortopulmonary window.

As pulmonary flow increases, left ventricular volume overload may occur with cardiac failure, decreased systemic output, pulmonary congestion, and edema. Over time, increased Q_p leads to a series of pulmonary microvascular changes that first produce reversible pulmonary vasoconstriction and later fixed pulmonary vascular disease.

As R_p increases over time, Q_p decreases. The primary determinant of pulmonary blood flow is pulmonary vascular resistance.

In patients with increased and reactive R_p , left ventricle (LV) function may be normal but oxygen delivery may be limited by decreased right ventricle (RV) output or by the development of intracardiac right-to-left shunting.

If pulmonary pressures exceed systemic pressures, right-to-left shunting predominates and the patient becomes cyanotic. Depending on the type and size of the lesion, pulmonary overcirculation that remains uncorrected may lead to pulmonary vascular obstructive disease as early as 6 months of age.

This increase in R_p occurs more commonly when the shunt is at the ventricular (VSD) or great vessel (e.g., truncus arteriosus) level than at the atrial level (ASD) (David G. Nichols, et al, 2006).

2.10 A cyanotic Congenital Cardiac Malformations

Congenital cardiac malformations has been defined as the presence of ‘a gross structural abnormality of the heart or intrathoracic great vessels that is actually or potentially of functional significance’ (Hoffman JJ,et al,2002).

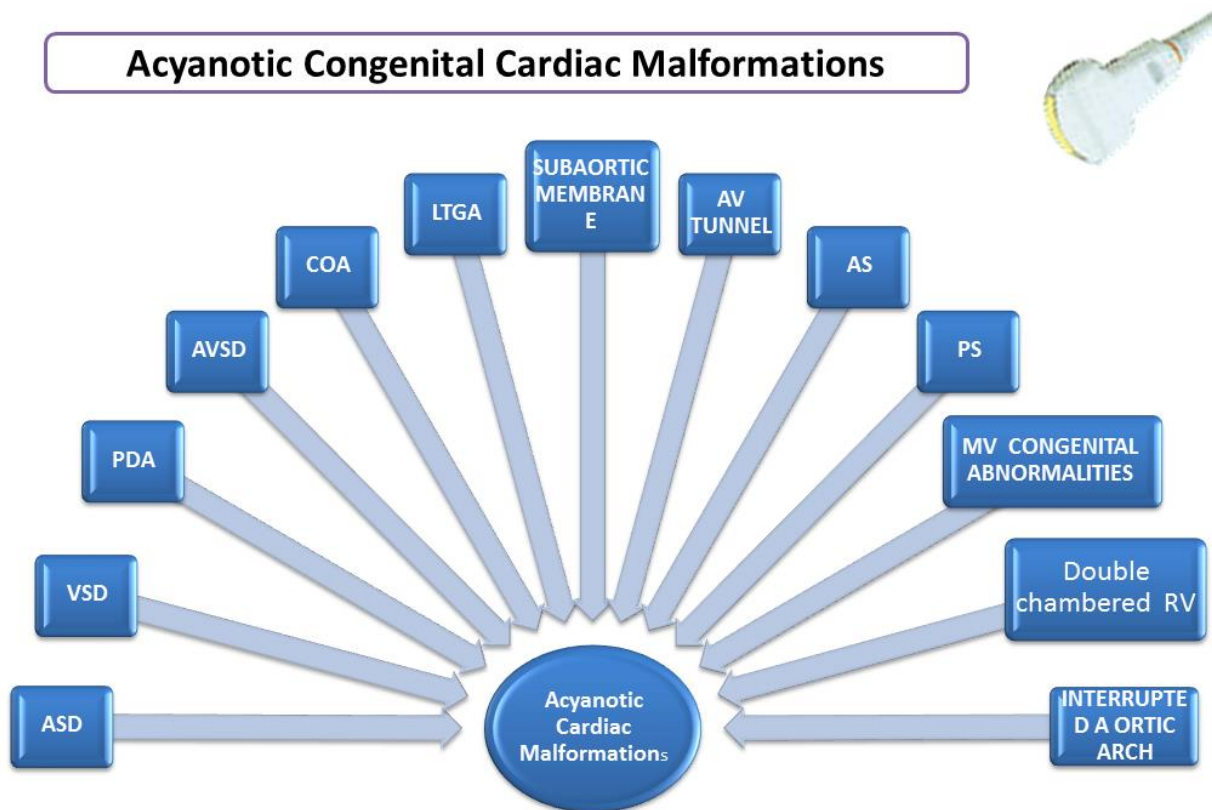


FIG 2.10

2.10.1 Epidemiology of Heart Disease:

- 👉 The study of the aetiology of congenital cardiac disease initially focused on epidemiological studies, which mainly incorporated the identification of factors that influence the incidence of the various lesions.

- ☞ This is in large part because familial inheritance is not obvious, and thus a tractable focus is environmental influence and assessment of heritability. These studies primarily led to the conclusion that there were multi-factorial influences.
- ☞ Several difficulties are apparent with these studies. First, intra-uterine mortality due to congenital cardiac disease is difficult to assess, and conversely, in addition to the nearly 1% of children with cardiac malformations, (Hoffman JJ, et al ;2002) an additional 1% to 2% of the population harbour more subtle cardiac developmental anomalies that only become apparent later in life.
- ☞ Second, familial associations are rarely obvious. In retrospect, this should be evident from the observations that defined mutations in a single gene can cause seemingly unrelated lesions, compounded by forme fruste or low genetic penetration.

2.10.2 Left-to-Right shunt lesions

The combination of increased pulmonary vascular markings and absence of

cyanosis indicates the presence of a cardiac defect that permits the passage of

blood from a left-sided cardiac chamber to a right-sided cardiac chamber.

Four cardiac defects account for most instances of left-to-right shunt and

half of all instances of congenital heart disease:

(1) ventricular septal defect,

(2) patent ductus arteriosus

(3) atrial septal defect of the ostium secundum type

(4) atrioventricular (AV) canal (endocardial cushion) defect.

In the first two conditions (**ventricular septal defect and patent ductus arteriosus**), the direction and magnitude of the shunt are governed by factors

influencing shunts at either the ventricular level or the great vessel level: Relative resistances if the defect is large and relative pressures if the communication is small.

In most cases, the resistances and pressures on the right side of the heart and pulmonary arterial system are less than those on the left side of the heart, causing a left-to-right shunt.

In the second two conditions (atrial septal defect and endocardial cushion defect) since the shunt occurs at the atrial level in atrial septal defect and endocardial cushion defect, ventricular compliances influence the shunt.

The left-to-right shunt in these patients is caused by the fact that the right ventricle normally is more compliant than the left. In certain circumstances, the shunt in these four malformations may become right-to-left; this state, sometimes called Eisenmenger syndrome.

The clinical and laboratory findings of any given condition vary considerably with the volume of pulmonary blood flow, the status of pulmonary vasculature, and the presence of coexistent cardiac anomalies.

Although most patients with these malformations are asymptomatic, poor growth and symptoms of congestive cardiac failure occur in the 5% of patients with greatly increased blood flow, as in ventricular septal defect and patent ductus arteriosus.

A tendency to frequent respiratory infections and episodes of pneumonia also is present in those with a large shunt (Walter H. Johnson, et al; 2008).

2.11 Ventricular Septal Defect (VSD)

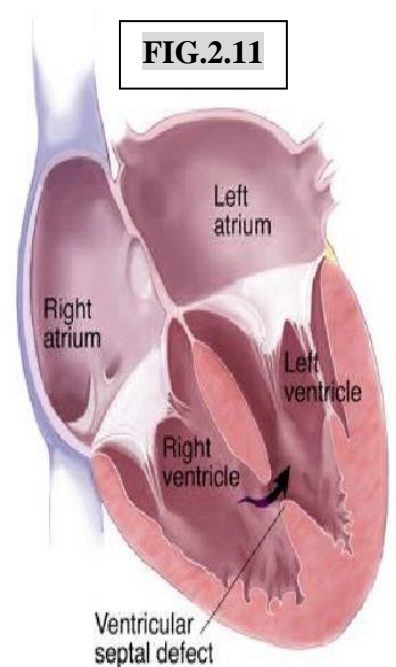
2.11.1 Previous studies:

The most common congenital cardiac anomaly is ventricular septal defect (VSD); it occurs as an isolated lesion in 20% of CHD patients and is present with other anomalies in another 5% of patients (J. Hodler, et al, 2007).

The ventricular septum may be divided into a small membranous portion {Perimembranous defects are most common (70%)}, and a large muscular portion. The muscular septum has three components: the inlet septum (or AV canal), the trabecular septum (also simply called muscular septum), and the outlet (infundibular or conal) septum. The trabecular septum is further divided into anterior, posterior, middle, and apical portions (Myung K.Park, 2008).

The defects vary in size, ranging from tiny defects without hemodynamic significance to large defects with accompanying CHF and pulmonary hypertension (Jae K.Oh et al, 2006).

Ventricular Septal Defect is usually symptomless at birth. It usually manifests a few weeks after birth. With a small VSD, the patient is asymptomatic with normal growth and development. With a



moderate to large VSD, delayed growth and development, decreased exercise tolerance, repeated pulmonary infections, and CHF are relatively common during infancy. But larger ones can result in heart failure, pulmonary hypertension or growth restriction with recurrent respiratory infections like pneumonia. Other features may be poor weight gain, breathlessness on breast feeding and increased heart rate. If not intervened, it can develop into (Eisenmenger's syndrome) Cyanosis and clubbing may be present in patients with pulmonary vascular obstructive disease, which has a very bad outcome(DeVore GR ,et al,1987, Myung K.Park,2008).

The two-dimensional echocardiogram shows the position and size of the VSD .In small defects, especially those of the muscular septum, the defect itself may be difficult to image and is visualized only by color Doppler examination. In defects of the membranous septum, a thin membrane (called a ventricular septal aneurysm but consisting of tricuspid valve tissue) can partially cover the defect and limit the volume of the left-to-right shunt (Vibhuti N Singh, 2011).

Echocardiography is also useful for estimating shunt size by examining the degree of volume overload of the left atrium and left ventricle; in the absence of associated lesions, the extent of the increased dimensions is a good reflection of the size of the left-to-right shunt. With a small defect, a large resistance to the left-to-right shunt occurs at the defect. With a large VSD, the resistance offered by the defect is minimal, and the left-to-right shunt depends largely on the level of PVR. The lower the PVR, to 8 weeks of age, when the shunt. increases and CHF may develop (Myung K.Park, 2008).

Pulsed Doppler examination shows whether the VSD is pressure restrictive by calculating the pressures gradient across the defect. Such calculation allows an estimated of right ventricular pressure and helps determine whether the patient is at risk for the development of early pulmonary vascular disease. The echocardiogram can also be useful to determine the presence of aortic valve insufficiency or leaflet prolapsed in the case of supracristal (Outlet) VSDs.

The Doppler echo allows estimation of pressures in the RV, PA, and LV using the flow velocity of certain valvular or shunt jets. Estimation of PA pressure is particularly important in pediatric patients (Jae K.Oh et al,2006).

2.11.2 ANATOMICAL CLASSIFICATION

The ventricular septum may be divided into a small membranous portion {Perimembranous defects are most common (70%)}, and a large muscular portion. The muscular septum has three components: the inlet septum, the trabecular septum (also simply called muscular septum), and the outlet (infundibular or conal) septum. The trabecular septum is further divided into anterior, posterior, middle, and apical portions.

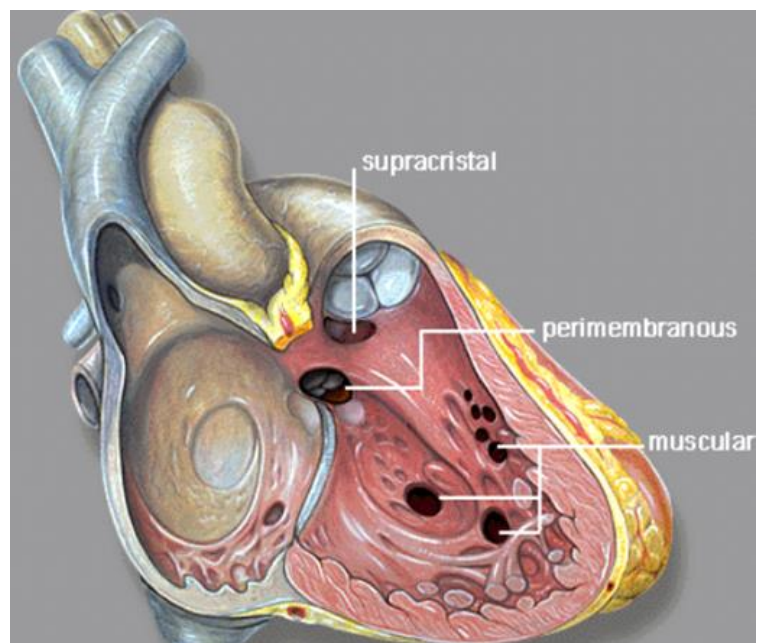


FIG 2.12

Two-dimensional and Doppler echo studies can identify the number, size, and exact location of the defect; estimate PA pressure by using the modified Bernoulli equation; identify other associated defects; and estimate the magnitude of the shunt. Because the ventricular septum is a large, complex structure, examination for a VSD should be carried out in a systematic manner to be able to specify

the exact location and size of the defect. When possible, more than one view should be obtained, preferably a combination of the long- and short-axis views.

In patients with VSD right ventricular pressure can be determined noninvasively by subtracting the VSD-gradient from the systolic blood pressure. Using a stand-alone continuous-wave Doppler the VSD-gradient may be underestimated due to a large angle theta caused by the various VSD locations and the often atypical VSD-jet directions. Therefore Color-Doppler was used to visualize the VSD-jet and to align (angle less than 15 degrees) the continuous-wave Doppler beam.

Because the ventricular septum is a large, complex structure, examination for a VSD should be carried out in a systematic manner to be able to specify the exact location and size of the defect. When possible, more than one view should be obtained, preferably a combination of the long- and short-axis views(Myung K.Park; 2008).

The cardiac valves serve as markers of specific types of VSDs, except for the trabecular septum. The membranous VSD is closely related to the aortic valve, the inlet VSD to the tricuspid (or AV) valve, and the infundibular VSD to the semilunar valves. Selected parasternal, apical, and subcostal views that are useful in locating the site of VSDs. Good understanding of these views is necessary in the assessment of a VSD in terms of location and size of the defect Two-dimensional echocardiographic short axis subcostal views are reliable in the detection and localization of VSD. Nevertheless, trabecular and apical VSDs are particularly difficult to visualize and the use of pulsed Doppler coupled with two-dimensional echocardiography should enhance the sensitivity in diagnosing this type of VSD (Piot JD et al; 1981).

The anatomic localization of all VSDs is facilitated by coupling 2D sonograms with a Doppler system and by superimposing a color-coded direction and velocity of blood flow on the real-time images (Vibhuti N Singh.2011).

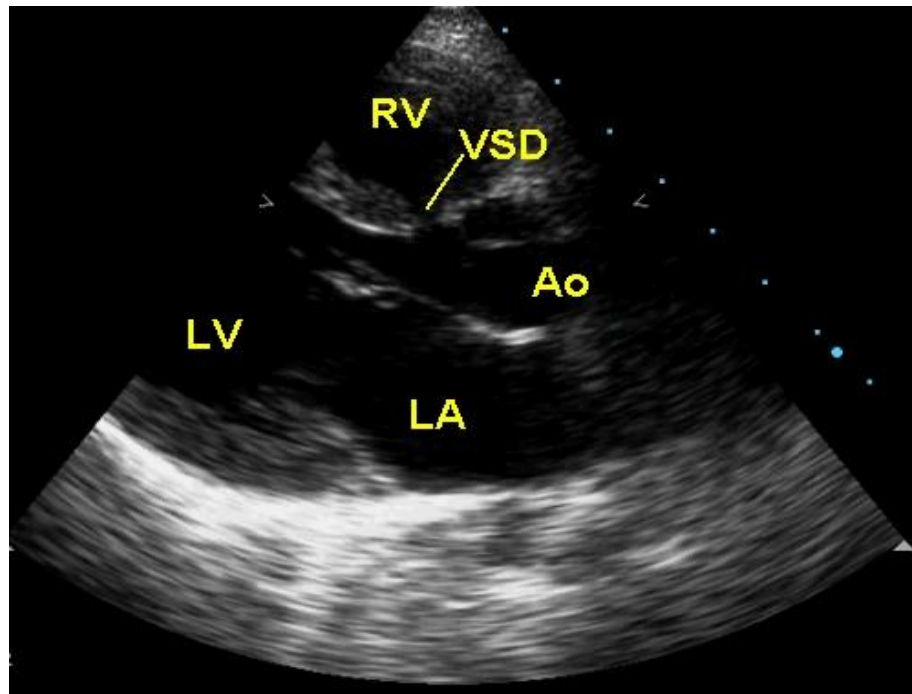


FIG 2.13

Echocardiographic profile in ventricular septal defect

Ventricular septal defect (subaortic) seen from parasternal long axis view

Parasternal long axis view showing aorta (Ao), left atrium (LA), left ventricle (LV) and a small perimembranous (subaortic) ventricular septal defect. Mitral valve is in the open position and the aortic valve in the closed position.

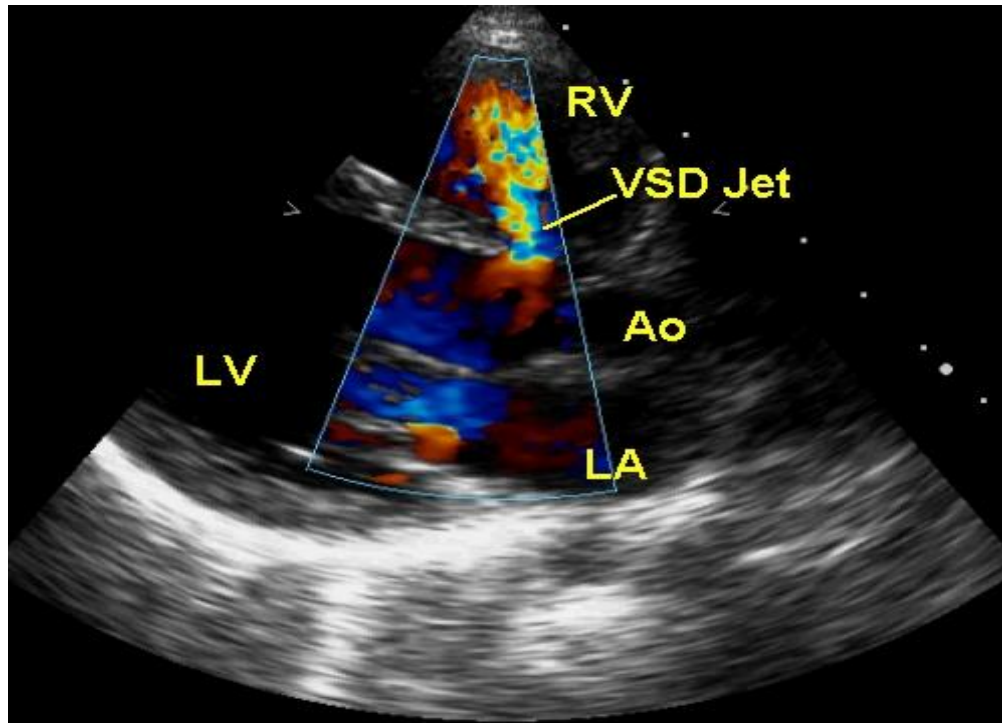


FIG 2.14

VSD Jet visualized by colour flow mapping (colour Doppler)

Colour sector in parasternal long axis view shows the mosaic (multi-coloured) VSD jet across the perimembranous VSD from the left ventricle to the right ventricle. It is a high velocity jet because the VSD is restrictive. The neck of the jet almost corresponds to the size of the VSD. VSD jet is seen in a systolic frame.

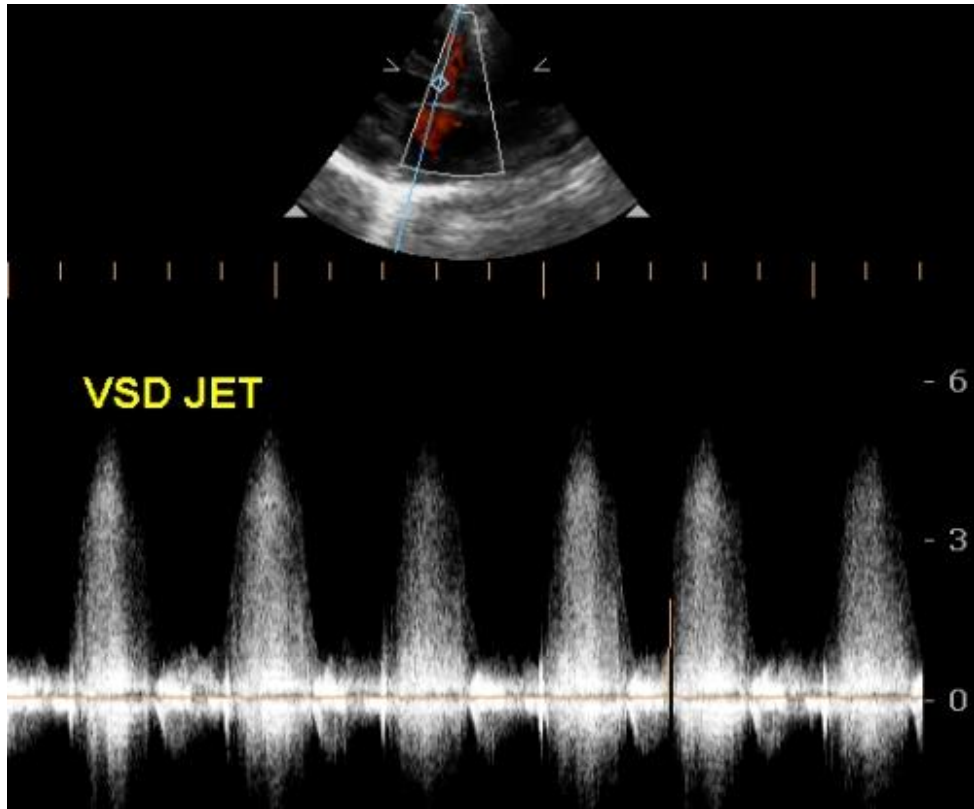


FIG 2.15

Continuous wave Doppler interrogation of VSD jet

VSD jet can be picked up in parasternal long axis or short axis view, guided by color Doppler. It may also be picked up from the apical four chamber view, but the alignment may not be good. Pulsed Doppler cannot measure the jet velocity as it is much higher than the Nyquist limit of the pulsed Doppler system. Hence continuous wave Doppler is used for interrogation of the VSD jet. The interventricular gradient is calculated using the Bernoulli equation. A high interventricular gradient indicates that the VSD is restrictive. A low gradient indicates unrestrictive VSD and pulmonary hypertension.

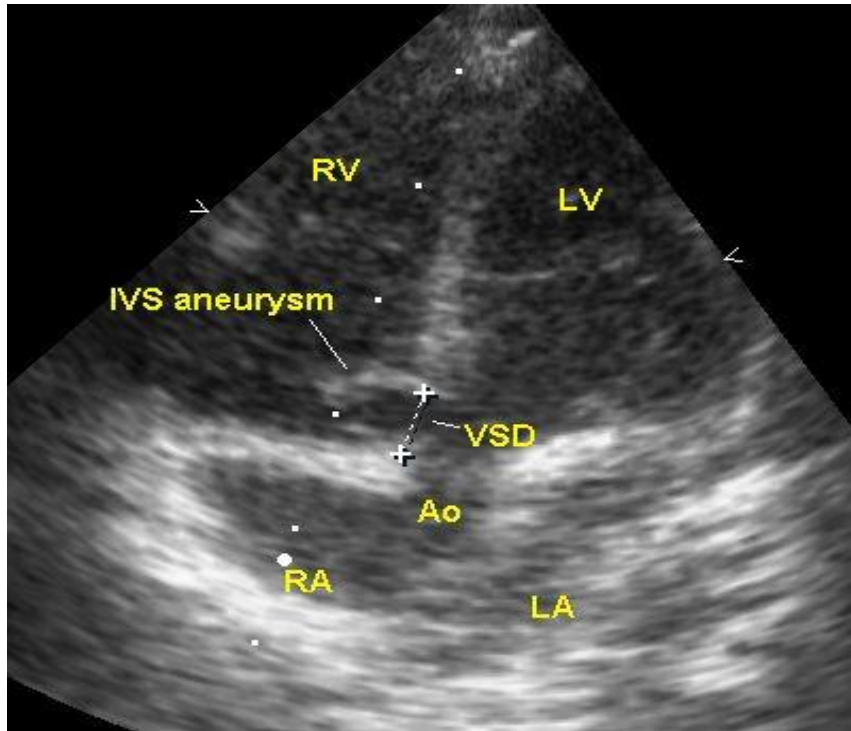


FIG 2.16

Moderate sized ventricular septal defect in peri-membranous location seen from the apical five chamber view. RV: right ventricle; LV: left ventricle; VSD: ventricular septal defect; Ao: aorta; RA: right atrium; LA: left atrium; IVS: interventricular septum. There is aneurysm of the interventricular septum covering the VSD, leaving a small gap. The VSD jet passes through this small defect which is restrictive (below).

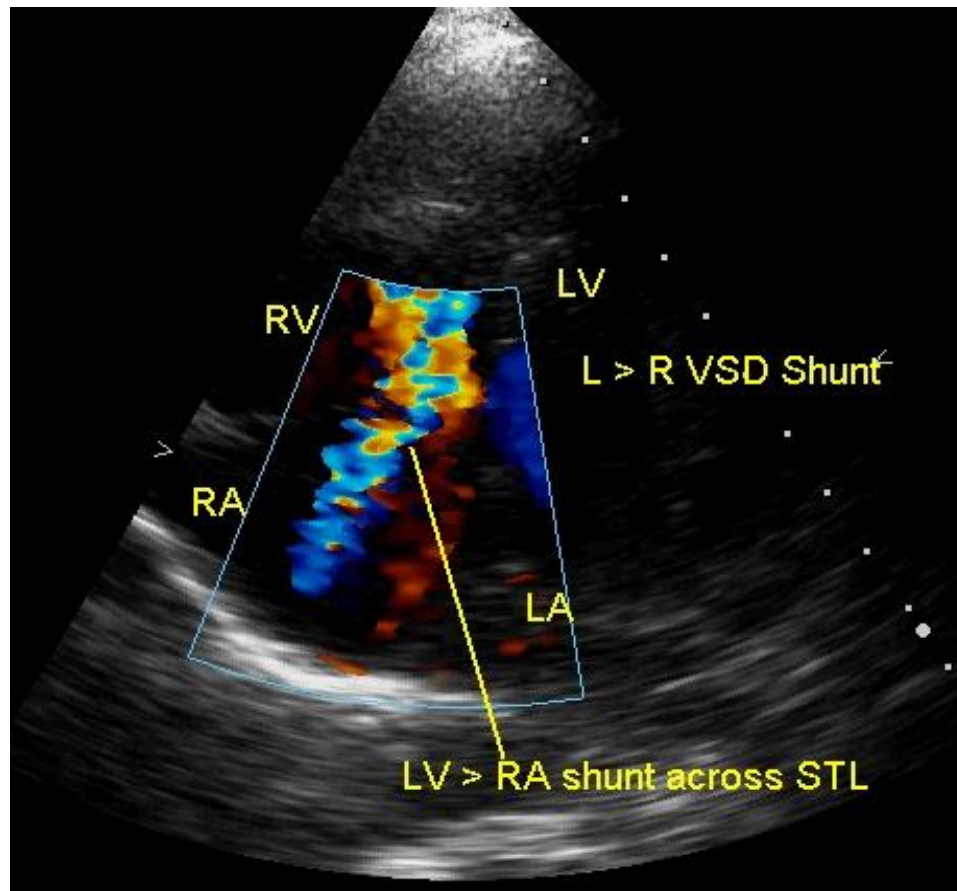


FIG 2.17

LV – RA shunt in perimembranous VSD across STL fenestration
 the jet from the left ventricle to the right ventricle across the perimembranous VSD

2.12 Atrial Septal Defect (ASD)

2.12.1 Previous studies

- Atrial septal defect (ASD) is among the most common types of congenital heart disease. With reported incidence of 1.8% (Zhao QM ,et al 2013) .
 - Small defects can bear minor hemodynamic derangements. Rate of closure is from 9-50%.(Dickinson DF ,et al; 1981, Demir T ,et al;2008) .
 - Depending on the baseline conditions, very small defects of <3 mm size are likely to be closed in 100 % of infants.
 - ASD with larger size >10 mm rarely close due to increased left to right shunting (Saito T, et al; 2012, Fiszler R, et al 2014).
- ☞ Little is known about their natural history in different subgroups of ethnicity that by what age they get close what is the safe waiting period to postpone intervention, what is the effect of race, ethnicity, gender or baseline characteristic which affect natural course of the disease.
- ☞ Since ASD may progress to pulmonary hypertension, heart failure, or arrhythmias it is mandatory to evaluate the effect of various baseline variables which can affect the spontaneous closure of the ASD like gender, age, normal growth and weight gain, BMI, and the initial size of the ASD (Senocak F,et al;1996)
- ❖ The echocardiography spatial resolution assists in comprehensive evaluation of ASD and associated cardiac pathology.
 - ❖ A quantification of shunt flow and hemodynamics can be easily accomplished with Doppler, and provide an objective means of follow up for these patients.

- ❖ Finally, echocardiography can be used to guide percutaneous closure of ASD, providing an important avenue for minimally invasive intervention.
- ❖ Echocardiography is currently the basis for the initial diagnosis, and appropriate, management of ASD.
- One of the most frequently encountered acyanotic congenital lesions in clinical practice is the atrial septal defect (ASD), of which echocardiography provides invaluable information in the initial assessment, follow-up, and management.

2.12.2 The common anatomic types of Atrial Septal Defects (ASDs)

- Ostium secundum occurs in the midportion of the Inter Atrial Septum (IAS) in fossa ovalis region in 65–80% of cases.
- The second type defects are located antero inferior to the fossa ovalis and in continuity with mitral and tricuspid valve tissue inferiorly named as Ostium primum ASDs.
- The 3rd type is Sinus venosus ASDs their usually site at the roof of the atria either close or adjacent to SVC insertion, when the defect was close to SVC it may be overridden (Ted Plappert CVT, et al;2006).
- ****Secundum ASD patients are often asymptomatic

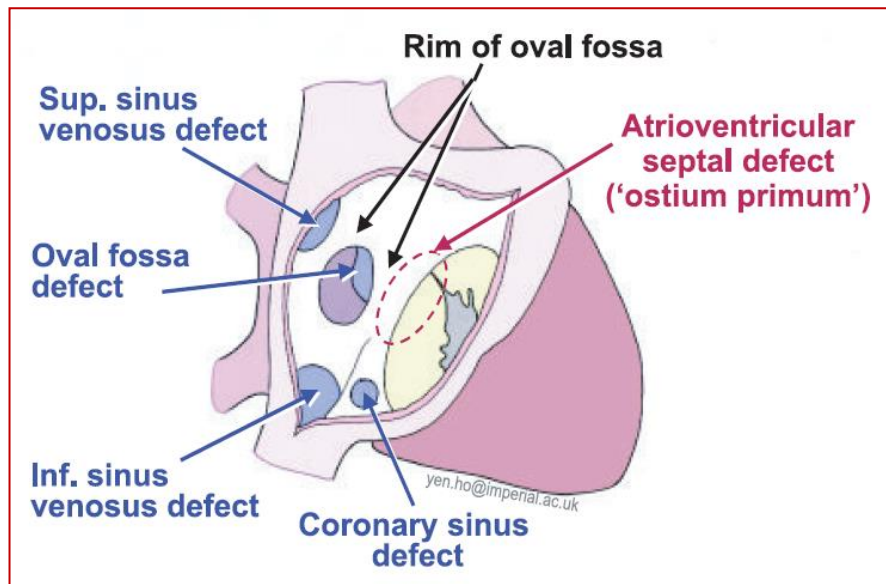


FIG 2.18

Diagram showing the common anatomic types of Atrial Septal Defects (ASDs)

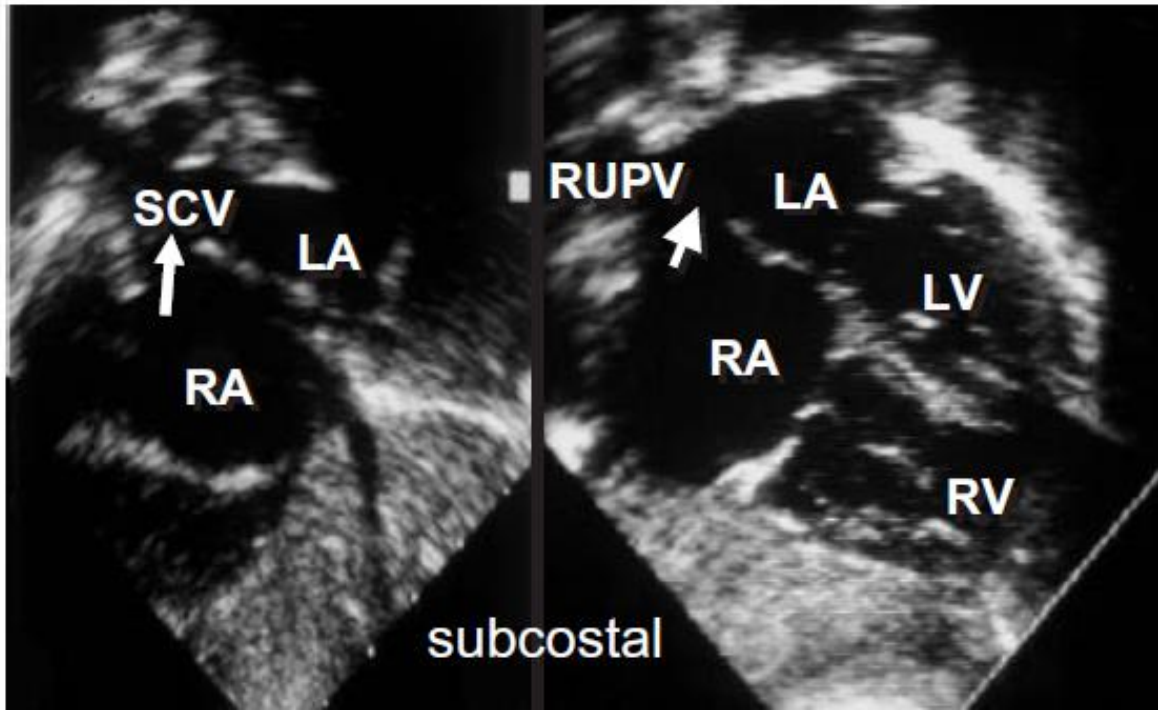


FIG 2.19

Subcostal paracoronal sections showing a superior sinus venosus defect (arrows) with overriding of the superior caval vein and right upper pulmonary vein. The oval fossa is intact (Siew Yen Ho.,et al;2005).

2.13 Atrio-Ventricular Septal Defect(AVSD)

2.13.1 Nomenclature

- Atrioventricular septal defects (AVSD) are a group of anomalies that share a defect of the atrioventricular septum and abnormalities of the atrioventricular valves.
- The terms atrioventricular canal defects or endocardial cushion defects also describe these lesions.
- These lesions are divided into partial and complete forms.
- In partial AVSD, a primum atrial septal defect (ASD) is always present and there are two distinct mitral and tricuspid valve annuli.
- The mitral valve invariably is cleft.
- The complete form also includes a primum ASD, but it is contiguous with an inlet ventricular septal defect (VSD) and the common atrioventricular valve has a single annulus.
- Similarly, the clinical manifestations and management of these patients depend on the extent and severity of the lesions present.

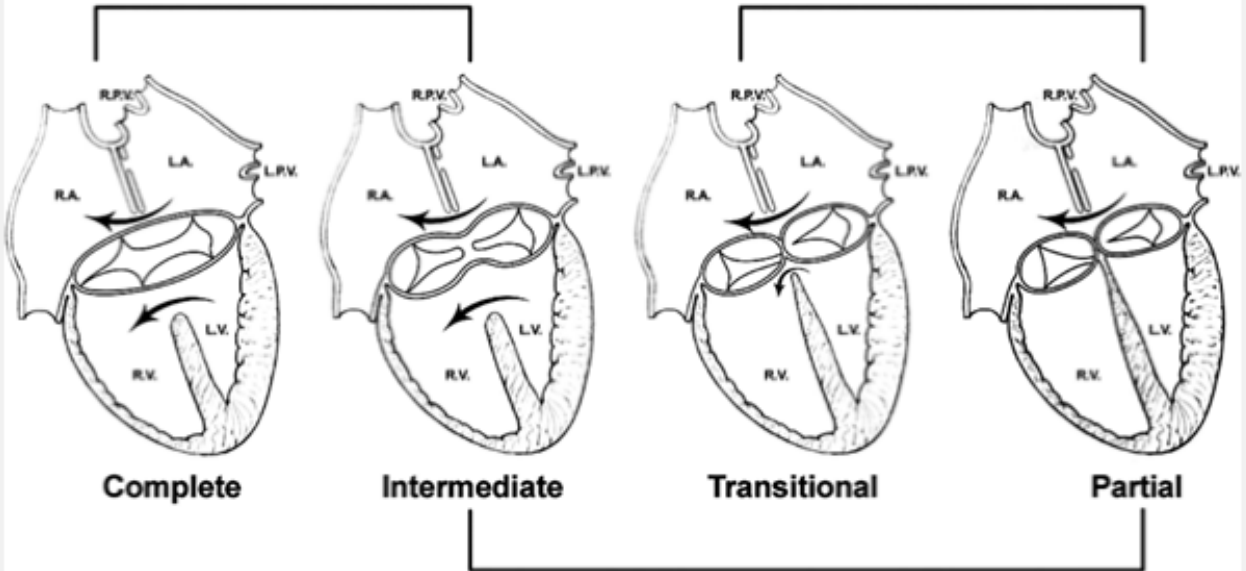
Surgical repair of AVSD has been one of the great successes of the last several decades of congenital cardiac surgery(Studer et al;1982) reported average operative mortality <2%. Long-term survival has been excellent.

A cumulative 20-year survival of 95% has been reported (Aubert S,ET AL;2005). However, at least 25% of patients (McGrath LB, ET AL ;1987) await reoperation, most commonly because of progressive left atrioventricular valve regurgitation or relief of left ventricular outflow tract obstruction.

AVSD Summary

Similar physiology – VSD & ASD

Similar physiology – ASD



Similar AV valve anatomy:
A tongue of tissue divides the common AV valve into a right and left component by connecting the anterior and posterior "bridging" leaflets centrally

FIG 2.20 AVSD

2.13.2 Demographics

AVSDs account for 4% to 5% of congenital heart disease and an estimated occurrence of 0.19 in 1,000 live births (Fyler DC ,et al;1980, Samanek M ;1991).

In a large fetal echocardiography experience, AVSD was the most common anomaly detected, constituting 18% of abnormal fetal hearts (Allan LD ,et al; 1994). **In utero diagnosis of an AVSD is readily made on routine fetal four-chamber imaging. Gender distribution is approximately equal or may show a slight female preponderance (Fyler DC ,et al;1980).

About 40% to 45% of children with Down syndrome have congenital heart disease, and among these, approximately 40% have an AVSD, usually the complete form (Fyler DC ,et al;1980).

Complete AVSDs also occur in patients with heterotaxy syndromes (more common with asplenia than with polysplenia). Common atrium has been associated with Ellis van Creveld syndrome.

2.13.3 Embryogenesis

- ☞ Faulty development of the endocardial cushions and of the atrioventricular septum is thought to be responsible for the broad range of AVSDs.
- ☞ In partial AVSDs, incomplete fusion of the superior and inferior endocardial cushions results in a cleft in the midportion of the anterior mitral leaflet, often associated with mitral regurgitation.
- ☞ In contrast, complete AVSD is associated with lack of fusion between the superior and inferior cushions and, consequently, with the formation of separate anterior and posterior bridging leaflets along the subjacent ventricular septum (Fig 2. 21).

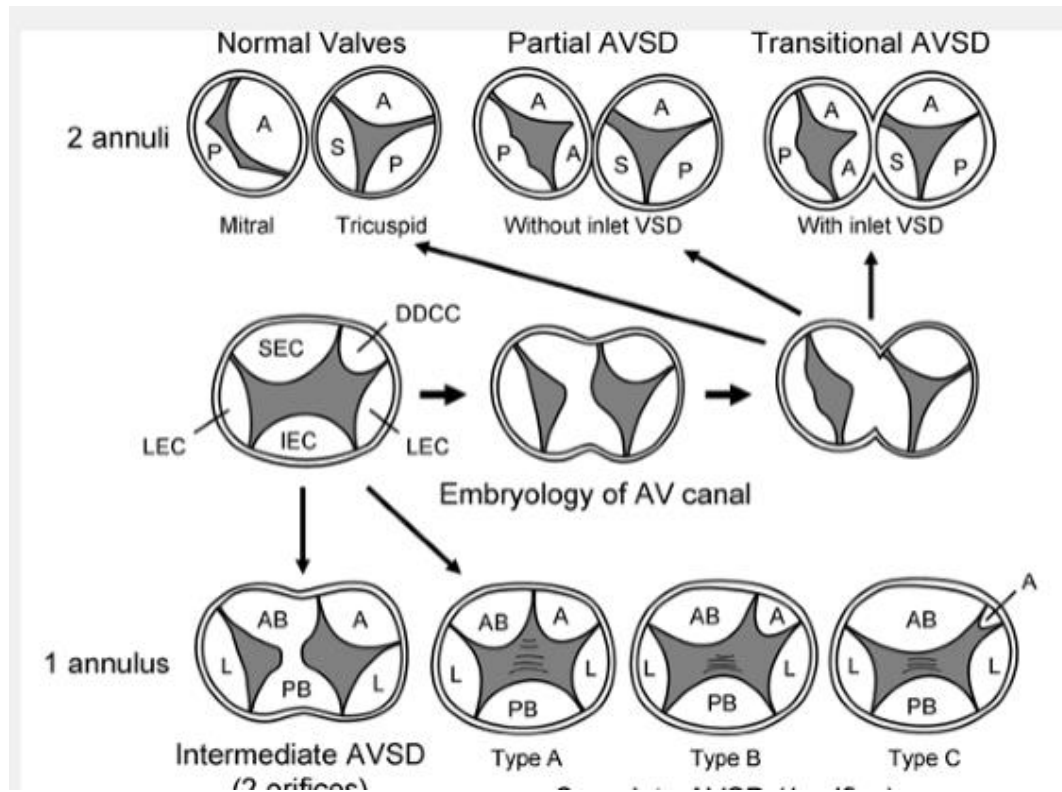


FIG 2.21

Diagram of the embryologic development of the atrioventricular canal region and the spectrum of AVSD, including partial, transitional, complete, and intermediate forms. A, anterior leaflet; AB, anterior bridging leaflet; DDCC, dextrodorsal conus cushion; IEC, inferior endocardial cushion; LEC, lateral endocardial cushion; P, posterior leaflet; PB, posterior bridging leaflet; S, septal leaflet; SEC, superior endocardial cushion; L, lateral leaflet.

- ☞ Failure of the endocardial cushions to fuse creates a defect in the atrioventricular septum.
- ☞ The primum atrial septal component of this defect is usually large.
- ☞ This results in downward displacement of the anterior mitral leaflet to the level of the septal tricuspid leaflet (Gutgesell HP,et al;1986).
- ☞ In AVSDs, the atrioventricular valves have the same septal insertion level in contrast to the leaflet arrangement in the normal heart (Fig 2.21)
- ☞ The distance from the cardiac crux to the left ventricular apex is foreshortened, and the distance from the apex to the aortic valve is increased.
- ☞ This is in contrast to the normal heart, in which the two distances are roughly equal.
- ☞ In AVSDs the disproportion between the two distances causes anterior displacement of the left ventricular outflow tract (LVOT).
- ☞ As a result, the LVOT is longer and narrower than normal and produces the gooseneck deformity. After surgical repair of the defect, progressive subaortic stenosis may develop. (Taylor NC,et al;1981).
- ☞ Since the dextrodorsal conus cushion contributes to the development of the right atrioventricular valve and the outflow tracts lie adjacent to their respective inflow tracts, AVSDs may be associated with conotruncal anomalies, such as tetralogy of Fallot and double-outlet right ventricle.
- ☞ In addition, shift of the atrioventricular valve orifice may result in connection of the valve primarily to only one ventricle, creating disproportionate or unbalanced ventricles.

2.13.4 Clinical Manifestations

- ☞ Although patients with partial AVSD may be asymptomatic until adulthood, symptoms of excess pulmonary blood flow typically occur in childhood.
- ☞ Tachypnea and poor weight gain occur most commonly when the defect is associated with moderate or severe mitral valve regurgitation or with other hemodynamically significant cardiac anomalies.
- ☞ Patients with primum ASDs usually have earlier and more severe symptoms, including growth failure, than patients with secundum ASDs.
- ☞ An uncomplicated primum ASD often is discovered in young children when echocardiography is performed to investigate a murmur.
- ☞ The murmur has typical systolic ejection qualities and is best heard over the upper left sternal border with radiation to the lung fields.
- ☞ The second heart sound is widely split and fixed during respiration. A holosystolic murmur owing to mitral regurgitation through the cleft may be heard at the apex.
- ☞ A low-pitched middiastolic murmur heard at the left lower sternal border may be present if the shunt is large or if significant mitral regurgitation is present.

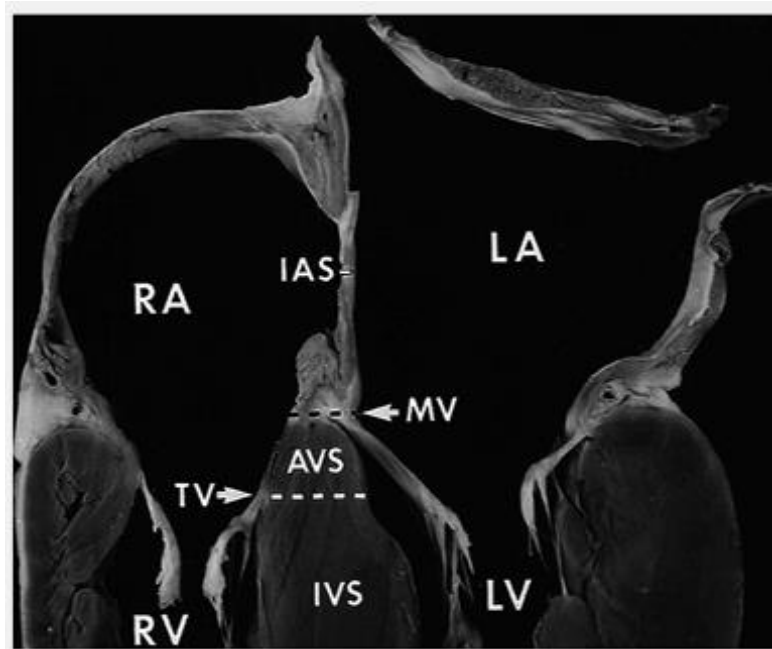


FIG 2.22

Atrioventricular septum in the normal heart (four-chamber view). The atrioventricular septum (AVS) lies between the right atrium (RA) and the left ventricle (LV) with the interatrial septum (IAS) above and the interventricular septum (IVS) below. The septal tricuspid leaflet (TV) normally inserts at a lower (more apical) level than the anterior mitral leaflet (MV). LA, left atrium; RV, right ventricle.

(Edwards WD, 1987)

2.13.4 AVSD Echocardiography

Two-dimensional echocardiography is the primary imaging technique for diagnosing AVSDs (Seward JB ,et al;1980, Silverman NH ,et al;1984, Snider RA ,et al; 1997).

It is particularly useful for delineating the morphology of the atrioventricular valves. In larger patients or in patients with associated complex abnormalities, transesophageal echocardiography can provide incremental diagnostic information. (Hugh D. Allen, et al; 2008)

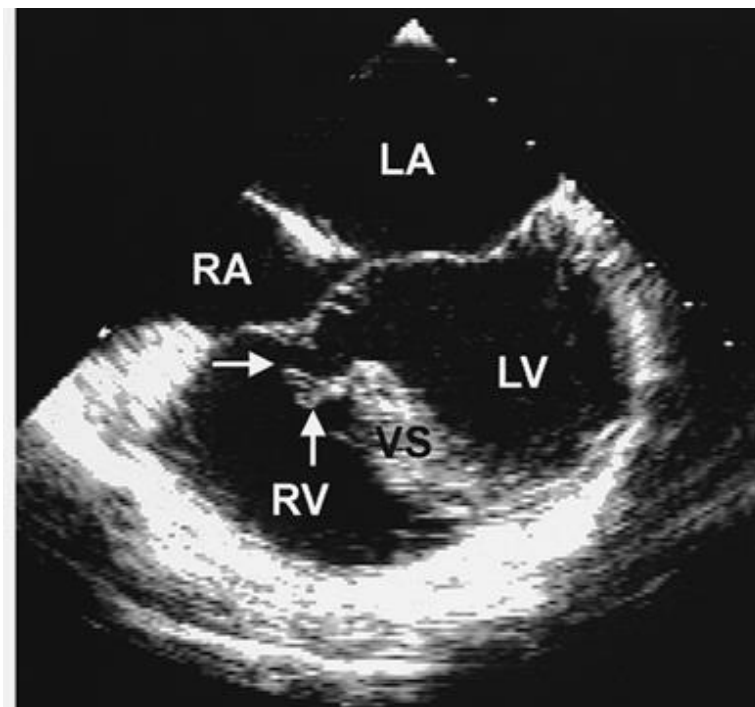


FIG 2.23

Transitional AVSD. Note the membranous aneurysm in the inflow ventricular septum (arrows).

There is a primum atrial septal defect (ASD); thus, functionally, the entity presents as a partial AVSD. There can be restrictive ventricular septal defects (VSDs) in the inflow aneurysmal membrane. This patient did not have additional features that occur in this form of AVSD, such as a restrictive VSD, parachute mitral valve, or left ventricular outflow tract (LVOT) obstruction. LA, left atrium; LV, left ventricle; RA, right atrium; RV, right ventricle; VS, ventricular septum.

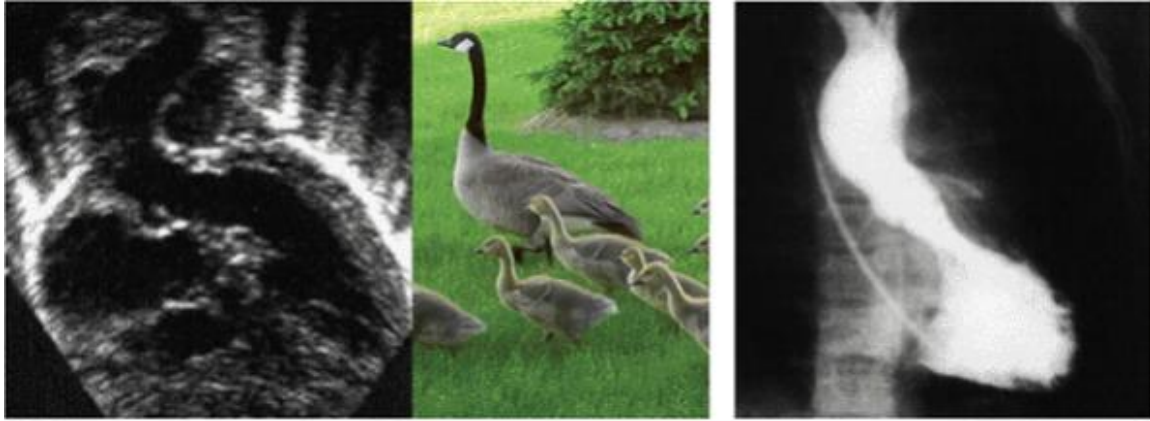


FIG 2.24

Because of the anterior displacement of the left ventricular outflow tract (LVOT) in AVSD, the elongate LVOT has been described as a goose neck with echocardiographic and angiographic imaging.

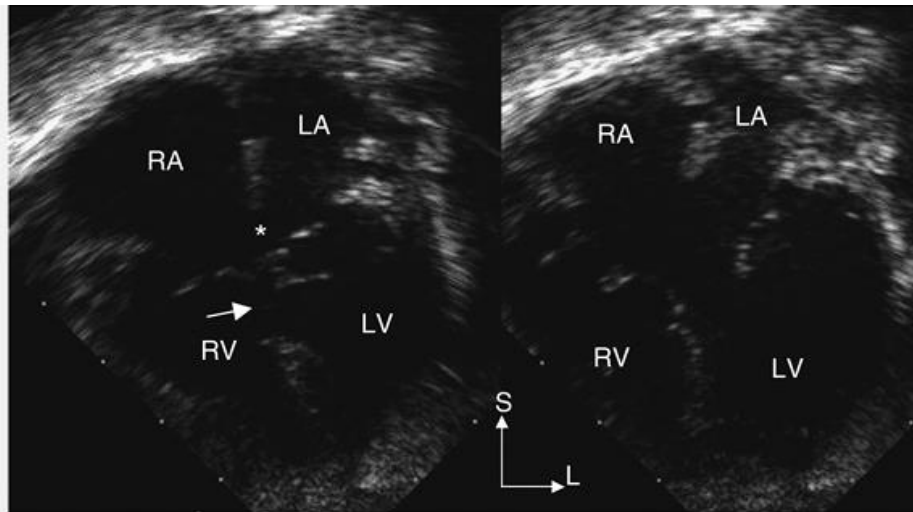


FIG 2.25

Complete AVSD: Apical four-chamber images in systole (left) and diastole (right) demonstrating a complete AVSD with large primum atrial septal defect (ASD) (asterisk), large inlet ventricular septal defect (VSD) (arrow), and common single-orifice atrioventricular valve. The right panel demonstrates the valve opening as a single unit with only lateral hinge points visible in this image.

Biventricular volume overload and a small secundum ASD are present in this

2.14 Patent Ductus Arteriosus (PDA)

The hemodynamics of PDA are similar to those of VSD. The magnitude of the left to- right shunt is determined by the resistance offered by the ductus (i.e., diameter, length, and tortuosity) when the ductus is small and by the level of PVR when the ductus is large (i.e., dependent shunt). Therefore, the onset of CHF with PDA is similar to that with VSD.

Hemodynamic consequences of PDA are similar to those of VSD.

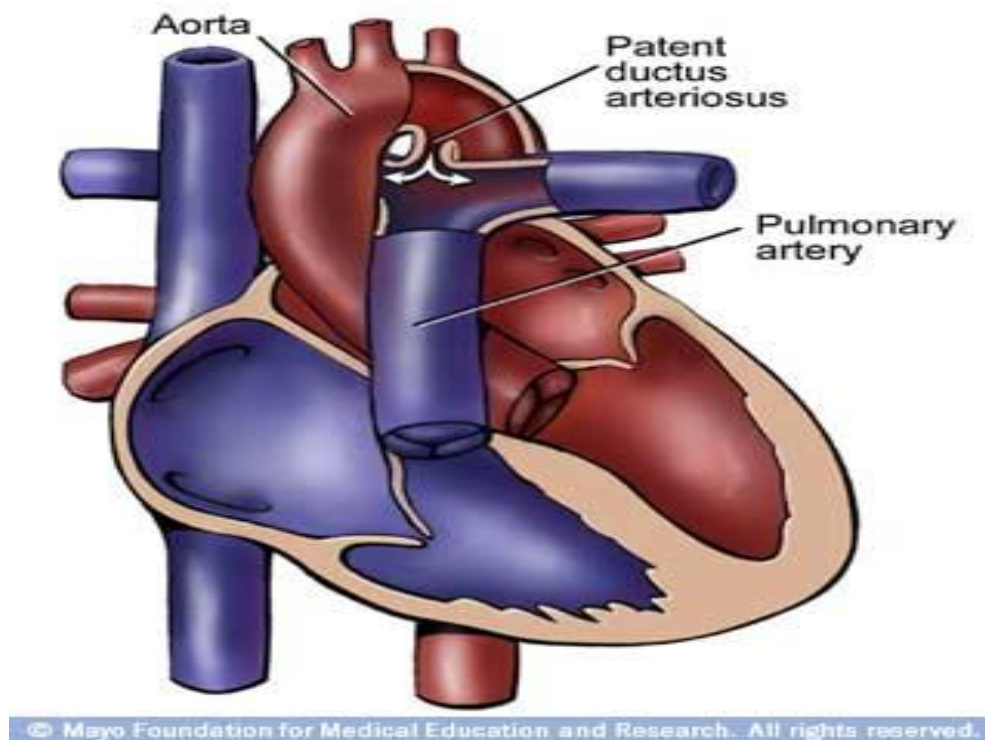


FIG 2.26

Diagram Show Patent Ductus Arteriosus

In PDA with a small shunt, the left ventricular enlargement is minimal; therefore, the ECG and chest x-ray findings are close to normal. Because there is a significant pressure gradient between the aorta and the PA in both systole and diastole, the left-to-right shunt occurs in both phases of the cardiac cycle, producing the characteristic continuous murmur of this condition. With a small shunt, the intensity of the P2 is normal because the PA pressure is normal.

In PDA with a moderately large shunt, the heart size is moderately enlarged with increased pulmonary blood flow. The chambers enlarged are the LA, LV, and PA segment.

In a large PDA, marked cardiomegaly and increased pulmonary vascular markings are present. The volume overload is on the LV and LA, which produces LVH and occasional LAH on the ECG. The free transmission of the aortic pressure to the PA produces pulmonary hypertension and RV hypertension, with resulting RVH on the ECG (Myung K. Park,2008).

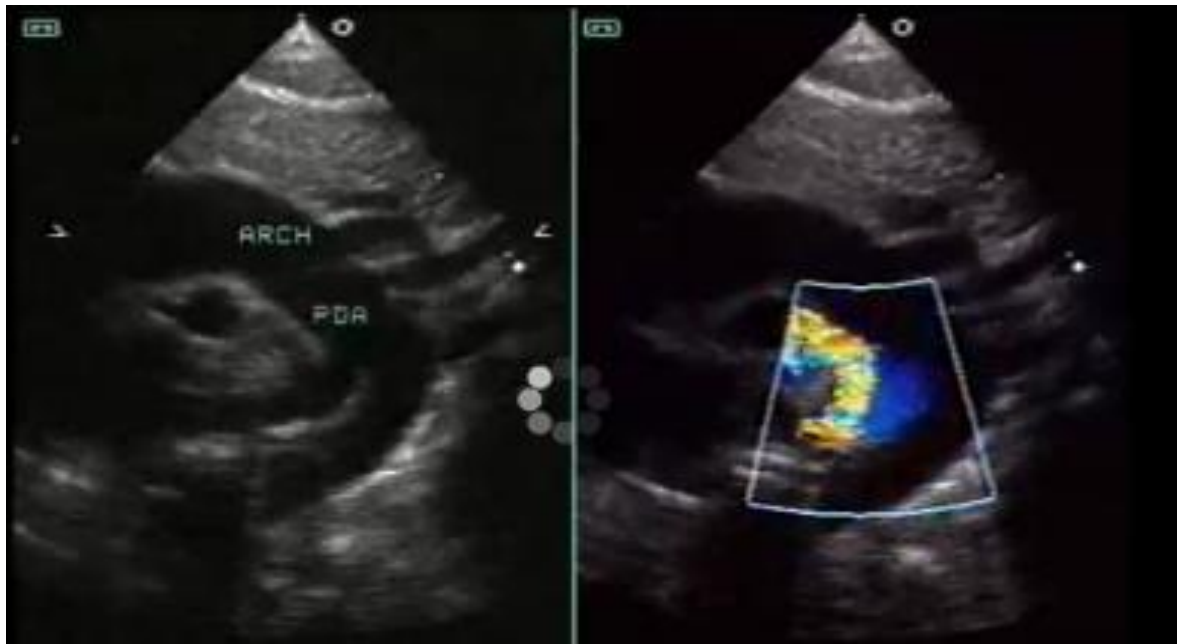

FIG 2.27

New born baby echocardiography showed: a large VSD, Overriding aorta, right ventricular hypertrophy and pulmonary stenosis. Also a large vertically oriented patent ductus arteriosus.

2.15 Obstructive & Valvular Regurgitant Lesions

Hemodynamic abnormalities of obstructive and valvular regurgitant lesions of congenital and acquired causes. For convenience, they are divided into the following three groups on the basis of their hemodynamic similarities:

1. Ventricular outflow obstructive lesions (e.g., aortic stenosis [AS], pulmonary stenosis [PS], coarctation of the aorta [COA]).
2. Stenosis of atrioventricular (AV) valves (e.g., mitral stenosis [MS], tricuspid stenosis [TS])
3. Valvular regurgitant lesions (e.g., mitral regurgitation [MR], tricuspid regurgitation [TR], aortic regurgitation [AR], pulmonary regurgitation [PR]) (Myung K. Park, 2008).

2.15.1 Obstruction to Ventricular Output

Common congenital obstructive lesions to ventricular output are AS, PS, and COA.

All these obstructive lesions produce the following three pathophysiologic changes (Fig. 28)

An ejection systolic murmur (as heard on auscultation), Hypertrophy of the respective ventricle (as seen in the ECG), Poststenotic dilatation (as seen in chest-x ray films). (This is not seen with subvalvular stenosis.).

In isolated stenosis of the pulmonary or aortic valve, the intensity and duration of the ejection systolic murmur are directly proportional to the severity of the stenosis.

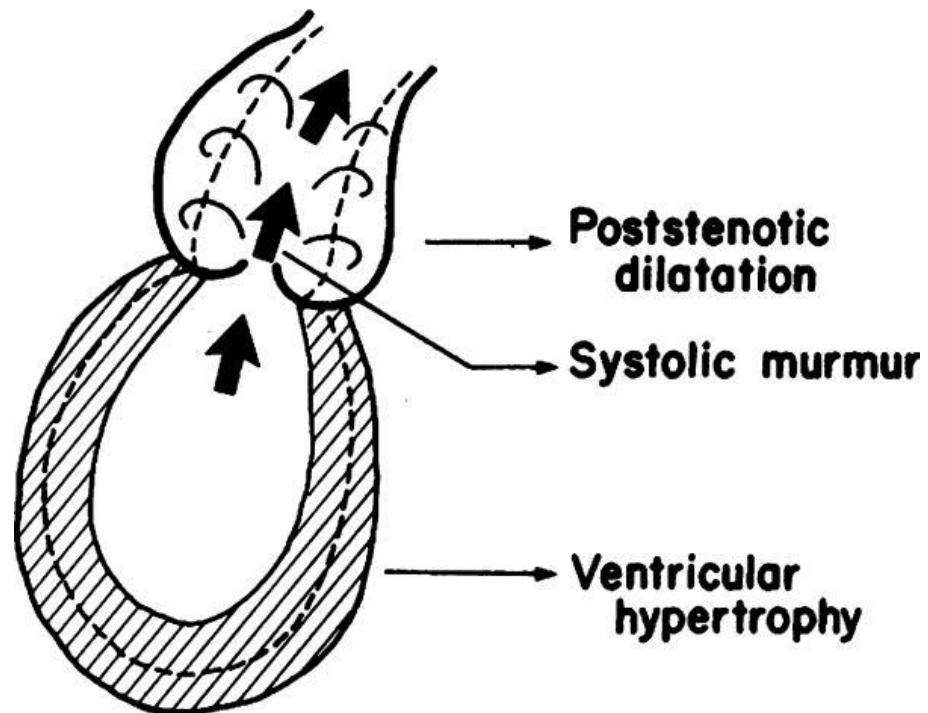


FIG 2.28

Three secondary changes are seen in aortic valve and pulmonary valve stenosis: an ejection systolic murmur, hypertrophy of the responsible ventricle, and poststenotic dilatation of a great artery. A normal-sized ventricle and a great artery are shown by broken lines. The end results of a semilunar valve stenosis are illustrated by solid lines. A similar change occurs with coarctation of the aorta.

- ☞ If the obstruction is severe, the ventricle that has to pump blood against the obstruction hypertrophies. The left ventricle (LV) hypertrophies in AS and the right ventricle (RV) in PS, which results in left ventricular hypertrophy (LVH) and right ventricular hypertrophy (RVH), respectively, on the ECG.
- ☞ Cardiac output is maintained unless myocardial failure occurs in severe cases; therefore, the heart size remains normal.
- ☞ Left ventricular (LV) outflow tract (LVOT) obstruction (LVOTO) may be defined as an obstruction to the flow of blood from the systemic ventricle to the ascending aorta that occurs as a result of a defect present at birth.
- ☞ The obstructive process can occur at any level of the systemic ventricular outflow tract, including the aorta. LVOTO often presents with numerous associated anomalies, including coarctation of the aorta, patent ductus arteriosus, ventricular septal defects, pulmonary stenosis, and mitral stenosis (Mulder DG, et al, 1968) LV chamber size can also be affected.
- ☞ Infants with LVOTO may have relative hypoplasia of the left ventricle and diffuse endothelial scarring that is also termed endocardial fibroelastosis (EFE). The clinical presentation of LVOTO depends on the anatomic site of obstruction, the age at which the child presents, and the associated cardiac abnormalities.
- ☞ The obstructive process can be classified based on the level of the narrowing of the LVOT.
- ☞ These anatomic classifications include valvular, supra-valvular, and sub-valvular stenosis.

☞ A fourth form, caused by hypertrophy of the interventricular septum, presents as a unique variety of subvalvular obstructions that varies in its physiology and treatment from other forms of stenotic lesions.

**Valvular aortic stenosis is the most common anatomic type, with deformities of both number and structure of the valve leaflets.

**Subvalvular aortic stenosis consists of a discrete membrane or muscular tunnel below the aortic valve.

**This type of obstruction will usually present in early adulthood with increasing exercise intolerance.

**Supravalvular aortic stenosis is equivalent to coarctation of the aorta with narrowing of the ascending aorta just distal to the aortic valve.

** Several inherited syndromes are often seen in association with this defect.

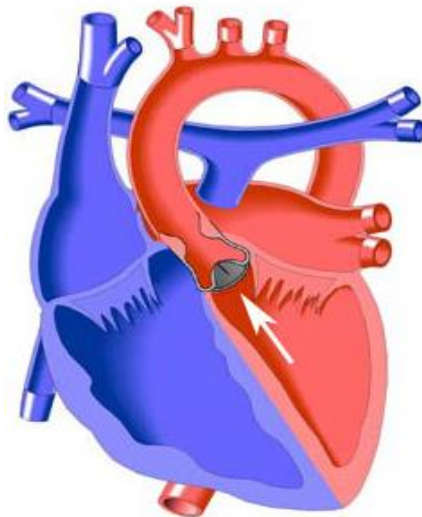


FIG 2.29

Supravalvular aortic stenosis

2.16 Valvular Aortic Stenosis

2.16.1 Natural History, Clinical Presentation, and Diagnosis

- ☞ Abnormalities of the aortic valve leaflets account for 70% to 80% of LVOTO. Stenosis of the aortic valve can present at any age, from the neonatal period to late adulthood.
- ☞ Valvular stenosis is three to four times more common in male than in female patients.
- ☞ The natural history is influenced by the age at presentation and morphology of the valve.
- ☞ Patients who present during the early neonatal period with critical aortic stenosis are usually in cardiogenic shock with severe hypoperfusion and profound acidosis.
- ☞ Critical aortic stenosis in the neonate is a serious, life-threatening lesion that is significantly different than aortic stenosis as it is commonly understood in older patients.
- ☞ This presentation results from the limited antegrade flow of blood across the LVOT and closure of the ductus arteriosus.
- ☞ Severe systemic hypoperfusion results without intervention.
- ☞ Individuals who present during this period often have anomalies of the mitral valve, hypoplasia of the LV cavity, hypoplasia of the subaortic LVOT, and coarctation of the distal aorta.
- ☞ Children who present after one year of age initially have little in the way of symptoms and generally manifest only mild exercise intolerance.
- ☞ These children do, however, have an increased risk of developing bacterial endocarditis on the abnormal valves and an ongoing risk of sudden death.
- ☞ The degree of stenosis present in children at the time of diagnosis predicts their likelihood of developing severe obstruction; only 20% of mild lesions progress in severity within 10 years, as opposed to 60% of moderate lesions that become severe within that time.

**The physiology of critical aortic stenosis in the neonate is such that the patent ductus arteriosus (PDA) can provide a substantial amount of blood flow to the aorta (Ao) by shunting right ventricular output right to left.

** This ductal-level shunt is helpful in maintaining systemic perfusion and decompressing pulmonary hypertension (which may exist until the left ventricular outflow obstruction is relieved).

**The valve leaflet morphology also dictates the presentation of the individual and the need for early intervention.

** In patients with stenosis severe enough to require operation in infancy or early childhood, the valve is bicuspid in approximately 70% of cases and consists of thickened leaflets with fusion of the anterior and posterior commissure and a slit-like orifice. In approximately 30% of cases, the valve is tricuspid, with three thickened leaflets of equal size and three recognizable commissures that are fused peripherally to varying degrees, creating a dome with a central stenotic orifice (Robicsek F, et al;1969).

***Rarely, the valve is unicuspid with only one commissure. This morphology is more common in infants presenting with severe stenosis, but occasionally the stenosis is not severe, and signs and symptoms develop in later life as the valve thickens and calcifies.

2.16. 2 Preoperative Critical Care Management

Neonates

--As stated, the course of treatment largely depends on the degree of obstruction to forward flow from the left ventricle and the presence of systemic hypoperfusion.

--Neonates that present in florid heart failure and cardiac collapse require emergent treatment and intervention.

--If the ductus arteriosus is closed, these infants demonstrate all the signs of severe low cardiac output with cold extremities, diminished pulses, pulmonary edema, acidosis, and tachypnea.

--When the diagnosis of critical aortic stenosis has been made in the neonate, prostaglandin E1 should be started to reestablish ductal-dependent systemic flow

2.17 Subvalvular Aortic Stenosis

2.17.1 Overview

- ☞ Defined as obstruction of the LVOT below the aortic valve, subvalvular stenosis occurs in 8% to 20% of patients with LVOTO.
- ☞ This type of congenital aortic stenosis morphologically consists of four subtypes: (1) a discrete membranous obstruction located anteriorly, immediately below the aortic valve;
- ☞ (2) a diffuse tunnel-like obstruction extending to include the muscular septum;
- ☞ (3) a hypertrophic cardiomyopathy;
- ☞ (4) Other unusual space-occupying lesions (such as duplication of the anterior leaflet of the mitral valve).
- ☞ Other unusual variants include accessory endocardial cushion tissue and anomalous chordal and papillary muscle insertion on the interventricular septum (Wright PW, et al,1983).

**Discrete subvalvular stenosis rarely presents in infancy, with most occurring in children and young adults.

- ☞ The obstruction consists of a diaphragm of muscular or fibrous tissue just below the aortic valve.
- ☞ The membrane is circular or crescentic, attaching to the interventricular septum and extending around the outflow tract to involve the anterior leaflet of the mitral valve.
- ☞ Historically considered an acquired form of aortic stenosis, there is evidence that an abnormal angulation of the connection between the left ventricle and the aorta may establish a flow pattern that forms the substrate for this lesion.
- ☞ **A subaortic discrete** membrane can be seen in association with a ventricular septal defect or after a ventricular septal defect that has spontaneously closed.
- ☞ The membrane creates abnormal blood flow jets that can lead to valvular insufficiency by preventing normal leaflet motion.
- ☞ Patients generally present with an asymptomatic murmur or increasing exercise intolerance.
- ☞ Indications for surgical intervention include a gradient of greater than 40 mm Hg, progressive aortic insufficiency, and/or symptoms associated with LVOTO.

2.18 Supravalvular Aortic Stenosis

2.18.1 Overview

- ☞ Left ventricular outflow tract obstruction can occur above the aortic valve at the level of the sinotubular junction or proximal ascending aorta.
- ☞ Supravalvular stenosis is the least common type of LVOTO, presenting in three distinct fashions: as part of Williams syndrome, in a sporadic form, or in a familial form transmitted as an autosomal dominant trait.

☞ The underlying defect in the sporadic form is a spontaneous inherited mutation of the elastin gene.

☞ When infants present with symptomatic supravalvular stenosis, it is most often in the familial form. In patients who present with asymptomatic supravalvular stenosis, as many as 50% have the defect as part of Williams syndrome.

**In 1961, Williams and associates described the association of supravalvular aortic stenosis, mental retardation, and elfin faces in a syndrome that now bears the author's name(Cornell WP, et al,1996).

**Subsequently, the presence of severe infantile hypercalcemia and pulmonary stenosis has been added to the syndrome(Garcia RE ,et al ;1964).

**The first surgical correction was reported in 1961 by McGoon and colleagues(Mc Goon DC,et al,1961) in which the stenotic aortic segment was enlarged by patching along the defect.

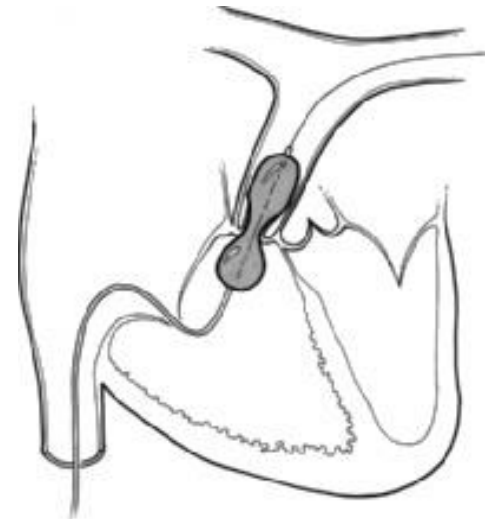
**Other repairs have since been described, most of which entail a more radical augmentation and/or resection of the diseased segment of aorta.

2.19 Pulmonary Stenosis

Pulmonary stenosis occurs at three sites in the right heart outflow area:

below the pulmonary valve (infundibular), at the level of the valve (valvar), or above the valve (supravalvar).

Infundibular pulmonary stenosis rarely occurs as an isolated lesion. Supravalvar stenosis or stenosis of the individual pulmonary arteries is also uncommon.



In most patients, obstruction occurs at the level of the pulmonary valve. Regardless of the anatomic type of stenosis, the results are similar. Blood flow through the stenotic area is turbulent and leads to murmurs.

2.19.1 Valvar pulmonary stenosis

In the usual form of pulmonary stenosis, the valve cusps are fused; and the valve appears domed in systole. A small central orifice and poststenotic dilation are found.

2.19.1.1 Echocardiography

Similar to aortic valvar stenosis, cross-sectional echocardiography shows thickened and doming pulmonary valve leaflets.

Poststenotic dilation of the main pulmonary artery and ductus “diverticulum” is potentially dramatic.

Doppler reveals turbulent high-velocity flow through the pulmonary valve; the maximum velocity allows estimation of the pressure gradient between the right ventricle and the pulmonary artery.

Right ventricular hypertrophy may occur, but quantitation is more difficult than in left ventricular hypertrophy, partly because of the geometry of the right ventricle and of the opposition between the right ventricular wall and the chest wall, making differentiation of the boundary between the two structures problematic.

However, hypertrophy of the infundibulum, the tubular right ventricular outflow tract, can become severe and is easily demonstrated by cross-sectional echocardiography as the muscular walls squeeze the pathway virtually closed by the end of each systole(Walter H. Johnson,et al ,2008)

2.19.2 Subvalvar Pulmonary Stenosis

- ☞ Most frequently, the substrate of obstruction is in the immediately subvalvar area of the right ventricular outflow tract.
- ☞ In congenitally malformed hearts, this is usually seen in association with a ventricular septal defect.

Tubular muscular obstruction of the subpulmonary outflow tract is unusual except when there is an associated septal defect.

Isolated obstruction of the outflow tract can also be produced by an anomalous muscle bundle, usually a hypertrophied septoparietal trabeculation.

This pattern is often called ‘two chambered right ventricle’. Even rarer as a cause

of subpulmonary obstruction is the finding of pouches of accessory tricuspid valvar tissue that prolapse into the outflow tract during systole, or accessory valvar leaflets derived from the tricuspid valve that have attachments directly in the outflow tract.

Such fibrous windsocks can also be derived from the valvar tissues guarding the openings of the inferior caval vein or coronary sinus within the right atrium or from an aneurysmal membranous septum.

2.20 Coarctation of Aorta (COA)

Coarctation of Aorta (COA) and interruption are obstructive anomalies of the aortic arch. Coarctation of the aorta is a hemodynamically significant narrowing of the thoracic aorta, directly opposite, proximal, or distal to the ductus arteriosus, resulting in a pressure gradient (Fig 2.30).

(David G. Nichols,et al,2006).

True coarctation is a distinct, shelf-like thickening or infolding of the aortic media into the lumen of the aorta (Sinha SN , et al,1969).

It is distinguished from hypoplasia of the aortic isthmus, previously referred to as “preductal” coarctation.

Aortic hypoplasia is defined as a narrowed diameter of an aortic segment with a normal aortic media. An atretic arch refers to two patent ends with an interposed ligamentous strand.

Aortic interruption consists of complete discontinuity between two parts of the aortic arch. In almost all cases, there is an associated ventricular septal defect (VSD), and the patent ductus arteriosus provides blood flow to the distal aorta(Backer CL, et al,2000).

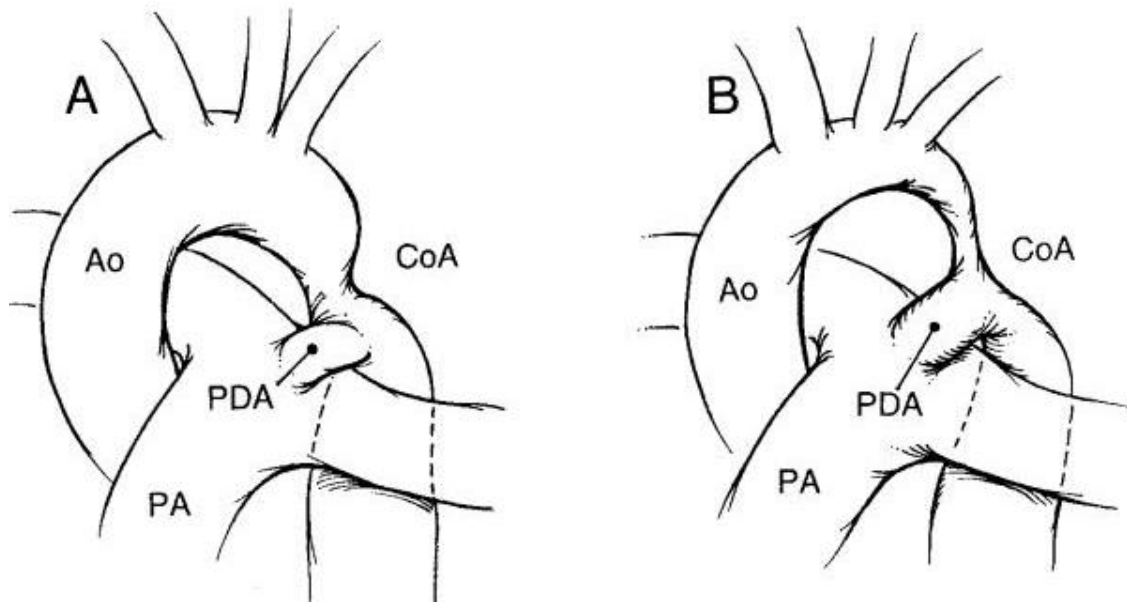


FIG 2.30

A, Representation of isolated coarctation of the aorta (CoA). The coarctation is most typically proximal to the patent ductus arteriosus (PDA) or ligamentum arteriosum. B, Aortic arch hypoplasia frequently accompanies CoA but can be found independently. Ao, aorta; PA, pulmonary artery.

Echocardiogram

- 👉 Cross-sectional images of the aortic arch, usually best obtained with the transducer positioned near the suprasternal notch, reveal narrowing at the site of coarctation and, in some patients, relative hypoplasia of the transverse segment of the aortic arch, extending from the ascending aorta to the coarctation.

- ☞ The proximal thoracic descending aorta just distal to the coarctation may be normal in size or may be slightly dilated, representing poststenotic dilation.
- ☞ Color Doppler shows a disturbed (turbulent) signal at the stenosis, and spectral Doppler shows high-velocity flow from the transverse aortic arch to the descending aorta with a continuous pattern (extending from systole into diastole).
- ☞ In neonates, the diagnosis may be difficult as long as the ductus arteriosus remains large.
- ☞ The flow through a ductus in a neonate with coarctation is bidirectional, often predominantly right to left (pulmonary artery to aorta), which is an important echocardiographic clue to the diagnosis.
- ☞ The echocardiogram provides rapid assessment of left ventricular hypertrophy, size, and function and also allows diagnosis of possible associated lesions, such as bicuspid aortic valve, mitral valve malformations, and ventricular septal defect (Walter H. Johnson, et al, 2006).

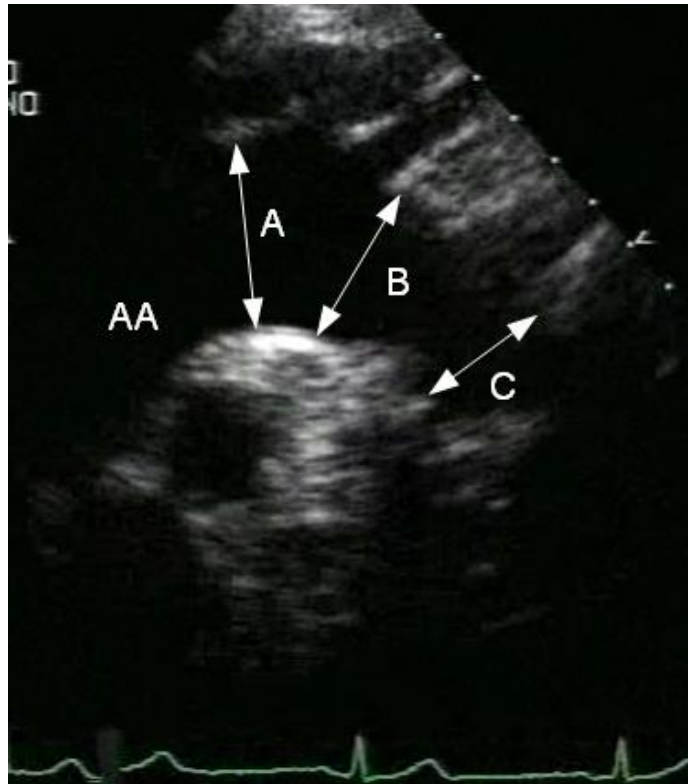


FIG 2.31

Aortic arch, 2D.

In 2D mode, with the transducer in the suprasternal notch, the long axis of the aortic arch is visualized with a 30°-45° leftwards (clockwise) rotation of the transducer. The anonymous, left carotid and left subclavian supra-aortic branches are often visualized. The proximal (A, just before the anonymous branch), intermediate (B, after the left carotid branch), and distal (C, just distal to the left subclavian branch) diameters of the aortic arch are measured between the superior and inferior inner borders (intima) of the aortic walls. AA: distal thoracic ascending

aorta.(http://www.echobyweb.com/htm_level3_outofstructure/formulas&calculations/aortic_root_ar

ch_eng.htm)

2.21 Obstructive (Stenotic) Lesions of the Mitral Valve

- ☞ Congenital obstruction may occur with functional or anatomic alterations of any component of the mitral valve.
- ☞ Classically, a segmental approach to analysis of congenital mitral stenosis has been used, although medical and surgical treatment may be more functionally oriented (Davachi F, et al, 1971).
- ☞ Most cases involve abnormalities of several components of the mitral valve (Ruckman RN, et al, 1974)

Supravalvular Mitral Ring

- ☞ This lesion is caused by the presence of extra left atrial connective tissue, enshrouding the mitral valve and causing an obstruction to transvalvular flow.
- ☞ It is attached at the level of the annulus or just above the annular ring (Sullivan ID, et al; 1986).
- ☞ This tissue can be directly adherent to the leaflets, fixing them in position, or can be on the adjacent tissues constraining leaflet motion (Coto EO, et al, 1976)
- ☞ This lesion is usually associated with other defects, including parachute mitral valve, subaortic stenosis, and aortic coarctation. (Anabtawi IN, et al, 1965, Rosenquist GC, 1974, Shone JD, et al, 1963).
- ☞ The subvalvular apparatus is usually abnormal, resulting in severe obstruction to flow; this lesion should always be considered when a child presents with signs of left-sided heart obstruction (Collins-Nakai RL, et al, 1977)

- ☞ The ring acts to constrain leaflet motion, providing a small orifice for cardiac output to flow through(Sullivan ID,et a,1986).
- ☞ There is often a single eccentric opening in the membrane.
- ☞ Relief of obstruction at the valvular level usually can be obtained by removal of the ring, which results in increased leaflet motion.
- ☞ Subvalvular anomalies can cause persistent obstruction and be more difficult to alleviate.

2.22 Regurgitant Lesions of the Mitral Valve

- ☞ Isolated insufficiency of the mitral valve is rare and is associated with underlying states such as connective tissue disorders and metabolic or storage diseases.
- ☞ Mitral insufficiency is more commonly present with other cardiac anomalies, such as endocardial cushion defect, ventricular septal defects, patent ductus arteriosus, and anomalous left coronary artery.
- ☞ Acquired valvular incompetence during childhood is due to diverse causes that include trauma, endocarditis, rheumatic fever, and collagen vascular diseases such as Kawasaki's disease. Any process leading to left ventricular dysfunction and altered ventricular geometry, such that the mitral apparatus no longer coapts properly, can result in mitral regurgitation.
- ☞ Mitral valve prolapse (myxomatous) is the most common cause of significant mitral incompetence for adults in developed countries; however, it is rarely the cause of significant regurgitation in infants and children.
- ☞ The leaflet tissue is redundant, and the most common site of prolapse is the middle portion of the posterior leaflet.

- ☞ Valve repair for this lesion has proven to be safe and durable; it consists of resection of prolapsed leaflet segment, leaflet reconstruction, and annuloplasty.

2.22.1 Echocardiography

- ☞ Echocardiography has become the principal modality for diagnosing mitral regurgitation (MR).
- ☞ Two-dimensional and B-mode echocardiography allow for the diagnosis of mitral regurgitation and provide insight into the anatomic basis of regurgitation; these modalities also provide valuable information about ventricular function and the presence of other associated anomalies.
- ☞ Progressive increase in atrial or ventricular dimensions also can be determined and is an important consideration concerning operative timing (David G .Nichols, et al,2006).
- ☞ Doppler analysis provides information related to regurgitant flow, including the direction of regurgitation and quantification, which depends on the length and width of the regurgitant jet (into the left atrium).
- ☞ Alone, echocardiography can provide sufficient information to proceed to valve surgery.
- ☞ Transesophageal echocardiography provides better resolution of the mitral mechanism and should be utilized prior to operative intervention and perioperatively in the operating room to evaluate repaired valve function.
- ☞ Development of three-dimensional echocardiography holds the promise of improved delineation of anatomy and more accurate determination of regurgitant fraction.

IN conclusion

- 👉 Isolated mitral valve pathology is rare in childhood.
- 👉 Symptomatology and presentation are related to the degree of regurgitation or stenosis and acuity of onset.

2.23 Sonographic Evaluation of the Heart (Echocardiography)

Echocardiography has emerged as the principal tool for noninvasive assessment of the cardiovascular system.

The basic principles of echocardiography, including the mechanical features of echocardiographic equipment, are no different from diagnostic ultrasound in general.

Nevertheless, there are aspects of echocardiography that set it apart from general ultrasonography.

Because the heart is a moving organ, and because echocardiography

must additionally capture that movement, an understanding of echocardiography requires an understanding of both cardiac anatomy and physiology.

This chapter reviews the basic principles of echocardiography and serves as a basis for understanding the specific disease processes discussed in the remainder of this text.

There are substantially different echocardiographic approaches for patients with congenital heart lesions and that used to evaluate other forms of cardiac disease.

Children imaging has advantages and disadvantages when compared with adults.

An enhanced image quality will be produced due to use of higher frequency transducers because of small patient size. The presence of less heavily calcified bone and the absence of windows and generally contribute to improved image quality. (Feigenbaum et al,2005).

The properties of ultrasound permit real-time generation of cardiac anatomical and hemodynamic data.

Improvements in transducer design and imaging modalities have led to improved image quality.

The addition of doppler ultrasound to 2d echocardiography provides reliable noninvasive determination of velocity shifts and pressure gradients within and across cardiac chambers. echocardiographic data is influenced by limitations intrinsic to ultrasound and doppler technology, patient characteristics, and operator skill.

2.24 Transthoracic Echocardiography (TTE)

- ☞ A full echocardiographic study involves a complete description of cardiac anatomy, valvar function, and cardiac systolic and diastolic function.
- ☞ Transthoracic windows are excellent in the majority of infants and children, so that interrogation from these windows can provide all anatomical, haemodynamic, and functional information required for diagnosis and treatment of most of the congenital and acquired cardiac lesions encountered by the paediatric echocardiographer.
- ☞ The majority of children are currently referred for cardiac surgery based only on transthoracic echocardiographic studies.
- ☞ For those aged between 3 months and 3 years, however, lack of co-operation can be a limiting factor, and sedation is generally required to permit performance of an adequate echocardiographic study.
- ☞ Transoesophageal imaging in children is mostly limited to peri-operative imaging.

2.24.1 Anatomic Segmental Approach for Congenital Cardiac Malformations

Defining Anatomy: Segmental Approach

The echocardiographic examination is performed, and the interpretation is presented using a segmental approach (Angelini P, et al;1988, Kovalchin JP ,et al ;1997), which requires complete definition of eight features of cardiac anatomy (Table.3). Accurate morphology can be accomplished definitively only by imaging chamber septal structures. Next, other malformations (e.g., cardiac shunts, valve function) and physiology (biventricular function, chamber sizes, pressure estimates) are described. To ensure that no anatomy or physiology is left undescribed, it is helpful during both the performance and interpretation of the examination to imagine the course of a red blood cell traveling through the heart, beginning in the systemic veins and terminating in the systemic arteries.

2.24.1.1 Sequential Segmental Analysis

For evaluating patients with suspected congenital heart disease, it is helpful to consider the heart as a segmented structure represented by three regions (Fig-32) atria, ventricles, and great arteries (Van Praagh R ,1984, Anderson RH ,et al,1984, Van Praagh R.,1972, de la Cruz MV et al, 1972).

- ☞ Each region, in turn, is partitioned into two components, usually right-sided and left-sided.
- ☞ Atrio ventricular valves serve as connectors between atria and ventricles, and semilunar valves join the ventricles to the great arteries.
- ☞ There are only a limited number of possible connections between the three major regions, regardless of their spatial orientations.

☞ In practice, each region is evaluated independently, following the direction of blood flow: (a) systemic and pulmonary veins, (b) atria, (c) atrioventricular valves, (d) ventricles and right ventricular outflow tract (infundibulum or conus), (e) semilunar valves, and (f) great arteries.

**In a systematic manner, right-sided and left-sided structures at each level are evaluated according to their morphology, their relative positions, their connections to proximal and distal segments, and the presence and location of shunts, obstructions, and valvular regurgitation (Edwards WD;1989).

**This constitutes the sequential segmental method for the investigation of congenital heart disease, and it represents a diagnostic cornerstone both for clinicians and for pathologists. Before applying this method, however, it is important to determine the cardiac position and the visceral situs (sidedness).

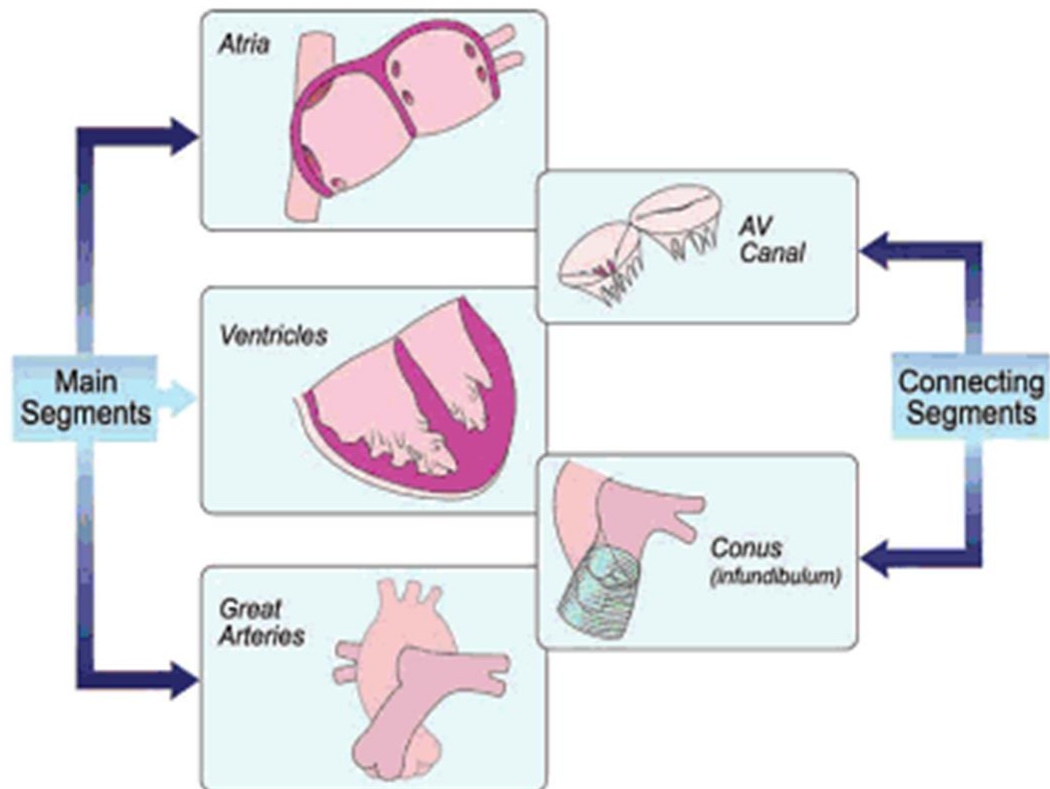


FIG 2.32 Show the heart as a segmented structure.

2.25 Echocardiography Technique

2.25.1 Echocardiographic Windows

- ☞ There are four major echocardiographic windows to the heart (Fig 2.34&2.35):
- (a) parasternal.
 - (b) apical
 - (c) subcostal
 - (d) suprasternal notch.
 - (A fifth window, the right parasternal window, obtained with the patient in a right lateral decubitus position, is used for obtaining an accurate Doppler gradient in patients with aortic stenosis.)
- ☞ The examination usually is performed in this same order, beginning with the least noxious parasternal window and finishing with the potentially most noxious suprasternal notch window.
- ☞ In complex cases associated with abnormal situs or cardiac position, the examination may alternatively begin with the apical or subcostal windows so that the echocardiographer can become oriented for the other views (David G. Nichols, et al, 2006).

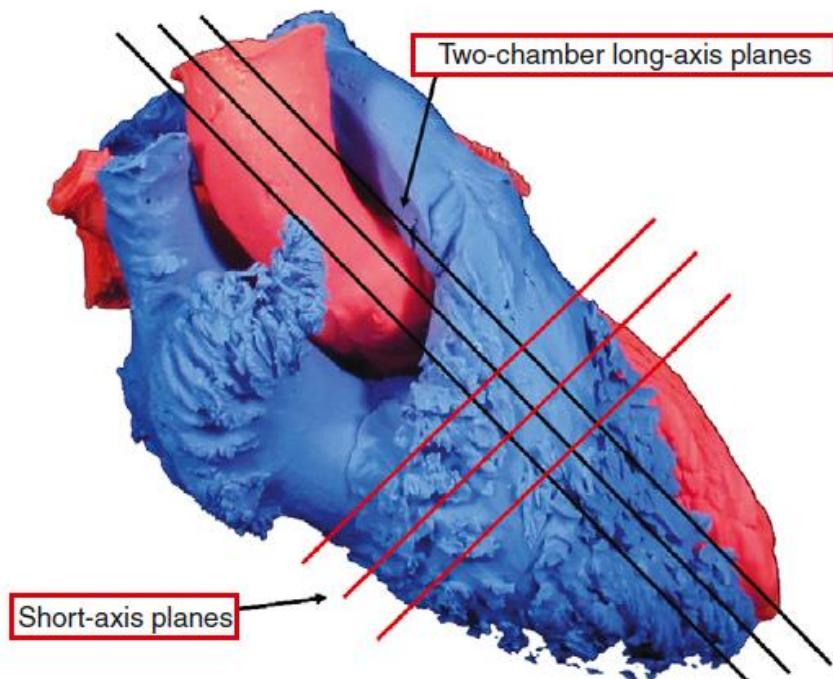


FIG 2.33

The heart can also be described in terms of its orthogonal planes, albeit that these are skewed relative to the long-axis planes of the body.

The image shows the long-axis planes that cut through two chambers of the heart, along with the short-axis planes. The third series of planes, in the long axis, are in the plane of the image itself.

They produce the so-called four chamber cuts.

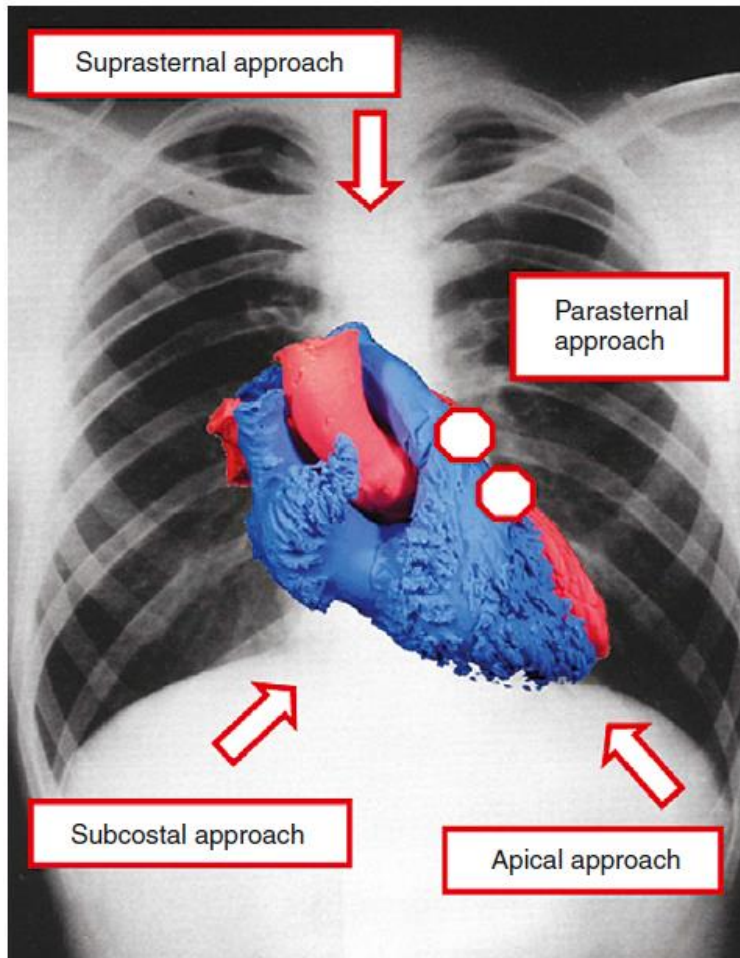


FIG 2.34

The image shows the location of the echocardiographic windows that permit visualization of cardiac anatomy

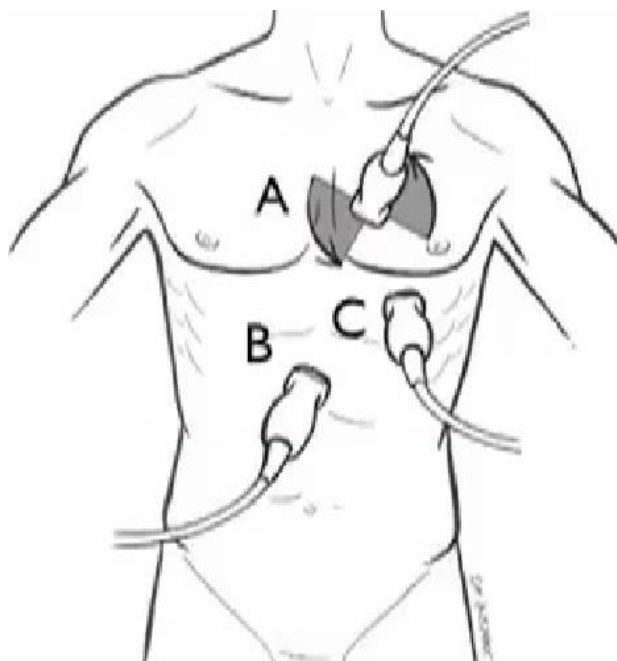


FIG2.35

Probe Position For:

- A) Parasternal Views Long/Short axis.
- B) Subxiphoid view
- C) Apical view.

2.25.2 Parasternal Long-Axis View (PLAX)

Transducer position: left sternal edge; 2nd – 4th intercostal space

Marker dot direction: points towards right shoulder

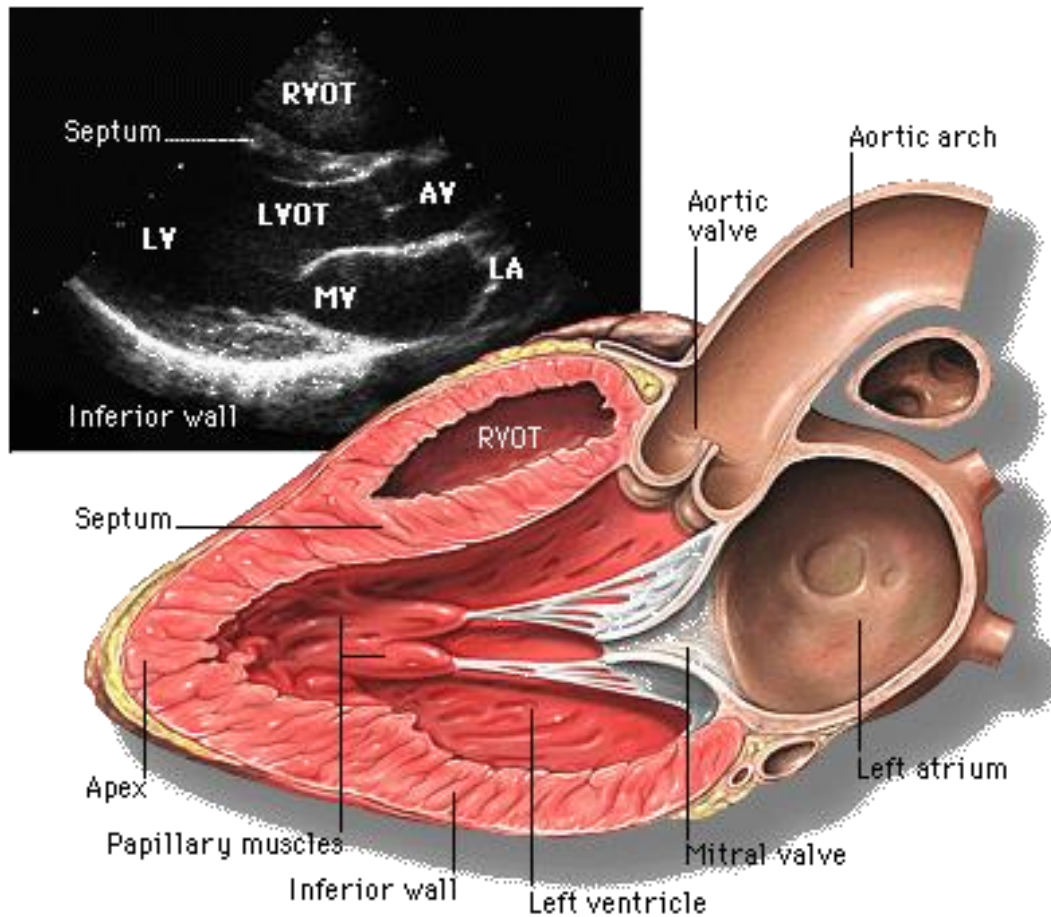


FIG.15

Parasternal Long-Axis View (PLAX)

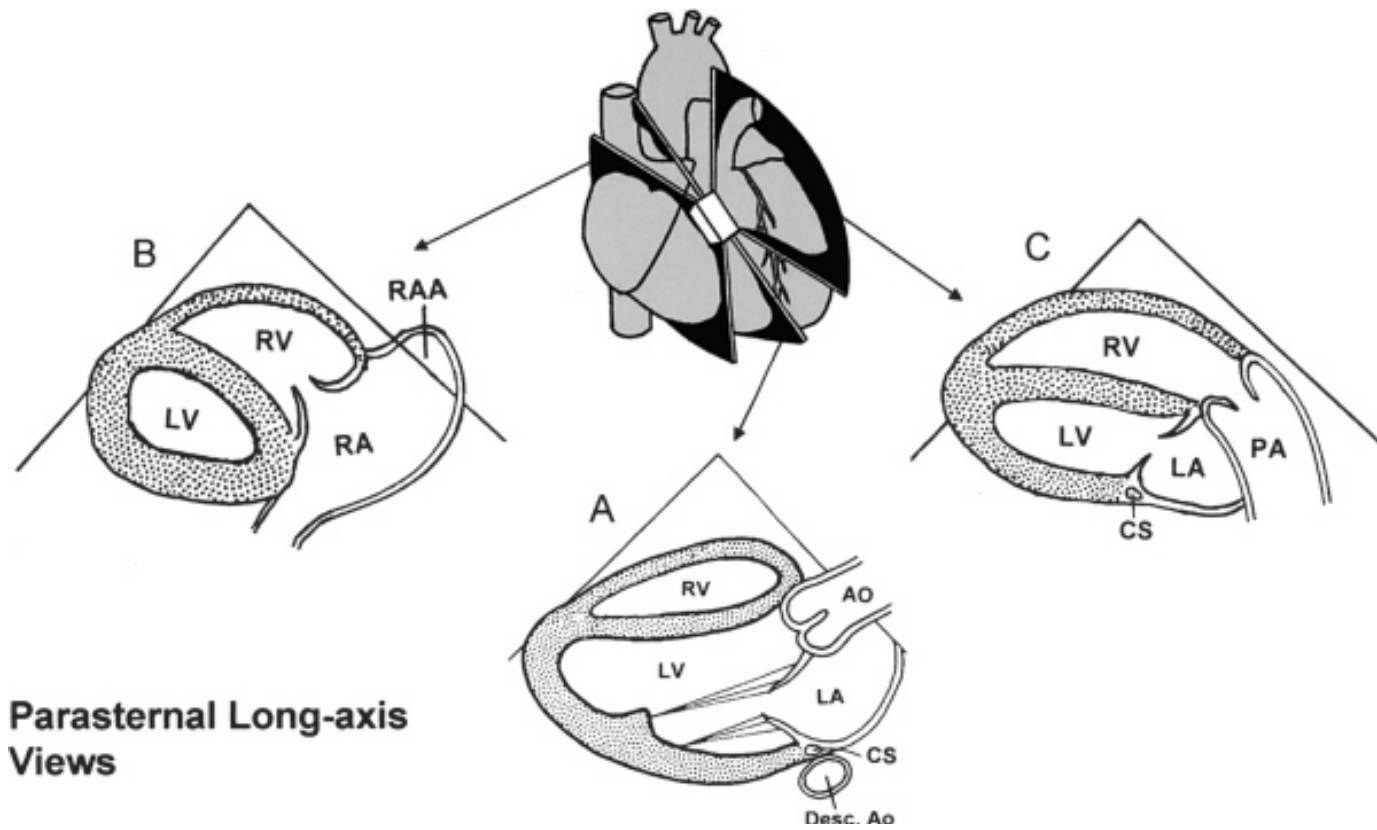


FIG 2.36

Diagram of important two-dimensional echo views obtained from the, parasternal long-axis transducer position. Standard long-axis view (A), RV inflow view (B), and RV outflow view (C). AO, aorta; CS, coronary sinus; Desc. Ao, descending aorta; LA, left atrium; LV, left ventricle; PA, pulmonary artery; RA, right atrium; RAA, right atrial appendage; RV, right ventricle.

2.25.3 Parasternal Short-Axis View (PSAX)

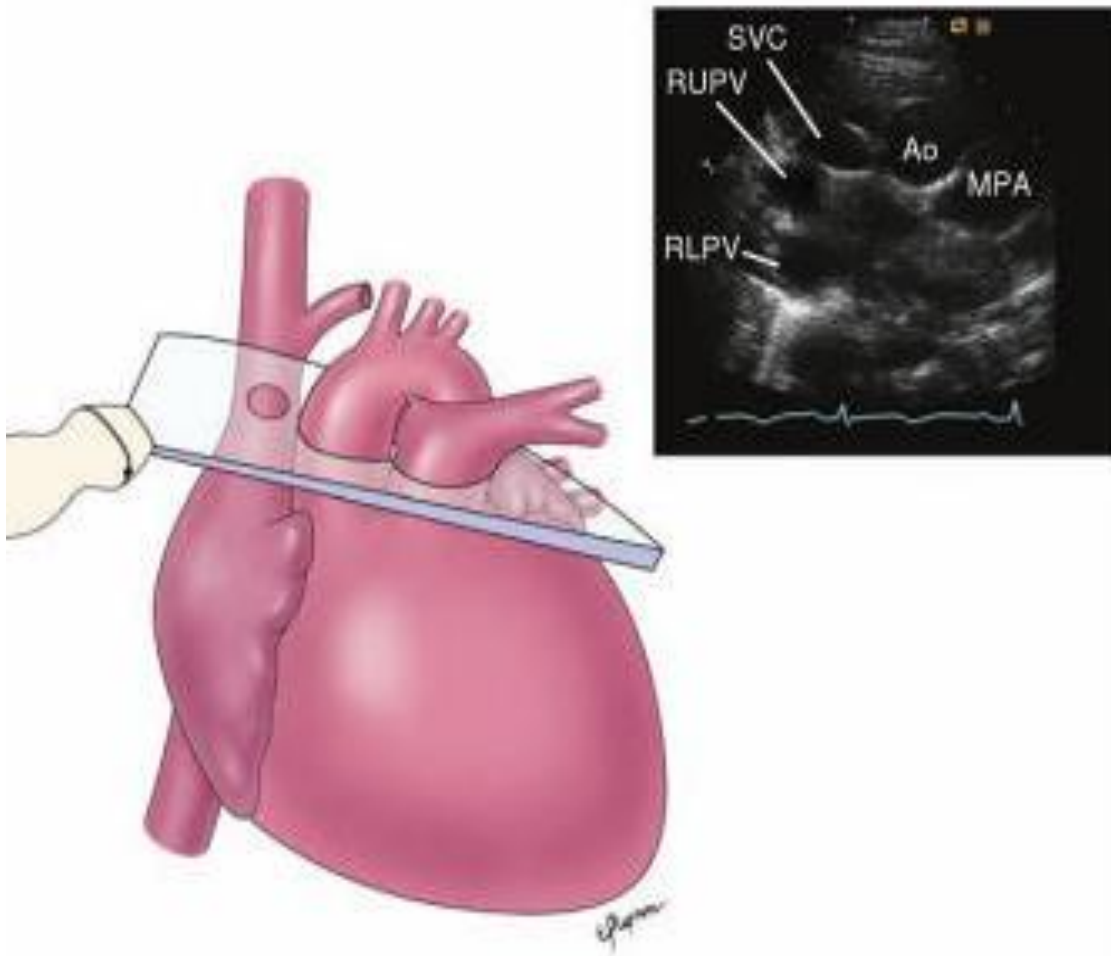


FIG 2.37

Image of right parasternal short-axis view: Ao Aorta, MPA main Pulmonary Artery, RLPV Right Lower Pulmonary Vein, RUPV Right Upper Pulmonary Vein, SVC Superior Vena Cava.

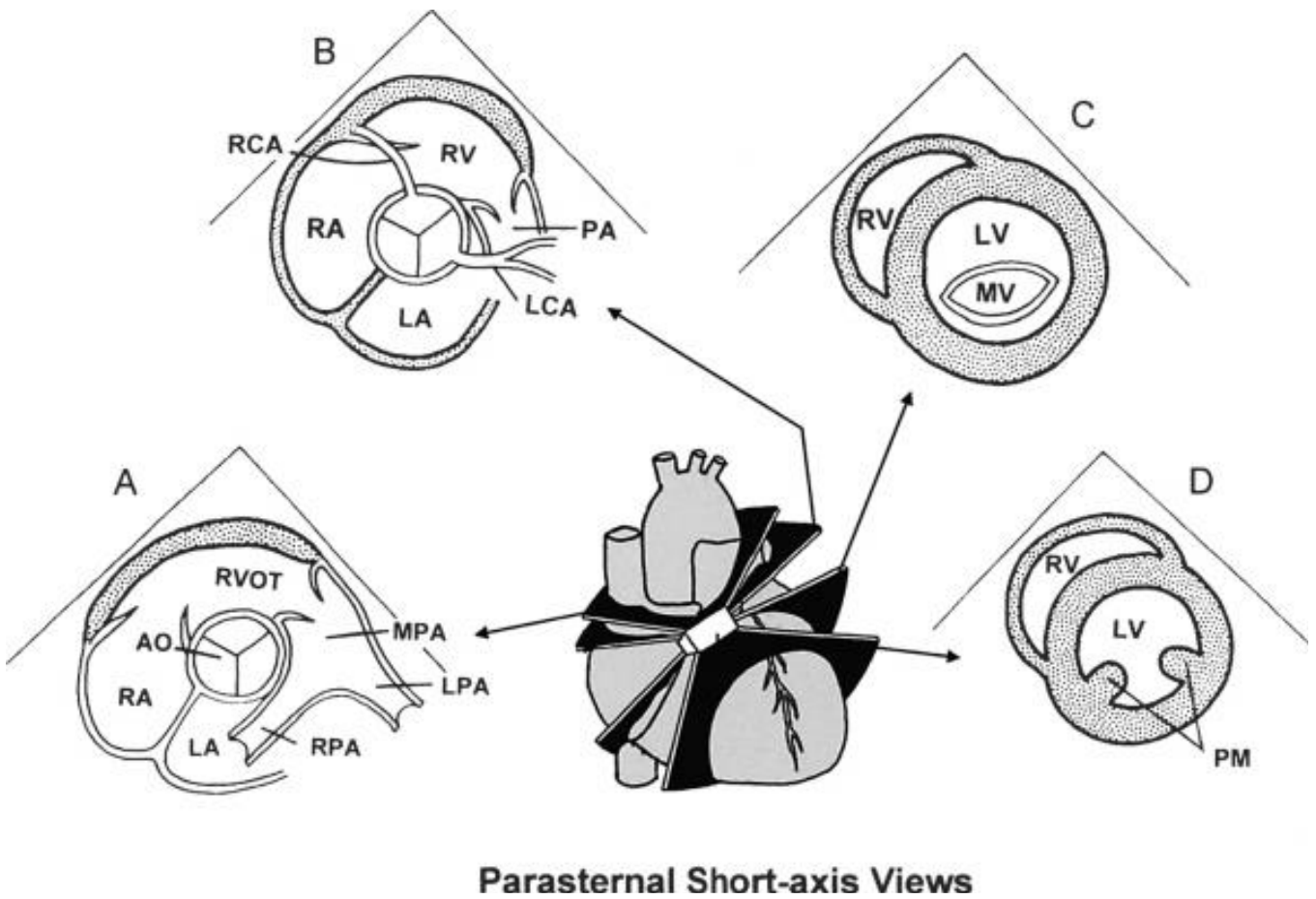


FIG 2.38

Diagram of a family of parasternal short-axis views. Semilunar valves and great artery level (A), coronary arteries (B), mitral valve level (C), and papillary muscle level (D). AO, aorta; LA, left atrium; LCA, left coronary artery; LPA, left pulmonary artery; LV, left ventricle; MPA, main pulmonary artery; MV, mitral valve; PM, papillary muscle; RA, right atrium; RCA, right coronary artery; RPA, right pulmonary artery; RV, right ventricle; RVOT, right ventricular outflow tract.

2.25.4 Apical 4-Chamber View (AP4CH)

Transducer position: apex of heart

Marker dot direction: points towards left shoulder

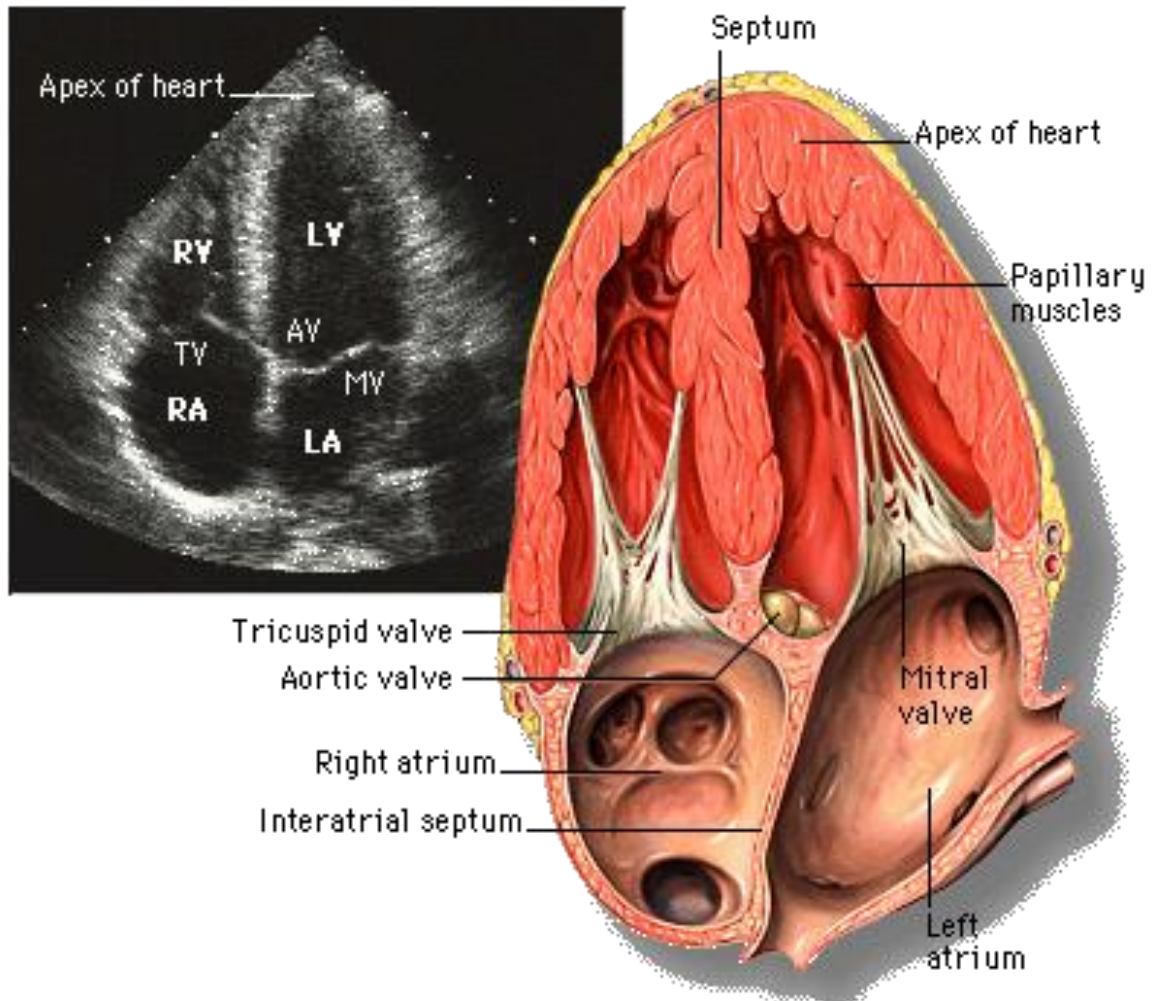


FIG 2.39

Note:

The AP5CH view is obtained from this view by slight anterior angulation of the transducer towards the chest wall. The LVOT can then be visualized.

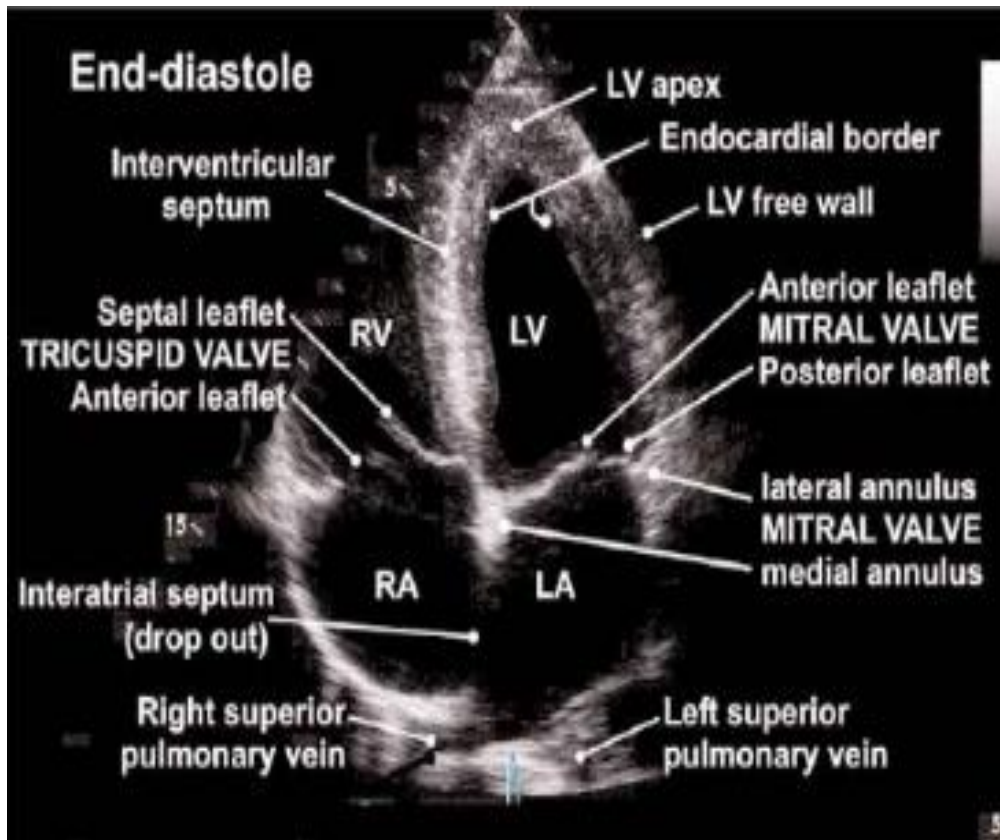
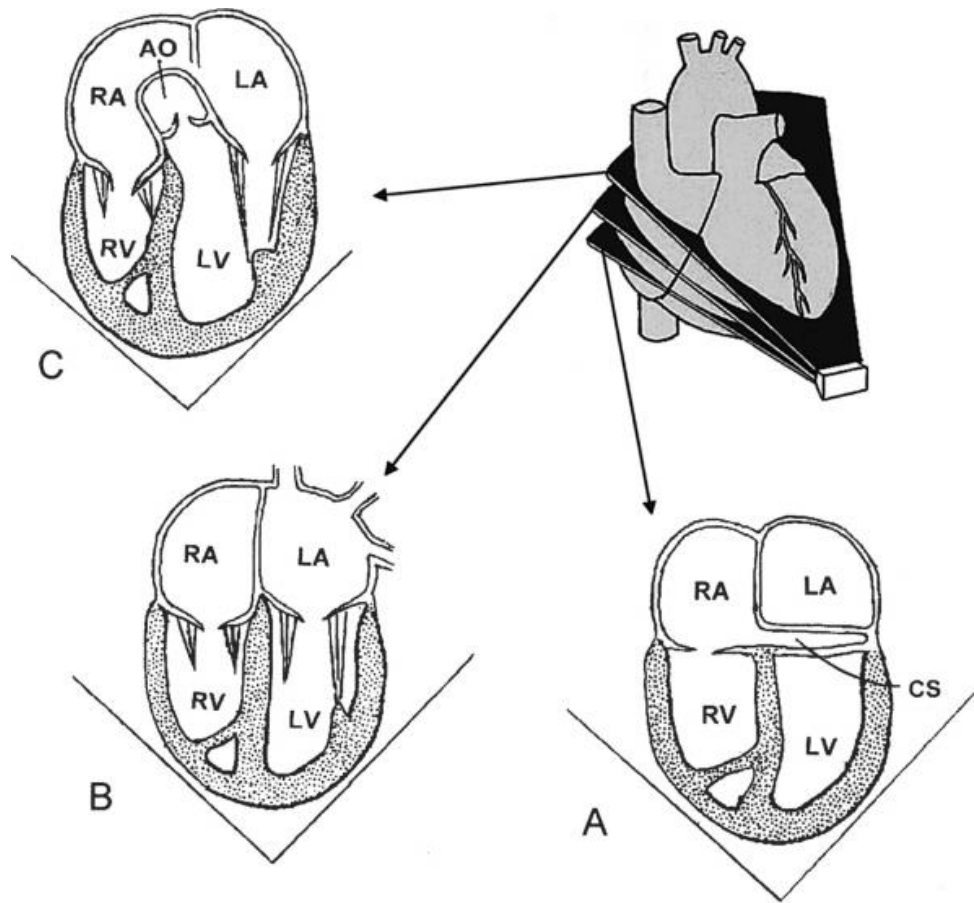


FIG 2.40

Apical 4-Chamber View (AP4CH)

shows the left atrium (LA), right atrium(RA), left ventricle (LV) ,right ventricle (RV)



Apical Four-chamber Views

FIG 2.41

Diagram of two-dimensional echo views obtained with the transducer at the apical position. A, A posterior plane view showing the coronary sinus. B, The standard apical fourchamber view. C, The apical “five-chamber” view is obtained with further anterior angulation of the transducer. AO, aorta; CS, coronary sinus; LA, left atrium; LV, left ventricle; RA, right atrium; RV right ventricle.

2.25.5 Subxiphoid View of Heart

- ☞ Probe placed inferior to sternum.
- ☞ Aimed to left shoulder.
- ☞ Marker to right side.
- ☞ Ultrasound screen indicator to left.
- ☞ Push down on probe and aim up toward heart.

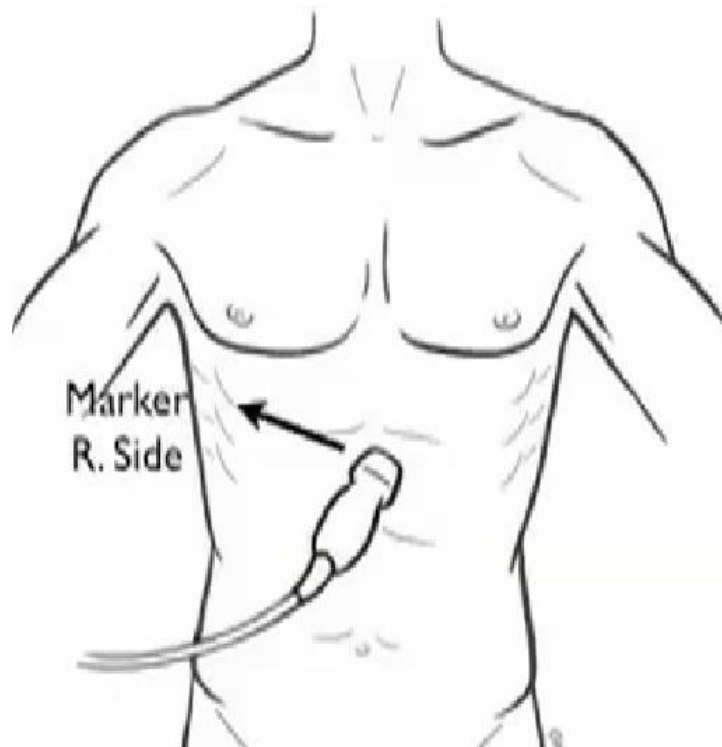


FIG2.42

Subxiphoid View Probe Position

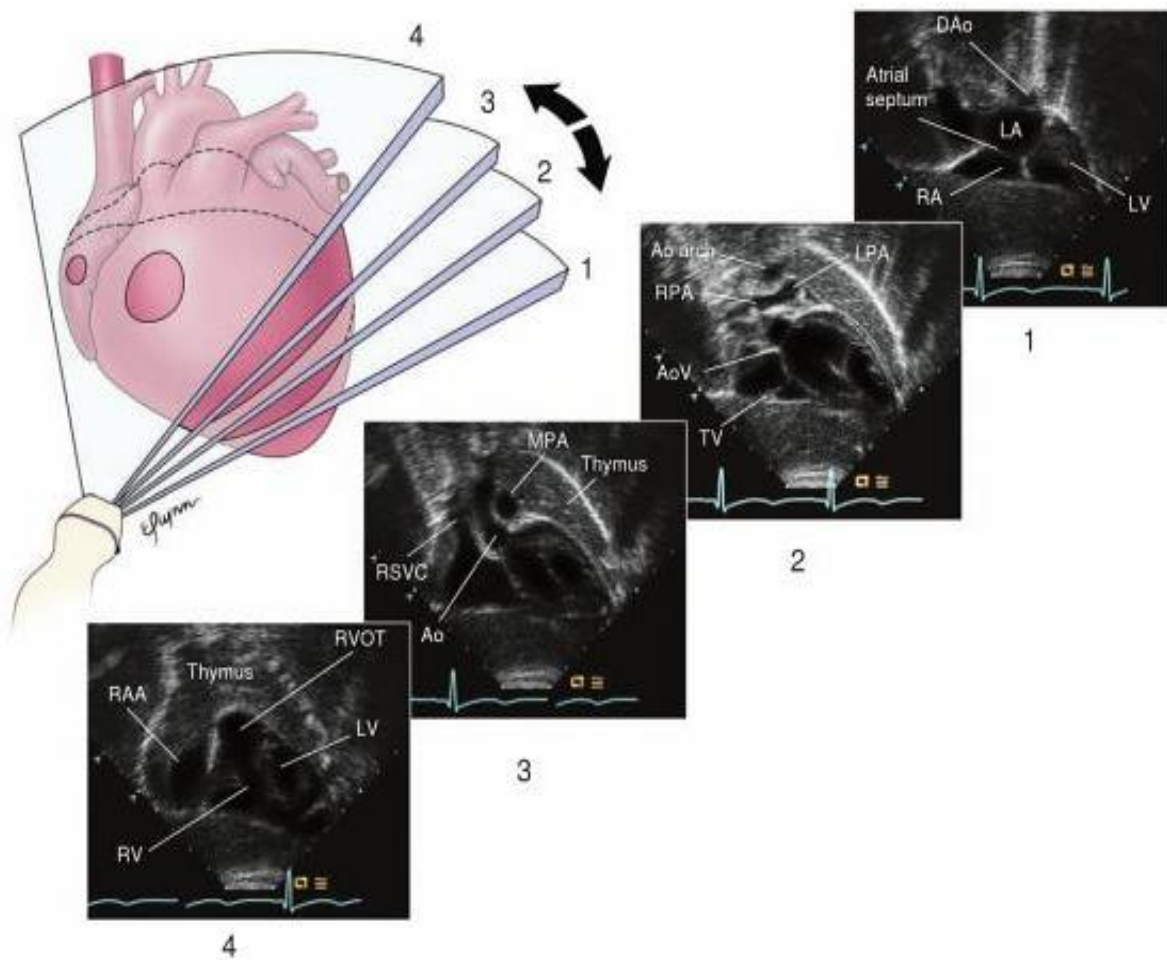


FIG 2.43

Serial images of subxiphoid Long-axis sweep;

- 1) DAo descending aorta , LA Left Atrium, LV Left Ventricle, RA Right Atrium.
- 2) Ao arch Aortic Arch, LPA Left Pulmonary Artery, RPA Right Pulmonary Artery, TV Tricuspid Valve.
- 3) Ao Aorta, MPA Main Pulmonary Artery, RSVC Right Superior Vena Cava.
- 4) LV Left Ventricle, RAA Right Atrial appendage, RV Right Ventricle, RVOT Right Ventricular Outflow tract.

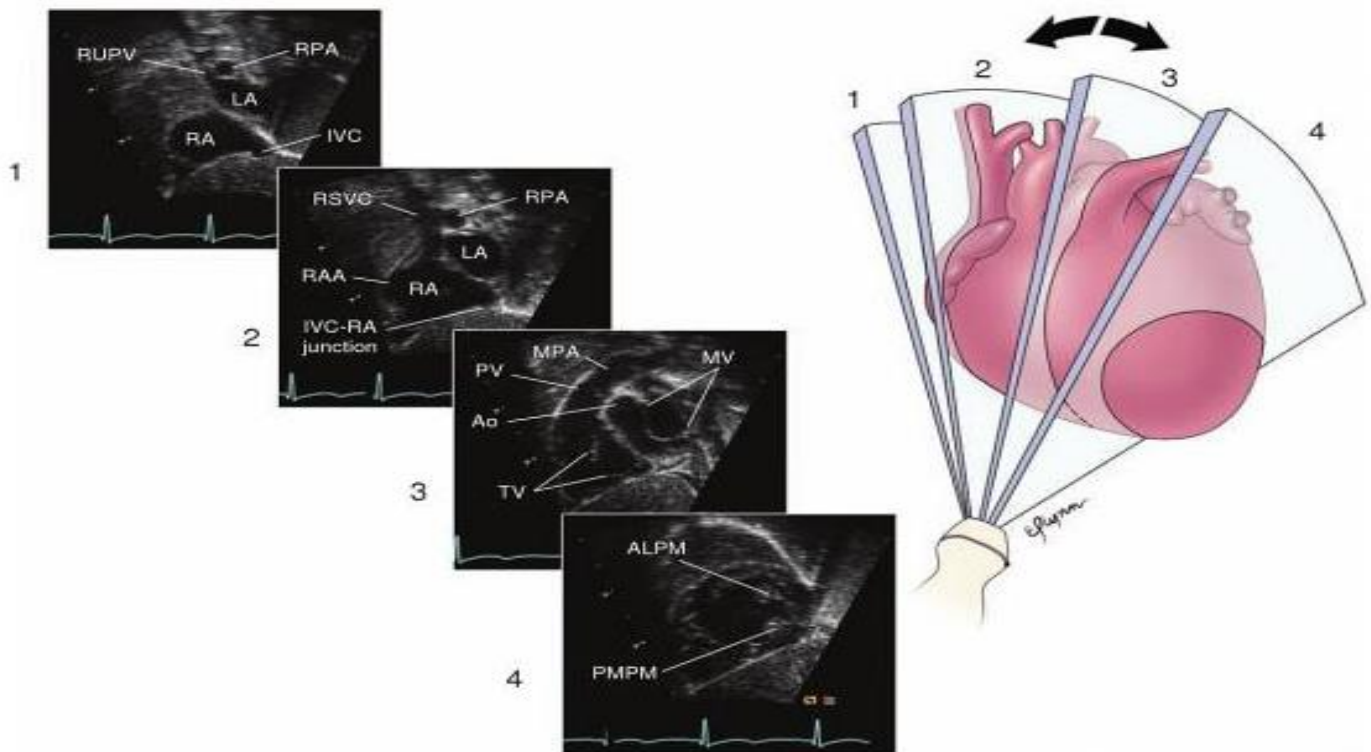


FIG 2.44

Serial images of subxiphoid short-axis sweep;

- 1) IVC inferior vena cava, LA Left atrium, RPA right pulmonary artery, RUPV right upper pulmonary vein.
- 2) IVC-RA junction, inferior vena cava and right atrial junction, LA left atrium, RA right atrium, RAA right atrial appendage, RPA, right pulmonary artery, RSVC right superior vena cava.
- 3) Ao aorta, MPA main pulmonary artery, MV mitral valve, PV pulmonary valve, TV tricuspid valve.
- 4) ALPM anterolateral papillary muscle, PMPM posterolateral papillary muscle

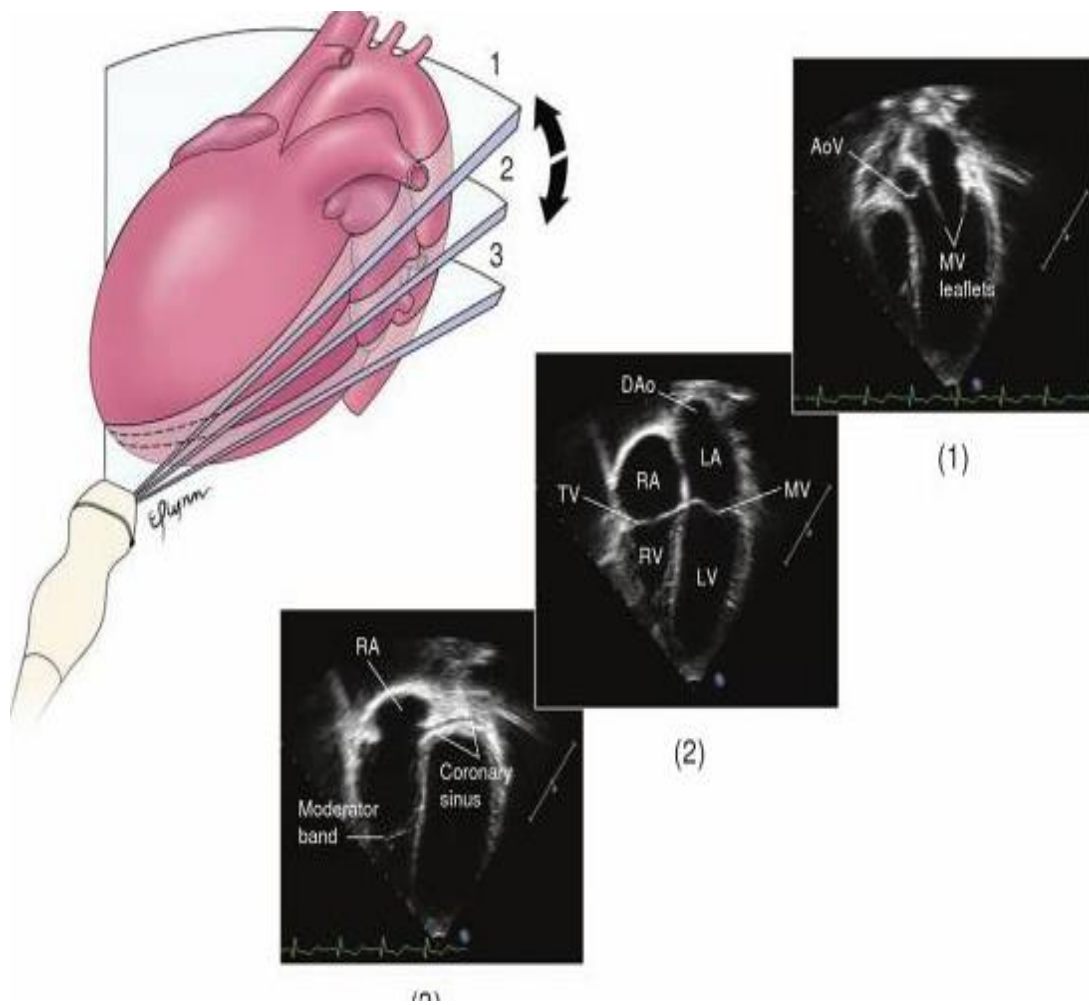


FIG 2.45

Serial Images of Apical four chamber sweep

1)AoV aortic Valve , MV leaflet mitral valve leaflet.

2) Dao Descending Aorta, LA Left Atrium, LV Left Ventricle, MV Mitral Valve, RA Right atrium,RV Right Ventricle, TV Tricuspid valve.

3) RA Right atrium.

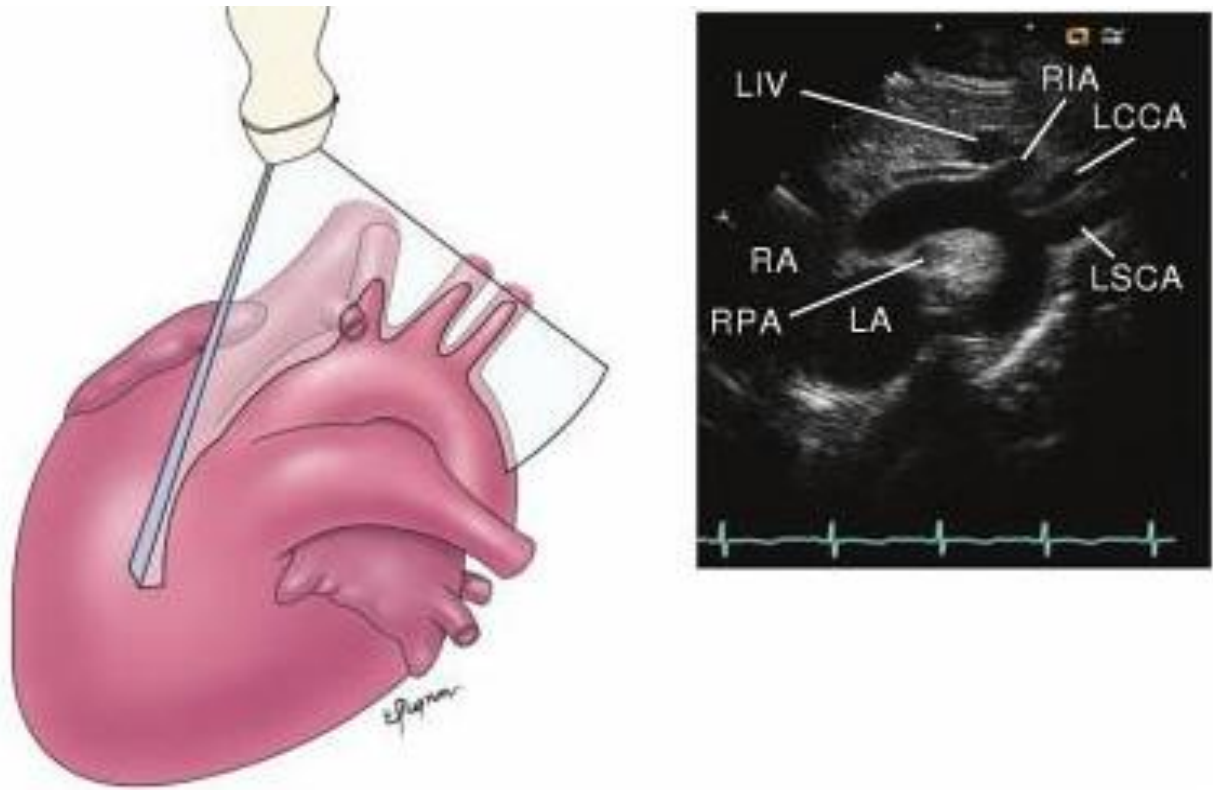


FIG 2.46

Image of suprasternal notch aortic arch view.

LA left atrium, LCCA left common carotid artery, LIV left innominate vein, LSCA left subclavian artery, RA right atrium, RIA right innominate artery, RPA right Pulmonary artery

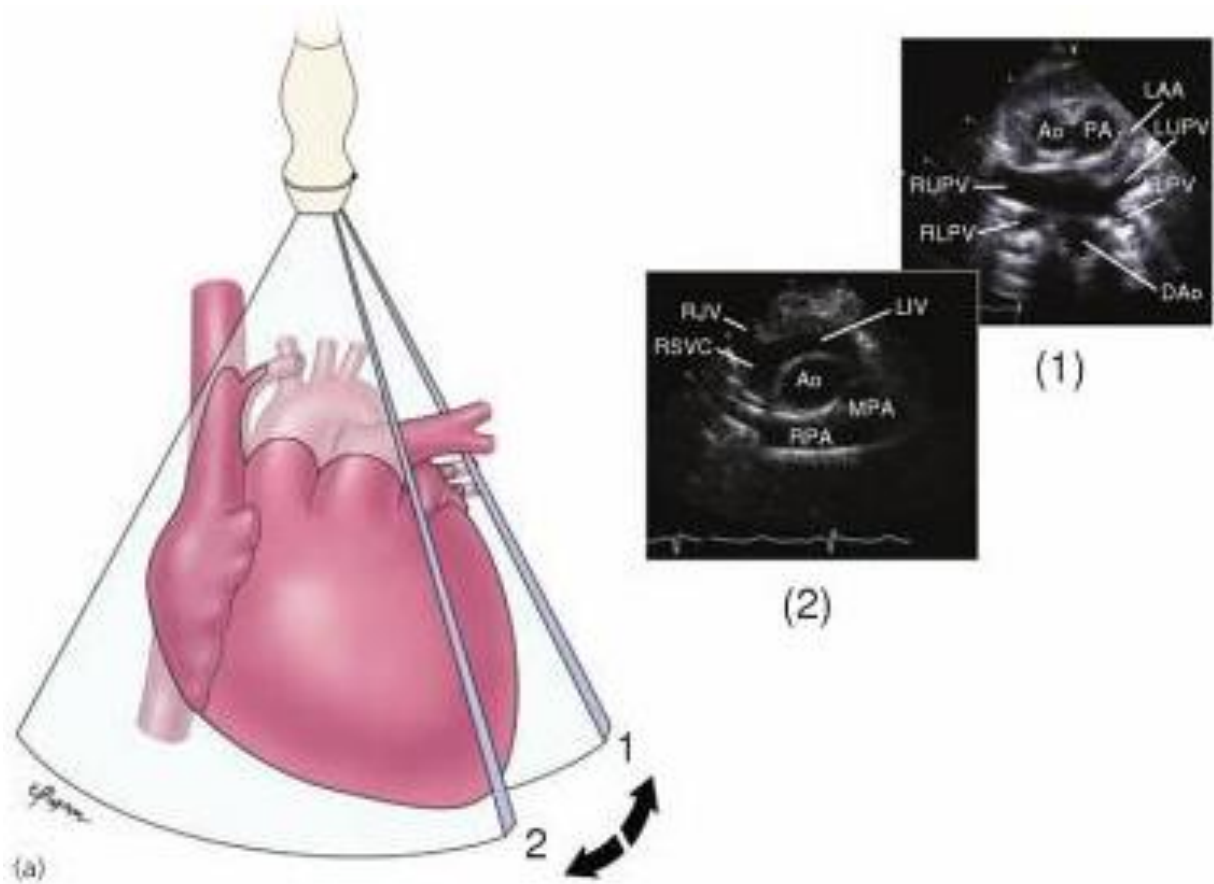


FIG 2.47

(a) Serial images of suprasternal notch short axis sweep. (1) Ao Aorta, LAA left atrial appendage, LLPV left lower pulmonary vein, PA pulmonary artery, RLPV right lower pulmonary vein, RUPV right upper pulmonary vein, Dao descending aorta. (2) Ao Aorta, LIV left innominate vein, MPA main pulmonary artery, RPA right pulmonary artery, RJV right jugular vein, RSVC right superior vena cava.

2.27 Previous studies

Different studies give wide variation in the incidence of CHD varying from 4/1000 to 50/1000 live births (Hoffman et al., 2004). Variation is primarily due to the use of different methods of diagnosis (Hoffman et al., 2004). The highest prevalence for CHD was observed in a population based study from Taiwan with a prevalence of 13.1 per 1,000 live births between 2000 and 2006 (Wu et al., 2010). In most CHD cases, the etiology is not known, but some studies have found that CHD is linked with either genetic or environmental predispositions (Blue et al., 2012).

Regarding the Prevalence and Pattern of Congenital Heart Defects (CHD) studies in Sudan and KSA there were; a study investigated the clinical features of 320 patients diagnosed with CHD at a Saudi hospital in the period between 1988 and 1991 found that both sexes were equally affected. Relative frequency of VSD was higher than Atrial Septal Defect (ASD), Pulmonary Stenosis(PS), Patent Ductus Arteriosus (PDA) and Atrio-ventricular Septal (AVSD) with percentages of 38.5, 11.5, 9, 8% and 5%, respectively (Jaiyesimi et al., 1993). Bhat et al., (1997) screened all children referred to the cardiology clinic at the Madina Maternity and Children Hospital for three years and documented very similar findings with VSD representing 29.7% of all CHD diagnoses, ASD (26%), PS (16.1%) and PDA (13.2%) (Baht et al., 1997). Abbag (1998) documented that the most common defect was VSD 32.5% (Abbag, 2006). Likewise, Alabdulgader (2001) studied the prevalence of CHD using a cross-sectional design and concluded that VSD was the most common defect (39.5%), followed by ASD (11.5%), PS (8.9%), PDA (8.6%), AVSD (3.5%), Tetralogy of Fallot, TOF (4.2%), Coarctation of Aorta COA (2.7%), Aortic Stenosis (AS) (3.5%) (Alabdulgader, 2001). Few studies estimated the prevalence of CHD at the population level. Greer et al. (2005) showed that Southwestern region had the highest burden of CHD with a period prevalence of 748 cases per 100,000 persons (Greer et al., 2005). Alqurashi et al. (2006) determined the prevalence of CHD in children and adolescents by

randomly sampling households in all regions of Saudi Arabia. The results found the prevalence of CHD over all as 21 per 10,000 persons. VSD was the most common defect with 10 cases per 10,000 (Alqurashi et al., 2006). Alnajjar et al., (2009) found that CHD represents 34.4% of all cardiac problems diagnosed at Al Madina city. Ventricular septal defect period represented 34.5% of all CHD diagnoses, followed by ASD (8.9%), PS (7.9%), PDA (6%), AVSD (3.8%), TOF (3%), AS (3.5%), COA (3.4%), Transposition of the Great Arteries (TGA) (3.5%), and others (26%) (Alnajjar et al., 2009). Almawazini and Al-Ghamdiin (2011) studied the proportion of CHD among all diagnoses in the Southwestern Albaha region. Of all cardiac patients, 26.8% were diagnosed with CHD (Almawazini and Al-Ghamdiin, 2011). Al-Mesned et al., (2012) reported on the incidence of severe CHD in Al-Qassim. The incidence of severe CHD was 5.4/1,000 live births/year. VSD defect was the most common lesion 22.5/1,000 live births/year (Al-Mesned et al., 2012).

(A Suliman, 2011) study revealed that; the prevalence of congenital heart disease among schoolchildren aged five to 15 years was studied as part of phase 1 of the WHO Global Rheumatic Fever/Rheumatic Heart Disease Prevention Programme in Sudan. There were 27 cases of congenital heart disease found in a total of 13 322 children screened, giving a prevalence rate of 2.0 per 1 000 children. Khalil S ,et al,1997 , Mitchell SC ,et al, 1971) reported that; the rate was comparable to that of similar African countries but lower than European and North American rates.

(El Hag AI,et al,1994) reported that the congenital heart disease is the commonest cause of heart disease among children admitted to hospital, followed by rheumatic heart disease and cardiomyopathy. Ventricular septal defect, atrial septal defect, tetralogy of Fallot, patent ductus arteriosus and pulmonary stenosis were the commonest diseases.

(Samia H.Osman, et al, 2011) concluded that out of study was done at cardiology clinic in Gafaar Ibn Auf Specialized hospital, Khartoum, Sudan; Most of cases were diagnosed too late in infancy,

clear that there is a prompt need to enable the early detection which will be achieved by introduction of fetal echo, accurate evaluation of neonates, and after confirmed diagnosis a suitable intervention planning should be arranged.

There was a recent study by (Amirah M. Alenezi, et al, 2015) The aim of this review is to provide a comprehensive summary of CHD incidence, prevalence, burden and impact on the Saudi population. Concluded that; this study give a general understanding of the CHD epidemiology in Saudi Arabia. There was higher prevalence when compared with Western countries and comparable to those reported in other developing countries The congenital heart diseases , pose a considerable impact on children and their families, have that in. Consanguineous marriages, maternal age, diabetes and Down syndrome and were among risk factors related to CHD in studies conducted in Saudi Arabia. Identified risk factors are potentially modifiable, emphasizing the importance of public health programs that are aimed at tackling such determinants.

Chapter Three

Material & Methodology

CHAPTER THREE

3.0 Material &Methodology

3.1 Methodology

A retrospective, prospective study was conducted on 356 patients referred to King Fahad Cardiac Center - Pediatric Cardiology Unit , King Khalid University Hospital -King Saud University- Riyadh-KSA. Department of Pediatric Echocardiography for evaluation and diagnosis of congenital cardiac malformations. Echocardiographic images and reports for these patients forms part of the routine medical management.

Once the cardiac location, orientation and situs have been determined, the echocardiographer then examines each cardiovascular segments and the connection between them, all these made by using subcostal transducer position , the remainder of the examination usually begins in that position and progresses from there to parasternal, apical, and suprasternum views in a sequential fashion by sequential segmental approach to congenital heart disease, it divides the patient cardiovascular system into a sequence of individual segment and the connection between them. When using this approach one can be confident that complete assessment has been obtained even in the most unusual cases.

Complete echocardiographic examination usually entails a combination of M-mode and two-dimensional imaging, and Spectral Doppler (Pulsed-wave (PW) & continuous-wave (CW)) and color-flow Doppler imaging (CFI) echocardiography provides measurements of blood flow velocities and assessment of intra cardiac pressures and haemodynamics.

3.2 Equipment

Philips iE33x Matrix Echocardiography system, one of Cardiac applications recommended ultrasound machines. With the following capabilities;

Transducers: X-Matrix cardiac transducers x5-1 which supports all types of cardiac ultrasound scanning, including 2D, 3D, M-mode, color flow, PW/CW Doppler, Tissue Doppler imaging, and contrast-enhanced exams. Which produce high quality images.

Also it contains handle with a new design that aids in the user fatigue reduction, because the scanning consume long time more than 30 minutes.

Revelation of imaging: In the same transducer it combining unprecedented 2D and 3D image quality and the quantification is easy-to-use, clinical performance, and it contains tools for management of information, so it play a vital role suited the clinical needs for managing patients with ; congenital cardiac malformations, other cardiac diseases; e.g. , valvular disease and heart failure.

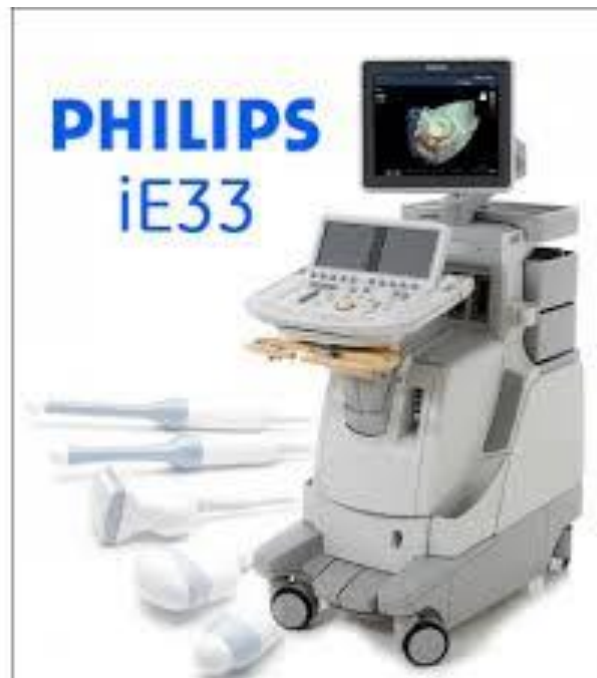


FIG 3.1

Philips iE33x Matrix Echocardiography System & X-Matrix Cardiac Transducers

3.3 Research Setting

The study will be conducted in the King Fahad Cardiac Center "Where Academia Complement Care", Pediatric Cardiology Unit - King Khalid University Hospital -King Saud University-Riyadh-KSA.

3.4 Research Design

A quantitative comparative and descriptive study was conducted to determine a study of pediatric acyanotic congenital cardiac malformations(defects) Echocardiographic techniques which added another dimension of information, allowing the assessment of blood flow and hemodynamic function procedures, as a valuable non-invasive, portable, and efficacious tool in diagnosis of congenital heart defect (CHD).

3.5 Population Sample

The target populations of the present study were, all neonates, infants and older children, including both genders male and female. Their ages from 1 day to 15 years old. Were referred to the Cardiac Unit, either in OPD pediatrics clinic or in the echocardiography laboratories, for evaluation and diagnosis of congenital cardiac malformation; included either known cases attend for follow up or suspected congenital cardiac malformation, or echocardiographic imaging reveal CHD.

Excluded: Patient with small PFO (Patent Foramen Oval), patient with Rheumatoid fever, Kawasaki disease, patient had spontaneous closure and the recent echo report reveal normal study.

Sample Volume (N) = 356 patients.

3.6 Data Collection

The researcher was collected echocardiographic sonograms, reports and took all patient data from the memory of computer system (PACS); Advances in computer technology have made it possible to

capture, store, and manage echo data digitally and use computerized reports of echocardiographic studies. Then it was stored in CDs and flash memories.

3.7 Data Collection Sheet

Data collection sheet was well designed and divided into sections; 1st section include patient data; age, gender, weight, height, age at diagnosis, child body either normal or dysmorphic. The 2nd section include patient symptoms; Asymptomatic (Screening) , Heart Murmur, Recurrent chest infection, and CHF congestive heart failure (FTT failure to thrive, Tachypnea, Interrupted Feeding, Active Pericordium, Fatigue, SOB(shortness of breathing, and other CHF symptoms)

Section 3; Echocardiographic Findings;3.1; Atria(Right Atrium & left atrium size if it is (Normal, Mild Dilated, Moderate, and severe)- Atrial Septum(Intact, Atrial septal defect, if there ASDs, ASD various types , sizes, numbers, shunt direction. 3.2; Atrioventricular Valves; Tricuspid Valve (Normal, Stenosis, Regurgitation TR; Mild, Moderate ,or Severe TR)

& Mitral valve((Normal, Stenosis, Prolapses, and Regurgitation MR; Mild, Moderate ,or Severe MR)The 4th section include. The last section about the associated other cardiac anomalies. 3.3 Ventricles; RV Cavity Size(Small,normal, enlarged)if enlarge(mild, moderate, severe) , then RVOT obstruction , RVSP(normal or elevated)if elevated ($< 1/2$ Systemic, $1/2$ Systemic- Systemic , Suprasystemic)

3.4 LV cavity size (Normal, Mild Dilated, Moderate, and severe)

LVOT obstruction (yes or no), Ventricular Septum(intact , VSD(defect: Size a-small b-moderate c-large) Types(Membranous, Outlet Septum Defect, Inlet- AV septal defect, Muscular), then shunt direction.

4th section ;Semilunar Valves; Pulmonic Valve & Aortic Valve

5th section; Great Vessels (further details in index)

3.7 Duration of the study

For this retrospective, prospective study, the data collections were from October 2010- January 2014.

3.8 Data Analysis

Data analysis was performed using **SPSS** (Statistical Package for Social Sciences) statistical software (version 21 SPSS, Chicago, IL). Continuous variables are summarized as mean+ SD and categorical data as percentages.

3.9 Validity, reliability and generalizability

To ensure combined validity and reliability the data collection and all information's was known and followed by pediatric cardiologist and the head of cardiology department. This study was supported by King Fahad Cardiac Center "Where Academia Complement Care" at King Khalid University Hospital -King Saud University-Riyadh-KSA.

3.10 Ethical Consideration

The collected echocardiograms (images), reports for these patients forms part of the routine medical management, it was taken after receiving the ethical approval, for this study. There is no patient identification or individual patient details were published. Also confidentiality was ensured by making the collected data accessible only to the researcher and consultant pediatric cardiologist and the head of cardiology department. And also all data collected during the study was stored on computer protected by password. All paper format data was stored in locked cabinet.

Chapter Four

Results

Results

A retrospective-prospective study in 356 patients with different types of congenital cardiac malformations.

Almost all patients have normal "RVSP, Coronary arteries", no detection of pulmonary hypotension.

No cases of; Aortopulmonary window, LVIT obstruction, and Double chambered RV.

LVOT Left Ventricular Out Flow Tract Obstruction was detected in one patient only.

However, complex heart defects and mixed cardiac lesions like VSD with Right ventricular outflow tract obstruction and VSD with ASD were more common in females.

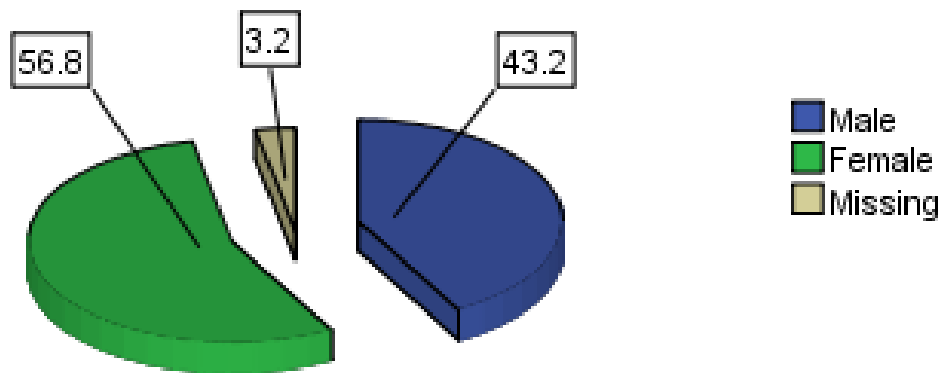


FIG 4.1

a Pie chart of patients gender in the present study, sample volume (N) =356 children with different types of congenital cardiac malformations.

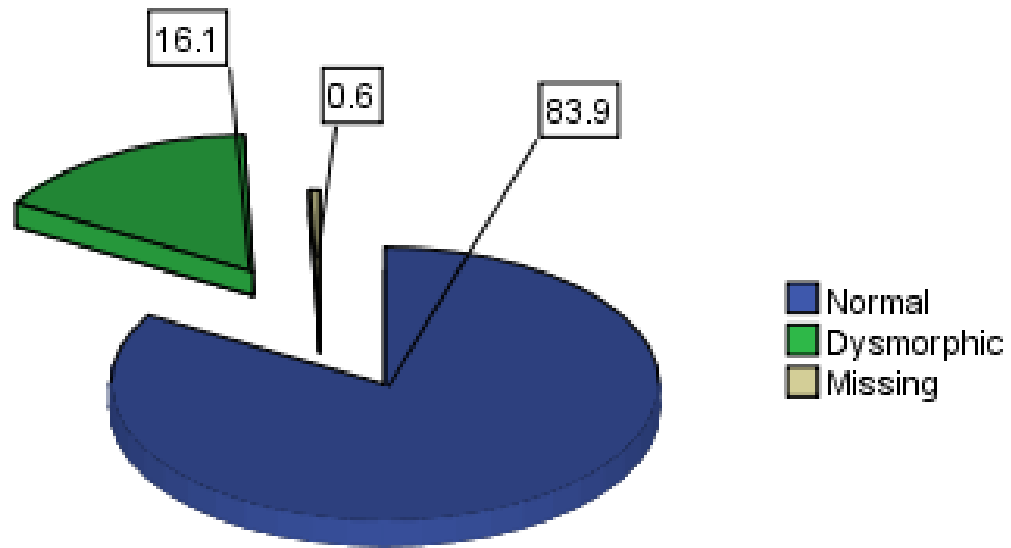


FIG 4.2

a Pie chart of patients body types in the present study, sample volume (N) =356 children with different types of congenital cardiac malformations.

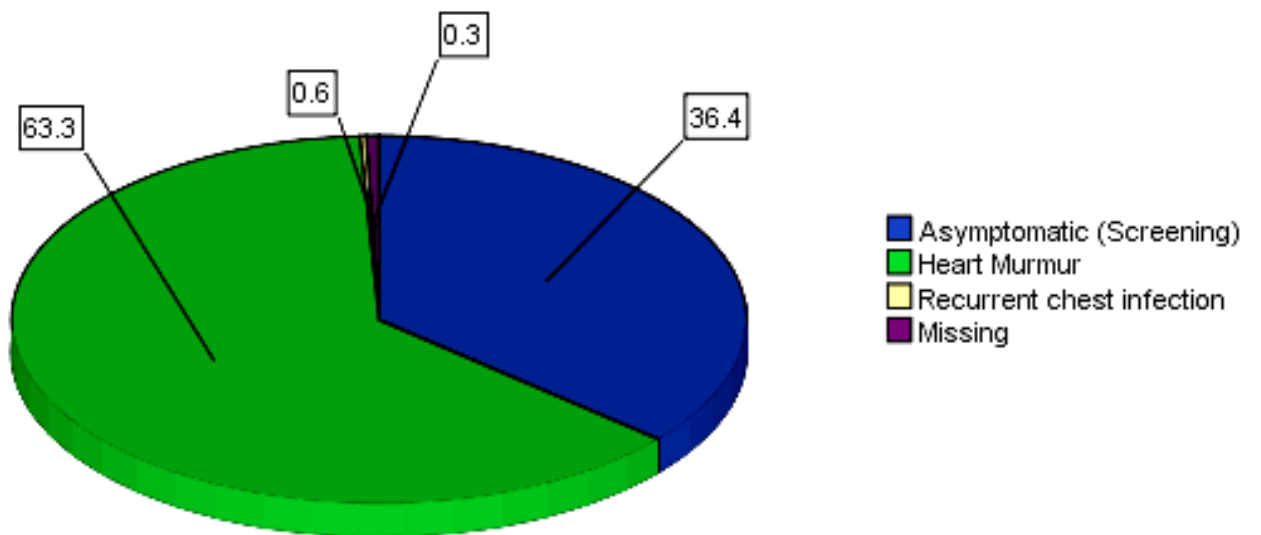


FIG 4.3

, a Pie chart of patients symptoms in the present study, sample volume (N) =356 children with different types of congenital cardiac malformations.

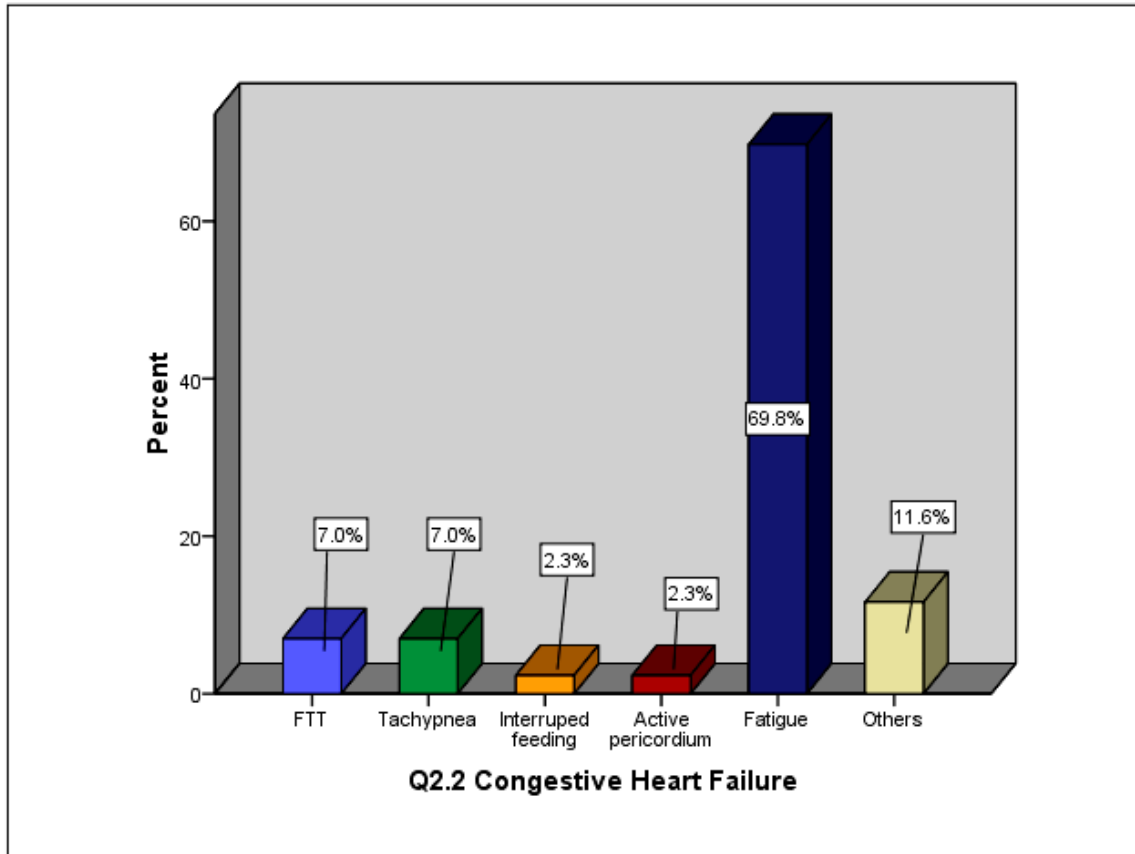


FIG 4.4

a Par chart of patient's symptoms indicates Congestive heart failure (CHF) in the present study, sample volume (N) =43 children had congestive heart failure.

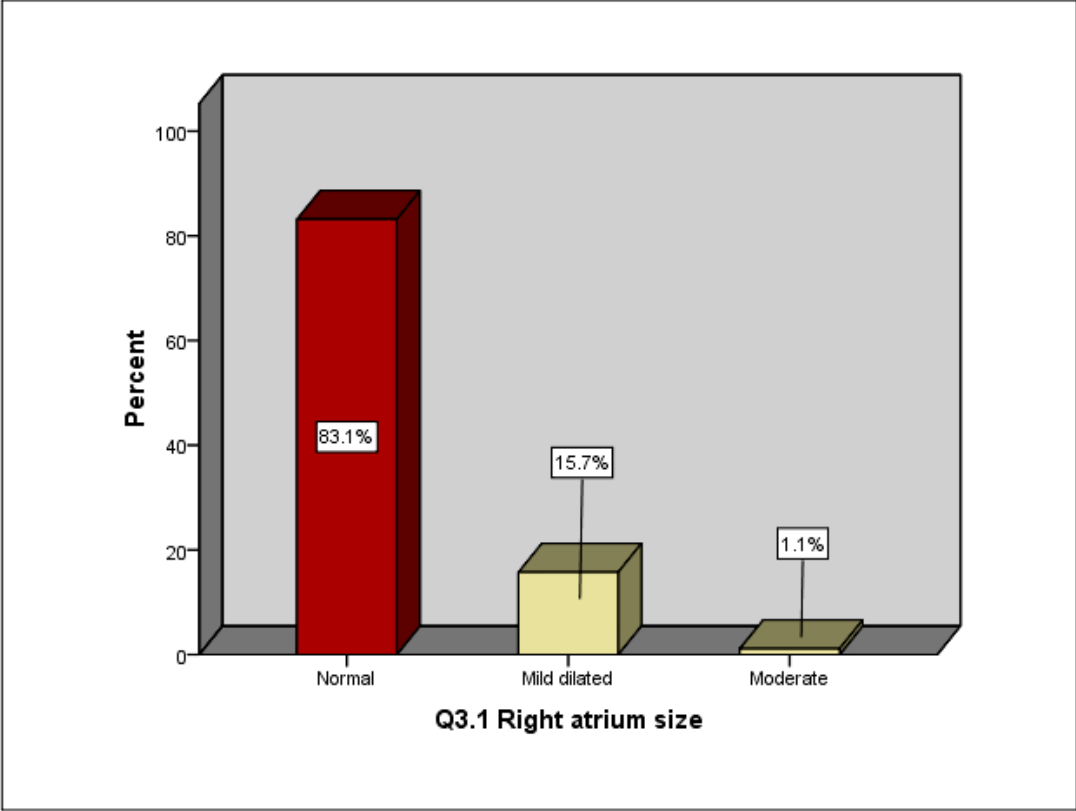


FIG 4.5

a Par chart of right atrium (RA) size in the present study, sample volume (N) =356 children with different types of congenital cardiac malformations.

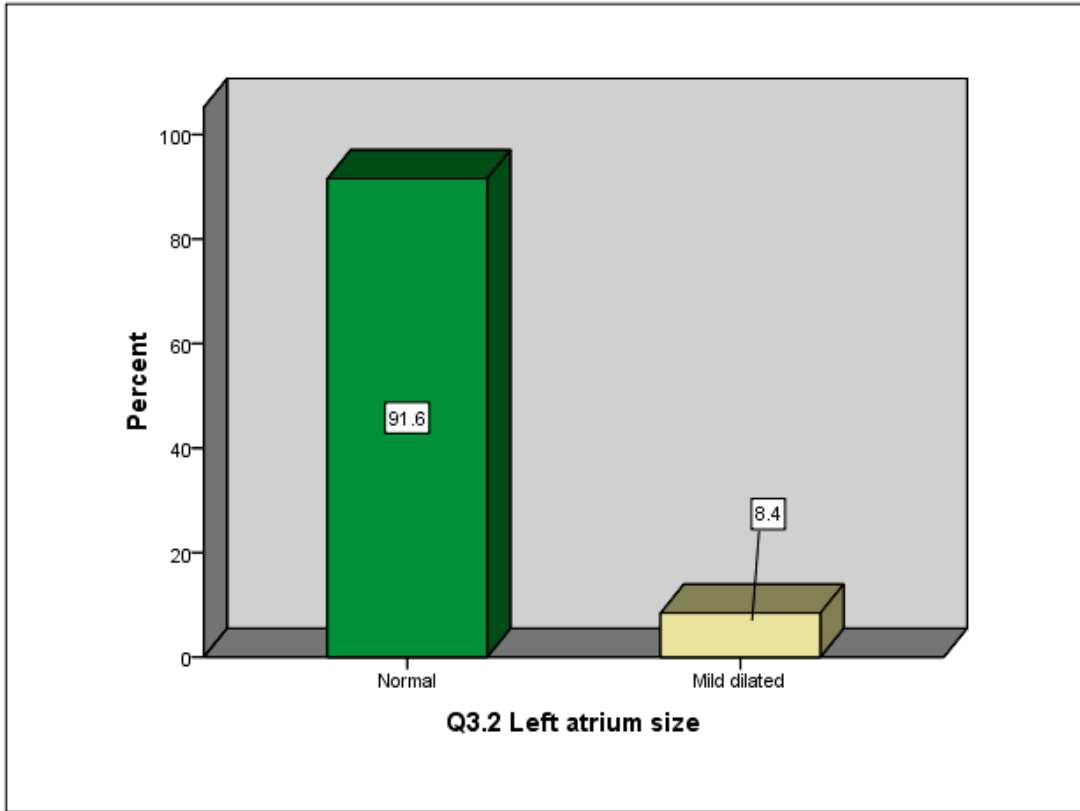


FIG 4.6

a Par chart of left atrium (LA) size in the present study, sample volume (N) =356 children with different types of congenital cardiac malformations

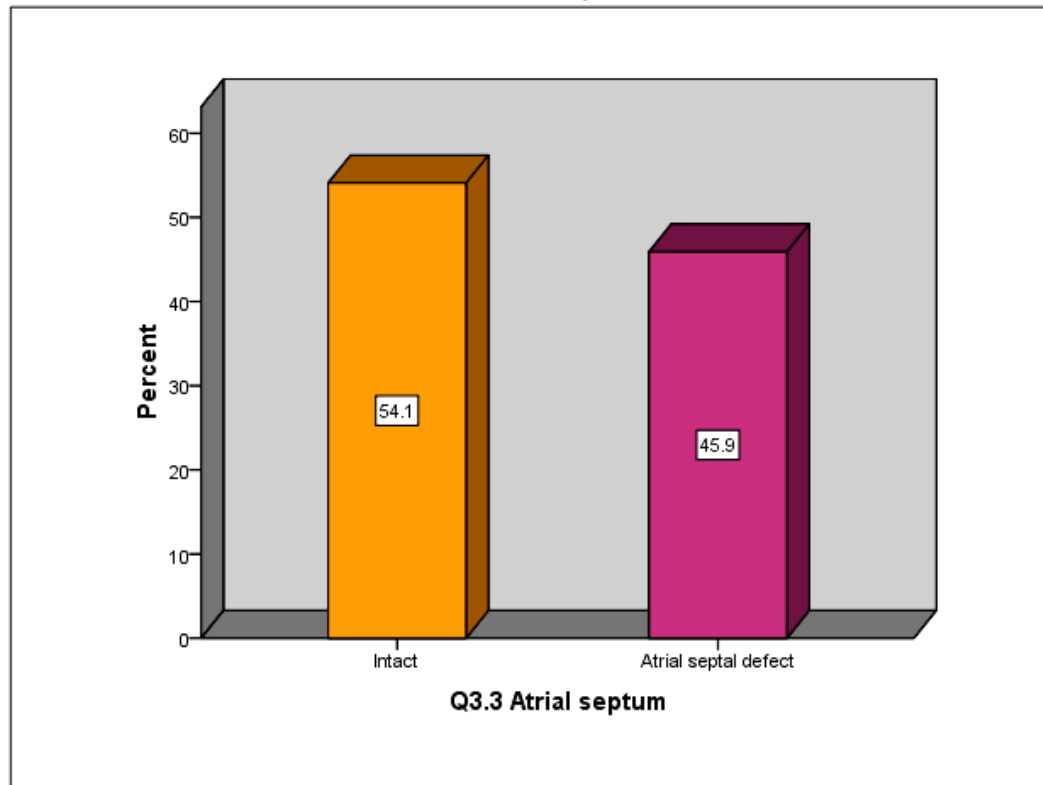


FIG 4.7

a Par chart of Atrial Septum in the present study, sample volume (N) =356 children with different types of congenital cardiac malformations.

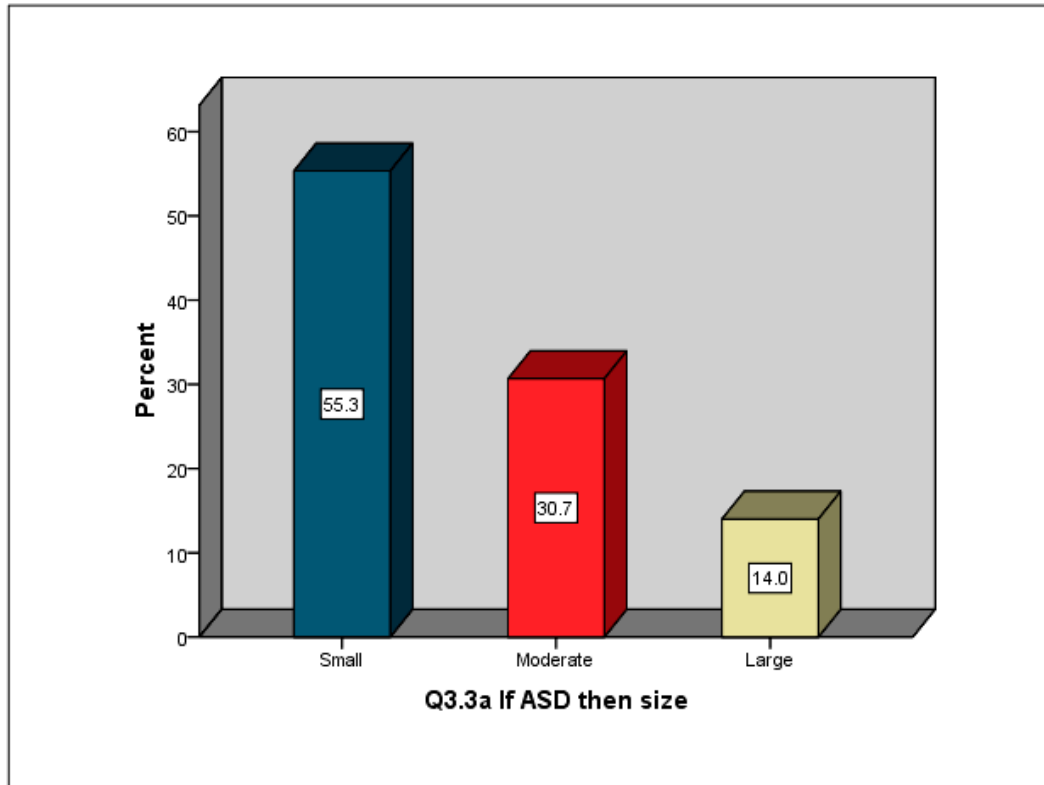


FIG 4.8

a Par chart of atrial septal defect(ASD) size in the present study, sample volume (N) =163 children had ASD.

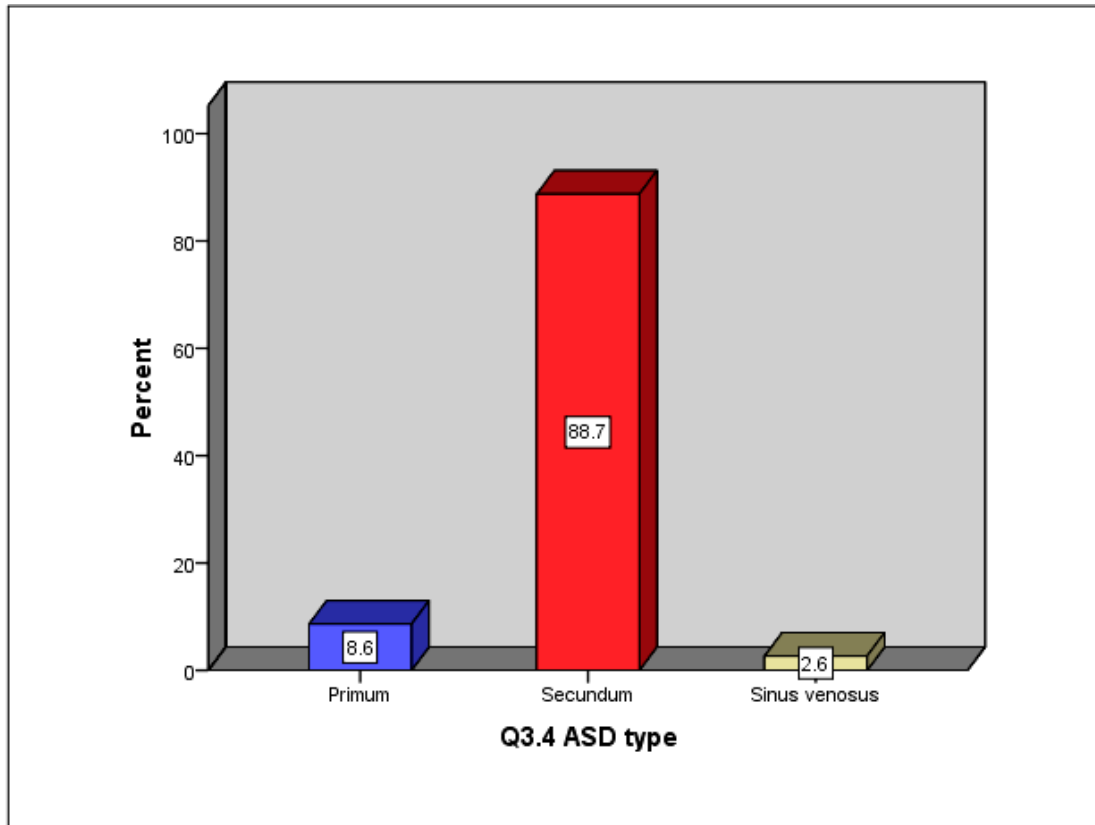


FIG 4.10

a Par chart of atrial septal defect(ASD) Types in the present study, sample volume (N) =163 child had ASD.

Right atrium size

		Frequency	Percent	Valid Percent	Cumulative Percent
Valid	Normal	114	69.9	69.9	69.9
	Mild dilated	45	27.6	27.6	97.5
	Moderate	4	2.5	2.5	100.0
	Total	163	100.0	100.0	

(Table 4.1)

Right atrium size regarding to ASD patients, sample volume (N) =163 child had ASD.

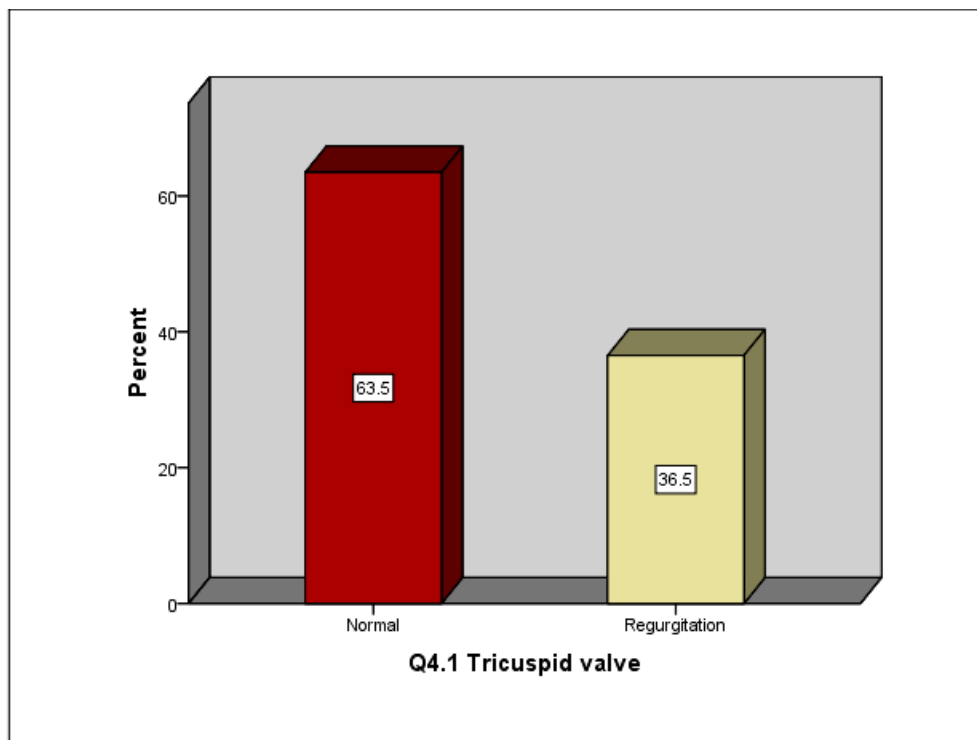


FIG 4.11

a Par chart of tricuspid valve (TV) in the present study, sample volume (N) =356 children with different types of congenital cardiac malformations

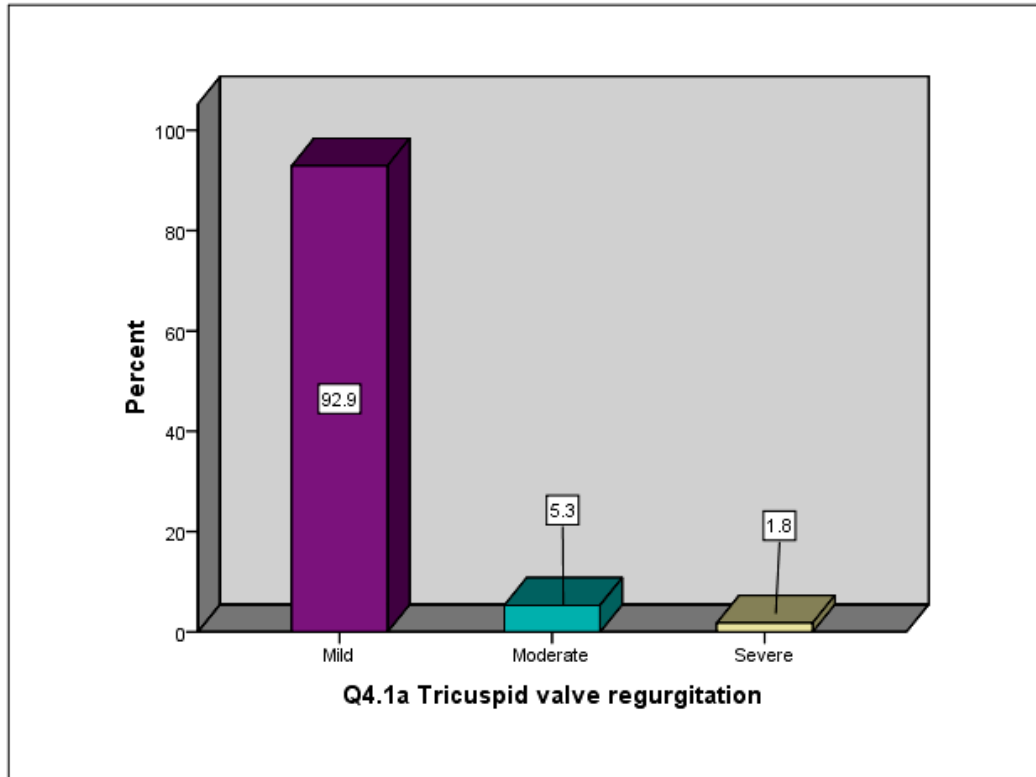


FIG 4.12

a Par chart of tricuspid valve Regurgitation (TR) in the present study, sample volume (N) =136 patients had TR

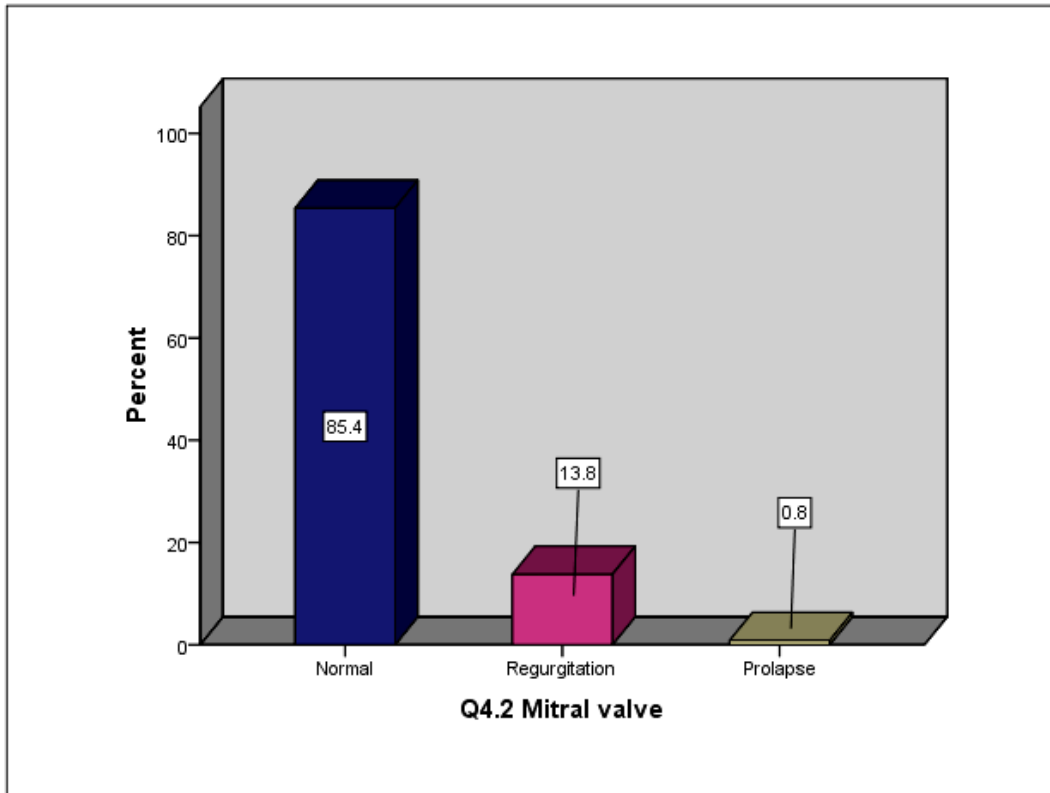


FIG 4.13

a Par chart of Mitral valve (MV) in the present study, sample volume (N) =356 children with different types of congenital cardiac malformations.

Mitral valve

	Frequency	Percent	Valid Percent	Cumulative Percent
Valid Normal	304	85.4	85.4	85.4
Regurgitation	49	13.8	13.8	99.2
Prolapse	3	.8	.8	100.0
Total	356	100.0	100.0	

(Table 4.2)

Mitral Valve in the present study, sample volume (N) =356 children with different types of congenital cardiac malformations.

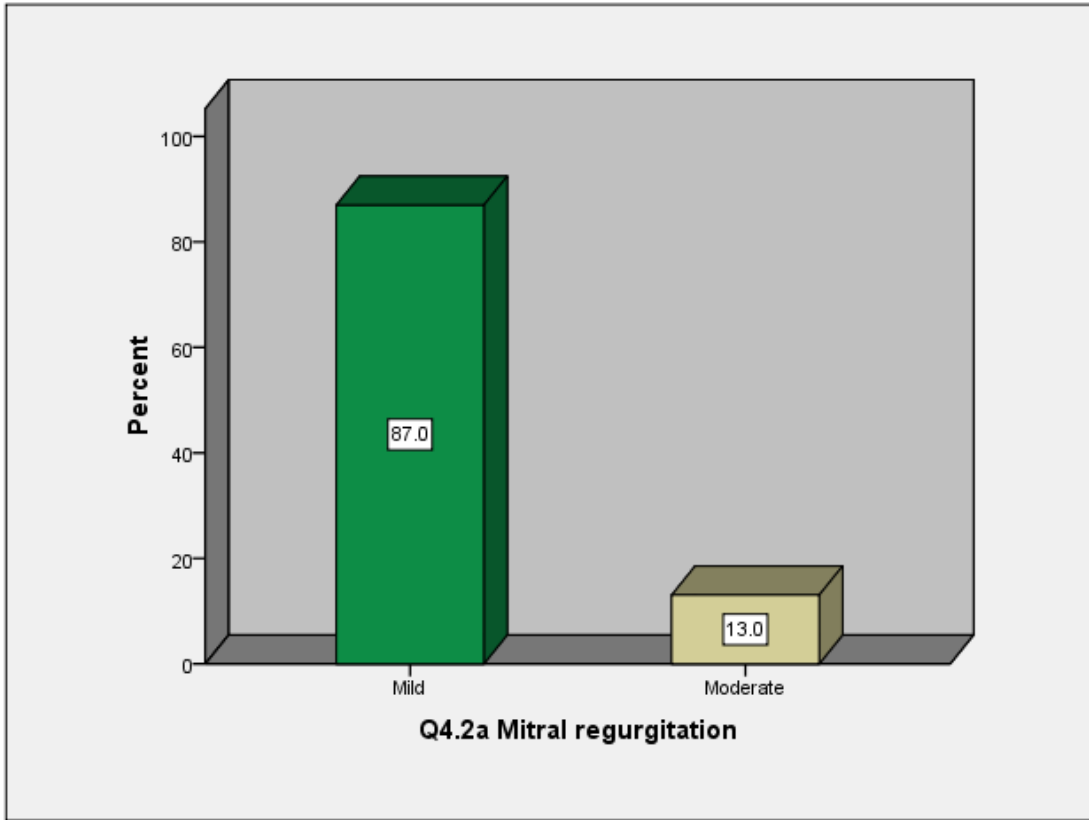


FIG 4.14

a Par chart of Mitral valve Regurgitation (MR) in the present study, sample volume (N) =49 patients

had MR

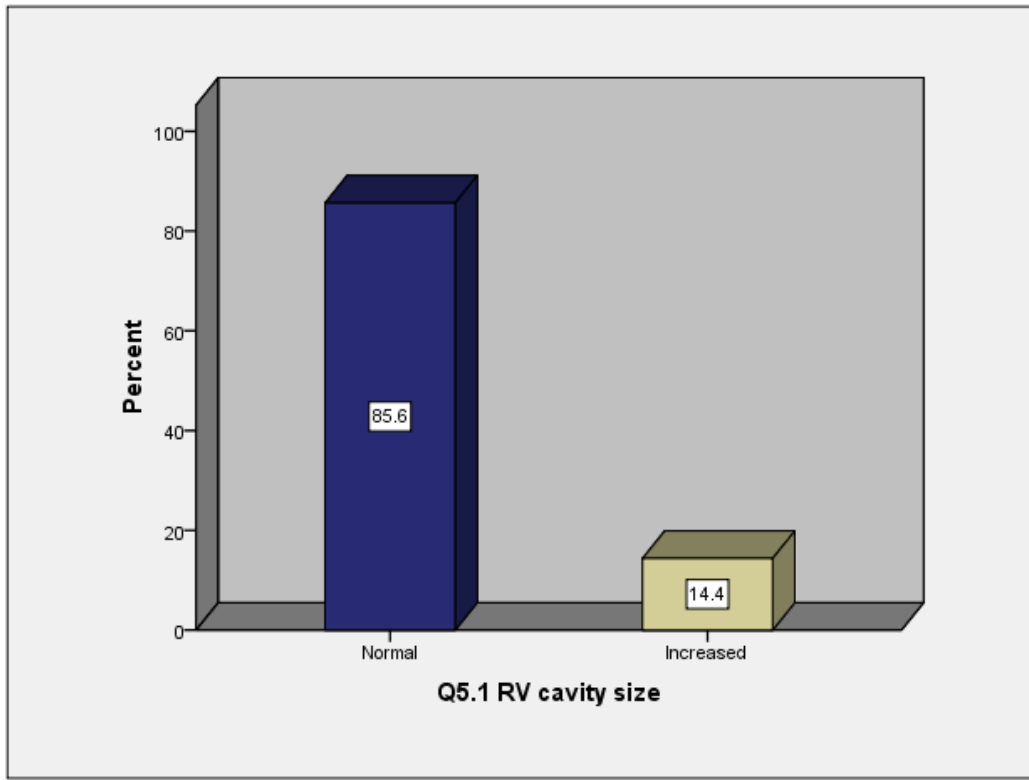


FIG 4.15

a Par chart of Right ventricle (RV) cavity size in the present study, sample volume (N) =356 children with different types of congenital cardiac malformations

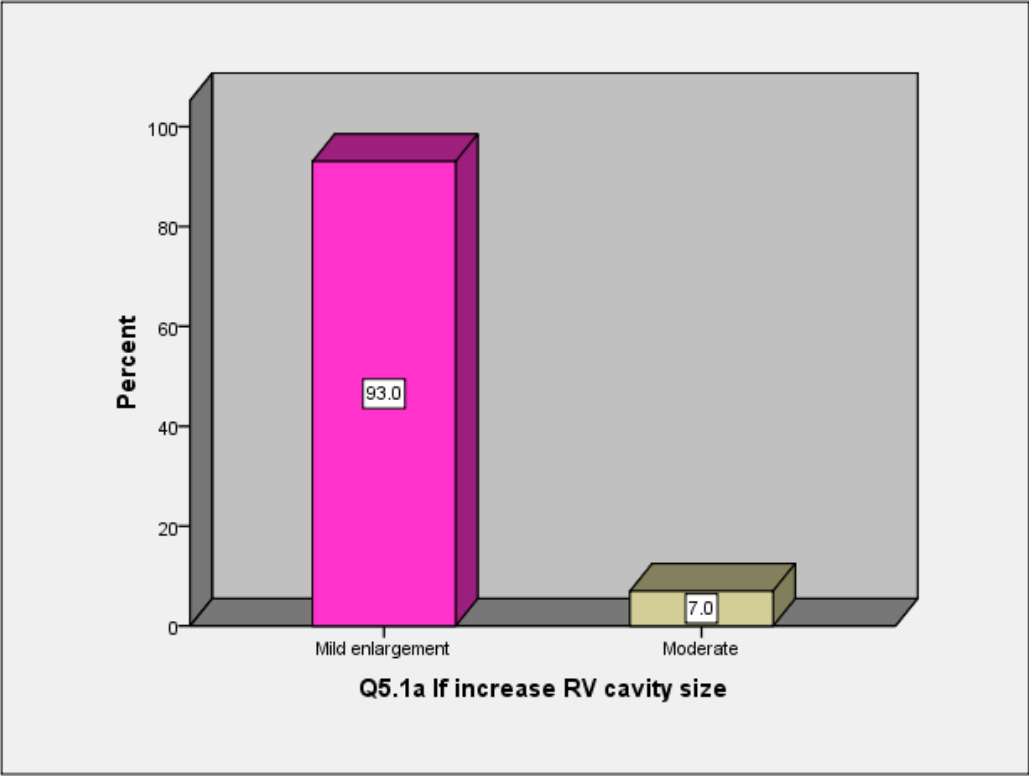


FIG 4.16

a Par chart of Increased RV cavity size in the present study, sample volume (N) =356 children with different types of congenital cardiac malformations

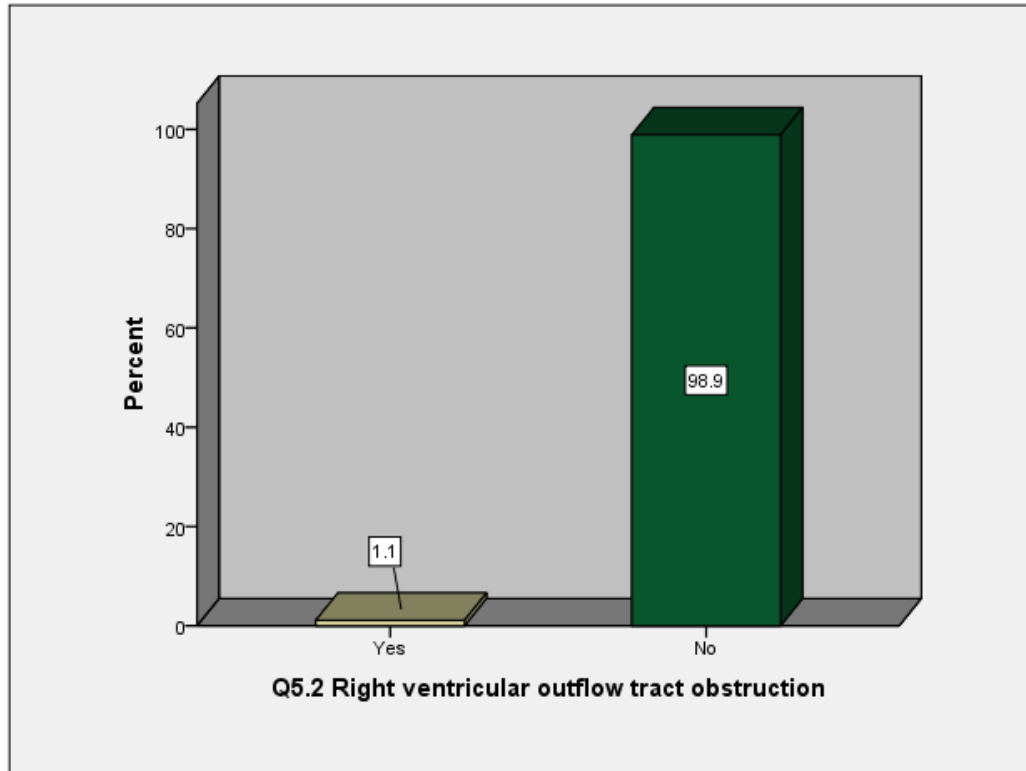


FIG 4.17

a Par chart of Right ventricular outflow tract (RVOT) obstruction in the present study, sample volume (N) =356 children with different types of congenital cardiac malformations

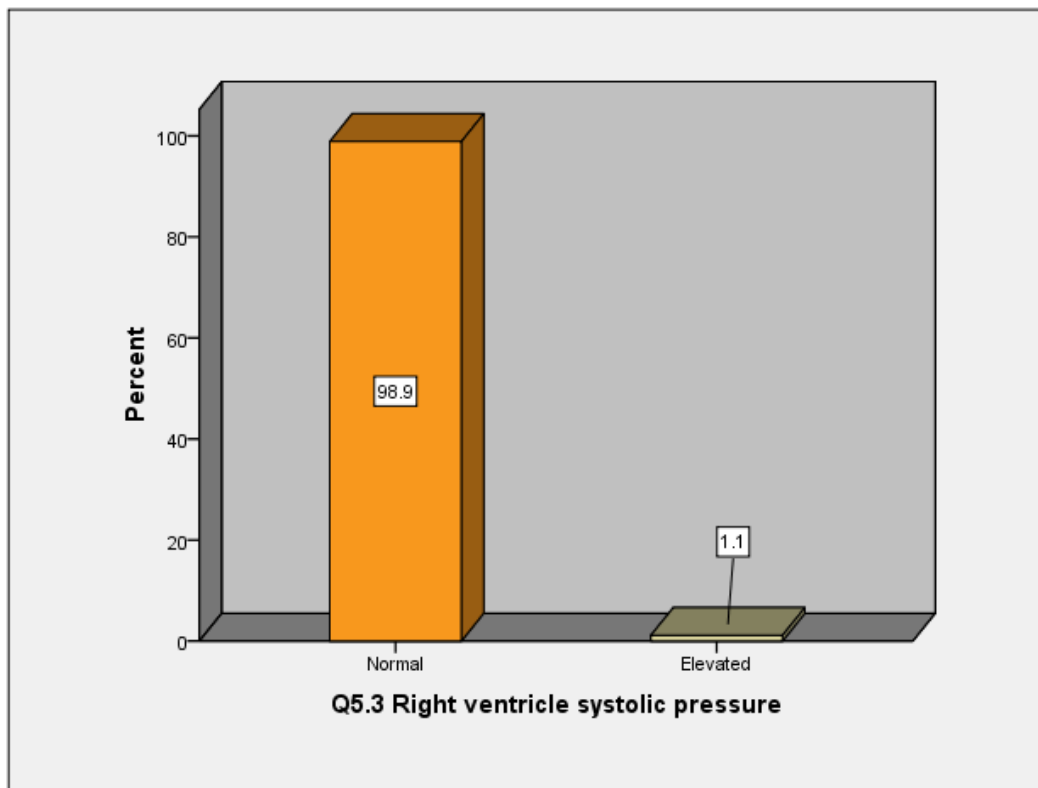


FIG 4.18

a Par chart of RVSP in the present study, sample volume (N) =356 children with different types of congenital cardiac malformations

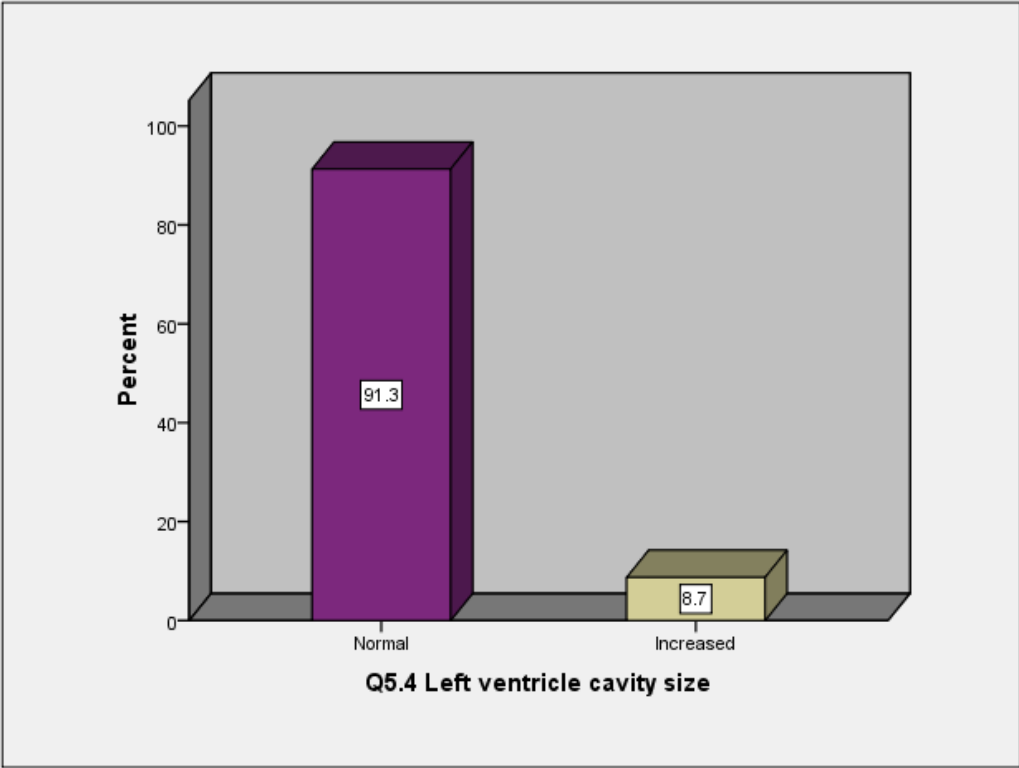


FIG 4.19

a Par chart of Left Ventricle (LV) cavity size in the present study, sample volume (N) =356 children with different types of congenital cardiac malformations

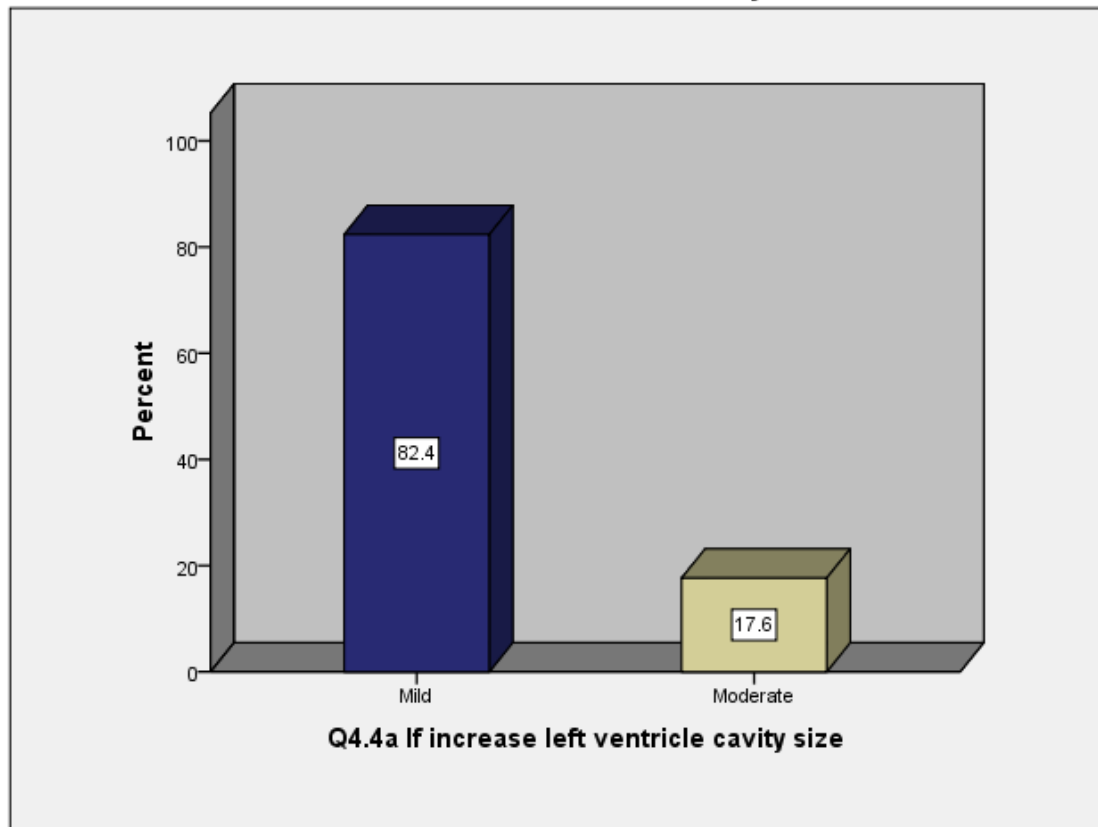


FIG 4.20

a Par chart of increased LV cavity size in the present study, sample volume (N) =31 children with different types of congenital cardiac malformations

Ventricular septum

	Frequency	Percent	Valid Percent	Cumulative Percent
Valid Intact	242	68.0	68.0	68.0
VSD	114	32.0	32.0	100.0
Total	356	100.0	100.0	

(Table 4.3)

Interventricular septum in the present study, sample volume (N) =356 children with different types of congenital cardiac malformations.

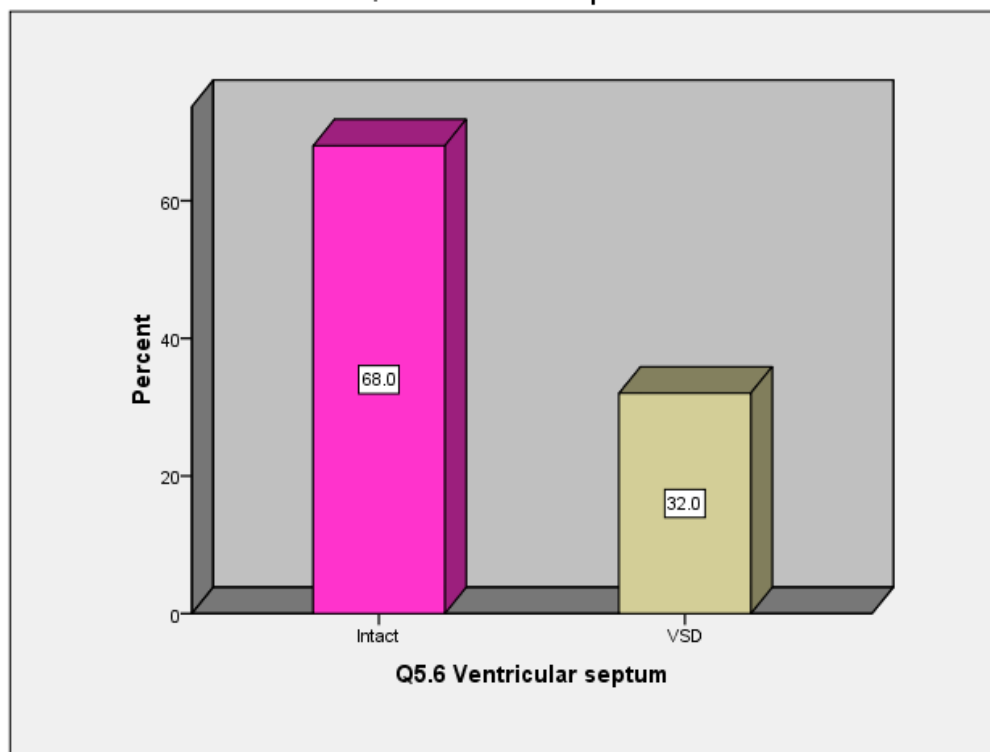


FIG 4.21

a Par chart of Interventricular septum(IVS) in the present study, sample volume (N) =31 children with different types of congenital cardiac malformations

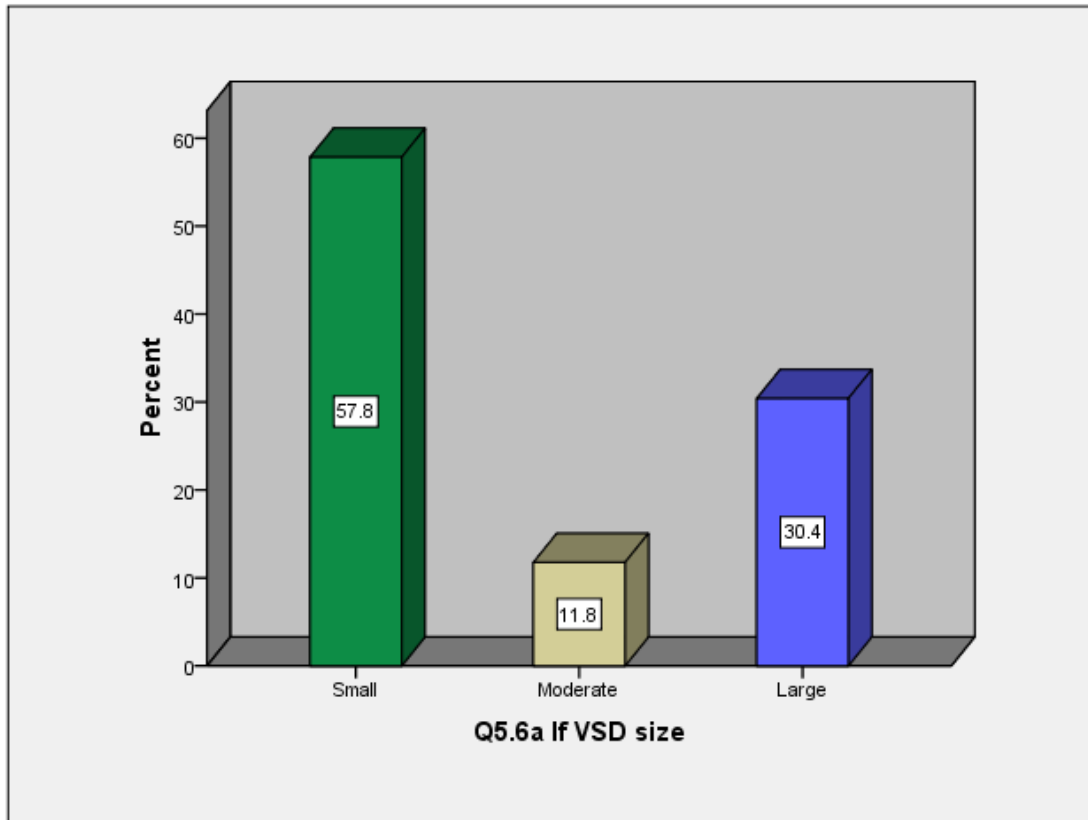


FIG 4.22

a Par chart of ventricular septal defect (VSD) size in the present study, sample volume (N) =114 children had VSD.

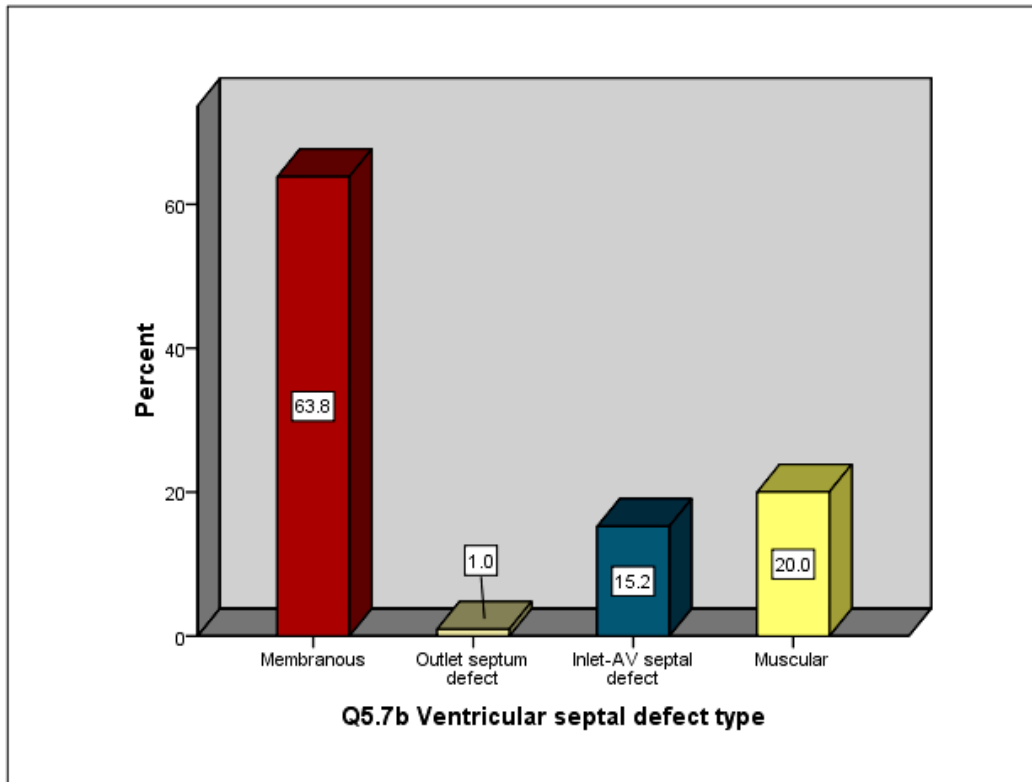


FIG 4.23

a Par chart of ventricular septal defect (VSD) Types in the present study, sample volume (N) =114 children had VSD.

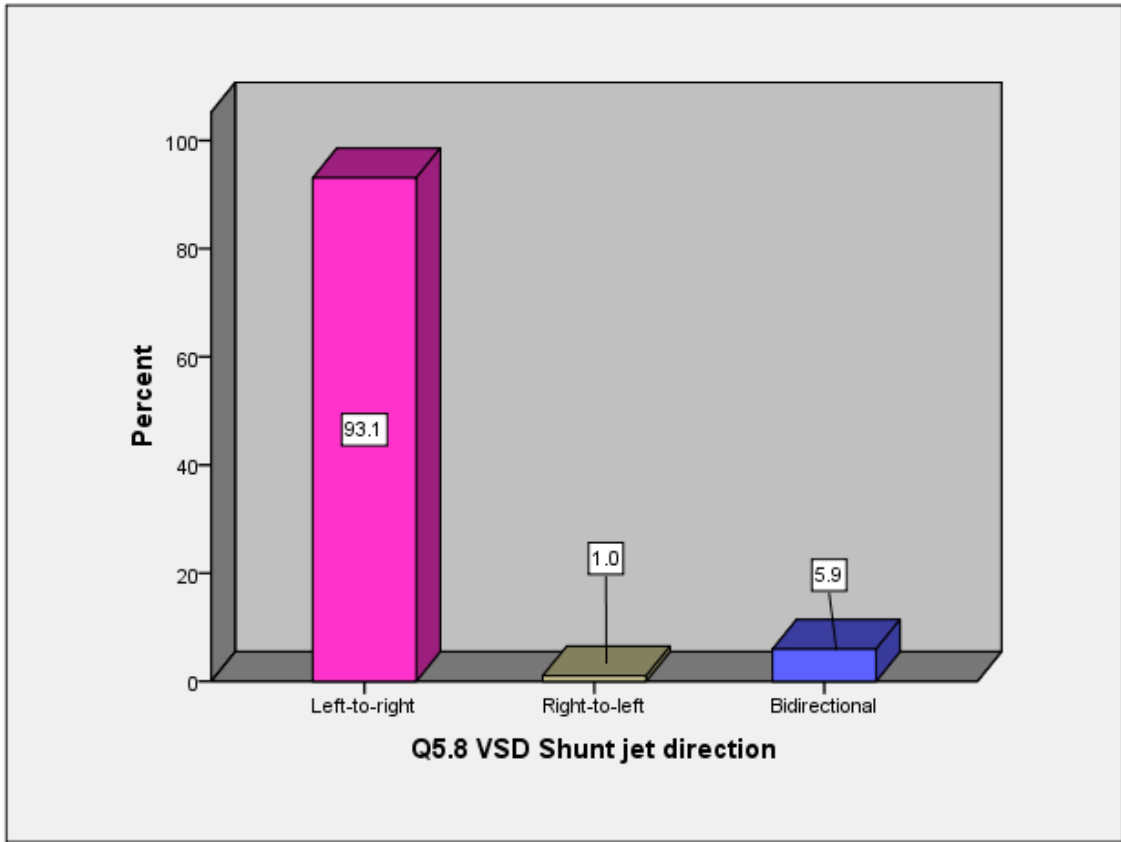


FIG 4.24

a Par chart of ventricular septal defect (VSD) shunt jet direction, in the present study, sample volume (N) =114 children had VSD.

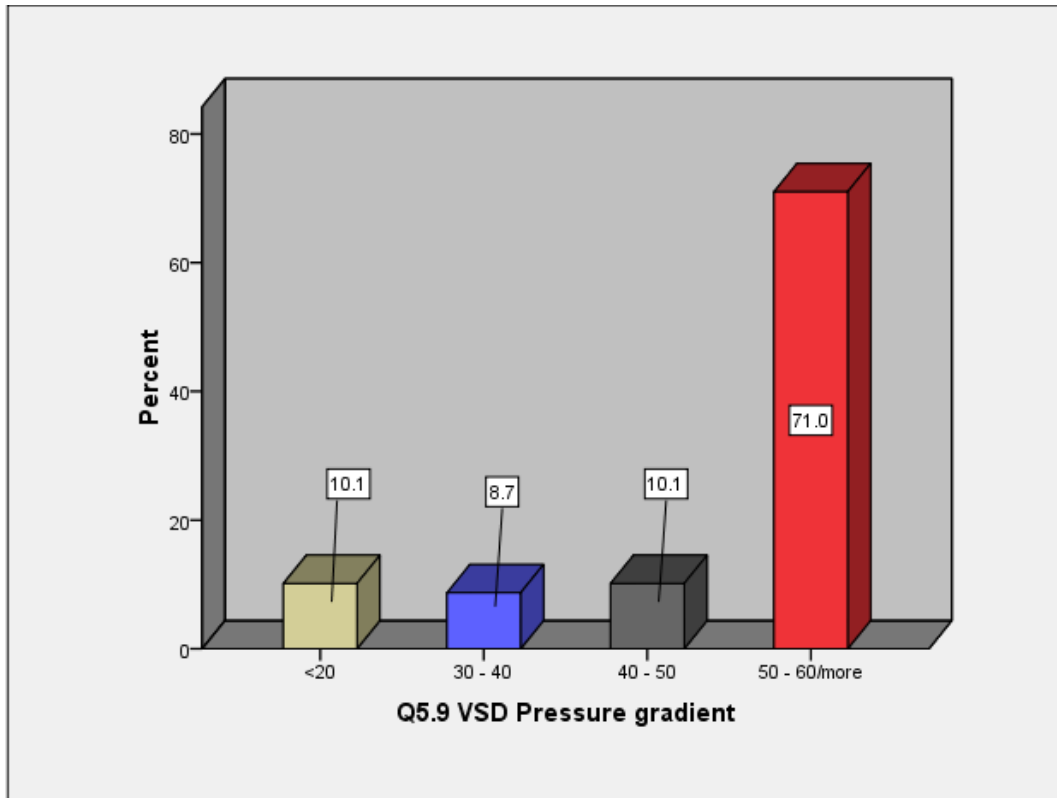


FIG 4.25

a Par chart of ventricular septal defect (VSD) pressure gradient, in the present study, sample volume (N) =114 children had VSD.

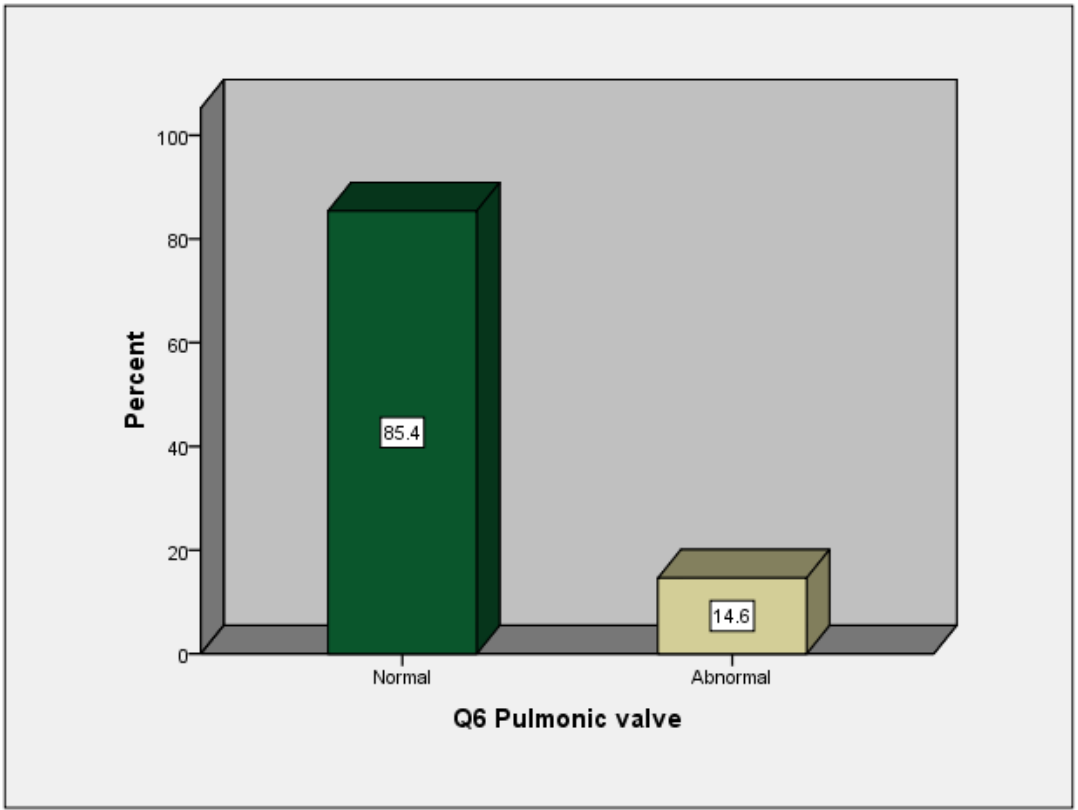


FIG 4.26

a Par chart of Pulmonary valve in the present study, sample volume (N) =356 children with different types of congenital cardiac malformations

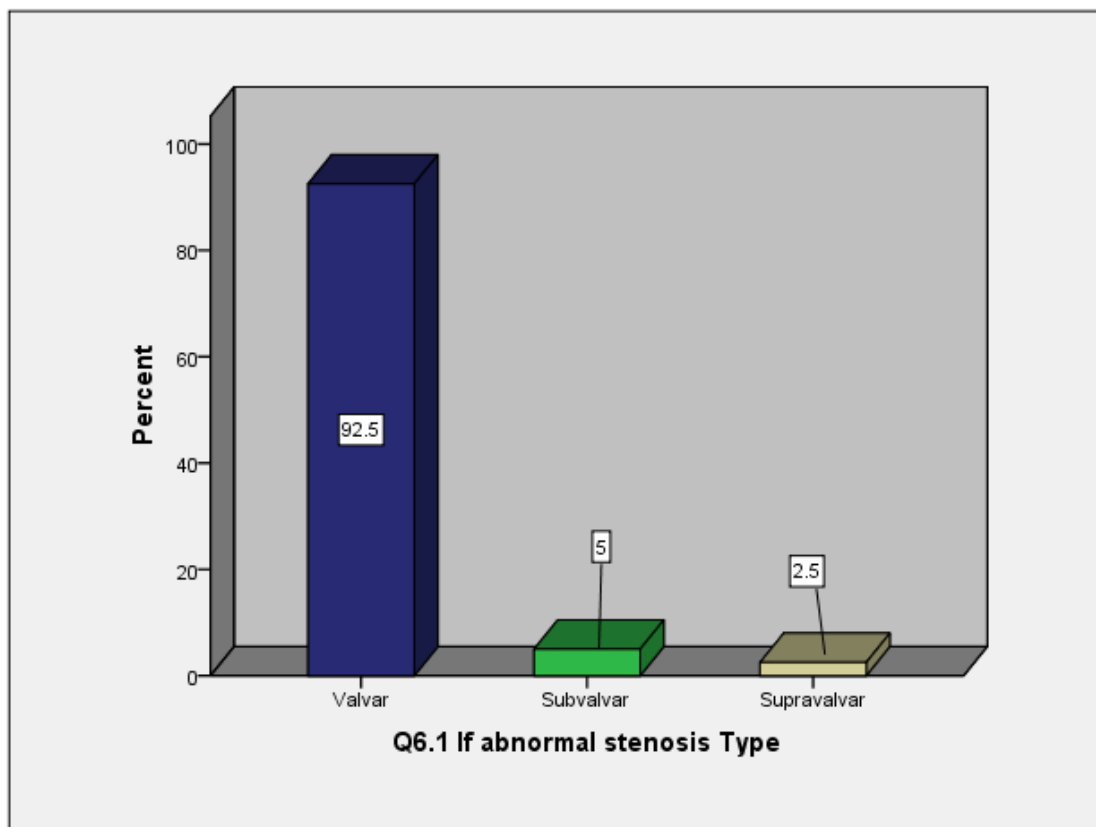


FIG 4.27

a Par chart of Pulmonary Stenosis (PS) types in the present study, sample volume (N) =40 children had PS.

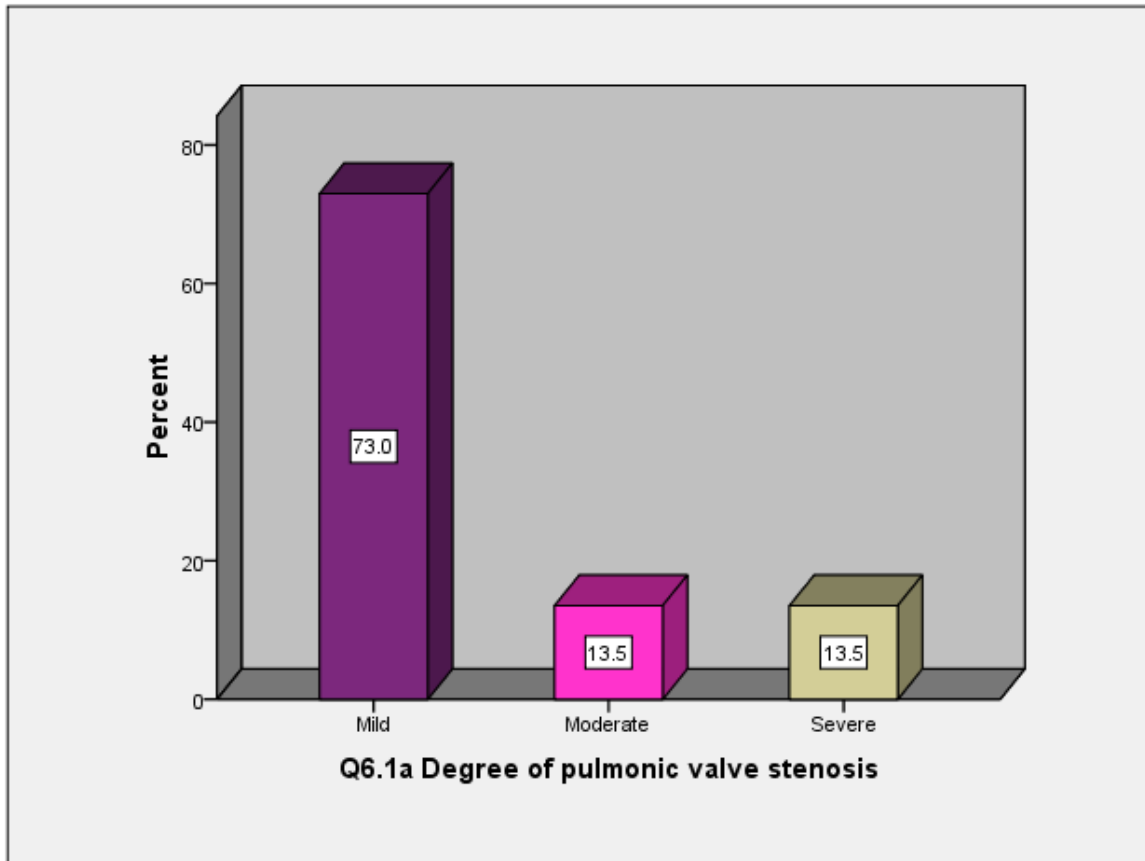


FIG 4.28

a Par chart of Pulmonary Stenosis (PS) Degree in the present study, sample volume (N) =40 children had PS.

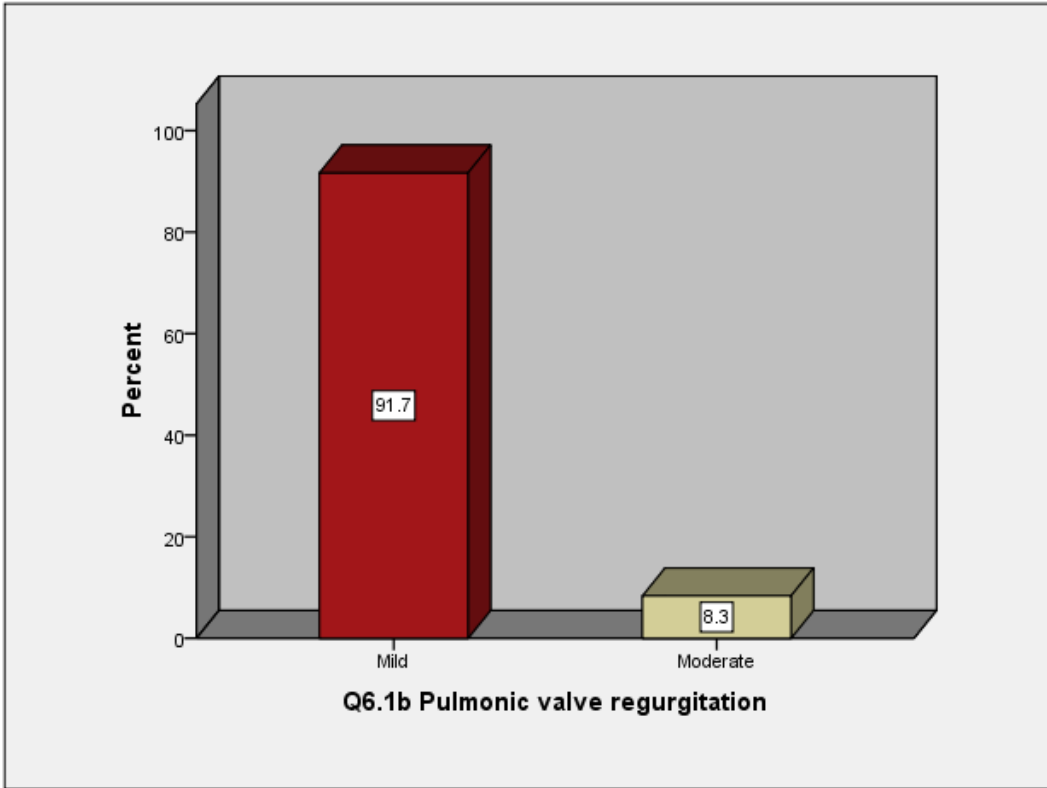


FIG 4.29

a Par chart of Pulmonary valve regurgitation in the present study, sample volume (N) =12children had PR.

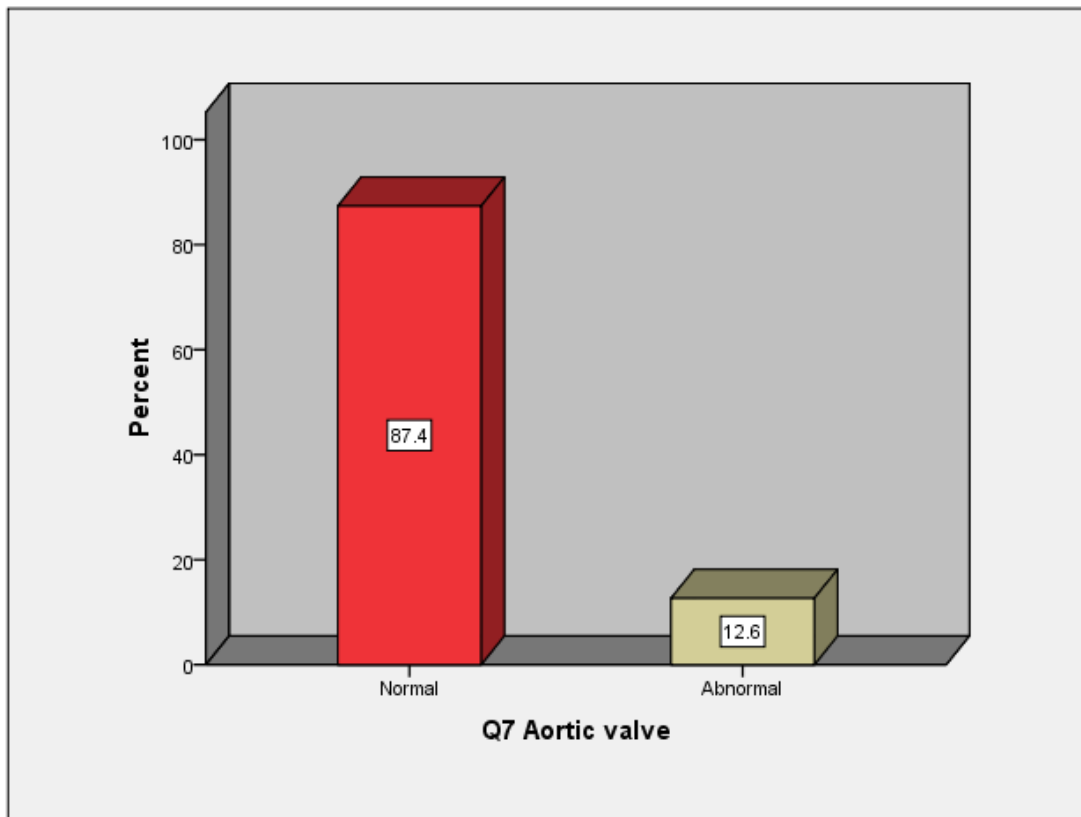


FIG 4.30

a Par chart of Aortic valve in the present study, sample volume (N) =356 children with different types of congenital cardiac malformations

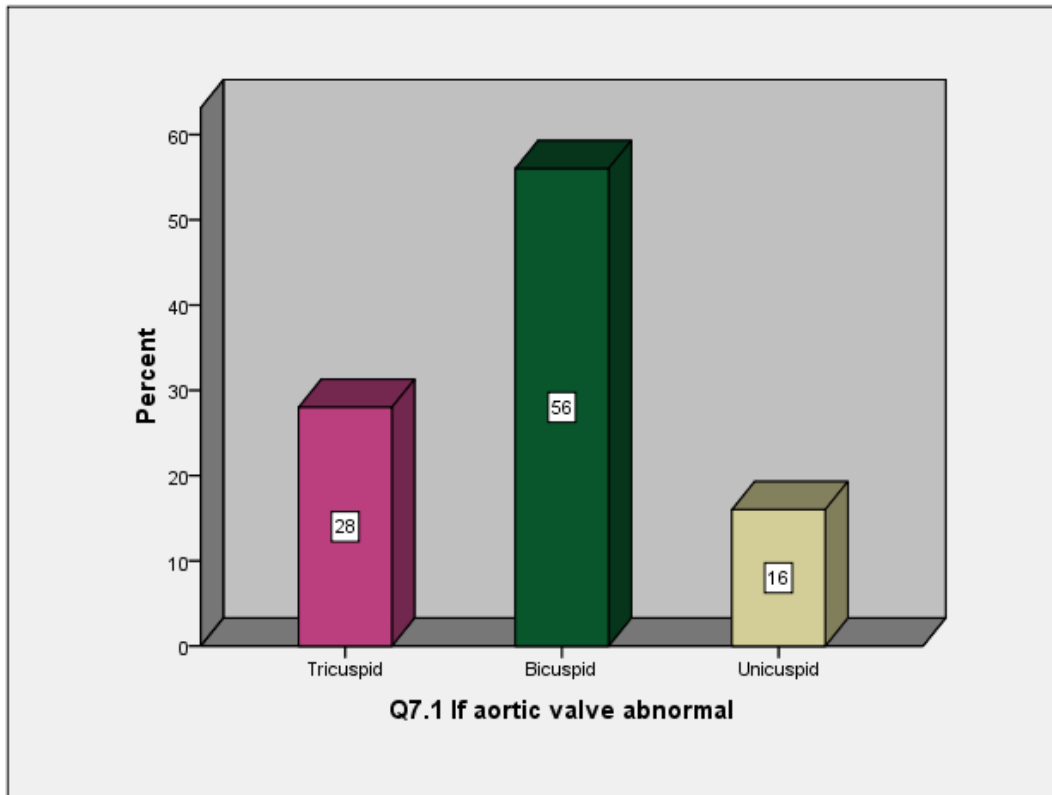


FIG 4.31

a Par chart of Abnormal Aortic valve in the present study, sample volume (N) =25 children.

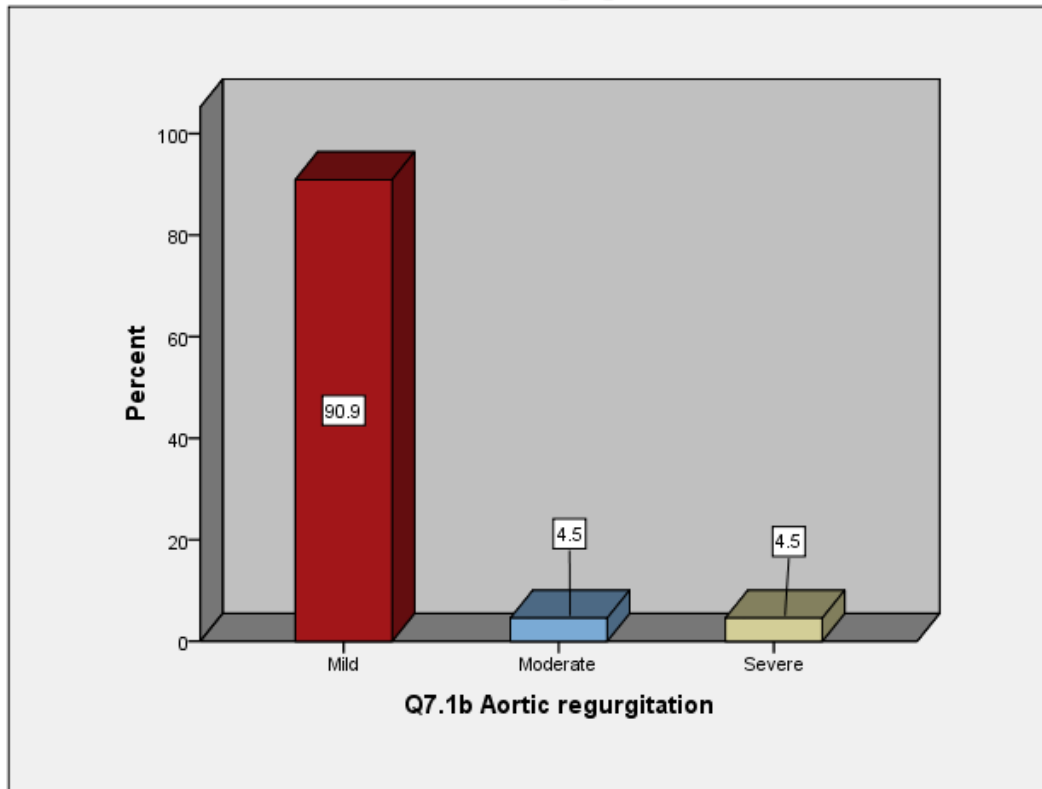


FIG 4.32

a Par chart of Aortic valve Regurgitation in the present study, sample volume (N) =22 children with
AR

Aortic stenosis

	Frequency	Percent	Valid Percent	Cumulative Percent
Valid Valvar STENOSIS	9	2.5	100.0	100.0
Missing System	347	97.5		
Total	356	100.0		

(Table 4.4)

Aortic Stenosis in the present study, sample volume (N) =356 children with different types of congenital cardiac malformations.

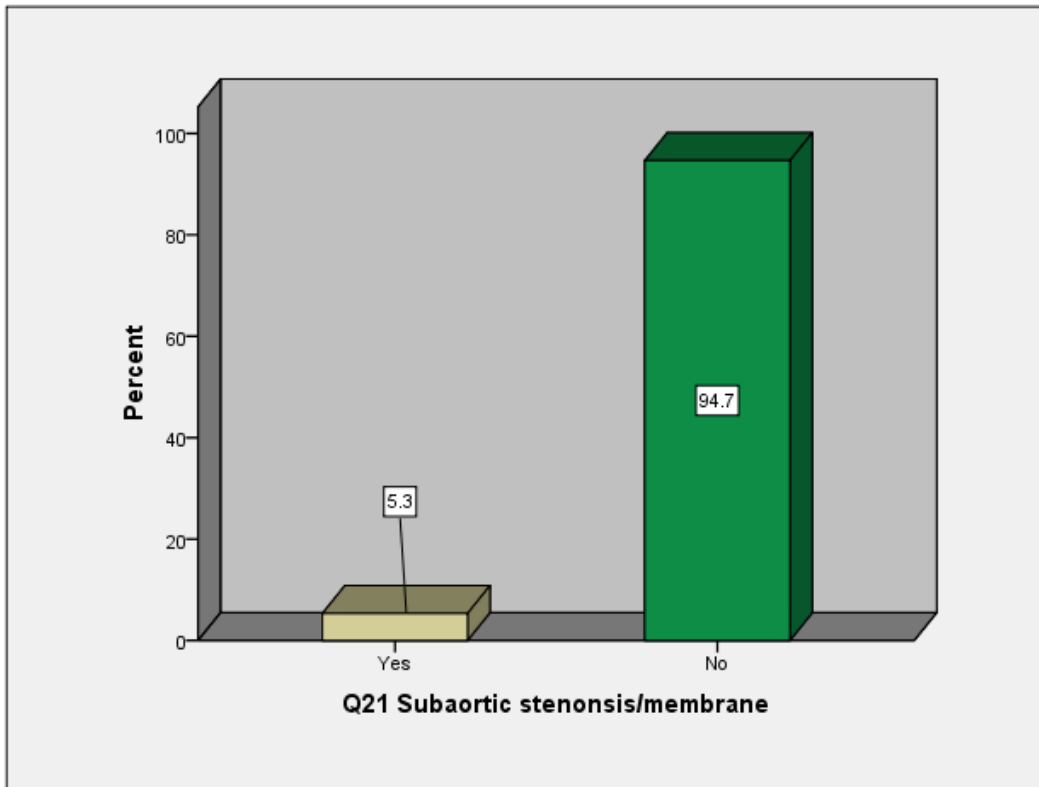


FIG 4.33

a Par chart of Sub-Aortic stenosis/membrane in the present study, sample volume (N) =356 children with different types of congenital cardiac malformations

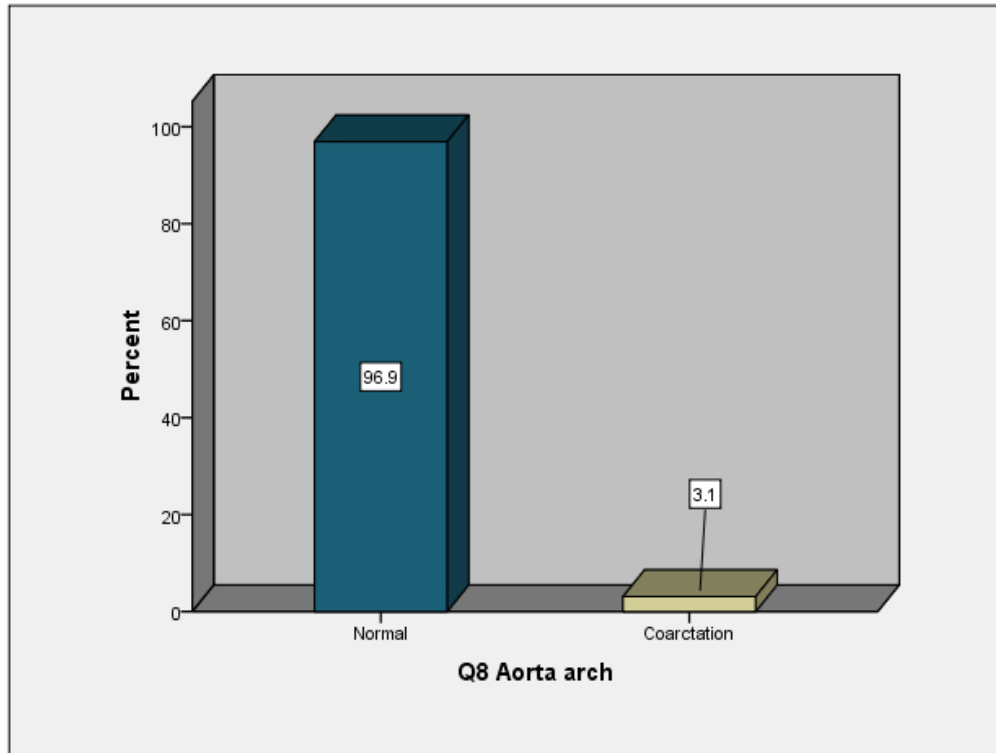


FIG 4.34

a Par chart of Aortic Arch in the present study, sample volume (N) =356 children with different types of congenital cardiac malformations

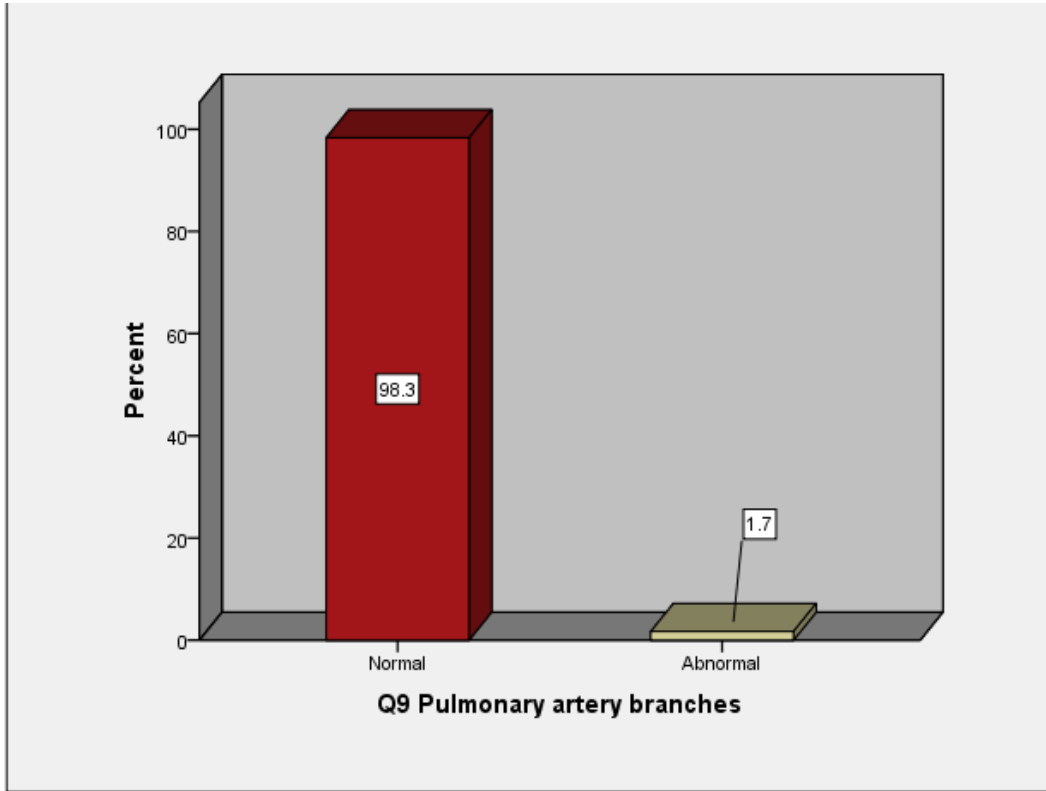


FIG 4.35

a Par chart of Pulmonary Artery Branches in the present study, sample volume (N) =356 children with different types of congenital cardiac malformations

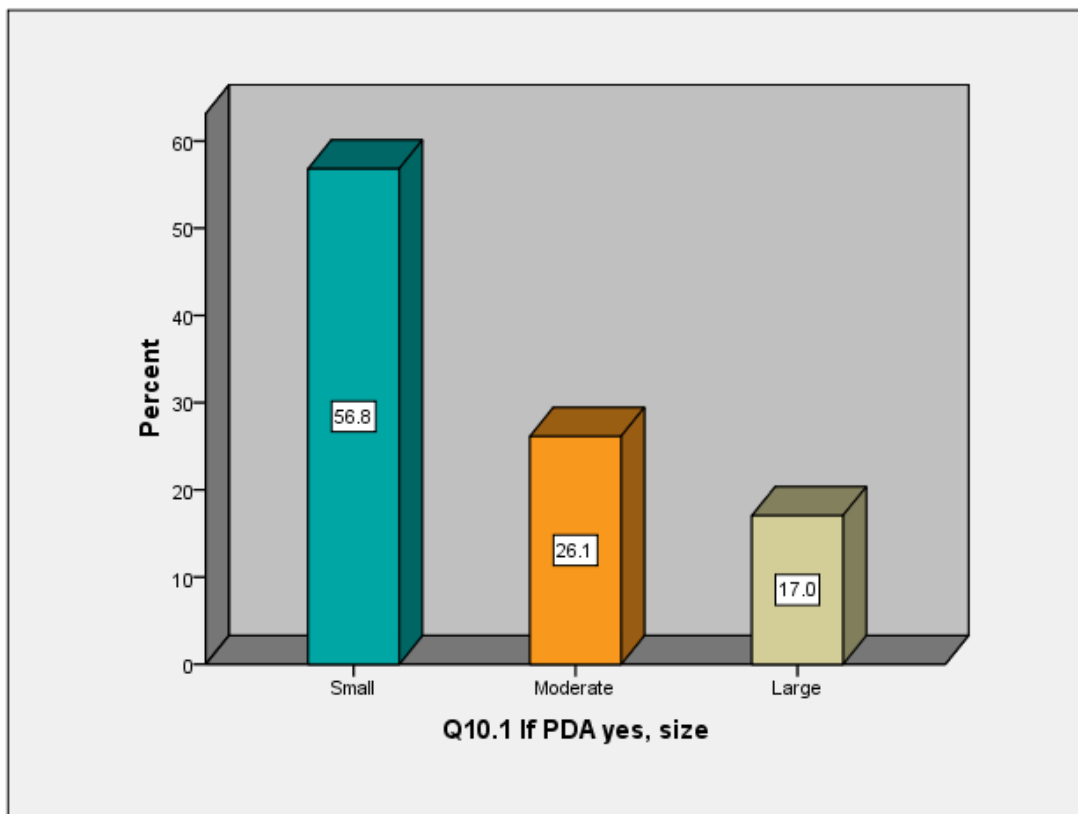


FIG 4.36

a Par chart of Patent Ductus Arteriosus(PDA) in the present study, sample volume (N) =356 children with different types of congenital cardiac malformations

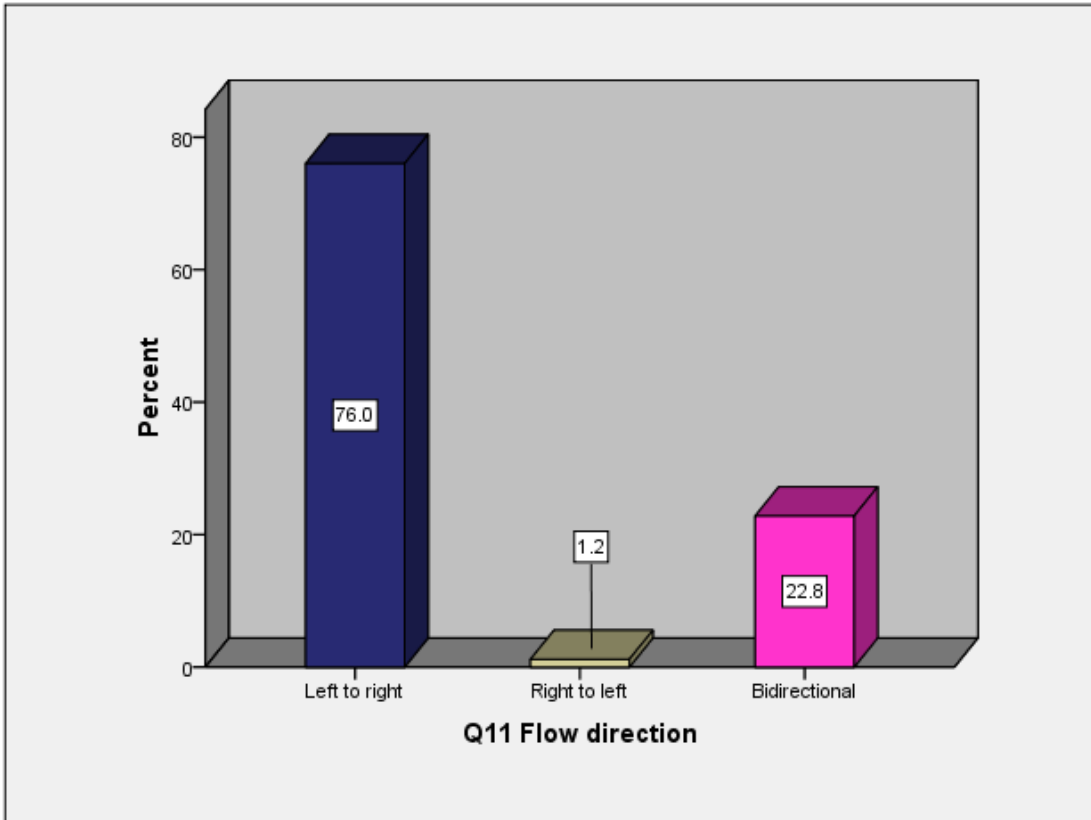


FIG 4.37

a Par chart of Patent Ductus Arteriosus (PDA) blood flow direction in the present study, sample volume (N) =356 children with different types of congenital cardiac malformations.

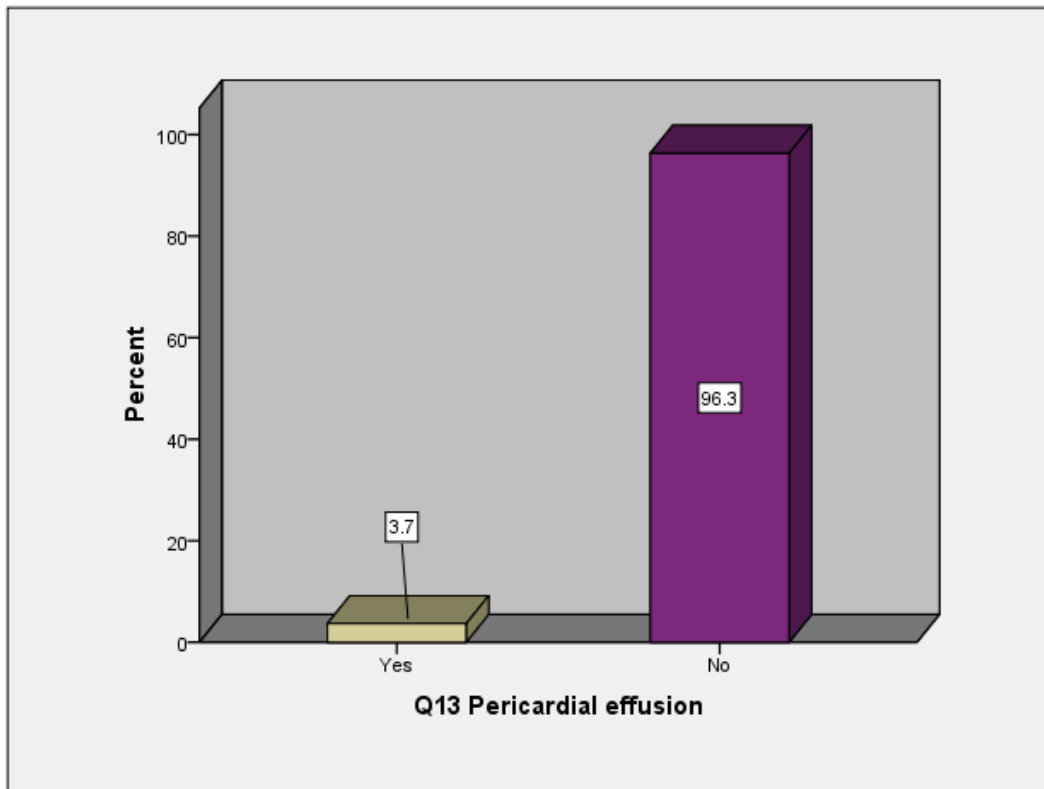


FIG 4.38

a Par chart of Pericardial Effusion in the present study was detected in 13(3.7%) patients, sample volume (N) =356 children with different types of congenital cardiac malformations.

Chapter Five

Discussion, Conclusion
&
Recommendations

CHAPTER FIVE

Discussion, Conclusion & Recommendations

5.1 DISCUSSION

Congenital cardiac malformations are a serious health concern and are associated with great morbidity and mortality (Alabdulgader A, 2001).

Heart diseases constitute an important group of pediatric illness and major cause of childhood mortality and morbidity (Knott Craig CJ et al, 1995). VSD is the commonest of all congenital lesions. And occurs in approximately 8 of every 1000 live births.

Late diagnosis of CHD carries a high risk of avoidable mortality, morbidity, and handicap (Christopher J et al, 1995).

With the advent of echocardiography and other sophisticated diagnostic tools. The diagnosis of congenital heart disease has become easy and the prevalence rate can be measured more accurately.

In the present study of 356 patients with different types of congenital cardiac malformations. The patient's age was range from (1 day newborn –up to-15 years old). Maximum number of children with congenital cardiac malformation was observed below 6 years of age groups. Complex heart defects and mixed cardiac lesions like VSD with Right ventricular out flow obstruction were also present. This finding is the same as already reported in a previously done study.

Out of this study majority of patients had normal body 83.95%, while 16.1% were dysmorphic, Down Syndrome (DS) is the most common disorder associated with acyanotic congenital cardiac malformations. This finding agree with previous studies in KSA ; Alabdulgader, (2001), reported that Down syndrome was found in 6% of all patients with congenital cardiac defects. Down syndrome patients with CHD presented with higher proportion of acyanotic lesions, than cyanotic lesions (Alabdulgader, 2001). Al-Jarallah (2009) reported a 49% prevalence of CHD among DS patients (Al-Jarallah, 2009). Al-Aama et al. (2012) described the prevalence of CHD among DS

patients in a prospective hospital-based study conducted between 2007 and 2011. A total of 130 DS patients aged 0 to 33 years (mean 5 ± 4.9) were included. The results found CHD in 86.8% of the patients with a prevalence of 7.1 per 1,000 live births (Al-Aama et al., 2012). Abbag et al., in 2006 documented that CHDs was found in 61.3% of DS patients (Abbag, 1998). Al Massned et al., found that DS is the most commonly encountered syndrome among children with CHD (Al-Mesned et al., 2012).

There were 149 males (43.2%) and 195 females (56.5%). An increase of reported prevalence of congenital cardiac malformation. Females are more vulnerable for heart disease our findings are similar to previous studies. (Abbag F. Pattern of Congenital Heart Disease in the Southwestern Region of Saudi Arabia. *Ann Saudi Med.* 1998; 18:393–395).

Distribution of specific lesions and sex distribution were similar to findings from other parts of the world; with increasing availability of echocardiography facilities more cases of congenital cardiac malformation are likely to be identified early.

There were 163(45.6%) cases of ASD atrial septal defect, VSD ventricular septal defect was detected in 114(32%) of cases, 176(49.7%) patients of PDA Patent Ductus Ateriosus (PDA), 9(2.5%) had AVSD, 5.4 Subaortic stenosis /or membrane, Coarctation of Aorta (CoA) was detected in 11(3.1%), 0.3% had Aorto-ventricular tunnel, The pulmonary valve abnormalities was detected in 52(14.6%) as following; Pulmonary stenosis in 40(11.2%) patients ,and Pulmonary regurgitation in 12(3.4%) patients., and 52(14.6%) had congenital mitral valve abnormalities, Mitral regurgitation(MR) 49(13.8%),and prolapse in 3(.8%) patients.

Most of these patients were asymptomatic 63.3 %, discover during screening 36.4 % had heart murmur, and 0.6% had recurrent chest infection.

Symptoms indicate the presence of heart failure was detected in 43 patients (12.1%) only out of 356 patients. The most common symptom was Fatigue which detected in 30 patients (69.6)%, Failure

to thrive(FTT) in 3 patients(7.0) %, Tachypnea in 3 patients(7.0) % , Interrupted feeding in 1 patient (2.3) %, and active pericardium also detected in 1 patient (2.3) %.(See Chart-5)

Regarding the right atrium size in the present study 83.1% of cases with normal size, 15.7% had Mild dilated right atrium, and 1.1% had moderate dilatation.

Regarding the left atrium size in the present study 91.6% of cases with normal size, 8.4% had Mild dilatation.

ASD are quite frequent congenital anomaly and which can present with symptoms of heart failure (Bostan OM et al ,2007; Oskit EM et al ,1993).The natural course e of ASD closure varies from patients to patient. ASD often closes spontaneously (da silva VM et al ,2007;Chang HK et al , 2011) ,but some times the size increases with growth of the patient (Kharouf R et al, 2011; Nawal Azhari et al, 2004).In this current study the interatrial septal was intact in 54.1%, and ASD Atrial Septal was detected in 163(45.9%) patients .which act as the sencondmost common acyanotic congenital cardiac malformation, When we study those 163(45.9%) patients with atrial septal we defected that; interatrial septal defect was most commonly small in 55.3%, Moderate size ASD in (30.7%) patients, and large ASD in 14.0%.There was 88.7% secundum ASD type act as the most common type, (8.6%) patients had primum , and 2.6% sinus venosus. In the present study we found a significant relationship between the initial size of ASD and the initial age at the time of diagnosis. Larger ASDs were present in older children while younger children had smaller ASD size.

In regarding to ASD we detect that; the right atrium size was normal in most of cases 114 (69.9%), followed by mild dilated in 45(27.6%), and moderated dilatation in 4 (2.5%). There increase in heart size in the last group and ASD wall stretching due to more dilatation of the right atrium.This finding was more than what had been reported in other studies which found only in 6.6% of patients in which ASD size increase with time(Lee C et al, 2014; Hansilk Al et al, 2006). In our study, almost half of the patients showed regression of the size of ASD size and one fifth had spontaneous ASD

closure. The spontaneous closure in our study is less compared to previous studies in which even 90% of ASD ended by spontaneous closure (Helgason H et al, 1999). These findings could be due to difference in the base line characteristics of different studies. Majority of our patients 88% were asymptomatic from cardio-respiratory point of view while only smaller number had presented with recurrent pulmonary infection and symptoms of heart failure which correlates with previously reported data (Lee C et al, 2014).

We found an unfavorable effect of low body weight on the spontaneous ASD closure. However, it is difficult to determine if the low weight gain is what leads to less chance of spontaneous ASD closure or if the large ASD is what causes these children to gain less weight. Other factor that influenced the incidence of spontaneous ASD closure was the gender. Both spontaneous closure of ASD and regression in ASD was noted more in females.

The tricuspid valve was normal 63.5% of patients, while Tricuspid regurgitation (TR) was detected in 136(36.5%) patients as following; 92.9% mild TR the most common, 5.3% moderate TR, and 1.8% severe TR.

The mitral valve was normal in 85.4% of patients, while 13.8% were detected to have MR mitral regurgitation, and 0.8% developed mitral valve prolapse.

Mitral regurgitation (MR) was detected in 49(13.8%) patients; 87.0% mild MR, 13.0% moderate MR.

Regarding the right ventricle cavity size in the present study 85.6% of cases with normal size, 14.4% had increased size of RV; 93% had mild enlargement and 7% with moderate enlargement.

Right Ventricular Outflow Tract (RVOT): obstruction was detected only in 1.1% while the remaining patients had normal RVOT 98.9% children with different types of congenital cardiac malformations.

Right Ventricular systolic Pressure (PVSP); was normal in 98.9% children with different types of congenital cardiac malformations, only 1.1% was elevated.

Regarding the left ventricle cavity size in the present study 325(91.3%) of cases with normal size, 31(8.7%) patients had increased size of LV. Among 31(8.7%) patients had increased size of LV there was; 82.4 mild enlargement, and 17.6% moderate enlargement.

The interventricular septum was intact in 68.0%, and VSD Ventricular Septal was detected in 114(32.0%) patients. In the present study of 114(32.0%) patients with ventricular septal defect. The interventricular septum defect was small in 57.8%, Moderate size VSD in (11.8%) patients, and large VSD in 30.4%. The interventricular septum defect types were: membranous 67(63.8%), Outlet septal defect (1.0%) patients, Inlet-Av septal defect in (15.2%), and muscular VSD in (20.0%). The shunt jet direction in the present study of 114(32.0%) patients with ventricular septal defect. 93.1% left-to-right shunt, 1.00% right-to-left shunt, and 5.9% bidirectional shunt. The pressure gradient (PG) of 114(32.0%) patients with ventricular septal defect was; less than 20 mmHg in (10.1%), 30-40 mmHg in (8.7%), 40-50 mmHg in (10.1%), and more than 50 mmHg in (71.0%) the most common PG.

Ventricular septal defect (VSD) is the most common CHD in infants and children, accounts for 25% of CHD, the prevalence of VSD was almost the same as found in studies done in India, Taiwan(Yu C.H et al, 2009; Abbag F ,1998).

When seen anatomically majority of patients had membranous type of VSD followed by muscular type of VSD. Membranous defect was present in 40(60.9%) of patients, muscular type of VSD was present in 14(20.3%)patients, these figures are in agreement with the findings of another European study(Becker SM,et al;2001).

The pulmonary valve was normal in 316(85.4%), and abnormal in 52(14.6%) as following; Pulmonary stenosis in 40(11.2%) ,and Pulmonary regurgitation in 12(3.4%). Total of 52(14.6%)

patients with abnormal pulmonary valve; there were 40(76.9 %) patients had pulmonary stenosis (PS), with sub types as following; valvar stenosis in 37(92.5%), subvalvar stenosis in 2 (5.0%), and 1(2.5%) supra-valvar in 1(2.5%). Out of 40(76.9 %) patients had pulmonary stenosis (PS), there were 73% had mild stenosis, 13.5% moderate, and 13.5 % had severe PS. Pulmonary regurgitation was detected in 12(23.1%) out of 52 patient with abnormal pulmonary valve. There were 91.7 % had mild pulmonary regurgitation, and (8.3%) had moderate regurgitation.

The aortic valve was normal in (87.4)% ,and abnormal in (12%). Abnormality detected aortic valve in 25 patients as following; 7(28%) tricuspid valve, 14(56%) Bicuspid and 4(16%) unicuspid valve. Aortic regurgitation was detected in 22(6.2%) patients; 20(90.9%) mild regurgitation , 1(4.5%) moderate, an 1(4.5%) severe aortic regurgitation.

Valvar Aortic stenosis (AS) was detected in 9(2.5%) of patient. Subaortic Stenosis/Membrane was detected in 19(5.3%) patients

The aortic arch was normal in 345(96.9%) and Coarctation of Aorta (CoA) was detected in 11(3.1%).

The Pulmonary Artery Branches were normal in 350(96.3%) and abnormal branches was detected in 6(1.7%).

The Patent Ductus Arteriosus (PDA) was detected in 176 (49.7%) patients act as the most common congenital cardiac malformation in this study; (56.8%) small size PDA, (26.1%) moderate size PD, and (17.0%) had large PDA. The blood flow direction was most commonly left –to-right in 130(76.0%), followed by the Bidirectional flow in 39(22.8%) patients, and the less common is Right-to Left in 2(1.2%)

Widespread use of echocardiography has made earlier diagnosis of patent ductus arteriosus (PDA) possible. Its increasing accuracy as a superior diagnostic tool resulted in increased values for

incidence of congenital cardiac malformations by uncovering commonly-overlooked lesions such as muscular ventricular septal defect, small patent ductus arteriosus Knowledge of the incidence of various types of congenital heart disease and their clustering in time or place may aid in understanding what caused them(A.A.A. Alabdulgader,2006)

The pericardial effusion was detected in 13(3.7%) patients.

The general objective of this study; to Study the Pediatric Acyanotic Congenital Cardiac Malformations using Echocardiography which all findings were mentioned above.

Specific objectives are To assess the prevalence and incidence of Acyanotic Congenital Cardiac Malformations in Saudi Arabia and all were recorded, to correlate between Echocardiographic findings and clinical findings most of patients were asymptomatic 63.3 %, discover during screening due to other physical and clinical examination findings, so both findings work together ,36.4 % had heart murmur, and 0.6% had recurrent chest infection.

While in the other hand clinical symptoms indicate the presence of heart failure play a vital role in the diagnosis of congenital cardiac malformation using echocardiography. , and to assess the heart structures changes in each defect (LV, RV, LA, RA, MV,...) .

We detect changes in these structure varied due to type and severity of the lesion.

ASD was found to be the second most common acyanotic congenital cardiac malformation (45.6%) in our study. This is in contrary to what is reported in other studies (Alnajjar AA, et al,).

Incidence of PDA was quiet high in the present study, Act as the most common congenital cardiac malformation. Which was present in 176(49.7%).

5.2 CONCLUSIONS

The study gives an overview of acyanotic congenital cardiac malformations in Saudi children admitted to King Fahad Cardiac Center ,Pediatric Cardiology Unit - King Khalid University Hospital -King Saud University-Riyadh-KSA.

Incidence of acyanotic congenital cardiac malformations is high among Saudi children; Careful evaluation and early diagnosis in high-risk group are highly indicated. As advanced tools of diagnosis have come up.

There is a need for development of prenatal screening programs for congenital cardiac malformations in our population so as to provide better medical care and improved outcome of CHD in the region.

In order to avoid complications, reduce mortality and improve quality of life, earlier detection and correction of disease is of utmost importance.

Awareness amongst parents and professionals will help do these at the optimal time.

In spite of remarkable progress in diagnosis and management of congenital cardiac malformations, they are still the main reason for death and complications in some of Arab countries.

The echocardiography, in conjunction with clinical features represents a significant factor in the diagnosis and follow up.

Heart diseases not only contribute to a significant morbidity and mortality and reduced quality of life, but also cause a tremendous psychological stress and economic burden to the whole family.

However, if the problems were recognized at earlier age, the chance of long term complications might be less with better outcome.

Pediatric echocardiography as diagnostic tool should be made more widely available especially in tertiary institutions to enable early diagnosis and, screening for possible cardiac defects during pregnancy.

All newborn babies should be examined thoroughly for any evidence of congenital cardiac malformations by pediatrician before hospital discharge and on follow up visits in the early neonatal period.

5.3 RECOMMENDATIONS

There should be a careful fetal ultrasound scanning to rule out any cardiac congenital cardiac malformation prenatally.

Prenatal diagnosis will improve ascertainment, but also allow for interventions, which may alter the prevalence at live birth.

The fetal echocardiography should be as a routine for all pregnant women.

Increase the utilization of screening echocardiography to become as a routine examination for new born to rule out the asymptomatic congenital cardiac malformation.

Further studies should be done in Saudi Arabia and Sudan, and all Arab countries. And close study to each lesion separately.

Further knowledge is needed about risk factors (including familial and environmental factors) related to Saudi Arabia.

Screening echocardiography for Sudanese school children in collaboration with a highly specialized pediatric Cardiology centers in Saudi Arabia.

Using accepted echocardiographic nomenclature regarding to acyanotic congenital cardiac malformations morphological and functional description, developmental aspects, and interrelationships.

REFERENCES

- Al-Jarallah AS Down's syndrome and the pattern of congenital heart disease in a community with high parental consanguinity. *Med Sci. Monit.* 15(8):409-412, 2009.
- Al-Mesned A, Al Akhfash AA, Sayed M. Incidence of severe congenital heart disease at the province of Al-Qassim, Saudi Arabia. *Congenit Heart Dis.* 7(3):277-282, 2012.
- Amirah M. Alenezi, Nada M Albawardi, Anna Ali, Mowafa S. Househ , Ashraf Elmetwally .The epidemiology of congenital heart diseases in Saudi. *Journal of Public Health and Epidemiology.* Vol. 7(7), pp. 232-240, 2015.
- Arabia: A systematic review Au Harb M, Hey E, Wrence deathin Infancyfrom unrecognized congenital heart disease. *Arch, Dis Child* 71:3-7, 1994.
- Al-Aama JY, Bondagji NS, El-Harouni AA. Congenital heart defects in Down syndrome patients from western Saudi Arabia. *Saudi Med. J.* 33(11):1211-1215, 2012.
- Alnajjar AA, Morsy MF, Almuzainy IS, Sheikh AA. Pediatric heart diseases in Madina, Saudi Arabia. Current status and future expectations. *Saudi Med J.* 30(9):1186-1191, 2009
- Alqurashi M, ElMouzan M, Al Herbish A. Symptomatic congenital heart disease in the Saudi Children and Adolescents. Project. *Ann. Saudi Med.* 27(6):442-444, 2006.
- Anderson RH, Becker AE, Freedom RM, et al. Sequential segmental analysis of congenital heart disease. *Pediatr Cardiol* 5:281-288,1984.
- A Suliman .The state of heart disease in Sudan, *Cardiovasc J Afr.* 22(4): 191–196, 2011.

Aubert S, Henaine R, Raisky O, et al. Atypical forms of isolated partial atrioventricular septal defect increase the risk of initial valve replacement and reoperation. *Eur J Cardiothorac Surg* 28:223-228, 2005.

Allan LD, Sharland GK, Milburn A, et al. Prospective diagnosis of 1006 consecutive cases of congenital heart disease in the fetus. *J Am Coll Cardiol* 23:1452-1458,1994.

Angelini P, Lopez-Velarde P, Leachman RD. Ventriculoarterial discordance revisited: Angiographic presentation and discussion of a typical case. *Tex Heart Inst J*;15(3):174-182, 1988.

Alexiou C, Langley SM, Dalrymple-Hay MJ, et al: Open commissurotomy for critical isolated aortic stenosis in neonates. *Ann Thorac Surg* 71:489-493,2001.

A.A.A. Alabdulgader. Congenital heart disease in Saudi Arabia: current epidemiology and future projections. *Eastern Mediterranean Health Journal*, Vol. 12, 2006.

Alabdulgader AA. Congenital heart disease in 740 subjects: Epidemiological aspects. *Ann. Trop. Paediatr.* 21(2):111-118, 2001.

Anne Waugh, Allison Grant; *Anatomy and Physiology in Health and Illness*,9th ed ,2001.

Anabtawi IN, Ellison RG: Congenital stenosing ring of the left atrioventricular canal (supravalvular mitral stenosis). *J Thorac Cardiovasc Surg* 49:994-1005,1965.

Becker SM, Al Halees Z, Molina C, Paterson RM. Consanguinity and congenital heart disease in Saudi Arabia. *American Journal Of Medical Genetics* 99(1), 8-13, 2001.

Benjamin W. Eidem, Frank Cetta, and Patrick W. O’Leary et al: *Echocardiography in Pediatric and Adult Congenital Heart Disease* pp500, 2010.

Backer CL, Mavroudis C: Congenital heart surgery nomenclature and database project: Patent ductus arteriosus, coarctation of the aorta, interrupted aortic arch. *Ann Thorac Surg* ; 69:S298-S307, 2000.

Brom AG: *Obstruction of the Left Ventricular Outflow Tract*, Rockville, Md, Aspen, 1988.

Baht BA, Sheikh A, Khan A, Dad MAI. Pattern of congenital heart disease among children in Madina Munawara. *J. Saudi Heart Assoc.* 9:16-19, 1997.

Blue GM, Kirk EP, Sholler GF, Harvey RP. Congenital heart disease: current knowledge about causes and inheritance. *Med. J. Aust.* 197(3):155-159, 2012.

Cook AC, Anderson RH: Attitudinally correct nomenclature ,editorial *Heart* 2002;87:503–506.

Calcaterra G, Anderson RH, Lau KC, Shinebourne EA: Dextrocardia value of segmental analysis in its categorisation. *Br Heart J* 42:497-507, 1979.

Cornell WP, Elkins RC, Criley JM, Sabiston Jr DC: Supravalvular aortic stenosis. *J Thorac Cardiovasc Surg* 51:484-492,1996.

Collins-Nakai RL, Rosenthal A, Castaneda AR, et al: Congenital mitral stenosis. A review of 20 years' experience. *Circulation* 56:1039-1047,1977.

Coto EO, Judez VM, Juffe A, et al: Supravalvular stenotic mitral ring. A new case with surgical correction. *J Thorac Cardiovasc Surg* 71:537-539, 1976.

Davachi F, Moller JH, Edwards JE: Diseases of the mitral valve in infancy. An anatomic analysis of 55 cases. *Circulation* 43:565-579, 1971.

David G. Nichols, Ross M. Ungerleider, Philip J. Spevak, William J. Greeley, Duke E. Cameron, Dorothy G. Lappe, Randall C. Wetzel; *Critical heart disease in infants and children*. 2nd edition, part 4, 2006.

Drummond W, Gregory G, Heymann M, Phibbs R: The independent effects of hyperventilation, tolazoline, and dopamine on infants with persistent pulmonary hypertension. *J Pediatr* 98:603-611,1981.

DeVore GR, Horenstein J, Siassi B, Lawrence DP. Fetal echocardiography. VII. Doppler color flow mapping: a new technique for the diagnosis of congenital heart disease. *Am J Obstet Gynecol* 156:1054–64, 1987.

De la Cruz MV, Nadal-Ginard B. Rules for the diagnosis of visceral situs, truncoconal morphologies and ventricular inversions. *Am Heart J* 84:19-32, 1972.

Dickinson DF, Arnold R, Wilkinson JL. Congenital heart disease among 160480 liveborn children in Liverpool 1960 to 1969: implications of surgical treatment. *Br Heart J.* 46 :55 –62,1981.

Demir T, Ostund T, Eroglu AG, et al. Outcome for patients with isolated atrial septal defect in the oval fossa diagnosed in infancy. *Cardiol Young*, 18, 75–8, 2008.

Edwards WD. Congenital heart disease. In: Schoen FJ, ed. *Interventional and Surgical Cardiovascular Pathology: Clinical Correlations and Basic Principles*. Philadelphia: WB Saunders, 281-367, 1989.

Edwards WD. Applied anatomy of the heart. In: Brandenburg RO, Fuster V, Giuliani ER, et al., eds. *Cardiology: Fundamentals and Practice*. Vol. 1. Chicago: Year Book Medical 47-109, 1987.

El Hag AI. Pattern of congenital heart disease in Sudanese children. *East Afr Med J.* 71(9):580–586, 1994. [PubMed].

Feigenbaum,Harvey, Armstrong, William F., Rayan Thomas. *Feigenbaum's Echocardiography*,6th Edition,2005.

Fischer R, Szkutnik M, Chodór B, Białkowski J Postępy.Kardiol. ().Spontaneous closure of a large atrial septal defect in an infant. Interwencyjnej, 10, 264-6, 2014.

Fyler DC, Buckley LP, Hellenbrand WE, et al. Endocardial cushion defect. Report of the New England Regional Infant Cardiac Program. J Pediatr;65(suppl):441-444,1980.

Gutgesell HP, Huhta JC. Cardiac septation in atrioventricular canal defect. J Am Coll Cardiol 8:1421-1424, 1986.

Garcia RE, Friedman WF, Kaback MM, Rowe RD: Idiopathic hypercalcemia and supraaortic stenosis: Documentation of a new syndrome. N Engl J Med 271:117-120,1964.

Harmon JV Jr, Edwards WD. Venous valves in subclavian and internal jugular veins: Frequency, position, and structure in 100 autopsy cases. Am J Cardiovasc Pathol 1:51-54, 1987.

Hugh D. Allen, David J. Driscoll, Robert E.Shaddy, Timothy F. Feltes; Heart Diseases in infants, children, and adolescents Including the fetus and Young Adults,7th ed,Volume-1,2008.

Hoffman JI, Kaplan S: The incidence of congenital heart disease. J Am Cardiol 39:1890–1900, 2002.

Hoffman JIE, Kaplan S, Libberthson RR. Prevalence of congenital heart disease. Am. Heart J. 147(3):425-439, 2004.

Huhta JC, Hagler DJ, Seward JB, et al. Two-dimensional echocardiographic assessment of dextrocardia: A segmental approach. Am J Cardiol 50:1351-1360, 1982.

J. Hodler • G.K. von Schulthess • Ch.L. Zollikofer ,Diseases of the Heart, Chest & Breast Diagnostic Imaging and Interventional Techniques 39th International Diagnostic Course in Davos (IDKD) PP 162,2007.

Jae K. Oh,James B. Seward,A. Jamil Ta ; The Echo Manual,3rd Edition,2006.

Jae K. Oh, James B. Seward, A. Jamil Tajik. The Echo Manual. 1994.

Jaiyesimi F, Ruberu DK, Misra VK. Pattern of congenital heart disease in King Fahd Specialist Hospital, Buraidah. *Ann. Saudi Med.* 13(3):407-411,1993.

Khalil S, Gharieb K, El Haj M, Khalil M, Hakiem S. Prevalence of congenital heart disease among schoolchildren of Sahafa Town, Sudan. *Eastern Med Hlth J.* 3: 24–28, 1997 .

Kenna AP, Smithells RW, Fielding DW. Congenital heart disease in Liverpool. *Q J Med.*;44(173):17–44,1975. [PubMed]

Keith JE, Rowe RD, Vlad P, Keith JE, Rowe, RD, Vlad P (eds). *Heart Disease Incidence in Infancy and Childhood.* 2nd edition, 1967.

Kovalchin JP, et al. Echocardiographic determinants of clinical course in infants with critical and severe pulmonary valve stenosis. *J Am Coll Cardiol* 29(5):1095-1101, 1997.

Kitzman DW, Scholz DG, Hagen PT, et al. Age-related changes in normal human hearts during the first 10 decades of life. Part II (Maturity): A quantitative anatomic study of 765 specimens from subjects 20 to 99 years old. *Mayo Clin Proc* 63:137-146,1988.

Lev M, Liberthson RR, Gen JG, et al: The pathologic anatomy of mesocardia. *Am J Cardiol* 28:428-435,1971.

Lee C. Lim G. Kim W.S. Han H.S. Clinical Characteristics and Outcome of Incidental Atrial Septal Openings in Very Low Birth Weight Infants *Neonatology* ,105,85-90, 2014.

McGrath LB, Gonzalez-Lavin L. Actuarial survival, freedom from reoperation, and other events after repair of atrioventricular septal defects. *J Thorac Cardiovasc Surg*; 94:582, 1987.

McGoon DC, Mankin HT, Vlad P, Kirkland JW: The surgical treatment of supra-ventricular aortic stenosis. *J Thorac Cardiovasc Surg* 41:125, 1961.

Mulder DG, Katz RD, Moss AJ, Hurwitz RA: The surgical treatment of congenital aortic stenosis. *J Thorac Cardiovasc Surg* 55:786-796, 1968.

Myung K.Park; *Pediatric Cardiology for Practitioners*, 5th Edition, 9 &10:190-210/3 &6;72-73-118,119,196-171, 212,2008.

Mitchell SC, Korones SB, Berendes HW. Congenital heart disease in 56109 births: incidence and natural history. *Circulation.*;43:323–329,1971. [PubMed].

Nachlieli T, Gershoni-Baruch R: Dextrocardia, microphthalmia, cleft palate, choreoathetosis, and mental retardation in an infant born to consanguineous parents. *Am J Med Genet* 42:458-460,1992.

Piot JD, Lucet P, Losay J, Touchot A, Petit J, David P, Piot C, Binet JP.et al . Diagnosis and localization of ventricular septal defects by two-dimensional echocardiography. 50 cases, 1981.

Rudolph A, Yuan S: Response of the pulmonary vasculature to hypoxia and H⁺ ion concentration changes. *J Clin Invest* 45:399-411,1966.

Robert H. Anderson,Edward J. Baker, Daniel J. Penny, Andrew N. Redington, Michael L. Rigby, Gil Wernovsky; *Paediatric Cardiology*, 3rd Edition 2010.

Razook JR. Associated atrial septal defects increase perioperative morbidity after ventricular septal defect repair in infancy. *Ann Thorac Surg* 59(3),573-8,1995.

Rosenquist GC: Congenital mitral valve disease associated with coarctation of the aorta: A spectrum that includes parachute deformity of the mitral valve. *Circulation* 49:985-993,1974.

Ruckman RN, Van Praagh R: Anatomic types of congenital mitral stenosis: Report of 49 autopsy cases with consideration of diagnosis and surgical implications. *Am J Cardiol* 42:592-601,1978.

Robicsek F, Sanger PW, Daugherty HK, Montgomery CC: Congenital quadricuspid aortic valve with displacement of the left coronary orifice. *Am J Cardiol* 23:288-290,1969..

Sharma S, Devine W, Anderson RH, et al. The determination of atrial arrangement by examination of appendage morphology in 1842 autopsied specimens. *Br Heart J*;60:227-231,1988.

Saito T, Ohata K, Nakayama Y, et al. Natural history of medium-sized atrial septal defects in pediatric cases. *J Cardiol*,60,248–51,2012.

Senocak F, Karademir S, Cabuk F, et al. Spontaneous closure of Interatrial septal openings in infants: an echocardiographic study. *Int J Cardiol*, 53,221-6,1996.

Studer M, Blackstone EH, Kirklin JW, et al. Determinants of early and late results of repair of atrioventricular septal (canal) defects. *J Thorac Cardiovasc Surg* 84:523-542, 1982.

Sam Richmond, Christopher Wren et.al; Early diagnosis of congenital heart disease,2002

Snider RA, Serwer GA, Ritter SA. Defects in cardiac septation. In: *Echocardiography in Pediatric Heart Disease*. 2nd ed 277-289, 1997.

Shone JD, Sellers RD, Anderson RC: The developmental complex of ‘parachute mitral valve,’ supraavalvular ring of left atrium, subaortic stenosis, and coarctation of the aorta. *Am J Cardiol* 11:714-725, 1963.

Sullivan ID, Robinson PJ, de Leval M, Graham Jr TP: Membranous supraavalvular mitral stenosis: A treatable form of congenital heart disease. *J Am Coll Cardiol* 8:159-164, 1986.

Sinha SN, Kardatzke ML, Cole RB, et al: Coarctation of the aorta in infancy. *Circulation* 40:385-398, 1969.

Siew Yen Ho, Michael L. Rigby, Robert H. Anderson; *Echocardiography in Congenital Heart Disease Made Simple*, 2005.

Sweeney LJ, Rosenquist GC. The normal anatomy of the atrial septum in the human heart. *Am Heart J* 98:194-199, 1979.

Samanek M. Prevalence at birth, natural risk and survival with atrioventricular septal defect. *Cardiol Young* 1:285-289, 1991.

Seward JB, Tajik AJ, Hagler DJ. Two-dimensional echocardiographic features of atrioventricular canal defect. In: Lundstrm N-R, ed. *Pediatric Echocardiography: Cross Sectional, M-mode and Doppler*. New York: Elsevier/North Holland 197-206, 1980.

Silverman NH, Ho SY, Anderson RH, et al. Atrioventricular septal defect with intact atrial and ventricular septal structures. *Int J Cardiol* 5:567-572, 1984.

Taylor NC, Somerville J. Fixed subaortic stenosis after repair of ostium primum defects. *Br Heart J* 45:689-697, 1981.

Ted Plappert CVT, Martin G St John Sutton, *The Echocardiographers' Guide* pp167, 2006.

Vibhuti N Singh. Ventricular Septal Defect Imaging, 2011.
<http://emedicine.medscape.com/article/348121-overview>.

Van Praagh R. Diagnosis of complex congenital heart disease: Morphologic-anatomic method and terminology. *Cardiovasc Intervent Radiol* 7:115-120,1984.

Van Praagh R. The segmental approach to diagnosis in congenital heart disease. *Birth Defects* 8:4-23,1972.

Walter H. Johnson and James H. Moller; *Pediatric Cardiology 'The Essential Pocket Guide'*, 2008.

Wright PW, Wittner RS: Obstruction of the left ventricular outflow tract by the mitral valve due to a muscle band. *J Thorac Cardiovasc Surg* 85:938-940,1983.

Wyman W. Lai, Luc L. Mertens, Meryl S. Cohen, Tal Geva. *Echocardiography in pediatric and congenital heart disease: from fetus to adult*. 3,11,12,13:22-33, 174.2009.

Wu MH, Chen HC Lu, Chun-Wei, Wang, Jou-Kou Huang, Shin-Chung Huang, San-Kuei.
Prevalence of congenital heart disease at live birth in Taiwan. *J. Pediatr.* 156(5):782-785, 2010.

Zhao QM, MaXJ, Jia B. Prevalence of congenital heart diseases. *Acta Pediatr.* 102:397-402, 2013.



Appendix (A) Data Collection Sheet

STUDY OF PEDIATRIC ACYANOTIC CONGENITAL CARDIAC MALFORMATIONS BY ECHOCARDIOGRAPHY IN KSA

Data Collection Sheet

I---Patient Data:				
1. MRN	2. Age.....	3. Gender a) M (b)F	4. Normal	5. Dysmorphic Mention.....
5. Weight:Kg	6. Height:.....cm	7. Age at Dx	8. FHx: (a) -ve (b) +ve c) Unknown	
II--- Symptoms				
1- Asymptomatic (Screening)		2- Heart Murmur	3-) Recurrent chest infection	
4- CHF:	(a) FTT	(b)Tachypnea	(c) Interrupted Feeding	(d) Active Pericordium
(e) Fatigue	(f) SOB	5. Others		
IV--- Echocardiographic Findings:				
1)) Atria				
1.Right Atrium size:				
(i) Normal	(ii) Mild Dilated		(iii) Moderate	(iv) Large
2.Left Atrium size:				
(i) Normal	(ii) Mild Dilated		(iii) Moderate	(iv) Severe
3. Atrial Septum	1)Intact	2) Atrial septal defect	3. if 2 a-small b-moderate c-large	
4. ASD Type	1) Primum	2) Secundum	3) Sinus venosus	4) Primum& Secundum
2)) Atrioventricular Valves				
1.Tricuspid Valve	1. Normal		2.Stenosis	3. Regurgitation
If there is TR	1) Mild		2) Moderate	3) Severe
2. Mitral Valve	1. Normal	2.Stenosis	3. Regurgitation	4. Prolepses
If there is MR	1) Mild		2) Moderate	3) Severe
3)) Ventricles				
1. RV Cavity Size	1. Small		2. Normal	3. Increased
4- If Increase	a) Mild enlargement		b) Moderate	c) Severe
2. RVOT obstruction	1) Yes		2)No	
3. RVSP	1) Normal		2) Elevated	
If Elevated	1) < 1/2 Systemic	2) 1/2 Systemic- Systemic		3) Suprasystemic
4. LV Cavity	1. Normal		2. Increased	

Size					
4- If Increase		a) Mild		b) Moderate	
5. LVOT obstruction		1) Yes		2) No	
6. Ventricular Septum		1. Intact	2. VSD	3. defect: Size a-small b-moderate c-large	
7. VSD Type	1) Membranous	2) Outlet Septum Defect		3) Inlet- AV septal defect	4) Muscular
8. Shunt jet direction:		1) Left-to-right		2) Right-to-left	3) Bidirectional
9. PG:		1) <20	2) 20-30	3) 30-40	4) 40-50
					5) 50-60 /More
4) Semilunar Valves					
1. Pulmonic Valve		1) Normal		2) Abnormal	
If 2; a. Stenosis:		1. Valvar		2. Subvalvar	
b- Degree of stenosis		i) mild		ii) Mod	
		(iii) severe		b. Regurgitation	
				1. Mild	
				2. Mod	
				3. Severe	
2. Aortic Valve		1) Normal		2) Abnormal	
				3) If 2 a. Tricuspid b. Bicuspid	
a. Stenosis:		1. Valvar		2. Subvalvar	
b. Regurgitation		1. Mild		2. Moderate	
				3. Severe	
5) Great Vessels					
1. Aorta arch		1) Normal		2) Coarctation	
2. Pulmonary Artery branches		1) Normal		2) Abnormal	
3. PDA		1) Yes		2) No	
If Yes size		1- Small		2- moderate	
4. Flow direction		a- Lt_Rt		b- Rt_Lt	
				c) Bidirectional	
5. Coronary Arteries		1) Normal		2) Abnormal	
6) Pericardial effusion		1) Yes		2) No	
7) M Mode/ 2D Measurements :					
1) LVIDd: It depend on the body surface area		1) Normal		2) Abnormal	
2) LVID s		1) Normal		2) Abnormal	
3) Ao Root diameter		1) Normal		2) Abnormal	
4) LA/AO		5) RVD		6) EF%	
8) Acyanotic Congenital Malformations					
1. ASD		2. VSD		3. PDA	
				4. Aortopulmonary Window	

5. AVSD	1. Complete	2. Partial	3. If 2	a. Balance	b. Imbalance
6. Subaortic stenosis/ membrane		7. Coarctation of Aorta			
8. Aorto-ventricular Tunnel		9. Interrupted Aortic Arch		10. TGA	
11. LVIT obstruction		12. Double chambered RV		13. Cor Triatrium	
14. Pulmonary Vein Stenosis (PS)		15. LVOT Obstruction			
9)) Associated other cardiac anomalies		1. Yes		2. No	
If Yes Mention					
10)Outcome					

Signature

.....

Appendix B

ECHOCARDIOGRAPHIC IMAGES

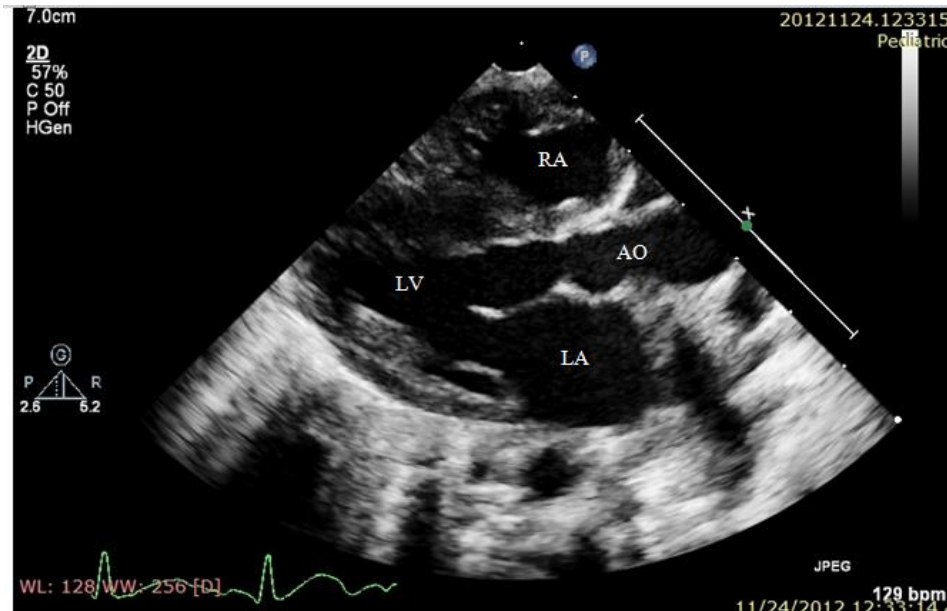


FIG 5.1

IMAGE (1)

15 months, Female patient; this parasternal long-axis view shows the Normal left atrium (LA), left ventricle (LV) and aorta (AO). Note the fibrous continuity between the leaflets of the mitral and aortic valves. The infundibulum of the right ventricle (RV) is seen antero-superiorly.

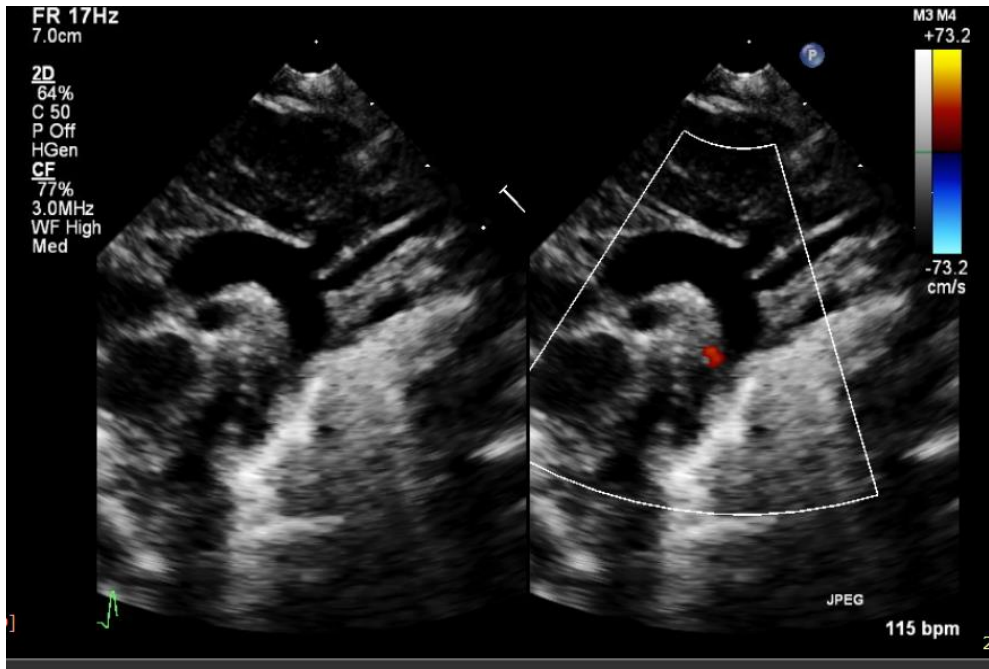


FIG 5.2

IMAGE (2)

3 days, Male patient; Suprasternal notch aortic arch view show normal Aortic Arch .

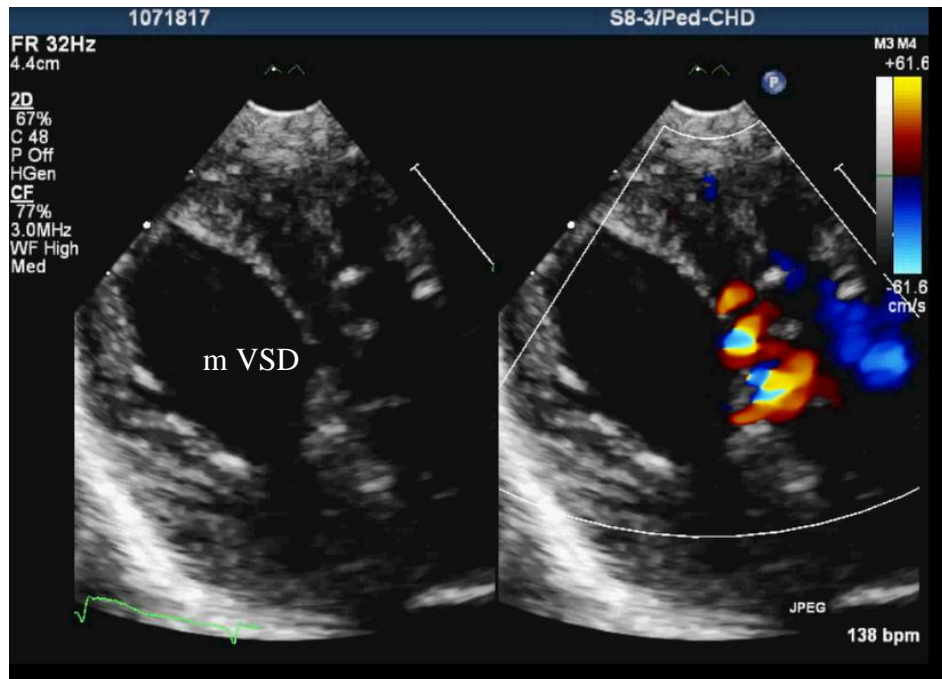


FIG 5.3

IMAGE (3)

Small Sized Ventricular Septal Defect (VSD) Muscular Type

1 day, Female patient; 2D echocardiogram, And Clour flow (CF) doppelr confirmation of LV – RA shunt in Muscular VSD the jet from the left ventricle to the right ventricle across VSD

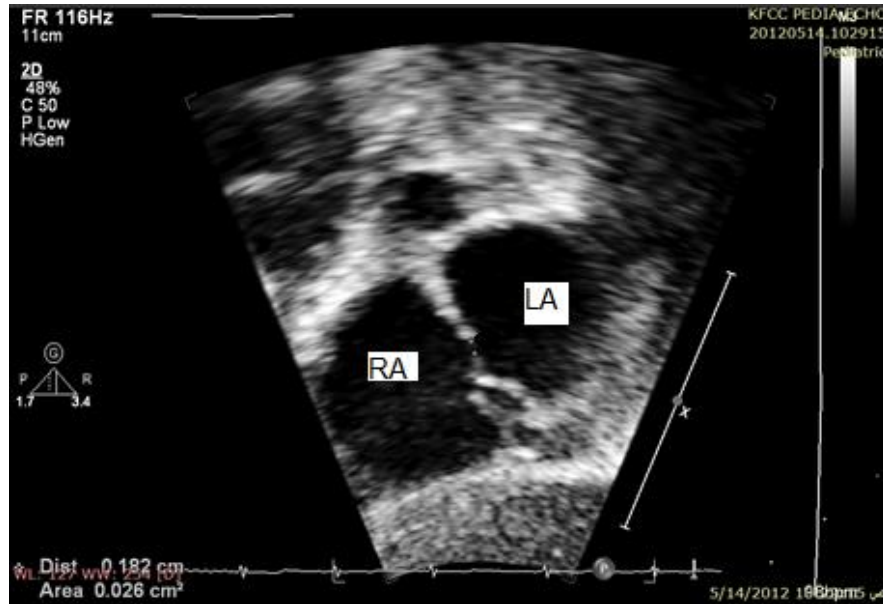


FIG 5.4

IMAGE (4)

2 years, Female patient; Small Secundum ASD (LA left atrium, RA right atrium)

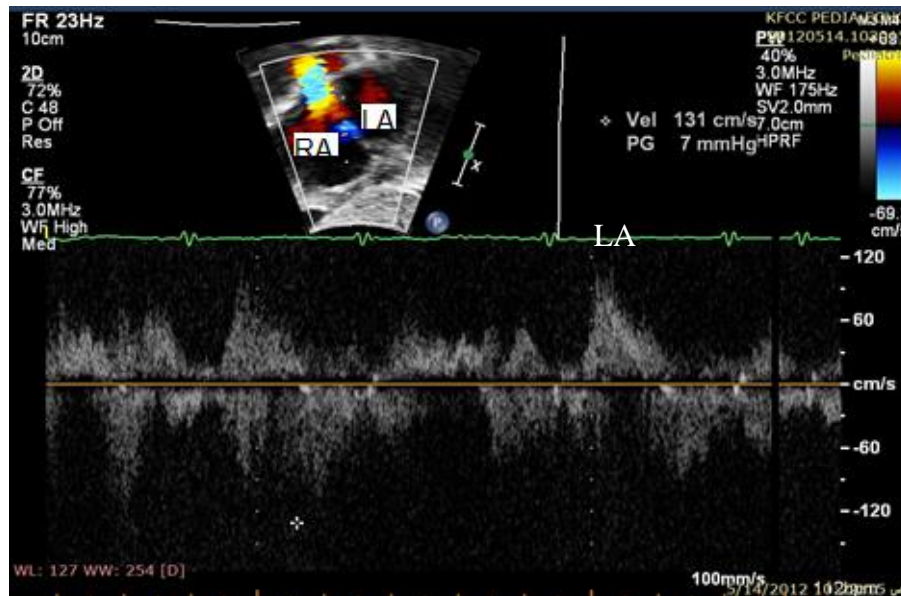


FIG 5.5

IMAGE (5)

2 years, Female patient; Color Doppler showing ASD secundum type

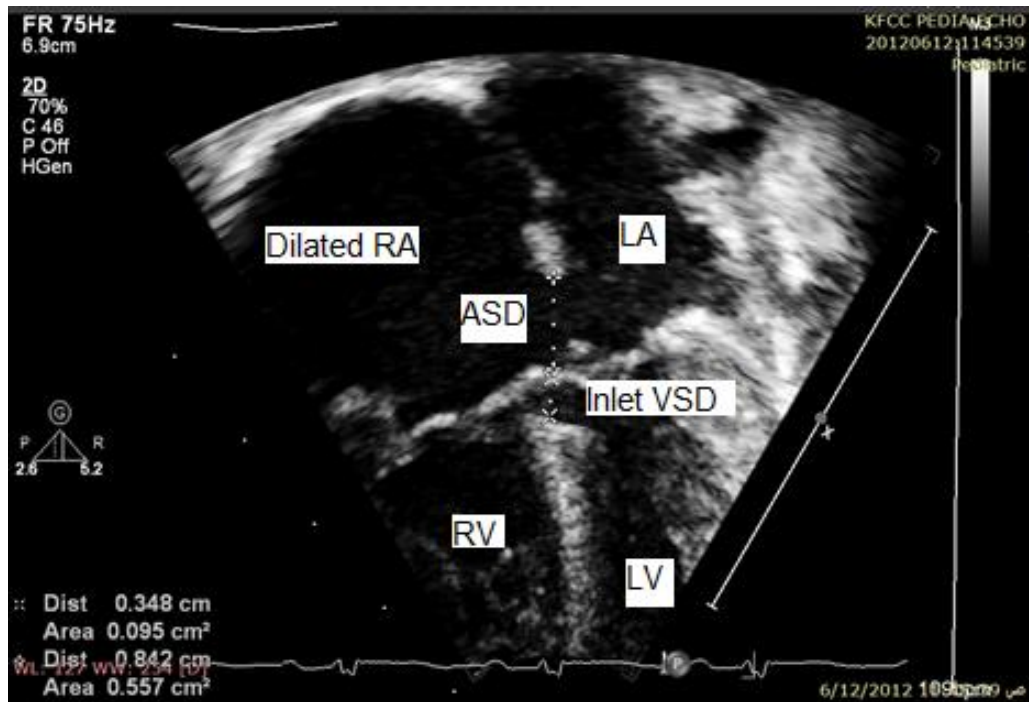


FIG 5.6

IMAGE (6)

6 days, Female patient; Apical four-chamber view demonstrating a complete AVSD with large primum atrial septal defect (ASD), & large inlet ventricular septal defect (VSD). This patient had dilated right atrium (RA), (LA left atrium, LV left ventricle).

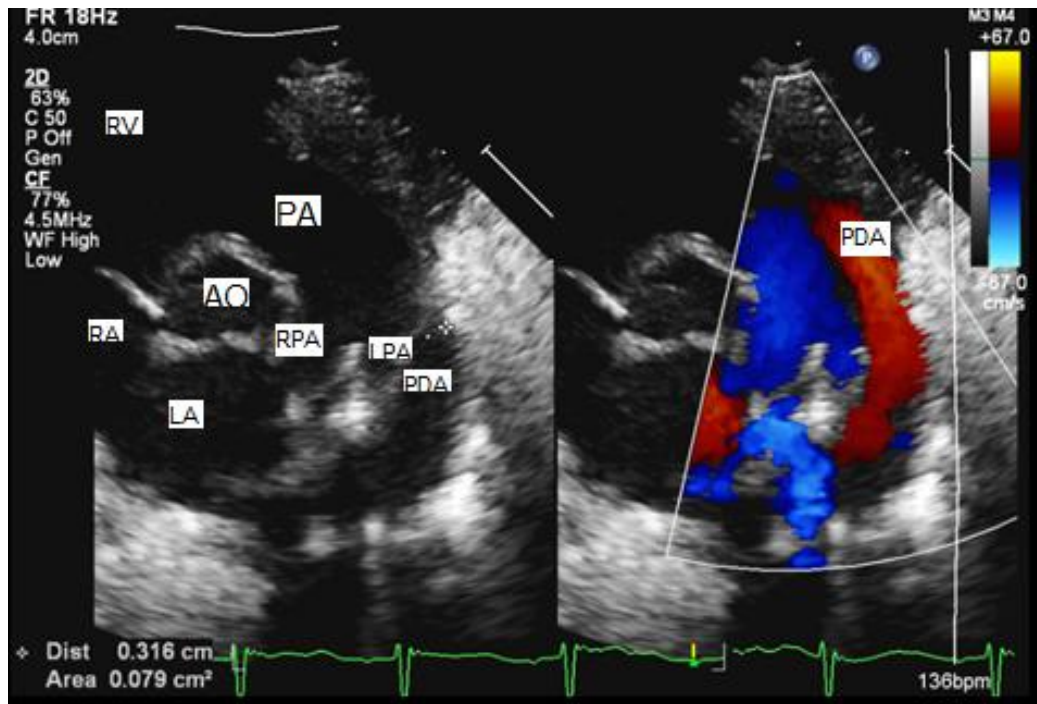


FIG 5.7

IMAGE (7)

13 months, Male patient; Showed Large PDA in 2D echocardiogram , And Clour flow (CF) doppelr confirmation (PA pulmonary artery, RV right ventricle, RA right atrium, Ao Aorta, RPA right pulmonary artery, LPA left pulmonary artery, PDA patent ductus arteriosus.

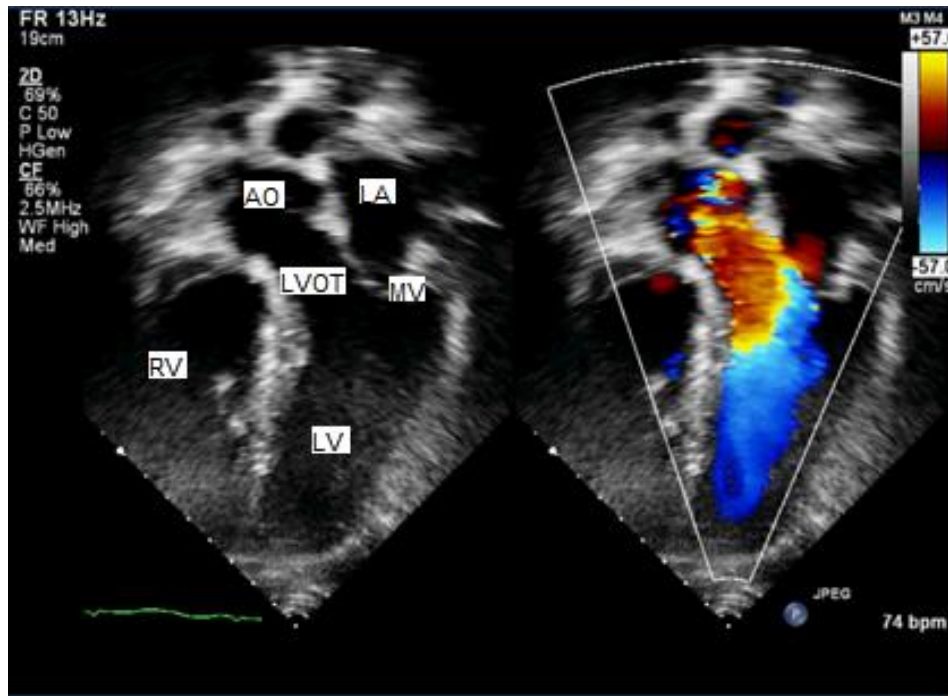


FIG 5.8

IMAGE (8)

Left ventricle out flow obstruction (LVOT)

2D echocardiogram , Confirmation by CF doppler

8months, Female patient; Apical five chamber view (5C) view with color flow mapping (CFM) showing the blue coloured flow from the left ventricle converging to the left ventricular outflow tract (LVOT). There is some turbulence in the LVOT, which could be due to narrowing of the LVOT

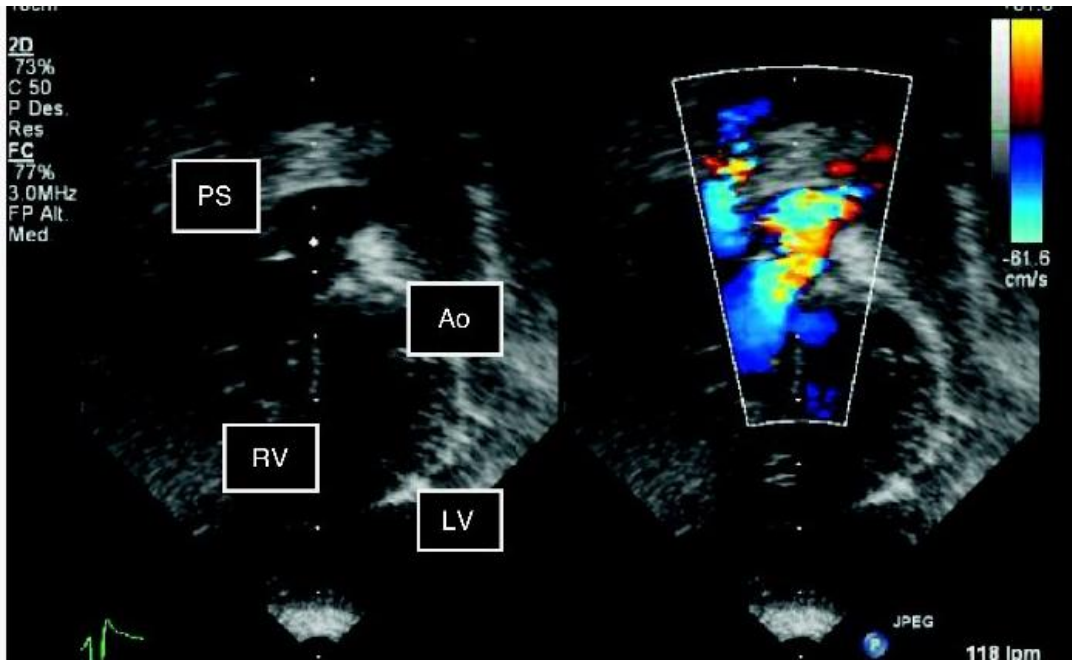


FIG 5.9

IMAGE (9)

1 year, Male patient; Two-dimensional echocardiogram in color flow Doppler: subcostal view of the outlet tract. Note the double outlet right ventricle and pulmonary stenosis. Ao: aorta; LV: left ventricle; PS: pulmonary stenosis; RV: right ventricle.

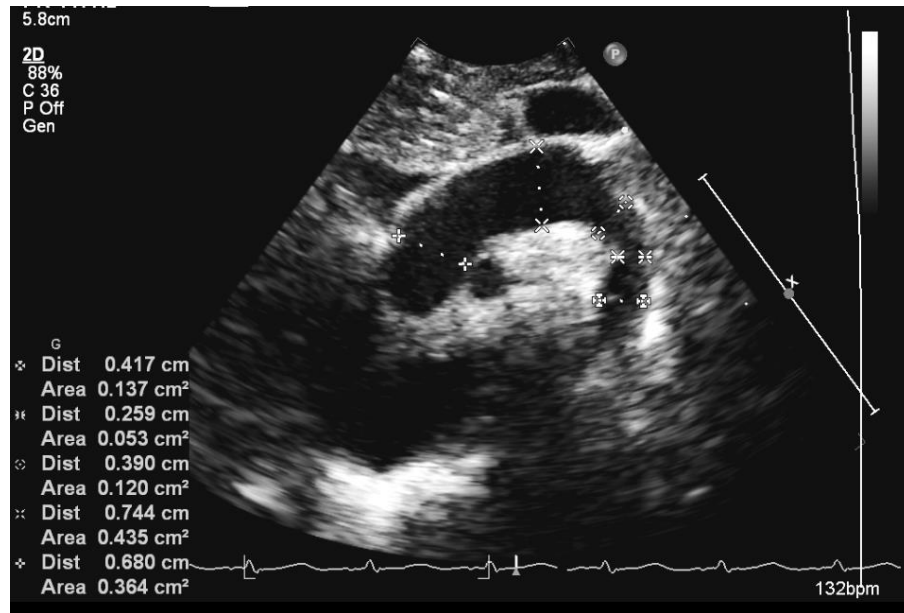


FIG 5.10

IMAGE (10)

23days, Male patient; COARCTATION OF AORTA (COA) in 2D echocardiogram

Descending aorta slightly dilated, representing poststenotic dilation.

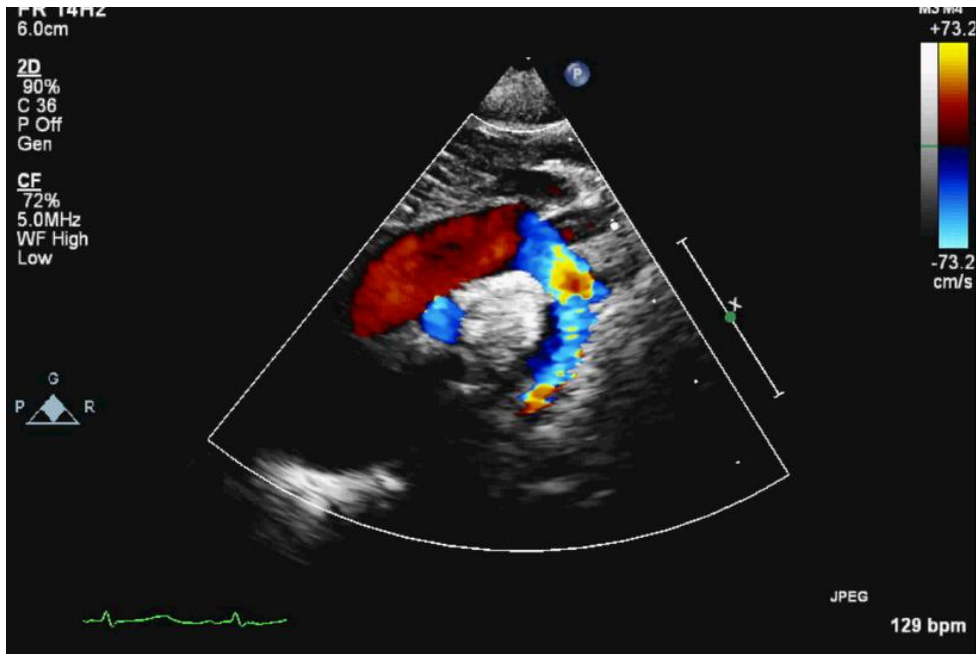


FIG 5.11

IMAGE (11)

COARCTATION OF AORTA (COA)

23days, Male patient; Color Flow (CF) Doppler mode confirmation; shows a disturbed (turbulent) signal at the stenosis.