Appendices

Examples of kidney stones seen by ultrasound

Image1 Longitudinal view US image of LT kidney in 11 years male student showing LT kidney multiple stones

Image2 Longitudinal view US image of RT kidney in 11 years male student showing LT kidney multiple stones

Image3& 4 longitudinal and axial view US image of LT kidney in 14 years male student showing LT kidney gravels and cyst

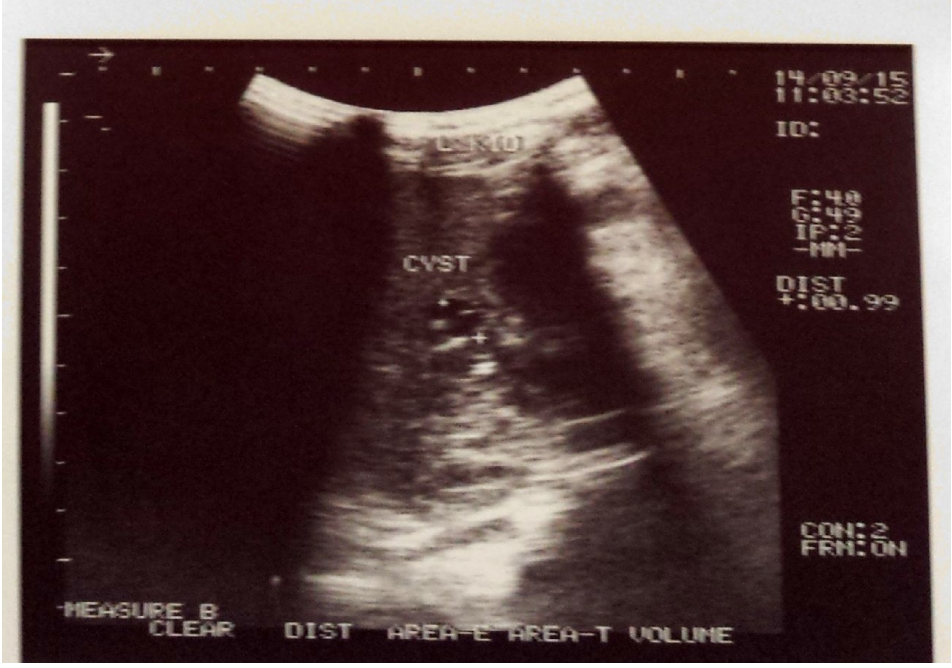

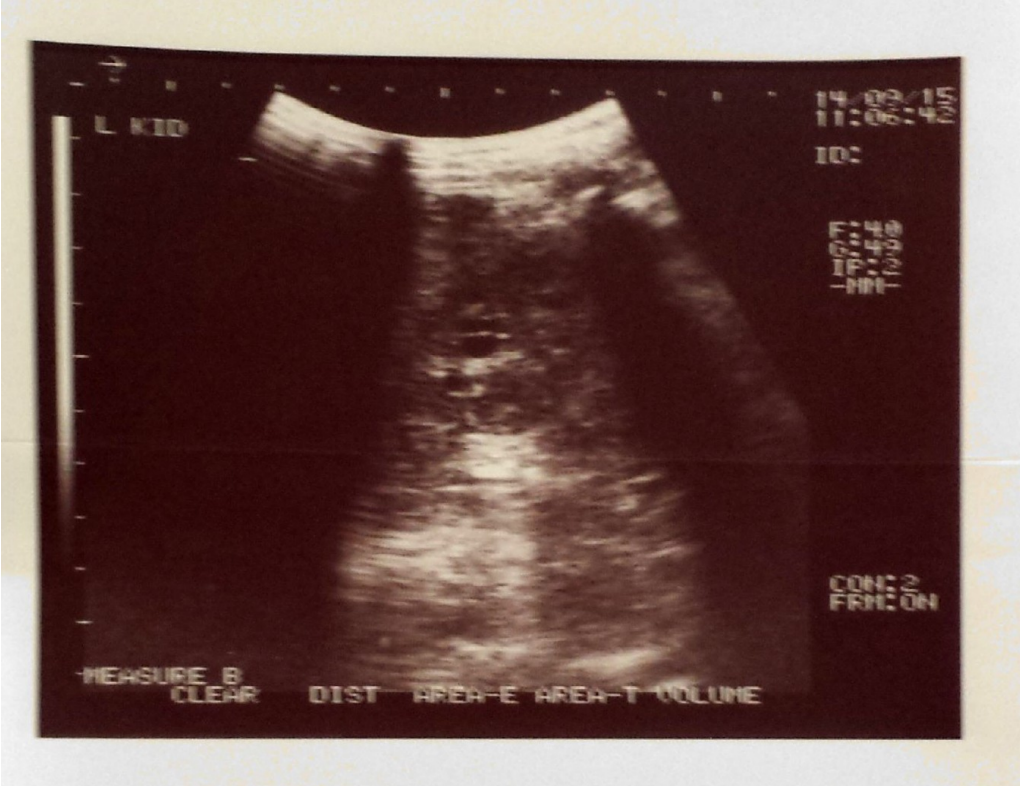

Image5 longitudinal view US image of LT & RT kidney in 12 years female student showing bilateral multiple stones and hydronephrosis

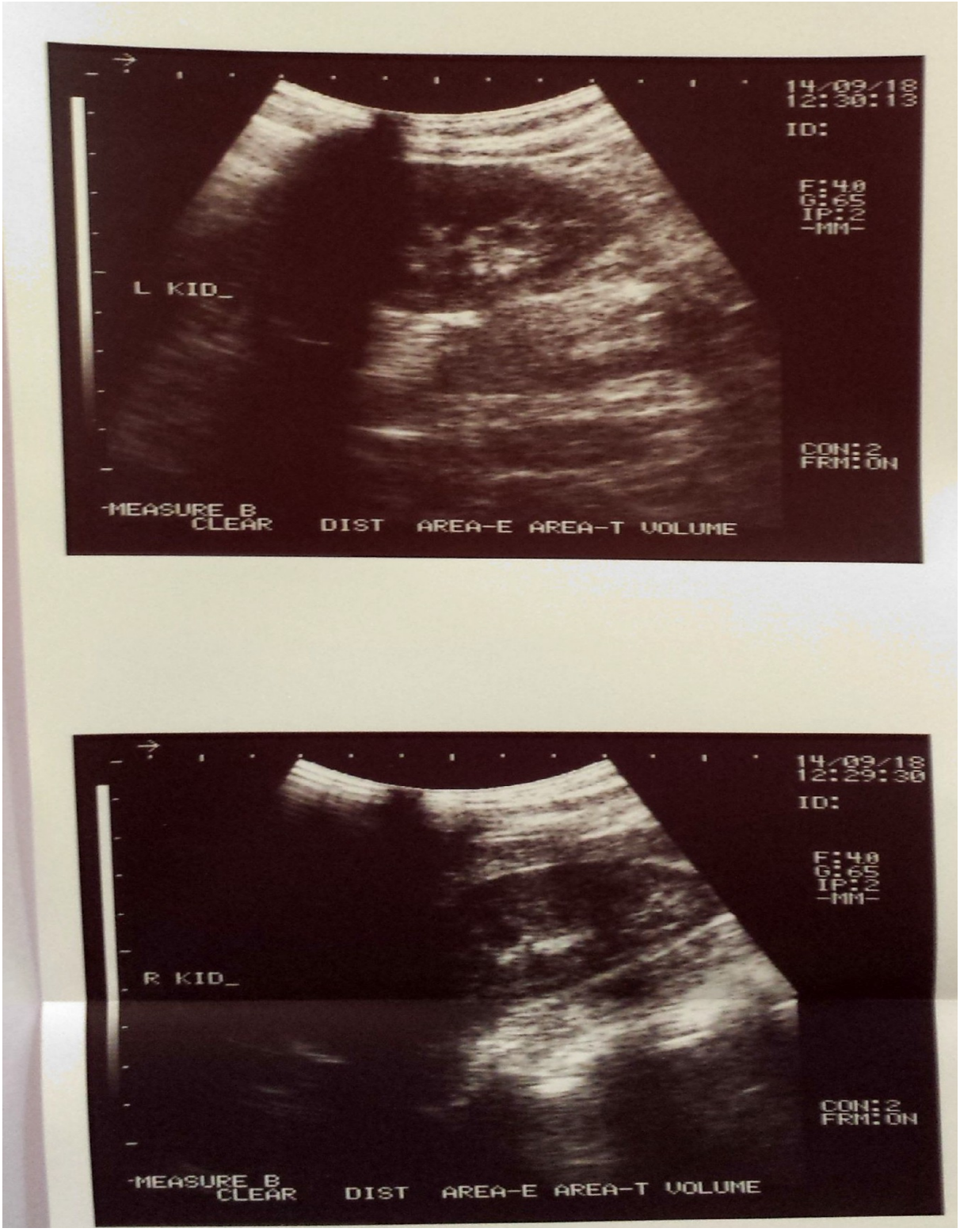

Image6 longitudinal view US image of RT kidney in 11 years female student showing multiple stones

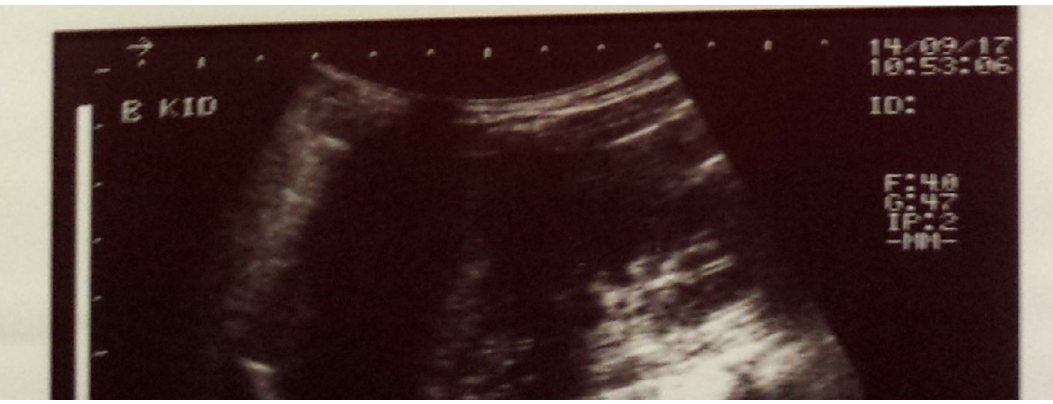

Image7 longitudinal view US image of RT kidney in 11 years male student showing multiple stones

Image8 longitudinal view US image of LT & RT kidney in 11 years female student showing bilateral multiple stones

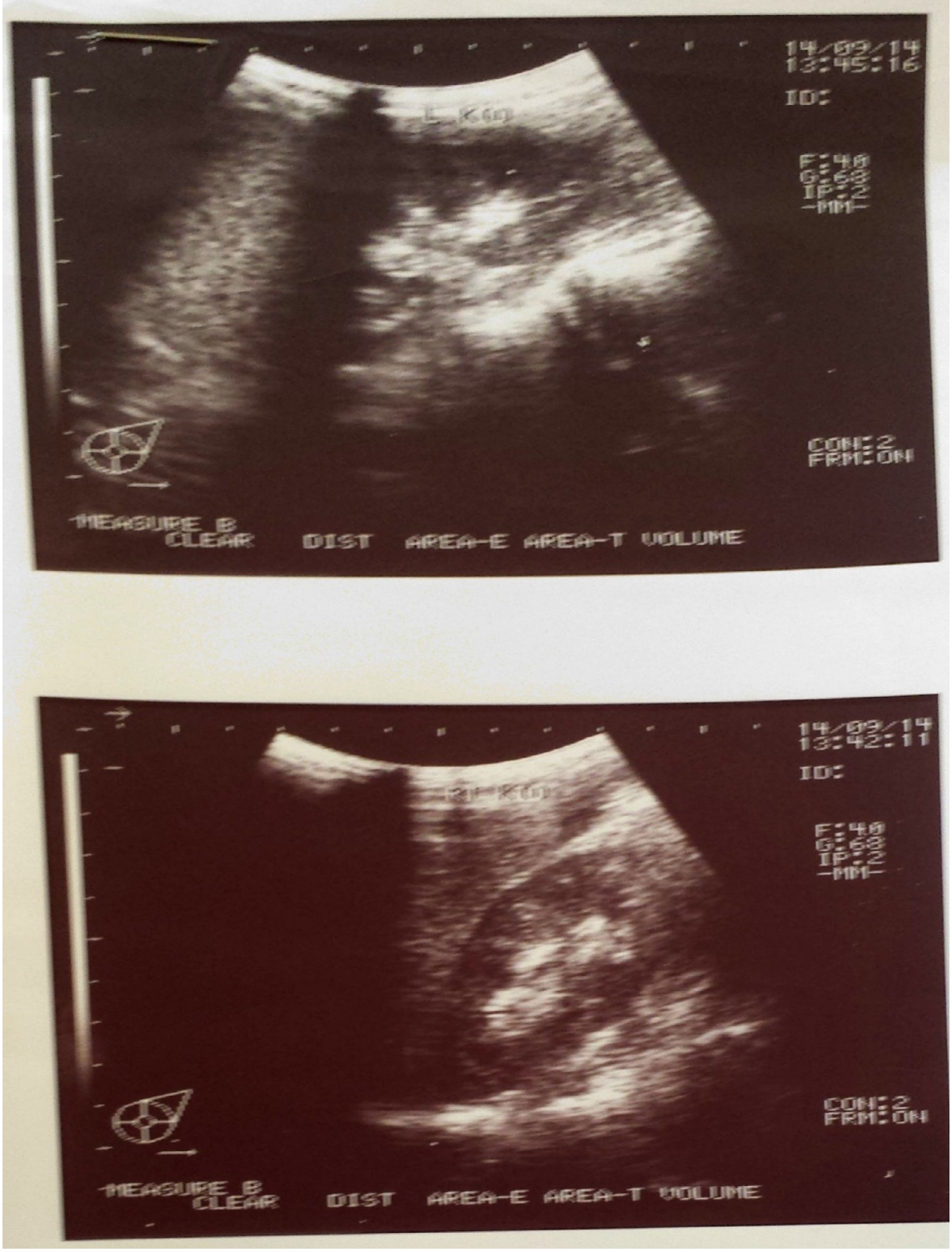

Image9 longitudinal view US image of RT kidney in 12 years female student showing 1cm stone

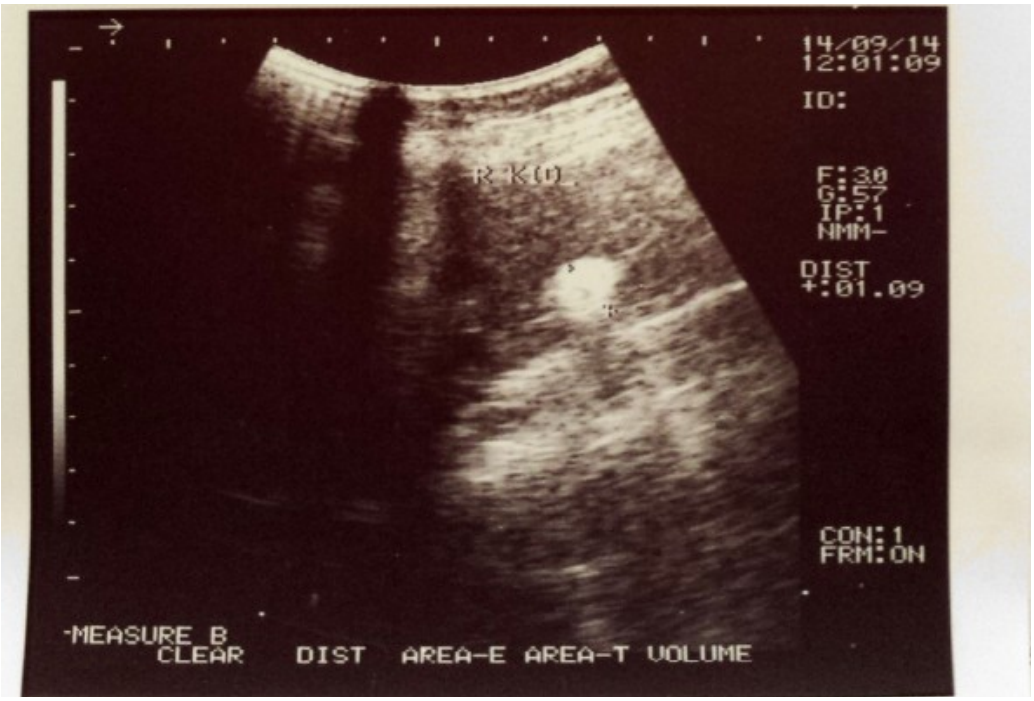

Image10 longitudinal view US image of RT kidney in 12 years female student showinghydroneprosis
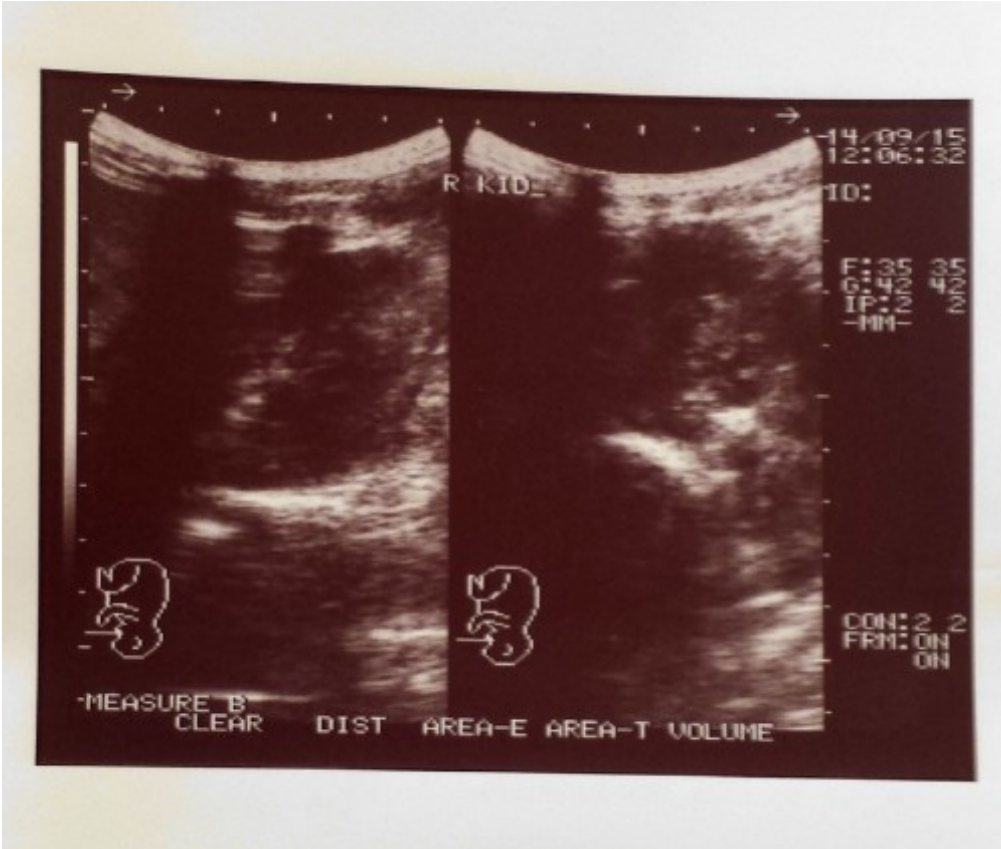
Image11 longitudinal and axial view US image of RT kidney in 12 years male student showing RT kidney stone