Sudan university of Science and

Technology College of Graduate Studies

Study of the First Trimester pregnancy Failure in United Arab Emirates Using Ultrasound

دراسة فشل الثلث الأول من الحمل في دولة الإمارات العربية المتحدة باستخدام الموجات فوق الصوتية

A Thesis Submitted for Partial Fulfilment for the Requirements of M.Sc Degree in Medical Diagnostic Ultrasound

By:

Zoleakha Abdel Wahab Khalid

Supervisor:

Dr. Muna A. Mohamed

2015

الآية

(ياأيُّها النَّاسُ إن كنتم في ريبٍ منَ البعثِ فإنَّا خَلقْناكم من تُرابٍ ثمَّ من نُطفةٍ ثمَّ من عَلَقةٍ ثمَّ من مُضغةٍ مُخَلَّقةٍ وغيرِ مُخلَّقةٍ لِنُبيِّن لكم ونُقِرُّ في الأرحام ما نشاءُ إلى أجلٍ مسمَّى ثمَّ نُخرِجُكُم طِفلاً ثمَّ لِتَبلغوا أشُدَّكم ومنكم من يُتَوفَّى ومنكم مَن يُرَدُّ إلى أَرْذلِ العُمُرِ لكيلا يَعْلَمَ من بعد عِلْمٍ شيئاً وترى الأَرضَ هَامدةً فإذا أنزلنا عليها الماء اهتزَّت وربَت وأنبتت من كلِّ زوجٍ بهيج)

الآية 5 من سورةالحج

DEDICATION

- *To my mother, for her great love and support.*
- *To the sole of my father.*
- *To my kind brother, and sisters for their encouragement.*

ACKNOWLEDGMENT

My great thanks at the beginning and end to Allah who gave me the gift of the mind and effort to do this thesis.

My special gratitude to my supervisor Dr.Mona Ahmed Mohamed who do her best helping and guiding me to do this thesis.

Profound thanks and gratitude to my colleagues in Dibba hospital in UAE for their endless support and my extended gratitude to everyone put a hand on this study.

ABSTRACT

This study has been conducted in Dibba Fujairah Hospital in United Arab Emirates in ultrasound department.

The aim of this research is to study the role of ultrasound imaging in diagnosing and investigating first- trimester failure of pregnancy using transabdominal ultrasound with 3.5 MHz frequency curve-linear probe, and transvaginal ultrasound with 5-7.5MHz frequency endovaginal probe. Ultrasound machines used general electric care,(GE)and(Sono Site M-Turbo) .

The data were collected from 50 pregnant cases presented with vaginal bleeding using patient personal data plus ultrasound finding.

The ultrasound finding revealed that the highest causes of early Pregnancy failure is miscarriage (76%), comparing with renal diseases (6%), uterine mass ,thyroid diseases, pelvic inflammatory(4%), and ectopic pregnancy (2%).

The study showed that the failure of first trimester is more common in age more than 35years old.

الخلاصة

اجريت هذه الدراسة فى مستشفى دبا الفجيرة بالامارات العربية المتحدة بقسم الموجات فوق الصوتية. الهدف الرئيسى من هذه الدراسة ، دراسة دور الموجات فوق الصوتية فى تشخيص وفحص فشل الثلث الاول من الحمل باستخدام جها ز سونار من خلال فحص البطن به مسبار مقوس تردده 3.5 ميقا هيرتز، والفحص من خلال المهبل بمسبار مهبلى تردده 5-7.5 ميقاهرتز،جهاز الموجات الصوتية المستخدم هو جهاز العناية العام الكهربائى.

تمت الدراسة على 50 حالة امراة تعانى من النزيف المهبلى باستخدام البيانات الشخصية للمرضى بالاضافة الى نتائج الموجات فوق الصوتية.

كانت نتائج الدراسة ان الاجهاض يمثل اعلى نسبة لاسباب النزيف المهبلى مقارنة بالالتهابات والاورام والحمل خارج الرحم،و حالات النزيف المقترنة بالاصابةبامراض الكلى او الغدة.

اظهرت الدراسة ان الاجهاض يكون اكثر عادة فى الاعمار ما فوق35 سنة.

LIST OF CONTENT:

Subject	Page
الاية	I
Dedication	II
Acknowledgement	III
Abstract	IV
الخلاصة	V
List of continent	VI
List of Figures	IX
List of Tables	XI
Chapter one	
Introduction	1
Problem of the study	2
Objective of the study	2
General objective	2
Specific objective	3
Signification of the study	3
Over view of the study	3

Chapter two	
Anatomy of female reproductive system	4
Physiology of female reproductive system	12
Pathology	19
Role of ultrasound in the first trimester	28
Ultrasound evaluations in Failure of pregnancy	30
Doppler Ultrasound in the early pregnancy loss	31
Imaging modalities using in the failure in early pregnancy	31
Previous study	33
Chapter three	
Material and method	35
Study Area& Duration	35
Study Subjects	35
Study Design	35
Sample Size	35
Inclusion Criteria	35
Exclusion Criteria	36
Data Management and Analysis Plan	36
Ethical Considerations	36

Scanning technique	36
Tools & equipment	42
Chapter four	
Result	45
Chapter five	
Discussion	51
Conclusion	53
Recommendation	54
References	55
Appendices	62

LIST OF FIGURES

Number	Figure	Page
Figure 2.1	female reproductive system	5
Figure 2.2	Anatomy of the cervix	6
Figure 2.3	Anatomy of the uterus	8
Figure 2.4	A bicornuate uterus	10
Figure 2-5	Anatomy of fallopian tube	11
Figure 2.6	Anatomy of the ovary	12
Figure 2.7	Menstrual cycle image	12
Figure 2.8	Ovarian cycle	13
Figure 2.9	Follicular phase	14
Figure 2.10	pregnancy conception	18
Figure 2.11	Transvaginal ultrasound	19
Figure 2.12	Miscarriage embryonal demise	20
Figure 2.13	Threatened Miscarriage	21
Figure 2.14	A missed abortion	22
Figure 2.15	Complete Miscarriage	23
Figure 2.16	Blighted ovum	24

Figure 2.17	Location of the ectopic pregnancy	24
Figure 2.18	Tubual ectopic pregnancy	25
Figure 2.19	Molar pregnancy	25
Figure 2.20	Embryoscopy	32
Figure 2.21	Blastocyst transfer by the EmbryoScopy	33
Figure 3.1	Transabdomen ultrasound technique	39
Figure 3-2	Transvaginal Technique	41
Figure 3.3	GE Ultrasound machine	43
Figure 3-4	Sono Site M-Turbo Ultrasound	44
Figure 4-1	Age percentage distribution	45
Figure 4-2	Distribution of clinical manifestations	46
Figure 4-3	Causations of failure pregnancy	47
Figure 4-4	Distribution of abortions frequency	48
Figure 4-5	Distribution of hCG	49

LIST OF TABLES

Number	Table	Page number
Table 2.1	Position of uterus	9
Table 4.1	Distribution of age	45
Table 4.2	distribution of clinical manifestations:	46
Table 4.3	Distribution of Causations	47
Table 4.4	Distribution of abortions	48
Table 4.5	Distribution of hCG blood	49
Table 4.6	Ultrasound finding	50

Chapter one

CHAPTER ONE

1.1 Introduction:

Ultrasound is one of the most important and useful diagnostic tool in the field of modern medicine. Being noninvasive, safe and without hazards of radiation, it has gained wide acceptability, as an integral part of basic investigative procedures. The convenience, high portability, rapidity, and accuracy are few of the advantages of ultrasound over the other procedures. In the last two decades, ultrasound has become an essential diagnostic imaging modality in the field of obstetrics and is being extensively used for evaluation of pregnancy. Obstetrical ultrasound enables the clinician to evaluate the development, growth, and well being of the fetus. The ability to study the fetus in the intrauterine environment has been notably enhanced by dramatic improvement in imaging.(Arck and Rose 2008).

Although static scan imaging compliment ultrasound studies, obstetrical examination should always be accompanied by real time, the standard transabodominal ultrasound lower frequencies with poorer axial resolution (ability to distinguish two separate points in the direct line of the ultrasound beam) are being used to image structures deeper in the body such as pelvic organs. The recent development of higher frequency (5 and 7.5 MHz) transvaginal transducer probe has resulted in the increased resolution of the female pelvic organs as the endovaginal probe is placed close to the pelvic organs than the transabdominal probe.(Rowling and Coleman1997).

Transabdominal scanning is used predominantly in second and third trimesters of gestation. Its use in first trimester is relatively limited and mostly diagnostic in nature. The introduction of the higher frequency

transvaginal probe, with its higher resolution of images, opens new possibilities to study early gestation .Diagnostic ultrasound is a powerful and frequently used tool in the assessment of failure of first-trimester pregnancy. A review of first-trimester ultrasound finding is presented. The normal first trimester, including practical embryology and pregnancy dating, is first discussed. Abnormal first- trimester finding, including sonographic evaluation of the failing first-trimester pregnancy.(Winikoff and Dzuba, 2008).

1.2 Problem of the study:

This study was aimed to reduce the risk of maternal and embryo mortality and morbidity in early diagnosis of pregnancy failure of first- trimester .The advent of high- resolution ultrasound has revolutionized our understanding of pathophysiology and the management of early pregnancy failure.

Ultrasound imaging has rapidly replaced all other techniques used to diagnosis loss of early pregnancy, and ultrasound features of the early gestational sac have corroborated anatomical studies showing that the first structures to appear are the celomic cavity and the secondary yolk sac.

1.3 Objective of the study:

The study aims to promote the following objective:

1.3.1 General objective:

To determine the role of Ultrasound imaging in diagnosing and investigating first- trimester failure of pregnancy.

1.3.2 Specific objective:

- To identify sonographic features of early pregnancy failure.
- To identify sonographic features of ectopic pregnancy.
- To determine the causes of early pregnancy failure.
- To evaluate the accuracy of first trimester ultrasound in diagnosis early embryonic demise.

1.4 Significant of the study:

Ultrasound plays a very important role in the evaluation of patients with pregnancy less than 20 weeks, with threatened abortion or completed abortion and ectopic pregnancy.

Knowledge of the ultrasound appearances of normal early pregnancy development and a good understanding of its pitfalls are essential for the diagnosis and management of early pregnancy failure.

1.5 Over view of the study:

This study contains five chapters:

Chapter one introduction

Chapter two theoretical background and previous studies

Chapter three materials and method.

Chapter four results.

Chapter five discussions,recommendations and conclusion.

Chapter two

CHAPTER TWO

2. Theoretical background and Literature Review

2.1Anatomy of the female reproductive system:

The female reproductive anatomy includes parts inside and outside the body.The organs can be subdivided into the internal and external genitalia (sees the Figure 2-1 below). The external female genitals are collectively referred to as The Vulva, from front to back, consist of the mons pubis which extend into the two labia majora, the two labia minora that fuse at the level of the clitoris, the vestibule, the external urethral meatus, the hymen or its remnants, the ostia of the accessory glands and the perineum.The internal genitalia are those organs that are within the true pelvis. The external genitalia lie outside the true pelvis.The female internal reproductive organs are the vagina, uterus, uterine tubes (Fallopian tubes) and ovaries.(Baron and Denmark 2010).

2.1.1.Vagina:

The vagina is a fibro-muscular tubular tract leading from the uterus to the exterior of the body in the female .The vagina extends from the vaginal opening to the cervix, the opening to the uterus. The vagina serves as the receptacle for the penis during sexual intercourse, and as the birth canal through which the baby passes during labor. The average vaginal canal is three inches long, possibly four in women who have given birth.The vagina lies at a 90° angle in relation to the uterus and is held in place by endopelvic fascia and ligaments. It is a potential space that is easily distended. The vasculature of the vagina is supplied primarily by the vaginal artery, a branch of the anterior division of the internal iliac artery. Several of these arteries may be found on either side of the pelvis to

richly supply the vagina.The nerve supply to the vagina is primarily from the autonomic nervous system. Sensory fibers arise from the pudendal nerve, and pain fibers are from sacral nerve roots.Lymphatic drainage of the vagina is generally to the external iliac nodes (upper third of the vagina), the common and internal iliac nodes (middle third), and the superficial inguinal and perirectal nodes (lower third). Vaginal glands:

The Bartholin glands are two small organs under the skin in a woman's genital area. They are on either side of the folds of skin (labia) that surround the vagina and urethra. Most of the time, you can't feel or see these glands. The Bartholin glands make a small amount of fluid that moistens the outer genital area, or vulva. This fluid comes out of two tiny tubes next to the opening of the vagina. These tubes are called Bartholin ducts.(Clarice 1995).

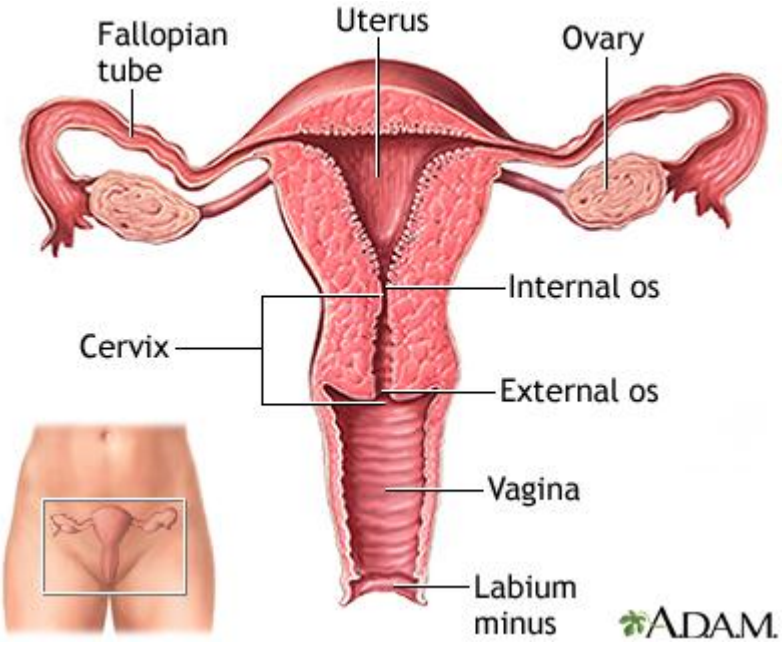

Figure 2.1 female reproductive system

(www. Anatomy of female reproductive system images.com)

2.1.2 Cervix:

The cervix is the lower, narrow portion of the uterus where it joins with the top end of the vagina. It is cylindrical or conical in shape and protrudes through the upper anterior vaginal wall. Approximately half its length is visible to the naked eye, the remainder lies above the vagina beyond view. The vagina has a thick layer outside and it is the opening where the fetus emerges during delivery. The cervix is also named the neck of the uterus.(Weinberg, and Donna 1995).

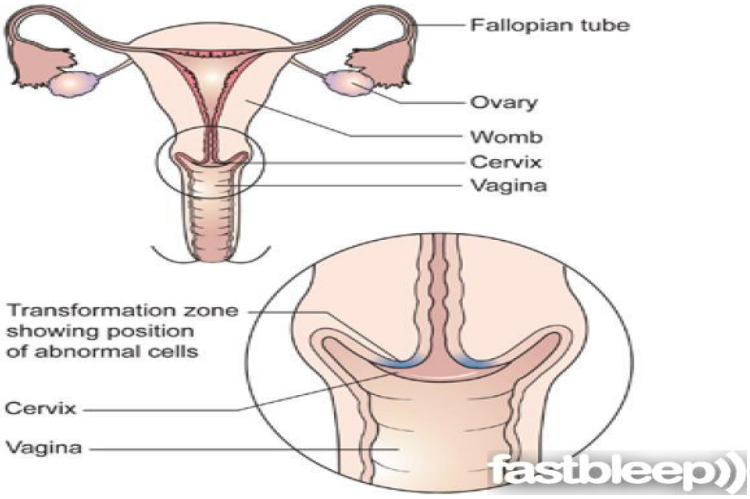

Figure 2.2:Anatomy of the cervix

(www. Anatomy of the cervix images.com)

2.1.3Uterus:

The uterus or womb is the major female reproductive organ of humans. The uterus provides mechanical protection, nutritional support, and waste removal for the developing embryo (weeks 1 to 8) and fetus (from week 9 until the delivery). In addition, contractions in the muscular wall of the

uterus are important in pushing out the fetus at the time of birth.(Curtis and Louis 1998).

The uterus contains three suspensory ligaments that help stabilize the position of the uterus and limits its range of movement. The uterosacral ligaments keep the body from moving inferiorly and anteriorly. The round ligaments restrict posterior movement of the uterus. The cardinal ligaments also prevent the inferior movement of the uterus.The uterus is a pear-shaped muscular organ. Its major function is to accept a fertilized ovum which becomes implanted into the endometrium, and derives nourishment from blood vessels which develop exclusively for this purpose. The fertilized ovum becomes an embryo, develops into a fetus and gestates until childbirth. If the egg does not embed in the wall of the uterus, a female begins menstruation.The uterus is located inside the pelvis immediately dorsal to the urinary bladder and ventral to the rectum. The human uterus is about 3 in. (7.6 cm) long, 4.5 cm broad (side to side) and 3.0 cm thick (anteroposterior). A nonpregnant adult uterus weighs about 60 grams. The uterus can be divided anatomically into four segments: The fundus, corpus, cervix and the internal os.The three layers, from innermost to outermost, are as follows: Endometrium: The lining of the uterine cavity is called the "endometrium". It consists of the functional endometrium and the basal endometrium from which the former arises. (Wilcox and Allen 1995).

The uterus mostly consists of smooth muscle known as "myometrium." The innermost layer of myometrium is known as the junctional zone, which becomes thickened in adenomyosis. The third layer is Perimetrium The loose connective tissue around the uterus.

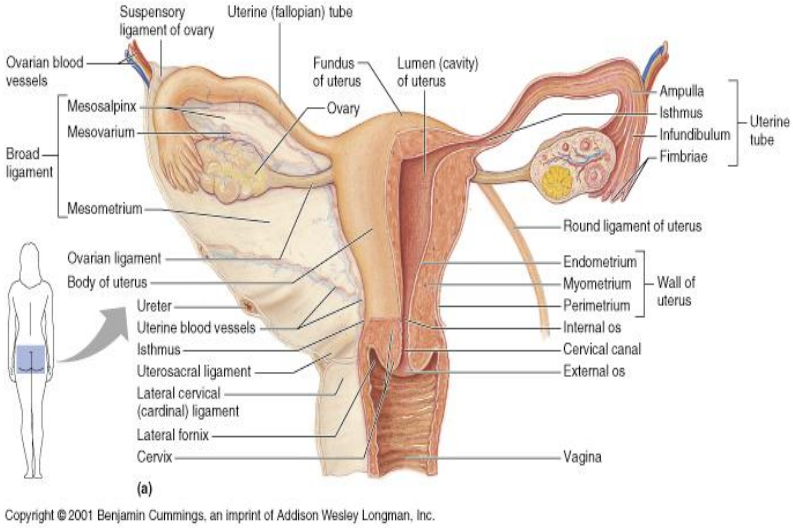

Figure 2.3:Anatomy of the uterus

(www. Anatomy of the uterus images.com)

The uterus is primarily supported by the pelvic diaphragm ,perineal body and the urogenital diaphragm. Secondarily, it is supported by ligaments and the peritoneum (broad ligament of uterus) .(Byer 1998).

Normally the uterus lies in anteversion&anteflexion. In most women, the long axis of the uterus is bent forward on the long axis of the vagina. This position is referred to as anteversion of the uterus. Furthermore, the long axis of the body of the uterus is bent forward at the level of the internal os with the long axis of the cervix. This position is termed anteflexion of the uterus. Uterus assumes anteverted position in 50% women, retroverted position in 25% women and rest have midposed uterus.(Mader and Sylvia 1992).

The position of uterus is in the middle of the pelvic cavity in frontal plane. The fundus does not surpass the lineaterminalis, while the vaginal part of the cervix does not extend below interspinal line. The uterus is mobile and moves under the pressure of the full bladder or full rectum an-

teriorly, whereas if both are full it moves upwards. Increased intraabdominal pressure pushes it downwards. The mobility is conferred to it by musculo-fibrous apparatus that consists of suspensory and sustentacular part. Under normal circumstances the suspensory part keeps the uterus in anteflexion and anteversion (in 90% of women) and keeps it "floating" in the pelvis. The meaning of these terms are described below in Table 2.1.

Table 2.1: Position of uterus

Distinction	More common	Less common
Position tipped	(Anteverted):Tipped forward	(Retroverted):Tipped backwards
Position of fundus	(Anteflexed):Fundus is pointing forward relative to the cervix	(Retroflexed):Fundus is pointing backwards

Shape of uterus including four main forms which it is found are:Duplex which There are two wholly separate uteri, with one fallopian tube each.Bipartite which therethe two uteri are separate for most of their length, but share a single cervix. Found in ruminants. Bicornuate Which the upper parts of the uterus remain separate, but the lower parts are fused into a single structure. The last form is simplex Which the entire uterus is fused into a single organ . A uterine malformation where the two parts of the uterus fail to fuse completely during fetal development.The uterus is supplied by arterial blood both from the uterine artery and the ovarian artery. Another anastomotic branch also supply the uterus from anastomosis of these two arteries.The Afferent nerves supplying uterus are T11 and T12. Sympathetic supply is from hypogastric plexus and ovarian plexus. Parasympathetic supply is from second, third and fourth sacral nerves.(Kenneth 2001).

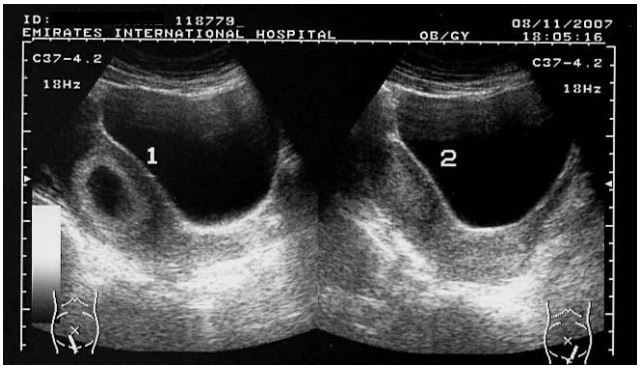

Figure 2.4 : A bicornuate uterus with a gestation sac in the right cornu , The empty left cornu

www.ultrasound images.com

2.1.4The Fallopian Tubes:

The Fallopian tubes or oviducts are two tubes leading from the ovaries of female into the uterus. On maturity of an ovum, the follicle and the ovary's wall rupture, allowing the ovum to escape and enter the Fallopian tube. There it travels toward the uterus, pushed along by movements of cilia on the inner lining of the tubes. This trip takes hours or days. If the ovum is fertilized while in the Fallopian tube, then it normally implants in the endometrium when it reaches the uterus, which signals the beginning of pregnancy.

In a woman's body the tube allows passage of the egg from the ovary to the uterus. Its different segments are (lateral to medial): the infundibulum with its associated fimbriae near the ovary, the ampullary region that represents the major portion of the lateral tube, the isthmus which is the narrower part of the tube that links to the uterus, and the interstitial (also known as intramural) part that transverses the uterine musculature. The tubal ostium is the point where the tubal canal meets the peritoneal cavity, while the uterine opening of the Fallopian tube is the entrance into the uterine cavity, the utero-tubal junction.

Fallopian tube, is approximately 10-12 cm long and 1- 4 mm in diameter. It bridges the gap between the ovary laterally, and the uterus medially. Though it, the ovum passes into the uterine cavity. If conception occurs, it does within the tube.(Shainberg and Grace,1998).

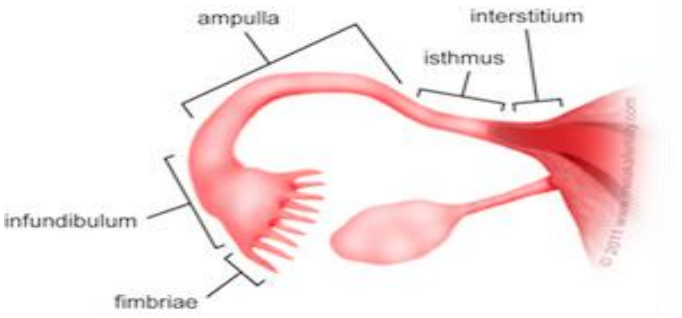

Figure 2-5:Anatomy of fallopian tube
(www.anatomy of the fallopian tube)

2.1.5 Ovaries:

The ovaries are small, paired organs that are located near the lateral walls of the pelvic cavity. These organs are responsible for the production of the ova and the secretion of hormones. Ovaries are the place inside the female body where ova or eggs are produced. The process by which the ovum is released is called ovulation. The speed of ovulation is periodic and impacts directly to the length of a menstrual cycle.

After ovulation, the ovum is captured by the oviduct, after traveling down the oviduct to the uterus, occasionally being fertilized on its way by an incoming sperm, leading to pregnancy and the eventual birth of a new human being.The Fallopian tubes are often called the oviducts and they have small hairs to help the egg cell travel. In the absence of fertilization, the ovum will eventually traverse the entire reproductive tract from the fallopian tube until exiting the vagina through menstruation.(Simon and Schuster, 1998).

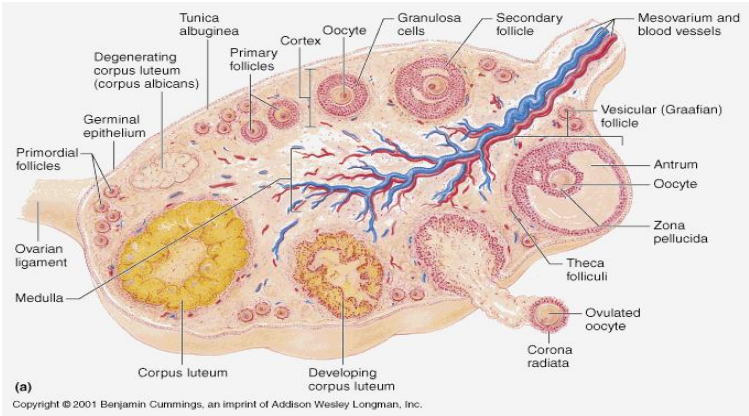

Figure 2.6:Anatomy of the ovary

(www.images of the anatomy of the ovary)

2.2Physiology of Female reproductive system :

2.2.1Menstrual Cycle:

The menstrual cycle can be described by the ovarian or uterine cycle. The ovarian cycle describes changes that occur in the follicles of the ovary whereas the uterine cycle describes changes in the endometrial lining of the uterus. Both cycles can be divided into three phases. The ovarian cycle consists of the follicular phase, ovulation, and the luteal phase whereas the uterine cycle consists of menstruation, proliferative phase, and secretory phase.(Konig and Liebich 1999)

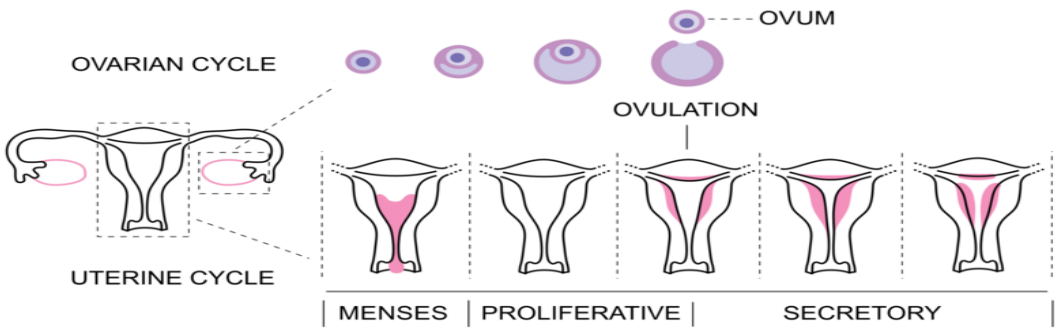

Figure 2.7: Menstrual cycle image

www.menstrual cycle images.com

The ovarian cycle is split into two phases: The follicular phase is the first part of the ovarian cycle. During this phase, the ovarian follicles mature and get ready to release an egg. The latter part of this phase overlaps with the proliferative phase of the uterine cycle. (Young 1992)

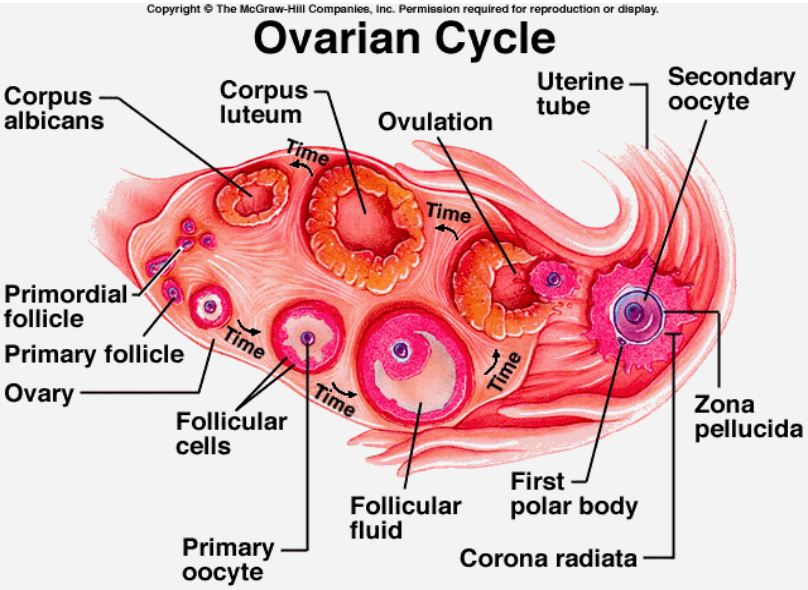

Figure 2.8:Ovarian cycle

www.Ovarian cycle images.com

Through the influence of a rise in follicle stimulating hormone (FSH) during the first days of the cycle, a few ovarian follicles are stimulated. These follicles, which were present at birthand have been developing for the better part of a year in a process known as folliculognesis, compete with each other for dominance. Under the influence of several hormones, all but one of these follicles will stop growing, while one dominant follicle in the ovary will continue to maturity. The follicle that reaches maturity is called a tertiary, or Graafian, follicle, and it contains the ovum.(Cappello 1990)

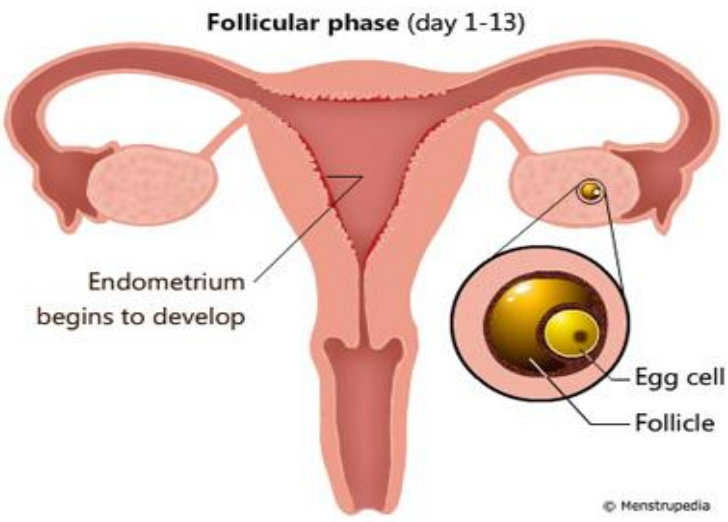

Figure 2.9:Follicular phase

www.Follicular phase images.com

Ovulation is the second phase of the ovarian cycle in which a mature egg is released from the ovarian follicles into the oviduct. During the follicular phase, estradiol suppresses production of luteinizing hormone (LH) from the anterior pituitary gland. When the egg has nearly matured, levels of estradiol reach a threshold above which this effect is reversed and estrogen stimulates the production of a large amount of LH. This process, known as the LH surge, starts around day 12 of the average cycle and may last 48 hours.Which of the two ovaries—left or right—ovulates appears essentially random; no known left and right co-ordination exists. Occasionally, both ovaries will release an egg; if both eggs are fertilized, the result is fraternal twins. After being released from the ovary, the egg is swept into the fallopian tube by the fimbria, which is a fringe of tissue at the end of each fallopian tube. After about a day, an unfertilized egg will disintegrate or dissolve in the fallopian tube. (Victoria 2002)

The luteal phase is the final phase of the ovarian cycle and it corresponds to the secretory phase of the uterine cycle. During the luteal phase, the

pituitary hormones FSH and LH cause the remaining parts of the dominant follicle to transform into the corpus luteum, which produces progesterone. The increased progesterone in the adrenals starts to induce the production of estrogen. The hormones produced by the corpus luteum also suppress production of the FSH and LH that the corpus luteum needs to maintain itself. Consequently, the level of FSH and LH fall quickly over time, and the corpus luteum subsequently atrophies. Falling levels of progesterone trigger menstruation and the beginning of the next cycle. From the time of ovulation until progesterone withdrawal has caused menstruation to begin, the process typically takes about two weeks, with 14 days considered normal. For an individual woman, the follicular phase often varies in length from cycle to cycle; by contrast, the length of her luteal phase will be fairly consistent from cycle to cycle. The loss of the corpus luteum is prevented by fertilization of the egg. The uterine cycle (menstrual cycle) is the monthly series of changes that the female's uterus, or uterine tissue, undergoes in preparation for the implantation of a fertilized egg. And, like all other cycles in biology, there're different phases - three in this case.Menstruation (also called menstrual bleeding, menses, catamenia or a period) is the first phase of the uterine cycle. The flow of menses normally serves as a sign that a woman has not become pregnant. (However, this cannot be taken as certainty, as a number of factors can cause bleeding during pregnancy, some factors are specific to early pregnancy, and some can cause heavy flow.)Levels of estradiol (the main estrogen), progesterone, luteinizing hormone, and follicle-stimulating hormone during the menstrual cycle, taking inter-cycle and inter-woman variability into account.Eumenorrhea denotes normal, regular menstruation that lasts for a few days (usually 3 to 5 days, but anywhere from 2 to 7 days is considered normal). The average blood loss

during menstruation is 35 milliliters with 10–80 ml considered normal. Women who experience Menorrhagia are more susceptible to iron deficiency than the average person. An enzyme called plasmin inhibits clotting in the menstrual fluid.(Sack and Wensing1990)

Painful cramping in the abdomen, back, or upper thighs is common during the first few days of menstruation. Severe uterine pain during menstruation is known as dysmenorrhea, and it is most common among adolescents and younger women (affecting about 67.2% of adolescent females). When menstruation begins, symptoms of premenstrual syndrome (PMS) such as breast tenderness and irritability generally decrease. Many sanitary products are marketed to women for use during their menstruation. (Dyce 1995)

The proliferative phase is the second phase of the uterine cycle when estrogen causes the lining of the uterus to grow, or proliferate, during this time. As they mature, the ovarian follicles secrete increasing amounts of estradiol, and estrogen. The estrogens initiate the formation of a new layer of endometrium in the uterus, histologically identified as the proliferative endometrium. The estrogen also stimulates crypts in the cervix to produce fertile cervical mucus, which may be noticed by women practicing fertility awareness .(David 1994)

The secretory phase is the final phase of the uterine cycle and it corresponds to the luteal phase of the ovarian cycle. During the secretory phase, the corpus luteum produces progesterone, which plays a vital role in making the endometrium receptive to implantation of the blastocyst and supportive of the early pregnancy, by increasing blood flow and uterine secretions and reducing the contractility of the smooth muscle in the

uterus; it also has the side effect of raising the woman's basal body temperature. (Bairbre 2000)

The average menstrual cycle lasts 28 days. The variability of menstrual cycle lengths is highest for women under 25 years of age and is lowest, that is, most regular, for ages 35 to 39. Subsequently, the variability increases slightly for women aged 40 to 44. Usually, length variation between eight and 20 days in a woman is considered as moderately irregular menstrual cycles. Variation of 21 days or more is considered very irregular.(Konig and Liebich 1999)

2.2.2.Pregnancy in the first trimester:

Pregnancy is associated with normal physiological changes that assist fetal survival as well as preparation for labour. It is important to know what 'normal' parameters of change are in order to diagnose and manage common medical problems of pregnancy**.**Most of the time, women won't know the exact day got pregnant. Doctor will count the start of pregnancy from the first day of last menstrual period. That's about 2 weeks ahead of when conception happens.Here's a primer on conception:

Each month inside ovaries, a group of eggs starts to grow in small, fluid-filled sacs called follicles. Eventually, one of the eggs erupts from the follicle (ovulation). It usually happens about 2 weeks before your next period.After the egg leaves the follicle, the follicle develops into something called the corpus luteum. The corpus luteum releases a hormone that helps thicken the lining of uterus, getting it ready for the egg. If one sperm does make its way into the fallopian tube and burrows into the egg, it fertilizes the egg. The egg changes so that no other sperm can get in.At the instant of fertilization, Baby's genes and sex are set. If the sperm has a Y chromosome, Baby will be a boy. If it has an X chromosome, the baby

will be a girl. Implantation: (Moving to the Uterus)The egg stays in the fallopian tube for about 3 to 4 days. But within 24 hours of being fertilized, it starts dividing fast into many cells. It keeps dividing as it moves slowly through the fallopian tube to the uterus. Its next job is to attach to the lining of uterus. This is called implantation.Some women notice spotting (or slight bleeding) for 1 or 2 days around the time of implantation. The lining of the uterus gets thicker and the cervix is sealed by a plug of mucus. It will stay in place until the baby is ready to be born. A fertilized ovum up to 14 days old, before it becomes implanted in the uterus.The first week of embryonic development will be described in the following:Fertilization**,** Capacitation**,** Acrosome Reaction**,** Zygote**,** Cleavage**,** Morula**,** Inner cell mass or embryoblastandOuter cell mass or Trophoblast**.** The embryonic development first begins with the fusion of female and male gametes (with haploid, n number of chromosome). The process of fusion of male and female pronuclei is known as fertilization. Fertilization occurs in the ampullary region of the uterine or fallopian tube. (Senger 2002)

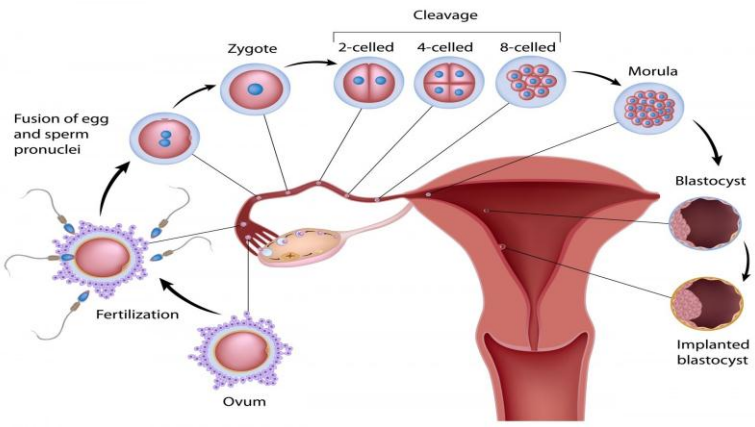

Figure 2.10: pregnancy and conception

www.pregnancy and conception images.com

2.3 Pathology of the Female reproductive System:

The pathological evaluation of the first trimester miscarriage includes assessment of the morphological features of the gestational sac, embryo or fetus, whereas the initial pathologic assessment should be used to confirm the presence or absence of pregnancy tissue as shown in the follow:

2.3.1 Failure of pregnancy in first trimester:

Early pregnancy failure is a common cause of miscarriage. It happens when a fertilized egg implants in the uterus but the resulting embryo either stops developing very early or doesn't form at all.

A miscarriage is a pregnancy that ends by itself within the first 20 weeks. "Stillbirth" refers to the loss of a pregnancy with fetal death that occurs after the first 20 weeks. Experts estimate that about half of all fertilized eggs die and are miscarried, usually even before the woman knows she is pregnant. Most miscarriages occur between the 7th and 12th weeks of pregnancy.(Wilcox 1988)

Figure 2.11:Transvaginal ultrasound for normal gestation sac

www.ultrasound images.com

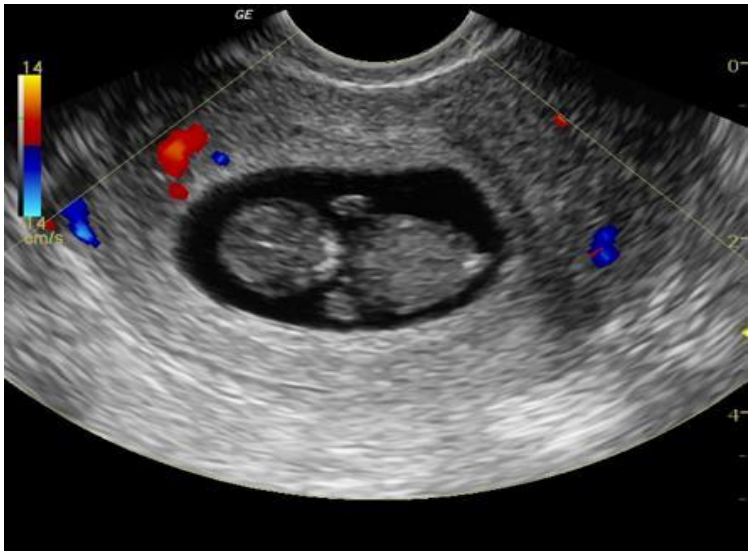

Figure 2.12: miscarriage embryonal demise

www.ultrasound images.com

2.3.2 Causes of Miscarriage:

Most miscarriages occur when the unborn baby has fetal genetic problems. Usually, these problems are unrelated to the mother.

Other possible causes of miscarriage include: infection, medical condition in the mother, such as diabetes or thyroid disease, hormonal factors, immune responses, physical problems in the mother ,and uterine abnormalities. A woman has a higher risk of miscarriage if sheis over age 35or if she has a history of more previous miscarriages.(Arck 2008)

2.3.3Types of miscarriage:

A pregnant woman can undergo different miscarriages that are categorized by different names. It is used as an umbrella term to explain different types of loss of pregnancies. These different types of spontaneous loss of pregnancies are discussed below:

2.3.3.1ThreatenedMiscarriage:

This is a type that sends shivers down an expecting mother's spine. In this

condition, a woman suffer from vaginal bleeding along with some light spotting. It is ,1 in 4 pregnant women suffer from this type of bleeding during their first trimester. In this type, the cervix remains tightly closed. The mother and the fetus need to be closely monitored and in majority of the cases, the pregnancy continues without any major issues. An ultra-sound is an important diagnostic tool to monitor it.

(Rowling and Coleman 1997)

Figure 2.13: Threatened Miscarriage

www.threatened abortion ultrasound images.com

2.3.3.2 Missed Miscarriage:

Many pregnant women experience this type without any symptoms. They are unaware of the fact that they have just undergone an abortion and suffered from embryonic death. The embryo is not expelled from the womb for unknown reasons and thus the mother does not experience any symptoms. Fetal death is only determined when fetal heart tones checked during an ultrasound examination.(Bagratee and Khullar 2004)

Figure 2.14: A missed abortion

www. Ultrasound images.com

2.3.3.3IncompleteorInevitableMiscarriage:

This occurs when the body starts the process of spontaneous abortion, but fails to expel all the tissues of failed pregnancy from the womb. The cervix dilates indicating it is a sure sign of expelling the fetus from the uterus. The mother experiences abdominal or back pain along with bleeding and cramps. This type of failed pregnancy is inevitable as there is no way from stopping the loss from occurring. Aninevitable miscarriage refers to the presence of an open internal os in the presence of bleeding in the first -trimester of pregnancy .(Ledger1994)

2.3.3.4 Complete Miscarriage:

When all the products of conception, that is, the embryo have been expelled from the womb, it is termed as a complete failure. The bleeding will stop quickly and one can confirm it with the help of an ultrasound.

Essentially, a threatened miscarriage progresses to an inevitable miscarriage if cervical dilatation occurs. Once tissue has passed through the cervical os, this will then be termed an incomplete miscarriage and ultimately a complete miscarriage.(Winikoff and Dzuba 2008)

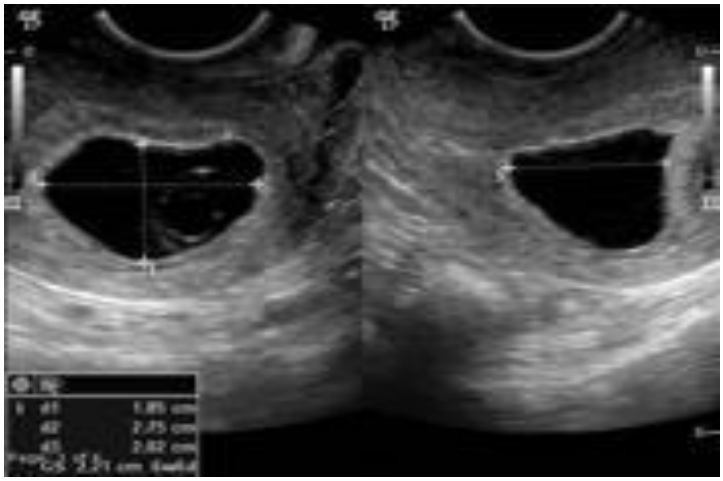

Figure 2.15: Complete Miscarriage

www.ultrasound images.com

2.3.3.5 Recurrent Miscarriage:

There are about 1% couples who suffer from this form. It occurs when there is loss of three or more consecutive first trimester miscarriages. absence of any kind of fetal growth.(Regan 2004)

2.3.3.6 Blighted Ovum:

When a fertilized egg is implanted in the uterine wall, it will undergo fetal development. However, in case of a blighted ovum, also called an embryonic pregnancy, this never occurs. The presence of a gestational sac with or without the presence of a yolk sac. However, there is total absence of any kind of fetal growth. (Moon 2009)

Figure 2.16: ultrasound image showed blighted ovumwww.ultrasound images.com

2-3-3-7 Ectopic Pregnancy:

When a fertilized egg implants itself inside the fallopian tube instead of the uterus, it is termed as an ectopic or tubal pregnancy. These pregnancies require immediate termination as the developing egg will lead to rupture of the fallopian tube. If left untreated, it could lead to serious complications including maternal death. .(Scott 1987)

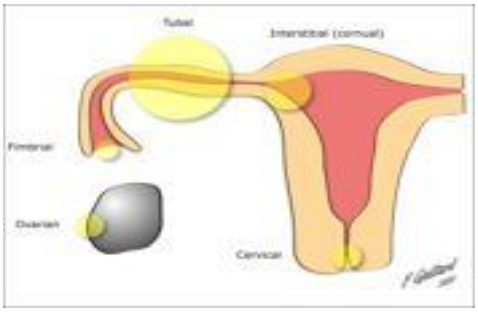

Figure 2.17: Location of the ectopic pregnancy (www.location of the ectopic pregnancy images.com)

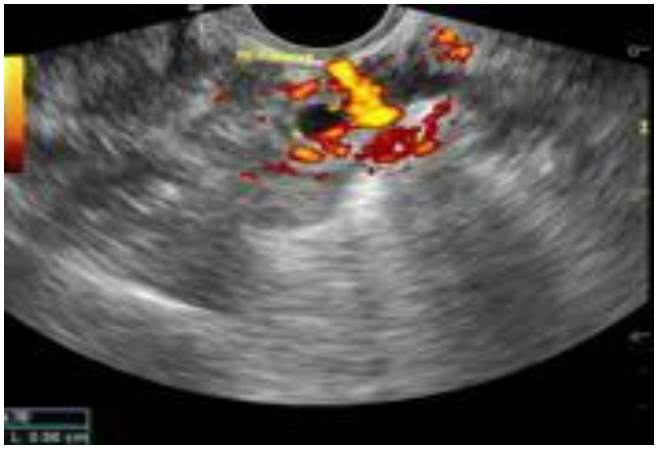

Figure 2.18Tubual ectopic pregnancy (www.ectopicpregnancy ultrasound images.com

2-3-3-8 Molar Pregnancy:

During fertilization, an error in the genetic coding can lead to growth of an abnormal tissue. These pregnancies rarely involve the embryo, but cause in development of cells that make up the placenta. However, there is no fetus just presence of an incomplete mole. It is actually a form of tumor that will not survive. This is a very rare kind of pregnancy, thus, not seen in majority of the cases.(Mangili 1993)

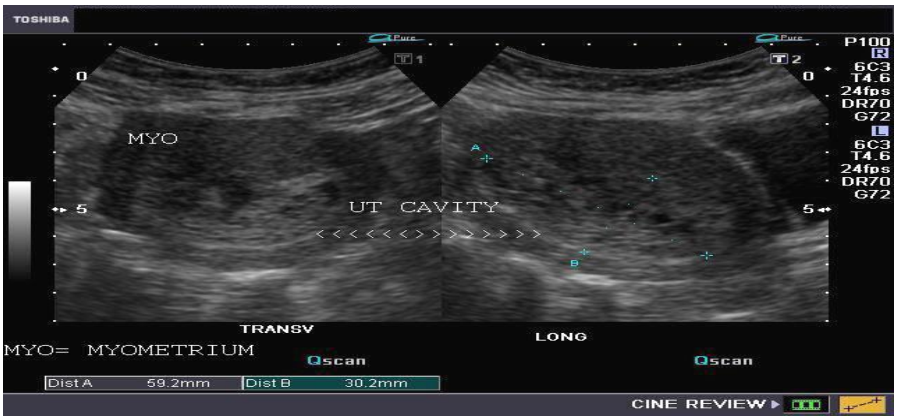

Figure 2.19Molar pregnancy (www.ultrasound images.com)

2.3.4. Signs and symptoms of Early Miscarriage:

Most miscarriage symptoms are not definitive indicators of pregnancy loss, but possible signs include vaginal bleeding in pregnancy, cramping, and loss of pregnancy symptoms. Patients with spontaneous complete abortion usually present with a history of vaginal bleeding, abdominal pain, and passage of tissue. After the tissue passes, the vaginal bleeding and abdominal pain subsides. Other symptoms, such as fever or chills, are more characteristic of infection, such as in a septic abortion. Septic abortions need to be treated immediately; otherwise they may be life-threatening. Patients who are pregnant and bleeding vaginally need immediate evaluation. (Elson 2003).

2.3.5 Others Diseases affect early pregnant failure:

There are many types of diseases affect the first trimester:

2.3.5.1 Renal Disease in pregnancy:

Renal disease can affect the outcome of pregnancy, pregnancy can affect the progression of pre-existing renal disease, and pregnancy can itself cause renal impairment. The renal system undergoes significant physiological and anatomical changes during a normal pregnancy:

Renal plasma flow increases by 50-70% in pregnancy (the change is most pronounced in the first two trimesters). There is an increased glomerular filtration rate (GFR), which peaks at about the 13th week of pregnancy and can reach levels up to 150% of normal. Therefore, both urea and creatinine levels are decreased. (Fink and Schwartz 1998)

Increased levels of progesterone at the beginning of pregnancy increase relaxation of arterial smooth muscles and so decrease peripheral vascular resistance, causing a blood pressure fall of approximately 10 mm Hg in

the first 24 weeks of pregnancy.The anatomical changes are mainly in the collecting system. A dilatation of the ureters and pelvis occurs, which can lead to urinary stasis and an increased risk of developing urinary tract infections (UTIs). (Cunningham 1990)

There is also an increase in overall kidney size by about 1-1.5 cm.

In general, the physiological changes peak by the end of the second trimester and then start to return to pre-pregnancy levels; anatomical changes generally take up to 3 months postpartum to subside.

Asymptomatic bacteriuria is found in 2% of sexually active women, and is more common (up to 7%) during pregnancy.(Trevisan and Ramos 2004)

Because of the dilatation of the calyces and ureters that occurs in pregnancy, 25% will go on to develop pyelonephritis, which can cause fetal growth restriction, fetal death, and premature labour.

Pyelonephritis is common at around 20 weeks and in the puerperium.

Asymptomatic bacteriuria and urinary tract infections (UTIs) in pregnancy should be treated with antibiotics. Antibiotic prophylaxis should be given to women with recurrent bacteriuria or UTIs and kidney disease.(Fisher MJ, Lehnerz 2004)

20% of women having pyelonephritis in pregnancy have underlying renal tract abnormalities and an intravenous urogram (IVU) or ultrasound at 12 weeks postpartum should be considered.(Bar and Orvieto 2000)

The Problems related to specific kidney diseases in pregnancy:

Reflux nephropathy ,Diabetic nephropathy, and Kidney transplant recipient, they are Increased risk of miscarriage in the first trimester , hypertension, and Premature delivery.(Shemin 2003)

2.3.5.2 Pregnancy and Thyroid Disease:

Thyroid disease is a disorder that affects the thyroid gland. Sometimes the body produces too much or too little thyroid hormone. Thyroid hormones regulate metabolism, the way the body uses energy-and affect nearly every organ in the body. Too much thyroid hormone is called hyperthyroidism and can cause many of the body's functions to speed up. Too little thyroid hormone is called hypothyroidism and can cause many of the body's functions to slow down. (Okosieme and Marx 2008)

Thyroid hormone plays a critical role during pregnancy both in the development of a healthy baby and in maintaining the health of the mother.

Women with thyroid problems can have a healthy pregnancy and protect their fetuses' health by learning about pregnancy's effect on the thyroid, keeping current on their thyroid function testing, and taking the required medications. (Vissenberg 2012)

2.4 Role of Ultrasound in diagnosis early pregnant loss:

Confirming the presence of baby's heartbeat. The ultrasound can routinely detect a heartbeat of baby as early as 6-7 weeks.Confirming the correct dates of pregnancy. Some women are uncertain of their last menstrual period (LMP) or have irregular menstrual cycles, making it difficult for their doctor to correctly estimate when the baby is due. Establishing accurate dates can be important, especially if there are concerns about baby later in the pregnancy (for example, if the baby is not growing well). An ultrasound in the first trimester can give an accurate estimated date of confinement (EDC) to within 3-5 days. Generally speaking, the earlier in pregnancy the ultrasound is performed, the more accurate it will be at estimating baby due date (technical factors such as the quality of the ultra-

sound image and the expertise of the sonographer will affect this accuracy.(Confirming the location of pregnancy. The ultrasound will check if pregnancy is developing normally within the uterus.

(Jauniaux and Johns 2005)

Determining the number of babies present. Ultrasound can concerned about having more than one baby (for example, twins or triplets) if pregnancy conceived with the help of clomiphene or a family history of twins or uterus seems larger than expected. This ultrasound can determine the number of babies, as well as the type of twins. Identifying pregnancies at increased risk of miscarriage or pregnancy loss. The first trimester ultrasound detect changes in the early pregnancy that are concerning and associated with an increased risk of pregnancy loss (for example, the pregnancy sac is small or irregular, or the baby's heart beat is much slower than expected) Such appearances not always be significant for baby, that pregnancies with these changes continue without problems over subsequent weeks.(Lazarus 2003)

Checking other pelvic organs. Ultrasound checks other things in pelvis apart from pregnancy, such as the uterus (for example, if there is a history of fibroids) and the ovaries (for example, pelvic pain and there is concern about an ovarian cyst).To concerned about abdominal pain or vaginal bleeding. This early ultrasound can provide reassurance that everything is progressing normally. It detects a serious problem with either mother or pregnancy, some of which require further investigations or treatment. Sometimes the results of a first trimester scan inconclusive or uncertain, and need to be combined with clinical history and blood tests (serum BhCG) .Some women need to return for another ultrasound scan a few

weeks later to assess the progress of the pregnancy, or they require another blood test (serial serum BhCG). **(**Hately andCase 1995)

2.4.1 Ultrasound evaluation in the failure of first trimester:

With the increased availability of ultrasound, patients are receiving earlier sonographic diagnoses, and it is more precise to describe unsuccessful or failed pregnancies based on their sonographic appearance with "embryonic demise" referring to cases where the ultrasound clearly shows an "embryonic fetal pole" without cardiac activity. Anembryonic miscarriage is defined by sonography as an empty gestational sac at a gestational age where one would expect to see a yolk sac or embryo with cardiac activity.Ultrasound is the primary tool for diagnosing miscarriage. In early pregnancy, a vaginal ultrasound – which is completely safe – is more accurate than an abdominal ultrasound because the vaginal probe can get very close to the uterus to see the pregnancy more clearly. (Morin2005)

If a woman has a 28-day cycle, by five weeks after her last period, a small gestational sac can often be seen inside the uterus, and by six weeks, a small embryo with a heartbeat will usually be present. However, because women sometimes ovulate later than they think, the absence of these changes doesn't always mean miscarriage is occurring. Another ultrasound a week later may be needed. Nevertheless, if the gestational sac is quite big, but there is no embryo or if the embryo is quite big but there is no heartbeat, or if there has been no growth over a week, miscarriage is very likely. (Hately 1995)

An anembryonic pregnancy diagnosed when there is nofetal pole identified on trans-vaginal scanning, and: the size of the gestational sac is such that a fetal pole should be seen : MSD≥ **25** mm (by RCOG cri-

teria). There is little or no growth of the gestational sac between interval scans. Normally the MSD should increase by **1** mm per day if MSD is too small to ascertain viability on the initial ultrasound, a follow up scan in 10-14 days should differentiate early pregnancy from a failed pregnancy. Other ancillary features include

- absent yolk sac when MSD > **8** mm
- poor decidual reaction : often <**2** mm
- irregular gestational sac shape
- abnormally low sac position.

An ultrasound scan can be able to detect a pregnancy and a heartbeat in a normal pregnancy at around 6 weeks, but this varies a great deal and isn't usually advised.

The best time to have a scan is from about 7 weeks' gestation when it should be possible to see the baby's heartbeat in a normal pregnancy

2.4.2 Doppler Ultrasound Predicts Risk of Miscarriage:

Doppler ultrasound performed in early pregnancy can accurately identify embryonic congestive heart failure and subsequent risk of miscarriage. 3-D ultrasound was performed to evaluate vasculature (Uterine artery Doppler and 3-D power Doppler) and placental volume. (Acharya 2010)

2.4.3 Side Effects and Safety Risks of Ultrasounds:

Most of the time, ultrasounds do not have any side effects other than possible discomfort from having a full bladder. The procedure is not painful, although a transvaginal ultrasound is more invasive . Ultrasounds are generally considered safe. One study suggested that very frequent ultra-

sound use cause developmental problems but other studies have found no such risks.(Pavord 2010)

2.5 Imaging modalities for diagnosis pregnancy failure in the first trimester:

Radiology plays an essential role in identifying and diagnosing early pregnancy complications, with ultrasound (US) being the primary imaging modality. 3D and 4D ultrasounds use sound waves to create an image of fetal, 3D ultrasounds create a three-dimensional image of your baby, while 4D ultrasounds create a live video effect, like a movie , but the standard common obstetric diagnostic mode is 2D scanning.Nearly all instances of first trimester bleeding can be adequately evaluated with a combination of clinical evaluation, serum B-hCG assay and US, preferably endovaginal technique. Magnetic resonance imaging has a limited role, particularly if the US is technically inadequate, or in the setting of an indeterminate adnexal mass. (Lazarus 2003)

The embryoscopy can successfully augment the evaluation of vaginal bleeding(see Figure 2-7,Figure 2-8).There is essentially no role for CT in evaluating first trimester bleeding.



Figure 2-20: Embryoscopy

www.Embryoscopy images.com

Embryoscopy is the examination of the embryo at 9-10 weeks gestation through the intact membranes by introducing an endoscope into the exo-coelomic space transcervically or transabdominally. This is to recognize fetal abnormalities, the procedure- related risk of fetal loss is around 12 per cent.

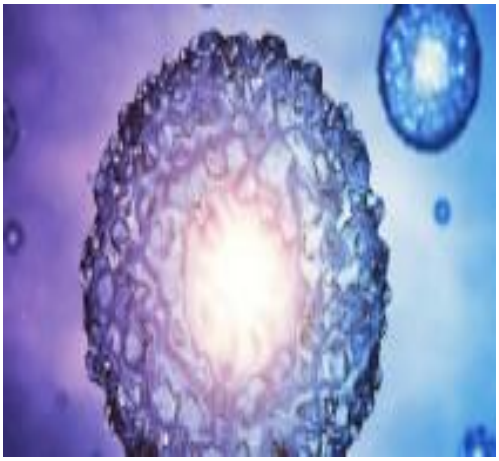

Figure 2.21: Blastocyst transfer by the EmbryoScopywww.EmbryoScopy images .com

2.6 Previous studies:

This study has been done by Ventura and Guyer et al,1999, to determine the proportion of women giving birth after 35 years of age has risen considerably in industrialized countries. In the USA, the birth rate (per 1000) of women aged 35–39 years increased from 19.0 in 1976 to 37.4 in 1998 Over the same period, several studies have concluded that women aged more than35 years have a higher frequency of various adverse reproductive events: infertility.

Study done by Schwartz and Mayaux et al, 1991, reported that spontaneous abortion, pregnancy complications ,congenital abnormalities, maternal mortality and perinatal mortality, than do younger women.

Other done by Leridon and Regan et al, 1989, reported that the risk factors for spontaneous abortion have concluded that the predominant negative effects are those of advanced maternal age (with a clear increase in risk after 35 years) and previous spontaneous abortion.

Study done by Risch and Coste et al, 1991,Were Conflicting results have been obtained for otherspontaneous abortion risk factors such as maternal consumption of tobacco, maternal psychological problems, interval between pregnancies, or previous use of the contraceptive pill Thus most of these studies analysed the effect of female factors on spontaneous abortion.

Other study done byYerushalmy and Woolf etal, 1965, study concluded that paternal age had an effect, after adjusting for maternal age and Resseguie.

Study done by Sid Kirchheimern ,2003, reported that Stress has long been suspected as a possible cause of miscarriage, with several studies indicating an increased risk among women reporting high levels of emotional or physical turmoil in their early months of pregnancy or just before conception.

Study done by Togas Tulandi ,2015 , reported that A miscarriage is a failed intrauterine pregnancy that ends before 20 weeks from the last menstrual period. A brief review of the events of early pregnancy will help in the understanding of miscarriage.

Study done by Sheuly Begum, and ArifaAkterJahan etal, 2012, that followed women's hormone levels every day to detect very early pregnancy found a total miscarriage rate of 31 percent .

Chapter three

CHAPTER THREE

Material and Methods of the study

3.1 Study Area& Duration:

The study conducted on Health care center that the patients came for follow up pregnancy in United Arab Emirates , Dibba Fujairah Hospital .The study carried over duration of 12 months from June 2014 to June 2015.

3.2 Study Subjects:

The data collected from fifty pregnant women with includes UAE pregnant women aged from 15 years old and above, with high positive clinical manifestations like vaginal bleeding, pelvic pain and Pelvic mass.

3.2.1 Inclusion Criteria:

Pregnant women with high positive clinical manifestations like vaginal bleeding, pelvic pain and Pelvic mass.

All pregnant women should be offered the screening are :

- Women who have a family history of birth defects
- Women who are15- 35 years or older
- Women who used possible harmful medications or drugs during pregnancy

3.2.2 Exclusion Criteria:

Pregnant women who have known previous diagnosis of early pregnant abnormalities, diabetic pregnant patients, hypertensive pregnant patients and placenta previa patients.

3.4 Study Design:

Prospective clinical experimental study

3.5 Data Management and Analysis Plan:

Data were analyzed by using SPSS , frequencies ,percentages ,and cross tabulation , between, age , risk factors , prevalence of miscarriage abortions, ectopic pregnancy, molar pregnancy and blighted ovum.

3.6 Ethical Considerations:

All results taken from patients images after the verbal agreement of them , the Head of the department , and Medical Records Clerks in Hospital .

All cases evaluated in so privacy way and no patients information more than needed used .

3.7 Scanning technique:

First trimester ultrasound scanning in pregnancy is often useful to identify many pregnancy and fetal abnormalities and also provides an abdominal approach or a vaginal approach.Abdominal ultrasound scanning is usually performed with a full bladder, provides a wider field of view, and pro-

vides the greatest depth of view . Vaginal scanning is best performed with field of view. And provides the greatest depth of view. Vaginal scanning is the best performed with the bladder empty, gives a much greater resolution with greater crispness of fine detail. In circumstances where both approaches are readily available, the greater detail provided by trans vaginal scans usually outweighs other considerations, and is preferred.

Scanning is usually done in the normal examination position (dorsal lithotomy)with her feet secure in stirrups and her perineum even with the end of the examination table.

3.7.1Transabdominal ultrasound:

It can be also used to evaluate first-trimester pregnancy, with a few differences.First, because the probe is farther away from the desired structures, 7 weeks from the last menstrual period (LMP) must elapse before the gestation can be visualized. Second, using the transabdominal probe, the bladder is seen on the right of the screen with the vagina seen just behind it. Third, unless there is significant pathology enlarging them, the ovaries are difficult to visualize. Principles of scanning otherwise remain the same--visualize the uterus in both longitudinal and transverse planes.

involves scanning through lower abdomen. A small amount of ultrasound gel is put on the skin of the lower abdomen, with the ultrasound probe then scanning through this gel. The gel helps improve contact between the probe and skin.(Ismail 1991)

Pregnancy ultrasounds are performed mainly using transabdominal ultrasound.For many women, especially after 8 weeks gestation, sufficient information about the fetal with transabdominal ultrasound only. However, in the early pregnancy, the developing embryo is very small (at 6 weeks gestation, the baby is only 5-9mm long) and a transvaginal ultrasound

required to get a better image of the baby. Transvaginal ultrasound is safe and commonly performed during all stages of pregnancy, including the first trimester. It will not harm mother or baby. **(**Hately 1995)

A 1st trimester series should include the following minimum images:

Uterus-long,trans,bothovaries,adnexae,cervix and Pouch of Doglas,gestationsac-Long&Trans,yolk sac if visible, fetal pole, M mode fetal heart,and document the normal anatomy. Any pathology found in 2 planes including measurements. Less than10 weeks , theCervix - assess if closed and measure length between internal and external os,Look for bright trophoblastic reaction around sac, a ssess placental location and distance from internal os ,check for retroplacentalhaemorrhages, placental masses, assess maternal ovaries, adnexae and Pouch Of Douglas (P.O.D),confirm presence of intrauterine gestation, and number If multiple pregnancy, confirm number of foetuses, number of sacs, and number of placentas present to determine chorionicity. Monochorionic/Monoamnionic(MCMA),Monochorionic/Diamnionic(MCDA),Dichorionic/Diamnionic(DCDA),confirm heart beat(s) & rate with M-Mode only, measure CRL to calculate gestational age and estimated date of delivery.The patient asymptomatic, presenting for early pregnancy ultrasound. Alternatively, she present with vaginal bleeding in early pregnancy.(Levi 1990)

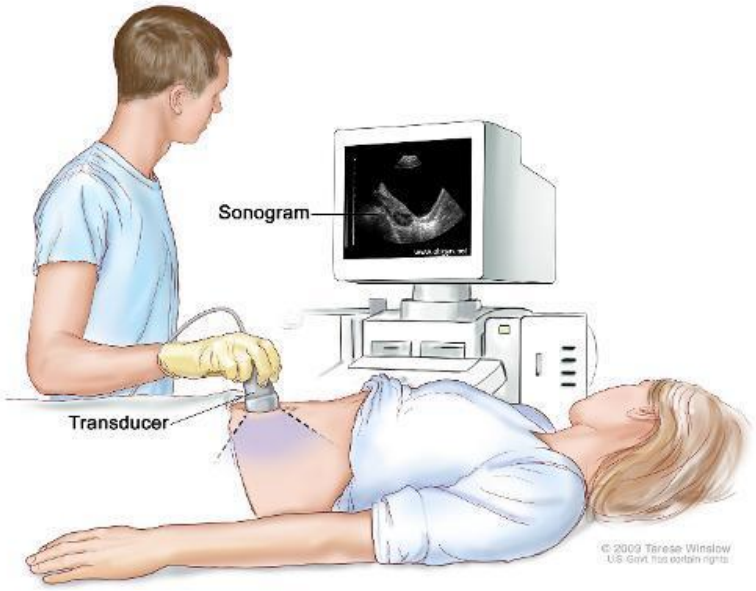

Figure 3.1 Transabdomen ultrasound technique

3.7.1.1Preparing for an Ultrasound:

Transvaginal ultrasounds do not require any preparation, but for an abdominal ultrasound in early pregnancy, drink at least 1 litre of water and do not go to the toilet until instructed. Having a full bladder positions your uterus to get the best picture.A full bladder moves bowel out from the pelvis into the abdomen, helping visualisation of the pregnancy, uterus and ovaries.Bladder should not be so full that it causes pain. If bladder is very full and painful, patient should empty a small amount so she will be more comfortable.she will be able to empty her bladder after the transabdominal ultrasound is completed and before the transvaginal ultrasound begins (if transvaginal ultrasound is required).(Lazarus 2003).

3.7.1.2Patient History:

Gravidity,Parity(Miscarriage, Termination of Pregnancy(T.O.P)), Fertility treatment,Date of last menstrual Period,Other pregnancy History, And gynaecological History.(Morin 2005)

3.7.2Transvaginal Ultrasound:

Transvaginal ultrasound in the early of pregnancy more accurate than abdominal ultrasounds. If there are any complications during pregnancy, such as pain or bleeding, it need one later .Transvaginal ultrasounds check baby's heartbeat and the placenta. It can rule out problems, such as ectopic pregnancies. It also show problems with the cervix "short cervix" that raise risk of early labor.On transvaginal ultrasound an empty intrauterine gestational sac measuring less than 20mm in mean sac diameter.an intrauterine gestational sac containing a fetal pole with a crown-rump length (CRL) of less than 6mm with no fetal cardiac activity .

gestational sac < 25mm in mean diameter and containing yolk sac only .
In these situations a follow up ultrasound scan in 7-14 days to be a viable pregnancy.(Timor 1988)

It is an internal ultrasound. It involves scanning with the ultrasound probe lying in the vagina. Transvaginal ultrasound usually produces better and clearer images of the female pelvic organs including the developing pregnancy, because the ultrasound probe lies closer to these structures.

The transvaginal ultrasound probe is thin, about 2cm diameter. The probe is covered with a disposable protective sheath. A small amount of ultrasound gel is placed on the end of this probe. The probe is then gently inserted a short distance into the vagina. All transvaginal probes have been cleaned and sterilised according to recommended protocols.

Privacy should always be respected during ultrasound, especially the transvaginal examination. Patient should have a large towel covering lower body, in addition to wearing a gown during the transvaginal ultrasound.(Takeuchi 2004)

patient always have a choice about whether transvaginal ultrasound is performed. If she have concerns about transvaginal ultrasound, she can

discuss this with sonographer before ultrasound begins.patient lies on a table with her feet in stirrups. It's like a pelvic exam. The technician will insert a small, lubricated probe into her vagina. It shouldn't hurt, but she may feel uncomfortable pressure.The technician will watch images on a screen and adjust the probe. The whole test will take about 30 to 60 minutes.An endocavitary probe is covered with a glove after transmission gel is first placed into one of the fingers, or a prefabricated sheath designed for this purpose can be used (see figure 3-3). A full bladder during the examination will retrovert the uterus and can be uncomfortable for the patient.(Nyberg 1986)

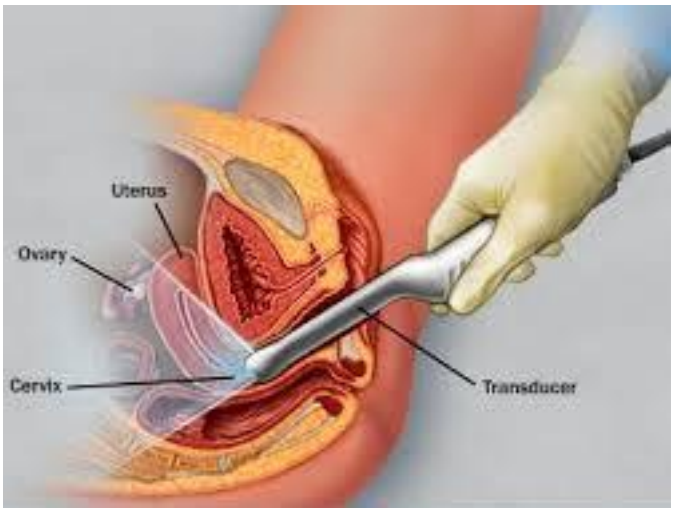

Figure 3-2 :Transvaginal Technique

With the patient placed in the lithotomy position, insert the probe into the vagina with the probe marker up, allowing a view of the uterus longitudinally. The bladder is seen on the left of the display screen, the body of the uterus in the middle and the cervix on the right. The vagina is not visualized because the probe is within it.Fan the probe to the right and to the left to scan through the body of the uterus and to assess that any gestation is contained within the uterus and not lying outside of it.Assess for free

fluid posterior to the uterus, as this indicate a pathological process. Fluid is easily seen in this location, and ultrasound has replaced culdocentesis as the standard method for detecting free fluid.The probe should then be rotated 90 degrees counterclockwise, placing the probe marker to the patient's right. This is the uterus viewed in the coronal plane . The uterus should be scanned through in its entirety in this plane as well, by gently moving the tip of the probe up and down.Evaluation of the adnexa is challenging, especially to facilitate finding the ovaries.First, while visualizing the uterus in the coronal plan, scan up toward the uterine fundus. Move the probe in a plane parallel to this level toward the lateral fornix of each side. Following the cornua laterally to the adnexa will bring the fallopian tube and ovary into view. Another method is to move the probe laterally to find the iliac vessels. The ovary lies just medial and anterior (toward the patient's abdomen) of these vessels, and angling the probe in this way should bring each into view. (Levi 1990)

2.4 Tools & equipment:

Ultrasound system general electric health care,(GE)and(Sono Site M-Turbo) ,Transabdominal ultrasound scanning done with moderately distended bladder by using real time scanners with low frequency probe (3/3.5 MHz); transvaginalsonography done with the real-time sector scanner using high-frequency endovaginal probe (5/7.5 MHz),. Ultrasound gel makes probe movement easy and more close contact probe-skin .Thermal paper .CD or DVD.The evaluation of the patients include the following: Record of patients obstetrical history and clinical examination, record of pregnancy test and relevant investigations, ultrasonic examination of pregnancy.

Figure 3-3: GE Ultrasound machine in Dibba Fujairah Hospital in UAE

Figure 3-2: Sono Site M-Turbo Ultrasound portable machine in Dibba Fujairah Hospita

Chapter four

CHAPTER FOUR

RESULTS

Table 4.1: Distribution of age

Age Distribution	**Frequency**	**Percent**
15-19	4	8%
20-25	6	12%
26-30	9	18%
31-35	14	28%
36-40	17	34%
Total	**50**	**100%**

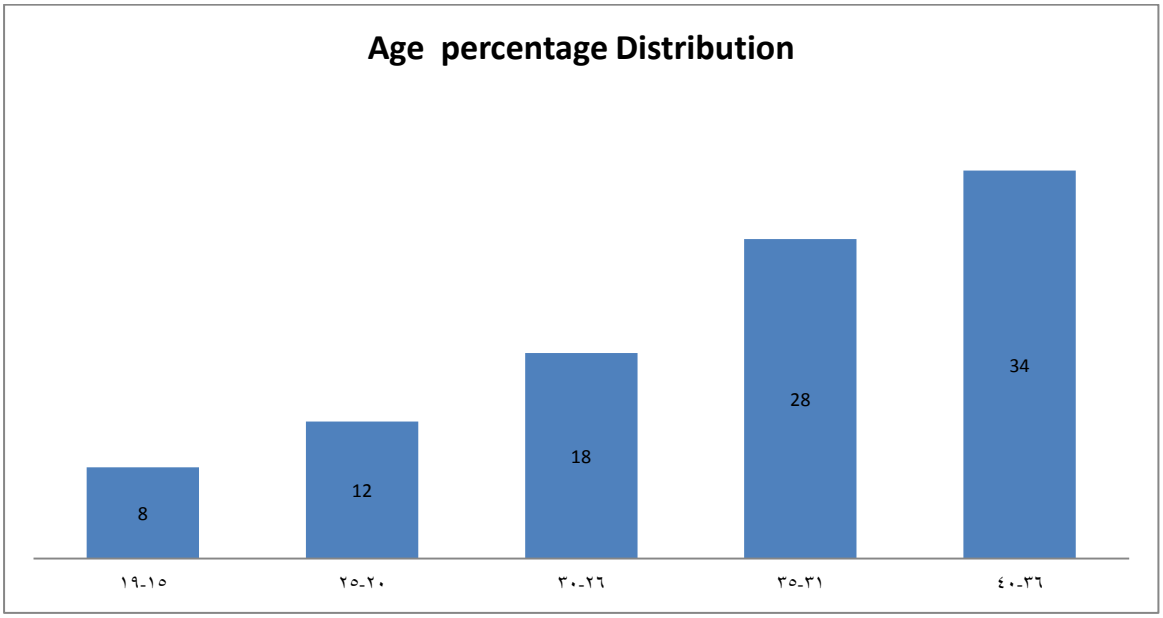

Figure 4.1 Age percentage distribution

Table 4.2 distribution of clinical manifestations:

Clinical Manifestations	frequency	Percent
Pelvic bleeding	25	50%
Pelvic pain	10	20%
Pelvic bleeding and pain	13	26%
Pelvic mass	2	4%
Total	50	100%

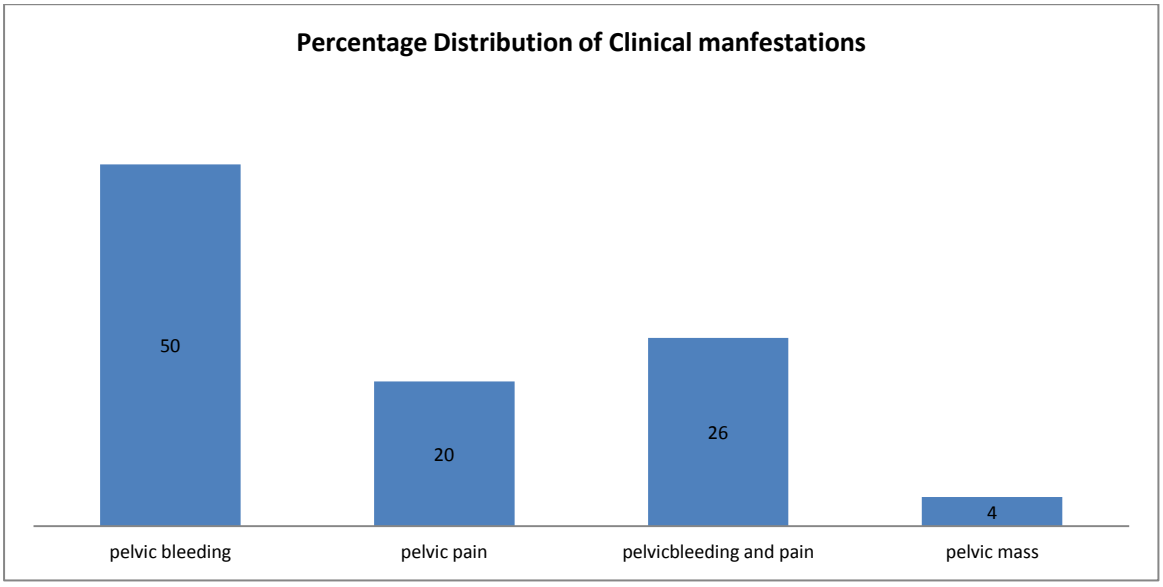

Figure 4.2 Percentage Distribution of clinical manifestations .

Table 4.3 Distribution of Causations

Causations of failure pregnancy	frequency	Percent
Miscarriages	38	76%
Uterine mass	2	4%
Ectopic pregnancy	1	2%
truma	2	4%
Renal diseases	3	6%
Pelvic inflammatory disease	2	4%
Thyroid disease	2	4%
Total	50	100%

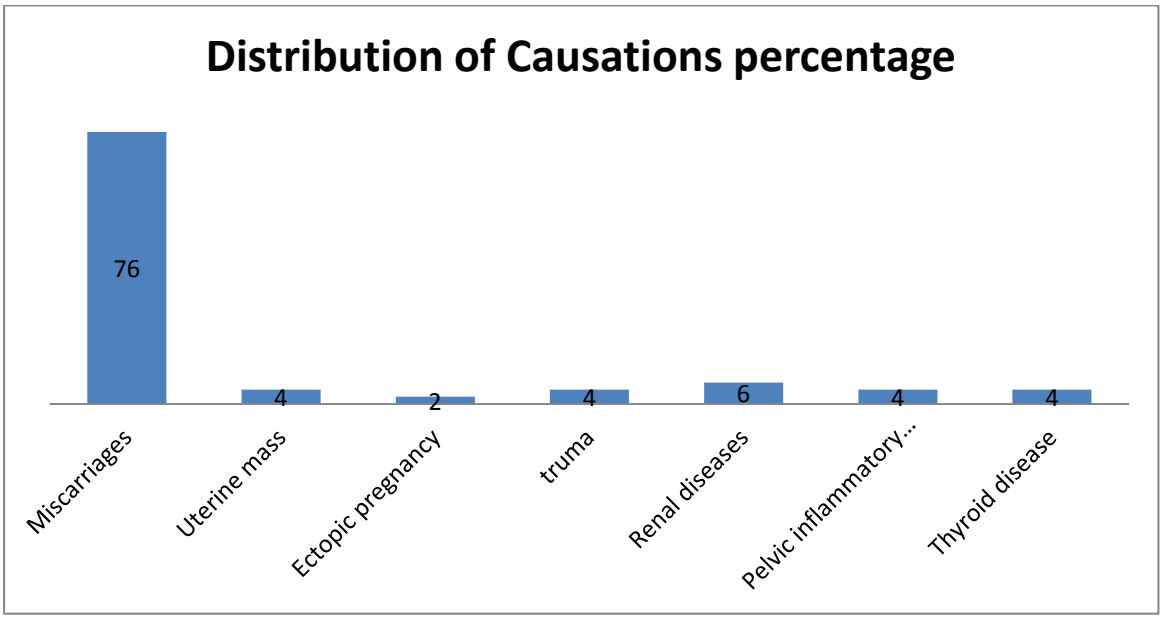

Figure 4.3 Percentage of Causations of failure pregnancydistribution

Table 4.4 Distribution of abortions

Distribution of Abortion In 1st trimester	**frequency**	**Percent**
Blighted ovum	2	4%
Threatened abortion	8	16%
Complete abortion	7	14%
Incomplete abortion	20	40%
Missed abortion	10	20%
Ectopic pregnancy	1	2%
Fibroid	2	4%
Total	50	100%

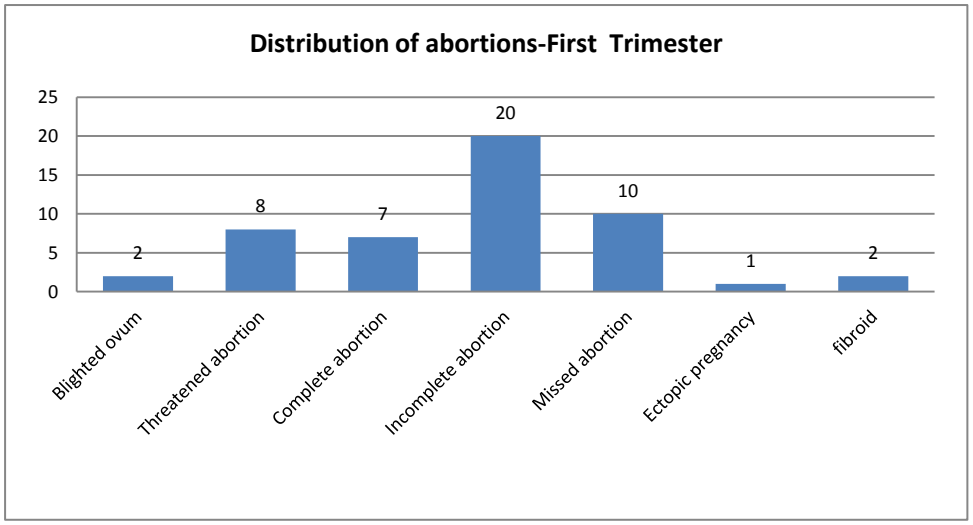

Table 4.4 Distribution of abortions frequency

Table 4.5 Distribution of hCG blood pregnancy test level

Beta hCG blood pregnancy test level	frequency	percentage
+ve(Increased level)	45	90%
-ve (normal level)	5	10%
Total	50	100%

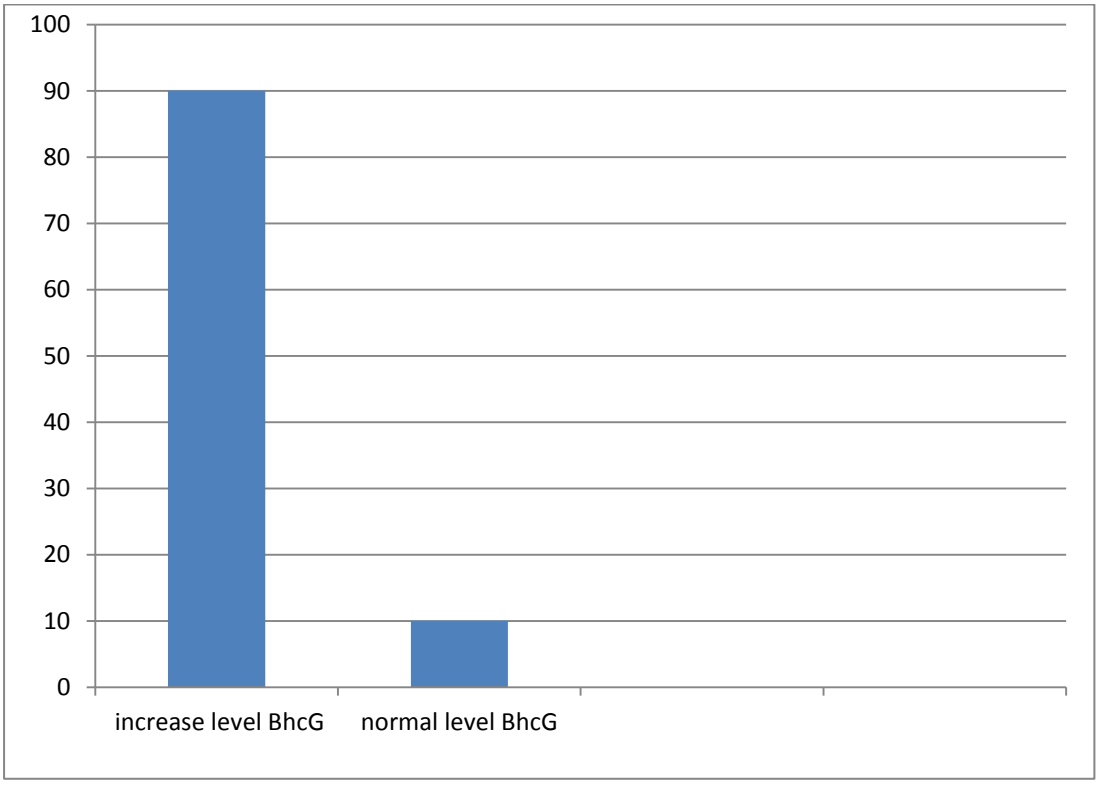

Figure 4.5 Distribution of hCG blood pregnancy test level

Table 4.6 Ultrasound finding and continuity of the pregnancy cross tabulation:

Ultrasound finding And continuity	Continue pregnancy	Not continue pregnancy	Total
Blighted ovum	0	2	2
Threatened abortion	6	2	8
Complete abortion	0	7	7
Incomplete abortion	0	20	20
Missed abortion	0	10	10
Ectopic pregnancy	0	1	1
fibroid	2	0	2
Total	8	42	50

Chapter five

CHAPTER FIVE

5-1 Discussion:

This study had been conducted in Dibba Fujairah Hospital in United Arab Emirates, In table 4:1 . 34% (17) of pregnant years are more affected by The first trimester pregnancy failure their age between 36-40 years .08% (13) of pregnant years are less affected by The first trimester failure their age between 15-19 years .This result was agreed with (Ventura et al., 1988; Guyer et al., 1999) ,that a proportion of women giving birth after 35 years of age has risen considerably in industrialized countries. In the USA, the birth rate (per 1000) of women aged 35–39 years increased from 19.0 in 1976 to 37.4 in 1998 Over the same period, several studies have concluded that women aged more than35 years have a higher frequency of various adverse reproductive events: infertility. (Ventura et al., 1988; Guyer et al., 1999) The first trimester failure affected is with age.

On this study I found that In table 4:2 . 50% (25) of pregnant women's clinical manifestations was pelvic bleeding, 04% (02) was pelvic mass. The first trimester failure affected with pelvic bleeding.

Regard causation of miscarriage the research showed that In table 4:3 . 76% (38) of pregnant women's ,The first trimester pregnancy failure more caused by miscarriages . 02% (01) of pregnant women's ,The first trimester pregnancy failure less caused by ectopic pregnancy. This Is disagree with(Sid Kirchheimern 2003) reported Stress has long been suspected as a possible cause of miscarriage, with several studies indicating an increased risk among women reporting high levels of emotional or physical turmoil in their early months of pregnancy or just before conception.

The study showed that In table 4:4 . 40% (20) of pregnant women's ,The first trimester abortion more caused by incomplete abortion . 02% (01) of pregnant women ,The first trimester abortion less caused fibroid is agreed with (Togas Tulandi 2015) reported A miscarriage is a failed intrauterine pregnancy that ends before 20 weeks from the last menstrual period. A brief review of the events of early pregnancy will help in the understanding of miscarriage. The first trimester abortion affected with incomplete abortion .

I found that In table 4:5 . 90% (45) of pregnant women's , Beta blood hCG pregnancy test level increases with The first trimester pregnancyfailure . 10% (10) of pregnant women's , blood Beta hCG pregnancy test level decreased with The first trimester pregnancy failure is agreed with (Sheuly Begum, Maliha Rashid, Arifa Akter Jahan 2012) One study that followed women's hormone levels every day to detect very early pregnancy found a total miscarriage rate of 31 percent. The first trimester pregnancy failure affected with increases level of blood Beta hCG pregnancy test .

Also I found that In table 4:6 . (20) of not continue pregnancy affected with incomplete abortion , (10) of not continue pregnancy affected with missed abortion, (06) of continue pregnancy affected with threatened abortion .

5-2 Conclusion:

- Early pregnancy failure is can be diagnosis by the ultrasound, it can provide useful information
- The first trimester pregnancy failure is proportionally correlated to age.
- The first trimester pregnancy failure is proportionally correlated to pelvic bleeding.
- The first trimester pregnancy failure is proportionally correlated to af causation of miscarriage
- The first trimester abortion more caused by incomplete abortion less caused fibroid .
- The first trimester abortion is proportionally correlated to incomplete abortion .
- The first trimester failure is proportionally correlated to increases level of blood Beta hCG pregnancy test .
- Not continue pregnancy affected with incomplete abortion and missed abortion,
- Continue pregnancy affected with threatened abortion .

5-3 Recommendations:

- Sonographic diagnostic scanning in older age should be done for suspicious threatened abortion (above 35 years) of pregnant women.
- Blood Beta hCG pregnancy test is recommended pre ultrasound scan.
- The embryoscopyexam recommended can evaluate of first trimester bleeding.,that its images are recorded and saved in sequence producing (amovie) of the embryo development .
- Ultrasound scanning is a proved to identify sonographic features of early pregnancy failure, ectopic pregnancy, determine the causes of early pregnancy failure and evaluate the accuracy of first trimester ultrasound in diagnosis early embryonic demise.
- Ultrasonography is recommended for the evaluation of patients with pregnancy less than 20 weeks, with threatened abortion or completed abortion and ectopic pregnancy.

References:

Acharya G, Morgan H. First-trimester, three-dimensional transvaginal ultrasound volumetry in normal pregnancies and spontaneous miscarriages. Ultrasound Obstet Gynecol. 2002;19:575–9.

B.Young, J.W Heath: Wheater's Functional Histology, A Text and Colour Atlas. Ultrasound ObstetGynecol .1999; 201:212-225

Baron , Denmark, Erika , Florence. An Exploration of Female Genital Mutilation. Ultrasound ObstetGynecol .2010 ;302:390-397.

Cohen HT, Spiegel DM: Air-exposed urine dipsticks give false-positive results for glucose and false-negative results for blood. J Clin Pathol 96: 398– 400, 1991

Diane U. First Trimester Ultrasound: Obstetric Ultrasound for Viability, Age, and Maternal Health. From Ultrasound in Obstetrics And Gynecology: Textbook and Atlas. Gynecology. 2009 Aug 22;2

Davison JM, Vollotton MB, Lindheimer MD: Plasma osmolality and urinal concentration and dilution during and after pregnancy: Evidence that lateral recumbency inhibits maximal urinary concentrating ability. Br J Obstet Gynaecol 88: 472, 1981

Egger M, Davey Smith G, Altman DG. Principles of and procedures for systematic reviews. Systematic Reviews in Health Care: Meta-Analysis in Context, 2nd edn. BMJ Books: London, 2001; 23–42.

Elson J, Salim R, Tailor A, Banerjee S, Zosmer N, Jurkovic D. Prediction of early pregnancy viability in the absence of an ultrasonically detectable embryo. Ultrasound ObstetGynecol 2003; 21: 57–61.

Goldstein SR. Significance of cardiac activity on endovaginal ultrasound in very early embryos. ObstetGynecol 1992; 80: 670–672.

Hately W, Case J, Campbell S. Establishing the death of an embryo by ultrasound: report of a public inquiry and recommendations. Ultrasound ObstetGynecol 1995; 5: 353–357.

Ismail AA, Kishk SM. Empty gestational sacs diagnosed by abdominal real-time ultrasonography. Eur J ObstetGynecolReprodBiol 1991; 42: 205–209.

Imbasciati E, Surian M, Bottino S et al: Lupus nephropathy and pregnancy. A study of 26 pregnancies in patients with systemic lupus erythematosus and nephritis. Nephron 36: 46, 1984

Kullner JA, D'Andrea NM, McMahan MJ: Renal biopsy and pregnancy. Am J Obstet Gynecol 184: 1093, 2001

Laing F, Mendelson E, Bohm-Velez M, Bree R, Finberg H, Fishman EK, Hricak H, Sartoris D, Thurmond A, Goldstein S. First trimester bleeding. American College of Radiology. ACR Appropriateness Criteria. Radiology 2000; 215: 879–893.

Lim KH, Friedman SA, Ecker JK et al: The clinical utility of serum uric acid measurements in hypertensive diseases of pregnancy. Am J Obstet Gynecol 178: 1067, 1998

Lazarus E. What's new in first trimester ultrasound. RadiolClin North Am. 2003;41:663–79.

Levi CS, Lyons EA, Zheng XH, Lindsay DJ, Holt SC. Endovaginal US: Demonstration of cardiac activity in embryos less than 5.0 mm in crown-rump length. Radiology 1990; 176: 71–74.

Morin L, Van den Hof MC. Diagnostic Imaging Committee, Society of Obstetricians and Gynaecologists of Canada. Ultrasound Evaluation of First Trimester Pregnancy Complications. J ObstetGynaecol Can. 2005;27:581–91.

Nyberg DA, Hill LM. Normal early intrauterine pregnancy: Sonographic development and hCG correlation. In: Nyberg DA, Hill LM, Bohm-Velez M, Mendelson EB, editors. Transvaginal Ultrasound. St. Louis: Mosby-Year Book; 1992. p. 65.

Nyberg DA, Laing FC, Filly RA. Threatened abortion: Sonographic distinction of normal and abnormal gestation sacs. Radiology. 1986;158:397–400.

Pavord S, Hunt B. Normal hematological changes during pregnancy and the puerperium. The obstetric hematology manual. Cambridge University Press2010; 305 : 102–121.

Robinson HP. “Gestational sac” volumes determined by sonar in the first trimester of pregnancy. Br J Obstet Gynecol. 1975;82:100–7.

Scott RF, Featherstone T, Hussey JK. Ultrasound of the empty gestation sac in threatened abortion. ClinRadiol 1987; 38: 127–130.

Takeuchi H. Transvaginal ultrasound in the first trimester of pregnancy. Obstet Gynecol. 2004 Mar 2 ;102:208-301.

Timor-Tritsch IE, Farine D, Rosen MG. A close look at early embryonic development with the high frequency transvaginal transducer. Am J Obstet Gynecol. 1988;159:679–81.

Timothy Jang, Chen JC. Bedside Ultrasonography, First-Trimester Pregnancy: Treatment and Medication. [Updated: May 29, 2009].

Tongsong T, Wanapirak C, Srisomboon J, Sirichotiyakul S, Polsrisuthikul T, Pongsatha S. Transvaginal ultrasound in threatened abortions with empty gestational sacs. Int J GynaecolObstet 1994; 46: 297–301.

Wilcox AJ, Weinberg CR, O'Connor JF, Baird DD, Schlatterer JP, Canfield RE, Armstrong EG, Nisula BC. Incidence of early loss of pregnancy. N Engl J Med 1988; 319: 189–194.

Zamora J, Abraira V, Muriel A, Khan K, Coomarasamy A. Meta-DiSc: a software for meta-analysis of test accuracy data. BMC Med Res Methodol 2006; 6: 31-66.

Timor-Tritsch IE, Farine D, Rosen MG. A close look at early embryonic development with the high frequency transvaginal transducer. Am J Obstet Gynecol. 1988;159:679–81.

Acharya G, Morgan H. First-trimester, three-dimensional transvaginal ultrasound volumetry in normal pregnancies and spontaneous miscarriages. Ultrasound Obstet Gynecol. 2002;19:575–9.

Lazarus E. What's new in first trimester ultrasound. Radiol Clin North Am. 2003;41:663–79.

Takeuchi H. Transvaginal ultrasound in the first trimester of pregnancy. [Last accessed on 2004 Mar 2]. (uptodate)

Morin L, Van den Hof MC. Diagnostic Imaging Committee, Society of Obstetricians and Gynaecologists of Canada. Ultrasound Evaluation of First Trimester Pregnancy Complications. J Obstet Gynaecol Can. 2005;27:581–91.

Diane U. First Trimester Ultrasound: Obstetric Ultrasound for Viability, Age, and Maternal Health. From Ultrasound in Obstetrics And Gynecology: Textbook and Atlas. Gynecology. 2009 Aug 22;2

Timothy Jang, Chen JC. Bedside Ultrasonography, First-Trimester Pregnancy: Treatment and Medication. [Updated: May 29, 2009].

Robinson HP. “Gestational sac” volumes determined by sonar in the first trimester of pregnancy. Br J Obstet Gynecol. 1975;82:100–7.

Nyberg DA, Laing FC, Filly RA. Threatened abortion: Sonographic distinction of normal and abnormal gestation sacs. Radiology. 1986;158:397–400.

Nyberg DA, Hill LM. Normal early intrauterine pregnancy: Sonographic development and hCG correlation. In: Nyberg DA, Hill LM, Bohm-Velez M, Mendelson EB, editors. Transvaginal Ultrasound. St. Louis: Mosby-Year Book; 1992. p. 65.

Robinson HP. Diagnosis of early pregnancy failure by sonar. Br J Obstet Gynecol. 1975;82:849–56.

Appendices:

Ultrasound images:

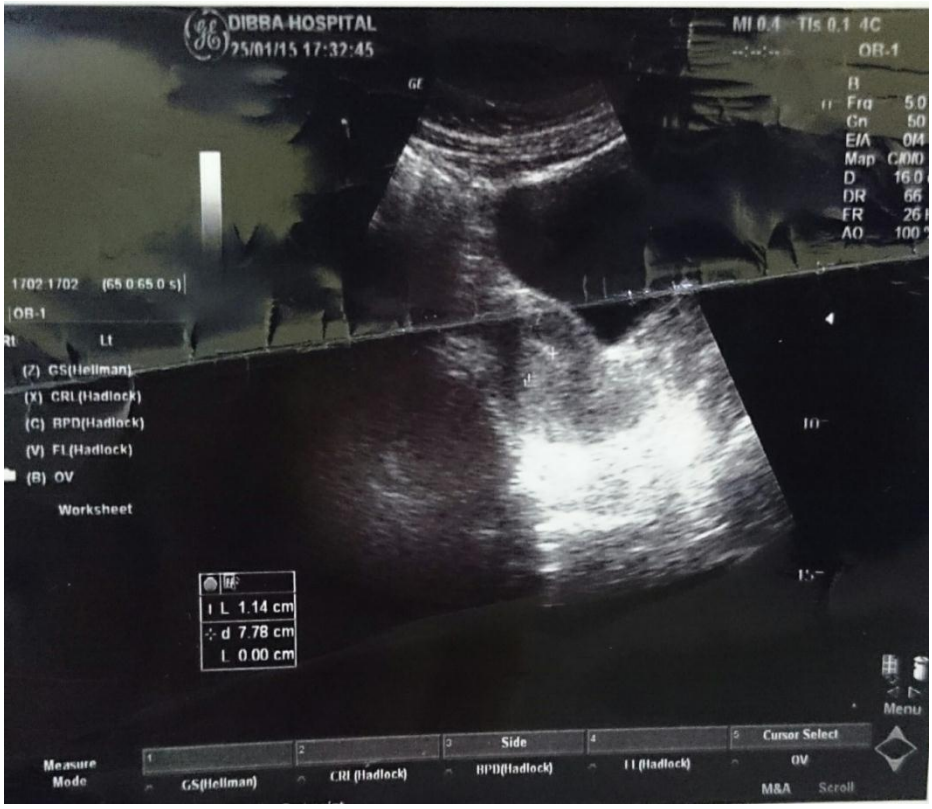

Figure 5-1: Complete abortion for pregnancy woman 33years old with7 W pregnancy and intrauterine gestational sac with a large bleeding and clot

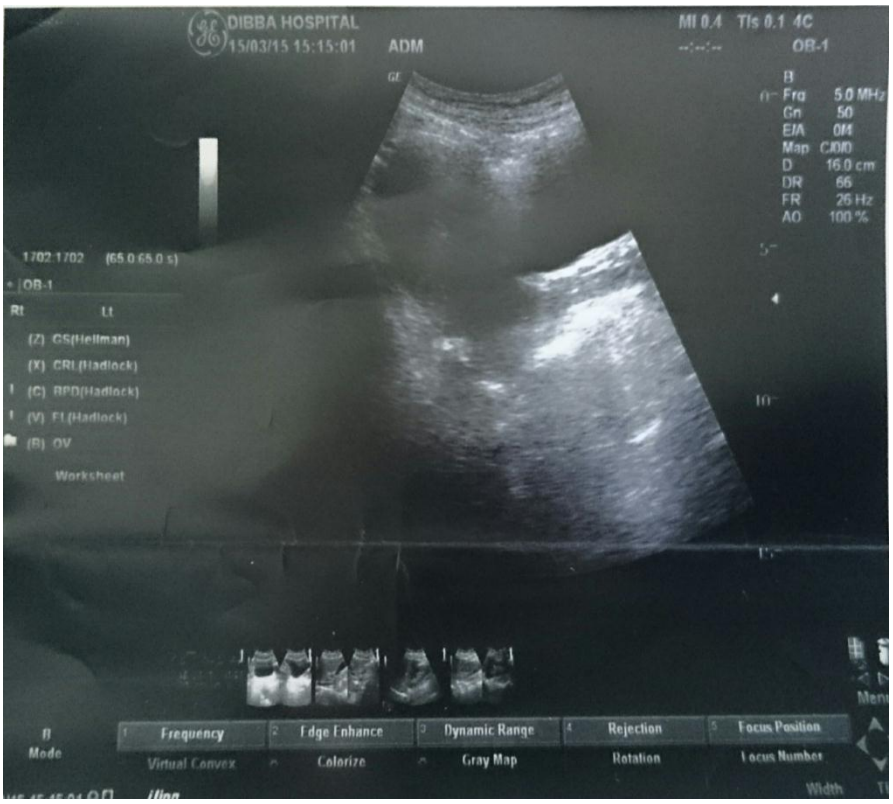

Figure 5-2: Complete miscarriage 6Wpregnancy woman with 25 years old, no heart activity ,she c/o bleeding

Figure 5-3: Incomplete abortion pregnancy ,test positive, patient 6W pregnancy with 23 years old

Figure 5-4:Threatened abortion for 35age Woman 5 W pregnancy with great bleeding and heart activity ,after 5 days repeat the scan bleeding reduced and pregnancy continue.

Figure 5-5: Incomplete abortion pregnancy ,test positive, there is blood in the uterus cavity ,patient 5W pregnancy with 27 years old

Figure 5-6: A 29year old female 5w pregnant and c/o cramping and vaginal bleeding with intermittent pelvic pain, no heart activity ,she have pelvic inflammation

Figure 5-7: A 5w pregnancy with blighted ovum for 30years old female patient with bleeding(no heart activity).

Figure 5-8: Missed abortion of IUP pregnancy for a 22years old female patient c/o bleeding ,and cramping ,with 8w of pregnancy(no heart activity)

Figure 5-9: Ectopic pregnancy of 35years old female patient,6w pregnancy, complain of bleeding and cramping

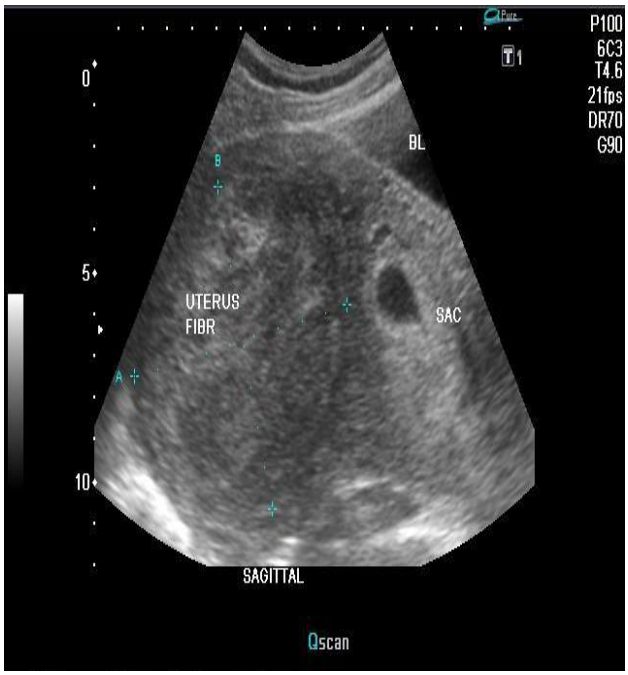

Figure 5-10:A 32years old female patient,6w pregnancy , c/o pleading (with a viable embryo), and a large fibroid in the fundus of the uterus. The mass (FIBR= fibroid), shows absence of degenerative changes or calcification ,despite its large size (8 x 9 cms.). Power Doppler image of the uterus shows rim of vessels around the fibroid. Such early pregnancies with large fibroids have a high risk of abortions.