Chapter one

1.0 Introduction:

Ultrasonography is the use of a high pitched sound to visualize the inside of a human body, sound of a frequency less than 20 KHz is audible, however, A sound more than that is called ultrasound. Ultrasound waves are sending through a probe when it strikes the tissue an echo will come back to the machine that process it and form the I e.

Abortion is a failure of pregnancy to continue before 28 weeks gestation, it is classified to many types according to the signs and symptoms. The here is about the threatened abortion, which is appearing as vaginal bleeding and lower abdominal plan.

We will use quantitative research method to conduct our study.In pelvic pain first trimester by using medical ultrasound.Our study conducted in Saudi and maternity hospitals between May to August 2013. However our population and samples size is selected randomly. We developed our questionnaire and delivered to 72 seventy two patients with pain, bleeding, and watery discharge.

1.1 The scope of the study:

The scope of this study is about pelvic pain in the first trimester. The nine month full term pregnancy is sectioned by the obstetricians into three trimesters. Three month each. We will use quantitative research method to conduct our study.

1.2 The problem statement:

The real maternal and fetal death statistics is not available, and abortions of different types are one of the causes of it. And one of the main causes is the pelvic pain in first trimester. The study will conduct to explore and determine this cause to save the woman and fetus during the period of pregnant.

1.3 Research hypothesis:

.Exploration and treatment of the causes of pelvic pain in first trimester by using ultrasound lead to normal pregnancy and available fetus.

1.4 Research objectives:

1.4.1-General objectives:

To study the causes, the symptoms as well as the end results of pelvic pain using ultra sound in the first trimester.

1.4.2- Specific objectives:

1- TO evaluate the uterus ultrasonography and fetal situation.
2- TO evaluate the presence of any clinical signs.
3- TO correlate between the ultrasound findings with patients age and clinical data.

1.5 Significance of the study:

Nowadays both the mother and the fetus are at risk in cases of pain / bleeding / watery discharge in the first trimester. To minimize the morbidity and mortality in both, expert qualified sonographer is important to be there in the obstetrics and gynecology department. To diagnose the pelvic pain and to deal with it, as well as to prevent it from continuing to a complete

one by giving good follow up and early helping information’s to the treating doctor , this study is conducted.

1.6 Over view of the study:

This proposal consist of seven chapters, the first one is an introductory words about the definitions and literature of the topic under the study. The second chapter gives an idea about the problem that needs a solution. The objectives necessary for the leader to understand the aim of the study and for the researcher to collect the data are enumerated in the third methods are discussed. The fifth chapter inform about the overview of the proposal written and the references used to collect the information of the subject under the study.

Chapter Two

2.0 Anatomy of the uterus

2.0.1 The uterus:

The uterus is a hollow, pear-shaped muscular organ which is approximately 7.5 cm length, 5 cm in width and 2.5 cm thick. It is divided, for descriptive purposes, into two parts: the body of the uterus. And the cervix of the uterus.

On the lower part of the uterus there is a slight constriction which marks the site of a narrowing of the cavity of the uterus called the internal OS. The portion of the uterus above this constriction is the body of the uterus and the portion below is the cervix.

The rounded upper part of the body of the uterus, above the site of entry of the uterine tubes, is called the fundus of the uterus, below this portion the body gradually narrows down to its junction with the cervix. The cavity of the body of the uterus is roughly triangular in shape. The apex of the triangle lies at the internal OS and the lateral angles at the site of the entry of the uterine tubes.

The cervix of the uterus is about 2.5 cm in length. It is narrower than the body of the uterus and is roughly cylindrical in shape. The cavities of the cervix uteri are wider in its middle part than above or bellow. The opening of the cavity of the cervix into the uterus is called the external OS. The lower part of the cervix protrudes into the anterior wall of vagina.

The long axis of the uterus shows a slight curve, which is concave interiorly. This is called anterflixion. The uterus is usually turned forward and lies o

n the superior surface of the bladder. This is called ante version.(Bchiri DMRD 1987).

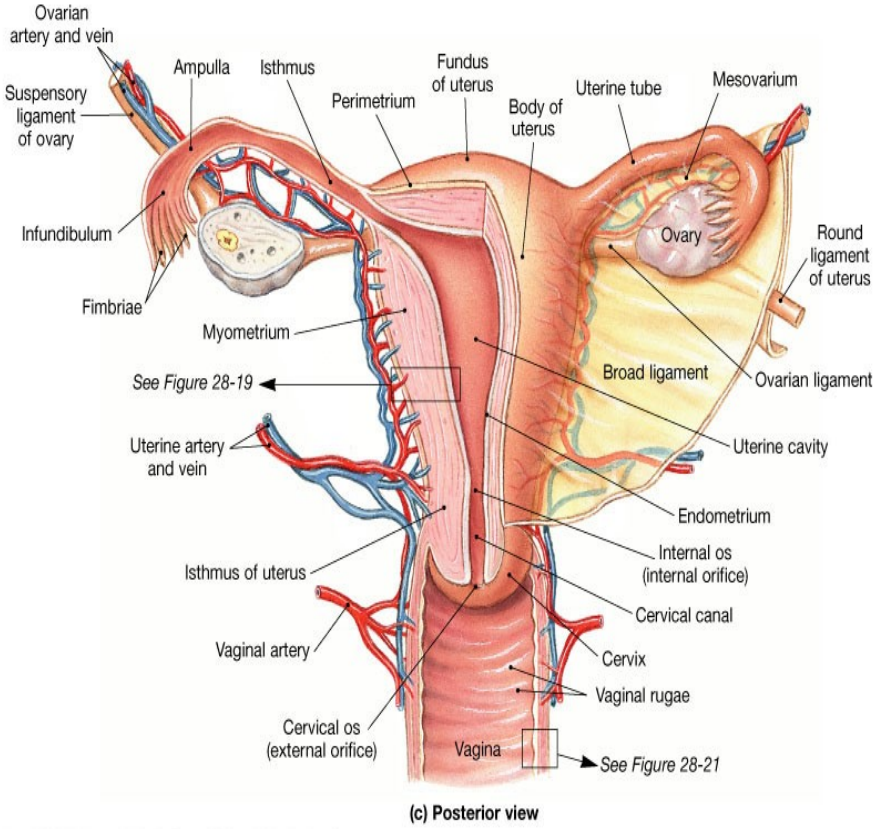

Figure 2.1 Uterus

2.0.1.1 The structure of the uterus:

The wall of the uterus is composed of three coats.

1. An outer serous, or peritoneal, coat covers the body of the uterus and the posterior surface of the portion of the cervix which lies above the vagina.

2. A middle muscular coat, called the myometrium, forms the main bulk of the uterus it is composed of bundles of smooth muscle fibers. During pregnancy this muscular coat becomes greatly thickened.
3. An inner mucous membrane of the uterine tubes above and with the mucous membrane of the vagina below. In the body of the uterus the mucous membrane is lined with columnar epithelium and contains numerous glands, called the uterine glands.

2.0.1.2 The ligaments of the uterus:

The uterus is supported by several ligaments:

- The broad ligaments are folds of peritoneum which pass from each side of the uterus to the lateral walls of the pelvis. The uterine tube lies in the free edge of the broad ligament.
- The round ligaments are two narrow bands of fibrous tissue which are attached to the uterus just below the uterine tubes. They run laterally, between the layers of the broad ligament, to the lateral walls of the pelvic. Having reached the lateral pelvis walls, they pass forwards through the inguinal canals to the vulva, where they blend with the adjacent areola tissue.
- The anterior and posterior ligaments are folds of the peritoneum which are attached to the bladder and the rectum respectively . Two bands of fibrous tissue run backwards on either side of posterior ligament, and attach the cervix to the sacrum.

2.0.1.3The blood supply to the uterus

The uterus receives arterial blood from the uterine arteries, which are branches of the internal iliac arteries, and from branches of the ovarian arteries.

The venous blood from the uterus drains into the ovarian veins and the uterine veins.(Bchiri DMRD 1987).

2.0.2 The vagina:

The vagina is a fibro muscular canal, about 7.5 cm in length, which extends from vulva to the uterus. It runs upwards and backwards, behind the bladder and urethra and in front of the rectum and anal canal. The long axis of the vagina forms an

angle of 90 degree or more with the long axis of the uterus its anterior and posterior walls are normal in contact. The lower part of the cervix uteri protrudes into the anterior wall of the vagina. The recesses in front and at the side are called the anterior and lateral furnaces respectively.

2.0.2.1The structure of the vagina:

The vagina is composed of three coats:

- An outer coat of loose areole tissue, which contains vessels and nerves;
- A middle coat of smooth muscle fibred;
- An inner coat of mucous membrane, which firmly attached to the muscular coat. The surface of the mucosa is thrown into a number of folds. Called reggae, and the inner linings is of stratified squalors epithelium.

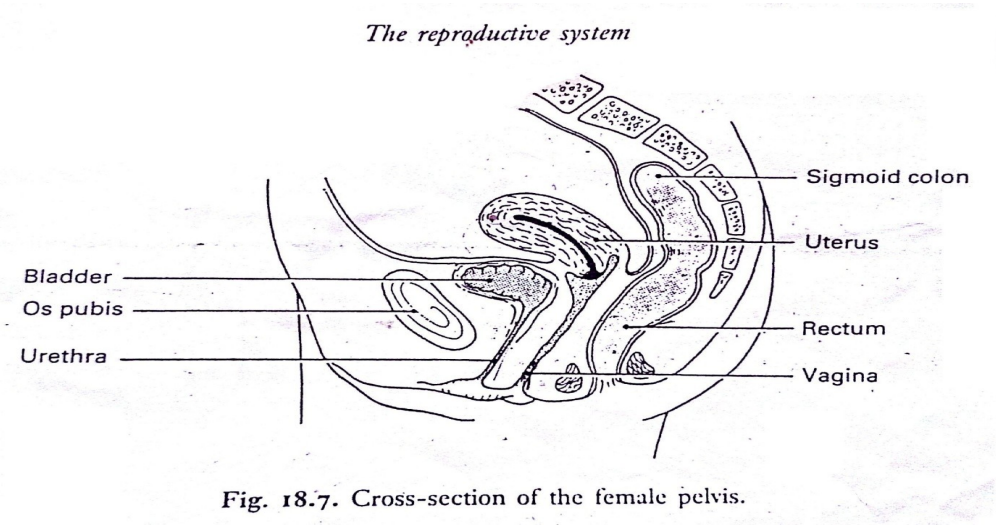

Figure 2.2 vagina

2.0.2.2 The blood supply to the vagina:

The vagina is supplied with arterial blood by branches of the internal iliac arterial. The veins of the vagina drain into the internal iliac veins.

2.0.2.3 The lymphatic drainage of the vagina:

The lymphatic vessels from the vagina pass mainly to the internal and external iliac groups of lymphatic nodes. The lymphatic vessels from the lower end of the vagina, however,

pass to the superficial inguinal lymph nodes.(Bchiri DMRD 1975).

2.0.3 The vulva:

The vulva is composed of the mom’s pubis, the labia major and minor, the editors, and the vestibule of the vagina, the hymen and the greater vestibular glands.

The moms pubis: is rounded eminence, in front of the pubic syphilis. It is formed by a collection of adipose tissue beneath the skin.

The labia major: are two longitudinal folds of the skin which extend down wards the from moms pubis. they form the lateral boundaries of the vulva and

They fuse posteriorly about 3cm in front of the anal canal. they possess large number of sebaceous glands on their inner surfaces. The labia minora are tow smaller longitudinal folds of skin which extend downwards and backwards on either side of the vagina. they contain large numbers of sebaccous glands on their surfaces . The labia minora each divide anteriorly into tow folds which enclose the clitoris. The clitoris is equivalent to the male penis and contains erectile tissue. it is suspended by a ligament from the pubic symphysis and is enclosed in the upper portions of the labia minora. The urethra, the vagina and the ducts of the greater vestibular glands open into the vestibule.

the hymen is a thin folds of mucous membrane which, in the virgin state, partially occludes the orifice of the vagina.

the greater vedtibular glands are tow oval shaped glands which lie one on either side of the vagina / they secrete mucus which lubricates the vagina .

the blood supply of the vulva:

the vulva is supplied with arterial blood by branches of the internal iliac and femoral arteries . the veins from the vulva drain into the internal iliac veins.

the lymphatic drainage of the vulva:

the lymphatic vessels from the vulva drain into the superficial inguinal lymph nodes. (Bchiri DMRD 1987).

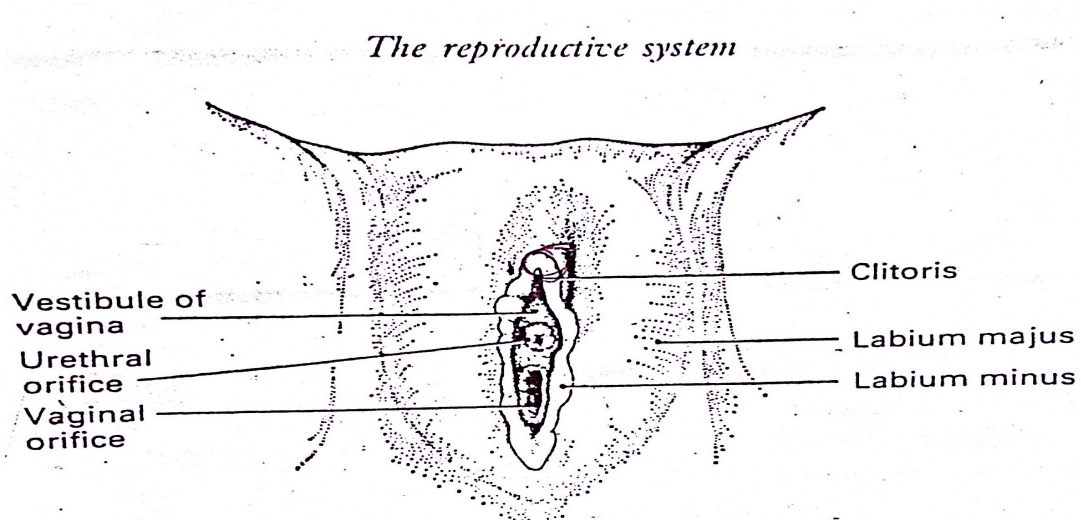

FIGURE 2.3 vulva

2.0.4 The ovaries:

The ovaries are the female sex glands and they lie , one on each side of the uterus , on the lateral wall of the true pelvis. each is attached to the upper layer of a peritoneal fold, called the broad ligament of the uterus , and lie below and behind the lateral end of the uterus tube. each ovary is about 3cm in length , 1.5cm in width and 1 cm thick . the ovaries are almond-shaped and greyish pink in colour . each ovary is attavhed to the broad ligament by afold of peritoneum called the

mesocarium. between the tow layers of this fold vessels and nerves pass to the hilum of the ovary.

2.0.4.1 The structure of the ovary :

the medulla is composed of connective tissue which contains large numbers of elastic fibres and many blood vessels.

the cortex of the ovary has an outer layer of cuboidal epithelium called the germinal epithelium . beneath this is a connective tissue framework , or stroma , which contain the ovarian follicles and corpora lutea. the thikness of the cortex varies according to age . before puberty the cortex is relatively thin and contains numerous primary ovarian follicles . after puberty one, or occasionally more , of these follicle matures and releases an ovum during each menstrual cycle .

the primary follicle is composed of a large central cell , called the oogonium , surrounded by a single layer of cuboidal cells, called the follicular cells. when development of this primary follicle begins, the follicular cells increase in number to form several layers and fluid collects between the cells to form a cavity . the follicular cells are now divided into tow groups, an outer layer of cells called the membrane granulosa and an inner layer of cells which contains the ovum . while these changes are occurring the oogonium matures to form the ovum. the mature follicle , now called a graafian follicle , approaches the surface of the ovary and rupture , releasing the ovum into the peritoneal cavity , whence it enters the uterine tube. after the release of the ovum the remaining cells of the graafian follicle increase in size and a pigment , called lutien , becomes deposited in their cytoplasm . this new structure ,

called the corpus luteum , becomes vascularized and, if fertilization of the ovum dose not occur, remains like this for 13-14 days . after this it gradually degenerates and is replaced by fibrous tissue . this fibrous remnant is called the corpus albicans. if fertilization does occur, however, the corpus luteum remains intact throughout pregnancy .

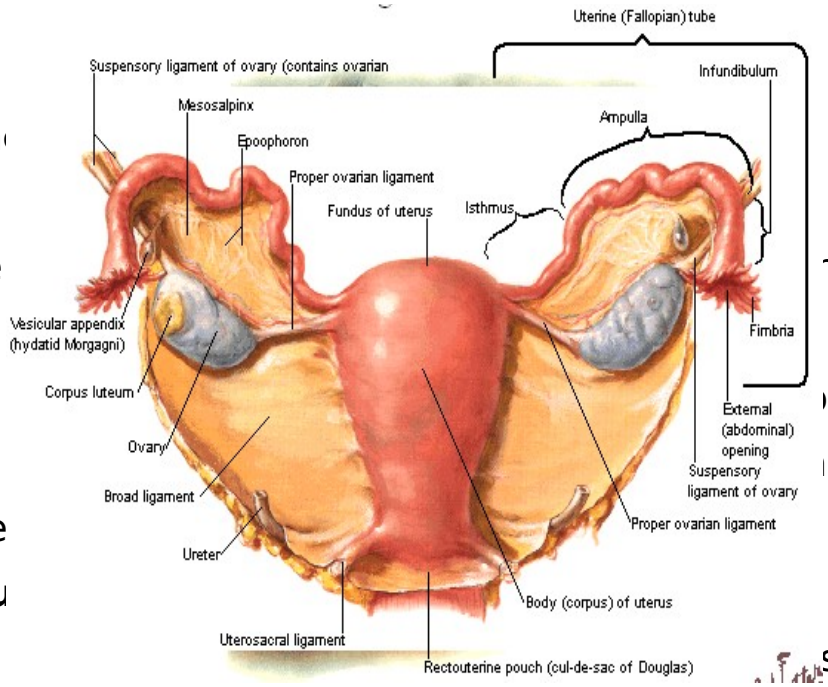

2.0.4.2 Th

the ovaries arteries which arise ne renal arteries .

the venous lexus of veins inthe ed from there by the

2.0.5 The u

the uterine s of the broad ligaments of the uterus . they are each about 10cm in

length and they serve to transmit the ovum from the ovary to the uterus. each runs medially from the lateral wall of the pelvis to the upper part of the uterus .they are divided , for desciptive into four parts:

- The infundibulum is the outer expanded portion of the uterine tube which opens into the peritoneal cavity. the mouth of the opening is surrounded by a number of finger-like processes called the fimbriae .
- The ampulla is the widest portion of the uterine tube. it runs a tortuous course and is about 5cm in length.
- Isthmus is the medial cord-like portion of the tube which lies between the ampulla and the uterus.
- The uterine portion is about 1cm in length and is the part of the tube which runs through the uterine wall.

2.0.5.1_The structure of the uterine tubes:

the uterine tubes are composed of three coats:

1- an outer serous coat, which is the peritoneal covering;
2- a moddle muscular coat, which is composed of an outer layer of longitudinal and an inner layer of circular smooth muscle fibers;
3- an inner layer of mucous membrane, which lies in longitudinal folds and is covered by a layer of ciliated epithelium.

ovarian vein passes upwards to enter the inferior vena cava just below the right renal vein . the left ovarian vein passes upwards to enter the left renal vein.

The lymphatic drainage of the ovary :

The lymphatic vessels from the ovary pass upwards. Alongside the ovarian vessels, and drain into the lateral aortic and preaortic lymph nodes.(Bchiri DMRD 1975).

2-1 Physiology of the uterus:

The function of the female reproductive organs:

The ovaries at birth contain oocytes which are the forerunners of the ova.

After the birth on new oocytes are formed. This is in contrast to spermatogenesis in the male which does not begin until puberty.

The onset of menstruation {the menarche} is caused by hypothalamic stimulation of the anterior pituitary to secrete LH and FSH in a cyclical fashion. The stimulation of the ovary by these tow hormones causes the development of the female reproductive organs and initiates menstruation. Menstruation then continues at regular intervals until the menopause. as in the male, the precise mechanism causing the hormonal changes which result in puberty remains obscure .

2.1.1 The menstrual cycle:

The menstrual cycle consists of a series of changes which occur in the female throughout the reproductive years and which generally result in ovulation. During each cycle one ovum {or occasionally tow ova} is released from the ovary and changes occur in the uterine lining, the endometrial, in preparation for pregnancy should fertilization of the ovum occur. The cycle lasts on average 28 days and is divided into three phases: the proliferative or follicular phase, the secretors or luteal phase, and menstruation .the changes of the menstrual cycle are due

to a series of intricate and reciprocal hormonal changes brought about by the ovary and pituitary.

The first day of the menstrual cycle is the day on which menstrual blood loss begins , but for case of description the follicular phase will be considered first .

- the follicular phase : during this part of the menstrual cycle pituitary secrete of FSH send LH stimulation the development of an ovarian {grafian} follicle which secretes estrogens in increasing amounts. The rising estrogens concentration stimulates proliferation of the endometrial. From the 6th to the 14th of the cycle, the glands , blood vessels and Struma increase causing the endometrial to double in thickness . on the 14th day , shortly after a shape peak of LH and FSH secretion , ovulation occurs . the ovarian follicle ruptures onto surface of the ovary and the mature ovum is released briefly into the peritoneal cavity before it is rapidly swept into yhe ampulla of the uterine duct.
- the luteal phase starts at the 15th day of the cycle . the high circulating oestrogen concentration suppresses the secretion of FSH thus allowing only one follicle to develop. in women treated for infertility by ovulation induction with gonadotrophic hormones this does not occur . and multiple follicles may develop resulting in a multiple pregnancy . the the corpus luteum secreted progestrone , which causes a further increase in cndometrial thickness due to growth of the glands which start to secrete. the arteries of the endometrium become tortuous and exudation of fluid and

blood into the endometrium occurs . these changes are in preparation for inmplantation of a fertlized ovum.

- menstruation: if fertlization of the ovum dose not occur, the corpus luteum regresses , the levels of oestrogen and progesteron fall , LH and FSH levels start to rise again in preparation for a furthet cycle , and the superficial part of the endometrium is shed . the flow of blood , mucu and cast-off endomitrium from the uterus is called the menstrual flow [menses] and lasts about four to six days.(Bchiri DMRD 1987).

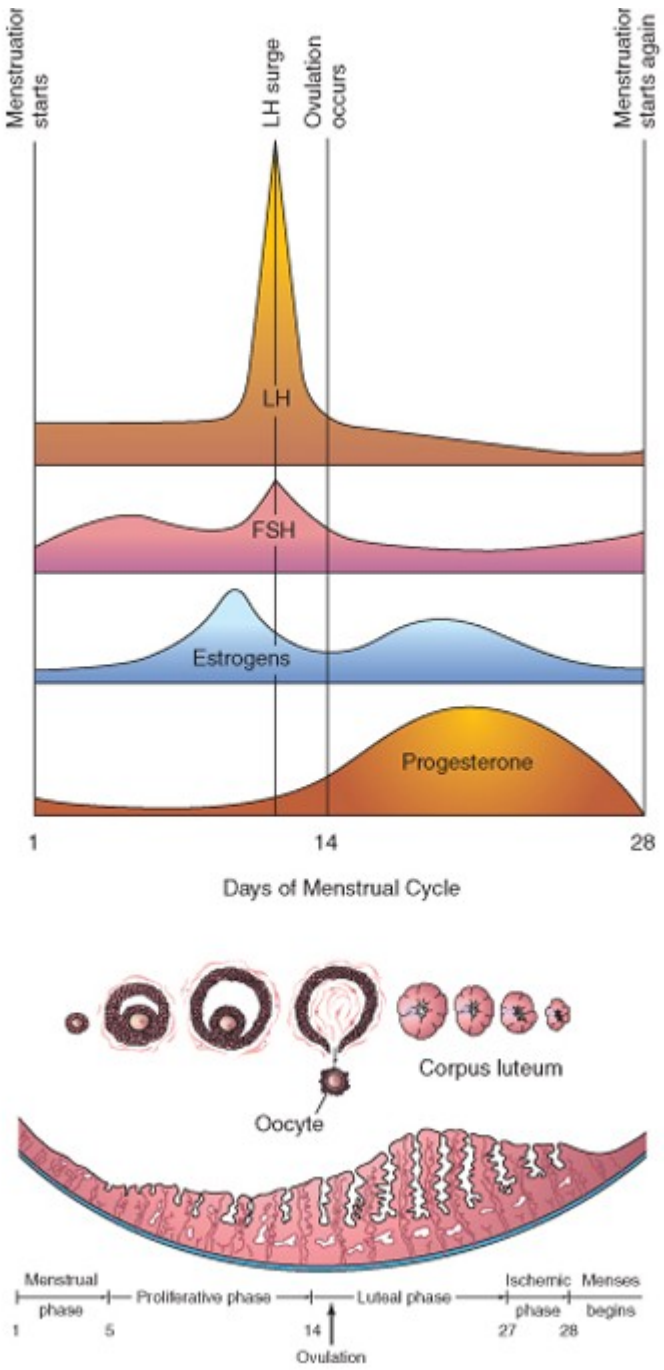

Figure 2.5 Menstrual cycle

2.1.2 Pregnancy :

if the ovum fertilized , which usually occurs in the ampulla of the uterine tube , the corpus luteum does not degenerate and the endometriom is not shed . cell division of the fertilized ovum proceed and after about seven days, when the blastocyst has grown to 200 cells , itbecomes implanted into the intact endomitrium . after implantation the trophoblast secretes chorionic gonadotrophin , which is very similar to LH and this prolongs the life of the corpus luteum .This causes continued ovarian secretion of oestrogen and progesterone which necessary for the maintenance of pregnancy . the placenta later becomes the main site of progesterone production which continues until the ens of pregnancy , when it dcclines prior to the onset of labour . after about ten weeks the placenta starts to secret placenta lactogen , a hormone which resembles growth hormone and prolactin , the secretion of this hormone increase steadily until term is reached and is necessary for the growth and development of the breast and the fetus . the secretion of chorionic gonadotrophin however , rises to a peak at ten weeks and then falls rapidly to a steadly level at which its secretion continues until term. the presence of this hormone in urine from the basis for all diagnostic tests of pregnancy. (Bchiri DMRD 1975).

2. 2 Pathology of the uterus

Pain is the discomfort you experience in the lower region of the abdomen and within the pelvis. This pain can be acute or chronic. Intermittent or chronic and may ranges from mild, moderate to severe. People with pelvic pain often find the pain

radiating towards their lower back. Hips and thigh region when one suffers from pelvic pain for mane thon 6 months. It’s called as chronic pelvic pain. When the pain occurs suddenly, it is referred to as acute pelvic pain.

2.2.1 Causes pain in the pelvic organs

There are a number of reasons for pelvic pain sometimes, multiple reasons lead to pain in the pelvis, and these reasons include:

Appendicitis – inflammation or infection of the appendix can lead to sudden pain in the right side of pelvis region.

- Colon cancer of the large intestine can lead to pelvic pain.
- Irritable bowel syndrome (IBS) – IBS can cause bloating. Constipation, diarrhea and cramps in the abdomen pelvic region.
- Crohndisease – the inflammation of the linnet of the digestive tract can lead to pain in the abdomen and pelvic vision.

2.2.1 Gastrointestinal causes of pelvic pain:-

- Acute appendicitis is most common, crohn’s disease can also be cause of pelvic pain in pregnancy, when arelaps of crohn’s occurs during pregnancy, it typically occur during the first trimester. We needed another modality such as MRI or CT. (Chiang .G.Levine D.Swire M etal 2004)

2.2.2 Pelvic inflammatory diseases (PID)

this is an infectious inflammatory disease that occurs due to complication of gonorrhea (SID). The pain radiates into the abdomen causes abnormal vaginal discharge and painful aviation and intercourse cause fluid in COLELE sac adenixia

area. Kidney stores – when tiny stores from the kidney pass through the waters. They cause intense pelvic pain.\

2.2.3 Interstitial cystitis (IC)

Pain and pressure in the mid pelvic area maybe a sign of interstitial cystitis (IC). It causes a sudden urge to urinate, pain during urination and intercourse.

1. Pelvic congestion syndrome – this is a condition where pelvic pain arises due to low blood flow in the pelvic veins. The pain increases while sitting on standing.

*(fibromyalgia) here, a person suffers home pain all over the body. This condition is more common in women they men. There is no curve for fibromyalgia

*prostitutes – the swelling and inflammation of the prostate gland in men can lead to pelvic pain.

(Ulcerative colitis) – Another common type of IBO, ulcerative colitis can lead can lead to long. Term inflammation of the digestive treats casing pelvic pain

(Inguinal hernia)- When the part of the abdominal membrane or intestine. Protrudytvogh another weak point in the abdomen, it can lead to inguinal hernia. The bulge that becomes large with time can lead to pelvic pain.

These were some of the common reasons of pelvic pain affecting men and women.

This causes sudden pain for a few minutes to few hours in the pelvic vegion.(Yehhc good man, Carrl etal 1986).

2.2.4 Premenstaval syndrome

(PMS) the pain and discomfort experience before the start of the monthly menstrual cycle is called of (OSPMS) .pelvic pain be apart of the discomfort experienced during his period.

2.2.5 menstrual cramps:

Pain and cramps experienced during the first few days of menstruation may also include pelvic pain.

+ Ovary influndbula. This can lead to severe abdomen and pelvic pain.

2.2.6 pelvic organ prolapsed

_ when the bladder or uterus slips into a lower position or protrudes outside the uterus, it is called pelvic organ prolapsed. This leads to pressure _ like pelvic pain.

2.2.7Abdominal adhesions

_ After undergoing a surgery such as C.sehction .appendectomy or hysterectomy, scar tissues may form. These scars tend to cause other organs in the abdomen to stick together tightly leading to abdomen and pelvic pain.

2.2.8Miscarriage

- Women who suffer for spontaneous abortion may experience pelvic pain during the sudden loss of pregnancy. Also there are some types of abortion – threatened, complete, incomplete, inevitable, and missed abortion.

2.2.9 Types of abortions:

Spothrroneous abortion or miscarriage

It’s a type of abortion that occurs without medical or other intervention?

2.2.9.1Threatened abortion :

Is a condition of pregnancy, occurring before the 2oth weele of gestation, the patient usually experiences vaginal bleeding with or without some cramps, and the eervix is closed bed rest is usually the only treatment needed.

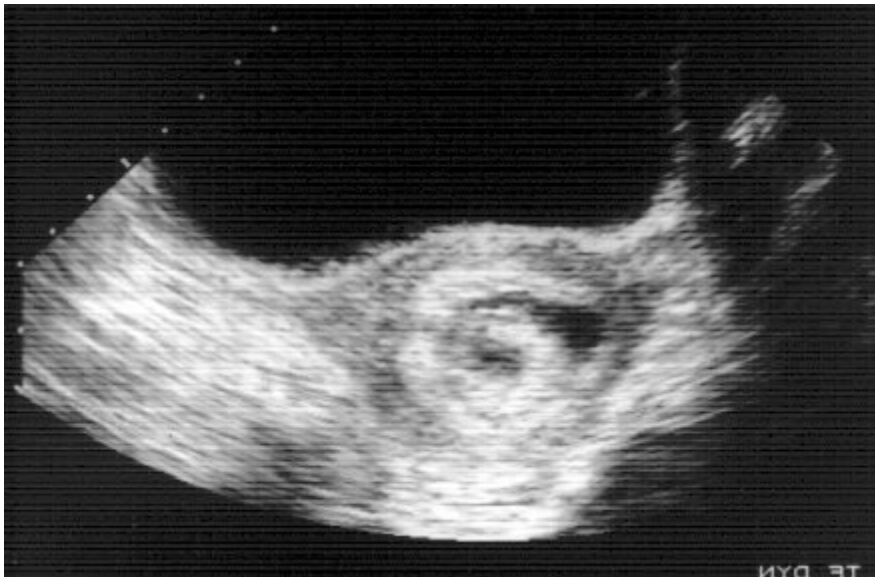

Figure 2.6

Sonographic appearance:

- vaginal spotting/bleeding, mild uterine cramping, closed os.
- may see intrauterine hematoma
- if viable gestation, just observe.

2.2.9.2 Inevitable abortion :

Is when the continues and becomes heavy, it usually means that the cervix is dilating and the contents of the uterus are being expelled.

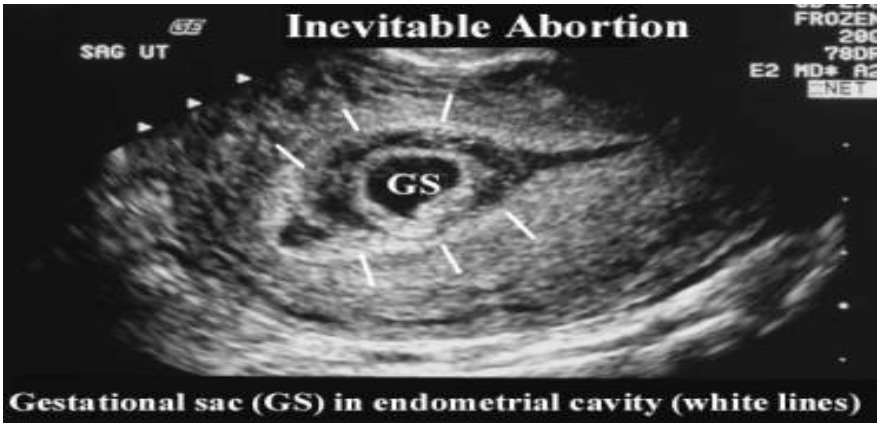

Figure 2.7

Sonographic appearancr :

-gestational sac in endometrial cavity (white lines)

- heterogenous echogenicity within the uterus, representing an embryo.

-The cervical canal is dilated.

2.2.9.3 Complete abortion:

Is when all the contents are expelled. There is no treatment needed.

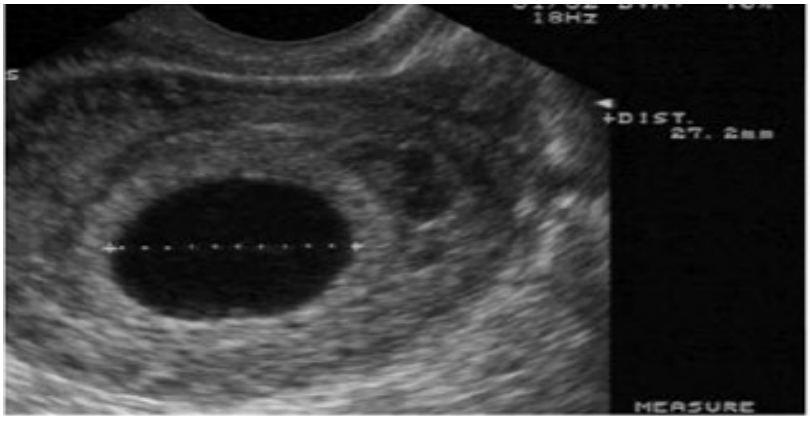

Figure 2.8

Sonographic appearance:

-uterus bulky.

-empty uterus.

- all products of conception have been expelled, os closed

2.2.9.4 Incomplete abortion:

Is a name seven to abortion where the uterus retains part or the entire placenta, (bleeding may occur).

Figure 2.9

Sonographic appearance :

-The gestational sac may be misshaped or collapsed.

-The gestational sac may be intact, containing a nonliving embryo.

- an irregular complex mass within the endometrial or endocervical canal may be present.

-Echogenic material or debris within the endometrial canal may represent retained products of conception or clotted blood.

2.2.9.5 Missed abortion:

Is case which an intrauterine pregnancy is present but no longer developing normally, missed abortion is usually indicated by the disappearance of the signs of pregnancy ept for the continued absence of menstral periods. Missed abortion usually treatmened

Fig anceure 2.10

Sonographic appearance:

-A CRL of ≥7 mm without a heart beat,

-Abnormal hyperechoic material within the uterine cavity and an irregular gestational sac.

Induced abortion: This type of abortion uses drugs.

1. Uterine body is divided into two, with normal cervix and tubes.

2. Inter uterine drvicer IUD:- maybe brolcea and fragment into uterine myometral lyer also multi load loop (metallic new type to both fallopian tube
3. Hydatidiform mole after dilation – (mole pregnancy).
4. Uterine myomas:-

U/S mucosal, intramural.

5. Endometrial hyperplasia:

Thiclcened endometrial mucosa.

2.2.10 Molar pregnancy:

Can be associated with pelvic pain because of either the rapid change in size of the water ours, the size of the associated theca lutein cysts ov torsion of the ovaries caused by theca lutein cysts. The classic Sonographic appearance of a complete mole has multiple cystic spaces represses sting hydrospace villa. Other appearance that can be seen in first trimester include an intrauterine an eddied fluid collection similar to gestational sac. Fluid complex collection.(Yehh 1999).

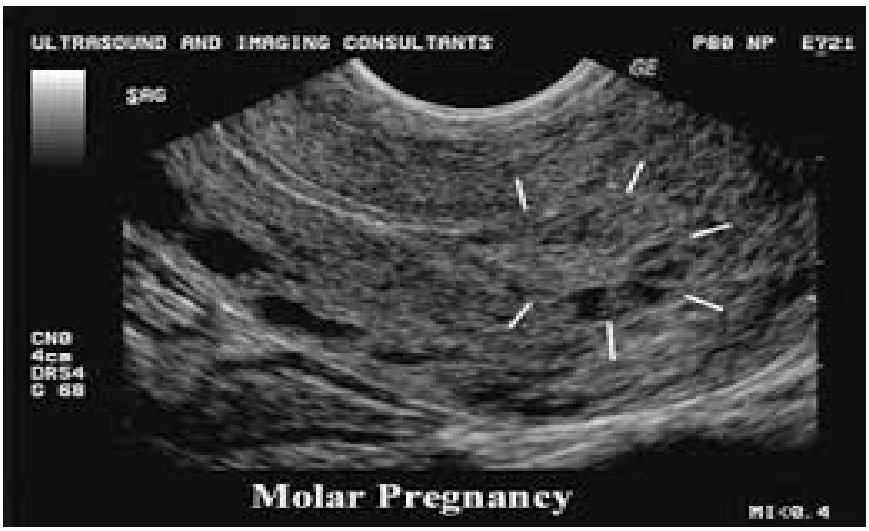

Figure 2.11

Sonographic appearance :

A complex echogenic mass containing small irregular cystic spaces is partially surrounded by a crescentic fluid collection within the endometrium.

2.2.11 Corpus luteum:-

The corpus Latium is the most common adenixia mass in pregnancy, and is common cause of pelvic pain the pain lateralized to side of the cyst. Pain can be due to the size of the cyst, bleeding within the cyst, torsion, or rupture, the cyst is typically less than 6 cm in diameter.

2.2.12 Ectopic pregnancy:

When an embryo grows outside the uterus. It can lead to sharp and intense pelvic pain, the areas of adenixia, lateral fallopian type: - ovary + infludbula + isthmus + uterine, RORE in abdominal cavity. Cause pseudo sac + fluid (cull de sac).

Symptoms of an ectopic pregnancy are pelvic and abdominal pain and menorrhea, vaginal SPOHING or bleeding maybe present.

Abdominal

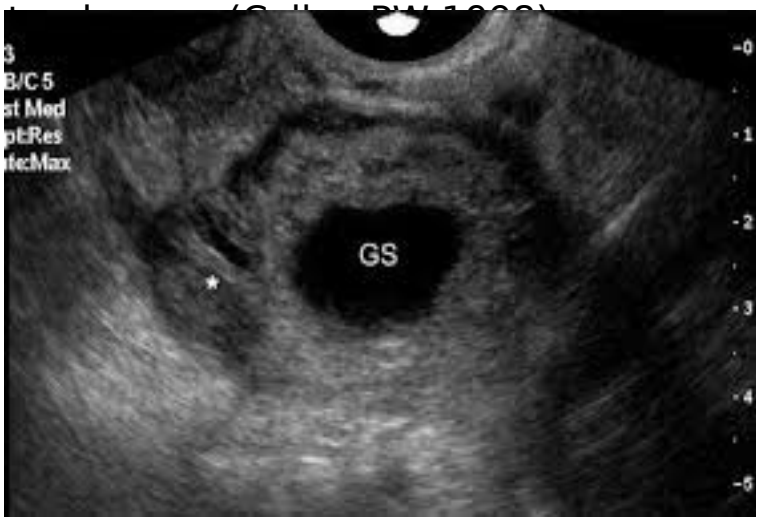

Figure 2.12

.Sonographic diagnoses of ectopic pregnancy:

Endometrial findings:

Small fluid collections without an echogenic rim can be present; this fluid collection represents blood in endometrial cavity. (Pseudo sac also). Used transvaginal probe.

Use of color Doppler in diagnoses of ectopic pregnancy (Ring of fire):

2.2.13 Scar pregnancy:

Scars in the uterus can be sites for implantation of pregnancy.

Ovarian hyper stimulation:

Ovarian hyper stimulation is diagnosed the presence of abdominal pain. Enlargement ST Ovary greater than 5 cm. and as cites or hydrothorax.

2.2.14 fibroids

Uterine fibroids are commonly found during pregnancy. In consistency of uterine size and gestational dates in pregnant patient who has acute abdominal pain maybe the first sign of leiomyoma – fibroid during pregnancy occasionally undergo red degeneration that is caused by hemorrliagic infarction. Symptom focal pain.

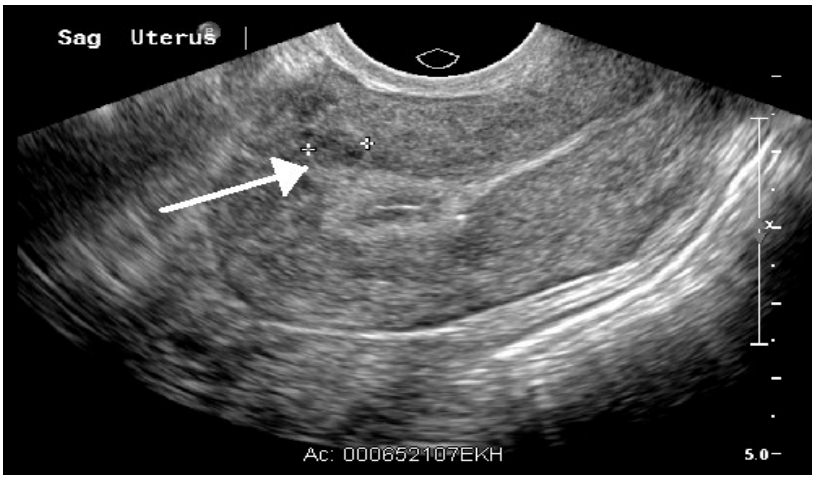

Figure 2.13

Sonographic appearance:

-Well defiend round or ovale in shape.

-Hemogenous in texure.

-Hypoechogenic nodular or masses

Diagnoses of pelvic pain:

Pelvic pain is diagnosed tests for pelvic pain includes: blood test + Na sound lapars copy sigmoid OS copy CT scan MRI.

2.2.15 Blighted ovum

blighted ovum (an embryonic pregnancy) is the term form an abnormal pregnancy in which the embryo either develops abnormally or has failed to develops the gastational sac may develop normally even with out any embryo in the uterus . a yolk sac is usually present . but occasionally is absent . Although the etiology is unknown , the major abnormality of a blighted ovum is an abnormal karyo type (primarily aotusomal trisomy , triploidy ,or monosomy x) the incidence of blighted ovum in spoteneous abortion ranges from

50-90% .(Yehh good man,Carrl etal 1986).

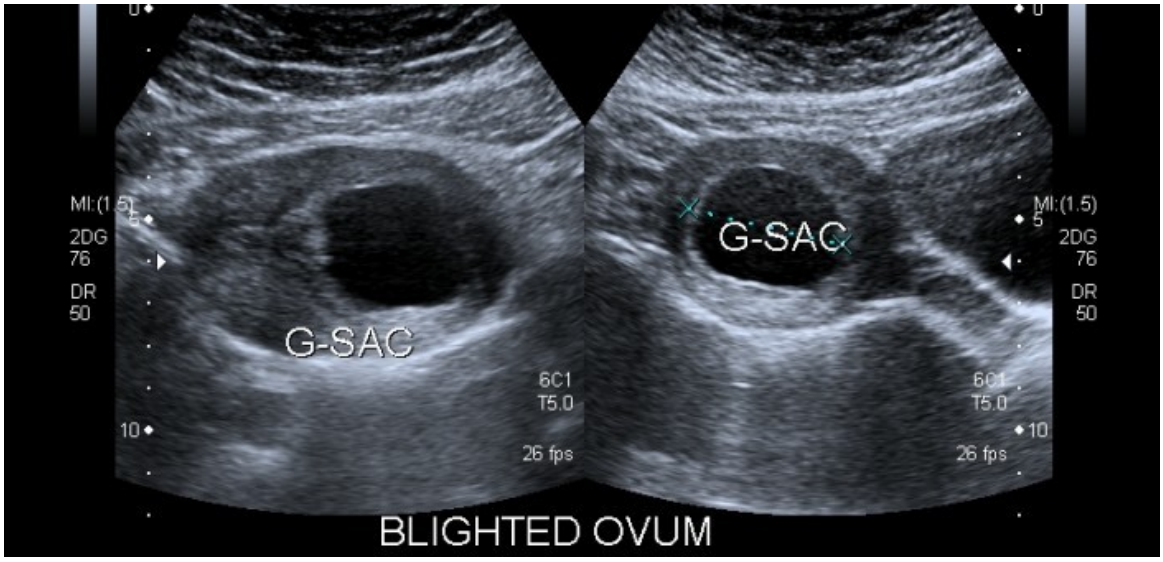

Figure 2.14

Sonographic appearance:

In the uterus there was a single intrauterine gestational sac but a fetal pole

was not visualized.

2.2.16 Ovarian cysts

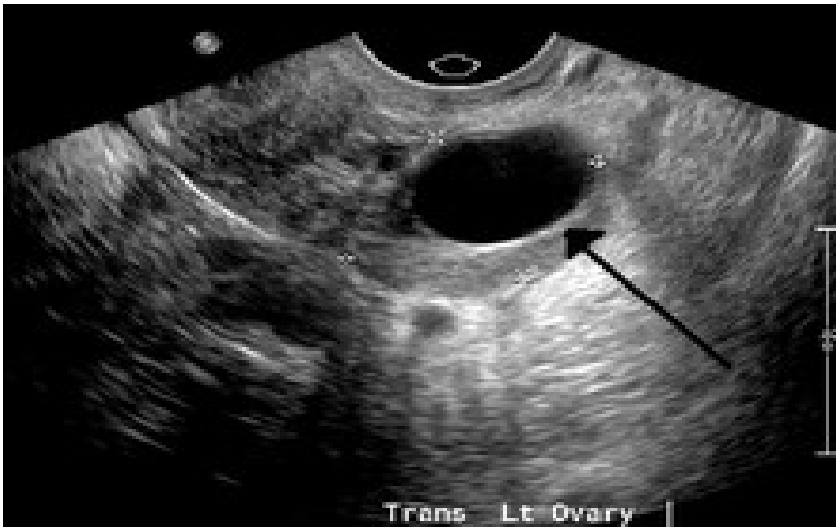

Figure **2.15**

Sonographic appearance:

-well defined thin walled cystic lesion.

- No internal echoes or debris**.**

-ovale or round in shape.

2.2.17 Others:

Hydro salpania, Abscess, Uterine anomaly ,Ovarian masses

2.3 Previous studies

Falco P, Zagonari S, Gabrielli S et.al7.2003 did a prospective observational cohort study on 50 patients to evaluate the outcome of pregnancies with first-trimester bleeding and a gestational sac less than or equal to 16 mm without a demonstrable embryo. Results suggested that, in general a gestational sac less than or equal to 16 mm without a demonstrable embryo is associated with a poor outcome, with miscarriage in two-thirds of patients.

Dogra V et al5.2005 in their study stated that, ultrasound evaluation of patients with first trimester bleeding is the mainstay of the examination. The intrauterine gestational sac should be visualized by Trans Vaginal Ultrasonography with beta HCG levels between 1000 to 2000 mIU/mL. A Gestational Sac with a mean sac diameter of 8 mm or more without a yolk sac and or Mean Sac Diameter of 16 mm or more without an embryo, are important predictors of a nonviable gestation. A difference of less than 5 mm between the mean sac diameter and the Crown Rump Length carries an 80% risk of spontaneous abortion.

Bjarne Chr. Eriksen MD ET al4 2005 did a prospective study on 169 patients with threatened abortion with bleeding per vagina. The diagnostic and prognostic value of ultrasound, β-human chorionic gonadotropin (β-hCG) subunit, and progesterone were evaluated. With ultrasound, a correct diagnosis of in-utero

situation (true positive and true negative) was made at admission in 93% and after 1 week in 99% of the cases, in 1% of the cases mistaken for abortions (false positive) and concluded ultrasound had the highest sensitivity in detecting a pathologic pregnancy and also the best predictive value when a pathologic condition was discovered.

The study by, Poulose T, Richardson R, Ewings P, Fox R, J Obstet Gynaecol , 2006, evaluate the outcome of early pregnancies with a viable singleton fetus that had been complicated by bleeding. A prospective study was performed on 370 women with a singleton live fetus who had presented to the early pregnancy assessment clinic (EPAC) with vaginal bleeding. Women were grouped into light, moderate and heavy loss according to the self-assessed degree of vaginal bleeding. The women were also categorized according to the presence or absence of an intrauterine hematoma. The overall spontaneous miscarriage rate in the study was 11.1%; almost 90% of pregnancies continued to viability. Women with moderate or heavy bleeding had more than twice the rate of miscarriage compared with those with light bleeding. A total of 14% of the women had an intrauterine hematoma and those women were 2.6 times more likely to miscarry than those without (23% vs. 9%). This relationship appeared to hold true even after controlling for blood loss. The data presented can be used to guide women with a live fetus about the chance of miscarriage after an episode of vaginal bleeding.

Timothy B.Jang ET al3 2006 did a prospective study on 670 patients with first-trimester vaginal bleeding or pain who

underwent emergency bedside sonography followed by pelvic sonography. Results of emergency bedside sonography were compared with those of pelvic sonography, which showed increase in sensitivity and specificity for an intrauterine pregnancy from 80% and 86% respectively to 100% and 100%, for an adnexal mass or ectopic pregnancy changed from 43% and 94% to 75% and 89%, and for a molar pregnancy changed from 71% and 98% to 100%.

Chapter three

3.1 Materials and methods:

In this study we used an ultrasound machine of Aloka type which has Doppler capability, with a convex probe for abdominal examination and sector one for transvaginal. The frequency of the transducers range between 3.5 -7.5 MHZ .to prevent any defaults or artifacts a coupling gel will be applied.

Ultrasound has emerged as the gold standard imaging modality for patients presenting to the emergency department in the first trimester with pregnancy-related complaints.[1]

It has become increasingly important for the emergency physician to be able to use bedside ultrasound to identify the conditions that require emergent gynaecological consultation, because the availability of ultrasound through the radiology department may be limited. In a time-efficient manner, focused pelvic ultrasound may be performed at the same time as the pelvic examination.

The primary question of interest is, "Is the conceptus inside the uterus?" Evaluation for heterotopic and molar pregnancy, miscarriage, ovarian cysts, and pelvic inflammatory disease with tubo-ovarian abscess will also be briefly addressed in this article

3.2 Methods:

The data collected in this way include the ultrasound findings in female patients complains of pelvic pain . The analysis of data were done using the SSPS program, with a chi square test and a p value equal to 0.05 (which is significant less than that error. The data will be represented, analyzed and the results used as

a base to create new knowledge able recommendations and suggestions.

*An endocavitary probe is covered with a glove after transmission gel is first placed into one of the fingers, or a prefabricated sheath designed for this purpose may be used (see photo 1). A sterile gel, such as Surgilube, should be placed as a transmission medium external to the sheath, as this will be placed into the vagina. The patient should be given the opportunity to void. A full bladder during the examination will retrovert the uterus and can be uncomfortable for the patient.

With the patient placed in the lithotomy position, insert the probe into the vagina with the probe marker up, allowing a view of the uterus longitudinally (see photo 2). The bladder is seen on the left of the display screen, the body of the uterus in the middle and the cervix on the right. The vagina is not visualized because the probe is within it. The depth should be adjusted to fit the uterus on the screen and to visualize the posterior cul-de-sac.

Fan the probe to the right and to the left to scan through the body of the uterus and to assess that any gestation is contained within the uterus and not lying outside of it.
Assess for free fluid posterior to the uterus, as this may indicate a pathological process. Fluid is easily seen in this location, and ultrasound has replaced culdocentesis as the standard method for detecting free fluid (see photo 3).[2]
The probe should then be rotated 90 degrees counterclockwise, placing the probe marker to the patient's right. This is the

uterus viewed in the coronal plane (see photo 4). Adjust depth to fit the entire uterus on the screen, and evaluate the posterior cul-de-sac. The uterus should be scanned through in its entirety in this plane as well, by gently moving the tip of the probe up and down. Evaluation of the adnexa is challenging, especially for a novice sonographer. There are a few tricks that can be used to facilitate finding the ovaries. First, while visualizing the uterus in the coronal plan, scan up toward the uterine fundus. Move the probe in a plane parallel to this level toward the lateral fornix of each side. Following the cornua laterally to the adnexa will bring the fallopian tube and ovary into view. Another method is to move the probe laterally to find the iliac vessels. The ovary lies just medial and anterior (toward the patient's abdomen) of these vessels, and angling the probe in this way should bring each into view. Tran abdominal ultrasound also can be used to evaluate first-trimester pregnancy, with a few differences.*First, because the probe is farther away from the desired structures, 7 weeks from the last menstrual period (LMP) must elapse before the gestation can be visualized. Second, using the Trans abdominal probe, the bladder is seen on the right of the screen with the vagina seen just behind it (see photo 5). Third, unless there is significant pathology enlarging them, the ovaries are difficult to visualize. Principles of scanning otherwise remain the same--visualize the uterus in both longitudinal and transverse planes, and adjust depth to fit the entire uterus on the screen to evaluate the posterior cul-de-sac.

3.3 High definition of Transvaginal U/S probe:

Introduced in the mid – 1980s. The vaginal probe used higher frequency transducer in close proximately to the structure being studied. It yields degree of image magnificative dubbed son microscopy. Used in women who postmenauposal bleeding to see if it cold predict which patient laked significant tissue and could avoid dilation curettage

3.4 Research design:

In order to gain greater understanding about pelvic pain in first trimester, a quantitative approach is applied in this research .This descriptive analytical study was applied. After data has been entered, appropriate methods (e.g. charts, tables and descriptive statistics) was used to present response data. Quantitative data is statistics driven and can provide a lot of information.

3.5 Population and sample:

A population is the total of all the individuals who have certain characteristics and are of interest to a researcher.

The population of this study is the pregnancy women`s in al Saudi and maternity hospitals who are in first trimester pregnancy. The samples of the study are selected randomly from the population by using simple random sampling technique, which is the most widely-used probability sampling method, probably because it is easy to implement and easy to analyze.

3.6 Data collection:

The study will be conducted in maternity and al Saudi hospitals that is between 15 May to the first of April 2015. A written permission from both the hospitals should be issued from our

study population the sample size selected randomly. This is about 73 patients with vaginal bleeding + pain + watery discharge from those attendants in the mentioned hospitals. Any patient with vaginal bleeding + pain + watery discharge in first trimester will be included; however, any lady that lost her fetus in the same trimester will be excluded. Any patient targeted in the study should have a written agreement after being told what should be done.

Any object in the study should come the next day with a full bladder to be examined abdominally and transvaginally with empty bladder after the bleeding stops. The patients are examined in supine and oblique positions while the examiner is scanning with full survey. A brief description of the study was presented to the respondents including the study aims and background.

3.7 Data analysis:

As quantitative method is applied for this study, raw data will be processed and analyzed by using SPSS Statistics 20.0 versions to test the eligibility of hypotheses. Answers from data collection sheet will be coded and put into the statistical package to make data matrix This study is a correlation research study.

To analyze the data, a linear multiple regression and factor analysis used to learn more about the relationship between several independent or predictor variables and a dependent or criterion variable (pelvic pain). Multiple regressions can establish that a set of independent variables explains a proportion of the variance in a dependent variable at a

significant level (through a significance test) and can establish the relative predictive importance of the independent variables

Chapter four

Results

The following tables and figures presented the data obtained from 73 female patients with pelvic pain in the first trimester, all were investigated using ultrasonography. The data was presented as frequency and percentages and Cross tabulations were obtained using Chi square test (SPSS programme version16)

Table 4.1 The sample age classes, Frequency and percentages

Age classes	frequency	Percentages%
15-19	8	10.9
20-24	19	26.0
25-29	17	23.3
30-34	10	13.7
35-39	15	20.6
40-44	4	5.5
Total	73	100

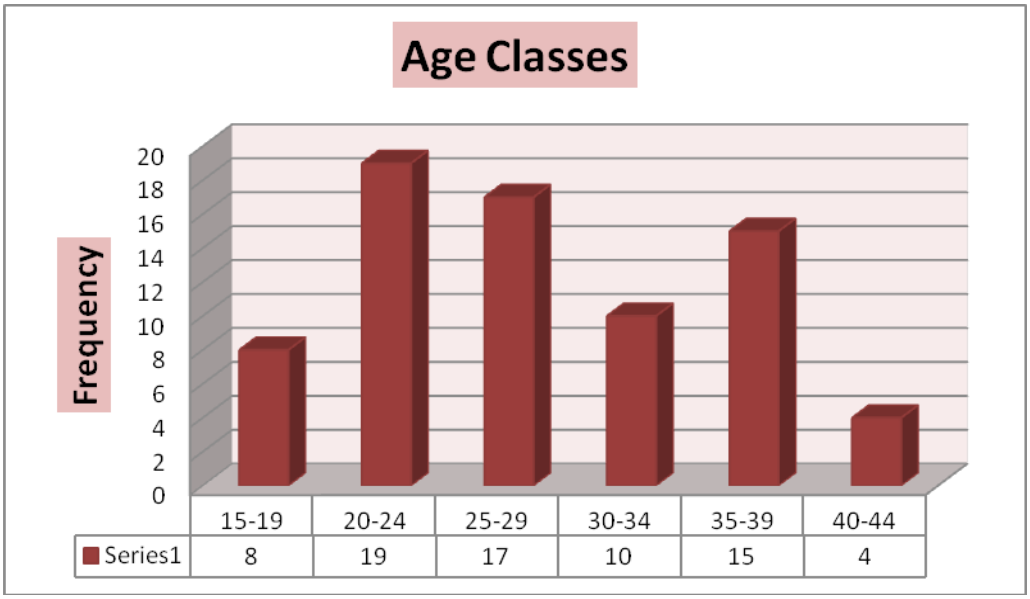

Figure 4.1 The sample age classes, Frequency and percentages

Table 4.2 The Number of Deliveries, Frequency and percentages

Number of Deliveries	frequency	Percentages%
0	7	9.6
1	23	31.5
2	13	17.8
3	9	12.4
4	12	16.4
5	3	4.1
6	3	4.1
7	2	2.7
8	1	1.4

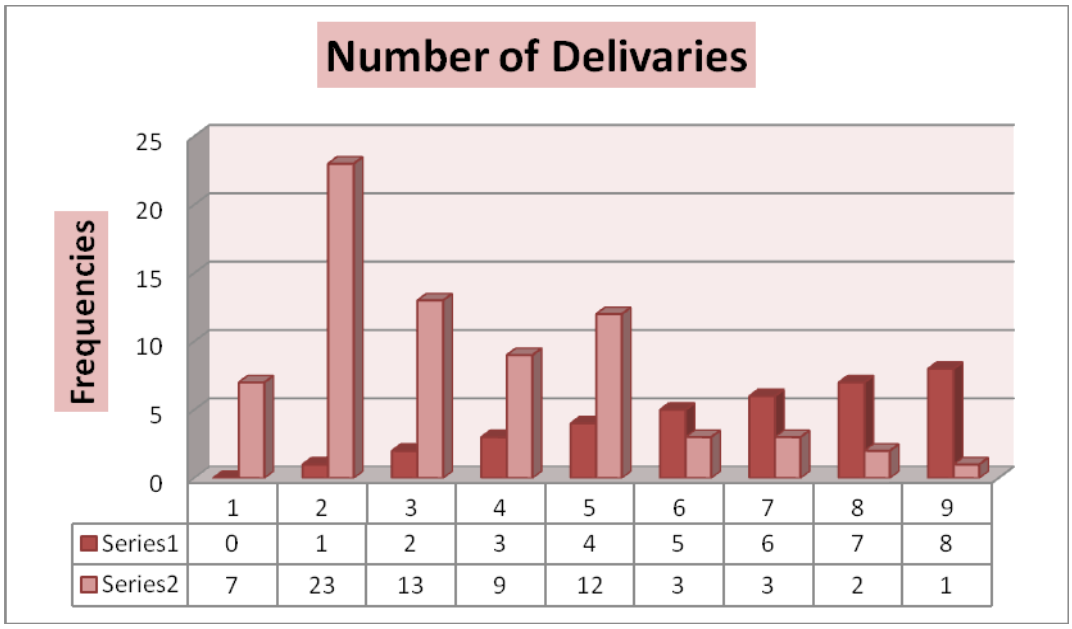

Figure 4.2 The Number of Delivery and Frequency (Series 1 stands for number of deliveries, series 2 stands for frequencies of deliveries).

Table 4.3 The Clinical signs, Frequency and percentages

Clinical Signs	frequency	Percentages%
Pain	4	5.5
Pain with watery discharge	5	6.8
Pain with bleeding	36	49.3

Pain with bleeding and watery discharge	28	38.4

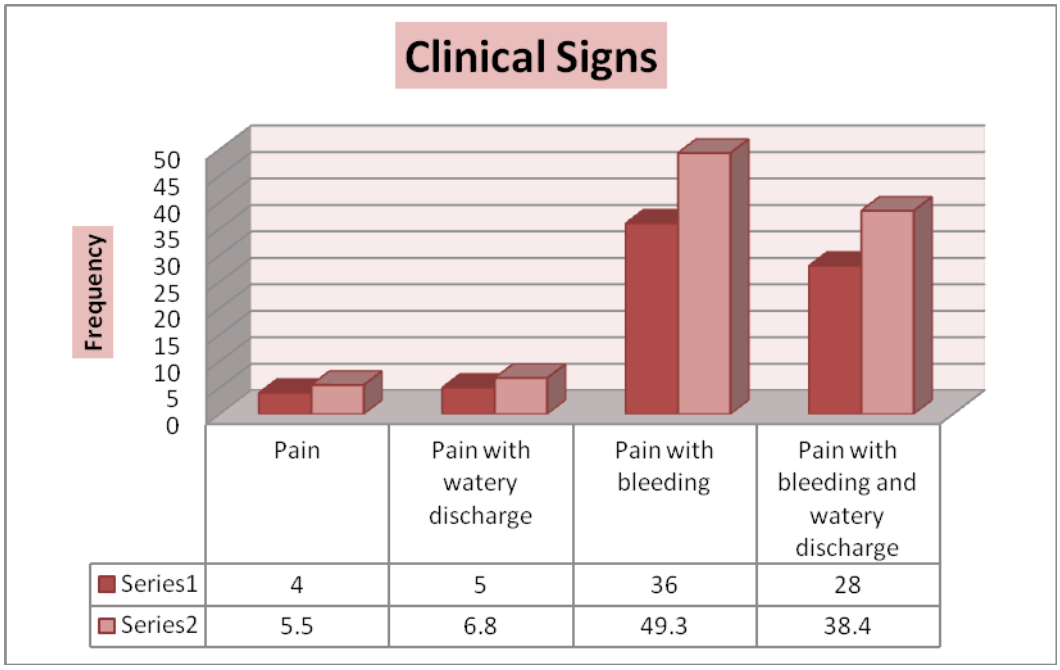

Figure 4.3 The Clinical Signs, Frequency and percentages (Series 1 stands for number of patients with the specific clinical sign, series 2 stands for percentages%).

Table 4.4 The Ultrasound Findings in patients with pelvic pain

Abortion Causes	Frequency	Percentage%
Complete Abortion	13	17.8
Ectopic Pregnancy	2	2.7
Incomplete Abortion	16	21.9
Normal Pregnancy	4	5.5
Inevitable	3	4.1
Missed Abortion	13	17.8
Threatened Abortion	8	11.0
Blighted Ovum	7	9.6
Molar Pregnancy	2	2.7
Pregnancy With Bleeding	5	6.8
Total	73	100.0

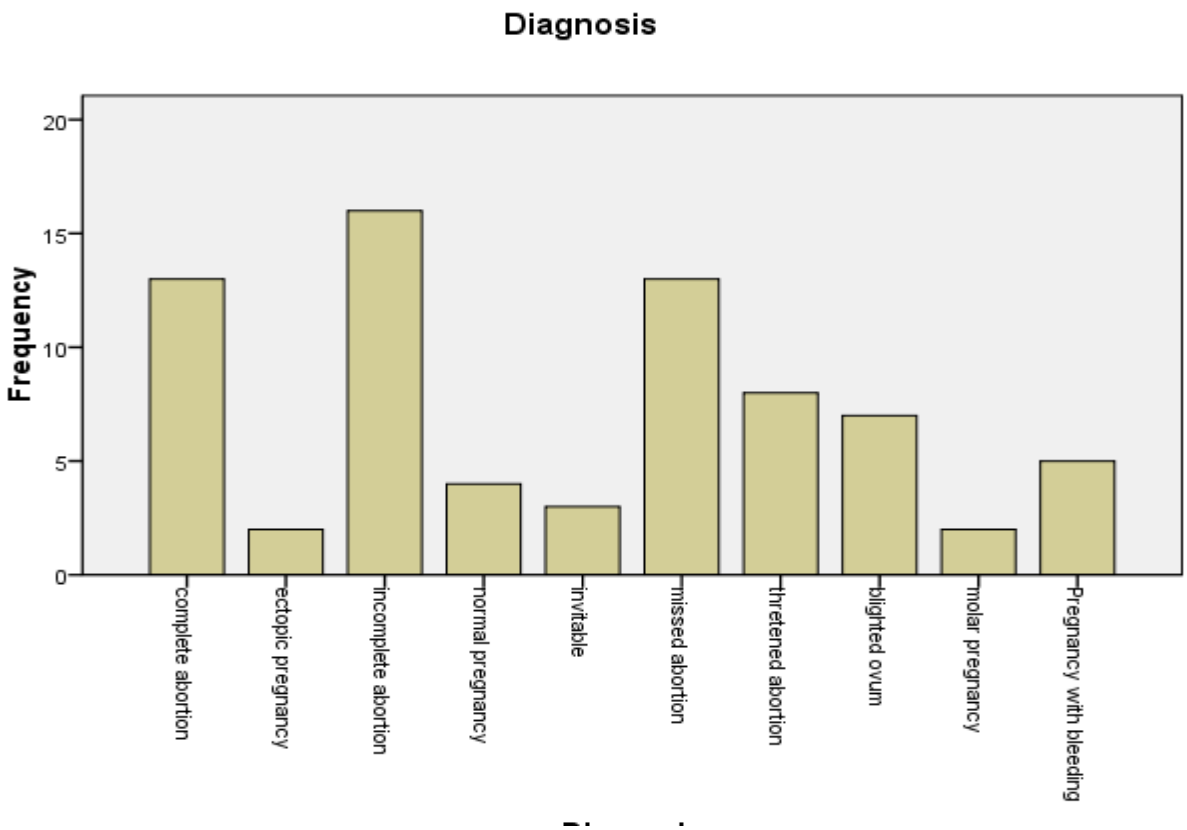

Figure 4.4 The causes of abortion and Frequency

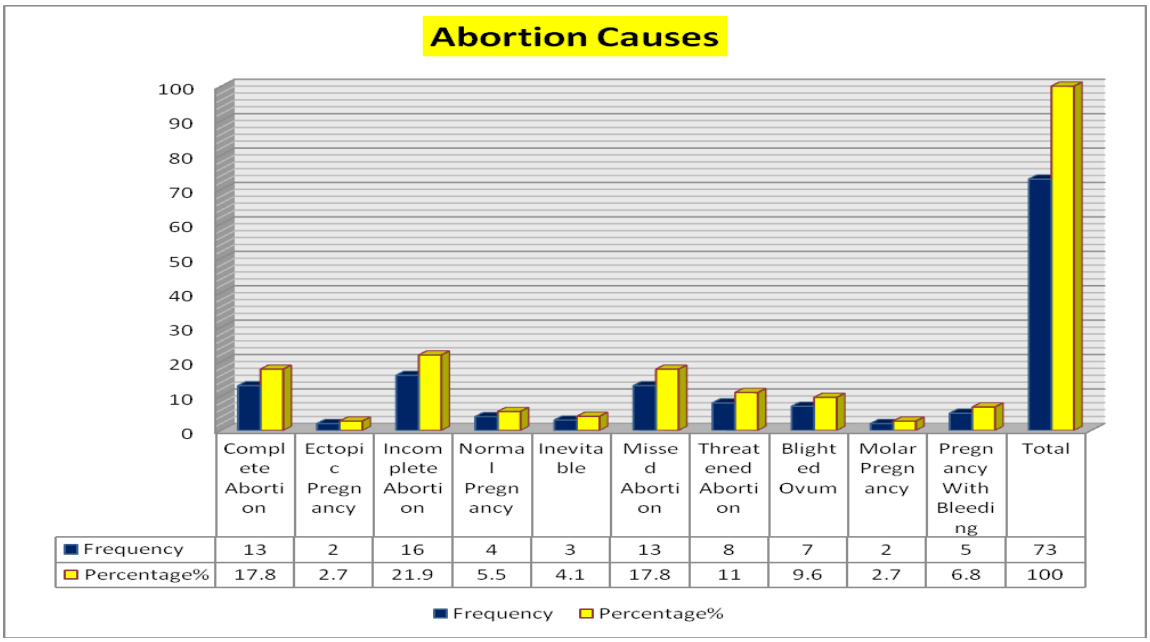

	Complete Abortion	Ectopic Pregnancy	Incomplete Abortion	Normal Pregnancy	Inevitable	Missed Abortion	Threatened Abortion	Blighted Ovum	Molar Pregnancy	Pregnancy With Bleeding	Total
Frequency	13	2	16	4	3	13	8	7	2	5	73
Percentage%	17.8	2.7	21.9	5.5	4.1	17.8	11	9.6	2.7	6.8	100

Table 4.5 The classification of abortion and its causes

Ultrasound Findings For abortion classification (Complete and Incomplete)	**frequency**
Complete abortion	8
Complete abortion with ovarian mass	4
Complete abortion with dilated OS	1
Incomplete abortion/dilated OS	6
Incomplete abortion/dilated OS/Bicornate Uterus	1
Incomplete abortion	9
Missed Abortion	13
Threatened abortion	8

Table 4.6 The Correlation between the variables

Correlations					
		clinical signs	Age	Number Of deliveries	Diagnosis
clinical signs	Pearson Correlation	1	.011	-.104-	.084
	Sig. (2-tailed)		.924	.383	.478
	N	73	73	73	73
Age	Pearson Correlation	.011	1	.504**	-.114-
	Sig. (2-tailed)	.924		.000	.335
	N	73	73	73	73
Number of deliveries	Pearson Correlation	-.104-	.504**	1	.157
	Sig. (2-tailed)	.383	.000		.185
	N	73	73	73	73
Diagnosis	Pearson Correlation	.084	-.114-	.157	1
	Sig. (2-	.478	.335	.185	

	tailed)				
	N	73	73	73	73
**. Correlation is significant at the 0.01 level (2-tailed).					

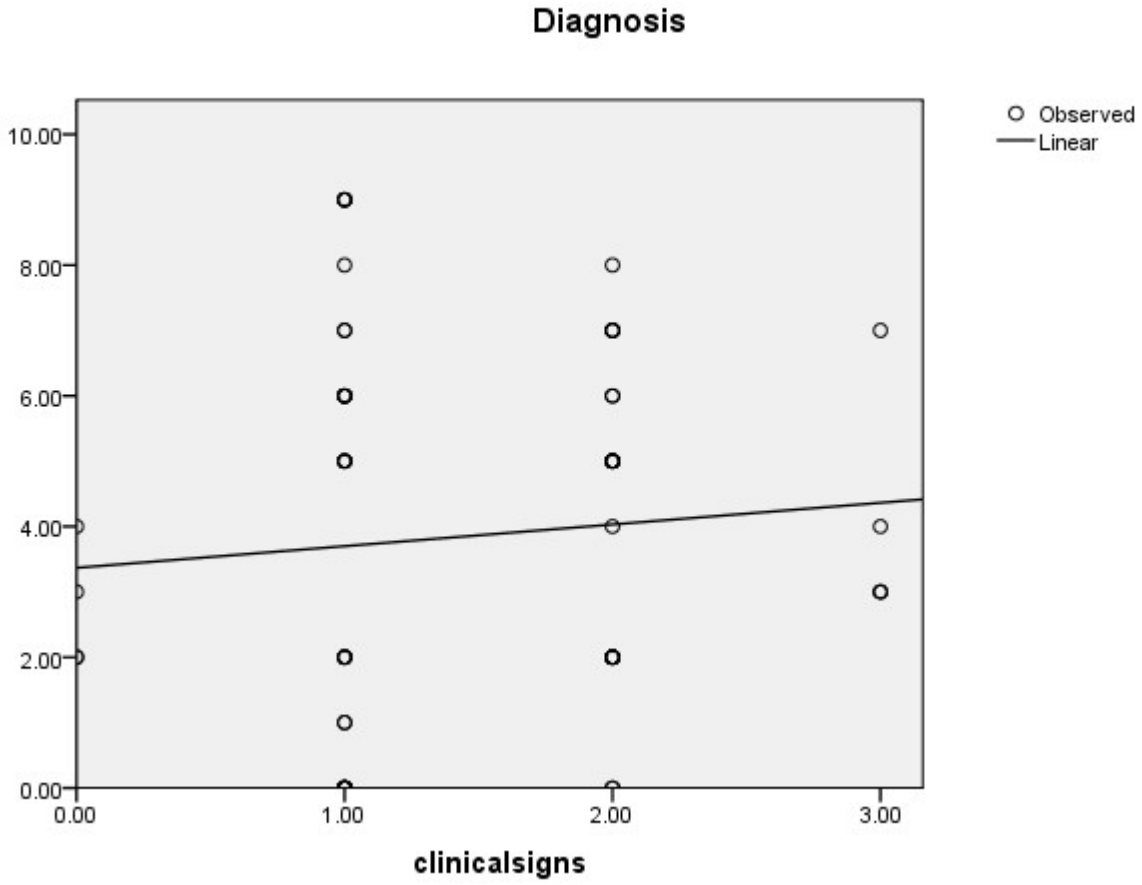

Figure 4.5 A scatter plot diagramme shows a linear relationship between the clinical sign and ultrasound findings(diagnosis)

Table 4.6 the coefficient of variables (Clinical signs and the diagnosis)

Coefficients				
	Unstandardized Coefficients	Standardized Coefficients	t	Sig.

	B	Std. Error	Beta		
clinical signs	.332	.465	.084	.714	.478
(Constant)	3.368	.750		4.491	.000

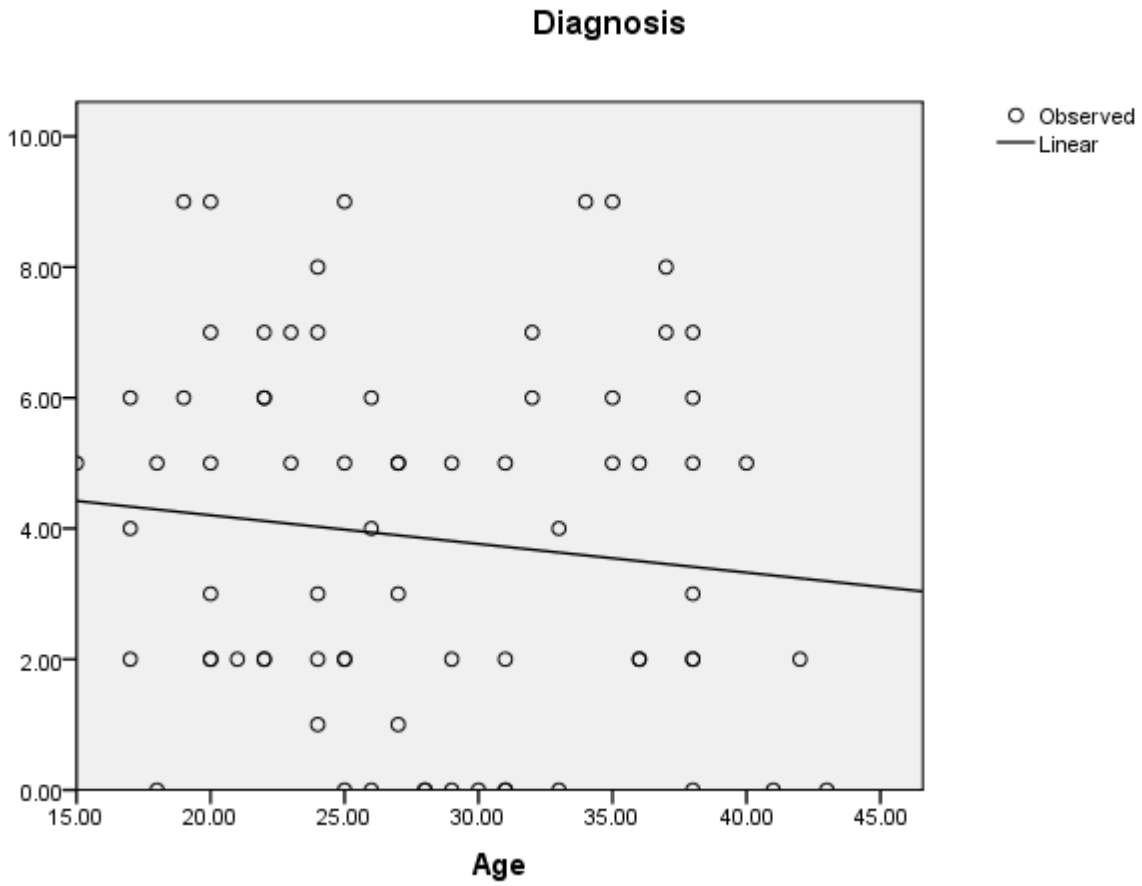

Figure 4.6 A scatter plot diagramme shows a linear relationship between the Age and ultrasound findings (diagnosis)

Table 4.7 The coefficient of variables (Age and the diagnosis)

Coefficients					
	Unstandardized Coefficients		Standardized Coefficients	t	Sig.
	B	Std. Error	Beta		
Age	-.044-	.045	-.114-	-.971-	.335
(Constant)	5.080	1.309		3.881	.000

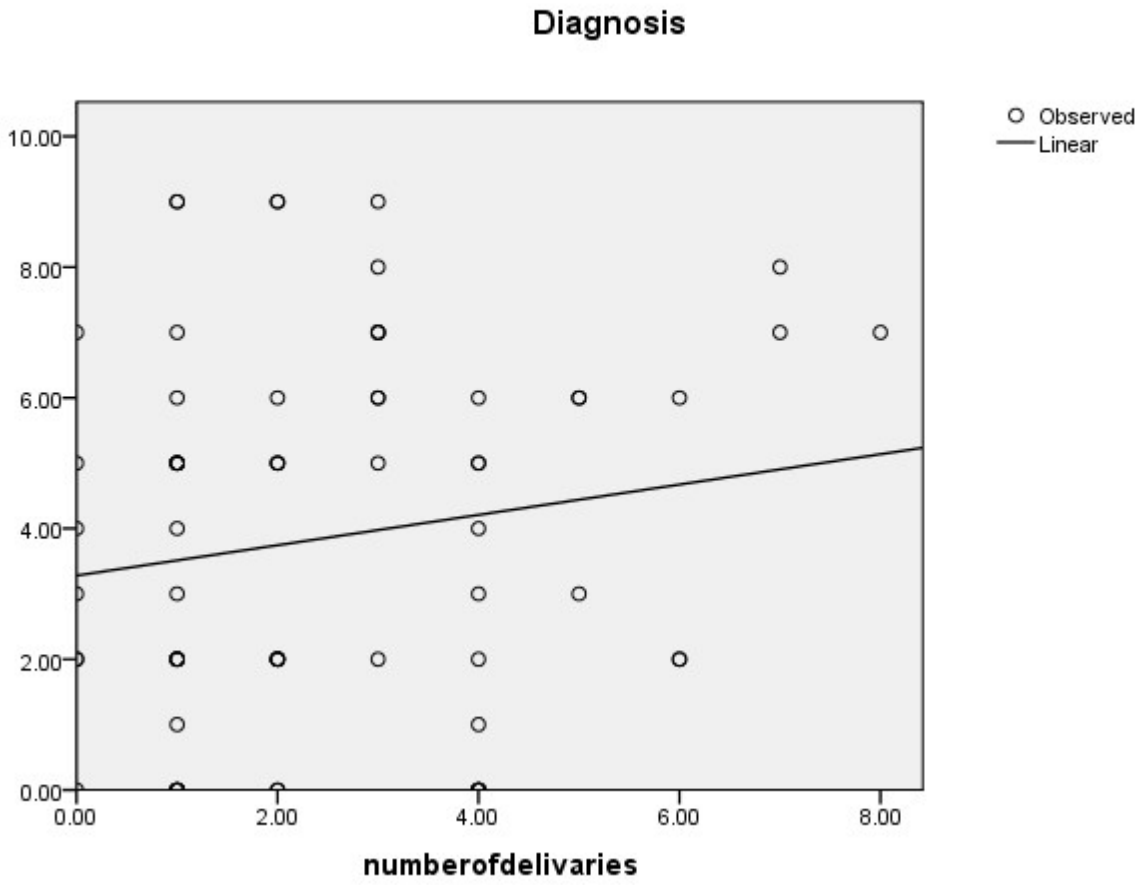

Figure 4.7A scatter plot diagramme shows a linear relationship between the Number of deliveries and ultrasound findings(diagnosis)

Table 4.8 The coefficient of variables (Number of Deliveries and the diagnosis)

Coefficients					
	Unstandardized Coefficients		Standardized Coefficients	t	Sig.
	B	Std. Error	Beta		
Number of deli varies	.232	.174	.157	1.337	.185
(Constant)	3.280	.535		6.133	.000

CHAPTER FIVE

5-1 Discussion:

This study was conducted at Omdurman maternity & Al Saudi hospitals, in the period from May 2013 to April 2015. In this study Ultrasound machine of Aloka type which has Doppler capability, with a convex probe for abdominal examination and sector one for trans-vaginal and another machine of Sonac were used. The frequency of the transducers range between 3.5 -7.5 MHZ. The study was done in (n= 73) pregnant women in the first trimester, their ages range between (15-44years). The 73 female patients with pelvic pain in the first trimester were investigated using ultrasonography. The data were presented as frequency tables and percentages and cross tabulations, all were obtained using Chi square test (SPSS programme version16).

In order to gain greater understanding about pelvic pain in first trimester, a quantitative approach is applied in this research .This descriptive analytical study was applied. After data has been entered, an appropriate method (e.g. charts, tables and descriptive statistics) was used to present response data. Quantitative data is statistics driven and can provide a lot of information.

Table 4.1 shows the age groups which are six (the first is 15-19 of percent = 10.9%, the last 40-44 with percent =5.5 %), also this is represented in Fig 4.1

The results of this study showed that 4 patients (5.5%) their clinical signs are pain only, 5 patients (6.8%)suffering from pain with watery discharge,36 patients (49.3%) pain with bleeding and28 patients (38.4%) pain with both bleeding and watery discharge.

The clinical feature of abortion were suffering from pain and other discharges (auther,1990)Our patients clinical presentation were consistent with the miscarriage findings which was mentioned in the literature

Table 4.4 showed that 13 patients (17.8%) with complete abortion, 2 patients (2.7%) ectopic pregnancy, 16 patients (21.9%) incomplete abortion,4 patients (5.5%) normal pregnancy,3 patients (4.1%) inevitable abortion,13 patients (17.8%) missed abortion,8 patients (11.0%)threatened abortion,7 patients(9.6%)blighted ovum,2 patients (2.7%)and 5 patients(6.8%) pregnancy with bleeding.

The ultrasound findings showed that when the cases were diagnosed as complete abortion their songraphic findings were

empty free bulky uterus similarly this was mentioned by (carol A. Krebs etal 1993) where the incomplete the uters contain the gestational sac, may be misshaped or collapsed, the gestational sac may be intact, containing a nonliving embryo, an irregular complex mass within the endometrial or endocervical canal may be present(www.mypacs.net).woman sufferfor missed abortion the CRL of ≥7 mm without a heart beat, abnormal hyperechoic material within the uterine cavity and an irregular gestational sac (www.radiopaedia.org).woman suffer for ineivtable abortion showed gestational sac in endometrial cavity (white lines) heterogenous echogenicity within the uterus, representing an embryo, the cervical canal is dilated (www.my pacs.net),and woman suffer for threatened abortion showed vaginal spotting/bleeding, mild uterine cramping, closed os, may see intrauterine hematoma if viable gestation, just observe (carol A. Krebs 1993).woman who suffer for spontaneous abortion may experience pelvic pain during the sudden loss of pregnancy (www.babymed.com)

We found a linear relationship between the Age and ultrasound findings (diagnosis). A linear relationship also observed between the clinical signs and ultrasound findings (diagnosis).As represented in(table 4.6) a strong correlation found between clinical signs ,age and the number of deliveries ;using Pearson Correlation coefficient it is significant at the 0.01 level (2-tailed).

In summary there are week or even in some variables of the study no relationship between the tested clinical signs on one hand and the pelvic pain and the watery discharge on the other

hand, except the different types of abortions and their causes. This is found significant using Chi test put in mind that our error level is 0.05. Therefore this statistical analysis shows very strong association between pelvic pain and all types of abortions, and other shows moderate or no association between it and other clinical signs.

5-2 Recommendations:

After the enumeration of the results that related to the following thesis, there are some ideas which could help further in the field of research and better to be recommended as follow:

- Ultrasonography could be used as routine checkup, follow up to help in the early diagnosis, prevention and control of female pelvic pain.
- Our advice to the directors in the primary health care unit to put a U/S machines in their centers as well as a trained sonographer to help in this policy.
- To the mothers doing antenatal care she must have a monthly follow-up and observation to detect any problem early.
- To apply the ultrasound examination frequently every month for check up.

5-3 conclusion:

Statistical analysis shows very strong association between pelvic pain and all types of abortions, and other shows moderate or no association between it and other clinical signs.

5.4 References:

- Basic anatomy and physiology for radiographers. M.R.E. DEAN. MB. Bchiri DMRD. Cansultant rudilosist the royaln shrew burg hospital T.E.T.WEST MD.FRCP cunsultum physician the royal shrews bury hospital.3rd edition 1970-1975-1987.
- Chiang G. Levine D. swire m, etal. The intradecidual sign: is it reliable for cliagnosis of early intrauterine pregnancy, AGR AmJroengenol 2004: 183: 725- 31.
- Filly RA U/S evduution during the first trimester m: callen PW , editor ultrasonography in obstetric and gynecdogy , phisadelphia :W B saunders; 1998 P 63-85
- Ultrasound Atlas of disease processes .Carol A.Kerbs RDMS etal .1993
- www.babymed.com.
- www.my pacs.net .
- www.radiopaedia.org.
- Yeh HC Good man ID, carrl, et al. intradecidual sign: auscriterion of early intrauterine pregnancy. Radiology 1986 , 16) :4637 Filly RA U/S evduution during the first trimester m: callen PW , editor ultrasonography in obstetric and gynecdogy , phisadelphia :W B saunders; 1998 P 63-8
- Yehhc efficacy of the intradecidual sign in the diagnostic of early intrauterine Sal sign in the diagnoses of early intrauterine. Pregnancy – radiology 1999:210:579:82.

5.5 Appendix

NO.	patient age	NO. of delivers	Clinical Symptoms	ultrasound findings
1	18	1	pain and bleeding	complete abortion /ovarian masses
2	33	4	pain and bleeding	complete abortion
3	24	1	pain and bleeding	ectopic - adenixia mass
4	20	1	pain	incomplete abortion / products
5	22	2	pain and bleeding	GA 7w + 3D / normal pregnancy
6	29	3	pain and bleeding	incomplete abortion - dilated OS / products
7	38	4	pain and bleeding	complete abortion
8	43	4	pain & bleeding & water discharch	complete abortion - ovarian masses
9	36	6	pain & bleeding	incomplete abortion products / ovarian masses
10	25	2	pain and bleeding	pregnancy with bleeding with fibroids overian mass
11	26	0	pain & watery discharch	inevitable / GA 13W
12	17	1	pain	inevitable / GA 9
13	27	2	pain & bleeding & watery discharch	missed abortion / GA 7 pregnancy with bleeding
14	22	3	pain & bleeding	threatended abortion normal pregnancy GA 9w -bleeding
15	32	5	pain & bleeding & watery discharch	threatended abortion normal pregnancy with bleeding
16	17	1	pain & bleeding	threatended abortion pregnancy with bleeding
17	35	5	pain and bleeding	threatened abortion GA=7W , pregnancy with bleeding
18	19	2	pain and bleeding	threatened abortion pregnancy with bleeding GA 12W
19	20	2	pain & bleeding & watery discharch	missed abortion GA 10w pregnancy with bleeding
20	35	1	pain & bleeding	miss abortion / GA low pregnancy with bleeding
20	28	1	pain & bleeding	complete abortion
21	31	1	pain	incomplete abortion (products)
22	15	1	pain & bleeding	GA 8w missed abortion pregnancy with bleeding
23	31	4	pain & bleeding	complete abortion
24	31	1	pain & bleeding	complete abortion
25	23	3	pain / bleeding / watery discharch	missed miss carriage / GA7w + 2d , pregnancy with bleeding
26	29	1	pain / bleeding	complete abortion
27	36	1	pain / bleeding / watery discharch	incomplete abortion / products
28	37	8	pain / bleeding	blighted ovum / 9w + 2d
29	36	1	pain / bleeding / watery discharch	missed carriage / GA7w + 2d
30	38	1	pain / bleeding / watery discharch	missed miss carriage / GA 8w

31	22		3		pain / bleeding / watery discharch	blighted ovum GA 9w + 1d
32	31		4		pain / bleeding	missed miss carriage GA 7w+3d
33	38		6		pain / bleeding / watery discharch	incomplete abortion / dilated OS / products
34	24		1		pain / watery discharch	normal pregnancy / GA 7w
35	19		1		pain / bleeding	pregnancy with bleeding / GA 7w
36	38		4		pain / bleeding / watery discharch	threatended abortion pregnancy with bleeding GA 8w + 6d
37	25		2		pain / bleeding / watery discharch	complete abortion
38	34		2		pain / bleeding	pregnancy with bleeding / GA 6w + 5D
39	30		0		pain / bleeding	complete abortion / overian mass
40	27		4		pain / bleeding	missed abortion pregnancy with bleeding GA 9w
41	28		2		pain / bleeding	complete abortion dilated OS
42	25		1		pain / bleeding / watery discharch	incomplete abortion / products/ overian cyst
43	20		0		pain / watery discharch	normal pregnancy / dilated OS
44	24		3		pain / bleeding / watery / discharch	molar pregnancy
45	20		0		pain / bleeding / watery / discharch	incomplete abortion + products
46	40		1		pain / bleeding / watery discharch	missed abortion pregnancy with bleeding / GA 8w + 3D
47	38		7		pain / watery discharch	Blighted ovum
48	24		2		pain / bleeding / watery discharch	incomplete abortion dilated OS + products
49	29		1		pain and bleeding	missed abortion / pregnancy with bleeding GA 8w
50	18		0		pain / bleeding / watery discharch	missed abortion pregnancy with bleeding GA 9w
51	33		4		pain / bleeding / watery discharch	Investable miscarriage / dilated OS
52	38		2		pain / bleeding / watery discharch	incomplete abortion + products
53	21		2		pain & bleeding	incomplete abortion+ products7 * 35
54	38		5		pain	normal pregnancy / GA low + 5D
55	27		4		pain & watery discharch	normal pregnancy / GA low + 5D
56	41		4		pain and bleeding	complete abortion / overian cyst
57	26		1		pain and bleeding	complete abortion
58	42		4		pain & bleeding & watery discharch	incomplete abortion / dilated OS + products
59	22		1		pain & bleeding & watery discharch	incomplete abortion / dilated OS + products
60	25		2		pain & bleeding & watery discharch	missed abortion / pregnancy with bleeding GA = 12w
61	35		1		pain / bleeding	pregnancy with bleeding / GA 7w + 1D
62	25		2		pain / bleeding / watery discharch	incomplete abortion| products
63	23		0		pain / bleeding / watery discharch	blighted ovum /GA 7w
64	27		4		pain / bleeding	Ectopic pregnancy + hydro salpania

65	20		3		pain / bleeding			pregnancy with bleeding + I.U.C.D / ovarian cyst									
66	24		1		pain / bleeding			blighted ovum / GA 6w									
67	32		3		pain / bleeding / watery discharch			blighted ovum / 8wk = GA									
68	37		7		pain / bleeding			molar pregnancy									
69	26		6		pain / bleeding			threatened abortion / pregnancy eighth bleeding + pregnance with abscesses' + hydro salpania / GA									
70	20		3		pain / bleeding / watery discharch			blighted ovum									
71	22		3		pain / bleeding			threatened abortion / pregnancy e bleeding / ovarian mass complex 7*6 mm / GA 11w + 2D									
72	17		0		pain / bleeding / watery discharch			incomplete abortion / dilated OS + products / bicornated uterus									
		Analysis 0/ PAIN		1/ pain / watery discharch			2/ pain / bleeding			3)Pain / bleeding watery discharch							
		4		5				35				28					

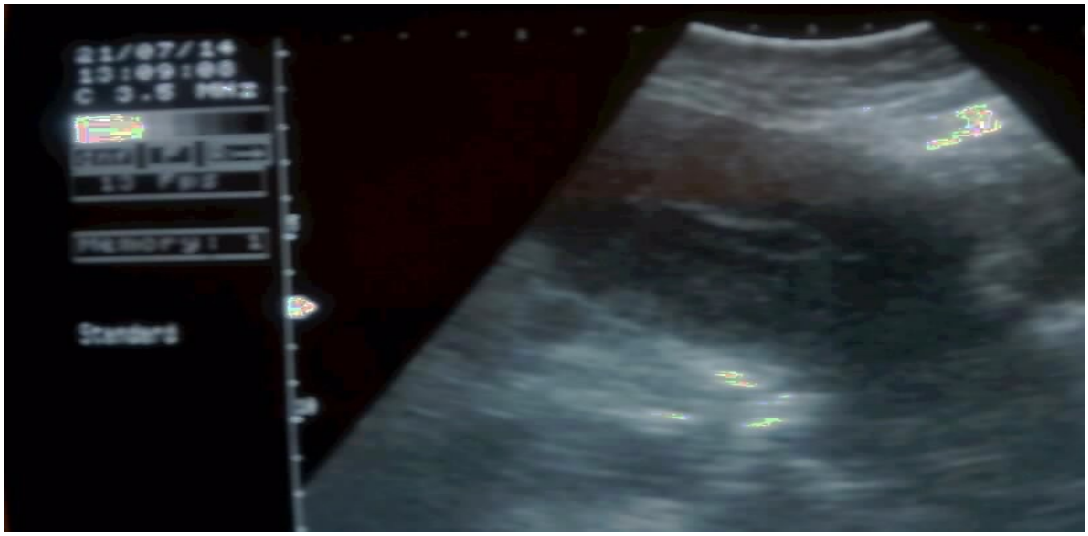

Image 1 :Complete abortion: Woman 31 years age with vaginal bleedingi

Image 2: Incomplete abortion: woman 35 years presented to U/S department with vaginal bleeding

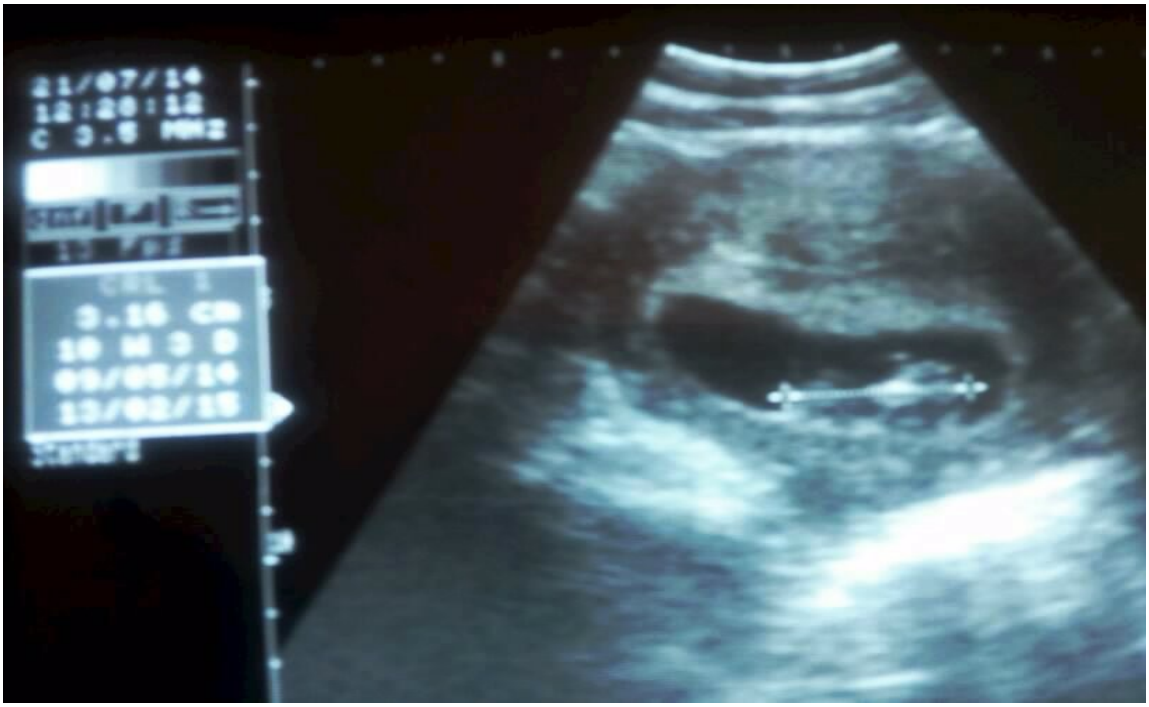

Image 3 : Threatened abortion: pregnant woman, 32 age presented with mild vaginal bleeding and pelvic pain.

Image 4 :Molar pregnancy: woman with 44 age, gravid a 6, presented to U/S with severe vaginal bleeding, positive pregnancy test with high level of HSG.

Image 5 :Incomplete abortion with retain product.

Image 6 :Incomplete apportion

Image 7: Blighted ovum: no embryonic pole .yolk sac seen

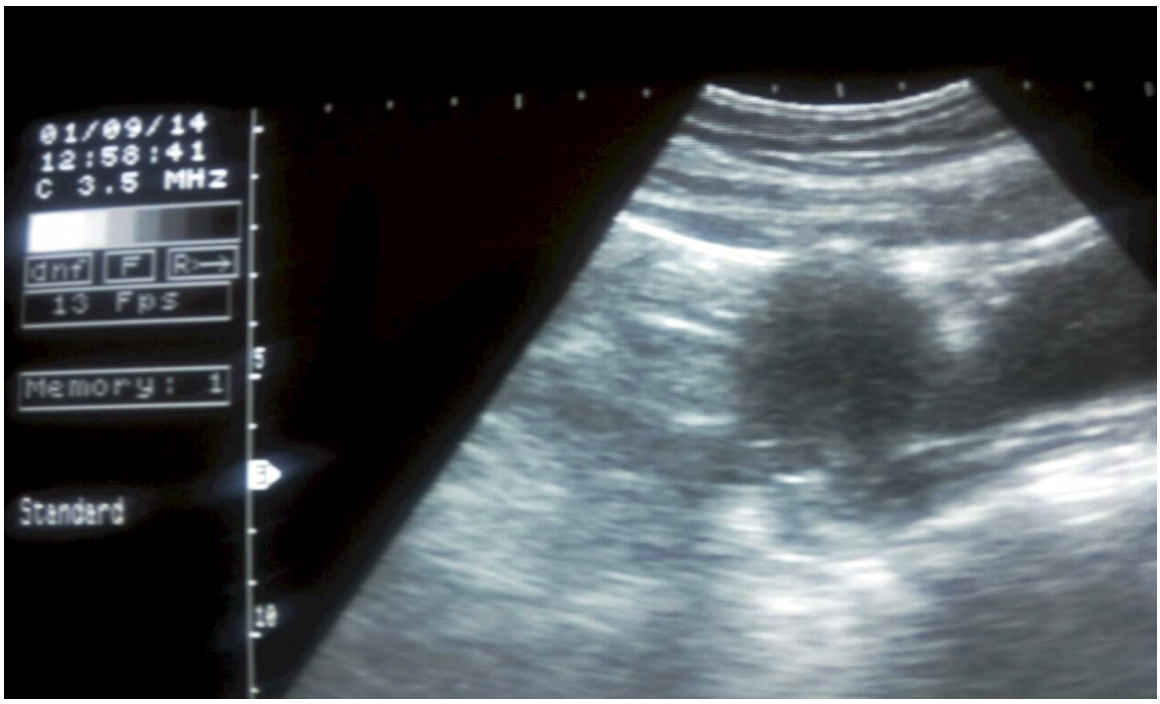

Image 8 : Complete abortion: patient presented with vaginal bleeding continue 2 weeks.

Image 9 : Missed abortion: embryonic collapsed, no heart beats seen.

Image 10 : Blighted Ovum: patient presented with mild vaginal bleeding, no embryonic pole .yolk sac seen.

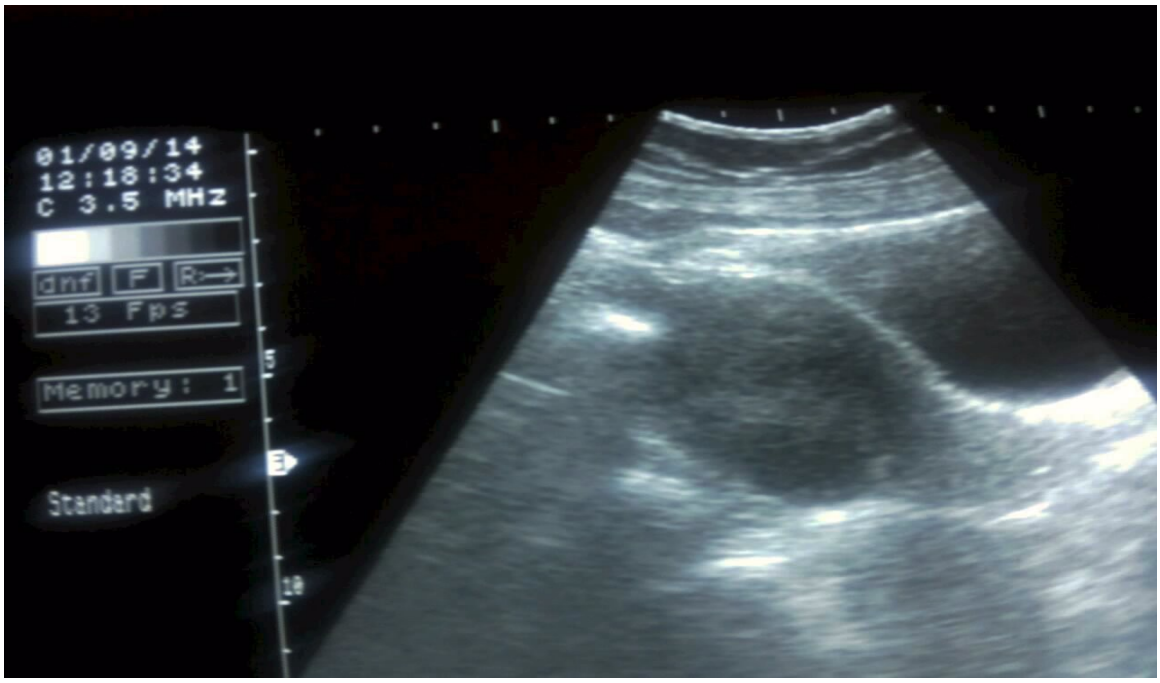

Image 11: Complete abortion.

Image 12 : Missed abortion: 29 years patient presented with mild vaginal bleeding, no heart beat seen.

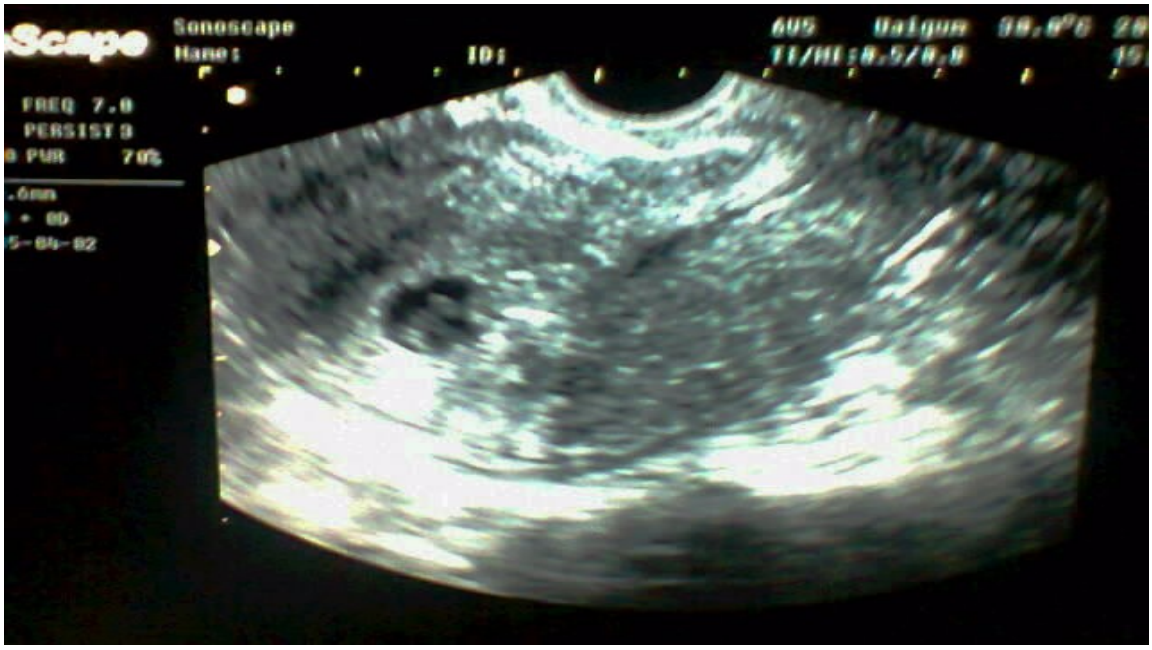

Image 13 : Threatened abortion: patient, 22 years, presented with mild vaginal bleeding

Image 14 : Molar pregnancy: patient 42 years , presented with vaginal bleeding, positive pregnancy test.

Image 15 : Threatened abortion: patient, 32 years, presented with mild vaginal bleeding, pelvic pain.

Image 16 : Threatened abortion: patient, 35 years, gravid 3. presented with mild vaginal bleeding.

Image 17 : Ectopic pregnancy: patient presented with mild vaginal bleeding,U/S showed adenxal mass like GS when done lab investigation HSG low than normal level.

Image 18 :Blighted Ovum :32 years woman .

Image 19 : Incomplete abortion, with retain product 13.4mm.

Image 20 :Blighted Ovum

In the name of Allah

Sudan University

Pelvic pain in first trimester

Cautionary:

Patient age ..... { }

Pregnancy with abscesses { }

No of Delivers { }

Clinical symptoms { }

Pain { }

Bleeding { }

Watery { }

U/S findings { }

Cavity conditions

GA { }

Normal pregnancy { }

Pregnancy with bleeding { }

Pregnancy with fibroids { }

Blighted ovum { }

Dilated OS { }

Products { }

Types of abortion { }

Ectopic pregnancy { }

Overian masses { }

Overian cyst { }

Hydrosalpania { }

Utrineanomalis { }

Pregnancy with appendices { }

SUDAN UNIVERSITY OF SCIENCE AND TECHNOLOGY

COLLAGE OF GRADUATE studies

STUDY OF PELVIC PAIN IN FIRST TRIMESTER USING ULTRA SOUND

دراسة آلام الحوض في الثلوث الأول من الحمل باستخدام الموجات فوق الصوتية

ATHESIS SUBMITTED FOR PARTIAL FULFILMENT OF MSC DEGREE IN MEDICAL ULTRASOUND

BY: **ABDAL AZIZ ELTAYEB BASHIR ATA AL MANAN**

SUPERVISOR: **Dr. EL SAFI AHMED ABDALLAH**

الآية الكريمة

قال تعالى: (هُوَ ٱلَّذِى يُصَوِّرُكُمْ فِى ٱلْأَرْحَامِ كَيْفَ يَشَآءُ ۚ
لَآ إِلَٰهَ إِلَّا هُوَ ٱلْعَزِيزُ ٱلْحَكِيمُ ﴿٦﴾

سورة آل عمران

سورة الشورى

وقال تعالى: (لِّلَّهِ مُلْكُ
ٱلسَّمَٰوَٰتِ وَٱلْأَرْضِ ۚ يَخْلُقُ مَا يَشَآءُ ۚ يَهَبُ لِمَن يَشَآءُ إِنَٰثًا
وَيَهَبُ لِمَن يَشَآءُ ٱلذُّكُورَ ﴿٤٩﴾ أَوْ يُزَوِّجُهُمْ ذُكْرَانًا وَإِنَٰثًا ۖ
وَيَجْعَلُ مَن يَشَآءُ عَقِيمًا ۚ إِنَّهُۥ عَلِيمٌ قَدِيرٌ ﴿٥٠﴾

I

Dedication

To whom my life is given a purpose I would like to thank Allah and then my mother’s soul who encouraged me to perform this master who wished from the bottom of her heart to see me reaching the master degree and also My profound thanks to my father, then my wonderful family, especially to my loving wife Samar who had sacrificed her time and career to undertake my Master. Her encouragement and never ending low of moral support. Also to all my children Altayeb, Wigdan. They are all under 10 years of age, they haven t got any idea what this task is all about but never doubted their dad will succeed., I also thank my brothers and sisters for their never ending encouragement. And my special thanks to my sister`s son Altayeb which his age is below 15 for his hard working to type and arrange this research.

Acknowledgments

I am very much thankful to my supervisor Prof: Elsafi Ahmed Abdullah, whose encouragement, guidance and support from the initial stages of my research to the final level enabled me to develop and understand the subject. I also give my best wishes and appreciate Dr. Karolin Edward .I acknowledge Sudan University of science and technology for supporting this work, and I wish to give my great appreciation to all workers in al Saudi and Maternity hospitals for helping me in filling the study questionnaire. Lastly, I offer my regards and blessings to all of those who supported me in any respect during the completion of this research.

Abstract

This study done to know and evaluate the causes and symptoms of the pelvic pain in the first trimester using ultrasound as diagnostic imaging modality. This study conducted at Omdurman maternity & Al Saudi hospitals, in the period from 15 May 2013 to 1 August 2015. In this study Ultrasound machine of Aloka type which has Doppler capability, with a convex probe for abdominal examination and sector one for trans-vaginal and another machine of sonac were used . The frequency of the transducers range between 3.5 -7.5 MHZ. The study was done in 73 women pregnant in the first trimester, their ages range between (15-44years).

The results of this study showed that 4 patients (5.5%) their clinical signs are pain only, 5 patients (6.8%)suffering from pain watery discharge,36 patients (49.3%) pain with bleeding and28 patients (38.4%) pain with bleeding and watery discharge. Also the results showed that 13patients (17.8%) with complete abortion, 2 patients (2.7%) ectopic pregnancy, 16 patients (21.9%) incomplete abortion,4 patients (5.5%) normal pregnancy,3 patients (4.1%) inevitable abortion,13 patients (17.8%) missed abortion,8 patients (11.0%)threatened abortion,7 patients(9.6%)blighted ovum,2 patients (2.7%)and 5 patients(6.8%) pregnancy with bleeding.

ملخص الدراسة

اجري هذا البحث لمعرفة وتقييم اسباب واعراض الام الحوض في مرحلة الحمل الاولي باستخدام الموجات فوق الصوتية كوسيلة للتشخيص .
واجري هذا البحث بمستشفي الولادة امـدرمان والمستشـفي السـعودي للنسـاء والتوليد في الفترة ما بين 15 مايو 2013 الي 1 اغسـطس 2015 . اسـتخدم في هذه الدراسة جهاز موجات فوق الصوتية ماركـة الوكـا ويقـدم خدمـة تصـوير الاوعية الدموية (دوبلر) يحتوي علـي مجـس محـدب لتصـوير الاعضـاء الداخليـة للبطن والحوض ومجـس اخـر مهبلـي واسـتخدم ايضـا فـي هـذه الدراسـة جهـاز موجات فوق الصوتية اخر ماركة سـوناك ذو مجسـات تـتراوح ترددداتهـا بيـن 3,5 الي 7,5 ميغاهيرتزز.
اجري هذا البحث علي 73 امراة في مرحلة الحمل الاولـي تـتراوح اعمـارهن مـا بين 15-44 سنة .اوضحت النتائج :
ان 4 مريضات (5.5%) يعانين من الام في الحوض فقط , 5 مريضــات (6,8%) يعانين من الام حوض وافراز مائي , 36 مريضة (49,3%) يعانين من الم ونزيف مهبلي و28 مريضة (38,4%) يعانين من الم ونزيف مهبلي وافراز مائي معا .
واوضحت الدراسة ايضا ان 13 مريضة (17,8%) اجهـاض كامـل , مريضـتين (2,7%) حمـل خـارج الرحـم , 16 مريضــة (21,9%) اجهـاض غيـر كامـل , 4

مريضات (5,5%) حمل طبيعي , 3 مريضات(4,1%) اجهاض مهدد , 13 مريضة (17,8%) اجهـاض غيـر معـروف , 8 مريضـات (11%) اجهـاض بسـيط و 5 مريضات (6,8%) حمل مصحوب بنزيف مهبلي .

List of contents

No	Topic	Page
	Chapter one	
1.0	Introduction	1
1.1	The scope of study	1
1.2	The problem statements	2
1.3	Research hypothesis	2
1.4	Research objectives	2
1.4.1	General objectives	2
1.4.2	Specific objectives	2
1.5	Significance of study	2
1.6	Overview of the study	2-3
	chapter two	
2.0	Anatomy of the Uterus	4
2.0.1	The uterus	4
2.0.1.1.	Structure of the Utters	5
2.0.1.3	The blood supply of the uterus	6
2.0.2	The vagina	6
2.0.2.	The structure of the vagina	7

1
2.0.2. The blood supply of vagina 7
2
2.0.2. The hypothetic drainage of vagina 7
3
2.0.3 The vulva 8
2.0.4 Ovaries 9
2.0.4. The structure of the ovany 9
1
2.0.4. The blood supply of the ovaries 11
2
2.0.5 The Uterine tubes 11
2.0.5. The structure of Uterine tubes 11
1
2.1 Physiology and Uterine tubes 12
2.1.1 Menstrual cycle 12
2.1.2 Pregnancy 15
2.2 Pathology of the Uterus 15
2.2.1 Causes pain in the pelric organs 15
2.2.2 Pelvis inflammatory Diseases 16
2.2.3 Interstitial cystitis 16
2.2.4 Premenstaval syndrome 17
2.2.5 Menstural cramps 17
2.2.6 Pelvic organ prolapsed 17
2.2.7 Abdominal adhesions 17
2.2.8 Miscarriage 18
2.2.9 Types of abortions 18
2.2.9. Threatened abortion 18
1
2.2.9. Inevitable abortion 19
2
2.2.9. Complete abortion 19
3
2.2.9. Incomplete abortion 20
4
2.2.9. missed abortion 20
5

2.2.1 Molar pregnancy 21
0
2.2.1 Corpus luteum 22
1
2.2.1 Ectopic pregnancy 22
2
2.2.1 Scar pregnancy 23
3
2.2.1 Fibroids 23
4
2.2.1 Blighted Ovum 24
5
2.2.1 Ovarian cyst 25
6
2.2.1 Others 26
7
2.3 Previous studies 26
Chapter three
3.1 Material and methods 28
3.2 Methods 28
3.3. High definition and transvaginal 30
probe
3.4 Research design 30
4.5 Population and sample 30
3.6 Data collection 31
3.7 Data analysis 30
Chapter four
Results 32.-39
Chapter five
5.1 Discussion 40
5.2 Recommendations 42
5.3 Conclusion 53
5.4 References 44
5.5 Appendix

List of figures

Figure 2-1 uterus
Figure 2-2 vagina
Figure 2-3 Vulva
Figure 2-4 Ovaries
Figure 2-5 Menstrual cycle
Figure 2-6 threatened abortion
Figure 2-7 inevitable abortion
Figure 2-8 complete abortion
Figure 2-9 incomplete abortion
Figure 2-10 missed abortion
Figure 2-11 Molar pregnancy
Figure 2-12 Ectopic pregnancy
Figure 2-13 fibroid
Figure 2-14 Blighted Ovum
Figure 2-15 Ovarian cyst
Figure 4-1 sample age classes
Figure 4-2 Number of delivery
Figure 4-3 clinical signs, frequency and percentage
Figure 4-4 causes of abortion and percentage
Figure 4-5 linear relationship between the clinical sign and ultrasound findings
Figure 4-6 linear relationship between age and Ultrasound findings
Figure 4-7 Linear relationship between number of deliveries and Ultrasound findings

List of tables

Table 4.1 The sample, age classes , percentage

Table 4.2 Number of delivers

Table 4.3 clinical sign, frequency and percentage

Table 4.4 Ultrasound findings

Table 4.5 classification of abortion

Table 4.6 correlation between variables.

Table 4.7 coefficient , variables age and diagnosis

Table 4.8 coefficient , variables (number of deliveries)