

## **Chapter Three**

### **Materials and Methodology**

#### **3.1-Materials :**

Sonograms were obtained with an HDI 5000 or HDI 3000 system (Philips Medical Systems, Bothell, WA) or an Acuson 128XP system (Siemens Medical Solutions, Mountain View, CA). Evaluation is done multiple, clinical and sonographic variables, including lesion size, location, echogenicity and color Doppler.

#### **3.1.1-Type of transducer:**

- Real time or Linear curved linear transducers.
- High frequency: 7MHz or higher.
- Sufficient resolution to detect characteristics of lesions.
- Highest possible Doppler frequencies: 5 to 10 MHz.
- Total US exposure as low as reasonably achievable –ALARA –Principle.
- Standoff pad can be used to improve imaging.

#### **3.1.2-Sonographic technique of scrotum:**

- Supine position & scrotum supported by towel
- Testes examined in two planes: longitudinal & transverse
- Skin thickness in each hemi-scrotum evaluated
- Color & Pulsed Doppler optimized for low-flow velocity
- Compare both testes for size, echogenicity & vascularity
- Compare both epididymis for size, echogenicity & vascularity
- Bilateral testicular spectral Doppler tracings recorded
- Palpable scrotal lesion –put probe on it
- Acute scrotum –asymptomatic side scanned first Power Doppler also used
- Tumor of testes found –search for abdominal adenopathies
- *Ultrasound gel* is a conductive medium placed on the skin during *ultrasonic* procedures; it's used to improve *ultrasound* quality. Don't use cold gel to

avoid contraction of scrotum during ultrasound procedure. Alternatively, one can request the patient to support the penis with his hand in a cephalad direction and a drape can be placed on top. Additional views were also obtained in coronal and oblique planes, with the patient being upright.

### **3.2 Design of the study:**

Prospective cohort

### **3.3 Population of the study:**

The medical records and ultrasound images of 315 male patients with testicular pathology were reviewed. The patients were aged from newborn to 90 years (mean age, 35.2 years).

### **3.4 Sample size and types:**

ultrasound images of 315 male patients with testicular pathology were reviewed.

### **3.5 Duration and place of the study:**

The patients were collected and reported by radiologists at King Fahad and Dr. Suliaman AL-habib -Hospitals- Al –gassim region –Saudi Arabia -between 2012 and 2015.

### **3.6 Method and data collection technique:**

Patients are came to sonographic department at King Fahad and Dr. Suliaman AL-habib -Hospitals- All patients with infertility, scrotal swelling, scrotal pain, varicocele, scrotal trauma or erectile dysfunction underwent scrotal ultrasonography. Additional technique – Valsalva or upright positioning.

### **3.7 Method of data analysis:**

For analysis, result and discussion, we have used axial. Duration of clinical follow-up, or at least 6 months of clinical follow-up with sonography. Clinical follow-up was defined as a subsequent visit and physical examination with the original referring physician or a complete medical history and physical examination with another institutional physician. Although many of the patients had follow-up scrotal sonography, this was required for inclusion only if the duration of clinical follow-up

was between 6 and 12 months. If any patient had more than 1 mass, only the largest mass was considered in this study. We reviewed each patient's clinical history for age, the duration of clinical follow-up, the presence of pain, a history of orchidectomy, and prior vasectomy. The histologic diagnosis was obtained from the pathologic report if available. Other information gathered from the history included clinical changes before surgery, growth of the mass according to patient reports or physical examinations, and the clinical reasoning for pursuing surgery. From the patient information reviewed all scrotal sonograms for the following features: location in the testis (right or left), location in the epididymis (head, body, tail, or multiple sites), largest diameters, echogenicity compared with the surrounding testicular or epididymal tissue, presence of color Doppler flow, calcifications, and definitions of borders (well circumscribed or poorly defined borders). Pathologic diagnoses for all available specimens were reviewed by a genitourinary pathologist and categorized as inflammatory or neoplastic processes. Neoplastic masses were subclassified as benign or malignant. Statistical analysis was performed for malignant versus benign lesions and for masses treated with surgical excision versus observation. Lesions that were unchanged on clinical follow-up were considered benign.

## Chapter Four Result

### 4.1-Frequency of testicular pathology and sonographic characteristic;

The following chapter will highlight the results related to characterize -testicular pathology in forms of bars percentage.

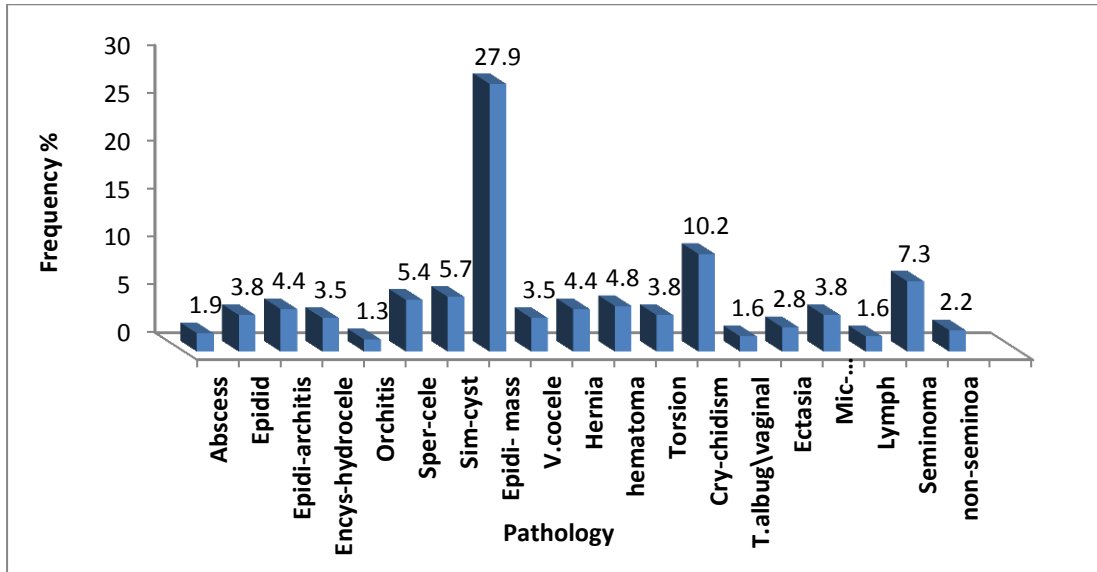


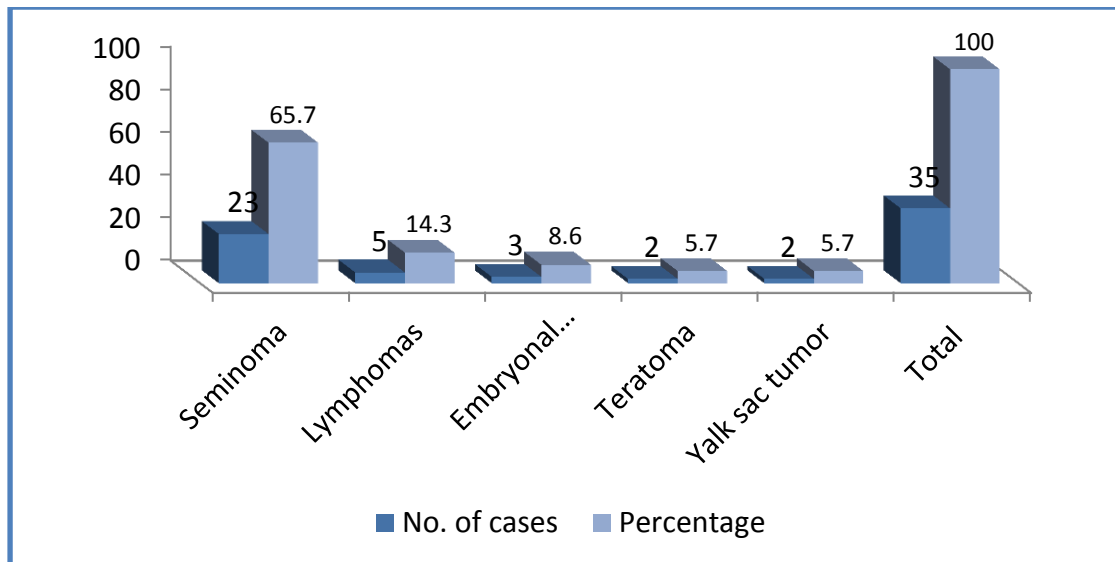
Figure (4.1) -General frequency of testicular pathology.

**Table (4.1) shows -sonographic features of testicular pathology**

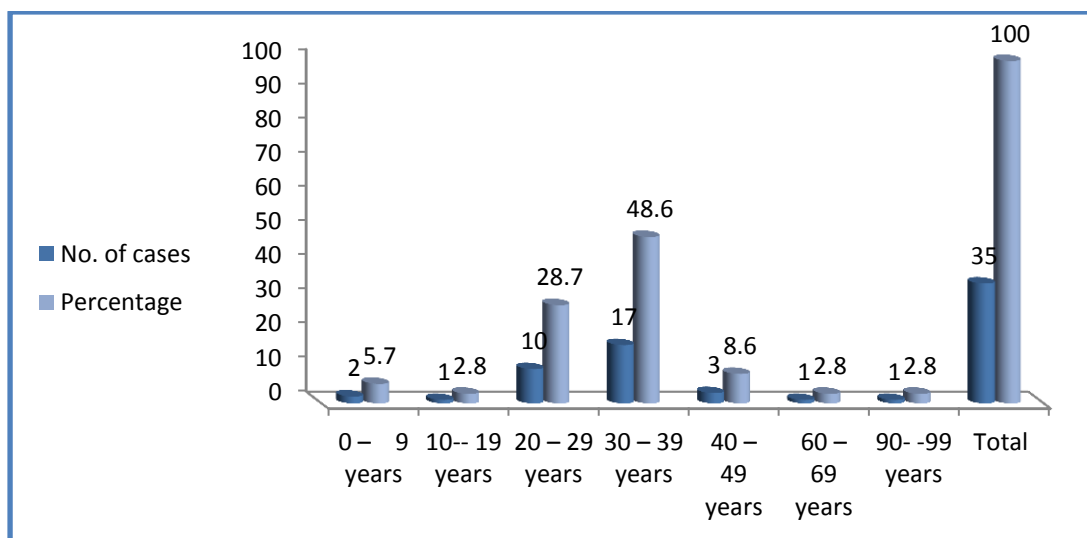
Type of Pathology	Sonographic apperance
Seminoma	Hypoechoic, homogeneous mass
Non-seminoma	heterogeneous,cystic mass
Lymphoma	An anechoic mass with or without testicular enlargement
Microlithiasis&calcification	Multiple tiny hyperechoic masses
Simple testicular cysts	An anechoic mass,give enhancement
Epididymal masses	77.3% cystic masses (anechoic),22.7% hyperechoic
Spermatocele	Difficult to differentiation spermatocele from epididymal cyst (anechoic mass)
Tunica albugineaand vaginal cyst	An anechoic mass
Intratesticular abscess	Hypoechoic mass
Epididymo-orchitis	Enlarged epididymis, enlarged testis (heterogeneous)
Epididitis	Enlarged epididymis
Orchitis	Enlarged testis
Encysted hydrocele	Hypoechoic area
Vascular lesion (varicocele)	Dilatation of vein more than 2mm
Tubular ectasia	Dilatation of the rate testes
Cryptorchidism	Not present(seen) in the scrotal sac
Intratesticular haematoma	Early stage seen hyperechoic,after begin accumilation of blood seen as free fluid
Torsion	Absence of colour flow to testis
Inguinal hernia	Hypoechoic area in scrotum accurated by visible of peristaltic movement of bowels

**Table.(4.2) show types of lesion,number of patients and side effected (unilateral or bilateral).**

Type of Lesion	No.	mean age	Unilateral		Bilateral
			Right	Left	
<b>Seminoma</b>	<b>23</b>	<b>32years</b>	<b>13</b>	<b>8</b>	<b>2</b>
<b>Non-seminoma</b>	<b>7</b>	<b>30.8years</b>	<b>5</b>	<b>2</b>	
<b>Lymphoma</b>	<b>5</b>	<b>42 years</b>	<b>3</b>	<b>1</b>	<b>1</b>



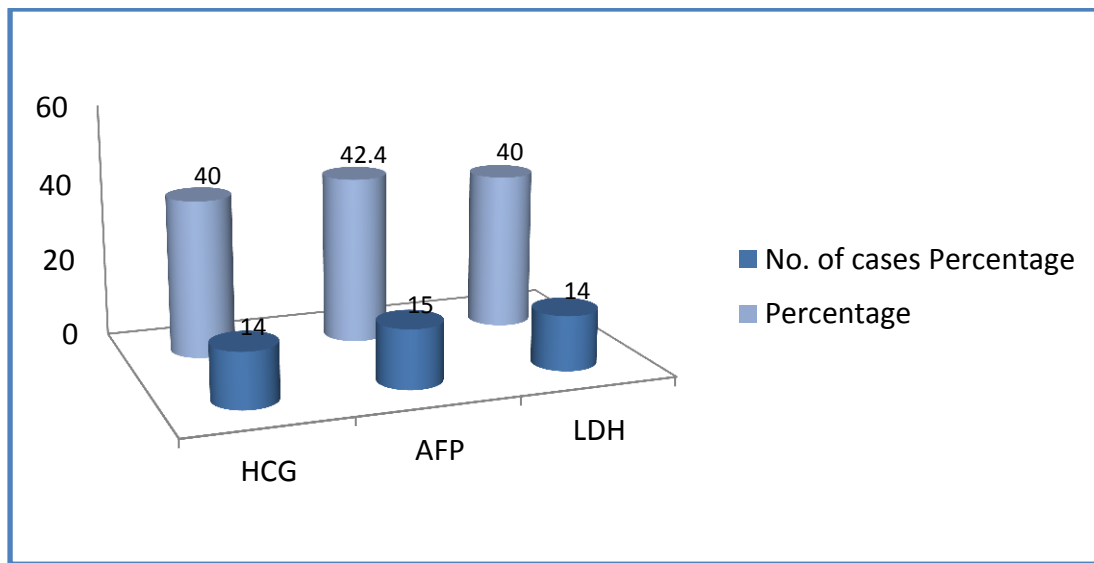
**Figure (4.2) - shows number of testicular tumors as per histological type (As per W.H.O. classification).**



**Figure (4.3) –shows age wise distribution of 35 testicular tumors.**

**Table (4.3) - shows detailed information of clinical presentation in 35 cases of testicular tumors.**

Presenting features	Seminoma	Yolk-sac tumor	Embryonal carcinoma	Teratoma (all types)	Lymphoma
Swelling of scrotum only	12	1	1	1	3
Swelling of scrotum with pain	6	0	0	1	2
Swelling of scrotum with hydrocele	3	1	1	0	0
Cryptorchidism	2	0	1	0	0
Lymphadenopathy	0	0	0	0	0



**Figure (4.4) –shows testicular tumors with elevated tumor marker values (n=35)**

**Table. (4.4) – shows HCG levels in germ cell tumors.**

HCG (mIU/mL)	Seminoma	Yolk-sac tumor	Embryonal carcinoma	Teratoma (all types)	Lymphoma	Total
Normal range (0-5)	12	2	2	2	3	21
< 5,000	8	0	0	0	1	9
5,000 – 50,000	3	0	0	0		3
> 50,000	0	0	1	0	1	2

**Table. (4.5) shows- AFP levels in germ cell tumors**

AFP (ng/mL)	Seminoma	Yolk-sac tumor	Embryonal carcinoma	Teratoma (all types)	Lymphoma	Total
Normal range (<40)	20	0	0	0	1	21
< 1,000	3	1	1	1	1	7
1,000 – 10,000	0	1	1	0	1	3
> 10,000	0	0	1	1	2	4

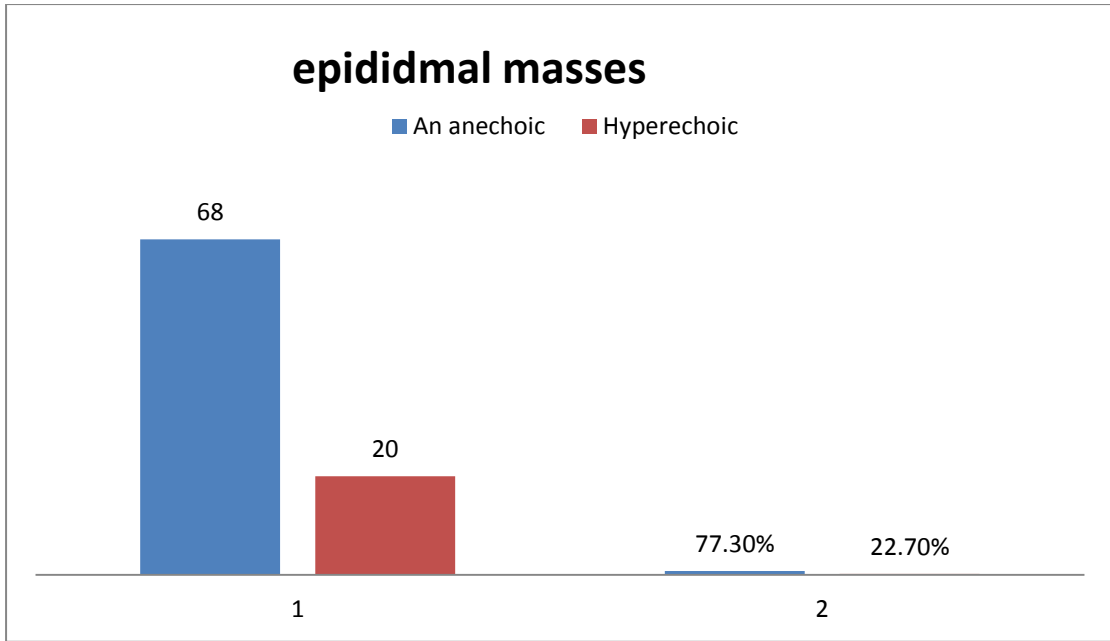
**Table. (4.6) – showsLDH levels in germ cell tumors.**

LDH (ukat/l)	Seminoma	Yolk-sac tumor	Embryonal carcinoma	Teratoma (all types)	Lymphoma	Total
Normal range (1.5– 3.2)	17	1	1	0	1	20
< 1.5X N	5	1	1	1	2	10
1.5 – 10 X N	1	0	1	1	1	4
> 10 X N	0	0	0	0	1	1

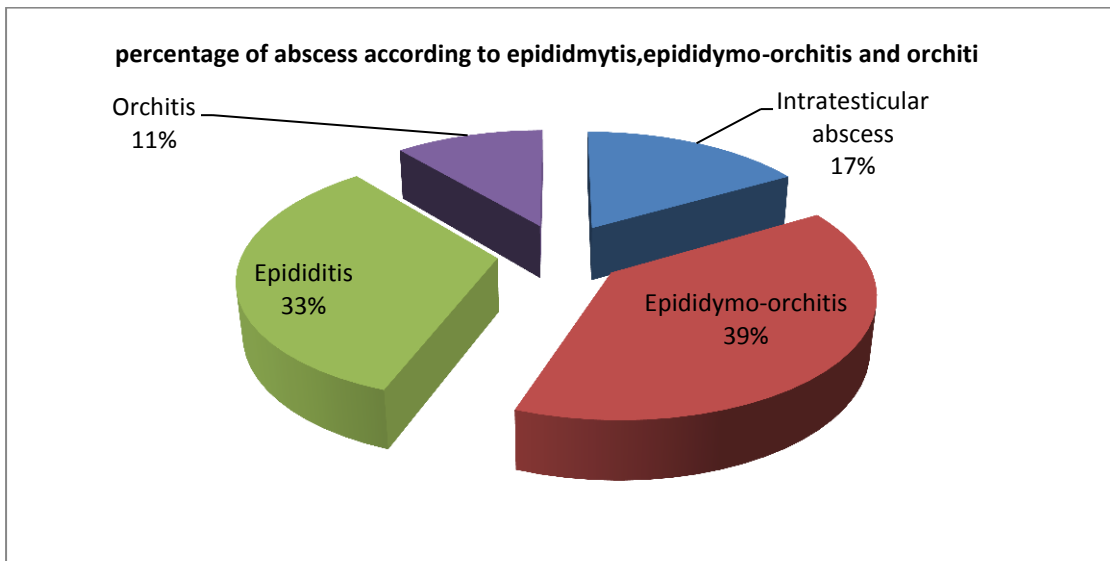
**Table- (4.7) for a follow-up period after operation**

operation	Age	Causes	Follow up	findings
Left orchidectomy	90	Lymphoma	1 year	No significant change
right orchidectomy	61	teratoma	5 months	Multiple cystic masses
right orchidectomy	22	Torsion	1 month	Small hydro dense area in right testis
Left orchidectomy	30	Seminoma	1 month	Solitary calcification
Left orchidectomy	38	seminoma	1 year	Increase vascularity in right epididymis
Left orchidectomy	22	Hematoma	1 year	Cystic mass
right orchidectomy	29	Seminoma	1 year	No evidence of focal lesion
Left orchidectomy	50	Hernia	6months	calcification
Left orchidectomy	49	Hernia	2months	Small cyst in right testis

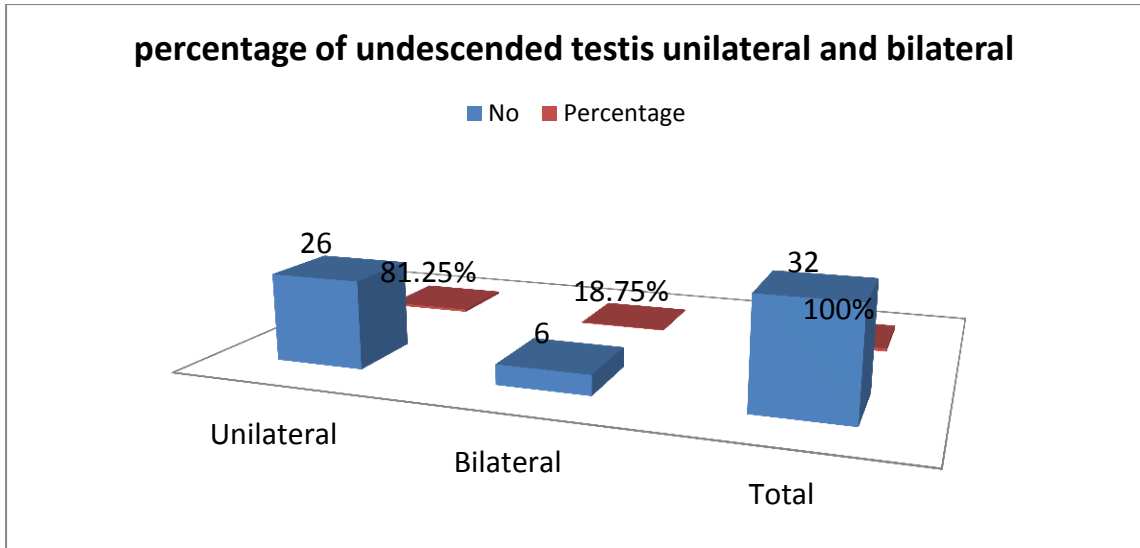




**Figure 4.5 show epididymal masses percentage of cystic and solid**



**Figure (4.6) show percentage of abscess according to epididitis, epididymo-orchitis and orchitis.**



**Figure (4.7) show percentage of undescended testis (unilateral and bilateral)**

## Chapter Five

### Discussion, Conclusion and Recommendation

#### 5.1 Discussion

figures. (Figure 4.1) shows the general frequency of testicular pathology in percent. It reveals that: testicular cancer such as, seminoma 23 (7.3%), non-seminoma 7 (2.2%) hypoechoic masses and Lymphoma 5 (1.6%) heterogeneous in appearance. 12 (3.8%) tiny hyperechoic microlithiasis and calcification, epididymal masses 88 (27.9%), most of solid epididymal masses hypoechoic, more than (75%) on the head, scrotal pain, varicocele and scrotal trauma (hematoma) were found in 15 (4.8%) seen heterogeneous on ultrasound, benign cyst such as simple cyst 18 (5.7%) smooth an anechoic give enhancement, tubular ectasia 9 (2.8%) dilatation of the rete testes, tunica albuginea and virginals' cyst 5 (1.6%), encysted hydrocele 11 (3.5%) anechoic fluid collection, spermatocele 17 (5.4%) an anechoic smooth lesion, Scrotal hernia 14 (4.4%) hypoechoic mass, testicular torsion 12 (3.8%) absence of blood flow. To all patients with infertility investigated with ultrasound for varicocele 11 (3.5%) dilatation of vein more than 2mm, and other causes such as abscess 6 (1.9%) a hypoechoic lesion, usually secondary to epididymo-orchitis 14 (4.4%), epididymitis 12 (3.8%) and orchitis 4 (1.2%) enlargement just of testis. Undescended testis occurred in 32 (10.2%), ectopic not seen in normal location (table 4.1) reveals sonographic feature of scrotal pathology. In this study the tumors size range from 0.4cm to 3.95cm but most of them less than 1.2cm.

Germ cell tumors arise from spermatogenic cells and are almost uniformly malignant. Germ cell tumours are broadly divided into seminomatous and non-seminomatous types. Non-germ cell tumors represent the remainder of primary and secondary testicular tumors, and are made-up of sex cord stromal tumours (Leydig or Sertoli cell

tumors), lymphoma and metastasis. The most common pure germ cell tumors occurred in an older population, with an average patient age of 40.5 years (**Ercan et al, 2007**).

- **Seminoma:**

Seminoma account 23 (7.3 %), the patients were aged 23 to 48 years (mean age, 32 years). Clinical characteristics and ultrasound findings of patients with seminoma were compared to those of patients with non-seminoma. Ultrasound images of seminoma were more often hypoechoic, homogeneous, and lobulated than those of non-seminoma. There was no difference in tumor size, multiplicity, presence of calcium or lesion margination. Testicular microlithiasis was more common in seminoma more than 52% occurred in the right side.

- **Non-seminoma:**

Non-seminoma represented in 7 (2.2%), the patients were aged 1 to 61 years (mean age, 30.8 years). Images of non-seminoma were more often heterogeneous and Cystic. There was no difference in tumor size, multiplicity, presence of calcium or lesion margination, in both tumor of seminoma and non-seminoma. Teratomas are also germ cell tumors, occurred in two patients. On ultrasonography teratomas appear as hypoechoic masses with foci of increased echogenicity due to calcifications, which are common. Cystic components are also common. (Malignant transformation into a teratocarcinoma is documented. In the pre-pubertal testes a pure teratoma is considered benign and testis-sparing surgery may be undertaken, but this is not the case for the post-pubertal teratoma which will metastasize irrespective of the histological features. Embryonal cell carcinoma tends to act more aggressively than does seminoma. Metastasis is not uncommon. This kind of tumor is also hypoechoic but is more inhomogeneous and less defined on ultrasonography because of cyst formation and hemorrhage calcification can also be

occurred. Of the non-seminomatous germ cell tumours, mixed germ cell tumours are much more common than any of the pure histological forms. Embryonal carcinoma is the most common component, and is often combined with one or more components of teratoma, seminoma and yolk sac tumour. The imaging findings reflect the diversity of the components of these lesions. On B-mode images these tumors showed inhomogeneous, with areas of increased echogenicity, calcification and cyst formation. Increased vascularity not demonstrated, and therefore may be mistaken for a benign avascular abnormality, such as a segmental infarction or focal scarring.

- **Lymphoma :**

Lymphoma is one of the most frequent testicular tumors seen in older men. It is the most frequent bilateral testicular neoplasm, accounting only five cases- age range from 29 to 90 years. The second most frequent testicular metastatic cancer is leukemia. The ultrasonographic appearance is generally that of an anechoic mass with or without testicular enlargement, and the testicular contour is generally preserved. (4.2). The most frequent type of lymphoma to affect the testis is non-Hodgkins lymphoma, with sonographic appearances similar to germ cell tumours particularly a seminoma.

- **4.3-Histological diagnosis of testicular tumors**

During the period from January 2012 to June 2015, 315 cases of scrotal pathology in male patients were diagnosed, out of which 35 (11.11%) were testicular tumors. The testicular tumors studied were classified in accordance with WHO (World Health Organization) classification. Out of 35 cases, 85.7% were germ cell tumors, while only 2 (5.7%) for each teratoma and yolk sac tumor, embryonal carcinoma 8.6% (n=3) and lymphomas 14.3% (n=5) were seen. Seminoma was the most common (65.7%). (Figure.4.2)-shows detailed histological diagnosis and number of cases of

each testicular tumor encountered in our study. The age range of testicular tumors in this study was wide, youngest being 1 year to eldest being 90 years of age. 77% (n=27) cases were seen in age of 20-39 years. While 2.8% (n=1) seen in age group 10-19 years. (Figure 4.3) shows detailed age-wise distribution of all 35 cases. In present study, 90.1% (n=32) cases had unilateral involvement of testis. Only 3 cases showed bilateral involvement two seminoma and one lymphoma. In the present study, right testis was slightly more affected than left testis. Seminoma was commonly seen in right testis (n=12). Embryonal carcinoma was seen equally in both right and left testis. 32 patients (90.1%) out of total 35 patients in this study had scrotal swelling. Table. (4.3) - shows detailed clinical presentations of all 35 cases based on their histologic types. Amongst tumor markers, LDH was raised in 40% (n=14) cases. Whereas AFP was raised in 15 (42.8%) cases and HCG was raised in 14 (40%) cases (Figure 4.4). In present study, out of 35 cases, 60% (n=21) had normal HCG values. 25.7% (n=9) of patients had serum HCG values < 5000 mIU/mL. Maximum no of seminomas (n=7) had raised HCG value. One case each of embryonal carcinoma and lymphoma had raised HCG levels. Only 2 patients had very levels of serum HCG i.e >50,000 mIU/mL, indicating poor prognosis. Table. (4.4) Shows details of HCG levels in various testicular tumors based on histologic types. From total 35 cases, 21 (60%) cases had normal AFP levels. 2.8% (n=1) each of teratoma and embryonal carcinoma and yolk sac tumor has elevated AFP levels. Out of total 14 patients with raised AFP levels, 4 (11.4%) had very high levels indicating poor prognosis and 3 (8.6%) indicated intermediate prognosis table (4.5), shows details of AFP levels in various testicular tumors based on their histological types. Out of total 35 cases, 57.1% (n=20) cases had normal LDH levels. Out of these 15 cases with raised LDH

levels, 40 % ( n=6) were seminomas and 60 % ( n=9) were NSGCT and lymphoma Table (4.6).

- **Microlithiasis&calcification**

12 (3.8%) patients represented with calcification and microlithiasis, microlithiasis 5 bilateral and two in left sides, but the patient with calcification 3 in right and 2 in left side. The patients age 16 to 80. Testicular microlithiasis ( $\geq 5$  or more microcalcifications within a testicle) results from concentric cores of calcification of intrasubstance collagen fibers. Testicular microlithiasis (TM) is an entity of unknown etiology that results in formation of intratubular calcifications. It is often detected incidentally when scrotal ultrasonogram is done for various indications. Testicular microlithiasis is often multiple, uniform, small, echogenic polytopic intratubular calcifications without acoustic shadows (**Janze et al, 1992**). A study of 9 patients with surgically proved testicular tumors was performed to determine the appearance at color Doppler ultrasound (US) scanning. There was a general correlation of tumor size and vascularity. 2 of 5 (40%) tumors larger than 1.8 cm were hypervascular. 1 of 5 (20%) tumors smaller than 1.8 cm was hypovascular. One small, 1.2-cm-diameter seminoma was hypervascular, and one 2.9-cm-diameter seminoma was hypovascular. The histologic findings of the tumor did not correlate with the vascularity of the lesion as seen at color Doppler US. The gray-scale findings, as well as history and physical examination findings, correctly suggested a neoplasm in all cases. The findings at color Doppler US were prospectively interpreted as indicative of neoplasm in 4 cases and as indicative of inflammation in one case. The radiologist concludes that color Doppler US scanning has only a limited role in the evaluation of testicular tumors. In three patients (one with testicular tumor, two who preferred surgical exploration with the agreement of the referring clinician), the diagnosis was confirmed at histologic

examination. Two of these patients underwent emergency surgery, and the third underwent surgery 2 week after the onset of symptoms and repeated ultrasound before the operation. For the other 2 patients the final diagnosis was based on a combination of clinical findings (regression or cessation of symptoms, no tumor marker abnormalities, no palpable testicular mass) and ultrasound evidence of improvement (size reduction or shape change from oval to wedge) during a follow-up period of at least 2 month post-operative evaluation and follow-up, table (4.7).

- **Simple testicular cysts**

Testicular cysts occurred approximately 18 (5.7%) of patients, most of testicular cyst in the right testis and 40% bilateral. The patients were aged 2 to 70 years (mean age, 38.5 years), occurred near the mediastinum, and associated with extra testicular spermatoceles, simple cysts have shown an imperceptible wall, an anechoic center, posterior enhancement and through transmission, with sizes ranging from 2 mm to 2.5 cm in diameter (**Dogra et al, 2001**). Three cases in this study have a complicated testicular cyst.

- **Epididymal masses:**

The purpose of this study was to determine whether benign and malignant masses of the epididymis can be distinguished on the basis of the clinical history and sonographic appearance. In this study, epididymal masses 88 (27.9%), the patients were aged from new born to 85 years (mean age, 41.8 years). The patient information reviewed all scrotalsonograms for the following features: location (right or left), location in the epididymis (head, body, tail, or multiple sites), largest diameters, echogenicity compared with the surrounding epididymal tissue, presence of color Doppler flow, calcifications, and definitions of borders. 65 (73 %) of epididymal masses are unilateral, most of them hypoechoic, cystic and more than 75% on the



head of epididymis. Solid epididymal masses (80%) out of them are suspiciously benign. A size of greater than 1.6 cm and the presence of color Doppler flow may help identify possible malignant masses. Cystic masses of the epididymis include the simple epididymal cyst and often bigger, multilocular. Most epididymal cysts involve the head of the epididymis; they can also involve the epididymal tail or body. Spermatoceles contain spermatozoa, whereas epididymal cysts contain clear fluid. Ultrasonography cannot dependably differentiate between these 2 entities. Spermatoceles and epididymal cysts are generally clinically asymptomatic and not treated unless symptomatic (Choyke et al, 1997). The query of the database yielded 20 cases with solid epididymal masses (Figure 4.5), of these, 5 were excluded because of lack of clinical follow-up. Although some of these patients had clinical follow-up at outside institutions, to maintain consistency in clinical review, these cases were withdrawn. Two cases were excluded after additional review of the images showed no distinct epididymal mass or a mass located outside of the epididymis. The final group involved 12 cases of solid epididymal masses, included in the study, had clinical follow-up of more than 1 year (mean, 40 months; median (range), (12– 32--40) months). One patient had 10 months of clinical follow-up and subsequent negative scrotal sonographic findings. Advice clinical correlation and follow up continue to remain patients. The result remains suspicious of a primary epididymal adenocarcinoma or benign epididymal masses.

- **Spermatocele:**

17(5.4 %) representing as spermatocele, nine in right side, six in the left and two bilateral. Only one representing as spermatic cord cyst (cystic dilatation of efferent ductules). May be associated with hydrocele or orchitis and epididymitis. Spermatocele measurement range from large to small 0.6 x 0.5 cm to 2.32 x 1.58 cm. Age of

patients from 1 to 72 years. They usually sit near the top and/or behind the testicle, but appear separate from the testis. Spermatoceles are typically smooth and they are usually filled with a whitish, cloudy fluid and usually contain sperm. Differentiation spermatocele from epididymal cyst by US not possible.

- **Tunica albuginea and vaginalis**

5 (1.6%) Tunica albuginea cyst & Tunica vaginalis focal calcification and tunica vaginalis tear. Patients age were range from 17 to 57 years. Tunica albuginea cysts are benign and arise from within the leaves of the tunica albuginea. Palpable despite being very small in size, ranging from 2 to 7 mm, these cysts meet the criteria for a simple cyst by ultrasound but see calcified or even contain of calcification (Dogra et al, 2001) of Tunica vaginalis.

- **Intratesticular abscess:**

In this study 6 (1.9 %) represent intratesticular abscess formation, the patients were aged 38 to 71. Usually secondary to epididymo-orchitis. Ultrasonography is the imaging modality is demonstrated a hypoechoic lesion within the testis marked by low-level echoes and shaggy margins. Color flow Doppler demonstrated absent internal vascularity with increased peripheral hyperemia (Stewart and Sidhu 2007) . (Figure .4.6)

- **Epididymo-orchitis :**

14 (4.4%) The patients were represented with epididymo-orchitis aged 1 up to 85 years .Some patient came with severe pain and associated with hydrocele. Acute epididymo-orchitis is a clinical syndrome consisting of pain, swelling and inflammation of the epididymis, with or without inflammation of the testes. The most common route of infection is local extension and is mainly due to infections spreading

from the urethra (sexually transmitted infections (STIs)) or from the bladder. Orchitis (infection limited to the testis) is much less common. Chronic epididymitis refers to epididymal pain and inflammation (usually without scrotal swelling) that lasts for more than six months. Grey scale and color Doppler images show a small hydrocele around the left testis. The scrotal skin also appears thickened.

- **Epididitis**

The most common cause of scrotal pain is epididymitis; an inflammation of the epididymis. It is treatable with antibiotics, if left untreated, this condition can lead to an abscess or loss of blood flow to the testicles. Ultrasound is also a valuable tool for evaluating the epididymis. 12 (3.8%) of the patients represented with epididymitis, were aged 1 to 48 years. Most of cases associated with hydrocele. Ultrasound shows markedly enlarged left epididymis with marked vascularity of the head of epididymis on color Doppler scan.

- **Orchitis**

Infection appeared as inflammation (Orchitis) affected testis four patients represented with Orchitis 4 (1.2%). (The patients age 16 to 61. Ultrasound images show in homogenous echotexture of the right testis is of normal size and echogenicity with no evidence of focal lesion. Color Doppler and Power Doppler images show markedly increased vascularity in the right testes with moderate vascularity in the left testes, however, the epididymis is replaced by large cyst (Cook and Bewbury 2000).

- **Encysted hydrocele :**

11 (3.5%) represented encysted hydrocele. The patients age range from new born to 58 years. Mostly with septation seen in the lower part of the left inguinal region extending to the hemiscrotum (Martin et al, 1996) .

- **Vascular lesions**

Intratesticular varicocele 11 (3.5%), the patients were aged new born to 58 years. Color flow Doppler has also visualized intratesticular varicoceles. A Valsalva maneuver is done for some of the vessels may not show spontaneous flow. It is present in 15 to 20 percent of post-pubertal males (**Henry et al, 2009**). In this study ultrasound classified varicocele in four grades smaller measurement of vein 2.7mm in diameter but during Valsalva maneuver measured 3.2mm but the large one 5.5 mm and Valsalva maneuver 6.5mm.

- **Tubular ectasia:**

9 (2.8%) represented Tubular ectasia; the patients were aged 27 up to 77. Tubular ectasia, also known as cystic transformation of the testis, is a dilatation of the testis as a result of partial or complete obliteration of the efferent ductules (**Sellars and Sidhu, 2001**). Tubular ectasia of the testis is a benign entity that is important to identify on ultrasonography, because it can be confused with a hypoechoic mass, which may lead to unnecessary biopsy. Ultrasonographic findings are those of hypoechoic branching cystic configurations in the mediastinum testis .

- **Cryptorchidism:**

In this study, undescended testis account 32 (10.2%), the patients were aged 1 to 41 years (mean age, 14.5 years) .is failure of descent of the testes into the scrotum during fetal development. The defect may result in the testes being located within the abdomen, inguinal canal, or some ectopic location. More than 81 % of undescended testis are unilateral and all of them seen small in size, in the inguinal region. If it is not present in the scrotal sac, it may have stopped on its way and lie in the inguinal canal, in which case the ultrasound examination will often see it. If it has not left the abdominal cavity, it may not be seen by sonography. If a testicle is not detected, an urologist may

be consulted in order to decide whether additional imaging such as an MRI is needed to determine its location. If the testicle is found to be in the inguinal canal, it can be moved into the scrotum (**Pillai and Besner, 1998**). (Figure .4.7)

- **Intratesticular haematoma:**

Intratesticular haematoma is not well described in the ultrasound literature and may be mistaken for a primary testicular malignancy if a detailed clinical history and careful ultrasound examination are not performed (**Langer 1993**). Hematoma account 15 (4.7%). The patients were aged 18 to 81 years. A clinical history coupled with Doppler ultrasound features is crucial for conservative management and accurate diagnosis.

- **Torsion:**

Torsion commonly appears during adolescence, and less often in the neonatal period. 12 (3.8%) represented testicular torsion is usually diagnosed following by orchidectomy. The patients age range new born to 48. The predisposing factors to segmental infarction include polycythaemia, intimal fibroplasia of the spermatic artery, sickle cell disease, hypersensitivity angiitis, and trauma, although the majority, as in the present case, are idiopathic in origin. Scrotal ultrasound is a valuable investigation in distinguishing intratesticular and extratesticular pathology, although it cannot always exclude testicular torsion. The B-mode ultrasound hallmark of global testicular ischaemia and infarction in the acute stage is an enlarged low reflective testis. This is followed by gradual shrinkage of the testis over time and an increase in reflectivity (**Waldert et al, 2010**). CDUS is useful in the evaluation of testicular torsion, where absence of colour flow to one testis in the presence of normal flow to the contralateral testis is diagnostic in the appropriate clinical situation .

- **Inguinal hernia**

14(4.4%) represented scrotal hernia in our study age range 1 to 90 years. Inguinal hernias begin when the intestines push through the abdominal wall by following the path of the testicles when they descended into the scrotum during fetal development. Though this path usually closes prior to birth, it leaves a weak area in the abdomen. This type of hernia generally shows itself by a bulge around the testicles. Diagnosis is supported by visualization of peristaltic activity in US .

## 5.2 Conclusion

After successful achievement of all objectives related to this study, the researcher would like to conclude that.

- Traditionally, B-mode ultrasound is extremely sensitive in the detection of testicular masses, but does not provide histological diagnosis. Although most focal lesions will be malignant and require an orchiectomy, recognition of the benign entity may be challenging.
- Ultrasound is a sensitive and accurate technique for the evaluation of testicular abnormalities, and is widely accepted as the first-line imaging technique for many common and uncommon testicular diseases.
- Color Doppler ultrasonography is an excellent, a safe, and reliable method for evaluating patients with scrotal diseases. It aids in diagnosis of testicular tumors and reduces the number of unnecessary exploratory operations.
- Testicular cancer most often occurs in white males between ages 20 and 39 and doubled in white males over the last decade(in the United States)(Joseph et al,2013).
- Senoussi et al, (2006) introduced study related to epidemiology and clinical characteristics of testicular tumors in Saudi. Testicular seminomas (TS) and non-seminomatous testicular tumors (NSTT) comprised 50% each. The mean age was 41 and 27.8 years for TS and NSTT, respectively.
- Testicular tumors are 10 times less frequent in children than in postpubertal males, with a reported incidence of 0.5e1 per 100,000 children compared to 5.4 per 100,000 adults Liniger et al (2012).
- Purushothaman et al, (2007); they have found that, the ultrasound literature may be mistaken for a primary testicular malignancy if a detailed clinical history and careful ultrasound examination are not performed. Ultrasound is highly sensitive in detecting testicular tumours with the specificity of ultrasound depending on the clinical referral pattern (Sidhu et al, 2006).
- Appropriate clinical history and sonographic features (gray-scale and color Doppler) almost always allow the correct diagnosis.

- Our study concludes that malignant testicular tumors exhibited a varied histomorphology of tumors. Germ cell tumors form the bulk of testicular tumors. Among the individual germ cell tumors, seminomas 23(65.7%) are the commonest followed by non-seminomas 7(20%) and lymphoma5 (14.3%).
- In our study the testicular tumors are commonest in third and fourth decade of life. All the yolk-sac tumors are seen exclusively in children. The most common clinical presentation is swelling of the scrotum with some patients having associated pain and hydrocele.
- Ultrasound is effectively the sole scrotal imaging technique that a patient will undergo prior to surgery, can be used in the setting of Trauma to evaluate damage to scrotal contents, but should be followed with MRI if non diagnostic.
- Serum tumor markers are raised in maximum number of germ cell tumors but not in any non germ cell tumor. AFP is raised in maximum patients followed by HCG and LDH. Thus, our present study shows correlation between clinical, histology features and tumor marker levels.
- Most of the lesions in our study are hypoechoic and cystic. An incidental lesion is considered asymptomatic and non palpable with negative markers.
- On B-mode ultrasound, seminomas typically appear as a solid round homogeneous low-reflectivity mass without calcification inside the tumor mass, reflecting their uniform cellular nature. On CDUS there is demonstrable vascularity within the lesion of seminoma.
- 65 (73 %) of epididymal masses are unilateral, most of them hypoechoic, cystic and more than 75% on the head of epididymis.
- Sonography revealed injured outside the testes. Hence, the value of ultrasound scanning in evaluating patients after blunt scrotal trauma was established. It complemented clinical findings and detected unsuspected testicular injury.
- The current study is characterized by a high percent of ultrasonographic lesions and a high rate of benign lesions.
- Ultrasonography continues to be a fast and effective modality for evaluation of the acutely painful scrotum, scrotal masses, and male infertility.



### 5.3 Recommendations

- The highest frequency transducer that allows for adequate penetration should be used to maximize the Doppler shifts.
- Testicular ultrasound should be mandatory assessment
- Orchidectomy and pathological examination of the testis are necessary to confirm the diagnosis.
- An ideal follow-up schedule identifies a recurrence early without causing harm by using unnecessary radiation in these young long-term survivors.
- B-mode ultrasound is extremely sensitive in the detection of testicular masses, but must be provided histologically.
- Follow-ups could be formulated based on the knowledge of different recurrence risks and recurrence patterns.
- Careful evaluation and follow-up is advised in those at high risk of developing testicular cancer like cryptorchidism, infertility, testicular atrophy and contralateral testicular cancer.
- Patients of testicular cancer should therefore be grouped into risk categories.
- High-resolution US Doppler ultrasound (CDUS) and Knowledge of the normal appearance of the testis and scrotal contents and familiarity with the many pathologic conditions is needed for accurate diagnosis.
- The diffusion of scrotal ultrasonography in urology and andrology has caused an increase in the detection of focal testicular lesions that are not always easy to interpret.
- Comparison of the Doppler waveforms of the symptomatic and asymptomatic testis should be used as comparison of the gray scale images.
- Appropriate clinical history and sonographic features (gray-scale and color Doppler) almost always should be done to allow the correct diagnosis.
- Ultrasonography is the standard imaging technique used to identify testicular carcinoma. It has a high sensitivity, but it must be combined with physical examination to achieve the best specificity.
- In intra-testicular cystic lesions rare –avoid unnecessary surgical intervention.

## References:

Ada Kessler, MD, Shmuel Meirsdorf, MD, Moshe Graif, MD, Paul Gottlieb, MD, Simon Strauss, MBChB, Intratesticular Varicocele Gray Scale and Color Doppler Sonographic Appearance, *Ultrasound Med* 2005; 24:1711–1716 • 0278-4297/05/\$3.50.

Aguado A, Grant TH, Miller FH, Garnett J. Radiation-induced fibrosis of the spermatic cord: sonographic and MRI findings. *AJR Am J Roentgenol* 2005; 184:S102–103.

Akbar SA, Sayed TA, Jafri SZ, Hasteh F, Neill JS. Multimodality imaging of paratesticular neoplasms and their rare mimics. *Radiographics* 2003; 23:1461–1476.

Anderson, J.E., Grant's Atlas of Anatomy eighth edition, Williams & Wilkins, Baltimore, MD, 1983.

Bach AM, Hann LE, Shi WT, Yoo HH, Giess CS, Sheinfeld J, et al. Testicular microlithiasis: what is its association with testicular cancer? *Radiology* 2001; 220:70–5.

Baer HM, Gerber WL, Kendall AR, Locke JL, Putong PB. Segmental infarct of the testis due to hypersensitivity angitis. *J Urol* 1989; 142:125–127.

Becker D, Burst M, Wehler M, Tauschek D, Herold C, Hahn EG. [Differential diagnosis of acute testicular pain using color-coded duplex ultrasonography: difference between testicular torsion and epididymitis]. *Dtsch Med Wochenschr.* 1997; 122:1405–9.

Beddy P, et al. Testicular varicocele. *Clinical Radiology.* 2005; 60:1248–1255.

Bertolotto M, Derchi LE, Sidhu PS, Serafini G, Valentino M, Grenier N, Cova MA. Acute segmental testicular infarction at contrast-enhanced ultrasound: early features and changes during follow-up. *AJR Am J Roentgenol* 2011.

Bird K, Rosenfield AT. Testicular infarction secondary to acute inflammatory disease: demonstration by B-scan ultrasound. *Radiology* 1984; 152:785–788.

Bosl GJ, Motzer RJ. Testicular germ-cell cancer. *N Engl J Med* 1997.

Brehmer-Andersson E, Andersson L, Johansson JE. Hemorrhagic infarctions of testis due to intimal fibroplasia of spermatic artery. *Urology* 1985; 25:379–382.

Bushby LH, Sriprasad S, Hopster D, Muir G, Clarke JL, Sidhu PS. High frequency colour Doppler US of focal testicular lesions: crossing vessels (criss-cross pattern) identifies primary malignant tumours. *Radiology* 2001; 221:449.

Cast JE, Nelson WM, Early AS et al. Testicular microlithiasis: prevalence and tumor risk in a population referred for scrotal sonography. *AJR* 2000; 175: 1703–6.

Choyke PL, Glenn GM, Wagner JP, Lubensky IA, Thakore K, Zbar B, Linehan WM, et al (1997) Epididymal cystadenomas *in* von Hippel-Lindau disease. *Urology*.

Cook J, Bewbury K. The changes seen on high resolution ultrasound in orchitis. *Clinical Radiology* 2000; 55: 13-8.

Cook JL., Dewbury K. (2000). The changes seen on high-resolution ultrasound in orchitis. *ClinRadiol. ClinRadiol.* Jan; 55(1):13-8.

Daniel J.'s Story by Angela Generoso MedicineNet.com Reviewed by William Shiel, MD, FACP, FACR Testicular Cancer ©1996-2013 Medicine Net, Inc. All rights

Das KM, Prasad K, Szmigielski W, Noorani N. Intratesticular varicocele. Evaluation using conventional and Doppler sonography. *AJR Am J Roentgenol* 1999; 173:1079–1083.

DeBeck C, Ghasemian R. Acute segmental testicular infarction. *Int J Urol* 2006; 13:651–652.

Derouet H, Braedel HU, Brill G, Hinkeldey K, Steffens J, Ziegler M. [Nuclear magnetic resonance tomography for improving the differential diagnosis of pathologic changes in the scrotal contents]. *Urologe A*. 1993; 32:327-33.

Dieckmann KP, Boeckmann W, Brosig W, Jonas D, Bauer HW. Bilateral testicular germ cell tumors. Report of nine cases and review of the literature. *Cancer* 1986; 57:1254–1258.

Dogra V, Nathan J, Bhatt S. Sonographic appearance of testicular adrenal rest tissue in congenital adrenal hyperplasia. *J Ultrasound Med* 2004;23:979–81.

Dogra VS, Gottlieb RH, Oka M, Rubens DJ. Sonography of the scrotum. *Radiology* 2003; 227:18–36.

Dogra, V. S., Gottlieb, R. H., Rubens, D. J. and Liao, L.: Benign intratesticular cystic lesions: US feature. *Radiographics*, **21**:S273, 2001.

El-Senoussi Mohamed A., Nabil K. Bissada, Salah El-Akkad, Agop Y. Bedikian, Rafik Morcos, Colin Bull. (2006). Epidemiology and clinical characteristics of testicular tumors in Saudi Arabia: King Faisal specialist hospital and research centre experience. *Journal of Surgical Oncology: Volume 35, Issue 1, pages 39–41.*

Ercan Kocakoc, MD<sup>a</sup>, Shweta Bhatt, MD<sup>b</sup>, Vikram S. Dogra, MD<sup>b</sup> Ultrasound Evaluation of Testicular Neoplasms, Volume 2, Issue 1, January 2007, Pages 27–44.

Fitzgerald SW, Erickson S, DeWire DM, et al. Color Doppler sonography in the evaluation of the adult acute scrotum. *J Ultrasound Med*. 1992; 11:543-8.

Flanagan JJ, Fowler RC. Testicular infarction mimicking tumour on scrotal ultrasound-- a potential pitfall. *Clin Radiol* 1995; 50:49–50.

Frates MC, Benson CB, DiSalvo DN, Brown DL, Laing FC, Doubilet PM. Solid extratesticular masses evaluated with sonography: pathologic correlation. *Radiology* 1997; 204:43–46.

Frush DP, Kliewer MA, Madden JF. Testicular microlithiasis and subsequent development of metastatic germ cell tumor. *AJR* 1996; 167:889-90.

Frush DP, Sheldon CA. Diagnostic imaging for pediatric scrotal disorders. *Radiographics* 1998; 18:969-85.

Gallardo Agromayor E, Pena Gomez E, Lopez Rasines G, et al. [Testicular tumors. Echographic findings]. *Arch ESP Urol*. 1996; 49:622-6.

Ganem JP, Jhaveri FM, Marroum MC. Primary adenocarcinoma of the epididymis: case report and review of the literature. *Urology* 1998; 52:904–908.

Germaine P, Simerman LP. Fibrous pseudotumor of the scrotum. *J Ultrasound Med* 2007; 26:133–138.

Goddi A, Sacchi A, Magistretti G, Almolla J, Salvador M. Real-time tissue elastography for testicular lesion assessment. *Eur Radiol* 2012.

Gooding GA, Leonhardt W, Stein R. Testicular cysts: US findings. *Radiology* 1987; 163:537–538.

Greek G. Vasectomy: a safe, effective, economical means of sterilization. *Postgrad Med* 2000; 108:173–176, 179.

Hamm B, Fobbe F, Loy V. Testicular cysts: differentiation with US and clinical findings. *Radiology* 1988; 168:19–23.

Hedayati V, Sellars ME, Sharma DM, Sidhu PS. Contrast-enhanced ultrasound in testicular trauma: Role in directing debridement and aiding organ salvage. *Br J Radiol*. 2012 Mar; 85(1011):e65-8. Doi: 10.1259/bjr/95600238.

Heinemann V, Frey U, Linke J, Dieckmann KP. Testicular microlithiasis--one case and four points to note. *Scand J Urol Nephrol* 2003; 37:515–518.

Henry M. Rosevear, Alek Mishail, Yefim Sheynkin & Moshe Wald Unusual scrotal pathology. *Nature Reviews Urology* 6, 491-500 (September 2009).

Henry Oscar, FRCR (UK), Jeevesh Kapur, FRCR (UK), Role of Ultrasound in Management of Scrotal Abnormalities in Children, *Med J Malaysia* Vol 67 No 5 October 2012.

Holden A, List A. Extratesticular lesions: a radiological and pathological correlation. *Australas Radiol* 1994; 38:99–105.

Holmes NM, Kane CJ. Testicular infarction associated with sickle cell disease. *J Urol* 1998; 160:130.

Horstman WG, Melson GL, Middleton WD, Andriole GL. Testicular tumors: findings with color Doppler US. *Radiology*. 1992 Dec; 185(3):733-7.

Horstman WG, Middleton WD, Melson GL. Scrotal inflammatory disease: color Doppler US findings. *Radiology* 1991; 179:55-9.

Horstman, W. G., Haluszka, M. M. and Burkhard, T. K.: Management of testicular masses incidentally discovered by ultrasound. *J Urol*, **151**: 1263, 1994.

Huang, Bmedsci, Mrcpch, FRCR, EBIR and Sidhu, Focal testicular lesions: color Doppler ultrasound, contrast-enhanced ultrasound and tissue elastography as adjuvants to the diagnosis, sPublished online before print June 6, 2012, doi:10.1259/bjr/30029741.

Janze DL, Mathieson JR, Marsh JI, et al. Testicular microlithiasis: sonographic and clinical features. *AJR* 1992; 158: 1057-60.

Jeffrey RB, Laing FC, Hricak H, McAnich JW. Sonography of testicular trauma. *AJR Am J Roentgenol* 1983; 141:993-5.

Jordan GH. Segmental hemorrhagic infarct of testicle. *Urology* 1987; 29:60-63.

Joseph, Nicholas, and Clayton, Lindy J. Testicular ultrasound pathology All Site Content ©2004-2013 CE Essentials, LLC; All Rights Reserved.

Karmazyn B, Steinberg R, Kornreich L, Freud E, Grozovski S, Schwarz M, et al. Clinical and sonographic criteria of acute scrotum in children: a retrospective study of 172 boys. *Pediatr Radiol* 2005; 35:302-10.

Kessler A, Meirsdorf S, Graif M, Gottlieb P, Strauss S. Intratesticular varicocele: gray scale and color Doppler sonographic appearance. *J Ultrasound Med* 2005; 24:1711-1716.

Krone KD, Carroll BA. Scrotal ultrasound. *Radiol Clin North Am* 1985; 23:121-139.

Kutlu R, Alkan A, Soyulu A, and Sigirci A, Dusak A. Intratesticular arteriovenous malformation: color Doppler sonographic findings. *J Ultrasound Med* 2003; 22:295-298.

Langer JE. US of the scrotum. *Semin Roentgenology*. 1993; 28:5-18.

Lindsay C, Boardman L, Farrell M. Testicular hamartomas in Cowden disease. *J Clin Ultrasound* 2003; 31:481-483.

Liniger, Fleischmann, Zachariou Benign cystic lesions in the testis of children, *Journal of Pediatric Urology* (2012) 8, 226e233.

Lock G, Schmidt C, Helmich F, Stolle E, Dieckmann, KP. Early experience with contrast-enhanced ultrasound in the diagnosis of testicular masses: a feasibility study.

Urology. 2011 May; 77(5):1049-53. Doi: 10.1016/j.urology.2010.12.035. Epub 2011 Feb 18.

Loya AG, Said JW, Grant EG. Epidermoid cyst of the testis: radiologic-pathologic correlation. *Radiographics* 2004; 24 Suppl1:S243–246.

Luca Carmignani, Franco Gadda, Giacomo Gazzano, Franco Nerva, Mario Mancini, Mario Ferruti, Gaetano Bulfamante, Silvano Bosari, Guido Coggi, Francesco Rocco and Giovanni Maria Colpi, High incidence of benign testicular neoplasms diagnosed by ultrasound, *the journal of urology*® Printed in U.S.A. Copyright © 2003 by American Urological Association Vol. 170, 1783–1786.

Luker GD, Siegel MJ. Pediatric testicular tumors: Evaluation with grayscale and color Doppler US. *Radiology* 1994; 191: 561-4.

Lung PFC, Jaffer OS, Sellars ME, Sriprasad S, Kooiman GG, Sidhu PS. Contrast enhanced ultrasound (CEUS) in the evaluation of focal testicular complications secondary to epididymitis. *AJR Am J Roentgenol* 2012).

Lutzker LG, Zuckier LS. Testicular scanning and other applications of radionuclide imaging of the genital tract. *Semin Nucl Med.* 1990; 20:159-88.

Lutzker LG, Zuckier LS. Testicular scanning and other applications of radionuclide imaging of the genital tract. *Semin Nucl Med.* 1990 Apr; 20(2):159-88.

Maizlin ZV, Belenky A, Baniel J, Gottlieb P, Sandbank J, Strauss S. Epidermoid cyst and teratoma of the testis: sonographic and histologic similarities. *J Ultrasound Med* 2005; 24:1403–1409; quiz 1410–1401.

Martin LC, Share JC, Peters C, Atala A. Hydrocele of the spermatic cord: embryology and ultrasonographic appearance. *Pediatr Radiol* 1996; 126: 528-30.

Megremis S, Michalakou M, Mattheakis M, Agianniotakis E, Sfakianaki E. An unusual well-circumscribed intratesticular traumatic hematoma: diagnosis and follow-up by sonography. *J Ultrasound Med* 2005; 24:547–50.

Micallef, M., Torreggiani, W. C., Hurley, M., Dinsmore, W. W. and Hogan, B.: The ultrasound investigation of scrotal swelling. *Int J STD AIDS*, **11**: 297, and 2000.

Middleton WD, Thorne DA, Melson GL. Color Doppler ultrasound of the normal testis. *AJR Am J Roentgenol.* 1989; 152:293-7.

Mishkin FS. Differential diagnostic features of the radionuclide scrotal image. *AJR Am J Roentgenol.* 1977; 128:127-9.

Montie, J. E.: Follow-up after radical orchiectomy for testicular cancer. *Urol Clin North Am*, **21**: 757, 1994.

Muttarak M, Lojanapiwat B, Chaiwun B, Wudhikarn S. Preoperative diagnosis of bilateral tuberculous epididymo-orchitis following intravesical Bacillus Calmette-Guerin therapy for superficial bladder carcinoma. *Australas Radiol* 2002; 46:183–185.

Nagler-Reus M, Guhl L, Volz C, Wuerstlin S, Arlart IP. [Magnetic resonance tomography of the  
Naseem S, Lindley R, Mufti GR. Testicular sarcoid. *Urol Int* 2001; 67:100–101.

Nistal M, Palacios J, Regadera J, Paniagua R. Postsurgical focal testicular infarct. *Urol Int* 1986; 41:149–151.

Obinata D, Yamaguchi K, Hirano D, Fuchinoue A, Nemoto N, Takahashi S. Intrascrotal involvement of sarcoidosis presenting like testicular appendices. *Int J Urol* 2007; 14:87–88.

Parker PM, Pugliese JM, Allen RC, Jr. Benign fibrous pseudotumor of tunica vaginalis testis. *Urology* 2006; 68:e417–429.

Patel K, Sellars ME, Clarke JL, Sidhu PS (2012) Sonographic features of testicular epidermoid cysts on contrast enhanced ultrasound and real time tissue elastography. *J Ultrasound Med.*

Pavlica P, Barozzi L. Imaging of the acute scrotum. *Eur Radiol* 2001; 11: 220-228.

Pellice C, Jr., Castella JA, Alert E, Cosme MA, Comas S. Focal infarction of the testis. Report of a case simulating a gonadal mass. *Actas Urol Esp* 1995; 19:716–720.

Pillai SB, Besner GE. Pediatric testicular problems. *Pediatr Clin North Am* 1998.

Proto G, Di Donna A, Grimaldi F, Mazzolini A, Purinan A, Bertolissi F. Bilateral testicular adrenal rest tissue in congenital adrenal hyperplasia: US and MR features. *J Endocrinol Invest* 2001; 24:529–531.

Purushothaman H, Sellars ME, Clarke, JL, Sidhu, PS. Intratesticular haematoma: differentiation from tumor on clinical history and ultrasound appearances in two cases. *Br J Radiol* 2007.

Purushothaman, Sellars, Clarke, Sidhu, Intratesticular haematoma: differentiation from tumour on clinical history and ultrasound appearances in two cases, *The British Journal of Radiology*, 80 (2007), e184–e187.

Ricci Z, Koenigsberg M, Whitney K. Sonography of an arteriovenous-type hemangioma of the testis. *AJR Am J Roentgenol* 2000; 174:1581–1582.

Riley TW, Mosbaugh PG, Coles JL, Newman DM, Van Hove ED, Heck LL. Use of radioisotope scan in evaluation of intrascrotal lesions. *J Urol*. 1976; 116: 472-5.

Sandlow JI, Winfield HN, Goldstein M. Surgery of the scrotum and seminal vesicles. In: Wein AJ, ed. *Campbell-Walsh Urology*. 9th ed. Philadelphia, Pa: Saunders

Elsevier; 2007: chap 34.Scrotum. Experiences with 129 patients].Radiology.1995; 35:494-503.

Secil M, Kocyigit A, Aslan G, et al. Segmental testicular infarction as a complication of varicocelectomy: sonographic findings. J Clin Ultrasound 2006; 34:143–145.

Seethala RR, Tirkes AT, Weinstein S, Tomaszewski JE, Malkowicz SB, Genega EM. Diffuse fibrous pseudotumor of the testicular tunics associated with an inflamed hydrocele. Arch Pathol Lab Med 2003; 127:742–744.

Sellars and Sidhu, 2001, RATE TESTIS, Ultrasound of the Urogenital System, Georg Thieme Verlag 2005.

Shah A, Lung PF, Clarke J L, Sellars ME, Sidhu PS. New ultrasound techniques for imaging of the indeterminate testicular lesion may avoid surgery completely. Volume 65, Issue 6, pages 496-497, June 2010.

Shweta Bhatt, Syed Zafar H. Jafri, Neil Wasserman, Vikram S. Dogra Imaging of non-neoplastic intratesticular masses, Diagn Interv Radiol 2011; 17:52–63.

Sidhu PS. Diseases of the testis and epididymis. In: Baxter GM, Sidhu PS, editors. Ultrasound of the urogenital system. Stuttgart, Germany: Thieme, 2006: 153–80.

Simon, S. D., Lee, R. D. and Mulhall, J. P.: Should all infertile males undergo urologic evaluation before assisted reproductive technologies? Two cases of testicular cancer presenting with infertility. Fertil Steril, **75**: 1226, 2001.

Sinclair J, Ferucci P, Lovell MA, Koyle MA. Spontaneous testicular hemorrhage in an adolescent. J Urol 2003; 169:303–304.

Srigley JR, Hartwick RW. Tumors and cysts of the paratesticular region. Pathol Annu 1990; 25:51–108.

Sriprasad SI, Kooiman GG, and Muir GH, Sidhu PS. Acute segmental testicular infarction: differentiation from tumour using high frequency colour Doppler ultrasound. Br J Radiol 2001; 74:965–7.

Stewart VR, Sellars ME, Somers S, Muir GH, Sidhu PS. Splenogonadal fusion: B-mode and color Doppler sonographic appearances. J Ultrasound Med 2004; 23:1087–90.

Stewart VR, Sidhu PS. The testis: the unusual, the rare and the bizarre. Clin Radiol 2007.

Strauss S, Belenky A, Cohen M, Manor H, Avrech OM, Fisch B, et al. Focal testicular lesion after sperm extraction or aspiration: sonographic appearance simulating testicular tumor. AJR Am J Roentgenol 2001; 176:113–5.

Strauss S, Gottlieb P, Kessler P, Graif M, Heyman Z, Manor H. Non-neoplastic intratesticular lesions mimicking tumour on ultrasound. Eur Radiol 2000; 10:1628–35.



Süzer O, Ozcan H, Küpeli S, Gheiler EL. Color Doppler imaging in the diagnosis of the acute scrotum. *Eur Urol.* 1997;32:457-61.

Syed Amjad Ali Rizvi, Ibne Ahmad, Mohammed Azfar Siddiqui, Samreen Zaheer, Kaleem Ahmad, Role of Color Doppler Ultrasonography in Evaluation of Scrotal Swellings *Urology Journal* Vol 8 No 1 Winter 2011.

Tseng A Jr, Horning SJ, Freiha FS, et al. Gynecomastia in testicular cancer patients. Prognostic and therapeutic implications. *Cancer* 1985.

Ulbright TM, Amin MB, Young RH. Miscellaneous primary tumors of the testis, adnexa, and spermatic cord. Washington, DC: Armed Forces Institute of Pathology, 1999.

Valla JS for the Group D'Etude en Urologie Pédiatrique. Testis-sparing surgery for benign testicular tumors in children. *Journal of Urology* June 2001; 165: 2280-3.

Viswaroop BS, Kekre N, Gopalakrishnan G. Isolated tuberculous epididymitis: a review of forty cases. *J Postgrad Med* 2005; 51:109–111, discussion 111.

Wade G. Alleman, MD, Brian Gorman, MB, BCh, Bernard F. King, MD, Dirk R. Larson, MS, John C. Cheville, MD, Ajay Nehra, MD, Benign and Malignant Epididymal Masses Evaluated With Scrotal Sonography, *Ultrasound Med* 2008; 27:1195–1202 • 0278-4297/08/\$3.50.

Waldert M, Klatt T, Schmidbauer J, Remzi M, Lackner J, Marberger M. Color doppler sonography reliably identifies testicular torsion in boys. *Urology* 2010; 75: 1170-4.

Weiss AJ, Kellman GM, Middleton WD, Kirkemo A. Intratesticular varicocele: sonographic findings in two patients. *AJR Am J Roentgenol* 1992; 158:1061–1063.

Woodhouse J, Ferguson MM. Multiple hyperechoic testicular lesions are a common finding on ultrasound in Cowden disease and represent lipomatosis of the testis. *Br J Radiol* 2006; 79:801–803.

Woodward PJ, Schwab CM, Sesterhenn IA. From the archives of the AFIP: extratesticular scrotal masses: radiologic-pathologic correlation. *Radiographics* 2003; 23:215–240.

Woodward PJ, Schwab CM, Sesterhenn IA. From the archives of the AFIP: extratesticular scrotal masses—radiologic- pathologic correlation. *Radiographics* 2002; 23:215– 240.

Woodward PJ, Sohaey R, O'Donoghue MJ, Green DE. From the archives of the AFIP: tumors and tumor like lesions of the testis: radiologic-pathologic correlation. *Radiographics* 2002; 22:189–216.

Wu JT, Book L, Sudar K. Serum alpha fetoprotein (AFP) levels in normal infants. *Pediatric Research* 1981; 15:50-52.

Yagan N. Testicular US findings after biopsy. *Radiology* 2000; 215:768–773.

Zeev. Maizlin, , Alexander Belenky, Myriam Kunichezky, Judith Sandbank, Simon Strauss, Leydig Cell Tumors of the Testis ,Gray Scale and Color Doppler Sonographic Appearance, *J Ultrasound Med* 2004; 23:959–964 • 0278-4297/04/\$3.50.

Zoller G, Kugler A, Ringert RH. [“False positive” testicular perfusion in testicular torsion in Power Doppler ultrasound]. *Urologe A*. 2000; 39:251-3.