Sudan University for science and Technology
College of Graduate Studies

Study of Common Carotid Arteries in diabetic Patients by Using Ultrasound

دراسة الشرايين السباتيه للمرضى المصابين بالسكري باستخدام الموجات فوق الصوتية

Research submitted for partial Fulfillment for the award of Master degree in Diagnostic Medical Ultrasound

Prepared by:

Sahar Abdelgader Omer Haj Elawad

Supervisor:

Dr. Al Safi Ahmed Abdallah
Associated Professor

2015

الآية

قال تعالى:

وَقُــلِ اعْمَلُــواْ فَسَــيَرَى اللّــهُ عَمَلَكُــمْ وَرَسُــولُهُ وَالْمُؤْمِنُونَ وَسَـتُرَدُّونَ إِلَـى عَـالِمِ الْغَيْـبِ وَالشَّـهَادَةِ فَيُنَبِّئُكُم بِمَا كُنتُمْ تَعْمَلُونَ}

صدق الله العظيم

Dedication

To my parents

To my small family

To whom I Love

I dedicate this work

Acknowledgment

I would like to express my deep gratitude and thanks to that who supervised me during this work.

I wish to thank Dr. Alsafi Ahmad Abd Allah for his guidance, support, help and provided invaluable advice.

Also I wish to thank Dr. Caroline Edward Ayad for encouraging me and provide more help to do this study.

And all those who help me directly or indirectly to complete this research.

Abstract

The aim of this study is to evaluate the accuracy of Ultrasound in detecting the impact of diabetes mulletus on carotid arteries.

This study was done among 60 Sudanese patients. The data were collected during the period April 2012 to April 2013 in clinic of College radiological science and other clinics in Khartoum hospitals, all patients were affected with D.M.

Divided into two groups:

Group (1) 50 patients, the study depends on practical scanning of carotid arteries of all patients and based on different parameter which is intima – media.

Thickness (IMT), caliber and presence of plaque of carotid arteries and correlating between these parameter using B-mode Ultrasound

In this study the IMT ranges from 0.09 cm to 0.20 cm (mean 0.15± cm) for the Rt CCA and from 0.08 cm to 0.20 cm (mean 0.13± cm) for the Lt CCA.

The caliper of Rt CCA ranges from 0.57 cm to 0.89 cm (mean 0.69± cm) and the left CCA ranges from 0.47 cm to 0.90 cm (mean 0.66± cm).

Group (2) were contained ten patients scanned by Doppler ultrasound to find the correlation between intima media thickness for right and left and RI and PI, with both correspond to the impedance of the flow in the vessels were calculated by the ultrasound machine.

A good correlation was noted between the intima media thickness and Resistive Index and intima media thickness and the pulsatility index, the intima media thickness is directly proportional to the RI and PI in both right and left common carotid artery.

For the right common carotid artery the RI ranges from 0.5 to 0.8 and the PI ranges from 1.75 to 2.10, while for the left common carotid artery the RI ranges from 0.5 to 0.91 and the PI ranges from 1.74 to 2.20

Finally the study showed atherosclerosis plaque in CCAs in some of patient.

ملخص البحث

هدفت هذه الدراسة الى تقويم دقة الموجات فوق الصوتية في تشخيص تأثيرات السكري في الشرايين السباتية المغذية للمخ ثم جمع المعلومات في الفترة من أبريل 2012م حتى أبريل 2013م من خلال الكشف الطبي على 60 مريض مصابين بارتفاع السكر في الدم في ولاية الخرطوم بعيادة كلية علوم الاشعة الطبية للموجات الصوتية والعيادات الاخرى بالمستشفيات قسمت الى مجموعتين:

المجموعة (1) تشمل 50 مريض، متوسط أعمار المرضى من 46 – 52 اعتمدت الدراسة على الفحص بالموجات فوق الصوتية العادية على الشرايين السباتية للمرضى المصابين بارتفاع السكر في الدم والتعرف على سمك الجدار الداخلي للشريان و قطر التجويف الداخلي للشرايين بالاضافة الى وجود اللويحات والعلاقة بينهم.

أظهرت الدراسة ازدياد سمك الجدار الداخلي للشريان السباتي الايمن و قد تراوحت قياسات سمك الجدار الداخلي من 0.09سم الى 0.20سم للشريان السباتي الايمن ومن 0.08 سم الى 0.20 سم في الشريان الايسر أما التجويف الداخلي للشرايين السباتية فقد تراوح القطر من 0.57 سم الى 0.89 سم والمتوسط 0.69 سم للشريان الايمن.

ومن 0.47سم الى 0.90 سم والمتوسط 0.66 سم في الايسر، وأخيراً وأظهرت الدراسة ترسب الدهون في الشرايين السباتية لعدد من المرضى.

والمجموعة (2) تشمل 10 مرضى تم المسح بواسطة الدوبلر لقياس كميات مؤشر المقاومة ومؤشر نبض الشريان و قد اوضحت الدراسة أن هناك علاقة جيدة بين سمك الجدار الداخلي ومؤشر المقاومة وسمك الجدار الداخلي ومؤشر نبض الشرايين بالنسبة للجانبين الايمن والأيسر حيث أن سمك الجدار الداخلي يتناسب طردياً مع مؤشر المقاومة ومؤشر نبض الشرايين و قد تراوح مؤشر المقاومة من 0.5 حتى 0.8 ومؤشر نبض الشرايين من 1.75 حتى 2.10 بالنسبة للشريان الايمن أما الايسر فقد تراوح مؤشر المقاومة من 0.5 الى 0.91 ومؤشر نبض الشرايين من 1.74 الى 2.20 بالنسبة للأيسر.

وختاماً يمكن القول بأن هذه الدراسة أثبتت قوة العلاقة بين الاصابة بالسكري وتصلب الشرايين السباتية.

List of Abbreviation

CCA	Common Carotid Artery
ECA	External Carotid Artery
ICA	Internal Carotid Artery
IMT	Intima Media Thickness
LDL	Low Density Lipoprotein
HDL	High Density Lipoprotein
Rt	Right
Lt	Left
DM	Diabetes Mullets
CVD	Cerebro Vascular Disease
RI	Resistive Index
PI	Pulsatility Index
C1	First Cervical vertebra
C2	Second Cervical vertebra
CW	Continuous Wave
PW	Pulsed Wave
PD	Power Doppler

Table of Contents

الآية..... I

Dedication..... II

Abstract..... IV

ملخص البحث..... VI

List of Abbreviation VIII

Table of Contents IX

List of Figures..... XI

List of table..... XIII

Chapter One..... 1

1.1 Introduction:..... 1

1.2 Problem of the study..... 2

1.3 Objectives: 2

1.3.1 Main Objective:..... 2

1.3.2 Specific Objectives:..... 2

1.4 Overview of the study:..... 3

Chapter Two..... 4

2.1 Anatomy 4

2.1.1 Common Carotid Arteries:..... 4

2.1.2 Relations: 4

2.1.3 External carotid artery:..... 5

2.1.3.1 Relations: 5

2.1.3.2 Branches:..... 5

2.1.4 Internal carotid artery: 6

2.1.4.1 Relations: 6

2.1.5 Vertebral Arteries: 7
2.2 Carotid Physiology:..... 9
2.3 Pathology:..... 10
2.3.1 Diabetes Mellitus:..... 10
2.3.1.1 Diabetic classification:..... 10
2.3.1.2 Macro vascular disease..... 11
2.3.2 Atherosclerosis: 12
2.3.3 Independent risk factors for Atherosclerosis: 13
2.3.4 Diagnosis of atherosclerosis: 13
2.3.5 Pathophysiology of Atherosclerosis in brain circulation: 13
2.3.6 Atherothrombotic Disease of the Internal Carotid Artery and its Branches: 15
2.4 Carotid Arteries and Ultrasound: 16
2.4.1 Indications for Carotid Artery Ultrasound: 16
2.4.2 Identification of Internal and External Carotid Arteries:..... 16
2.4.3 The External Carotid: 17
2.4.4 Internal Carotid Artery: 18
2.4.5 Measuring the Intima-medial Thickness (IMT): 19
2.4.5.1 Arterial Anatomy:..... 19
2.4.6 Assessment of Disease: 22
2.4.6.1 Measurement of the degree of stenosis: 22
2.4.6.2 Carotid Occlusion: 22
2.4.6.3 Plaque Characterization: 23
2.5 Carotid Ultrasound Examination..... 25
2.6 Carotid Ultrasound Interpretation..... 27
2.7 Doppler Ultrasound:..... 27
2.7.1 Doppler Modalities:..... 28

2.7.1.1 Continuous Wave (CW) Doppler:.....28
2.7.1.2 Pulsed Wave (PW) Doppler:.....28
2.7.1.3 Doppler Spectral Analysis:.....28
2.7.1.4 Color Doppler Ultrasound.....31
2.7.1.5 Power Doppler Ultrasound.....33
2.7.1.6 Spectral Analysis.....35
Chapter Three.....42
3-1 Scanning machine 42
3-2 population.....42
3-3 Technique of the Scan 42
3-4 Image Interpretation:.....43
Chapter Four.....45
Results.....45
Chapter Five.....61
5.1 Discussion:.....61
5.2 Conclusion:.....63
5.3 Recommendations:.....64
Increase the sample size.....64
References.....65

List of Figures

Figures	Page No
2.1 common carotid artery	7
2.2 Common carotid artery with vertebral artery	8
2.3 Anatomy of the extracranial carotid system	17
2.4 Normal external carotid artery (ECA)	18

2.5 Normal external carotid artery (ECA), internal carotid artery (ICA), and common carotid artery (CCA) waveforms 19

2.6 Arterial wall layers 20

2.7 Normal Intima-media (I-M) complex of common carotid artery. 20

2.8 Homogeneous plaque 23

2.9 The basic anatomy of Doppler Spectrum 34

4.1 The gender (Group A) 45

4.2 The age classes and frequency 46

4.3 Presence of Plaque in the right Common Carotid Arteries (CCA) 48

4.4 Presence of Plaque in the Left Common Carotid Arteries (CCA) 49

4.5 Scatter plot diagram shows the relationship between the diabetes duration and RT intima Thickness 49

4.6 Scatter plot diagram shows the relationship between the diabetes duration and LT intima Thickness 50

4.7 Scatter plot diagram shows the relationship between the diabetes duration and RT CCA Caliper 50

4.8 Scatter plot diagram shows the relationship between the diabetes duration and LT CCA Caliper 51

4.9 RT Intima Thickness and presence of RT Plaque 53

4.10 Lt Intima Thickness and presence of LT Plaque 54

4.11 The gender (Group B) 55

4.12 The mean value of variables 57

4.13 Scatter plot diagram shows the relationship between RT IMT and RI 58

4.14 Scatter plot diagram shows the relationship between RT IMT and PI 58

4.15 Scatter plot diagram shows the relationship between LT IMT and RI 59

4.16 Scatter plot diagram shows the relationship between LT IMT and PI 59

List of table

Table	Page No
4.1 the gender (Group A)	45
4.2 the age classes, frequency and percentages	46
4.3 the diabetes types, frequency and percentages	46
4.4 the Descriptive statistics of the variables	47
4.5 Presence of Plaque in the right Common Carotid Arteries (CCA)	47
4.6 Presence of Plaque in the Left Common Carotid Arteries (CCA)	48
4.7 The Correlations between the variables	52
4.8 the Chi test: RT Intima Thickness and RT Plaque	53
4.9 the Chi test: LT Intima Thickness * LT Plaque	54
4.10 the gender (Group B)	55
4.11 the mean and standard deviation of the RT and LT intimae thickness and Doppler Indices	56
4.12 the P-value between the variables	57

Chapter One

1.1 Introduction:

Ultrasound is a form of energy consisting of mechanically produced waves with frequencies above the rang of human hearing.

Ultrasound was introduced into diagnostic imaging in the early 1960s. However it took approximately 20 year for it to develop into principle diagnostic modality. Its inherent advantages – relatively low cost, non-invasive and easily conducted examinations – have led to an ever increasing demand for ultrasound technology. Today ultrasound stands as the first line of diagnostic imaging for many patients.(Carol M., 2011)

Ultrasound of extracranial cerebral circulation is used predominantly in the assessment of patients with symptoms which might arise from disease in the carotid artery such as amaurosis fugax and transient ischemic attacks (TIA), in order to identify those patients with significant changes who will benefit from surgery.(Paul L. 2013)

There are many causes of cerebral ischaemic symptoms apart from disease at the carotid arteries. These include cardiac arrhythmias, hypotensive episodes, embli and atheromatous disease elsewhere in the circulation between the heart and the intracerebral arteries. Many of these can be treated with medical therapy but is only the extracranial section of the carotid artery which is amenable to surgery, and for this reason it is essential to assess this area which can be done satisfactory by ultrasound and color Doppler.(Paul L. 2013)

Measurement of carotid intima media thickness (IMT) using high-resolution B-mode ultrasonography is a noninvasive, well validated

method to assess early cardiovascular disease, carotid IMT is significantly higher than in corresponding healthy, age- and sex-matched nondiabetic subjects. Hypertension, duration of diabetes, hyperglycemia, and dyslipidemia are associated with IMT and have been identified as significant risk factors for stroke Increased IMT is associated with increased risk of stroke as well as the risk of incident stroke. Common carotid artery IMT in patients with diabetes and acute stroke is significantly greater than in stroke-free patients with diabetes. Earlier studies showed that insulin resistance, an important feature of metabolic syndrome in T2DM, did not correlate with IMT. Hassinen *et al.* later found that after adjustment of other risk factors, the increase in carotid IMT was greater in elderly women who developed metabolic syndrome than in those who did not. Bertoni *et al.* found that the nonglucose component of metabolic syndrome did not correlate to increase IMT. Moreover, reducing the systolic blood pressure to ≤115 mm Hg in type-2 diabetes mellitus patients resulted in the regression of carotid IMT. (Marwan S., 2008)

1.2 Problem of the study

Patients with diabetes mellitus have greater carotid intima media thickness and they are at risk for generalized atherosclerotic deposit.

1.3 Objectives:

1.3.1 Main Objective:

To evaluate the common carotid artery with ultrasonography in order to estimate the luminal conditions.

1.3.2 Specific Objectives:

- To measure intima media thickness (IMT)
- To measure common carotid caliper (diameter)

- To determine the presence of plaque.
- To find the resistive index and pulsatility in both common carotid arteries using Doppler ultrasound.

1.4 Overview of the study:

Chapter one were contained introduction, objectives, methodology of the research then concluded with the scope of the study

Chapter two was contained:

- literature review
- Anatomy
- Physiology
- Pathology
- Ultrasound (standard examination)

C**hapter three:**

It was dealing with the material & methods

Chapter four:

It was including result presentation

Chapter five:

It was dealing with the discussion, conclusion & recommendation.

Chapter Two

2.1 Anatomy

2.1.1 Common Carotid Arteries:

The right common carotid artery arises from the brachiocephalic artery behind the right sternoclavicular joint while the left common carotid arises from the arch of the aorta in the superior mediastinum.

The common carotid artery runs upwards through the neck from the sternoclavicular joint to the upper border of the thyroid cartilage, where it divides into the external and internal carotid arteries. At its point of division, the terminal part of the common carotid artery or the beginning of internal shows localized dilatation called the carotid sinus.

The common carotid artery is embedded in the carotid sheath throughout its course and is closely related to the internal jugular vein and vogues nerve. The common carotid artery gives off no branches.(Richard S, 2009)

2.1.2 Relations:

Anterolaterally: The skin, the facia, the sternocleidomastoid, thesternohyoid, the sternothyroid and the superior belly of the ornohyoid.

Posteriorly: The transverse processes of the lower four, cervical vertebrae, the prevertebral muscles and the sympathetic trunk. In the lower part of the neck are the vertebral vessels.

Medially: The larynx and pharynx, and below these, the trachea and oesophags. The lobe of the thyroid gland also lies medially.

Laterally: The internal jugular vein, and posterolaterally the vagus nerve.(Richard S, 2009)

2.1.3 External carotid artery:

The external carotid artery is one of the terminal branches of the common carotid artery. It also supplies the tongue and maxilla. The artery begins at the level of the upper border of the thyroid cartilage terminates in the substance of the parotid gland behind the neck of the mandible by dividing into the superficial temporal and maxillary arteries.

At its origin, where it pulsations can be felt, the artery lies within the carotid triangle. At first it lies medial to the internal carotid artery, but as it ascends in the neck, it passes backward and laterally.(Richard S, 2009)

2.1.3.1 Relations:

Anterolaterally. The artery is overlapped at its beginning by the anterior border of the sternocleidomastoid. Above this level, the artery is comparatively superficial being covered by skin and fascia.

Medially: The wall of the pharynx and the internal carotid artery. (Richard S, 2009)

2.1.3.2 Branches:

- Superior thyroid artery.
- Ascending pharyngeal artery.
- Facial artery.
- Occipital artery.
- Posterior auricular artery.
- Superficial temporal artery
- Maxillary artery. (Richard S, 2009)

2.1.4 Internal carotid artery:

The internal carotid artery is one of the terminal branches of the common carotid artery. it supplies the brain, the eye, the forehead and part of the nose. The artery begins at the level of the upper border of the thyroid cartilage and ascends in the neck to the base of the skull, It enters the cranial cavity through the carotid canal in the petrous part of the temporal bone. It lies embedded in the carotid sheath with internal jugular vein and vagus nerve. At its beginning it lies superficially in the carotid triangle and then ascends deep to the parotid gland. The internal carotid artery gives no branches in the neck. (Richard S, 2009)

2.1.4.1 Relations:

Posteriorly: The sympathetic trunk, the longus capitis muscle, and the transverse processes of the upper three cervical vertebrae.

Medially: The pharyngeal wall arid the superior laryngeal nerve.

Laterally: The internal jugular vein and the vagus nerve**.**

Clinically, the bifurcation of the common carotid artery into the internal and the external carotid arteries can be easily palpated just beneath the anterior border of the sternocleidomastoid muscle at the level of the superior border of the thyroid cartilage. This is a convenient site to take the carotid pulse. (Richard S, 2009)

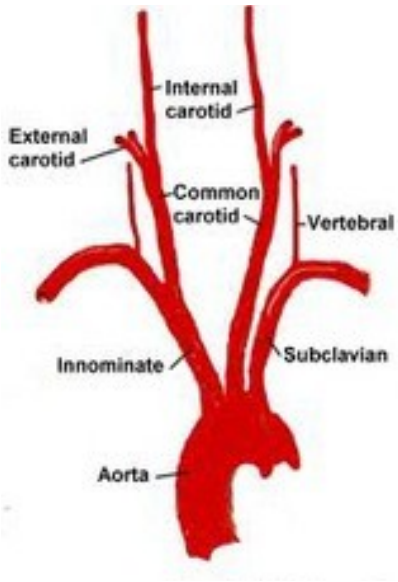

Fig 2.1 common carotid artery (www.quizlet.com)

2.1.5 Vertebral Arteries:

The vertebral artery on each side is the first branch of subclavian artery. It passes posteriorly and upwards to the vertebral foramen in the transverse process of the sixth cervical vertebra, and from there it passes upwards in the vertebral canal to the level of axis (C2). It emerges from the vertebral canal at (C2), passing behind the lateral mass of the atlas (C1) to enter the skull through the foramen magnum and join with the vessel of the other side in front of the brain stem to form the basilar artery. The common carotid arteries and the basilar artery together with their branches form the Willis circle, which supplies the brain. (Richard S, 2009)

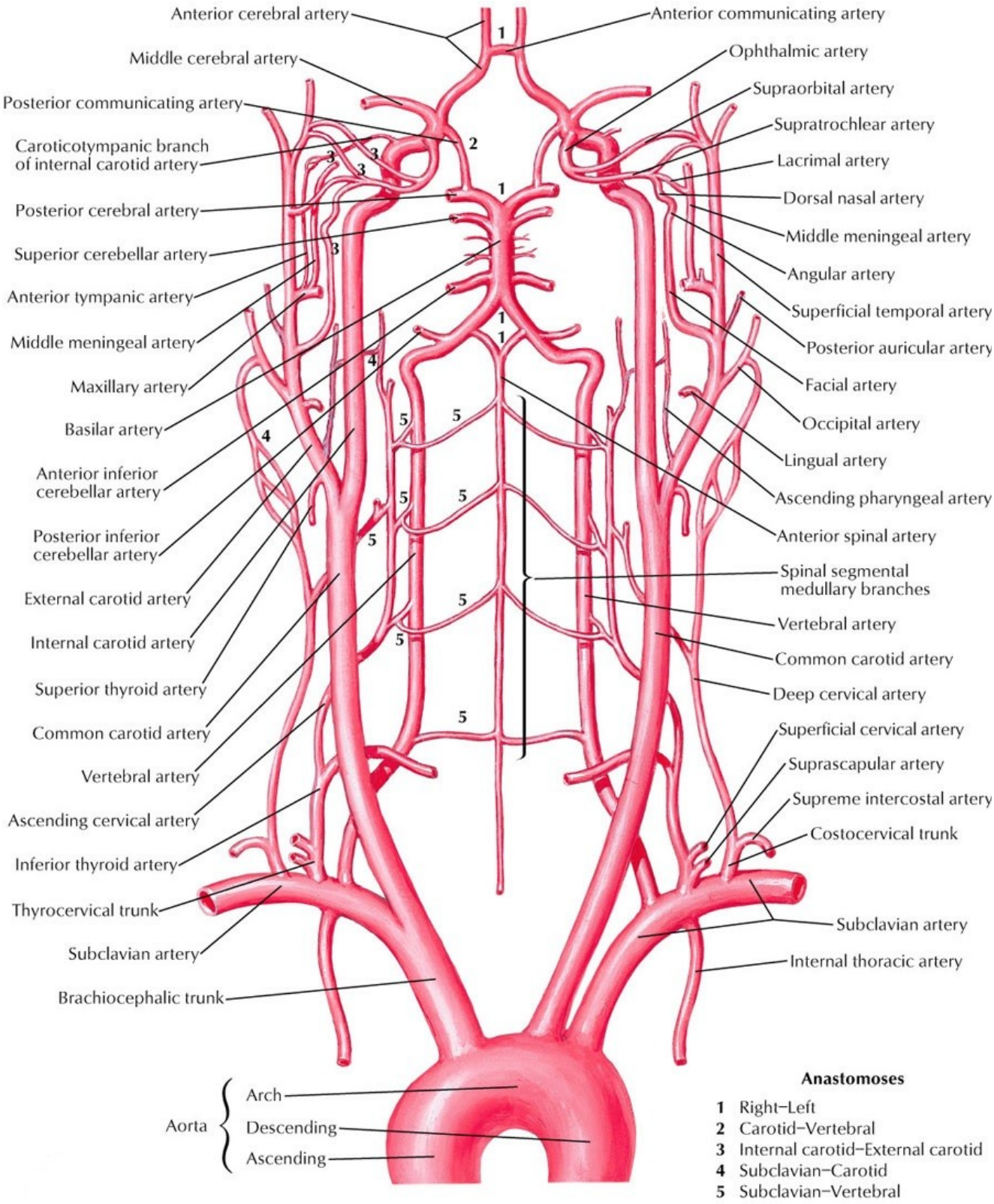

Fig 2.2 Common carotid artery with vertebral artery

(www.myroadtomedicalschool.blogspot.com)

2.2 Carotid Physiology:

Healthy arteries carry oxygen rich blood to the all part of the body and vien carry the blood back to the heart and lungs to replenish its oxygen. In human physiology and any of vessels that with one exception, carry the oxygenated blood and nourishment from the heart to the tissue of the body. The exception the pulmonary artery carries oxygen depleted blood to the lung for oxygenation and removal of excess carbon dioxide. The two carotid arteries supply blood to the head and neck, carotid arteries are located on each side of the neck and extend from aorta in the chest to the base of the skull, these arteries supply blood to the brain.

We have one main carotid artery on each side and each of these divides in to two major branches the external and internal carotid arteries.

The external carotid artery supplies blood to face and scalp.

The internal carotid artery is more important because it supplies blood to the brain.

2.3 Pathology:

2.3.1 Diabetes Mellitus:

Definition of the diabetic syndrome is controversial. The U.S department of health education and welfare defines diabetes as disease of uncertain cause, characterized by chronic hyper glycemia and other disturbance of carbohydrate and lipid metabolism and associated with the development of vascular complication.

These complications may affect specific organ such as the eye or the kidney or they may be associated with accelerated atherosclerosis resulting in increased frequency of coronary heart disease and peripheral vascular disease.

The definition proceeds to explain the classic symptoms of diabetes and the difference in on sit between young and older patients.(Jone A. Spittell, 1986).

2.3.1.1 Diabetic classification:

Primary

Autoimmune type 1 Diabetes Mellitus

Non insulin dependent Diabetes Mellitus (type 1 transient)

Insulin dependent diabetes mellitus.

Non autoimmune type 2 diabetes mellitus

Insulin dependent diabetes mellitus (type 2 transient).

Non insulin dependent diabetes mellitus.

Maturity onset diabetes of the young (MODY).

Secondary:

Diabetes caused by pancreatic disease.

Diabetes caused by hormonal abnormality.

Drugs or chemical induced diabetes.

Diabetes caused by insulin receptor abnormality.

Diabetes associated by genetic syndrome.

Diabetes of other causes. (Antony, 1998)

2.3.1.2 Macro vascular disease

To date there is a lack of clear pathologic distinction between atherosclerosis in diabetic and in non diabetic it seems however, at last from clinical observation, that atherosclerosis is accelerated in diabetics, it occur at younger age.

The pathogeneses of macro angiopathology is at the best theoretic consideration suggest initial endothelial damage followed by platelets adhesion to the endothelial surface, aggregation of platelets and liberation of certain platelets factors resulting in endothelial destruction and diffusion of different molecules in to smooth muscles this produces proliferation, lipid accumulation and plaque formation which are characteristic of atherosclerotic process.

The initial damage into the endothelial may be function of Van Will brand's factor found in excess of normal in diabetic. The proliferation of smooth muscles of the blood vessels may be contributed to by either growth hormone or other growth factors presented in diabetic serum.

Lipid accumulation is thought to be helped by increased level of cholesterol and triglycerides and decreased levels of high density of lipo protein (HDL).

The pathologic change in the vessels wall lead to fibrin deposition and thrombotic complication. (Jone A. Spittell, 1986).

2.3.2 Atherosclerosis:

Definition:

Atheroma: the lipid deposits in the intima of arteries producing a yellow swelling on the endothelial surface; a characteristic of Atherosclerosis.

Atherosclerosis: characterized by irregularly distributed lipid deposits in the intima of large and medium-sized arteries causing narrowing of arterial lumens and proceeding eventually to fibrosis and calcification.

Lesions are usually focal and progress slowly and intennittently. Limitations of blood flow accounts for most clinical manifestation, which

vary with the distribution and severity of lesion. (larry B., 2003)

Atherosclerosis is a complex process that begins with the appearance of cholesterol-laden macrophages (foam cells) in the intima of and smooth muscle cells respond of the presence of lipid by proliferating under the influence of platelet factors. A plaque formed at the site, consisting of smooth muscle cells, Ieukocytes and further deposition of lipid; in intima the plaque becomes fibrotic and may calcify. (larry B., 2003)

The name ‘atherosclerosis’ derived from Greek, refers to the thickening of the arterial. intima (sclerosis “hardening”) and accumulation vf lipid (athere “gruel”). (Antony S., 1998)

- Expansion of an atherosclerotic plaque leads to gradually increasing
  obstruction of the artery arid ischaemia of tissues supplied by it.

- Ulceration, thrombosis or embolization of a plaque or intimal haemorrhage and dissection, can cause more acute and severe impairment of blood flow, with the risk of infarction. (larry B., 2003)

These are the principal mechanisms of coronary artery disease (arteriosclerotic heart disease with or without heart failure, angina pectoris, myocardial infarction), peripheral vascular disease (particularly occlusive disease of the lower extremity causing intermittent claudication or gangrene), and stroke (cerebral infarction due to occlusion of carotid or intracranial arteries.(larry B., 2003)

2.3.3 Independent risk factors for Atherosclerosis:

These arc male sex, advancing age, the post-menopausal state, a family history of atherosclerosis, cigarette smoking, hypertension, diabetes mellitus, elevated plasma LDL cholesterol, elevated plasma homocystine, over weight and sedentary life style. (larry B., 2003)

2.3.4 Diagnosis of atherosclerosis:

The diagnosis of atherosclerosis is usually based on history and physica1 examination and confined by angiography or the non-invasive method Doppler ultrasonograp1y and other imaging techniques.(larry B., 2003)

2.3.5 Pathophysiology of Atherosclerosis in brain circulation:

Atherosclerosis is usually maximal at arterial bifurcation and commonly affects the origin of the internal carotid artery in the neck

and .the origin of major and minor arterial branches inside the head. Although: individuals with the most atherosclerosis are the ones most likely to have stroke, the correlation is only approximate. (Antony S.,1998)

The integrity of the extra-cranial and intra-cranial collateral circulation, the state of systemic cardiovascular function, and, possibly haematologic factors play a role in deter-mining whether a given atherosclerosis lesion will cause ischaemia or infarction. (Antony S.,1998)

Atherosclerosis plagues can Cause an arterial stenosis that produces a haernodynamic obstruction to flow, If this regional decrease in cerebral blood flow falls below a critical level, it will cause a transient or permanent ischemic event. In addition artery to artery emboli appear to be an important cause of retinal and hemispheric ischemia and infection. (Antony S.,1998)

When an atherosclerotic plaque on the arterial wall ulcerates, the necrotic materials (cholesterol crystals, calcified connective tissue, debris, etc) may dislodge and serve as emboli or may provide a surface on which aggregation of platelets and coagulation of fibrin occurs. (Antony S.,1998)

Although the exact course of ischemia or infraction in a given patient with atherosclerosis is not always known, the primary abnormality is clearly atherosclerosis with its complicating lesions, the fibrous plaque. The plaque contains various degrees of degeneration that may result in stenosis or with subsequent thrombosis or embolizatoin. (Antony S.,1998)

2.3.6 Atherothrombotic Disease of the Internal Carotid Artery and its Branches:

The origin of the internal carotid artery is the most common site of atherosclerosis and superimposed atherothrombosis that leads to transient ischemic attack (TIA) or stroke. Less often, disease at the siphon (S.shaped portion of the internal carotid artery) in the cavernus sinus or in the proximal sequent of the middle or anterior cerebral arteries may be responsible. These intracranial sites predominate in Africans, Americans and Asians. (Antony S.,1998)

Rarely the origin of the Common carotid artery may be the site.

Atherosclerosis in the proximal internal carotid artery is usually most severe in the first 2 cm and arises from the posterior wall, often extending downward into the common carotid artery. Atherosclerosis at this site, is often heralded by a TIA or minor stroke, presumably caused by embolism or less frequently, low flow. (Antony S.,1998)

Emboli arising from stenotic or ulcerated atherosclerotic may cause occlusion of the ophthalmic artery, the proximal middle cerebral arteryor one of its branches or, less often the anterior cerebral artery. (Antony S.,1998)

In some patients an ulcerated plaque may be the only lesion in the accompanying stenosis of 50 percent or more. A non-stenotic or slightly stenotic carotid lesion in conjunction with stroke or single prolonged TIA suggests the heart as the source of embolus. (Antony S.,1998)

2.4 Carotid Arteries and Ultrasound:

2.4.1 Indications for Carotid Artery Ultrasound:

- Transient ischemic attacks (TIA).
- Reversible ischemic neurologic deficits.
- Mild resolving strokes in younger patients.
- Atypical non-focal symptoms which may have a vascular aetiology.
- Arteriopaths, high-risk patients prior to surgery.
- Post-end arterectomy.
- Pulsatile neck masses.
- Trauma or dissection
- Screening for disease. (Paul L.2013)

2.4.2 Identification of Internal and External Carotid Arteries:

The common carotid artery on the right arises from the innominate artery behind the right sternoclavicular joint where the origin can be seen on ultrasound. (Paul L.2013)

On the left, the common carotid arises directly from the aorta, so that its origin on the left cannot be seen on scanning from the neck. The level of the carotid bifurcation is usually at about the level of the upper border of the laryngeal cartilage. The two branches of the common

carotid artery, the internal and the external carotid artery should be identified positively.

Proper identification of the internal and external carotid arteries is not a problem in most patients. The most reliable method to distinguish the ICA from the ECA is by Doppler signal. The ICA has diastolic flow due to the low peripheral resistance of the brain, and the ECA demonstrates a more pulsatile Doppler signal (minimal diastolic flow) because it supplies blood to the muscular bed of the jaw and face.

Additionally, the ECA is usually smaller in diameter, has cervical branches, and usually originates anterior and medial at the carotid bifurcation.(Gilani S.)

2.4.3 The External Carotid:

- Smaller diameter.
- Medial with respect to internal carotid artery.
- Extra cranial branches.
- High resistance flow.(Gilani S.)

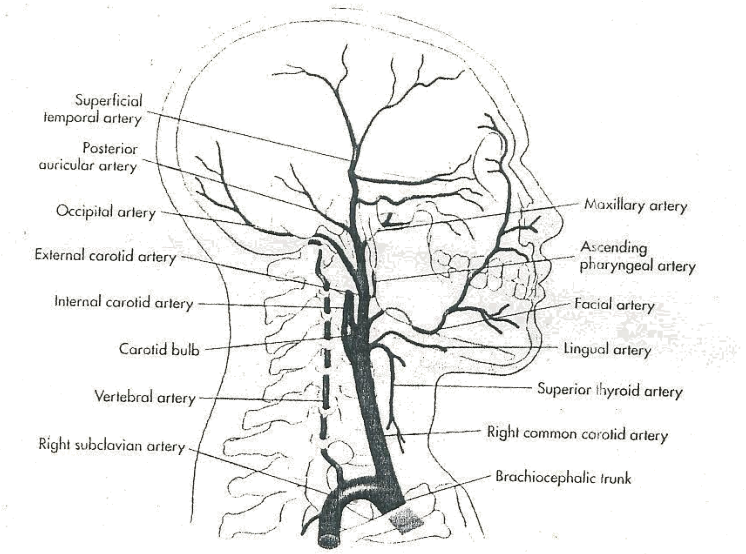

Fig. 2.3 Anatomy of the extracranial carotid system.(Sandra L.)

Superficial temporal artery tap (the superficial temporal artery is one of the terminal branches of the external carotid artery, and if this is tapped by a finger as it passes over the zygoma, it will produce rapid, clear fluctuations in the wave from in the external carotid artery.

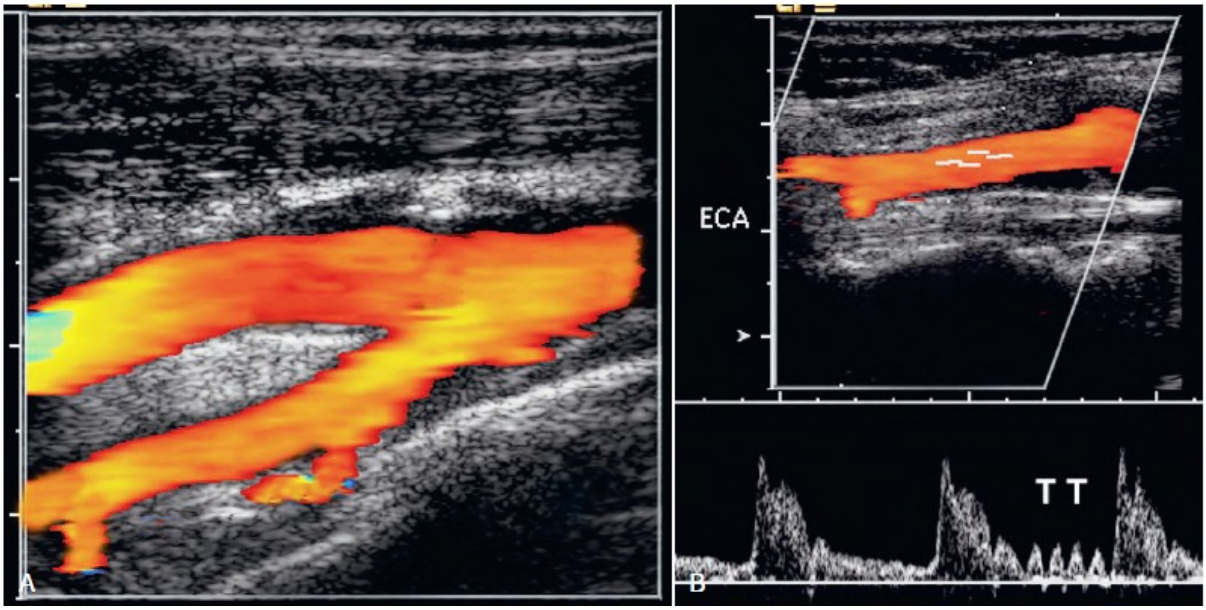

Fig. 2.4 normal external carotid artery (ECA). A color Doppler Ultrasound of bifurcation demonstrates two small arteries originating from the ECA. B, ECA spectral Doppler shows the anticipated serrated (sawtooth) flow disturbance from the temporal artery tap (TT).(Carol, 2001)

2.4.4 Internal Carotid Artery:

- Larger diameter.

- Lateral with respect to external carotid artery.

- Bulb at origin.
- No extracranical branches.
- Low resistance flow. (Gilani S.)

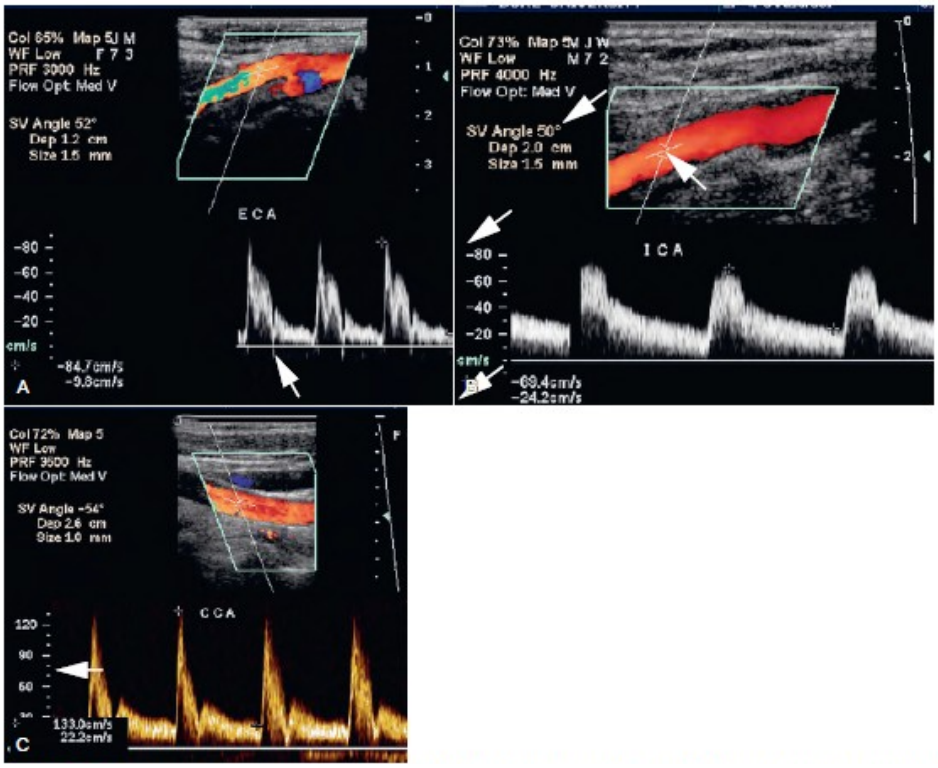

Fig. 2.5 Normal external carotid artery (ECA), internal carotid artery (ICA), and common carotid artery (CCA) waveforms.(Carol, 2001)

2.4.5 Measuring the Intima-medial Thickness (IMT):

2.4.5.1 Arterial Anatomy:

Artery have three layers to their vessel wall

- Intima.
- Media.
- Adventitia.

Normal thickness of the intima is < 0.8 mm.

Arterial Wall Layers

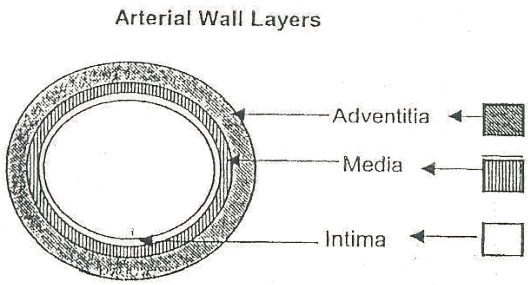

Fig. 2.6 Arterial wall layers (Gilani S.)

The IMT is best demonstrated in the upper common carotid artery where the vessel is usually at right angles to the ultrasound beam. The transducer is adjusted to show the characteristic double line appearance of the vessel wall. The image should be magnified as much as possible to make the measurement easier to perform.(Paul L.2013)

The internal carotid is more difficult to assess as the vessel slopes obliquely away from the transducer face in many cases.

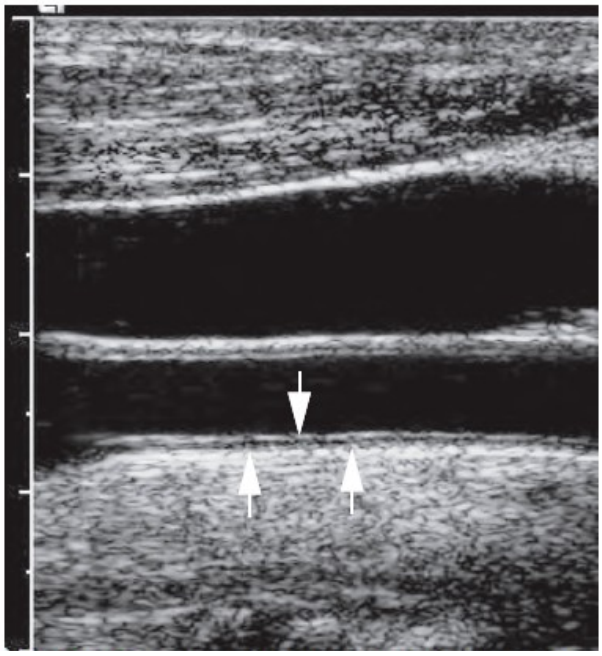

Fig: 2.7 Normal intima-media (I-M) complex of common carotid artery.(Carol, 2001)

2.4.6 Assessment of Disease:

2.4.6.1 Measurement of the degree of stenosis:

Two types of information can be used to assess the degree of stenosis:

1- Direct measurement using the calipers on the machine: if stenosis and plaque can be clearly then it is possible to measure the caliber of the residual lumen the original calibre of the vessel. Diameter reduction ratios, or area reduction ratios, are the usual methods for describing the reduction in vessel caliber.

2- Doppler criteria: in many cases the region of the stenosis is not seen clearly due to complex plague structure and calcification. In these cases direct measurement cannot be used to quantify the degree of stenos is and Doppler criteria must be used.

   – The peak systolic velocity (PSV), end-diastolic velocity (EDV) and
     the ratio of peak systolic velocities in the internal and common carotid arteries (IC/CC systolic ratio) arc the most useful measurements in general practice.

   – Spectral broadening and filling in of the window under the spectrum
     are subjective, difficult to quantify and can be affected significantly by gain control settings, however, they do indicate abnormal flow if they are present. (Paul L.2013)

2.4.6.2 Carotid Occlusion:

Occlusion can affect the internal carotid artery or common carotid artery separately, or together. Occlusion of the common carotid artery

does not always result in occlusion of the internal carotid artery, as sufficient blood flow may be provided by retrograde flow down the ipsilateral external carotid artery to maintain patency of the internal carotid artery.

Occlusion of the internal carotid artery results in the reduction of diastolic flow in the ipsilateral common carotid artery, so that the common carotid artery waveform becomes more like that seen in the therefore be an external carotid artery. Reduction of common carotid artery diastolic flow may therefore be an initial clue to the presence of an internal carotid artery occlusion, or a very severe stenosis.

Care should be taken, however, as the development of collateral channels between the external carotid artery and the internal carotid artety circulation in the orbit and meninges can result in ‘internalization’ of the external carotid artery flow with relatively high diastolic flow in the external carotid artery, this results in a mistaken impression of a patent internal carotid artery, if it is not recognized the temporal tap’ manoeuvre can usually clarify the situation.

If there is occlusion of both the internal carotid artery and external carotid artery then the ipsilateral common carotid artery also usually occludes. Before thrombosis occurs, however, a to-and-fro pattern of flow may be seen in the common carotid artery, which signifies that there is no net forward flow of blood up the vessel.(Paul L 2013.)

2.4.6.3 Plaque Characterization:

Atheromatous carotid plaques should be carefully evaluated to determine plaque extent, location, surface contour, and texture, as well as to assess luminal stenosis. 30 The plaque should be scanned and evaluated in both the sagittal and the transverse projections.31 the most

common cause of TIAs is embolism, not flow limiting stenosis; less than half of patients with documented TIA have hemodynamically significant stenosis. It is important to identify low-grade atherosclerotic lesions that may contain hemorrhage or ulceration, which can serve as a nidus for emboli that cause both TIAs and stroke.1 Polak et al.32 showed that plaque is an independent risk factor for developing a stroke.

The relationship between sonographic plaque morphology and the onset of symptoms is controversial. Plaque texture is generally classified as homogeneous or heterogeneous. The accurate evaluation of plaque can only be made with gray-scale ultrasound, without the use of color or power Doppler. The plaque must be evaluated in both sagittal and transverse planes.

Homogeneous plaque has a generally uniform echo pattern and a smooth surface. Sonolucent areas may be seen, but the amount of sonolucency is less than 50% of the plaque volume. The uniform acoustic texture corresponds pathologically to dense fibrous connective tissue. (Carol, 2001)

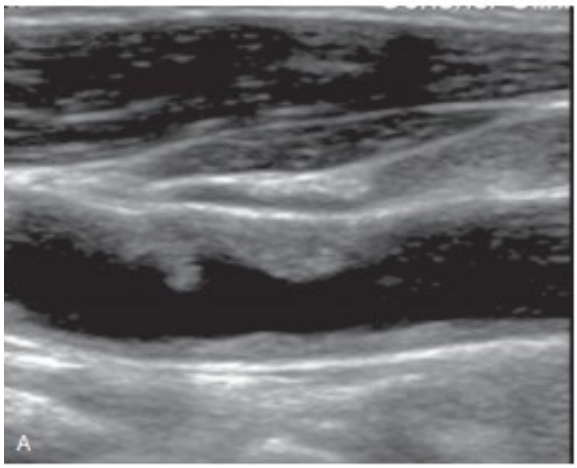

Fig: 2.8 Homogeneous plaque.(Carol, 2001)

Calcified plaque produces posterior acoustic shadowing and is common in asymptomatic individuals. Heterogeneous plaque has a more complex echo pattern and contains one or more focal sonolucent areas corresponding to more than 50% of the plaque volume.

Heterogeneous plaque is characterized pathologically by containing intraplaque hemorrhage and deposits of lipid, cholesterol, and proteinaceous material.10,42 Homogeneous plaque is identified much more often than heterogeneous plaque, occurring in 80% to 85% of patients examined.32 Sonography accurately determines the presence or absence of intraplaque hemorrhage (sensitivity, 90%-94%; specificity, 75%-88%).(Carol, 2001)

2.5 Carotid Ultrasound Examination

Carotid artery ultrasound examinations are performed with the patient supine, the neck slightly extended, and the head turned away from the side being examined. Some operators prefer to perform the examination at the patient’s side, whereas others prefer to sit at the patient’s head. The examination sequence also varies with operator preference. This sequence includes the gray-scale examination, Doppler spectral analysis, and color Doppler blood flow interrogations. Power Doppler sonography may or may not be employed. A 5 to 12 MHz transducer is used for gray-scale imaging and a 3 to 7–MHz transducer for Doppler sonography, Gray-scale sonographic examination begins in the transverse projection. Scans are obtained along the entire course of the cervical carotid artery, from the supraclavicular notch cephalad to the angle of the mandible. Inferior angulation of the transducer in the supraclavicular area images the CCA origin. The left CCA origin is deeper and more difficult to image consistently than the right. The carotid

bulb is identified as a mild widening of the CCA near the bifurcation. Transverse views of the carotid bifurcation establish the orientation of the external and internal carotid arteries and help define the optimal longitudinal plane in which to perform Doppler spectral analysis. When the transverse ultrasound images demonstrate occlusive atherosclerotic disease, the percentage of “diameter stenosis” or “area stenosis” can be calculated directly using electronic calipers and software analytic algorithms available on most duplex equipment.(Carol, 2001)

After transverse imaging, longitudinal scans of the carotid artery are obtained. The examination plane necessary for optimal longitudinal scans is determined by the course of the vessels demonstrated on the transverse study. In some patients the optimal longitudinal orientation will be nearly coronal, whereas in others it will be almost sagittal. In most cases the optimal longitudinal scan plane will be oblique, between sagittal and coronal. In approximately 60% of patients, both vessels above the carotid bifurcation and the CCA can be imaged in the same plane, in the remainder, only a single vessel will be imaged in the same plane as the CCA. Images are obtained to display the relationship of both branches of the carotid bifurcation to the visualized plaque disease, and the cephalocaudal extent of the plaque is measured. Several anatomic features differentiate the ICA from the ECA. In about 95% of patients, the ICA is posterior and lateral to the ECA. This may vary considerably, however,10 and the ICA may be medial to the ECA in 3% to 9% of people. The ICA frequently has an ampullary region of dilation just beyond its origin and is usually larger than the ECA. One reliable distinguishing feature of the ECA is its branching vessels A useful method to identify the ECA is the tapping of the superficial temporal artery in the preauricular area, the temporal tap (TT). The pulsations are

transmitted back to the ECA, where they cause a sawtooth appearance on the spectral waveform. Although the tap helps identify the ECA, this tap deflection may be transmitted into the CCA and even the ICA in certain rare situations.(Carol, 2001)

2.6 Carotid Ultrasound Interpretation

Each facet of the carotid sonographic examination is valuable in the final determination of the presence and extent of disease.

Generally, gray-scale and color or power Doppler images better demonstrate and quantify low-grade stenoses, whereas high-grade occlusive disease is more accurately defined by Doppler spectral analysis. For plaque characterization, assessment must be made in gray scale only, without color or power Doppler ultrasound.(Carol, 2001)

2.7 Doppler Ultrasound:

Ultrasound and Doppler ultrasound studies have emerged as a non-invasive diagnostic method for the evaluation of arteries and veins. They have almost replaced the invasive and expensive methods as angiography.

Doppler technology provides haemodynamic assessment of the arteries and veins. This technique is combined with sonographic imaging (Duplex) which provides the morphologic data. Color flow techniques represent a newer dimension that quickly detects motion and its direction; however it must be borne in mind that quantitative information is still derived from the Doppler assessment. In brief, Doppler studies can detect the presence or absence of blood flow beside the direction, speed and pulsatility of flow. A number of techniques have been developed which exploit the shift in frequency of ultrasound when it is reflected from moving blood. This frequency shift is known as Doppler effect.(Burwin)

2.7.1 Doppler Modalities:

2.7.1.1 Continuous Wave (CW) Doppler:

Continuous Wave Doppler must use a minimum of two transducer crystals, one to transmit and the other to receive so as to produce a continuously transmitted sound wave.

- The major advantage of (CW) Doppler is that it is not subject to aliasing.

  Aliasing is a common Doppler artifact that occurs when the Doppler shift exceeds the system's detection limit.

- The major disadvantage of (CW) Doppler is that it is unable to determine from which depth the detected Doppler shifts originate (poor spatial resolution). (Burwin)

2.7.1.2 Pulsed Wave (PW) Doppler:

Pulsed Wave Doppler can be performed with a single transducer crystal.

- The major advantage of (PW) Doppler is its excellent spatial resolution. The sonographer can control the placement of the sample volume at any depth along the scan line.

- The major disadvantage of (PW) Doppler is its susceptibility to aliasing.

2.7.1.3 Doppler Spectral Analysis:

The Doppler spectrum is a quantitative graphic display of the velocities and directions of moving red blood cells (RBCs) present in the Doppler sample volume. Although Doppler assessment of carotid occlusive disease can be performed using frequency data, velocity

calculations are preferable. Velocity values are potentially more accurate than frequency shift measurements, because angle theta, between the transducer line of sight and the blood flew vector, is used to convert a frequency shift to velocity.(Carol M., 2011)

Frequency shifts vary according to the angle theta and the incident Doppler frequency; velocity measurements take both these factors into account. (Carol M., 2011)

The Doppler spectral display represents velocities on the y axis and time on the x axis. By convention, flw toward the transducer is displayed above the zerovelocity baseline, and flw away from the transducer is below. For ease of analysis, spectra that project below the baseline are often inverted and placed above the baseline, always keeping in mind the true direction of flw within the vessel. The amplitude of each velocity component (number of RBCs with each velocity component) is used to modulate the brightness of the traces. This is also known as a gray-scale velocity plot. In the normal carotid artery, the frequency spectrum is narrow in systole and somewhat wider in early and late diastole. (Carol M., 2011)

There is usually a black zone between the spectral line and the zero-velocity baseline called the spectral window59,60).The ICA and ECA branches of the CCA have distinctive spectral waveforms. The external carotid artery supplies the high-resistance vascular bed of the facial musculature, so its flw resembles that of other peripheral arterial vessels. Flow velocity rises sharply during systole and falls rapidly during diastole, approaching zero or transiently reversing direction. (Carol M., 2011)

The internal carotid artery supplies the low-resistance circulation of the brain and demonstrates flw similar to that in vessels supplying other blood-hungry organs, such as the liver, kidneys, and placenta. The common feature in all low-resistance arterial waveforms is that a large quantity of forward flw continues throughout diastole. The common carotid artery waveform is a composite of the internal and external waveforms, but most often the CCA flw pattern more closely resembles that of the ICA, and diastolic flw is generally above the baseline. Approximately 80% of the blood flwing from he CCA goes through the ICA into the brain, whereas 20% goes through the ECA into the head musculature. The relative decrease in blood flw through the ECA will cause it to have a generally lower-amplitude gray-scale waveform than in either the ICA or the CCA. (Carol M., 2011)

Virtually all state-of-the-art ultrasound equipment offers color and power Doppler, as well as gray-scale capabilities and pulsed Doppler, for the carotid examination. A rapid color Doppler screen allows the detection of abnormal flw patterns, which allows the pulsed Doppler signal volume to be placed in areas that are abnormal, especially those with high-velocity jets. These high velocity jets are located in the region of and immediately distal to a high-grade stenosis. In cases where both gray-scale and color and power Doppler images of an entire carotid artery are normal, only representative spectral tracings from the CCA, ICA, and ECA are necessary to complete the examination. (Carol M., 2011)

The standard Doppler spectral examination consists of traces obtained from the proximal and distal CCA, carotid bulb, and proximal ECA; samples in the proximal, middle, and distal ICA; and a representative trace from the vertebral artery. Normal velocities are

higher in the proximal CCA and lower in the distal vessel; normal ICA velocities tend to increase from proximal to distal. (Carol M., 2011)

In addition, blood flow velocities are obtained immediately proximal to, at, and just beyond regions of maximal visible stenosis and at 1-cm intervals distal to the visualized plaque as far cephalad as possible The entire course of the CCA and ICA should be interrogated with a consistent angle theta between the transducer and the vessel maintained throughout the examination, when possible. Generally, only the origin of the ECA is evaluated because occlusive plaque is less common here than in the ICA and is rarely clinically significant. A stenosis of the ECA should be noted because it may account for a worrisome cervical bruit when the ICA is normal. (Carol M., 2011)

Atheromatous plaque projecting into the arterial lumen disturbs the normal, smooth laminar flow of erythrocytes. The RBCs move with a wider range of velocities, so the spectral line becomes wider, filing in the normally black spectral window. This phenomenon, termed spectral broadening increases in proportion to the severity of carotid artery stenosis. (Carol M., 2011)

2.7.1.4 Color Doppler Ultrasound

Color Doppler ultrasound displays blood flow information in real time over the entire image or a selected area. Stationary soft tissue structures, which lack a detectable phase or frequency shift, are assigned an amplitude value and displayed in a gray-scale format with flowing blood in vessels superimposed in color. The mean Doppler frequency shift produced by RBC ensembles pulsing through a selected sample volume is obtained using an auto correlative method or a time domain processing (speckle motion analysis) method. Color assignments depend

on the direction of blood flow relative to the Doppler transducer. Blood flow toward the transducer appears in one color and flow away from the transducer in another. These color assignments are arbitrary and are generally set up so that arterial flow is depicted as red and venous flow as blue. Color saturation displays indicate the variable velocity of blood flow. Deeper shades usually indicate low velocities centered around the zero velocity color flow baseline. As velocity increases, the shades become lighter or are assigned a different color hue. Some systems allow selected frequency shifts to be displayed in a contrasting color, such as green. This green-tag feature provides a real-time estimation of the presence of high-velocity flow. (Carol M., 2011)

Setting the color Doppler scale can also be used to create an aliasing artifact corresponding to the highest velocity flow within a vessel. These high-velocity jets pinpoint areas for spectral analysis. Color assignments are a function of both the mean frequency shift produced by moving RBC ensembles and the Doppler angle theta. If the vessel is tortuous or diving, angle theta between the transducer and vessel will change along the course of the vessel, resulting in changing color assignments that are unrelated to the change in RBC velocity. The color assignments will reverse in tortuous vessels as their course changes relative to the Doppler transducer, even though the absolute direction of flow is unchanged. Portions of a vessel that parallel the Doppler beam when angle theta is 90 degrees will have little or no frequency shift detected, and no color will be seen. (Carol M., 2011)

Color Doppler imaging provides a rapid means of determining the presence and direction of flow and is especially helpful at finding small vessels which often cannot be seen on the real-time gray scale display.

Color Doppler complements PW Doppler hut does not replace it. Color Doppler shows us the areas of flow within the image and the direction of flow. It can then be used to direct the pulsed wave sample volume placement for spectral analysis and velocimetry assessment. (Burwin)

2.7.1.5 Power Doppler Ultrasound

The color signal in power Doppler ultrasound is generated from the integrated power Doppler spectrum. The amplitude of the reflected echoes determines the brightness and color tone of the color signal. This amplitude depends on the density of RBCs flowing within the sample volume. Power Doppler ultrasound uses a larger dynamic range with a better signal-to-noise (S/N) ratio than color Doppler ultrasound. Because power Doppler ultrasound does not evaluate frequencies but rather amplitude (or power), artifacts such as aliasing do not occur. Power Doppler sonography, unlike color Doppler ultrasound, is largely angle independent. These features combine to make power Doppler ultrasound exquisitely sensitive to detecting a residual string of flow in the region of a suspected carotid occlusion. (Carol M., 2011)

It is also hypothesized that power Doppler ultrasound has better edge definition than color Doppler ultra sound. The combination of improved edge definition and relative angle-independent flow imaging offers the potential for better visual assessment of the degree of stenosis using power Doppler.86 Better edge definition may also allow power Doppler ultrasound to define plaque surface characteristics more clearly. (Carol M., 2011)

Despite the many potential benefits of power Doppler ultrasound, it does not provide velocity or directional flow information.88 Also, power

Doppler is very motion sensitive, which may result in a pseudostring of flow. If the vibrations of soft tissue at an echogenic interface exceed the clutter filter level, color information may be displayed in areas where there is no blood flow. Pulsed Doppler evaluation of a color or power string should always be performed to confirm the presence of real flow. (Carol M., 2011)

Power Doppler screening may produce an accurate and cost-effective method for patients at risk for carotid disease.89,90 Power Doppler imaging used independent of spectral analysis was effectively performed in 89 of 100 patients. The sensitivity for the detection of 40% or greater stenoses using power Doppler was 91%, with 79% specificity. This would be reasonable for a screening test, allowing patients with greater than 40% stenoses to undergo more expensive spectral analysis. Some believe that using this less expensive power Doppler screening could result in a more cost-effective approach to carotid Doppler screening. In addition, carotid power Doppler imaging, as well as carotid B-flow imaging, is ideally suited to combined use with vascular contrast agents that may be widely available in the future. (Carol M., 2011)

(PD) is a relatively new type of color Doppler imaging which is based on the power in the Doppler spectrum.

Advantages of PD over color Doppler imaging are:

- Increased sensitivity to slow flow.
- Angle independence.
- Lack of aliasing.

Disadvantages are that the PD can only indicate the presence of flow and not direction or velocity.(Burwin)

2.7.1.6 Spectral Analysis

Both continuous wave and pulsed wave demonstrate the characteristics of vascular flow using a graph called spectral display. The spectral display show the different shift that occur within a blood vessels during each cardiac cycle.(Burwin)

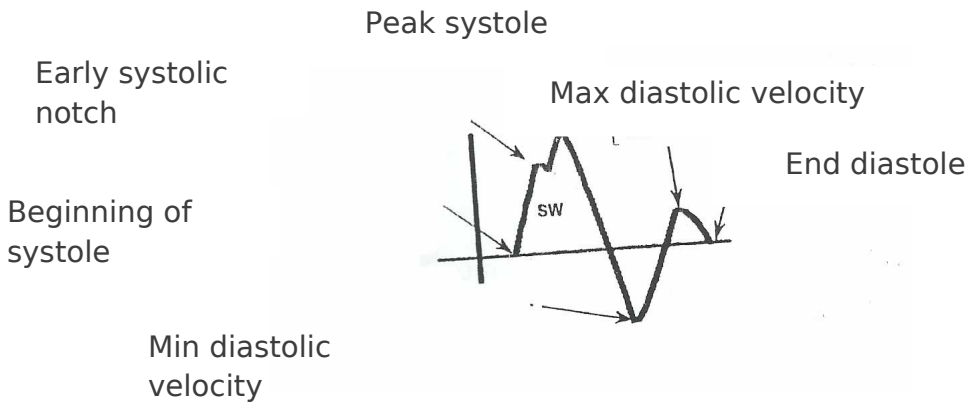

Fig 2.9 The basic anatomy of Doppler Spectrum (Gilani S.)

Resistive index (RI):

Calculation of the resistive index is one way of quantifying the Doppler wave form. The resistive index is impedance to blood flow and is the ratio of the peak systolic frequency shift minus the minimum diastolic frequency shift divided by the peak systolic frequency shift. (Burwin)

Pulsatility index (PI):

Calculation of pulsatility is another method of measuring vascular resistance the pulsatility index is a ratio of the peak systolic frequency shift minus the minimum diastolic frequency shift divided by mean frequency shift. (Burwin)

Previous Study:

Shahid Amin, *el*, 2011, studied Carotid Disease in Diabetic Patients Undergoing Coronary Artery Bypass Grafting

The blood flow hemodynamic of carotid arteries were obtained from carotid arteries of 168 individuals with diabetes using the 7:5 MHz ultrasound Doppler M-unit. Fast Fourier to compare the severity of carotid artery disease in diabetic and non-diabetic patients undergoing coronary artery bypass grafting. Methods: From January to June 2008, 379 patients undergoing elective coronary artery bypass surgery were preoperatively evaluated for the presence of carotid stenoses by duplex scanning. Patients were divided into two groups, Group I, 156 (41.2%) diabetic patients and Group II, 223 (58.8%) non-diabetic patients. Results**:** There were 314 (82.8%) males and 65 (17.2%) females with a mean age of 57.2±9.1 years. In diabetic group there were 125 (80.1%) males and 31 (19.9%) females with a mean age of 56.3±8.9 years. Left main stem stenosis was present in 59 (37.8%) diabetics and 45 (20.2%) non-diabetics ($p<0.0001$). Diffuse disease in left anterior descending (LAD) artery was observed in more diabetic patients 72 (46.2%) as compared to non-diabetics 83 (37.2%) ($p<0.295$). Single tight stenosis in LAD was observed in more non-diabetics. Significant carotid artery stenosis was observed in 50 (13.2%) patients. Carotid artery stenosis was observed in 30 (19.2%) diabetics as compared to 20 (9%) non-diabetics ($p<0.004$). Analysis of percentage stenosis of carotid artery disease in the study population revealed that >70% stenosis was present in 20 (5.3%) with 13 (8.3%) diabetics and 7 (3.1%) non-diabetics ($p<0.025$). Stenosis of 50– 70% was observed in 30 (7.9%) of which 17 (10.9%) were diabetics and 13 (5.8%) were non-diabetics.

Conclusion: Presence of diabetes mellitus is associated with diffuse coronary artery disease and significant carotid artery disease in patients undergoing coronary artery bypass grafting.

Piercesare SECCHI, 2010 studied Analysis of Doppler blood flow velocity in carotid arteries for the detection of atherosclerotic plaques.

In this thesis, a technique for nearly automated detection of Doppler flow velocity profile is developed. From this, it is possible to estimate the period of the velocity waveform throughout an innovative iterative method, based on Fourier smoothing and non linear least squares.

The estimate of the period enables the reconstruction of a function representing the velocity of the red blood cells, along the common carotid artery and at different distances from the bifurcation. Considering these functional data, it is possible to reduce the dimension of the problem performing a functional principal component analysis. The aim is that of exploring the blood flow along the common carotid artery, before the plaque is reached, and searching for features of the curve that indicate the presence of the plaque downstream.

Gerardo Heiss, *el*, 2001 studied Carotid Atherosclerosis Measured by B-Mode Ultrasound in Populations: Associations with Cardiovascular Risk Factors in the ARIC Study

To assess whether carotid atherosclerosis measured by B-mode ultrasound is related to cardiovascular risk factors, 386 cases with carotid artery wall thickening and an equal number of controls free of arterial intima-media thickening were drawn from the cohort of the Atherosclerosis Risk in Communities (ARIC) Study examined in four

communities in the United States between 1988 and 1990. Cases and controls were individually matched on sex, race, age group, study center, and date of examination. The mean values of total cholesterol, low density lipoprotein (LDL) cholesterol, total triglyceride, blood pressure, and pack-years of cigarette smoking were higher in cases than controls. Mean high density lipoprotein (HDL) cholesterol was lower in cases than controls. Case-control differences were all statistically significant. Multivariable-adjusted odds ratios point to differences of considerable magnitude in the risk of carotid atherosclerosis between groups defined by clinical and public health-oriented risk factor cut-points. *Am J Epidemiol* 1991;134:250–6. ugh a linear discriminant analysis. This permits to compare the blood velocity field in healthy people with the blood flow of stenotic patients, who will undergo TEA surgery.

Göksan B, Erkol G, Bozluolcay M, Ince B.2001 studied Diabetes as a determinant of high-grade carotid artery stenosis: evaluation of 1,058 cases by Doppler sonography.

Our objective was to investigate the association of risk factors, especially diabetes mellitus, with high-grade carotid artery stenosis. The study group was chosen from the patients who were sent to our Doppler ultrasonography laboratory for detecting the vascular anatomy. Doppler sonography was performed in 1,058 patients. High-grade carotid artery stenosis with a diameter reduction of 70% to 99% was detected in 89 patients. In the moderate and mild stenosis groups, we had 85 and 884 patients, respectively. Patients in the moderate stenosis group had a 40% to 69% carotid stenosis, and patients in the mild group had a 0% to 39% stenosis or normal ultrasonographic findings. Parameters of age, sex, alcohol, smoking, ischemic heart disease, hypertension, and diabetes were considered potential risk factors for stenosis. Multivariate logistic

regression model was used as the statistical test in comparing the 3 groups. In the high-grade stenosis group, sex distribution was 34.8% female and 65.2% male with a mean age of 64.48 +/- 10.19 years. In the second and third groups these distributions were 51.8% female and 48.2% male with a mean age of 65.15 +/- 9.66 years, and 54.30% female and 45.70% male with a mean age 59.56 +/- 12.37, respectively. Diabetes mellitus (odds ratio (OR) = 2.77), ischemic heart disease (OR = 1.67), age (OR = 1.02), and male gender (OR = 1.75) were found to be significantly associated with high-grade carotid stenosis. As a cost-effective, noninvasive, easily performed, and fast technique, Doppler sonography is used in vascular evaluation of patients. Early diagnosis of carotid artery disease in patients with modifiable risk factors like diabetes may play an important role in the prevention of a consequent stroke.

Kyoko Ariyoshi1, *el*. 2014, studied Ultrasound analysis of gray-scale median value of carotid plaques is a useful reference index for cerebro-cardiovascular events in patients with type 2 diabetes.

Measurements of plaque echogenicity, the gray-scale median (GSM), were shown to correlate inversely with risk factors for cerebro-cardiovascular disease (CVD). The eicosapentaenoic acid (EPA)/arachidonic acid (AA) ratio is a potential predictor of CVD risk. In the present study, we assessed the usefulness of carotid plaque GSM values and EPA/AA ratios in atherosclerotic diabetics.

Materials and Methods: A total of 84 type 2 diabetics with carotid artery plaques were enrolled. On admission, platelet aggregation and lipid profiles, including EPA and AA, were examined. Using ultrasound, mean intima media thickness and plaque score were measured in carotid arteries. Plaque echogenicity was evaluated using computer assisted

quantification of GSM. The patients were then further observed for approximately 3 years.

Results: Gray-scale median was found to be a good marker of CVD events. On multivariate logistic regression analysis, GSM <32 and plaque score ≥5 were significantly associated with past history and onset of CVD during the follow-up period, the odds ratios being 7.730 (P = 0.014) and 4.601 (P = 0.046), respectively. EPA/AA showed a significant correlation with GSM (P = 0.012) and high-desnsity lipoprotein cholesterol (P = 0.039), and an inverse correlation with platelet aggregation (P = 0.046) and triglyceride (P = 0.020).

Although most patients with CVD had both low GSM and low EPA/AA values, an association of EPA/AA with CVD events could not be statistically confirmed.

Conclusions: The present results suggest the GSM value to be useful as a reference index for CVD events in high-risk atherosclerotic diabetics. Associations of the EPA/AA ratio with known CVD risk factors warrant a larger and more extensive study to show the usefulness of this parameter.

Yogan Kisten, *el*, 2013, studied Duplex ultrasound: A diagnostic tool for carotid stenosis management in type 2 diabetes mellitus

Diabetic patients are at increased risk of developing cardiac events and stroke, and prevention of diabetes mellitus is therefore desirable. Marked geographical and ethnic variation in the prevalence of diabetes caused by urbanisation,demographic and epidemiological transitions has

rendered this one of the major non-communicable diseases in South Africa. Duplex ultrasound (DUS) plays an important role in primary health care in early detection of carotid atherosclerotic disease and the degree of carotid stenosis present. It is a reliable, cost-effective and non-invasive diagnostic tool. The purpose of this study was to determine the role of ultrasound in carotid stenosis management in type 2 diabetes mellitus (T2DM).

Objectives: To determine the prevalence of carotid stenosis in a selected T2DM population using DUS and to correlate these findings with other predisposing atherosclerotic risk factors.

Methods: The study setting was at an academic hospital in the Western Cape using carotid DUS reports of 103 diabetic subjects ≥ 35 years old. Predisposing risk factors were correlated with degree of carotid stenosis present. Data were analysed using the Fischer exact test, Chi-square and Student *t*-test.

Results: Carotid DUS reports of 63 out of 103 T2DM patients revealed no evidence of a carotid stenosis, thereby lowering the risk profile. Forty patients were identified as having carotid stenosis; 22 symptomatic patients had a > 70% carotid stenosis which warranted surgical intervention. A greater prevalence of stenosis in the Caucasian group, in both the male (p = 0.0411) and female (p = 0.0458) cohorts, was noted. The overall trend suggested a relationship between T2DM and lifestyle, and a statistically significant relationship (p = 0.0063) between smoking and carotid stenosis was observed.

Conclusion: T2DM and predisposing atherosclerotic risk factors significantly increased the possibility of carotid stenosis development.

Chapter Three

Material and Method

Material

3-1 Scanning machine

Two types of scanning machine with 5-7 MHz linear brop were used in this study.

1. General Electric Logio 5.
2. Eube 7

3-2 population

The target population amounts for this study were sixty patients present as area of the study included adult, male and female ranges age from 23 to 76 years.

- Excluded pediatric patients and adult patients under 23 years.

Methods

3-3 Technique of the Scan

- The patient lies supine with neck little extended by placing a pillow under the shoulder.
- The patient should be comfortable and excessive extension should avoided (some patient with carotid or vertebral disease may find that the neck extension compromises the flow of blood to the cerebral circulation, so if the appears to be a sleep it is worth checking that she/he has not consciousness.

- Patient can be examined adequately in a sitting position if they are not able to lie supine.
- The examiner can sit beside the patient's thorax or the patient head and scan the nec.
- A high frequency transducer (7-10 MHz is used)

3-4 Image Interpretation:

- Transverse scan from low in the neck up to behind the angle of the mandible to locate the bifurcation.
- Longitudinal scan for
    - Measuring the intima media thickness in the common carotid artery.
    - The transducer is adjusted to show the characteristic double line appearance of the vessels wall.
    - Measuring the caliber of common carotid artery from inner to inner.
    - Longitudinal color scan area of abnormal flow and disease ie, the presence of the atherosclerotic plaques.
    - Spectral Doppler :
        - Take readings from common carotid artery in the normal vessels
        - In abnormal vessels take reading from area of the disease in addition to the stander readings from common carotid artery.

- Calculation of the resistive index.
- Calculation of the pulsatility index.

Chapter Four

Results

Study cases:

60 Sudanese adult were included in this study during the period April 2012 to April 2013 were divided to two groups:

Group (1) 50 subjects had scanned by gray scale ultrasound.

The following tables and figures shows summary of the result including intima media thickness, caliber, age and duration of diabetes and the presence of the plaque of the sample of the study

Table 4.1 shows the gender, frequency and percentages

Gender	frequency	Percentages
Male	28	56%
Female	22	44%
total	50	100%

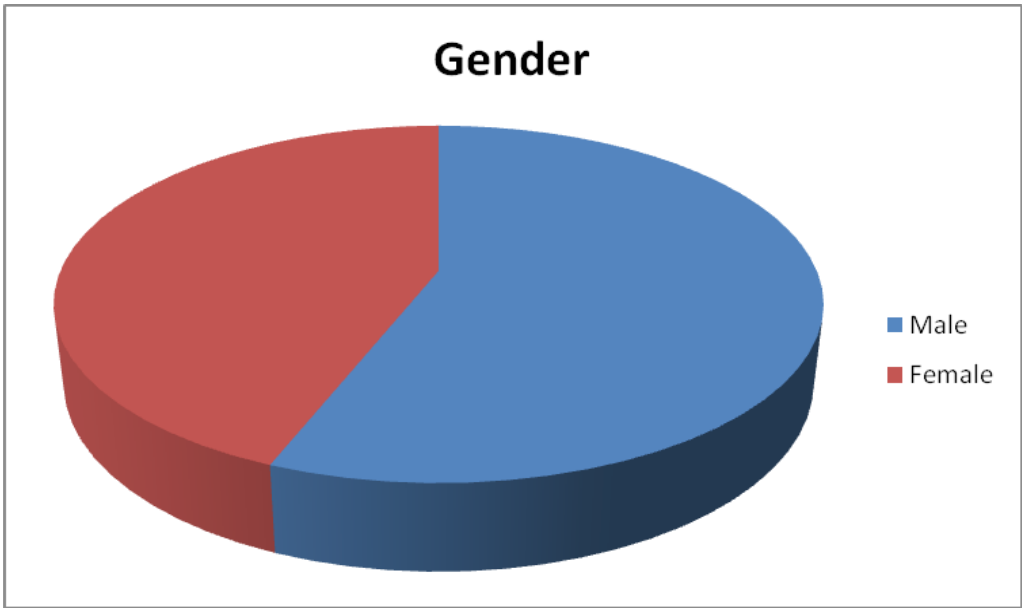

Fig.4.1 Pie graph shows the gender, frequency and percentages

Table 4.2 shows the age classes, frequency and percentages

Age Classes	frequency	Percentages
32-38	2	4%
39-45	6	12%
46-52	24	48%
53-59	16	32%
60-66	1	2%
>67	1	2%
total	50	100%

Fig 4.2 shows the age classes and frequency

Table 4.3 shows the diabetes types, frequency and percentages

Diabetes Type			
		Frequency	Percentages
Valid	Type1	12	24.0%
	Type2	38	76.0%
	Total	50	100.0%

Table 4.4 shows the Descriptive statistics of the variables

Descriptive Statistics					
	N	Minimum	Maximum	Mean	Std. Deviation
RT Intima Thickness	50	.09	.20	.15	±.03
RT Caliper	50	.57	.89	.69	±.07
RT Plaque	50	.00	1.0	.14	±.35
LT Intima Thickness	50	.08	.20	.13	±.03
LT Caliper	50	.47	.90	.66	±.08
LT Plaque	50	.00	1.0	.18	±.39

Table 4.5 Presence of Plaque in the right Common Carotid Arteries (CCA)

RT Plaque			
		Frequency	Percent
Valid	No	43	86.0%
	Yes	7	14.0%
	Total	50	100.0%

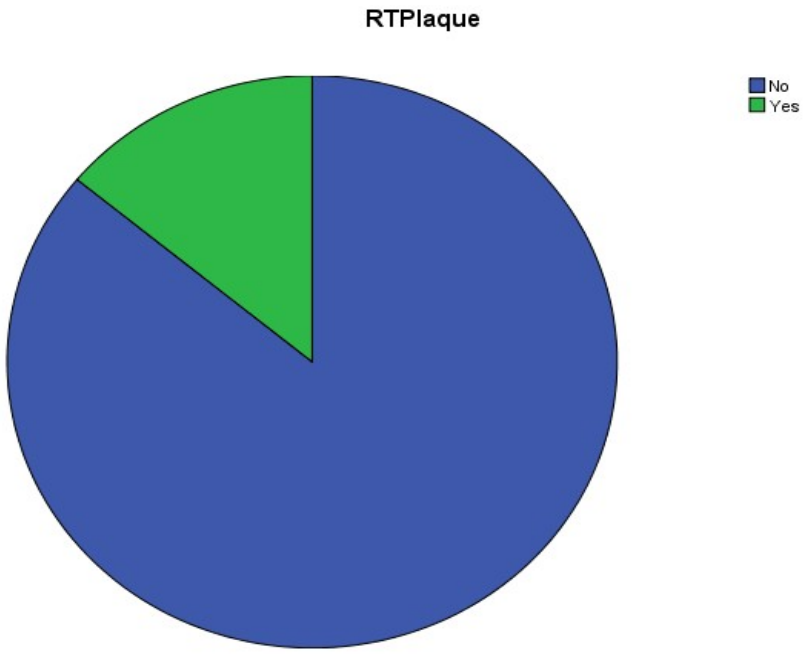

Fig 4.3 Pie graph shows the presence of Plaque in the right Common Carotid Arteries (CCA)

Table 4.6 Presence of Plaque in the Left Common Carotid Arteries (CCA)

LT Plaque			
		Frequency	Percent
Valid	NO	41	82.0%
	Yes	9	18.0%
	Total	50	100.0%

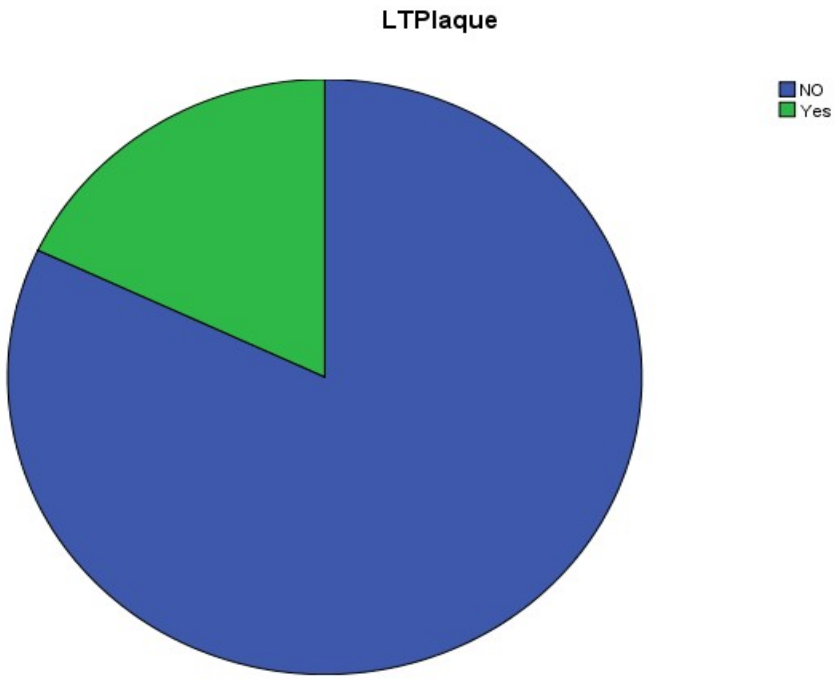

Fig 4.4 Pie graph shows the presence of Plaque in the Left Common Carotid Arteries (CCA)

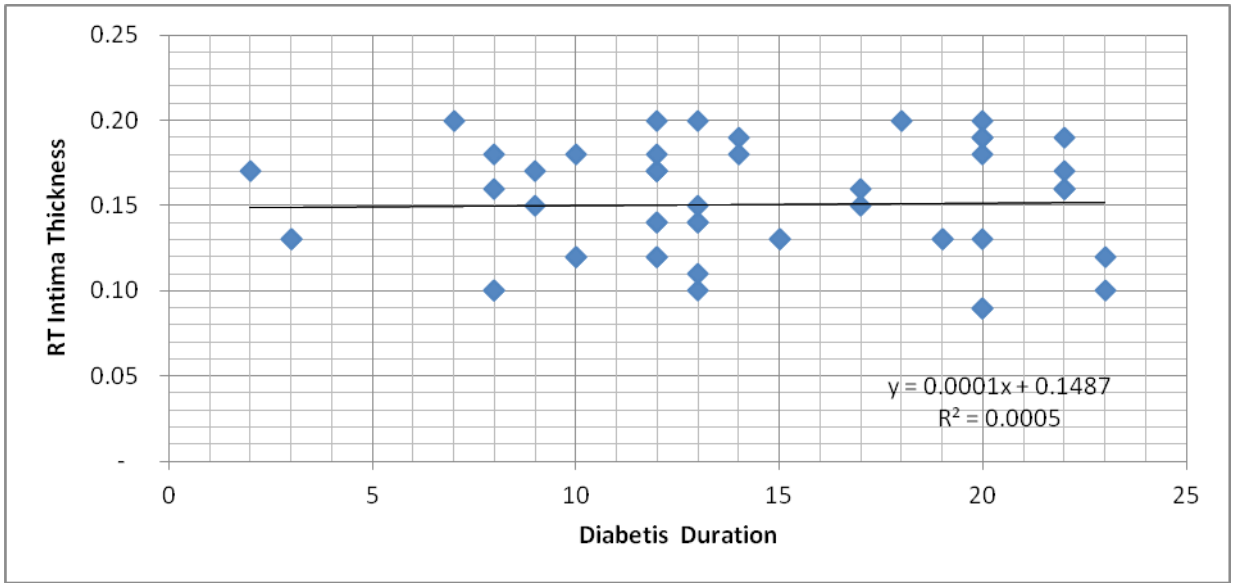

Fig 4.5 Scatter plot diagram shows the relationship between the diabetes duration and RT intima Thickness ,as The diabetes duration increased the RT thickness is also increased but this increasing is not significant R^2=0.000

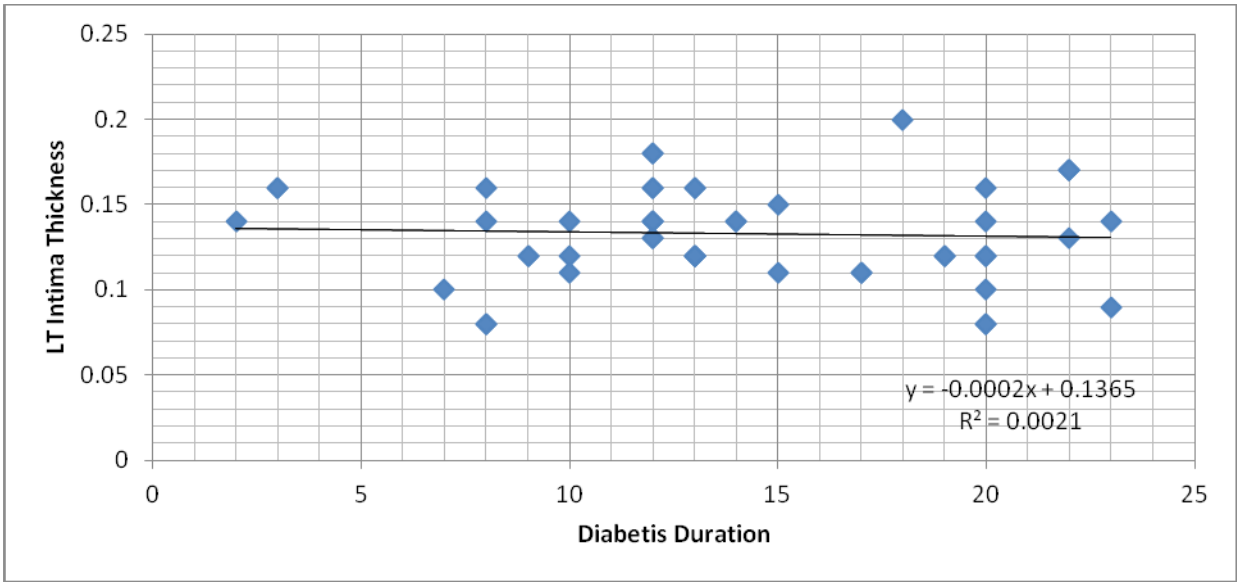

Fig 4.6 Scatter plot diagram shows the relationship between the diabetes duration and LT intima Thickness ,as The diabetes duration increased the LT thickness is decreased but this decreasing is not significant R^2=0.002

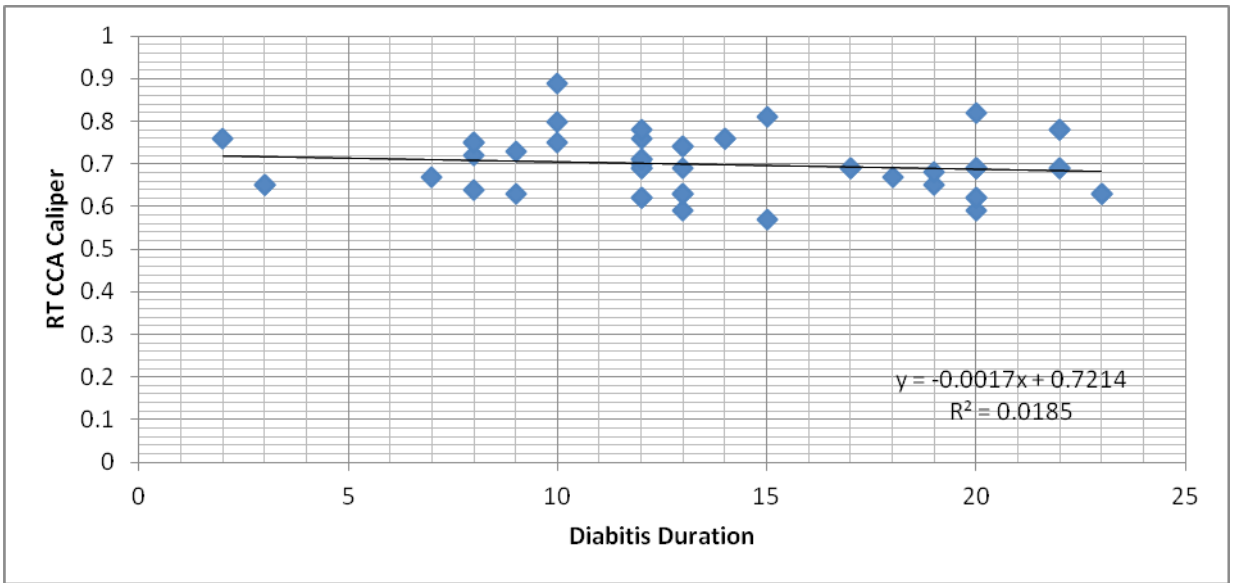

Fig 4.7 Scatter plot diagram shows the relationship between the diabetes duration and RT CCA Caliper ,as The diabetes duration increased the RT CCA Caliper is decreased but this decreasing is not significant R^2=0.018

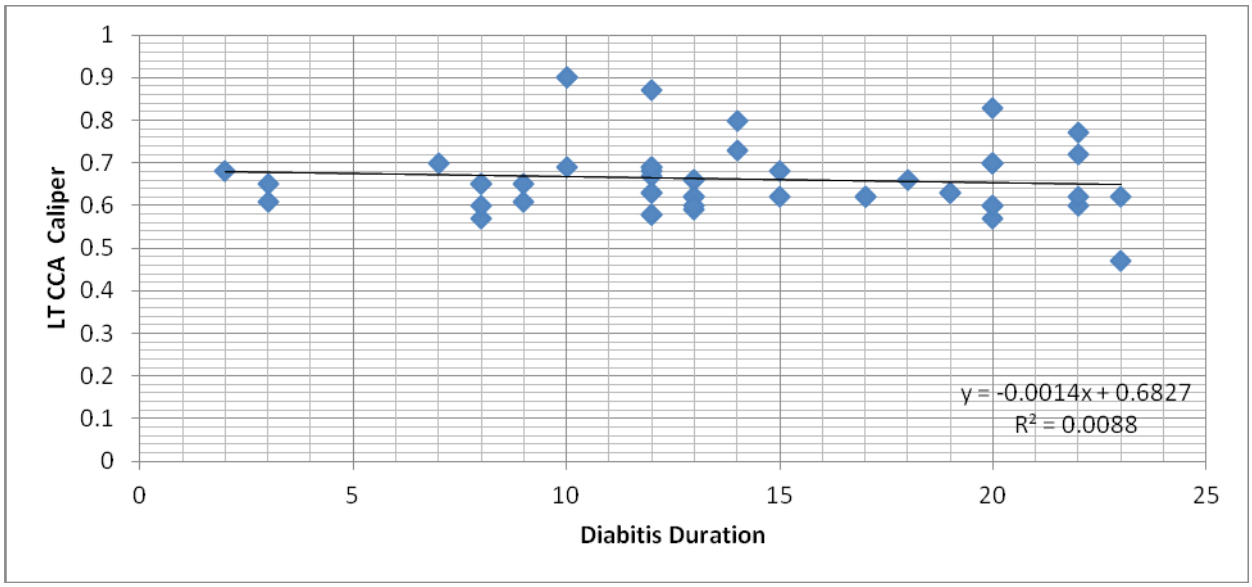

Fig 4.8 Scatter plot diagram shows the relationship between the diabetes duration and LT CCA Caliper ,as The diabetes duration increased the LT CCA Caliper is decreased but this decreasing is not significant R^2=0.008

Table 4.7 shows The Correlations between the variables

Correlations

		Diabetes Type	RT Intima Thickness	LT Intima Thickness	RT Caliper	LT Caliper	RT Plaque	LT Plaque
Diabetes Type	Pearson Correlation	1	.083	.081	-.103-	-.029-	.092	.020
	Sig. (2-tailed)		.569	.575	.479	.843	.526	.893
RT Intima Thickness	Pearson Correlation	.083	1	.550**	.203	.068	.046	-.089-
	Sig. (2-tailed)	.569		.000	.157	.638	.752	.539
LT Intima Thickness	Pearson Correlation	.081	.550**	1	.192	-.066-	-.067-	-.035-
	Sig. (2-tailed)	.575	.000		.180	.648	.644	.809
RT Caliper	Pearson Correlation	-.103-	.203	.192	1	.495**	-.116-	-.218-
	Sig. (2-tailed)	.479	.157	.180		.000	.422	.128
LT Caliper	Pearson Correlation	-.029-	.068	-.066-	.495**	1	.286*	.205
	Sig. (2-tailed)	.843	.638	.648	.000		.044	.153
RT Plaque	Pearson Correlation	.092	.046	-.067-	-.116-	.286*	1	.861**
	Sig. (2-tailed)	.526	.752	.644	.422	.044		.000
LT Plaque	Pearson Correlation	.020	-.089-	-.035-	-.218-	.205	.861**	1
	Sig. (2-tailed)	.893	.539	.809	.128	.153	.000	
	N	50	50	50	50	50	50	50

****. Correlation is significant at the 0.01 level (2-tailed).**

***. Correlation is significant at the 0.05 level (2-tailed).**

Table 4.8 shows the Chi test: RT Intima Thickness and RT Plaque

Chi-Square Tests			
	Value	df	Asymp. Sig. (2-sided)
Pearson Chi-Square	15.888[a]	11	.145
Likelihood Ratio	15.749	11	.151
Linear-by-Linear Association	.103	1	.748
N of Valid Cases	50		

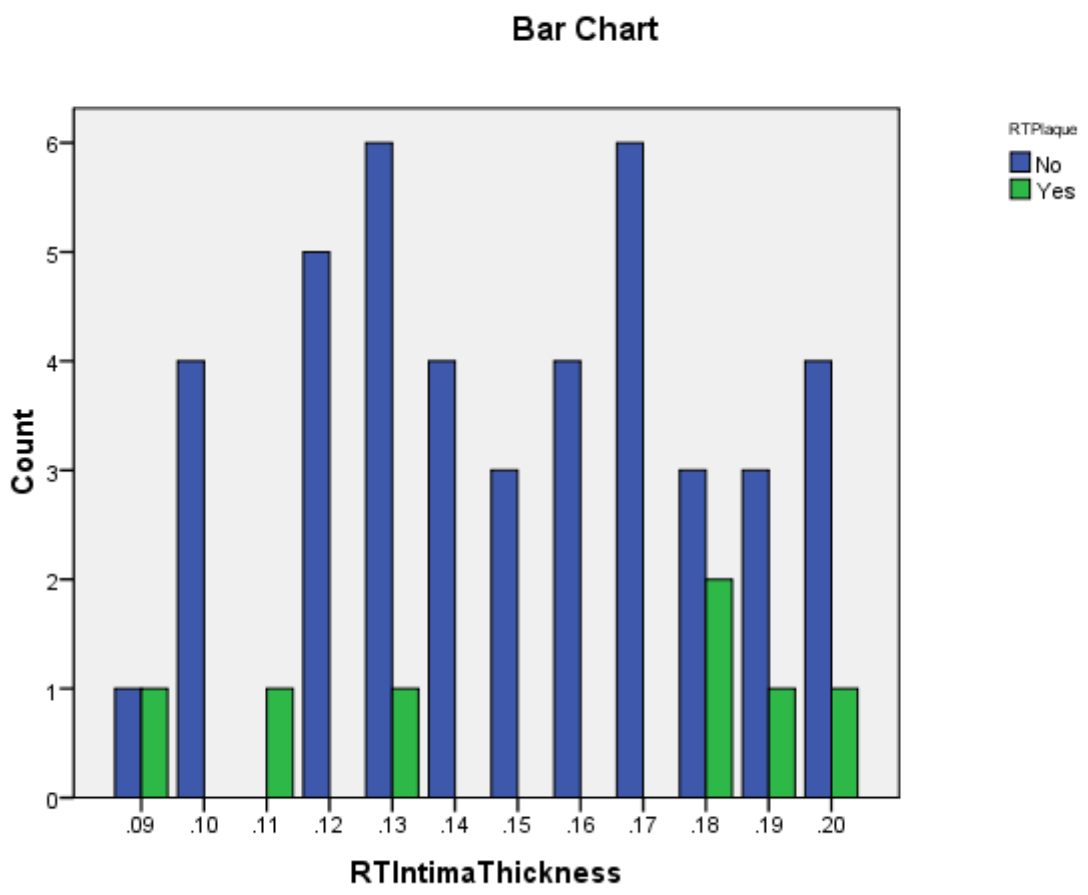

Fig 4.9 shows the RT Intima Thickness and presence of RT Plaque

Table 4.9 shows the Chi test: LT Intima Thickness * LT Plaque

Chi-Square Tests			
	Value	df	Asymp. Sig. (2-sided)
Pearson Chi-Square	6.901[a]	11	.807
Likelihood Ratio	8.419	11	.675
Linear-by-Linear Association	.060	1	.806
N of Valid Cases	50		

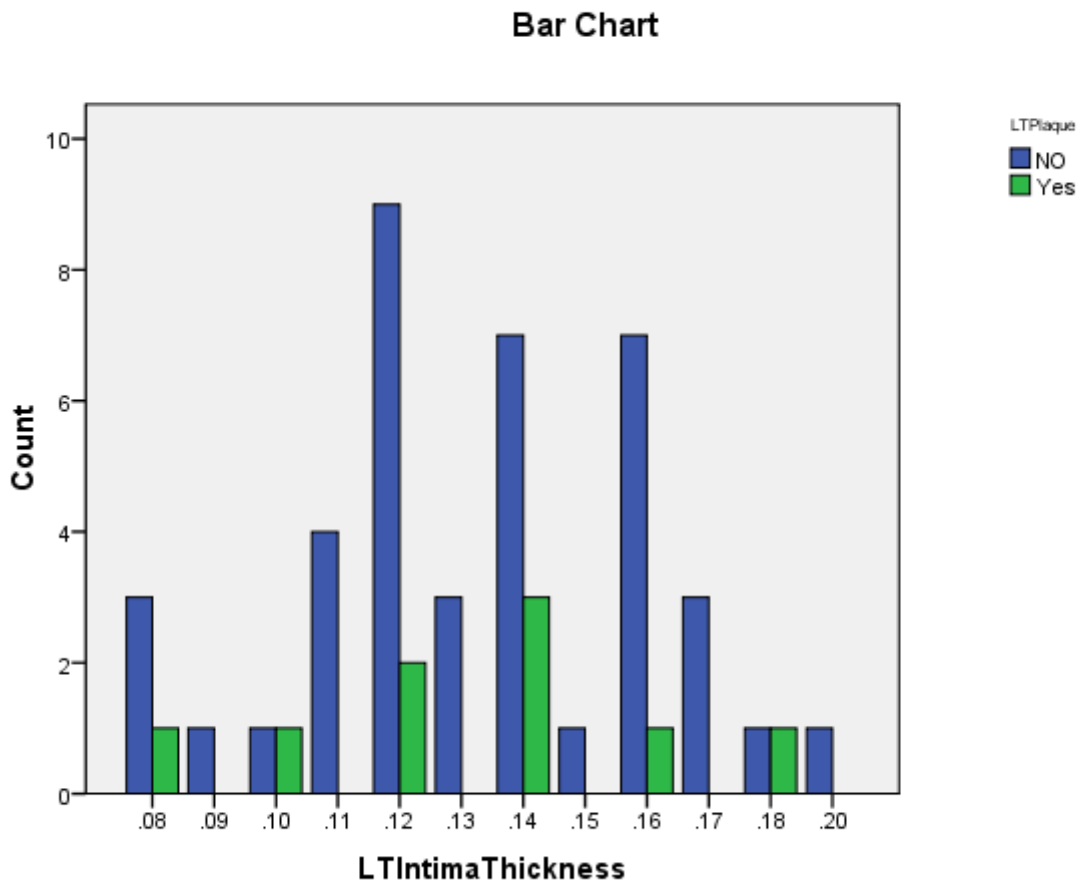

Fig 4.10 shows the Lt Intima Thickness and presence of LT Plaque

Group (2):

- 10 subject had Doppler Ultrasound which was done by the researcher and under supervisor care, machine used
- The following tables and graphs show summary of the result including intima media thickness RI-PI.
- Correlation has been performed for all IMT, RI, PI, variations in this study.
- P-value was calculated to show if there was any significant impact of each variables.
- P-value > 0.05 no significant
- P-value < 0.05 significant

Table 4.10 show the gender, frequency and percentage

Gender	frequency	Percentages
Male	5	50%
Female	5	50%
total	10	100%

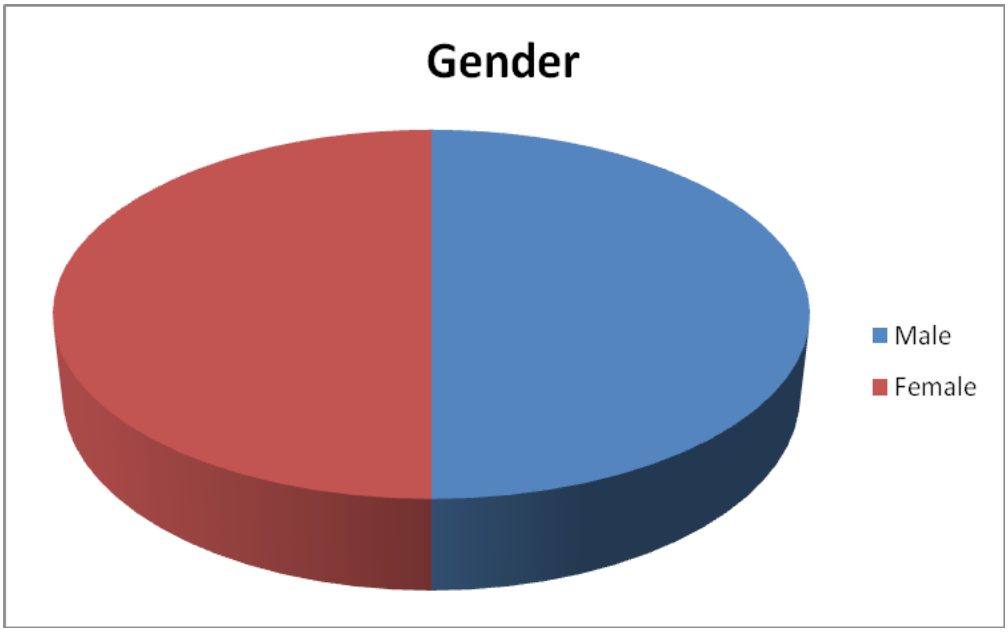

Fig.4.11 pie graph shows the gender, frequency and percentage

Table 4.11 shows the mean and standard deviation of the RT and LT intimae thickness and Doppler Indices

	RT IMT	RI	PI	LT IMT	RI	PI
Mean	0.71	0.68	1.888	0.701	0.747	1.891
STDV	±0.1	±0.1	±0.1	±0.1	±0.1	±0.1
Maximum	0.9	0.8	2.1	0.9	0.85	1.99
Minimum	0.5	0.5	1.75	0.4	0.5	1.74

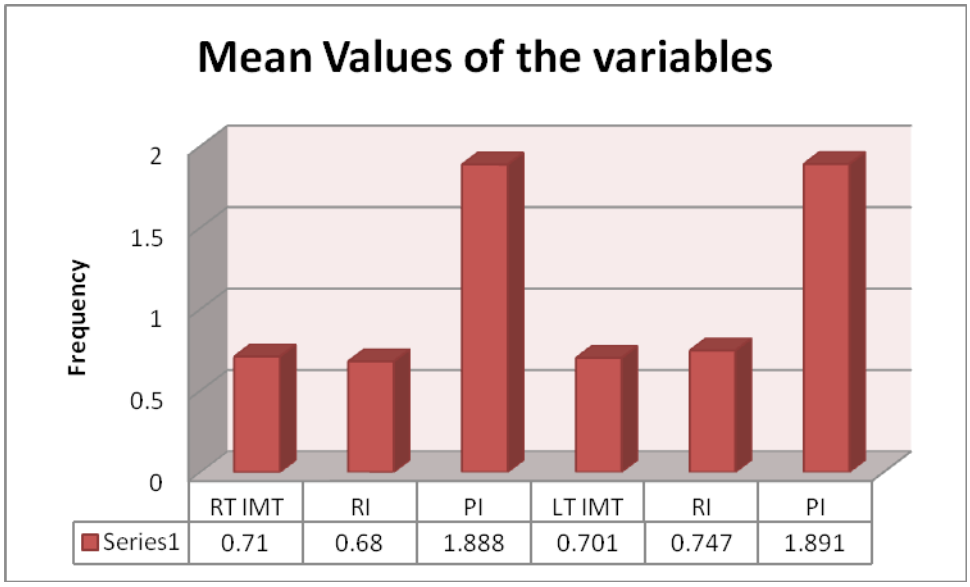

Fig 4.12 shows the mean value of variables

Table 4.12 shows the P-value between the variables

Variables	P-value
RT IMT	0.000*
LT IMT	
RIRT	0.000*
RILT	
PIRT	0.000*
PTLT	
The results showed that there is no significant difference between the RT and LT side	

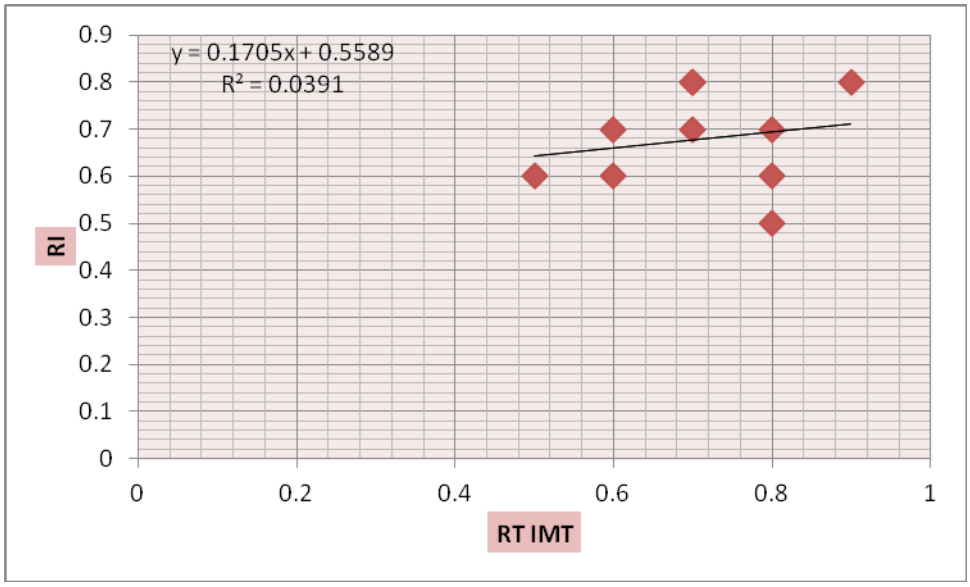

Fig 4.13 scatter plot diagram shows the relationship between RT IMT and RI, as the IMT increased the RI is increased but the increasing is not significant $R^2 = 0.0391$

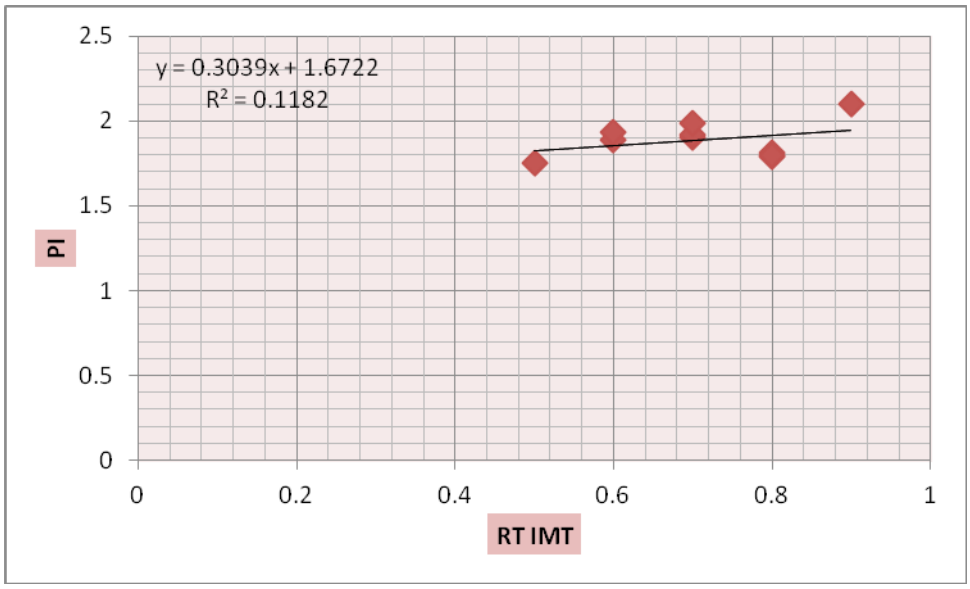

Fig 4.14 scatter plot diagram shows the relationship between RT IMT and PI, as the IMT increased the PI is increased but the increasing is not significant $R^2 = 0.1182$

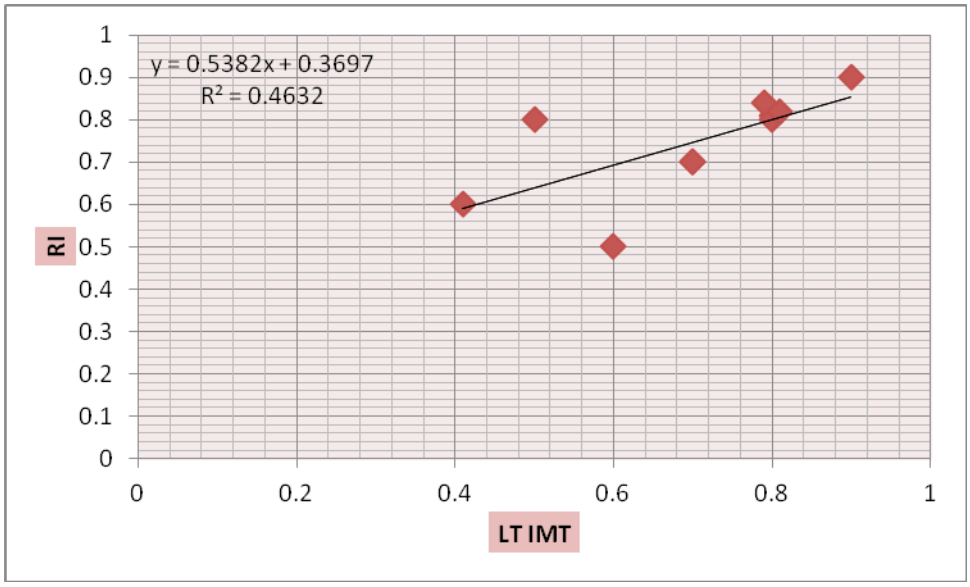

Fig 4.15 scatter plot diagram shows the relationship between LT IMT and RI, as the IMT increased the RI is increased but the increasing is not significant R^2= 0.4632

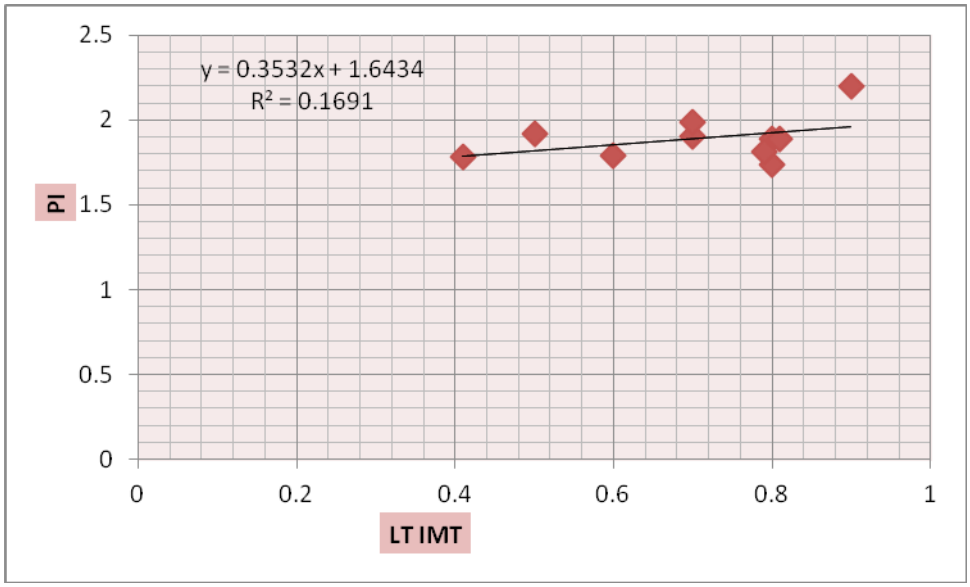

Fig 4.16 scatter plot diagram shows the relationship between LT IMT and PI, as the IMT increased the PI is increased but the increasing is not significant R^2 = 0.1691

Chapter Five

5.1 Discussion:

Whilst the small size is a limitation, these results are important in establishing a trend for larger studies and this study emphasis early detection of carotid artery IMT using gray scale Ultrasound.

A total of 50 patients with DM underwent Ultrasound examination for Rt and Lt CCA age range was 32 – 67 years old.

DM types and percent age was 24% type I patient and 76% type two patient.

The descriptive statistic of the variables show minimal Rt CCA intima thickness of 0.09 cm and maximum Rt IMT is 0.20 cm with mean is 0.15 cm (SD ±0.03).

The Rt CCA caliber was 0.57 cm at minimum and 0.89 cm at maximum with mean of 0.69 cm (SD ± 0.7)

A plaque presentation in Rt CCA noted in 14% only and no plaque presentation 86% of patients.

The Lt CCA Intima Media Thick was 0.08 at minimal and 0.20 cm at maximum with mean of 0.13cm and (SD ± 0.03).

The left common carotid artery minimal caliber was 0.47 cm and maximum caliber was 0.90 cm with mean (0.66 cm) and (SD ± 0.8).

Presence of plaque in the left common carotid artery was noted in 18% and no plaque presented in 82%.

Rt CCA Intima Media Thickening increase as duration of DM increase but is not significant R^2= 0.0005.

Rt CCA caliber decrease as duration of DM but this decreasing is not significant R^2= 0.018.

Lt CCA Intima Media Thickness decrease as duration of DM but this decreasing is not significant R^2= 0.002.

Lt CCA caliber decrease as DM duration increase but this decreasing is not significant R^2= 0.008.

A good correlation was noted between the caliber and diabetes duration in both right and left common carotid artery (inversely proportional).

On other hand a good correlation was noted between the right intima media thickness and diabetes duration (directly proportion).

For the left side of the intima media thickness is inversely proportional to the diabetes duration.

This mean that the two arteries behave differently in diabetes patients this due to anatomic variations between them, as it is known the left carotid artery directly from the aortic arch while the right one arises from brachiocephalic artery.

A good correlation was noted between the Intima media Thickness and the RI and PI.

The intima media thickness is directly proportion to the RI and PI in both right and left common carotid artery.

5.2 Conclusion:

In this study the Right Intima Media Thickness was minimal affected by duration; the change was not detectable for both right and left.

The right and left caliber were decrease by duration but this decreasing is not significant.

The Doppler ultrasound provides useful information on the wall of the blood vessel as well as flowing blood, whereas computed tomography CT and magnetic resonance angiography MRA. The blood and inter the wall characteristic from the shape of the blood flowing in the vessels.

Compared with these two techniques Doppler Ultrasound is relating cheap, rapid, non-invasive and accurate for extracranial carotid disease.

5.3 Recommendations:

Spectral and Doppler imaging of carotid artery Intima Media thickness measurement are recommended after further studies in order to identify atherosclerotic changes is subjects at high risk of stroke and CVD early, the Ultrasound examination will be great value in primary health care preventive medicine.

Gray scale finding and Doppler spectral analysis values must be integrated and correlate for complete Ultrasound assessment and carotid vessels.

As the Doppler ultrasound in operator depended skilled and well practiced operator are needed to perform this technique.

Ultrasound machine should be available in hospitals and clinics.

Literature review showed that there is strong correlation between atherosclerosis of the carotid arteries and coronary arteries so those who showed significant changes in the carotid arteries should be screened for coronary heart disease.

Increase the sample size.

References

(1) Antony S. Fauci, Eugene Broun Wald, Kurt J. Isselbacher, Jean D. Wilson, Joseph B. Martin, Dennis L. Kasper, Stephen L. Houser, Dan L. Longo, Harrisons Principles of internal Medicine: 14th edition.

(2) Carol A. Krebs, Vishan L. Giyanani, Ronald L. Eisenberg, ultrasound Atlas of Disease Processes 1st edition.

(3) Carol M. Rumack, Stephanie R. Wilson, J. William Charboneau, Deborah Levine, Diagnostic Ultrasound 4th edition, 2011.

(4) Christopher Haslett, Edin R. Chivlers, John A. A. Hunter, Noicholas A. Boon, Davidson's: principles and practice of medicine, 18th edition.

(5) Larry P. Tilly, Francic W. K.Smith, other, Dana Allen Stedmans procedure, edition 27th 2003.

(6) Marwan S. M. AL- Nimer and Ismail Alhussain, Int J diabetes dev ctries, March 2009.

(7) Paul L. Allan, Paul A. Dubbins. Myron A. Pozinak, W. Norman Mc Dicken, Clinical Doppler Ultrasound, 3rd edition, 2013

(8) Richard S. Snell, Emeritus professor of anatomy, 9th edition, 2001.

(9) Sandra L. Hagen-Ansert, Text Book of diagnostic Ultrasonography 4th edition.

(10) Sayed Amir Gilani, Introduction to Vascular Ultrasound.

(11) Stedman's Medical Dictionary: 27th edition.

(12) The Burwin. Institute of diagnostic ultrasound – module three.

(13) www.myroadtomedicalschool.blogspot.com

(14) www.quizlet.com.com

Appendixes

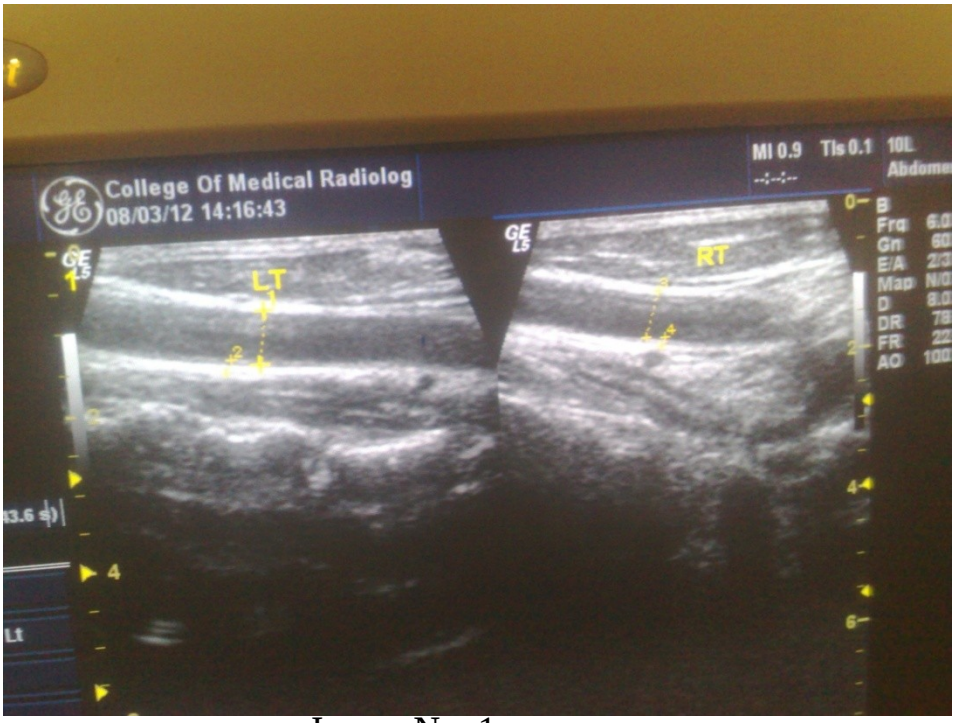

Image No. 1

Longitudinal scan for right and left CCA show normal intima media thickness and caliber using B mode U/S

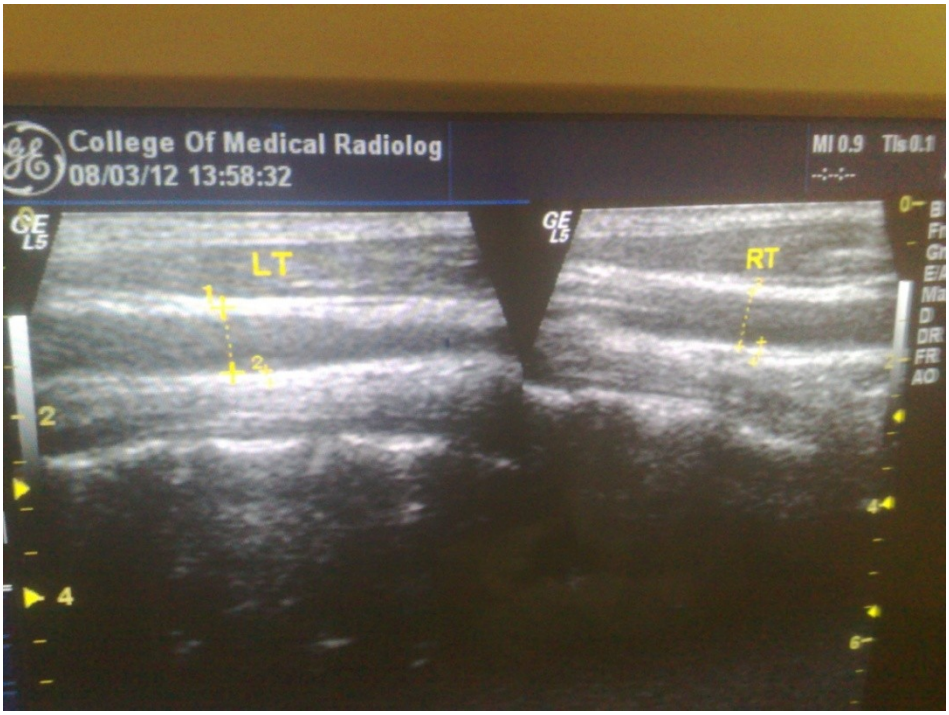

Image No. 2

B mode U/S for CCA show the typical view of normal IMT with two echogenic lines separate with hypoechoic

Image No. 2

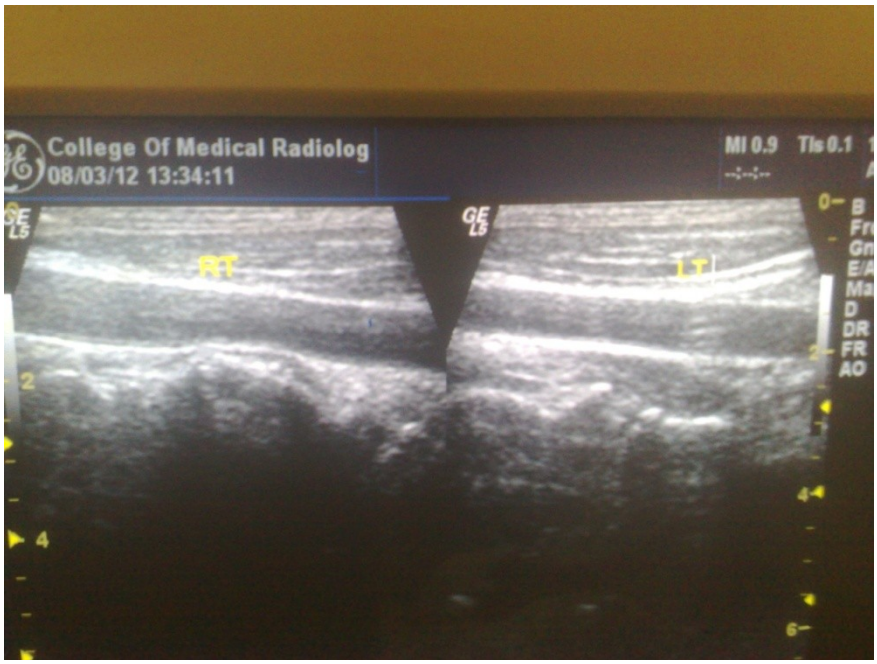

Image No 3

Longitudinal scan for CCA show the IMT and caliber

Image No. 4

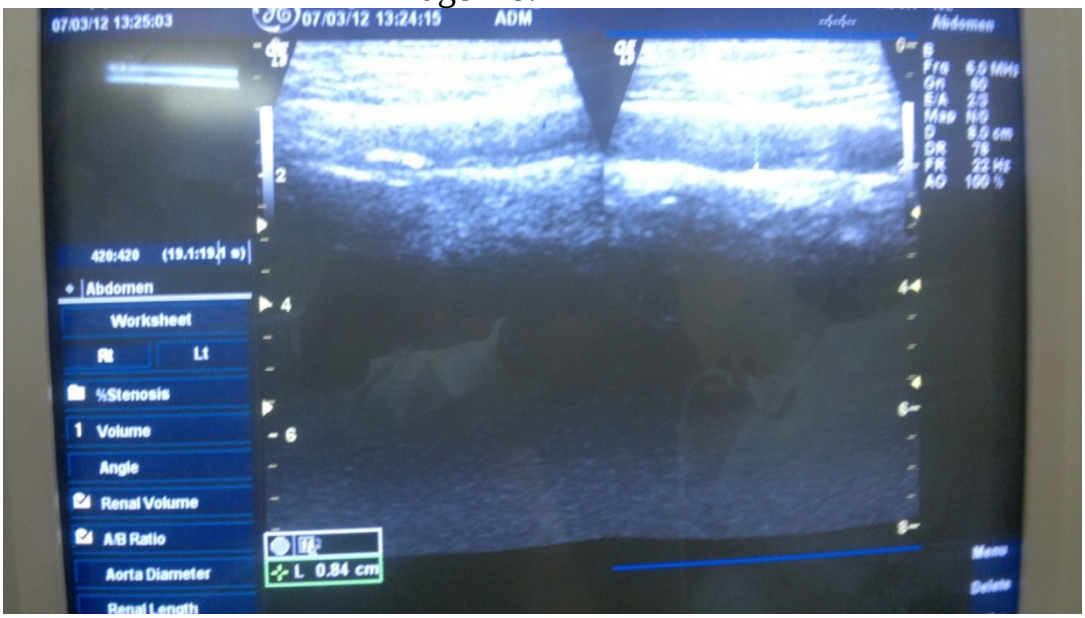

Longitudinal scan for CCA show the calcified plague in the far wall of the artery

Image No. 4

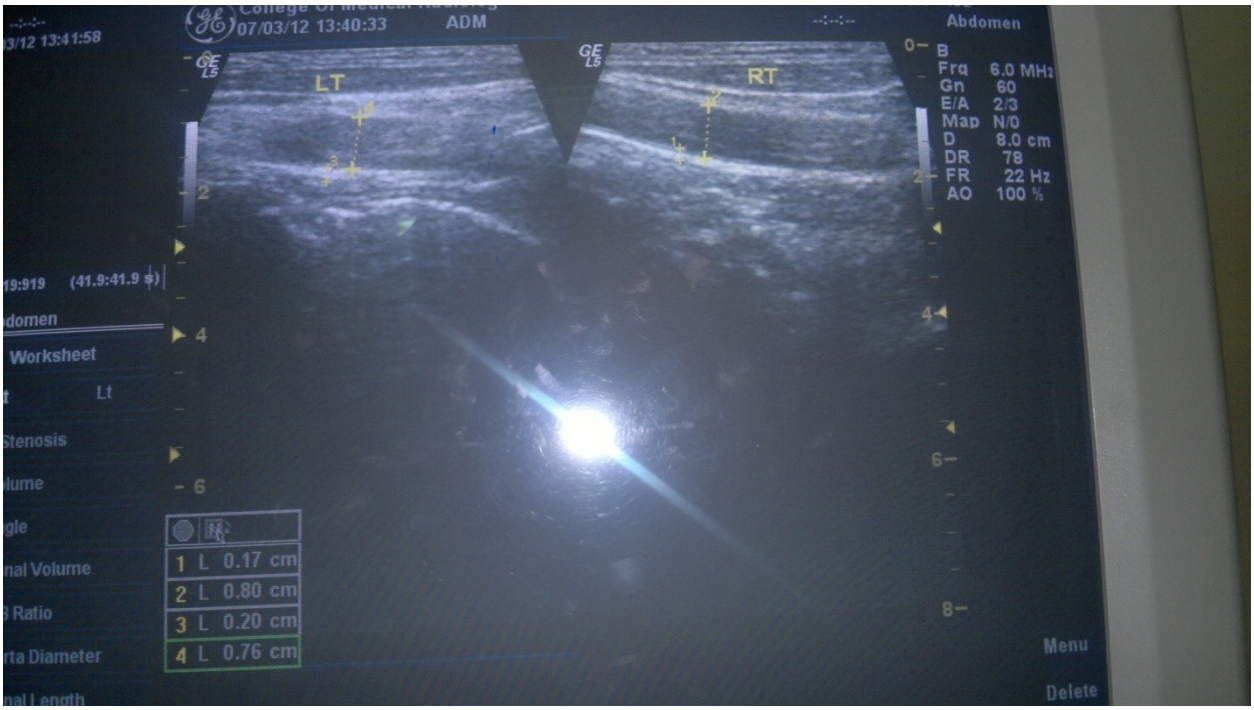

Image No.5

B. mode U/S of CCA to measure the IMT and caliber for right and left

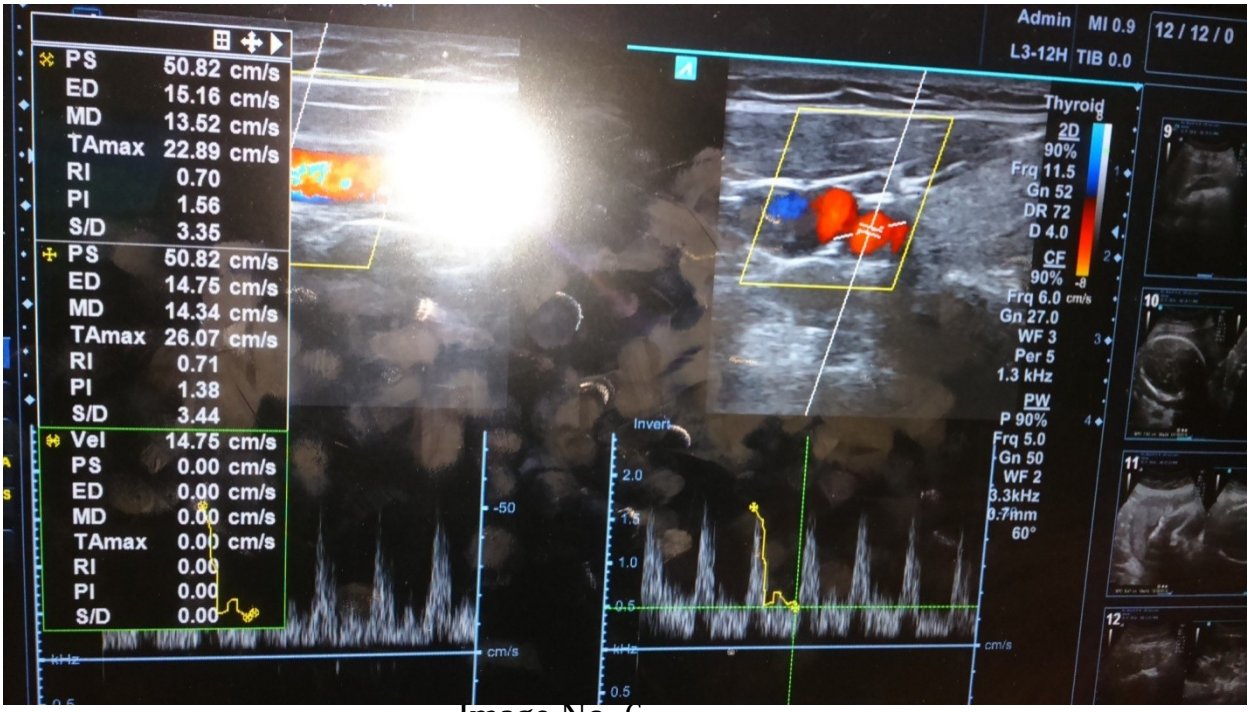

Image No. 6

Typical normal Doppler spectra obtain from CCA

Image No. 16

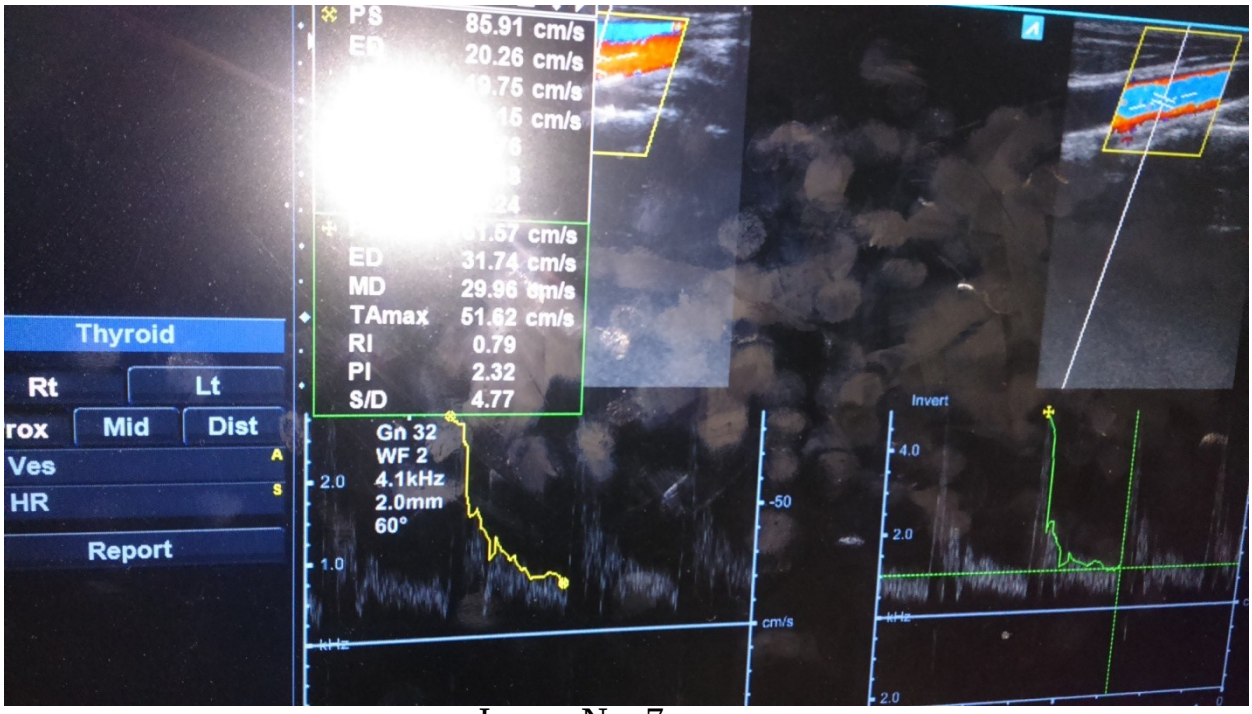

Image No. 7

Color Doppler U/S of CCA, the Doppler sample volume is central in the artery and the wave form is normal

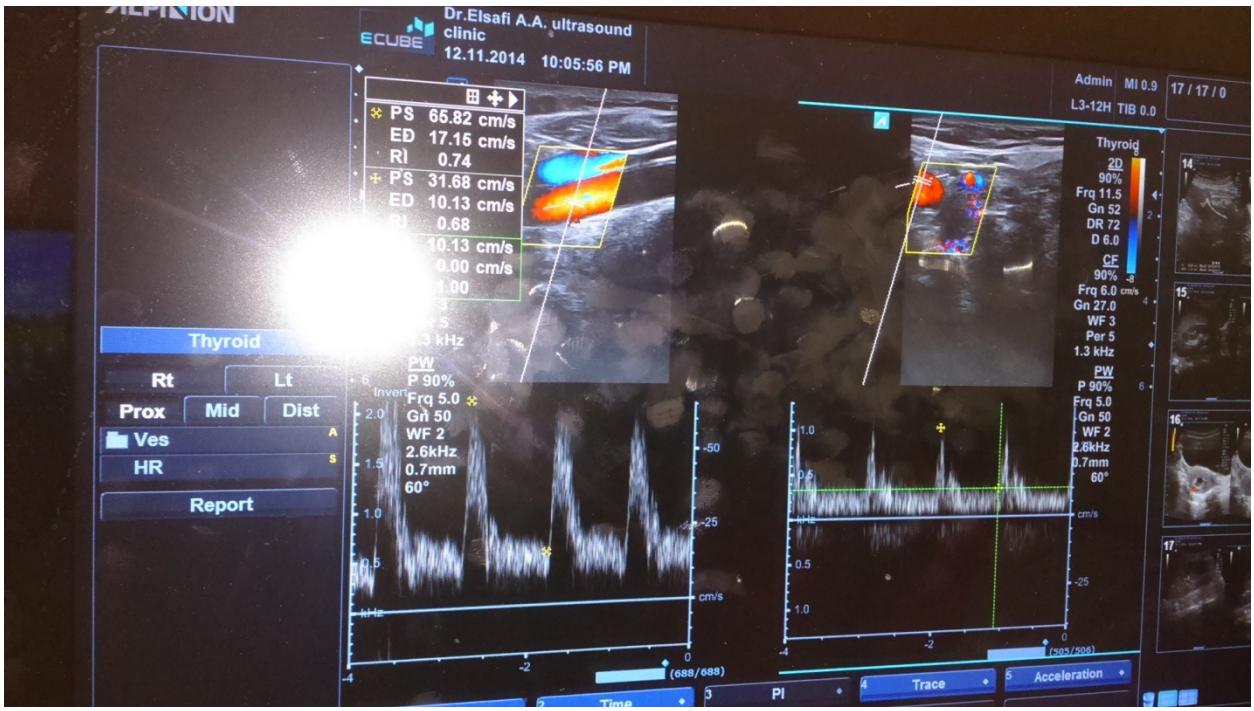

Image No.8

Normal flow of the CCA and normal RI and PI of the wave form

Image No. 18

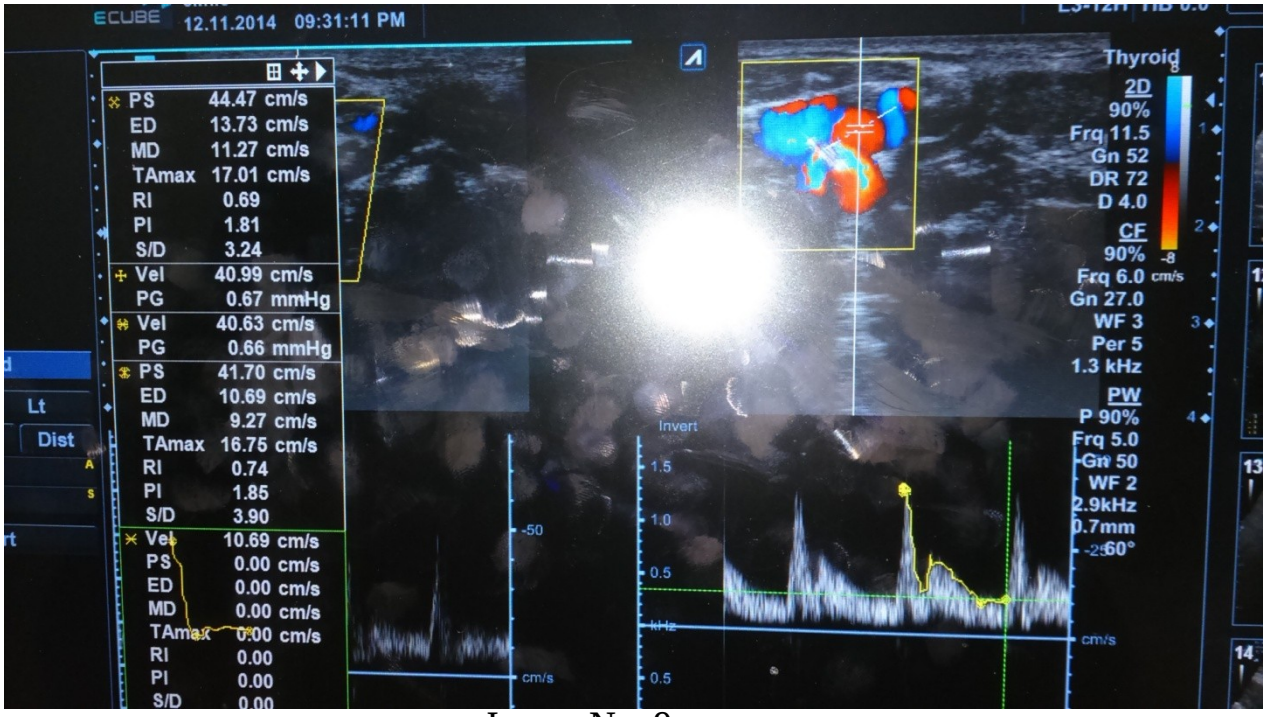

Image No. 9

Transverse scan of the CCA show the normal arterial wave form

Image No. 10

Transverse scan of the CCA show the normal flow pattern and normal spectral wave form

Image No. 20

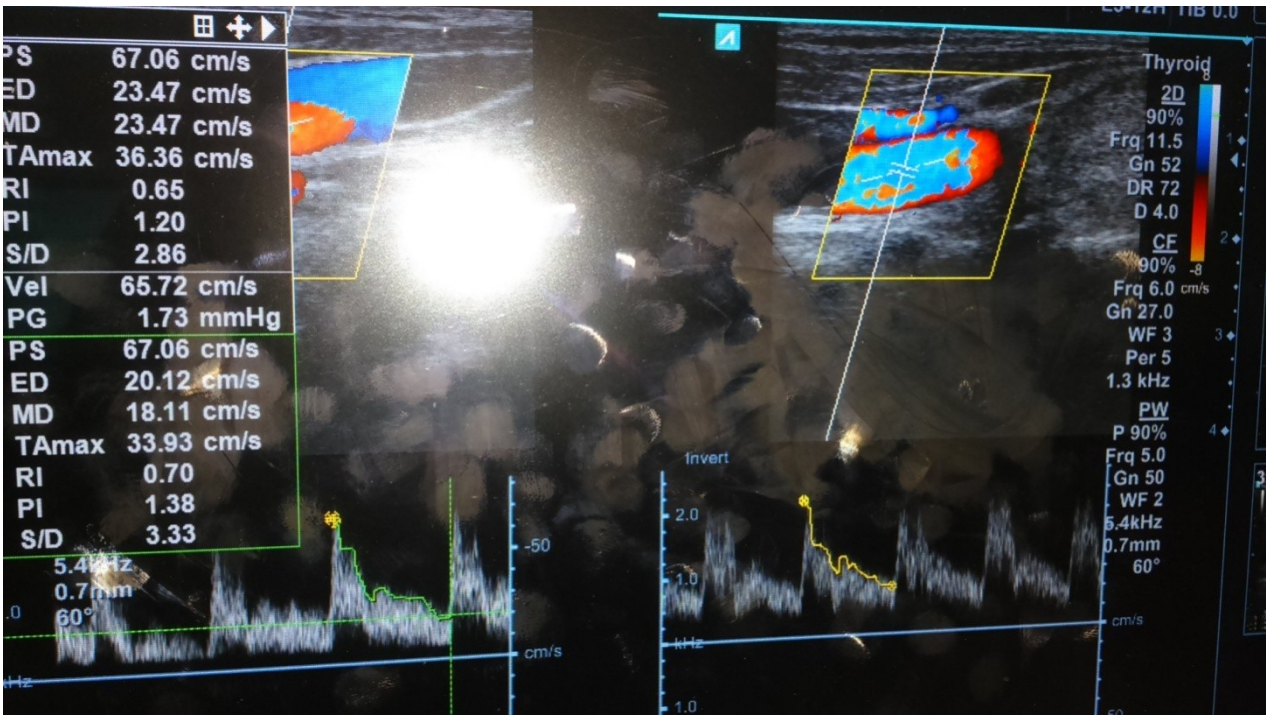

Image No. 11

Longitudinal scan for CCA show the normal flow and sample volume is central in the artery and the normal spectral wave form