بسم الله الرحمن الرحيم

Sudan University of Sciences& Technology

College of Graduate study

Classification of Brain MRI Image of Normal And Convulsion Pediatric By Using Texture Analysis

تصنيف صور الرنين المغنطيسي لدماغ الاطفال الاصحاء و المصابين بالتشنجات باستخدام التحليل النسيجي

A Thesis Submitted in Partial Fulfillment for the Requirements of Master Degree of Science in Radiological Technology

By:

Shaza Elfadel Said Ahmed.

B.Sc. in Diagnostic Radiology

Supervisor:

Dr. Mohamed Alfadil Mohamed Garel-naby

Associate professor

January 2015

بسم الله الرحمن الرحيم

قَالَ تَعَالَىٰ:

﴿ ٱللَّهُ لَآ إِلَٰهَ إِلَّا هُوَ ٱلۡحَيُّ ٱلۡقَيُّومُۚ لَا تَأۡخُذُهُۥ سِنَةٞ وَلَا نَوۡمٞۚ لَّهُۥ مَا فِي ٱلسَّمَٰوَٰتِ وَمَا فِي
ٱلۡأَرۡضِۗ مَن ذَا ٱلَّذِي يَشۡفَعُ عِندَهُۥٓ إِلَّا بِإِذۡنِهِۦۚ يَعۡلَمُ مَا بَيۡنَ أَيۡدِيهِمۡ وَمَا خَلۡفَهُمۡۖ وَلَا
يُحِيطُونَ بِشَيۡءٖ مِّنۡ عِلۡمِهِۦٓ إِلَّا بِمَا شَآءَۚ وَسِعَ كُرۡسِيُّهُ ٱلسَّمَٰوَٰتِ وَٱلۡأَرۡضَۖ وَلَا يَـُٔودُهُۥ
حِفۡظُهُمَاۚ وَهُوَ ٱلۡعَلِيُّ ٱلۡعَظِيمُ ٢٥٥ ﴾

صدق الله العظيم

سوره البقره الايه 255

Dedication

I thank almighty GOD for giving me the courgeand the determination as well as guidance in conducting this research study despite all difficult.

Thanks you for your unconditional support , I am honored to have you as my parent , thanks you for my giving me a chance to prove and improve myself through all my wake of life

TO MY PARENT

Thank you for believing in me ,for allowing me to further my studies place don't ever doubt my dedication and love for you.

TO MY Family

Hoping that with research i have a person's to you that there is no mounting higher as long as god is on our side

To my friends

Acknowledgments

I would like to express my deep gratitude to my master thesis advisor

Dr: MOHMED ELFADIL GAR ELNABY

I have learned many things since I became ***Dr: Mohamed's*** *student, I am also grateful to* ***Dr: Hussein and Abdurrahman Mohamed nor and radiology technologist in Alamal hospital for*** *facilitating data collection, during the research periods .I am very thankful to all of them. last but not the least important ,Iowa more than thanks to* ***my family*** *members which includes* ***my parents*** *For their support and encouragement throughout my life without their support it is impossible for me to finish my college and graduate education seem Lesley.*

Abstract

This study is an effort to study brain - white matter (WM), gray matter (GM), cerebrospinal fluid (CSF) - in MRI images which shows normal appearance if the patients were normal or had convulsion, through computerized analysis. The main objective of this study was to identify brain tissue as normal and abnormal "convulsion" pediatric using textural analysis. The textural features were extracted from the whole MRI image using a window of 3×3pixel wide, where the first order statistics (mean, standard deviation, Coefficient of variation etc…) were extracted using one pixel interlace. The features in the window were classified as GM or WM or CSF as well as normal or abnormal using K-means and discriminate analysis. The images were collected from MRI brain scans for 41 patients presented for examination in the period from July 2014 to December 2014, 5 patients is control and 36 patients as cases underwent epilepsy protocol and T1, T2 and FLAIR images obtained. Segmentation analysis and ratios are compared between structures of the both diseased and control groups. the classification technique were adopted as a method of pattern identification the image into normal or elliptic classes. Linear discriminate analysis using steps wise were used to classify the WM, GM and CSF into the predefined classes normal and convulsion one. The result of this classification showed that the white matter of the convulsion cases showed a high classification accuracy of 99.5% and demarked as separate class from the rest of the class's weather it normal or abnormal. In conclusion the white matter of the convulsion cases texturally were very different from the normal one while from visual perception point of view they appear similar

الملخص

أجريت هذه الدراسه لدراسه الدماغ عند الاطفال المصابين بالتشنجات وقد استهدفت الدراسة ثلاثه اجزاءوهي الانسجه البيضاء والرماديه اضافه الي سائل النخاع الشوكي في صور الرنين المغنطيسي للدماغ والتي كانت نتيجتها طبيعيه في كل العينات التي تم تشخيصهاواستخدمت ايضا مجموعه من الاطفال الاصحاء ،تم اخضاع الفئتين الي التحليل بواسطه بواسطه برامج تحليل الطيف المحوسبه (IDL) .

تم استخراج خصائص النسيج من كل صور الرنين المغنطيسي باستخدام نافذه بحجم 3*3بكسل عن طريق تقنيه الأوامر الأوليه من برنامج التحليل باستخدام (الوسط الحسابي ،الانحراف المعياري،ومعامل الاختلاف،.....) وتم تقسيمها وتصنيفها باستخدام تقنيه البكسل الواحد الي أنسجه طبيعية وغير طبيعية في الثلاث أنسجة باستخدام المتوسط _ك والتحليل التمييزي في برنامج التحليل الاحصائي ،تم جمع عينات الدراسة من41 مريض في الفترة من يوليو والي ديسمبر2014 وتم تقسيم العينات الي مجموعتين ، 5مرضاء استخدموا كعينات مرجعية و36 مريض بغرض الدراسة ،وهم الذين يحملون المرض وتم اخضاعهم جميعا للتصوير بالرنين المغنطيسي تمت مقارنة التحليل بين المجموعتين وصنفت الي طبيعية ومتشنجة وكانت النتيجة أن النسيج الأبيض من الدماغ للمتشنجين يمتلك دقة تصنيفية عاليه بنسبه99.5%وصنف علي أنه صنف مختلف بصوره كبيرة عن بقية الانسجة.وعليه يمكن القول أن النسيج الأبيض يختلف عن بقيه الأنسجه في المريض ذوي التشنجات علي الرغم من انه لا يمكن رؤيه الأختلاف بالعين المجرده .

List of Content

Content	Page number
الايه	I
Abstract (English)	II
Abstract(Arabic)	III
Dedication	IV
Acknowledgment	V
List of content	VI
List of tables	VII
List of figures	VIII
List of abbreviations	XI
Chapter one	
1.1 Introduction	1
1.2 problem of the study	3
1.3 Objective of the study	3
1.4 Significance of the study	4
1.5Over view of the study	4
Chapter tow	
2.1 Brain anatomy and physiology	5
2.2Etiology of the convulsion and epilepsy	10
2.3 Convulsion neuropathology	13
2.4 Brain imaging	14
2.5 Previous study	15
Chapter three	
3.1Materials of the data collection	19
3.1.1 MRI system	19
3.1.2 Design of the study	19
3.1.3 population of the study	19
3.1.4 Sample and type of the study	19
3.1.5 Place and duration of the study	19
3.2 Method of the data	20
3.2.1Technique	20
3.2.2 method of analysis	20
Chapter four	
Result	23
Chapter five	
5.1Disscicion	30
5.2Conculsion	33
5.3Recommendation	34
5.4 Reference	35
Appendix	36

List of The Table

No	content	Page number
Table 4-1	coefficient, mean, variance and stander deviation of the classes for normal and abnormal of the white and gray matter and CSF	26

List of The Figures

No	content	Page number
Fig2-2	normal anatomy of brain	6
Fig2-2	coronal cut o the brain illustrate the white and gray matter	9
Fig2-3	ventricle of brain	10
Fig2-4	Evaluation of pediatric febrile seizures	14
Fig3-1	Flow chart of the method analysis	23
Fig4-1	sample of orignal MRI and their coresponding classication map for convolution cases from A to C (MRI images) and from A- to C- the classification map. Similarrly for normal case as shown by the rest of the images and classification map.	25
Fig4-2	Illustrate the map of the canonical discriminate function for class of normal and abnormal classes of gray; CSF with the center of the class has star shape.	26
Fig4-3	an error bar plot of the COV features for the normal and abnormal of the white matter, gray matter and cerebrospinal fluid which demonstrate that higher value of discrimination scored by abnormal white matter compared with the normal and abnormal of other class	27
Fig4-4	an error bar plot of the feature mean for the normal and abnormal of the white matter, gray matter and cerebrospinal fluid which demonstrate that higher value of discrimination scored by abnormal white matter compared with the normal and abnormal of other classes	28

List of Abbreviations:

CAD	COMPUTER AXIAL DIAGNOSIS
CNS	CENTERAL NERVOUS SYSTEM
CSF	CEREBROSPINAL FLUID
COV	COEFFICENT OF VARITION
CAT	COMPUTED AXIAL TOMOGRAPHY
CT	COMPUTED TOMOGRAPHY
EEG	ELECROENCEPHALOGRAPHY
FOV	FIELD OF VIEW
FLAIR	FLIUD ATTENUATED INVERSION RECOVERY
GM	GRAY MATTER
GMA	GRAY MATTER ABNORMAL
MRI	MAGNETIC RESONACE IMAGE
MRS	MAGNETIC RESONACE SPECTROSCOPY
PET	POSITRONE EMISSION TOMOGRAPHY
ROI	REGION OF INTEREST
SD	STANDER DIVITION
SOL	SPACE OCCUPIED LESION
SPECT	SINGLE PHOTO EMISSION COMPUTED TOMOGRAPHY
T1	T1 RELAXITION TIME
T2	T2 RELAXITION TIME
WM	WHITE MATTER
WMA	WHITE MATTER ABNORMA

Chapter One

1.1 Introduction:

Convulsion is a medical condition where body muscles contract and relax rapidly and repeatedly, resulting in an uncontrolled shaking of the body. Because convulsion is often a seizure, however, not all epileptic seizures lead to convulsions, and not all convulsions are caused by epileptic seizures. Convulsions are also consistent with an electric shock. The word "fit" is sometimes used to mean a convulsion or epileptic seizure , Febrile convulsions are seizures that occur because of fever, which is a temperature higher than 38°C. High fevers might come with an infection. We don't know why, but in these cases, the rapid rise in temperature causes an abnormal electrical discharge in the brain ,Febrile convulsions are pretty common, occurring in about 4% of children between the ages of six months and five years. Two-thirds of these children will only ever have one fit. Most will occur while the child is younger than three years old; children who have their first febrile convulsion before the age of one year have a higher risk of having recurrent febrile convulsions. This type of convulsion tends to run in families, and affects boys more often than girls. (www .Convulsions in pediatric.com)

Epilepsy is a medical condition that produces seizures affecting a variety of mental and physical functions. It's also called a seizure disorder. When a person has two or more unprovoked seizures, they are considered to have epilepsy, and is among the least understood of major chronic medical conditions, even though one in three adults knows someone with the disorder, it affects nearly 50 million worldwide and strikes most often among the very young and the very old, although anyone can develop it at any age and the mortality rate among people, with epilepsy is two to three times higher and the risk of sudden death is 24 times greater than that of the general population.

(www. epilepsyfoundation.org)

Convulsion is one of the most common serious disorders of the brain, and accounts for 1% of the global burden of disease, can be cause by determined the number of productive life years lost as a result of disability or premature death. Among primary disorders of the brain, this burden ranks with depression and other affective disorders, Alzheimer's disease and other conditions, it ranks with breast cancer in women and lung cancer in men. Eighty percent of the burden of epilepsy is in the developing world, where 80–90% of people with

epilepsy receive no treatment at all. It is also necessary to recognize that epilepsy consists of more than seizures for the affected individual and effects on his or her family. Epilepsy leads to multiple interacting medical, psychological, economic and social repercussions, all of which need to be considered. For appropriate management of people with epilepsy, diagnostic services constitute an important resource, Computerized axial tomography (CAT),magnetic resonance imaging (MRI), electroencephalography (EEG) and long-term video/ EEG monitoring are available to health professionals in 85%, 69%, 87% and 50% of the responding countries, respectively.**(World Health Organization,2005)**

Seizures are the most common pediatric neurologic disorder, with 4% to 10%of children suffering at least one seizure in the first 16 years of life. The incidence is highest in children younger than 3 years of age, with a decreasing frequency in older children. Epidemiologic studies reveal that approximately 150,000 children will sustain a first-time, unprovoked seizure each year, and of those, 30,000 will develop epilepsy. Febrile seizures are the most common type of seizure in young children, with a 2% to 5% incidence of children experiencing at least one seizure before the age of 5 years. A febrile seizure is defined as a convulsion that occurs in association with a febrile illness in children between 6 months and 5 years of age. A simple febrile seizure is single, brief about 15 minutes and generalized. A complex febrile seizure is much less common (approximately 20%) and is recurrent in a single illness, prolonged 15 minutes and focal. The peak age for febrile convulsions is between 18 and 24 months. **(Friedman, 2006).**

Epileptic conditions can be thought of in three broad categories. In the first place seizures can occur in a normal brain, precipitated by specific factors such as hypoxia or hypoglycemia. This type of seizure may be experienced by anyone, depending on the circumstances. Second, seizures can occur in an apparently structurally normal brain, but with a known tendency to seizures, whether genetic, biochemical, or otherwise. Finally, seizures can occur in a brain that has a definite structural abnormality, either focally or diffusely. While this may seem an obvious distinction, it is essential to determine which category any given patient fits into, and it is not always immediately obvious which situation applies.**(Kuzniecky, 2004)**

In order to make this distinction the clinical history and investigations such as EEG (function) and MRI (brain structure) may be essential. Epilepsy is a general term that cannot be considered a diagnosis, To say that a person has epilepsy is not in any way specific, and should not be considered to be a complete diagnosis. While it may give a general indication of the nature of a problem, it is so nonspecific as to be almost meaningless in many contexts. Epilepsy encompasses a large number of conditions that can manifest as a variety of seizure types. **(Kuzniecky, 2004)**

1.2 Problem of the study:

As convulsion get rising as a serious hard- burden disease on entire world, more researches and studies try to fulfill and recognize that the temporal lobe and gray and white matter are the areas stands for the convulsion. Diagnostic Imaging with MRI play majority in such investigations. However MRI of a patient brain with convulsion usually shows no specific differentiation or malfunctions of related areas and appears normal. Therefore texture analysis might help in revealing differences between the normal and abnormal brain tissue since it deals with the microstructure pattern orientation rather than intensity appearances.

1.3 Objectives of the Study:

The main aim of this study was to classify brain MRI image of normal and convulsion pediatric using texture analysis overcome the limitation of visual perception system..

1.3.1Specific Objectives:

- To identify the region of interest (ROI) in MRI images(WM,GM,CSF,BONE)
- To extract the textural feature from the ROI (WM,GM,CSF,BONE)
- To classify the extracted feature into gray, white matter and CSF of brain and also the brain images into normal and convulsive one
- To calculate the accuracy of classification algorithms.

1.4 Significance of the Study:

This study will help in identifying the tissue of the brain as white, grey matter and CSF where quantitative analysis could be made to measure the size or volume for each of these tissues. Also texture analysis will help in demarcating the pattern of underlying structure where the normal and abnormal pattern can be recognized and classified, so quantitative measures can be applied for diagnosis rather than the subjective one which depend on the visual perception essence.

1.5 Thesis overviews:

This study will consist of five chapters, chapter one will be an introduction; introduce briefly this thesis and will contain (anatomy, physiology, pathology, problem of study also contain general, specific objectives and significant of the study). Chapter two is literature review about role of MRI images in diagnosis of convulsion, and other modalities might be use. Chapter three will describe the methodology (material, method) will be use in this study. Chapter four will include result of presentation of final finding of study; chapter five will include discussion, conclusion and recommendation for future scope in addition to references and appendices.

Chapter Two
Background

2.1 Brain anatomy and physiology:

The human nervous system functions as a high-speed anatomical and physiological unit. It controls the body's movements, and through its ability to receive, process, and transmit information in the form of chemical and electrical signals, it can adjust and fine-tune its control. The central nervous system consists of the brain and spinal cord, while the peripheral system consists of all the neural nerve tracts that lie outside these central tissues and connect to the rest of the body.**(Rogers, 2011)**

2.1.1 The Brain:

The brain essentially serves as the body's information processing centre. It receives signals from sensory neurons, nerve cell bodies and their axons and dendrites, in the central and peripheral nervous systems, and in response it generates and sends new signals that instruct the corresponding parts of the body to move or react in some way. It also integrates signals received from the body with signals from adjacent areas of the brain, giving rise to perception and consciousness. The cerebrum is the largest, uppermost portion of the brain. It is involved with sensory integration, control of voluntary movement, and higher intellectual functions, such as speech and abstract thought, there are two cerebral hemispheres, one on the left and one on the right side of the brain, the outer layer of each of these duplicate cerebral hemispheres is composed of a convoluted outer layer of gray matter, called the cerebral cortex. It is responsible for conscious behavior and contains three different functional areas: the motor areas, sensory areas and association areas. Located internally are the white matter, responsible for communication between cerebral areas and between the cerebral cortex and lower regions of the CNS, as well as the basal nuclei (or basal ganglia), involved in controlling muscular movement. Nerve fibers, or axons, are long, thin strands of tissue that project from a nerve cell and carry electrical impulses to and from the brain , These fibers connect the two cerebral hemispheres via a thick band of white matter called the Corpus Callosum. Other fibers, called association fibers, connect different regions of a single hemisphere, Myelinated

fibers, fatty white material that forms a sheath around some nerve fibers, projecting to and from the cerebral cortex formed a concentrated fan-shaped band, known as the internal capsule. The cerebrum also contains the basal ganglia, a mass of nerve fiber that helps to initiate and control matters of movement.the cerebral cortex is highly convoluted , the crest of a single convolution is known as a gyrus, and the fissure between two gyri is known as a sulcus. Sulci and gyri form a more or less constant pattern, on the basis of which the surface of each cerebral hemisphere is commonly divided into four lobes: frontal, parietal, temporal, and occipital. **(Rogers, 2011)**

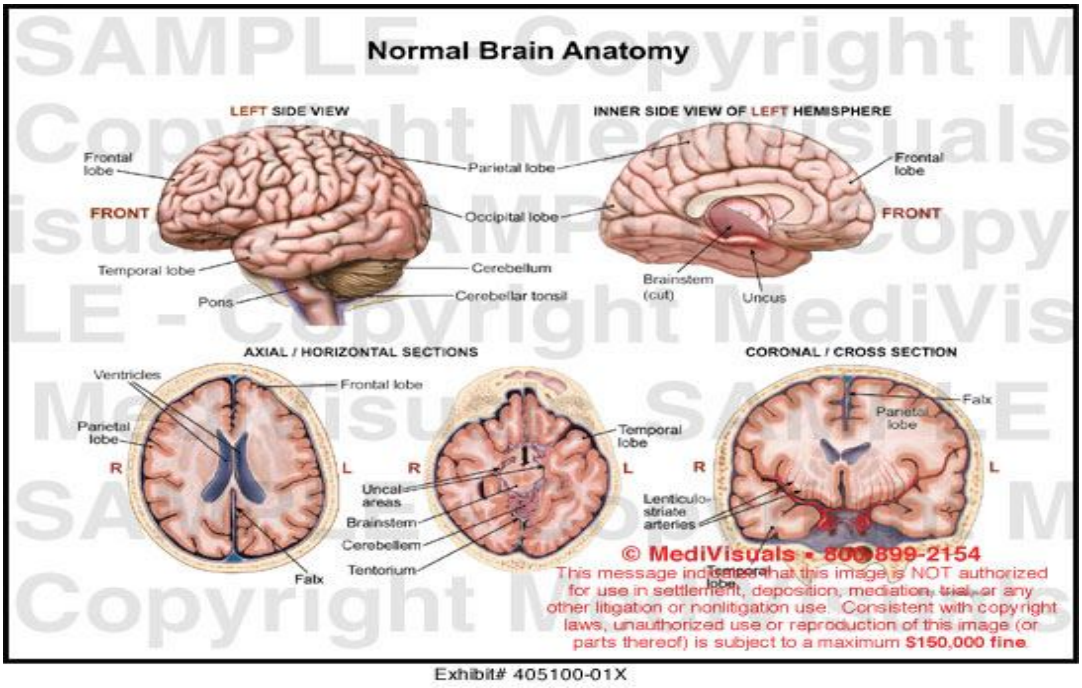

Fig 2-1 normal anatomy of brain **(www.brain_anatomy .com)**

2.1.2 Diencephalon:

The diencephalon is located centrally within the forebrain. It consists of the thalamus, hypothalamus and epithalamus, which together enclose the third ventricle. The thalamus acts as a grouping and relay station for sensory inputs ascending to the sensory cortex and association areas. It also mediates motor activities, cortical arousal and memories. The hypothalamus, by controlling the autonomic (involuntary) nervous system, is responsible for maintaining the body's homeostatic balance. Moreover it forms a part of the limbic system, the 'emotional' brain. The epithalamus consists of the pineal gland and the CSF producing choroid plexus. **(www.medphys.ucl.ac.uk)**

2.1.3 Brain stem:

The brain stem is similarly structured as the spinal cord; it consists of grey matter surrounded by white matter fiber tracts. Its major regions are the midbrain, Pons and medulla oblongata. The midbrain, which surrounds the cerebral aqueduct, provides fibre pathways between higher and lower brain centre's, contains visual and auditory reflex and sub cortical motor centers. The Pons is mainly a conduction region, but its nuclei also contribute to the regulation of respiration and cranial nerves. The medulla oblongata takes an important role as an autonomic reflex centre involved in maintaining body homeostasis. In particular, nuclei in the medulla regulate respiratory rhythm, heart rate, blood pressure and several internal white matter, and small, deeply situated, paired masses (nuclei) of grey matter. The cerebellum processes impulses received from the cerebral motor cortex, various brain stem nuclei and sensory receptors in order to appropriately control skeletal muscle contraction, thus giving smooth, coordinated movements.

(www.medphys.ucl.ac.uk)

2.1.4 Temporal Lobe:

The temporal lobe, which is below the lateral sulcus, fills the middle fossa, or hollow area, of the skull. The outer surface of the temporal lobe is an association area made up of the superior, middle, and inferior temporal gyri. An association area is a part of the cerebral cortex that is connected to both cerebral hemispheres and which helps link parts of the brain that are concerned with motor and sensory function. Near the margin of the lateral sulcus, two transverse (lying across) temporal gyri constitute the primary auditory area of

the brain. The transverse gyri are surrounded by a less finely tuned secondary auditory area. A medial, or inner, protrusion near the underside, or ventral surface of the temporal lobe, known as the uncus, constitutes a large part of the primary olfactory area, concerning the sense of smell**. (Rogers, 2011).**

2.1.5 White matter:

White matter is composed of the CNS in the brain and consist mostly of glial cell and myelinate axons that transmitted the signals from one region of the cerebrum to anther and between cerebrum and lower brain centers, white matter long thought to be passive tissue actively affects how the brain learns and function. The white matter is white because of fatty substance (myelin) that surrounds the nerve fibers (axons) this myelin is found in almost all long nerve fibers and act as an electrical insulation. This important because it allows the massages to pass quickly from place to place **(Http//en Wikipedia.org/wiki/white matter).**

2.1.6 Gray matter:

The gray nervous tissue found in the cortex of the cerebrum and cerebellum and the core of spinal cord. It is predominantly composed of neuron cell bodies and un myelinated axons,the gray color is produced by cytoplasm elements seen in all cell bodies and processes not covered by whitish myeline. Nuclei in the gray substance of the spinal cord function as centers for all spinal reflexes, also called gray substance, substantial grisea. The function of the brain depend on the ability of neurons to transmit electrochemical signals to other cells, and their ability to respond appropriately to electrochemical signals received from other cells. The electrical properties of neurons are controlled by a wide variety of biochemical and metabolic processes, most notably the interactions between neurotransmitters and receptors that take place at synapses. **(http//en Wikipedia.org/wiki/brain).**

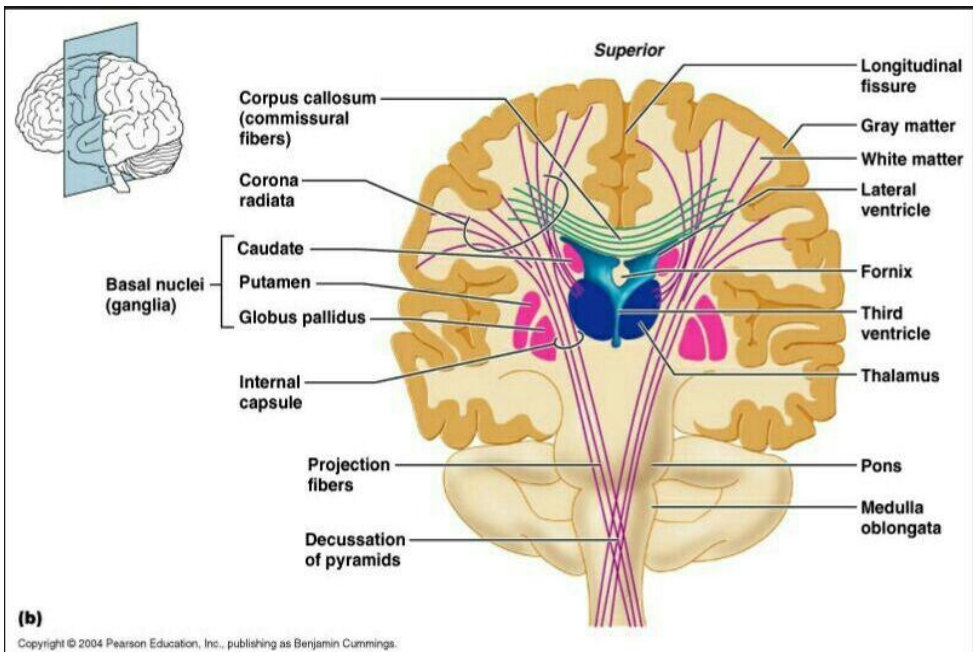

Fig2:2 coronal cut o the brain illustrate the white and gray matter **(www,brain anatomy.com)**

2.1.7 Ventricles of the brain:-

Within the brain there are four irregular-shaped cavities, or ventricles, containing cerebrospinal fluid (CSF).They are right and left lateral ventricles, third ventricle, and fourth ventricle. The lateral ventricles, these cavities lie within the cerebral hemispheres, one on each side of the median plane just below the corpus callosum. They are separated from each other by a thin membrane, the septum lucidum and are lined with ciliated epithelium. They communicate with third ventricle by interventricular foramina. **(Michael.Y.M. et al 1997)**

The third ventricle is a cavity situated below the lateral ventricles between the two parts of the thalamus. It communicates with fourth ventricle by a canal, the cerebral aqueduct or aqueduct of the brain. The fourth ventricle is a lozenge-shaped cavity situated below and behind the third ventricle, between the cerebellum and Pons variolii. It is continuous below with the central canal of the spinal cord and communicates with the subarachnoid space by the foramina in its roof Cerebrospinal fluid central canal of the spinal cord, through these openings and through the open distal end of the central canal of the spinal cord. **(Michael Y.M.et al 1997).**

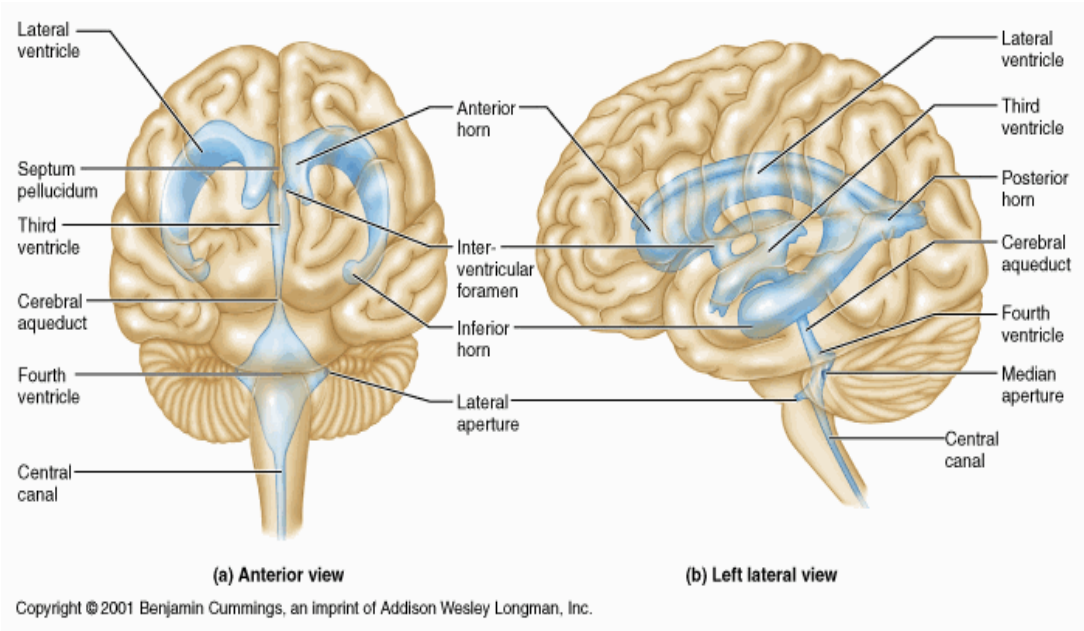

Fig 2:3 ventricle of brain **(www.brain_anatomy .com)**

2.2 Etiology of convulsion and Epilepsy:

A convulsion is a medical condition where body muscles contract and relax rapidly and repeatedly, resulting in an uncontrolled shaking of the body.[1] Because a convulsion is often a symptom of an epileptic seizure, the term convulsion is sometimes used as a synonym for seizure. However, not all epileptic seizures lead to convulsions, and not all convulsions are caused by epileptic seizures. Convulsions are also consistent with an electric shock ,For non epileptic convulsions, a seizure is any clinical event caused by an abnormal electrical discharge in the brain, whilst epilepsy is the tendency to have recurrent seizures. Epilepsy should be regarded as a symptom of brain disease rather than a disease itself. A single seizure is not epilepsy but an indication for investigation, and medication should generally be withheld until recurrent seizures occur. The recurrence rate after a first seizure is about 70% within the first year, and most recurrent attacks occur within a month or two of the first. Further seizures are less likely if a trigger factor is definable and avoidable. In some conditions, epilepsy is the only feature of underlying disease, whilst in others epilepsy is just one of the manifestations. The annual incidence of new cases of epilepsy after infancy is 20–70 of every 100000. The life time risk of having a single seizure is about 5%, whilst the prevalence of epilepsy in European countries is about 0.5%. The prevalence in developing countries is up to five times higher than in developed

countries. The classification of epilepsy is best achieved by considering the clinical events (the seizures), the abnormal electrophysiology and the anatomical site of seizure genesis and the pathological cause of the problem, a low percentage of all children have a seizure when younger than 15 years, half of which are febrile seizures (seizure brought on by a fever). One of every 100 children has epilepsy-recurring seizures**. (Colledge, 2010)**

2.2.1The is many type of the seizure:

2.2.1.1A febrile seizure:

Occurs when a child contracts an illness such as an ear infection, cold, or chickenpox accompanied by fever. Febrile seizures are the most common type of seizure seen in children. Two to five percent of children have a febrile seizure at some point during their childhood.

2.2.1.2 Neonatal seizures:

occur within 28 days of birth. Most occur soon after the child is born. They may be due to a large variety of conditions. It may be difficult to determine if a newborn is actually seizing, because they often do not have convulsions. Instead, their eyes appear to be looking in different directions. They may have lip smacking or periods of no breathing.

2.2.2.3Partial seizures

Only a part of the brain and therefore only a part of the body ,Simple partial seizures have a motor (movement) component that is located in one portion of the body. Children with these seizures remain awake and alert. Movement abnormalities can "march" to other parts of the body as the seizure progresses, Complex partial seizures are similar, except that the child is not aware of what is going on. Frequently, children with this type of seizure repeat an activity, such as clapping, throughout the seizure, they have no memory of this activity, after the seizure ends, the child is often disoriented in a state known as the poetical period. **(www.seizures in children .com)**

2.2.2.4 Generalize seizure:

Involve a much larger portion of the brain. They are grouped into 2 types, convulsive (muscle jerking) and non convulsive with several sub groups, convulsion seizures are noted by uncontrollable muscle jerking lasting for a few minutes-usually less than 5-followed by a period of drowsiness that is called the postictal period,the child should return to his or her normal self except for fatigue within around 15 minutes. Often the child may have incontinence (lose urine or stool), and it is normal for the child not to remember the seizure. Sometimes the jerking can cause injury, which may range from a small bite on the tongue to a broken bone. **(www.seizures in children .com)**

2.2.2.5Partial epilepsy:

Partial seizures may arise from any disease of the cerebral cortex, congenital or acquired, and frequently generalize. With the exception of a few idiopathic partial epilepsies of benign outcome in childhood, the presence of partial seizures signifies the presence of focal cerebral pathology. The occurrence of a partial seizure implies an origin of the seizure in a focal, but not necessarily small, area of the brain, with a tendency for propagation. Focality is also suggested through EEG analysis, Positive yields from imaging of patients with partial seizures, both simple (without loss of consciousness) and complex (with loss of consciousness), are considerably higher than those from imaging of patients with generalized seizures whose neurologic examination is normal. In a study by Jan et al, neuroimaging was positive in more than 50% of patients whose seizures had focal features, MRI was considerably more sensitive than CT. **(Karis, 2008)**

2.2.2.6Generalized Epilepsy:

It is originating uniformly in the entire brain and classified into primary and secondary.

The Primary generalized epilepsy, or idiopathic epilepsies make up some 10% of all epilepsies, including some 40% of those with tonic colonic seizures. Onset is almost always in childhood or adolescence. No structural abnormality is present and there is often a substantial genetic predisposition. Some, like childhood absence epilepsy, are relatively uncommon, whilst others, are common (5–10% of all patients with epilepsy). And the Secondary generalized epilepsy may arise from spread of partial seizures due to structural

disease, or may be secondary to drugs or metabolic disorders. Epilepsy presenting in adult life is almost secondary generalized, even if there is no clear history of a partial seizure before the onset of a major attack. The occurrence of epilepsy in those over the age of 60 is frequently due to cerebrovascular disease and presents specific diagnostic and management problems. **(shorvon, 2004)**

2.3 Convulsion Neuropathology:

When taking a history from a patient with suspected seizure, it is important to clarify which type of attack is occurring, bearing in mind that there may be more than one occurring in the same patient at different times. Sometimes specific, Trigger factors can be identified. When a person with recurrent seizures is diagnosed with epilepsy, a complete physical examination, blood tests, and a Neurological evaluation may be necessary to identify the cause of the disorder.

Electroencephalogram (EEG) monitoring is performed to detect abnormalities in,the electrical activity of the brain. Magnetic resonance imaging (MRI), positron Emission tomography (PET), and single photon emission computed tomography (SPECT), or magnetic resonance spectroscopy (MRS) may be used to locate Structural or biochemical brain abnormalities**. (Rogers, 2011).**

2.4 Brain Imaging:

Brain imaging is defined as neuroimaging that use various imaging modalities with different techniques to either directly or indirectly image the structure and function of the brain. Neuroimaging diverge into two broad categories; Structural imaging which is involved with the structure of the brain and the diagnosis of gross intracranial disease, such as tumor, malformations, trauma , and functional Imaging which is used to diagnose metabolic and cognitive psychological diseases such migraine, Alzheimer etc….

The major neuroimaging modalities include computed tomography (CT), magnetic resonance imaging (MRI), single photon emission computed tomography (SPECT), positron emission tomography (PET) , carotid and transcranial ultrasound, as well as interventional neuroimaging, which includes catheter angiography and myelography. Neuroimaging in Pediatric Epilepsy can be helpful tool for understanding the mechanisms underlying this syndrome with special consideration in the imaging in the inability of

children to cooperate for the long image acquisition times required, therefore in some cases sedation is required.Positron emission tomography (PET) is a nuclear medicine technique that measures regional brain activity and can help localize a seizure focus in preparation for epilepsy surgery. Single-photon emission computed tomography (SPECT) is a nuclear medicine technique that identifies areas of brain metabolic hypo- or hyper metabolism, however routine MR imaging of convulsions epilepsy protocol used to be axial T1-weighted inversion recovery,T2-weighted, and fluid-attenuated inversion recovery (FLAIR) images; coronal magnetization-prepared rapid gradient-echo, T2-weighted, and FLAIR images, and sagittal T1 Weighted images, all MR images are obtained at a 3-mm section thickness except magnetization-prepared rapid gradient-echo images, which are obtained at a 1.8-mm section thickness. **(www.wikepedia.com).**

2.5 previous studies:

Brambilla et al (2003) attempted to investigate anatomical abnormalities of temporal lobe structures in bipolar patients. Using GE of 1.5T, images are obtained of twenty-four DSM-IV bipolar patients (mean age 35 years) and 36 healthy controls (mean age 37 years). Study based on volumetric measurements of temporal lobe, hippocampus, amygdala, and superior temporal gyri STG in correlation to age, gender. Findings represented that the age and gender distribution were not significantly different between bipolar patients and healthy controls whereas bipolar patients had significantly larger left amygdale volumes. The volumes of the other temporal lobe structures did not differ significantly between the two groups. Among healthy controls, the right amygdale was 9%larger than the left, on the contrary in bipolar subjects, the volume of the right amygdala was only 2% bigger than the left. In fact bipolar males, bipolar females, male controls, and female controls did not differ significantly for any anatomical measures.(Brambilla et al 2003)

Cavus et al (2009) mentioned that temporal lobe epilepsy is associated with smaller hippocampal volume and with elevated extracellular glutamate levels. they investigated the relationship between the hippocampal volume and glutamate in refractory TLE patients. They used quantitative MRI images to measure the hippocampal volume and

zero-flow microdialysis to measure the interictal glutamate and GABA levels in the epileptogenic hippocampus of 17 patients' medication-resistant epilepsy undergoing intracranial EEG evaluation. The relationship between hippocampal volume, neurochemical levels and relevant clinical factors were examined. Glutamatein was significantly higher with the threshold for hippocampal atrophy estimated as 5 micro M. GABA and glutamate levels in the no atrophic hippocampus were comparable. Decreased hippocampal volume was related to higher seizure frequency. But not to disease duration or febrile seizure history, amajor study titled Methods for Normalization of Hippocampus Volumes Measured with MR by Bergin PS. And et al purposed to investigate the use of six cerebral measures as correlates for hippocampal volumes and, therefore, to enable normalized absolute hippocampal volumes to be calculated via two correction processes. For methods of the study MR data collected from 20 control subjects, then Hippocampus volumes and six cerebral measures were estimated. Three of these measures (the cranial volume, the cerebral volume, and the midsagittal cranial area) were then applied to a group of 32 control subjects, and regression analysis was performed to investigate the linear relationship between hippocampus volume and each measure. Division of hippocampus volume by cerebral measure and correction via a covariance calculation enabled corrected absolute hippocampal volumes to be determined for 32 control subjects and 23 patients with temporal lobe epilepsy. Results: correction processes reduced the variance in absolute hippocampus volumes in control subjects and enabled abnormally small absolute volumes to be defined. Of 11 patients with unilateral volume ratio abnormalities, 8 had unilateral abnormally small absolute hippocampus volumes. Of 12 patients with normal volume ratios, 4 had bilateral abnormally small absolute hippocampal volumes. It conclusion that correction processes can define absolute hippocampal volumes for correlation studies and may enable identification of unsuspected bilateral hippocampus volume loss. (Cavus et al 2009)

Geuze et al (2009) mentioned that Magnetic resonance imaging MRI has a big role in brain investigation. Measuring hippocampal volume with MRI has provided important information about several neuropsychiatric disorders. They reviewed the literature and

selected all English-Language, human subject, data driven papers on hippocampal volumetry, yielding a database of 423 records, Smaller hippocampal volumes have been reported in epilepsy, Alzheimer's disease, dementia, mild cognitive impairment, the aged, traumatic brain injury, cardiac arrest, Parkinson's disease, Huntington's disease, Cushing's disease, Herpes simplex encephalitis, Turner's syndrome, Down's syndrome, survivors of low birth weight, schizophrenia, major depression, posttraumatic stress disorder, chronic alcoholism, borderline personality disorder, obsessive-compulsive disorder and antisocial personality disorder. Significantly larger hippocampal volumes have been correlated with autism and children with fragile X syndrome. Preservation of hyppocampal volume has been reported in congenital hyperplasia, children with fetal alcohol syndrome, anorexia nervosa, attention deficit and hyperactivity disorder, bipolar disorder and panic disorder. (Geuze et al 2009)

Jack. (1990) has performed his study of the temporal lobe seizures; lateralization with MR volume measurements of the hippocampal formation in (41) right-handed patients with presumed sclerosis who underwent surgery for medically intractable, complex partial seizures of temporal lobe using five different MR imaging- based tests (a) hippocampal formation (HF) volume measurements,(b) visual grading of MR images for unilateral HF atrophy, (c) anterior temporal lobe (ATL) volume measurements, (d) visual grading of MR images for unilateral, atrophy, and (e) evidence of unilateral medial temporal lobe signal intensity abnormalities on long repetition time MR images. Some conclusions that MR imaging-based volume measurements are a sensitive (76%) and specific (100%) method for identifying the unilateral HF atrophy associated with TLE of non-mass lesion origin. This technique can provide reliable seizure lateralization data in a large group of patients (with presumed mesial sclerosis) for whom MR imaging, has not commonly provided such data. The study concluded that when quantitative MR evidence of HF atrophy correlates with noninvasively obtained electro-clinical evidence of seizure lateralization, surgical selection can be done without resorting to chronic invasive electro-physiologic monitoring. On the other hand, if there is disagreement between the quantitative MR evidence of HF atrophy and the electroclinical evidence of seizure lateralization, chronic

invasive electro-physiologic monitoring may well be needed before a decision is made with regard to surgery (Jack 1990.)

Jafari-khouzani, et al,(2011)studied the flair signal and texture analysis for lateralizing mesial temporal lobe epilepsy .they gathered the data of 36patients with EEG assessment over a minimum three day period ,MR image ,sodium am barbital study and neuropsychological assessment . control subjects were25 patients neurologically intact .region of interest (ROIS) encompassing the hippocampi were outlined manually for segmentation using sequential coronal T1weighted MR image ;three set of feature extracted :mean and standard deviation of the FLAIR MR signal intensity ,wavelet transform –derived energy and volumetric . the final value for each feature was expressed as aratio of measured values of the tow hippocampi for normalization purposes and to facilitate the classification and graphical analysis for left and right said epileptogenicity .a ratio of FLAIR signal intensity features was used to avoid the problem of variance in FLAIR signal intensity from case to case and scan to scan .their result showed that the combined application of the FLAIR mean signal intensity measure and its distinguishing the the laterality of MTLE. An accurate estimation was achieved in 98%of cases, leaving only a single case misclassification . The same case with several others was misclassification by volumetric . Their study should have been done using 3D MRI imaging protocol since they are arguing about the accuracy of volumetry and segmentation of the hippocampus. (Jafari-khouzani, et al, 2011)

Friedrich G Woermann et al. (1998) in their study Regional changes in hippocampal T2 relaxation and volume: a quantitative magnetic resonance imaging study of hippocampal sclerosis described the presence and features of hippocompal changes using MRI. Thirty patients with temporal lobe epilepsy, 10 patients with extra temporallocalisation related epilepsy and extratemporal lesions, and control subjects were studied using MRI T2 relaxometry and volumetry.

They concluded that the measurement of regional abnormalities of HT2 along the length of the hippocampus provides further refinement to the MRI assessment of the

hippocampi in patients with temporal lobe epilepsy and is complementary to volumetric and morphological data, and the principal MRI features of hippocampal sclerosis are volume loss and increased T2 weighted signal intensity, a previous study named Temporal lobe abnormalities on brain MRI in healthy volunteers a prospective case-control study by Labate A, et al. had used a sample of 99 patients, 48 (mean age 36.1 +/- 16.1 years; range 10 to 75) with TLE and 51 healthy volunteers (mean age 39.3 +/- 10.8 years) underwent the same MRI protocol specific for TLE. Review of Images by 2 neuroradiologists Showed that 47 of 99 (47.5%) patients showed either unilateral or bilateral major T2/FLAIR , hyper-intensities of the hippocampus. 19 of 48 TLE patients (39.5%) showed hippocampal atrophy seen at T1,inversion recovery sequences. In the controls, 15 of 51 (29.4%) individuals had unilateral or bilateral hyper-intensities (Friedrich G Woermann et al. 1998).

Chapter Three
Materials and Methods

3.1Materials of data collection:

3.1.1 MRI system:

MRI machines used for collecting brain images were those at Alamal Hospital with Philips 1.5 Tesla using sense head coil with parameters of 4mm slice thickness and 1 mm inter space and Modern medical center with GE Signa Hde 1.5Tesla using 8 channels neurovascular head coil with parameters of 3mm slice thickness and 1.5 mm inter space.

3.1.2 Design of the study:

This study is analytic study of a cases control type where normal MRI brains were taken as a reference.

3.1.3 Population of the study

The population of the study included patients coming with convulsion and diagnosed as normal patients according to history of the patient and request order of MRI brain received in Radiology department, and normal patients as a control group. The patients age ranged from 9 month to 13 years old of both genders males and females and all were Sudanese. The exclusion criteria included patients with brain trauma, brain infection, neurovascular pathology and space occupied lesion (SOL) because they alter the macro and micro pattern sequence of the brain tissue, since the aim was to find textural differences in area visually appear as normal.

3.1.4 Sample size and type:

The sample of this study consisted 41 pediatric were selected conveniently; 36 had convulsion and 5 normal cases as control cases.

3.1.5 Place and duration of the study:

This study was carried out in the period from jule 2014 to desemper 2015 in Khartoum state at Alamal Hospital and Modern Medical Center.

3-2 Methods of data collection:

3.2.1 Technique:

Patients were positioned supine with his head within the head coil and the longitudinal alignment light lies in the midline and the horizontal alignment light passes through the nasion. Straps and foam pads are used for immobilization and give the patient oral sedition A localize series was first obtained to verify patient position, image quality, and locate a midline segittal image, then the following brain image series done with specialized protocol that set for suspected epilepsy patient; first axial T1, T2 and FLAIR then segittal T1and coronal T2 and FLAIR with thin slices for the coronals, the field of view (FOV) change related to patient brain size which is often around 24×24 cm2.

3.3 Methods of analysis:

After that MRI image are stored In computer disk were viewed by the Radiant, Ant ,dicom in computer to selected the section of image and uploaded into the computer based software Interactive Data Language (IDL) where the DICOM image converted to TIFF format to suit IDL manipulation. Then the image were read by IDL in TIFF format and the user clicks on areas represents the white matter, grey matter, CSF, and bone. In these areas a window of 3×3 pixel were set and the first order statistics were calculated, which include mean, standard deviation, coefficient of variation, total, kurtosis and skewness, These features were assigned as classification centre used by the K-means function to classify the whole image. The algorithm scans the whole image using a window of 3×3 pixel and computes the first order statistics and computes the distance (the Euclidean distance) between the calculated features and the class's centers and assigns the window to the class with the lowest distance. Then the window interlaced one pixel and the same process stated over till the entire image were classified and a classification map were generated, after all images were classified the data concerning the white, grey matter and CSF for normal and abnormal were entered into SPSS with its classes to generate a classification score using stepwise linear discriminate analysis; to select the most discriminate features that can be used in the classification of normal and abnormal brain tissues. Where scatter plot using discriminate function were generated as well as classification accuracy and

linear discriminate function equations to differentiate between normal and abnormal brain tissue for unseen images.

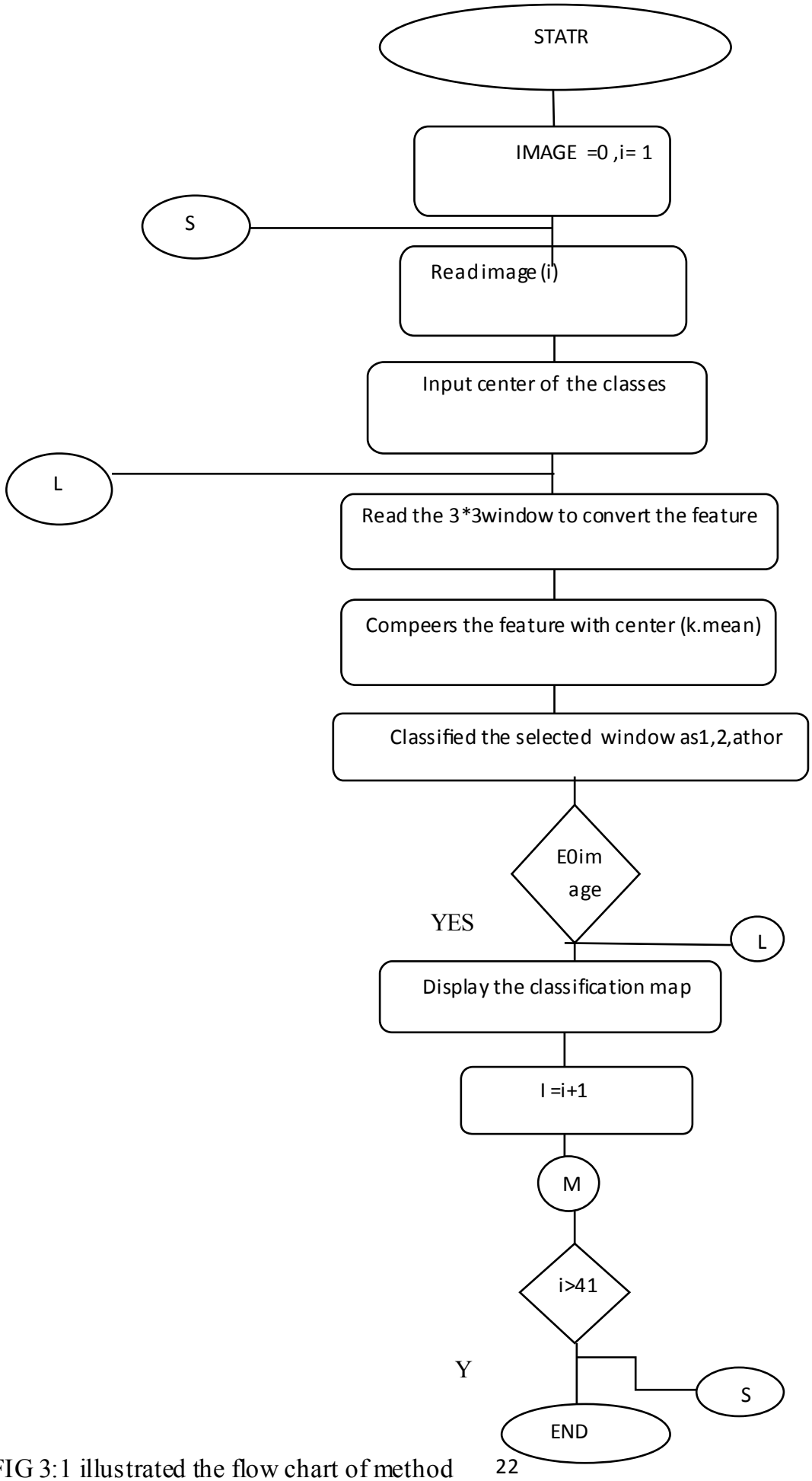

FIG 3:1 illustrated the flow chart of method

Chapter Four
Results

The following tables and figures presented the data obtained from 35patiens, complaining of convulsion and normal, all were children aged between (1-13)years.

The white and gray matter and cerebrospinal flied wewe classified by the computer program (IDL).

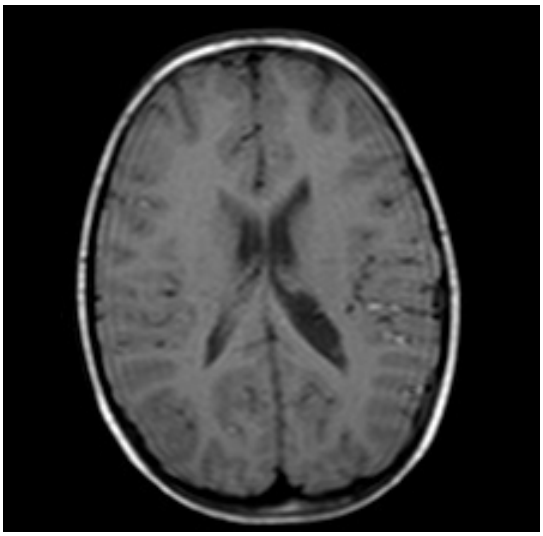

A

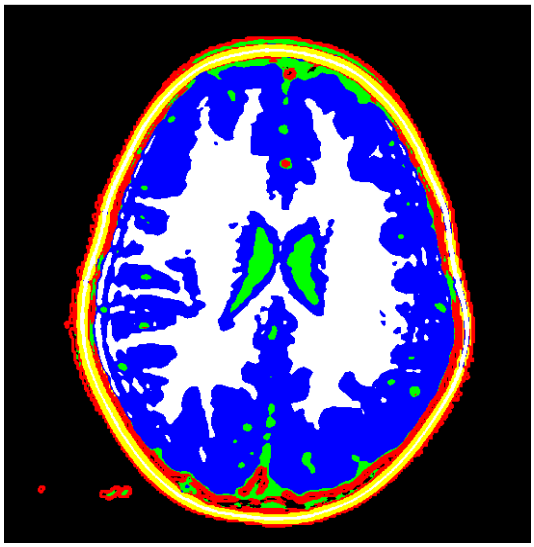

A-

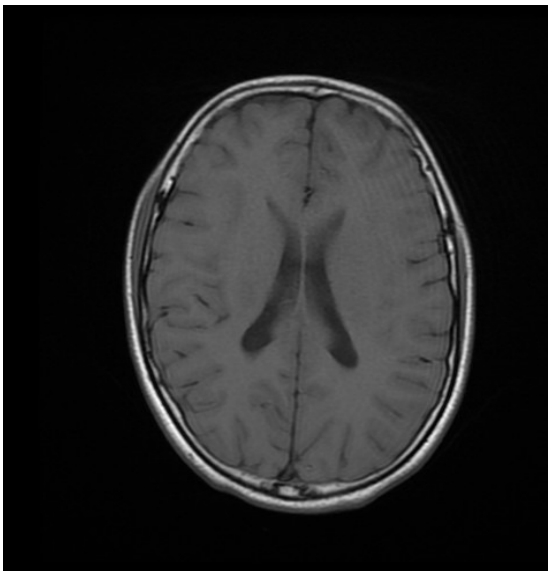

B

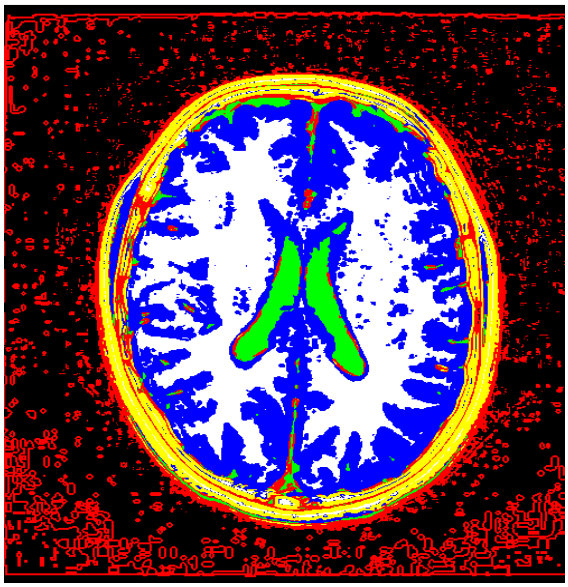

B-

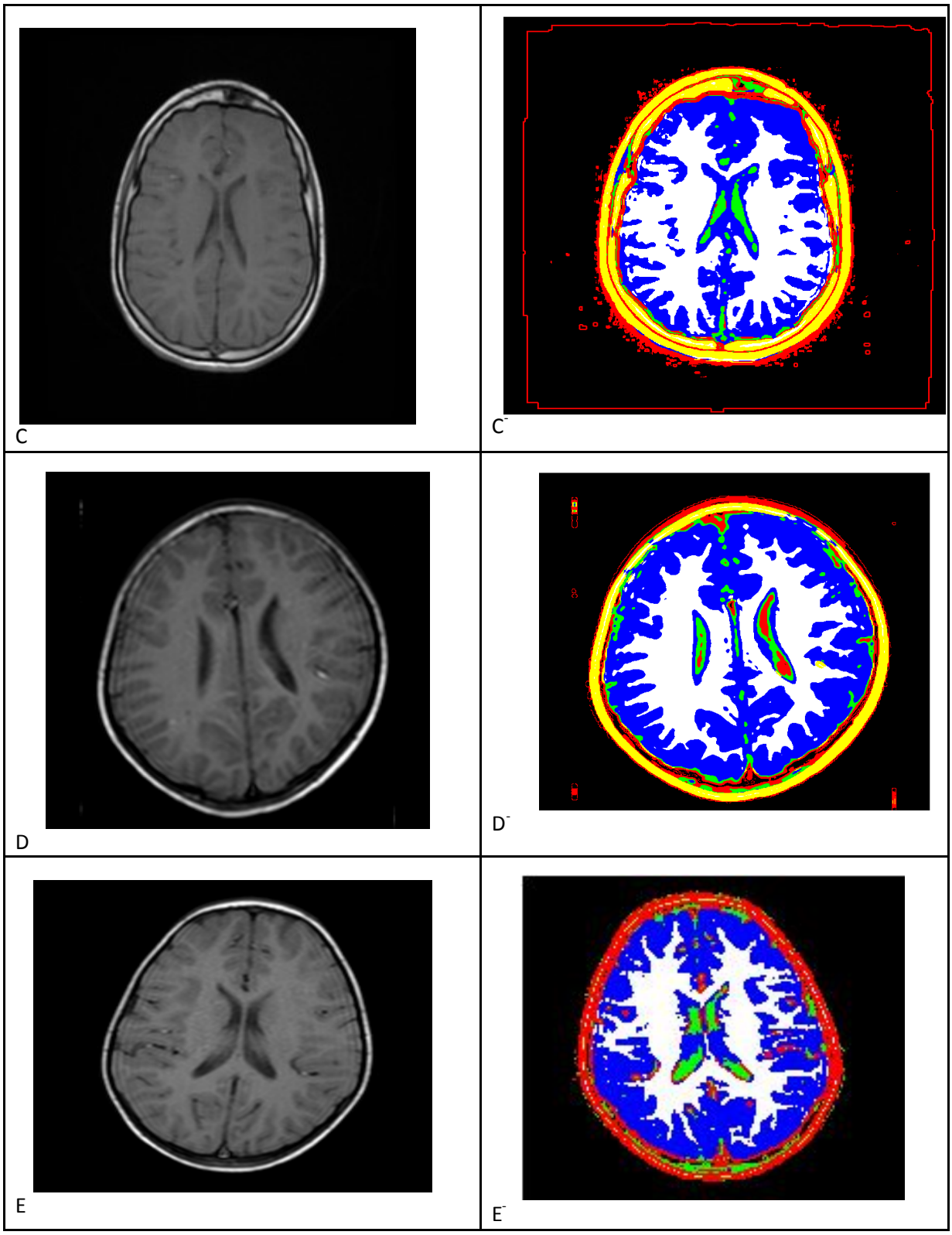

Figure 4:1 sample of orignal MRI and their coresponding classication map for convolution cases from A to C (MRI images) and from A- to C- the classification map. Similarrly for normal case as shown by the rest of the images and classification map.

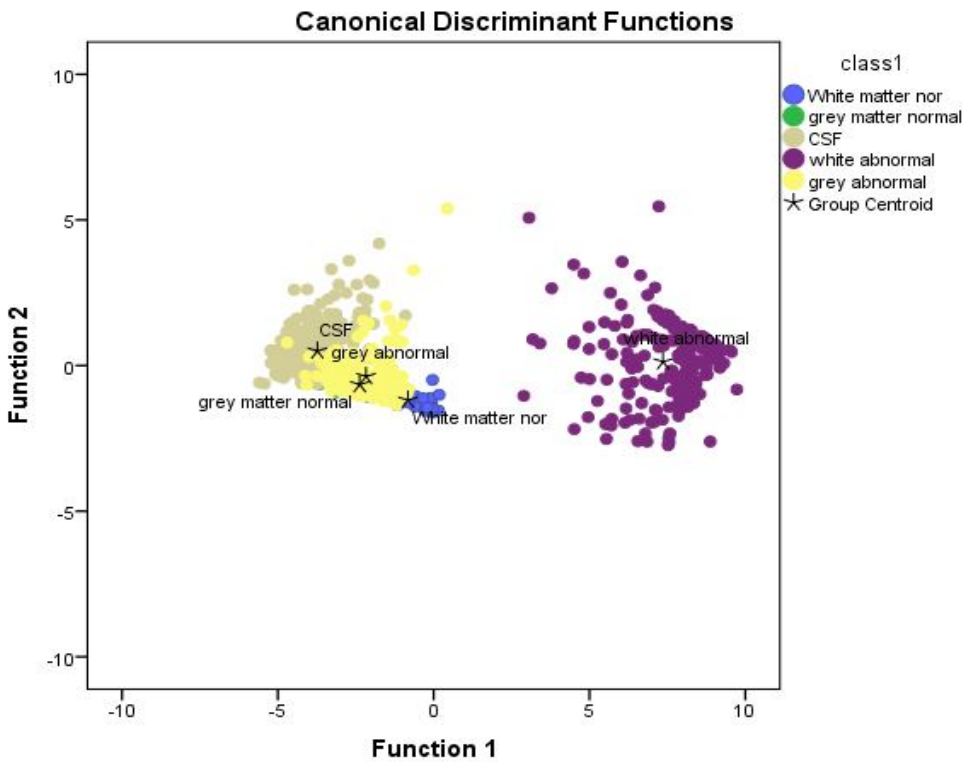

Figure 4:2 illustrate the map of the canonical discriminate function for class of normal and abnormal classes of grey, CSF with the center of the class has star shape.

Table 4-1 showing the coefficient, mean, variance and stander deviation of the class for normal and abnormal of the white and gray matter and CSF

Classification Results		Predicted Group Membership					Total
		White matter normal	grey matter normal	CSF	white abnormal	grey abnormal	
Percentage (%)	White normal	78.4	21.6	0	0	0	100
	grey normal	22.5	47.5	12.5	0	17.5	100
	CSF	0.9	7.4	87.3	0	4.4	100
	white abnormal	0.5	0	0	99.5	0	100
	grey abnormal	17.7	39.8	9.1	0	33.3	100
73.1% of original grouped cases correctly classified.							

.

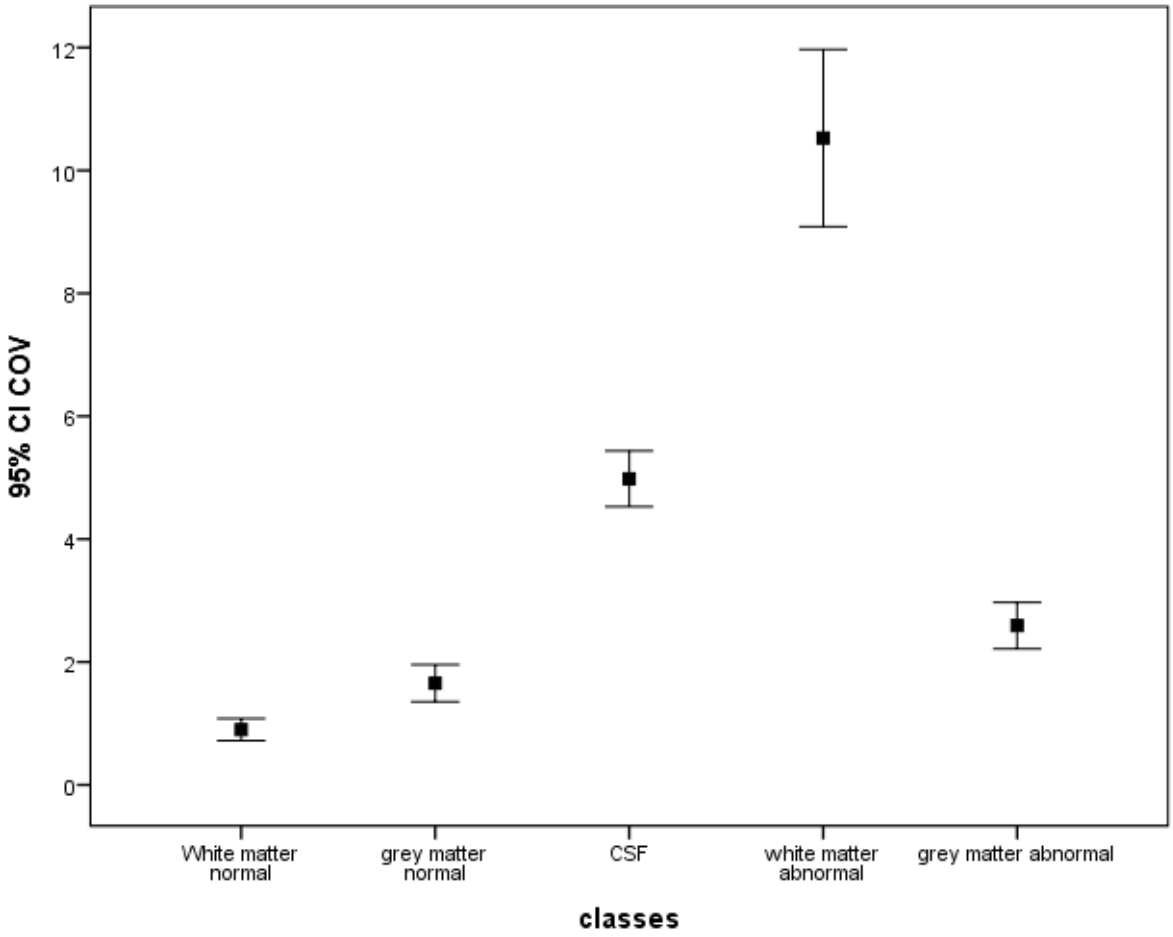

Figure 4;3 an error bar plot of the COV features for the normal and abnormal of the white matter, gray matter and cerebrospinal fluid which demonstrate that higher value of discrimination scored by abnormal white matter compared with the normal and abnormal of other class

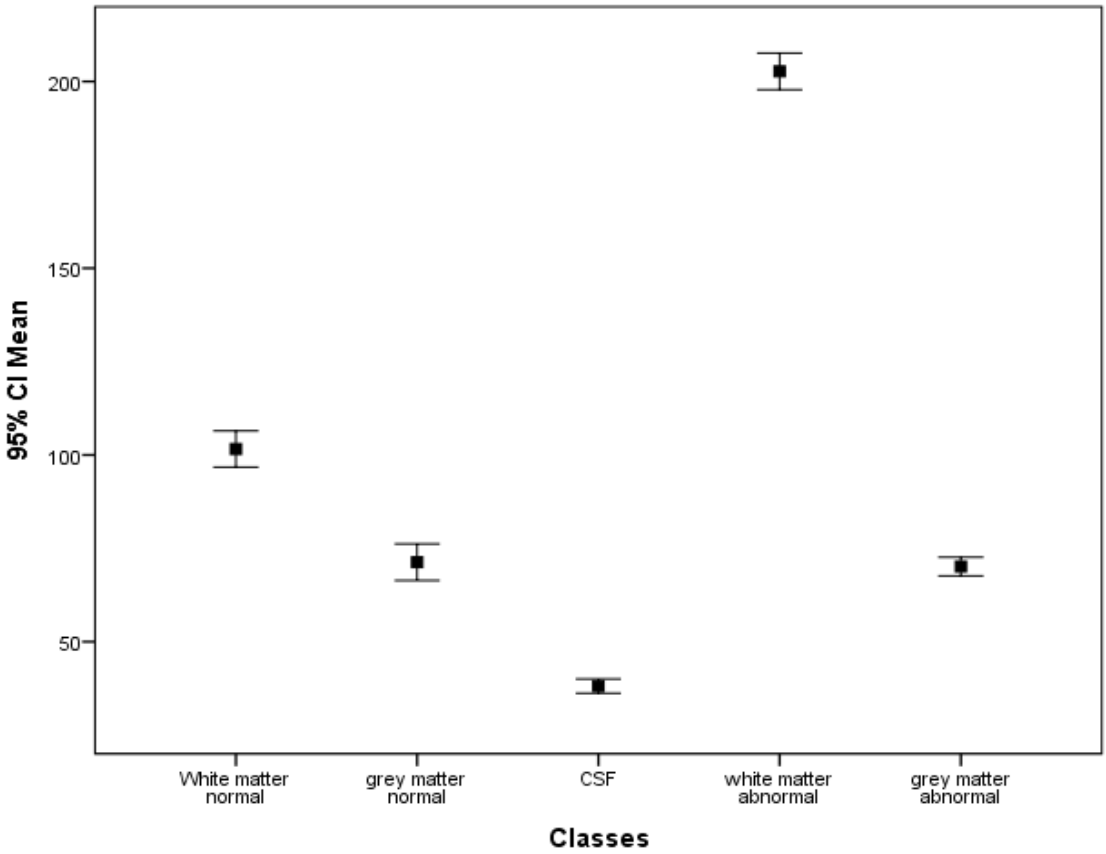

Figure 4-4 an error bar plot of the feature mean for the normal and abnormal of the white matter, gray matter and cerebrospinal fluid which demonstrate that higher value of discrimination scored by abnormal white matter compared with the normal and abnormal of other classes

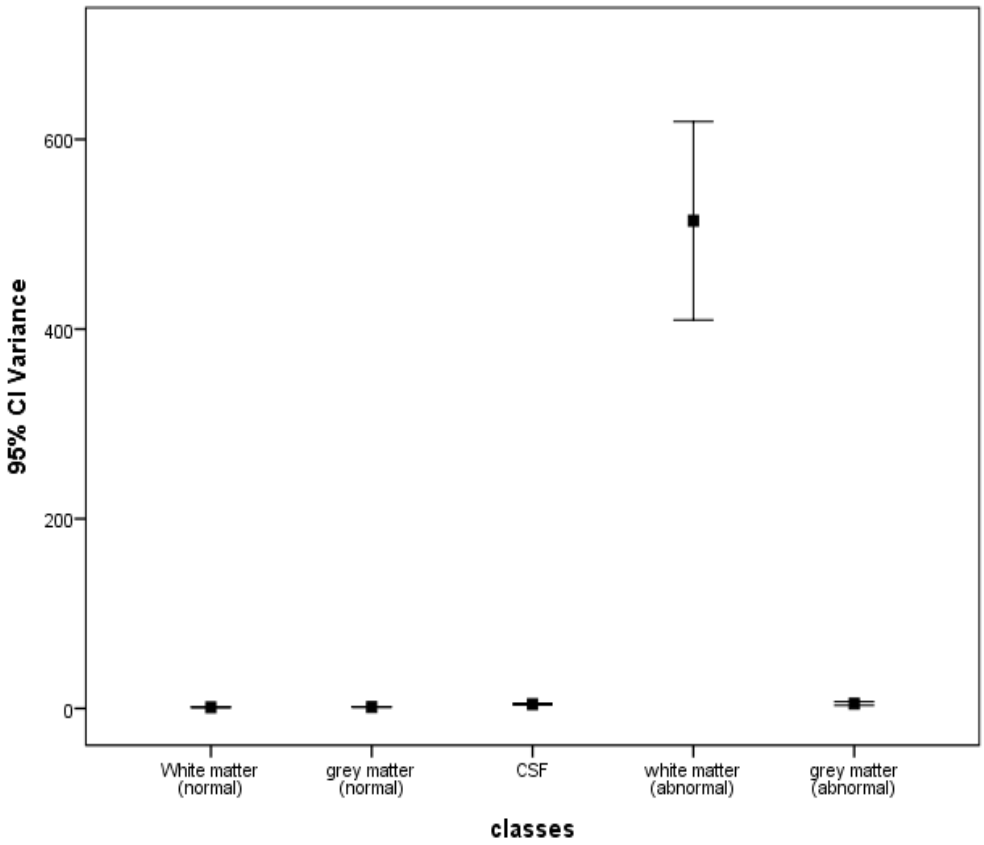

Figure 4-5 an error bar plot of the feature variance for the normal and abnormal of the white matter, gray matter and cerebrospinal fluid which demonstrate that higher value of discrimination scored by abnormal white matter compared with the normal and abnormal of other classes

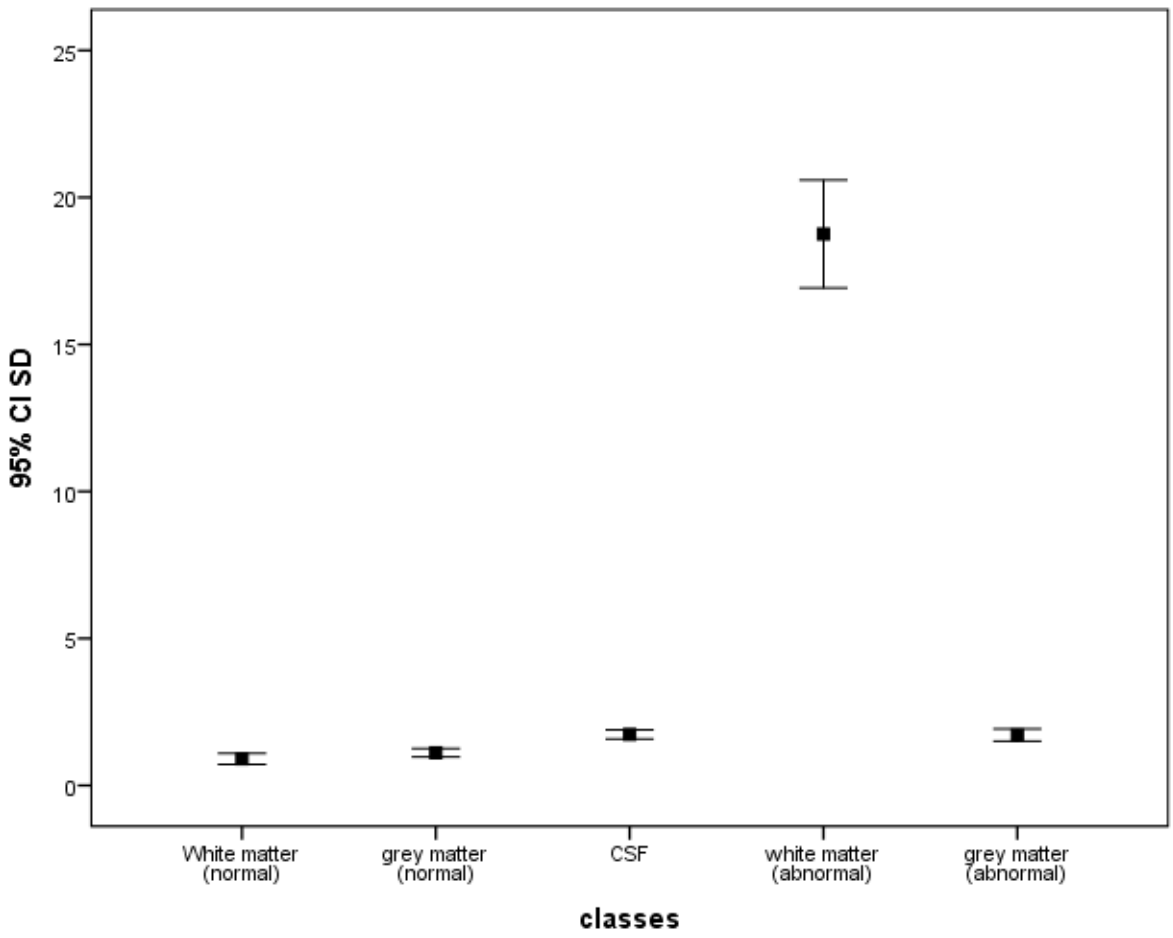

Figure 4-6 an error bar plot of the feature standard deviations for the normal and abnormal of the white matter, gray matter and cerebrospinal fluid which demonstrate that higher value of discrimination scored by abnormal white matter compared with the normal and abnormal of other classes

Chapter Five
Discussion, conclusion and recommendation

This study reports the MR findings in Sudanese pediatric patients with convulsion as suspected temporal lobe epilepsy (TLE). The diagnosis of TLE was based on clinical seizure characteristics and request order of MRI brain received.

5.1 Discussion

In this study there were six features extracted from normal and abnormal (convulsion) pediatric brain images using 3×3 window. From these features, 4 of them showed significant correlation with the predefined classes (white matter, grey matter, cerebrospinal fluid and bone) they includes mean, coefficient of variation, standered deviation and variance.

The classification maps as shown in Figure 4-1 were generated by using K-means, where the centre of the classes chosen arbitrary from areas represented the classes of interest white matter, grey matter, cerebrospinal fluid and bone. The algorithm classified these tissues using the selected centers as initial guess then iterates five cycle in each cycle change the classes centers using the mean value of each features allocated to the class. The changes in the class center were small fraction and start to get zero change from the third iteration. This means each class centers represent the class of interest (Figure 4-1).

The normal and abnormal white and grey matter in this essence appears to have the same color because the centers of the classes were dynamic i.e. each time the user set the class's centers by clicking over appropriate areas; then the center iteratively updated in the successive cycles; which means the centers attributed to the classified image

To classify the grey and white matter including cerebrospinal fluid as normal and abnormal (convulsion) the features of the classified regions of the whole images (as raw data) were classified furthers using linear discriminate analysis. The result of the

classification showed that the white matter of the patient with convulsion were very different from the rest of the tissues (Figure 4-2) with a classification accuracy of 99.5%. While the white matter of normal cases showed a classification accuracy of 78.4% it interchanges with the normal grey matter only Table (4-1).

The grey matter underlying features showed a variable similarity to most of the available classes except the white matter of the convulsion cases; this is why the classification accuracy of the grey matter of the abnormal cases revealed 33.3% of the tissues had markedly different from the normal while the rest were similar to the normal grey matter and also this is why the grey matter showed a lower classification score 47.7%. While the CSF showed a classification accuracy of 87.3% because the underlying texture were very different. The overall classification score were 73.1% mostly affected by the consideration of the grey matter as normal and abnormal while the difference between the two were minimal within the applied feature and the size of the extracting window (Table 4-1).

From the discriminate power point of view in respect to the applied features the coefficient of variation (COV) can differentiate between all the classes successfully, except between white matter and grey matter of normal cases where the separation were borderline (Figure 4-3). Similarly the mean do the same thing except between the grey matter normal and abnormal there is a barely variation (Figure 4-4), where the variance and standard deviation they just emphasize the uniqueness of the convulsion white matter from the rest of the tissue type, also due to scale problem i.e. high value of the abnormal white matter and the low values for the features of the other tissue types, it is not easy to visualize the difference clearly (Figure 4-5 and 4-6 respectively).

In summary patient with convulsion, their brain images in MRI appear normal, but texturally their white matter showed different underlying texture from the normal white matter ,this suggest that the white matter might reveal the causes of the problem. For simplicity the tissues can be diagnosed as normal or abnormal by using the following

simple equation after extracting the associated features using a window of 3×3 pixel from the region of interest; the biggest classification score assume the tissue type

WMN = (1.376× COV) + (0.383×mean) + (-0.003×variance) + (-0.274× SD) -21.551

GMN = (1.115×COV) + (0.280 ×mean) + (-0.004×variance) + (-0.181× SD) -12.406

CSF = (1.276× COV) + (0.197×mean) + (-0.007×variance) + (-0.246× SD) -8.327

WMA = (2.455× COV) + (0.810×mean) + (-0.027×variance) + 1.285× SD) -101.708

GMA = (1.238× COV) + (0.291×mean) + (-0.006×variance) + (-0.140× SD) -13.482

-

5-2 Conclusion:

This study aim to segmente and classify the brain MRI of normal and convulsion (abnormal) pediatric using image processing technique, therefore multible feature of first order statistic were included: coefficent of variation, mean, stander devition, varince, total, kertosis, skewness …etc.

The study found that the effect of convulsion were demonstrated in the white matter which reveal a very differend underlying pattern compared to the other tissues of the brain wethear they are from normal or abnormal cases. The classification accuracy of the abnormal white matter was 99.5% with overall acurrecy of 73.1% using linear discriminant analysis.

This study dictate that texture analysis is superior to visual perception system as well as the volumitric issues which is affected by the body characteristics differences. Texture reveals the change and the difference of the image pattern objectively in respect to the ground truth.

5.3 Recommendation

Larger sample must be used to emphasize that white matter in the convulsion cases represent area of interest.

Other textural features can be used like second order statistics, wavelet co-efficient or Gabor filters to find a better result concerning the grey matter.

CAD program should be adopted by the radiology department to deal with the challenging cases and to have an objective second opinion.

Initiation of medical image analysis units in the radiology department equipped with advance computer and well qualified personnel will solve most of the associated problems.

3.4 References:

Bergin PS, Free SL and et al, (1995): Methods for normalization of hippocampal volumes measured with MR, American Journal of Neuroradiology, volume 16, P.637–643.

Brambilla P, Harenski K, Nicoletti M And et al (2003): MRI investigation of temporal lobe structures in bipolar patients, journal of National Center for Biotechnology Information, volume 37, P. 287-95.

Cavus Idil, Jullie W. and et al, (2008): Decreased hippocampal volume on MRI is associated with increased extracellular glutamate in epileptic patients, Wiley online library, volume 49, P. 1358–1366.

Fougere C. la, A. Rominger et al, (2009): PET and SPECT in epilepsy: A critical review, Germany, Elsevier journal, volume 15, P. 50–55.

Friedrich G Woermann et al., (1998): Regional changes in hippocampal T2 relaxation and volume: a quantitative magnetic resonance imaging study of hippocampal sclerosis, journal of National Center for Biotechnology Information, volume 65, P.656–664.

Geuze E., Vermetten E. and et al, (2005): MR-based in vivo hippocampal volumetric;finding in neuropsychiatric disorders, journal of National Center for Biotechnology Information, volume 10, P. 160-184

IDL Version 6.1,Microsoft Windows (Win 32x86 m32).(c) 2004, research system Inc .Instration number:4751..

Jack CR Jr, Sharbrough FW, Twomey CK and et al, (1990): Temporal lobe seizures:lateralization with MR volume measurements of the hippocampal formation, journal of National Center for Biotechnology Information, volume 17, P. 423-429.

John M. Pellock, Blaise F. D. Bourgeois and et al, (2008): Pediatric Epilepsy Diagnosis and Therapy, 3d edition, P. 75 – 82 and P. 83 – 93, NewYork.

Kara Rogers, (2011): Brain and the nervous system P. 19-24, P.224, NewYork, USA.

Karis J.P., (2008): ACR Appropriateness Criteria of Epilepsy, American college of radiology journal, USA.

Ketonen L. M. et al, (2005): Pediatric Brain and Spine, an Atlas of MRI and Spectroscopy, P. 270-271, Germany..

Labate A, et al., (2010): Temporal lobe abnormalities on brain MRI in healthy volunteers a prospective case-control study, neurology journal, volume 16, P.553-557.

Larry D. Olson, (1990): Pediatric Epilepsy paper, P. 4, USA.

Lorrie. L. Kelley, Connie M. Peterson, (1997): Sectional anatomy for imaging professionals, P. 51, USA.

Marla J. Friedman and et al, (2006): Seizures in Children, P. 257, USA.

Nicki R. Colledge, Brain R. Walker, (2010): Davidson's principles and practice of medicine, 21th edition, P. 1172 -1175, UK.

Per Anderson, Richard Morris and et al, (2007): The Hippocampus Book, P. 9, P. 549 Oxford university, published in NewYork.

Richard A. Bronen, (1992): Epilepsy: The Role of MR Imaging, P. 1169, USA.

Ruben I. Kuzniecky, Graeme D. Jackson, (2004): MR in Epilepsy neuroimaging techniques, 2nd edition, P. 9, P. 107-109, USA. Simon D. Shorvon, Emilio Perucca et al, (2004): The Treatment of Epilepsy, P.6-7,Australia.

Simon S. Keller, Neil Roberts and et al., (2009): Measurement of brain volume using MRI: software, techniques, choices and prerequisites, Journal of Anthropological

Sciences, Journal of Anthropological Sciences, volume 87, P. 127-151.

World Health Organization (WHO), (2005): Atlas Epilepsy Care in the World.

www.epilepsyfoundation.org.

WWW. Medicines health .com

www.medphys.ucl.ac.uk

www.wikepedia

APPEDIEX

Example of data sheet

COV	Mean	Variance	SD	Uniform	total	class1	class2
1.04077	75.1111	0.611111	0.781736	0.026316	676	1	1
0.669643	74.6667	0.25	0.5	0.013333	672	1	1
1.05613	82	0.75	0.866025	0.024096	738	1	1
0.619835	80.6667	0.25	0.5	0.012346	726	1	1
0.782775	90.3333	0.5	0.707107	0.021978	813	1	1
0.990933	78.8889	0.611111	0.781736	0.025	710	1	1
0.627615	79.6667	0.25	0.5	0.0125	717	1	1
1.09623	79	0.75	0.866025	0.025	711	1	1
0.646242	81.5556	0.277778	0.527046	0.012195	734	1	1
0.496177	121.111	0.361111	0.600925	0.016393	1090	1	1
1.3422	112.444	2.27778	1.50923	0.035088	1012	1	1
0.290135	114.889	0.111111	0.333333	0.008696	1034	1	1
0.917489	114.889	1.11111	1.05409	0.025641	1034	1	1
0.280374	118.889	0.111111	0.333333	0.008403	1070	1	1
0.468254	112.556	0.277778	0.527046	0.00885	1013	1	1
0.679114	115.111	0.611111	0.781736	0.017241	1036	1	1
0.673265	116.111	0.611111	0.781736	0.017094	1045	1	1
0.372991	118.222	0.194444	0.440959	0.008403	1064	1	1
1.31036	104.111	1.86111	1.36423	0.037736	937	1	1
0.635126	111.333	0.5	0.707107	0.017857	1002	1	1
0.761899	113.667	0.75	0.866025	0.017391	1023	1	1
0.490022	107.556	0.277778	0.527046	0.009259	968	1	1
0.56872	117.222	0.444444	0.666667	0.016949	1055	1	1
1.34088	112.556	2.27778	1.50923	0.034783	1013	1	1
2.85129	106.667	9.25	3.04138	0.063636	960	1	1
1.22825	108.556	1.77778	1.33333	0.036364	977	1	1
0.583658	114.222	0.444444	0.666667	0.017391	1028	1	1
1.68201	115.556	3.77778	1.94365	0.050848	1040	1	1
1.2413	98.6667	1.5	1.22474	0.03	888	1	1
0.724	97.6667	0.5	0.707107	0.020202	879	1	1
0.826902	100.778	0.694444	0.833333	0.019608	907	1	1
0.752399	96.5556	0.527778	0.726483	0.020619	869	1	1
0.339751	98.1111	0.111111	0.333333	0.010101	883	1	1
2.37461	89.3333	4.5	2.12132	0.065217	804	1	1
0.686511	103	0.5	0.707107	0.019231	927	1	1
0.506757	98.6667	0.25	0.5	0.010101	888	1	1
1.34075	98.6667	1.75	1.32288	0.03	888	1	1
0.5386	61.8889	0.111111	0.333333	0.016129	557	2	1
1.67598	59.6667	1	1	0.04918	537	2	1

1.56001	50.1111	0.611111	0.781736	0.039216	451	2	1
1.04251	50.5556	0.277778	0.527046	0.019608	455	2	1
1.60375	54	0.75	0.866025	0.036364	486	2	1
1.76008	59.8889	1.11111	1.05409	0.04918	539	2	1
1.99303	52.8889	1.11111	1.05409	0.055556	476	2	1
6.01719	38.7778	5.44444	2.33333	0.166667	349	2	1
1.45296	48.6667	0.5	0.707107	0.04	438	2	1
2.82764	44.8889	1.61111	1.2693	0.085106	404	2	1
0.785859	92.4444	0.527778	0.726483	0.021505	832	2	1
0.969431	89.3333	0.75	0.866025	0.032967	804	2	1
0.696056	95.7778	0.444444	0.666667	0.020619	862	2	1
1.88445	88	2.75	1.65831	0.055556	792	2	1
2.74309	77.3333	4.5	2.12132	0.075	696	2	1
0.828641	85.3333	0.5	0.707107	0.022989	768	2	1
1.49134	85.1111	1.61111	1.2693	0.045977	766	2	1
1.40859	90.1111	1.61111	1.2693	0.043478	811	2	1
1.07715	90.2222	0.944444	0.971825	0.032609	812	2	1
1.13208	93.1111	1.11111	1.05409	0.031915	838	2	1
2.05788	84.5556	3.02778	1.74005	0.056818	761	2	1
1.55031	79	1.5	1.22474	0.049383	711	2	1
1.28618	67.3333	0.75	0.866025	0.043478	606	2	1
3.12471	64.8889	4.11111	2.02759	0.088235	584	2	1
1.57067	67.1111	1.11111	1.05409	0.043478	604	2	1
1.27119	78.6667	1	1	0.0375	708	2	1
1.04248	93.2222	0.944444	0.971825	0.031579	839	2	1
1.44056	88.1111	1.61111	1.2693	0.044444	793	2	1
2.56717	65.8889	2.86111	1.69148	0.072464	593	2	1
2.17246	76.3333	2.75	1.65831	0.063291	687	2	1
1.26996	69.4444	0.777778	0.881917	0.042254	625	2	1
0.835908	71.8889	0.361111	0.600925	0.027397	647	2	1
1.91468	64.5556	1.52778	1.23603	0.045455	581	2	1
1.57692	77.6667	1.5	1.22474	0.037975	699	2	1
1.08742	71.8889	0.611111	0.781736	0.027397	647	2	1
0.688449	76.5556	0.277778	0.527046	0.012987	689	2	1
2.44506	64.6667	2.5	1.58114	0.074627	582	2	1
1.73117	60.8889	1.11111	1.05409	0.048387	548	2	1
2.00844	55.6667	1.25	1.11803	0.052632	501	2	1
1.07681	65.6667	0.5	0.707107	0.029851	591	2	1
4.6875	14.2222	0.444444	0.666667	0.133333	128	3	1
3.65854	18.2222	0.444444	0.666667	0.105263	164	3	1
2.84037	18.5556	0.277778	0.527046	0.052632	167	3	1
16.7352	18.4444	9.52778	3.08671	0.363636	166	3	1
4.51128	14.7778	0.444444	0.666667	0.125	133	3	1
14.2857	7	1	1	0.333333	63	3	1
7.40867	16.2222	1.44444	1.20185	0.166667	146	3	1

13.9831	13.1111	3.36111	1.83333	0.3125	118	3	1
8.49057	17.6667	2.25	1.5	0.2	159	3	1
5.5156	19.1111	1.11111	1.05409	0.142857	172	3	1
1.2605	39.6667	0.25	0.5	0.025	357	3	1
1.88425	38.5556	0.527778	0.726483	0.05	347	3	1
1.84049	36.2222	0.444444	0.666667	0.054054	326	3	1
2.35753	41.2222	0.944444	0.971825	0.069767	371	3	1
5.83748	37.4444	4.77778	2.18581	0.170732	337	3	1
9.71838	34.5556	11.2778	3.35824	0.205128	311	3	1
3.59546	39.3333	2	1.41421	0.097561	354	3	1
1.22951	40.6667	0.25	0.5	0.02439	366	3	1
2.86675	39	1.25	1.11803	0.073171	351	3	1
3.66666	32.7778	1.44444	1.20185	0.114286	295	3	1
2.05788	84.5556	3.02778	1.74005	0.056818	761	3	1
1.55031	79	1.5	1.22474	0.049383	711	3	1
1.28618	67.3333	0.75	0.866025	0.043478	606	3	1
3.12471	64.8889	4.11111	2.02759	0.088235	584	3	1
1.57067	67.1111	1.11111	1.05409	0.043478	604	3	1
1.27119	78.6667	1	1	0.0375	708	3	1
1.04248	93.2222	0.944444	0.971825	0.031579	839	3	1
1.44056	88.1111	1.61111	1.2693	0.044444	793	3	1
2.56717	65.8889	2.86111	1.69148	0.072464	593	3	1
2.17246	76.3333	2.75	1.65831	0.063291	687	3	1
10.0998	48.1111	23.6111	4.85913	0.267857	433	3	1
4.48999	41.6667	3.5	1.87083	0.133333	375	3	1
7.02183	37	6.75	2.59808	0.15	333	3	1
7.77027	39.6667	9.5	3.08221	0.181818	357	3	1
3.26087	30.6667	1	1	0.09375	276	3	1
5.92804	32.6667	3.75	1.93649	0.142857	294	3	1
3.55096	30.7778	1.19444	1.09291	0.09375	277	3	1
7.59002	25.8889	3.86111	1.96497	0.172414	233	3	1
2.6254	22.8889	0.361111	0.600925	0.083333	206	3	1
5.42169	27.6667	2.25	1.5	0.133333	249	3	1
2.90181	239.444	48.2778	6.94822	0.081633	2155	4	1
15.1899	171.222	676.444	26.0085	0.357488	1541	4	1
4.53757	241.444	120.028	10.9557	0.126984	2173	4	1
2.81812	246.556	48.2778	6.94822	0.074803	2219	4	1
1.20311	250.889	9.11111	3.01846	0.03937	2258	4	1
2.96548	235.111	48.6111	6.97217	0.090535	2116	4	1
3.83319	216.222	68.6944	8.28821	0.110132	1946	4	1
7.8564	174.111	187.111	13.6789	0.230769	1567	4	1
12.5102	143.444	322.028	17.9451	0.329341	1291	4	1
10.6346	126.333	180.5	13.435	0.270833	1137	4	1
13.6448	199.222	738.944	27.1835	0.337607	1793	4	1
8.91956	236.222	443.944	21.07	0.207843	2126	4	1

12.4923	208.556	678.778	26.0534	0.279167	1877	4	1
1.14452	247.556	8.02778	2.83333	0.027888	2228	4	1
10.5254	209.222	484.944	22.0215	0.233766	1883	4	1
8.78269	227.111	397.861	19.9465	0.212	2044	4	1
10.9222	217.889	566.361	23.7983	0.229508	1961	4	1
5.76301	215.333	154	12.4097	0.133047	1938	4	1
8.04046	186.222	224.194	14.9731	0.206897	1676	4	1
4.30551	210	81.75	9.04157	0.12844	1890	4	1
2.11868	246.889	27.3611	5.23078	0.063492	2222	4	1
5.52429	241	177.25	13.3135	0.13834	2169	4	1
7.99248	217.111	301.111	17.3526	0.206612	1954	4	1
4.77675	242.889	134.611	11.6022	0.110672	2186	4	1
9.78092	213.667	436.75	20.8986	0.220833	1923	4	1
36.0329	130	2194.25	46.8428	0.612903	1170	4	1
24.9457	144.889	1306.36	36.1436	0.505263	1304	4	1
24.3641	168.444	1684.28	41.04	0.55157	1516	4	1
7.78795	236.222	338.444	18.3969	0.215686	2126	4	1
21.3096	170.333	1317.5	36.2974	0.513761	1533	4	1
4.99523	184.778	85.1944	9.23008	0.154639	1663	4	1
3.46122	176.333	37.25	6.10328	0.104396	1587	4	1
6.28253	177.444	124.278	11.148	0.154255	1597	4	1
17.2714	140.667	590.25	24.2951	0.35503	1266	4	1
9.93102	186.111	341.611	18.4827	0.252381	1675	4	1
19.1687	161.556	959.028	30.9682	0.435644	1454	4	1
13.7393	180.111	612.361	24.7459	0.360577	1621	4	1
11.3618	180	418.25	20.4512	0.311881	1620	4	1
21.1619	144.889	940.111	30.6612	0.510526	1304	4	1
20.6873	128.556	707.278	26.5947	0.48503	1157	4	1
5.15925	235.889	148.111	12.1701	0.116466	2123	4	1
14.7367	190.667	789.5	28.098	0.327434	1716	4	1
11.1687	228.667	652.25	25.5392	0.25098	2058	4	1
14.774	202.111	891.611	29.8599	0.340426	1819	4	1
3.53322	210.111	55.1111	7.42369	0.091324	1891	4	1
4.28962	184.667	62.75	7.92149	0.107143	1662	4	1
10.5595	164.444	301.528	17.3646	0.264865	1480	4	1
7.39633	161.222	142.194	11.9245	0.205714	1451	4	1
19.08	121.889	540.861	23.2564	0.441558	1097	4	1
9.47421	185.222	307.944	17.5483	0.259804	1667	4	1
8.52828	230	384.75	19.615	0.234818	2070	4	1
3.43287	246.222	71.4444	8.45248	0.094488	2216	4	1
7.09704	239.444	288.778	16.9935	0.200787	2155	4	1
7.09704	239.444	288.778	16.9935	0.200787	2155	4	1
8.65692	181.556	247.028	15.7171	0.227723	1634	4	1
15.1554	200	918.75	30.3109	0.395833	1800	4	1
12.5634	193.111	588.611	24.2613	0.315556	1738	4	1

2.49743	215.111	28.8611	5.37225	0.076923	1936	4	1
0.801253	197.333	2.5	1.58114	0.025	1776	4	1
14.1657	125.444	315.778	17.7701	0.310345	1129	4	1
5.19344	227.444	139.528	11.8122	0.130802	2047	4	1
10.5709	205.111	470.111	21.682	0.266094	1846	4	1
7.61039	218	275.25	16.5907	0.160173	1962	4	1
8.3329	227.889	360.611	18.9898	0.208	2051	4	1
11.1341	217.778	587.944	24.2476	0.271255	1960	4	1
12.4678	215.444	721.528	26.8613	0.330612	1939	4	1
4.6232	238.667	121.75	11.034	0.132	2148	4	1
8.07624	218.778	312.194	17.669	0.21097	1969	4	1
8.36236	213.667	319.25	17.8676	0.225532	1923	4	1
7.12679	190.333	184	13.5647	0.192308	1713	4	1
2.94046	235.889	48.1111	6.93622	0.069388	2123	4	1
8.76557	212.444	346.778	18.622	0.188596	1912	4	1
7.79579	214.111	278.611	16.6916	0.200855	1927	4	1
18.0536	129.778	548.944	23.4296	0.379747	1168	4	1
24.4885	86.5556	449.278	21.1962	0.468468	779	4	1
8.92722	228.333	415.5	20.3838	0.250996	2055	4	1
7.82165	238.111	346.861	18.6242	0.208661	2143	4	1
8.68954	231.222	403.694	20.0921	0.231076	2081	4	1
17.9221	173.667	968.75	31.1247	0.427907	1563	4	1
8.49175	186.889	251.861	15.8701	0.18593	1682	4	1
13.5079	186.556	635.028	25.1998	0.304762	1679	4	1
9.74574	201.333	385	19.6214	0.220183	1812	4	1
11.1257	204.667	518.5	22.7706	0.236607	1842	4	1
19.7682	170.444	1135.28	33.6939	0.414286	1534	4	1
11.0546	218.222	581.944	24.1235	0.308333	1964	4	1
57.9407	114.222	4379.94	66.1811	0.904977	1028	4	1
20.5043	209.889	1852.11	43.0362	0.529644	1889	4	1
56.9459	99.7778	3228.44	56.8194	0.884817	898	4	1
22.5631	166.333	1408.5	37.53	0.439614	1497	4	1
33.3987	135.778	2056.44	45.348	0.663158	1222	4	1
9.67153	193.444	350.028	18.709	0.244131	1741	4	1
27.8567	151.667	1785	42.2493	0.563981	1365	4	1
35.4166	148.444	2764.03	52.574	0.685446	1336	4	1
21.3143	191.222	1661.19	40.7578	0.512712	1721	4	1
34.0916	159.111	2942.36	54.2435	0.72807	1432	4	1
34.6144	153.333	2817	53.0754	0.717489	1380	4	1
6.4754	225.222	212.694	14.584	0.194915	2027	4	1
5.91783	220	169.5	13.0192	0.176724	1980	4	1
6.55735	197.778	168.194	12.969	0.167442	1780	4	1
9.58699	160.222	235.944	15.3605	0.236264	1442	4	1
9.80668	187.333	337.5	18.3712	0.218447	1686	4	1
7.70607	160.222	152.444	12.3468	0.186441	1442	4	1

16.0269	149.111	571.111	23.8979	0.393064	1342	4	1
9.37199	214.333	403.5	20.0873	0.275424	1929	4	1
4.76673	236.444	127.028	11.2707	0.131474	2128	4	1
5.73724	227.222	169.944	13.0363	0.183673	2045	4	1
7.50772	226.444	289.028	17.0008	0.197581	2038	4	1
10.5858	212.556	506.278	22.5006	0.272727	1913	4	1
4.3812	221	93.75	9.68246	0.12987	1989	4	1
6.55735	197.778	168.194	12.969	0.167442	1780	4	1
6.51985	230.889	226.611	15.0536	0.142857	2078	4	1
4.72245	229.889	117.861	10.8564	0.1125	2069	4	1
1.82293	221.889	16.3611	4.04489	0.053097	1997	4	1
14.5717	178.222	674.444	25.9701	0.319048	1604	4	1
6.70921	234.222	246.944	15.7145	0.192	2108	4	1
10.2184	221.444	512.028	22.628	0.27572	1993	4	1
5.92654	237.444	198.028	14.0722	0.179283	2137	4	1
13.7044	219.333	903.5	30.0583	0.358268	1974	4	1
7.03125	227.333	255.5	15.9844	0.209677	2046	4	1
16.2121	190.667	955.5	30.9112	0.411255	1716	4	1
1.19253	235.111	7.86111	2.80377	0.037815	2116	4	1
1.40058	247.333	12	3.4641	0.039683	2226	4	1
4.16747	237.778	98.1945	9.90931	0.093117	2140	4	1
6.80527	224.556	233.528	15.2816	0.165289	2021	4	1
5.62084	230.444	167.778	12.9529	0.149798	2074	4	1
2.74362	197.778	29.4444	5.42627	0.086957	1780	4	1
9.57953	197.889	359.361	18.9568	0.253456	1781	4	1
11.1469	173.667	374.75	19.3585	0.247423	1563	4	1
2.45501	158.778	15.1944	3.89801	0.060606	1429	4	1
4.86491	231.444	126.778	11.2596	0.130612	2083	4	1
4.86491	231.444	126.778	11.2596	0.130612	2083	4	1
9.92177	227.333	508.75	22.5555	0.20082	2046	4	1
8.56284	230.333	389	19.7231	0.174089	2073	4	1
5.39409	233.111	158.111	12.5742	0.149194	2098	4	1