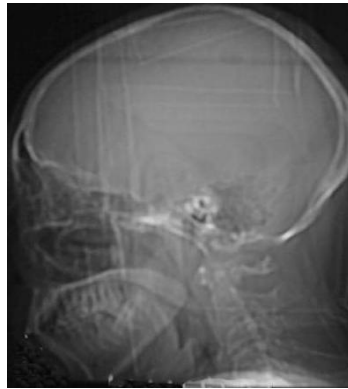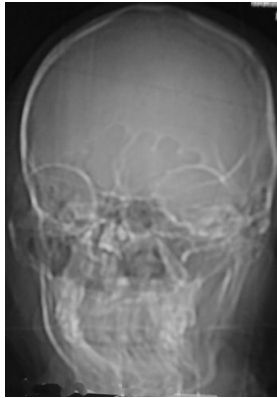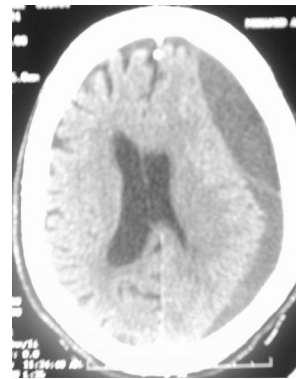
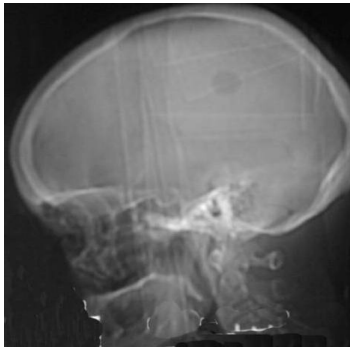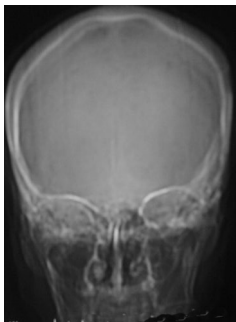




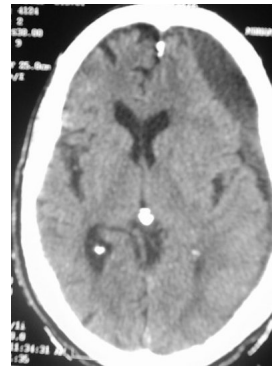
OF & lateral skull



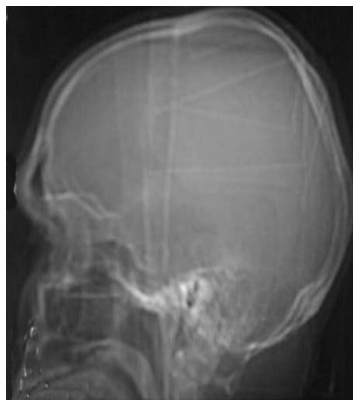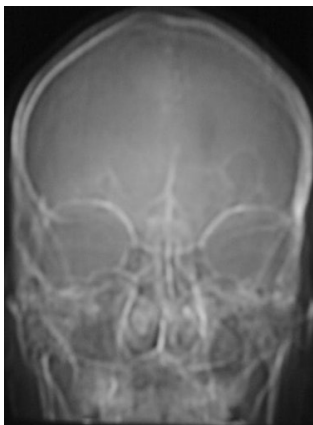SDH in axial CT scan



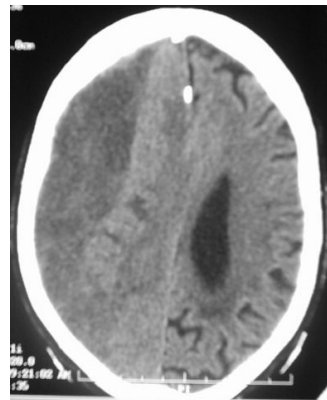
OF & lateral skull



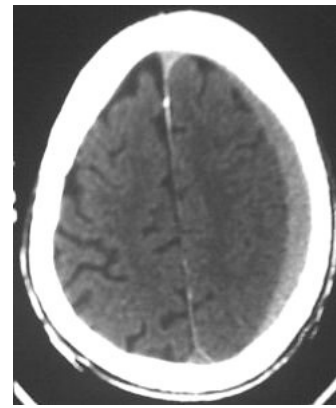
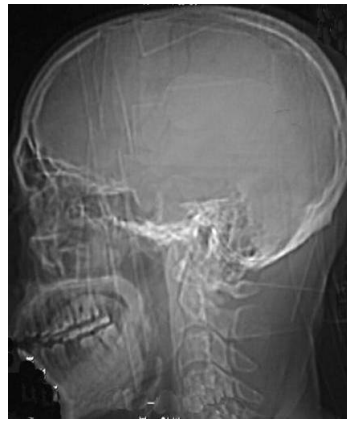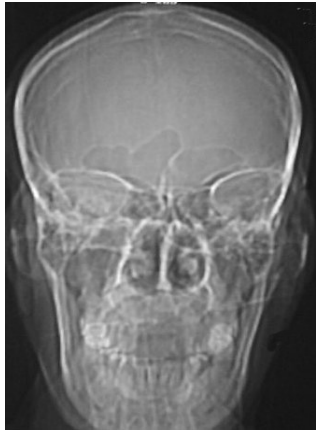SDH in axial CT scan



OF & lateral skull

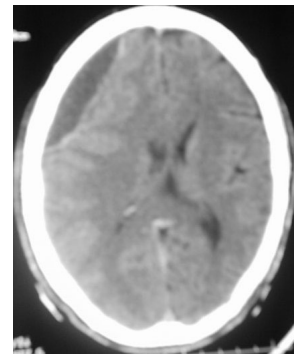
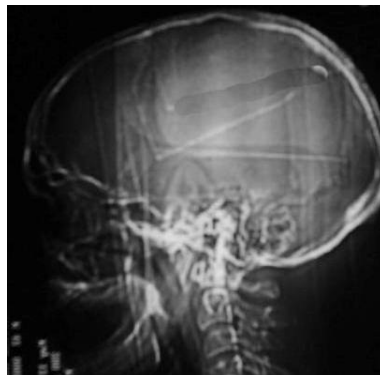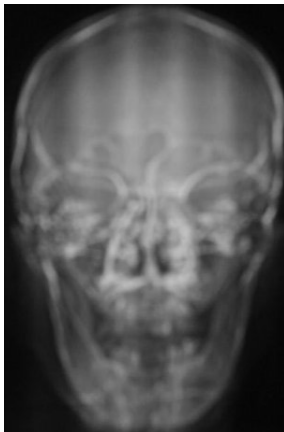


SDH in axial CT scan



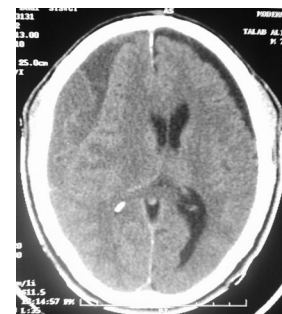
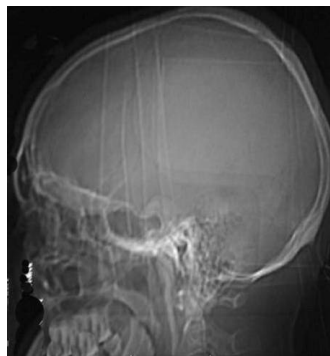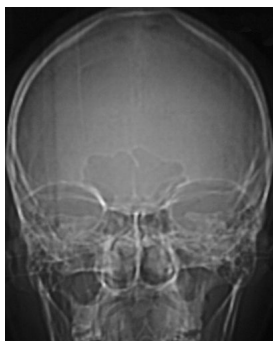OF & lateral skull

SDH in axial CT scan



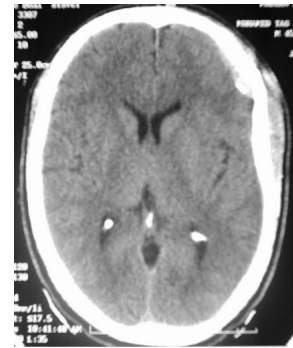
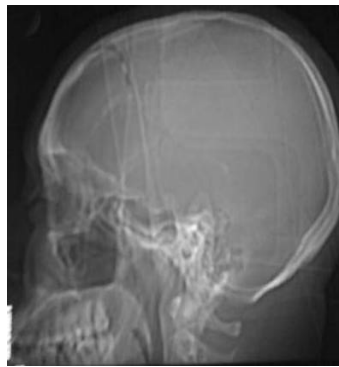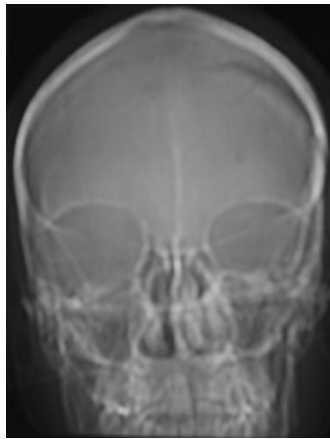OF & lateral skull

SDH in axial CT scan



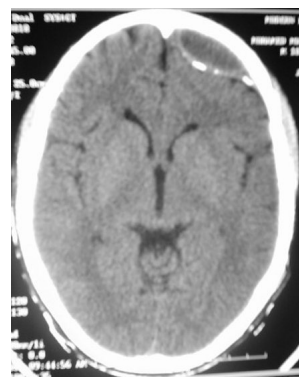
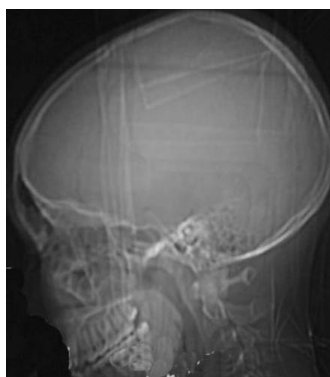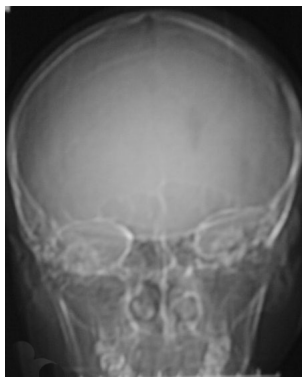
OF & lateral skull

SDH in axial CT scan



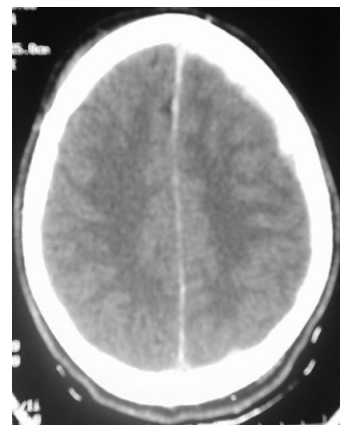
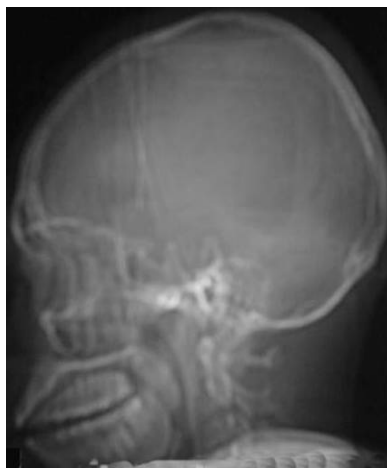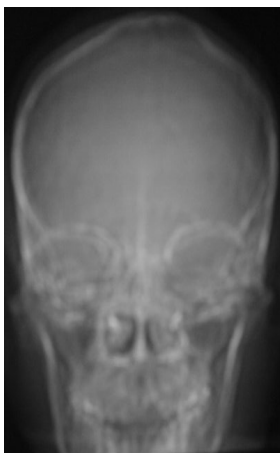OF & lateral skull

SDH in axial CT scan

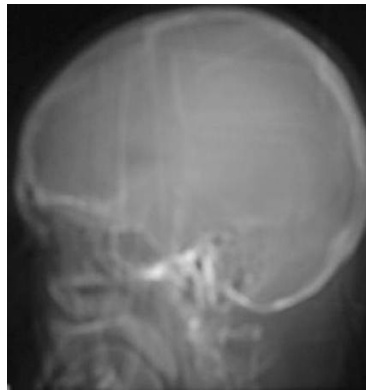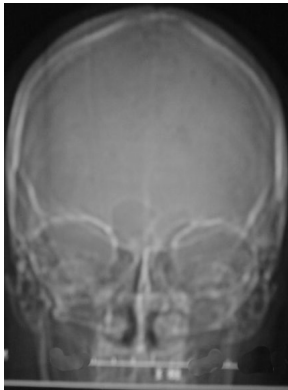


OF & lateral skull

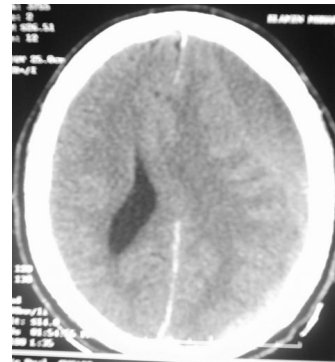
SDH in axial CT scan



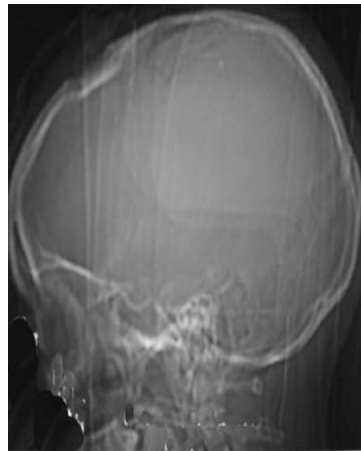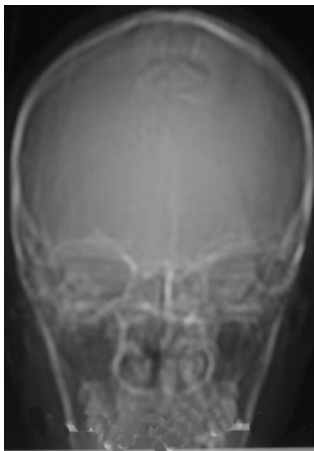OF & lateral skull



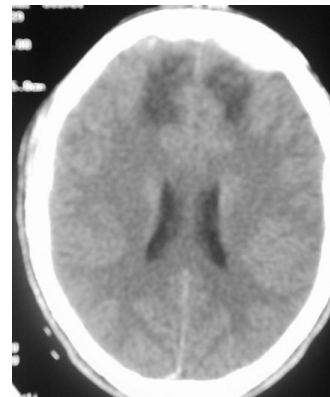
SDH in axial CT scan



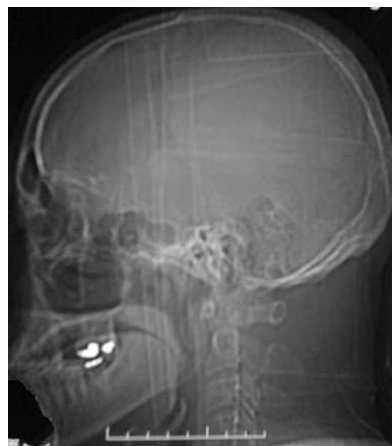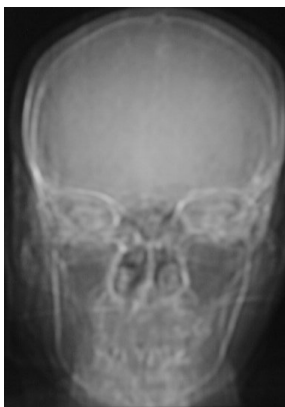
OF & lateral skull



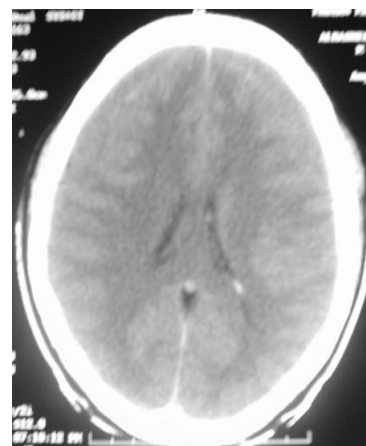
SDH in axial CT scan



OF & lateral skull

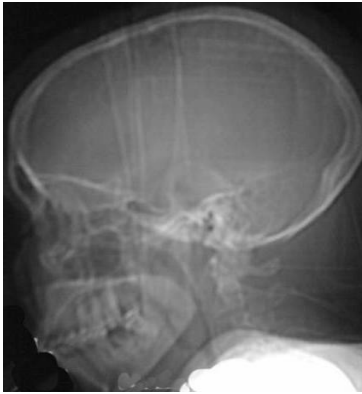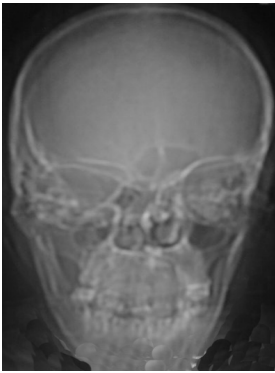


SDH in axial CT scan

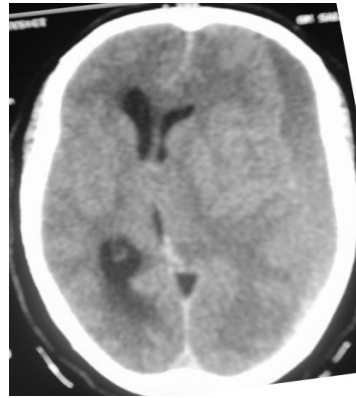




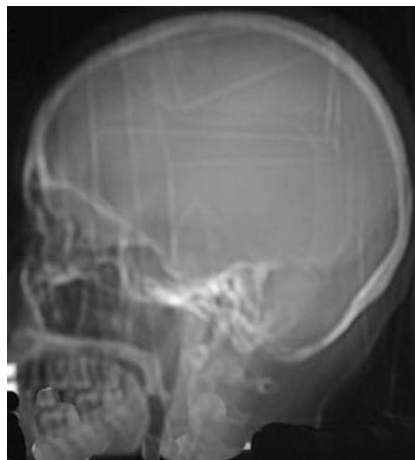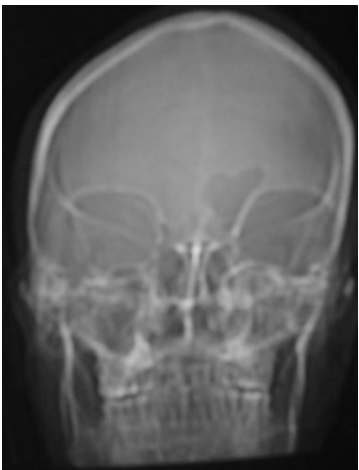OF & lateral skull



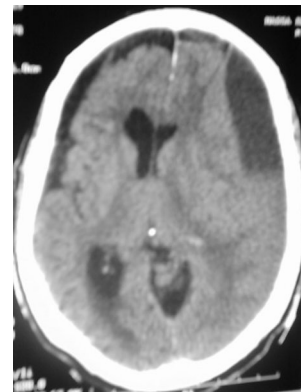
SDH in axial CT scan



OF & lateral skull

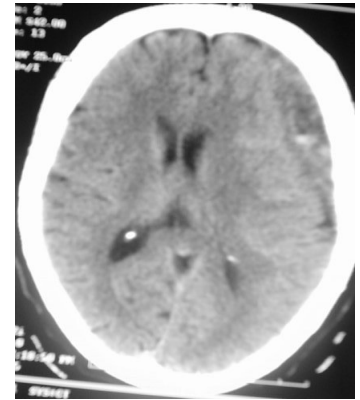
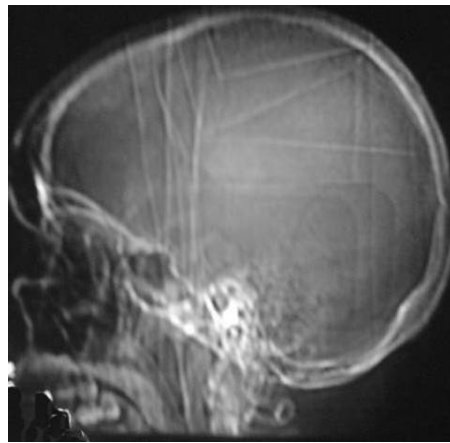
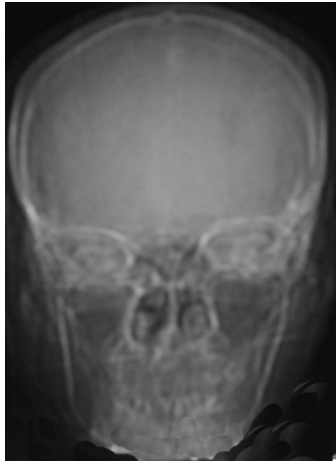

SDH in axial CT scan



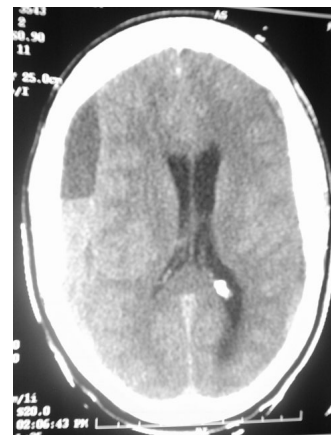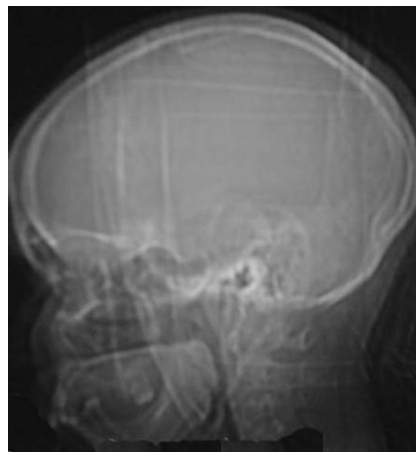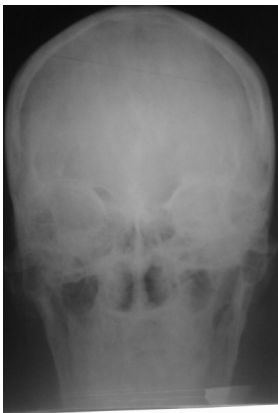OF & lateral skull

SDH in axial CT scan



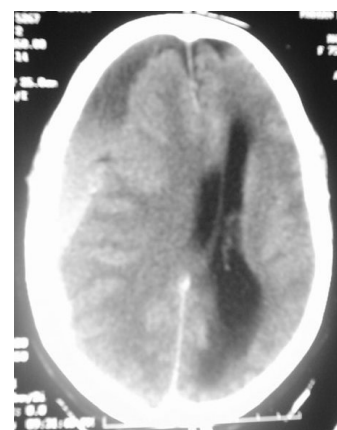
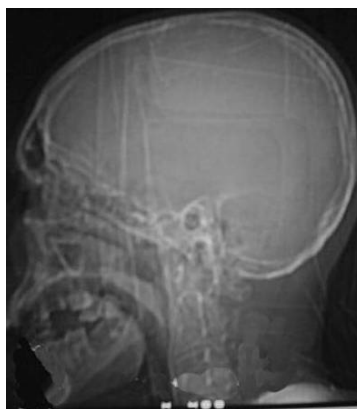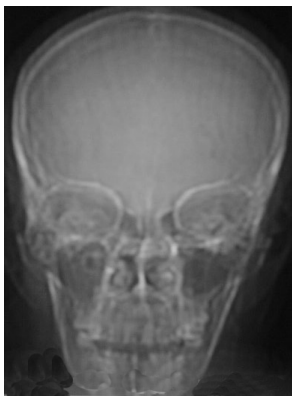OF & lateral skull

SDH in axial CT scan



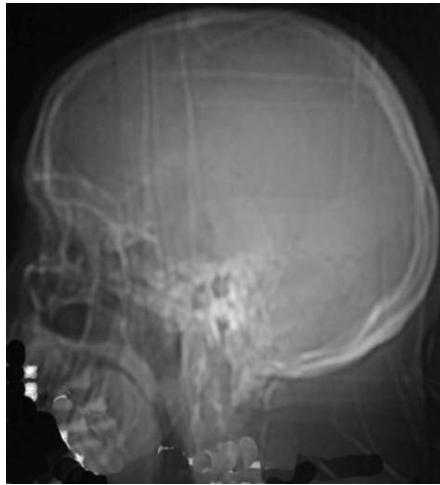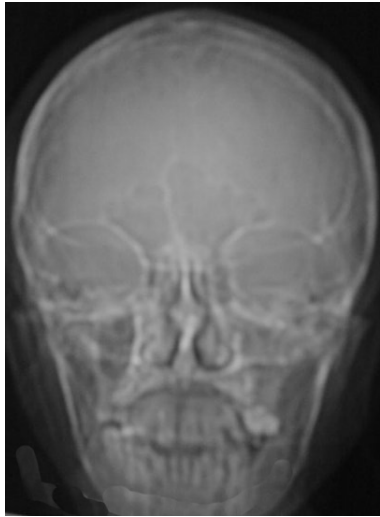OF & lateral skull

SDH in axial CT scan

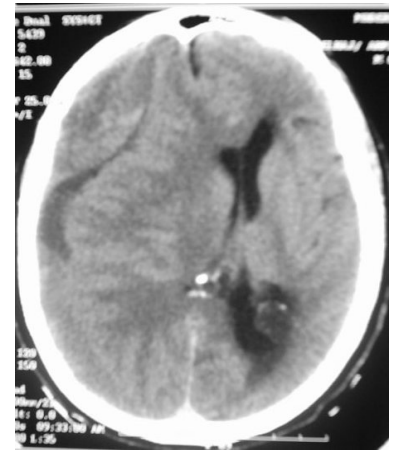

OF & lateral skull

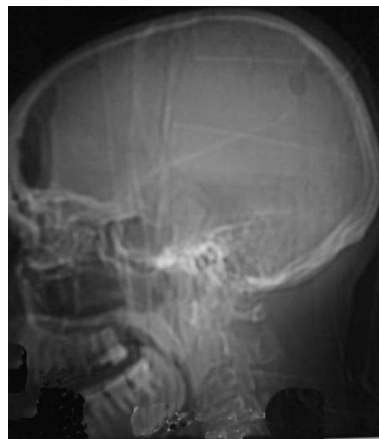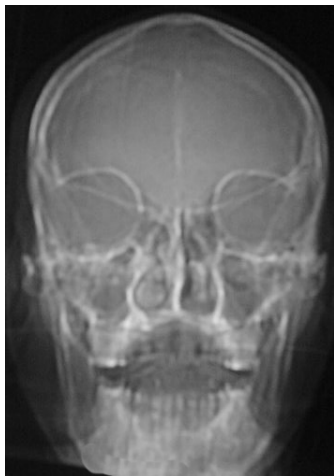SDH in axial CT scan



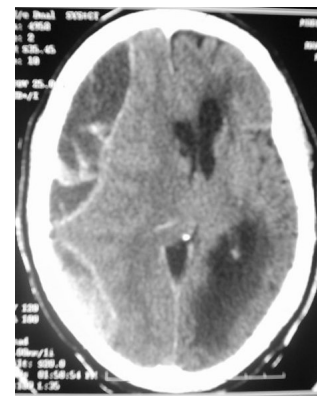
OF & lateral skull



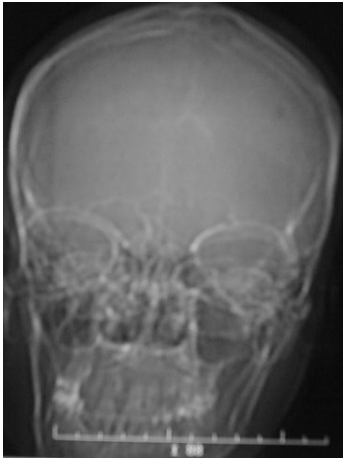SDH in axial CT scan



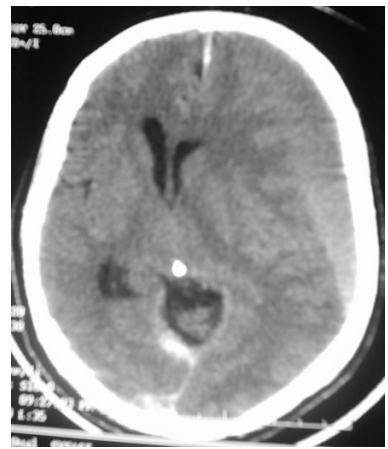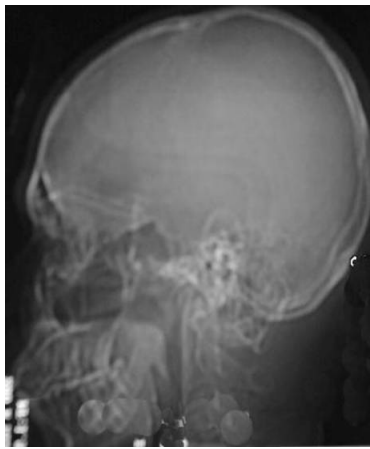OF & lateral skull



SDH in axial CT scan



OF & lateral skull



SDH in axial CT scan