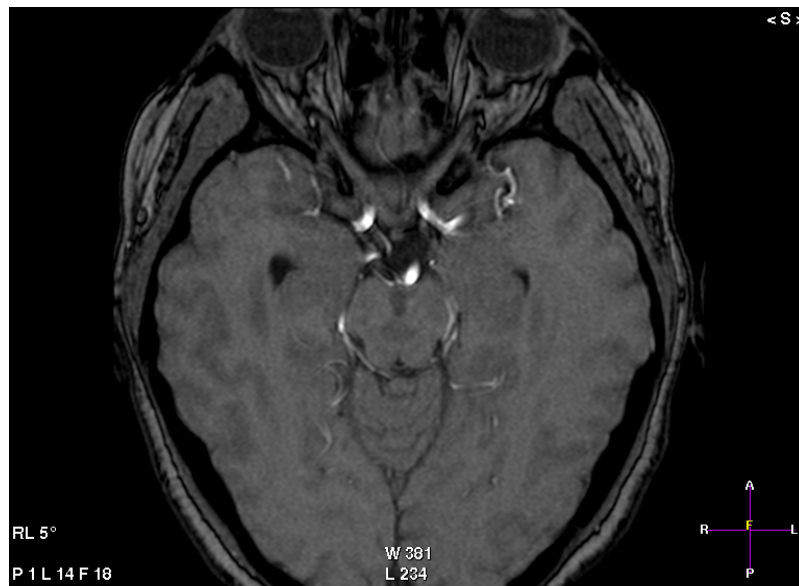
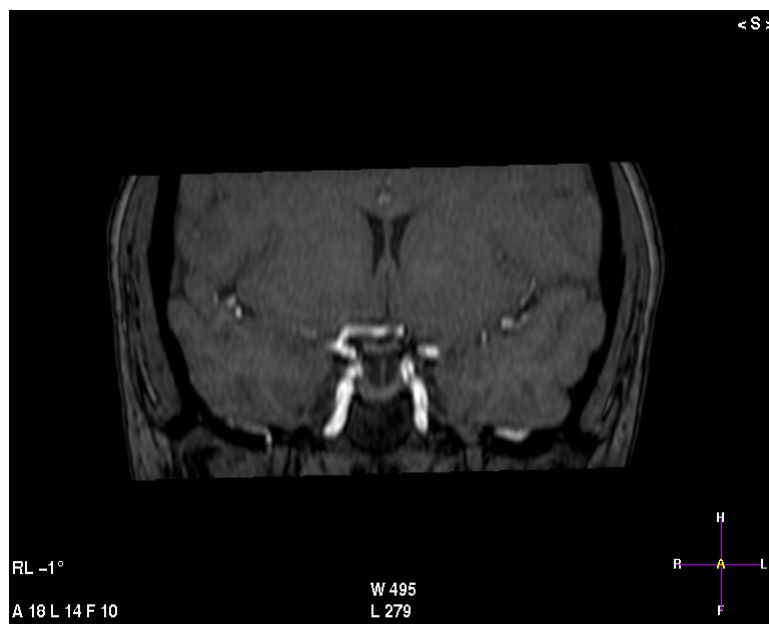
Axial MRI at level of pons of the brain showing

1. Optic chiasm
2. Optic Nerve



Coronal MRI at the level of the optic nerve showing

1. . Optic chiasm

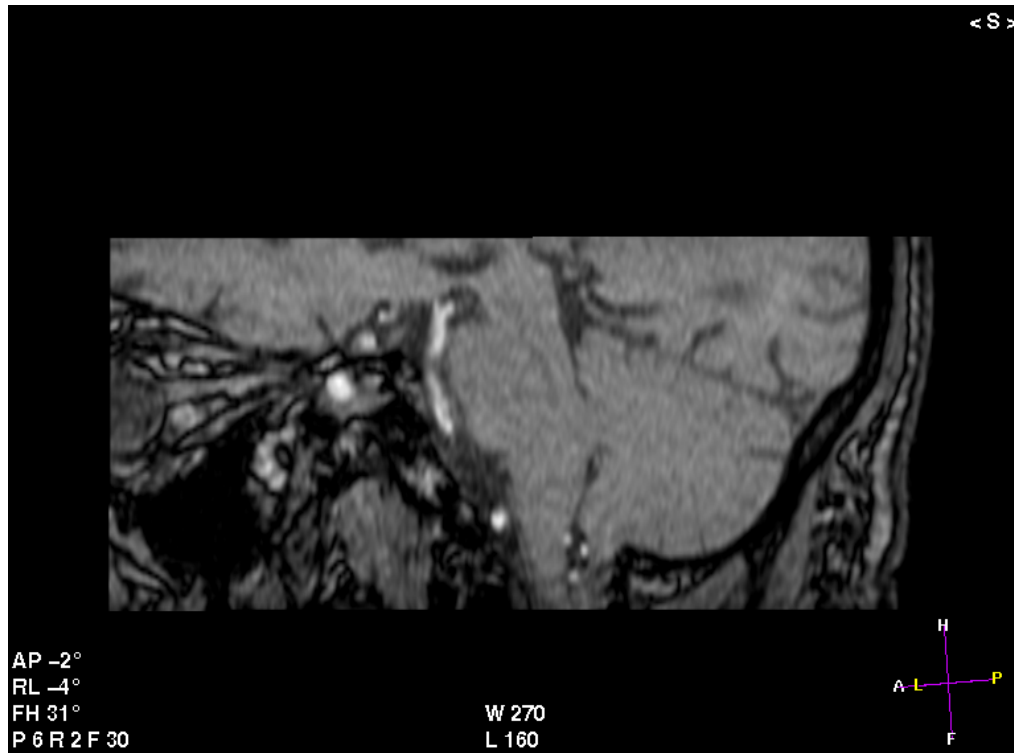


Image No (3)

Sagittal MRI showing

1. . optic nerve

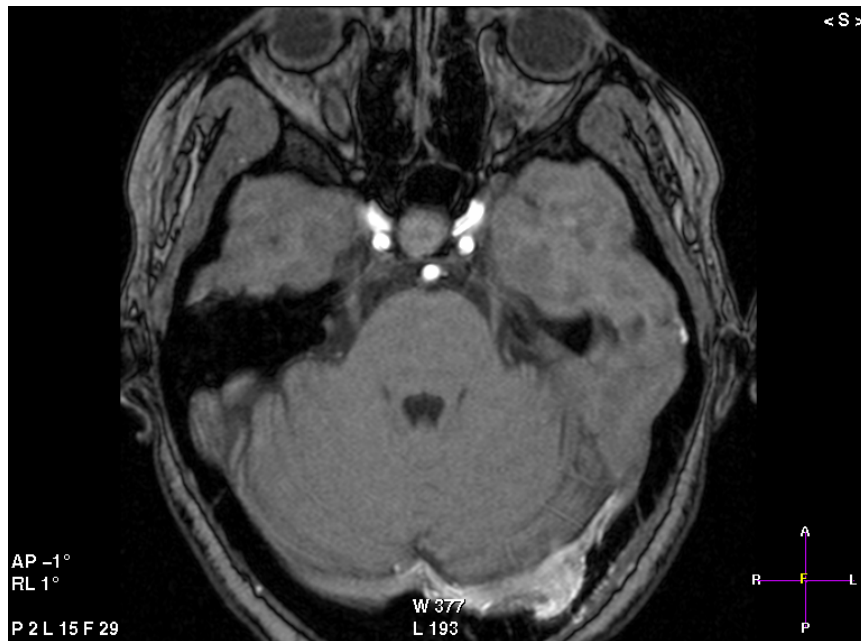

Image No (7)

Axial MRI at the level of the upper pons showing
 1. . Trigeminal nerve

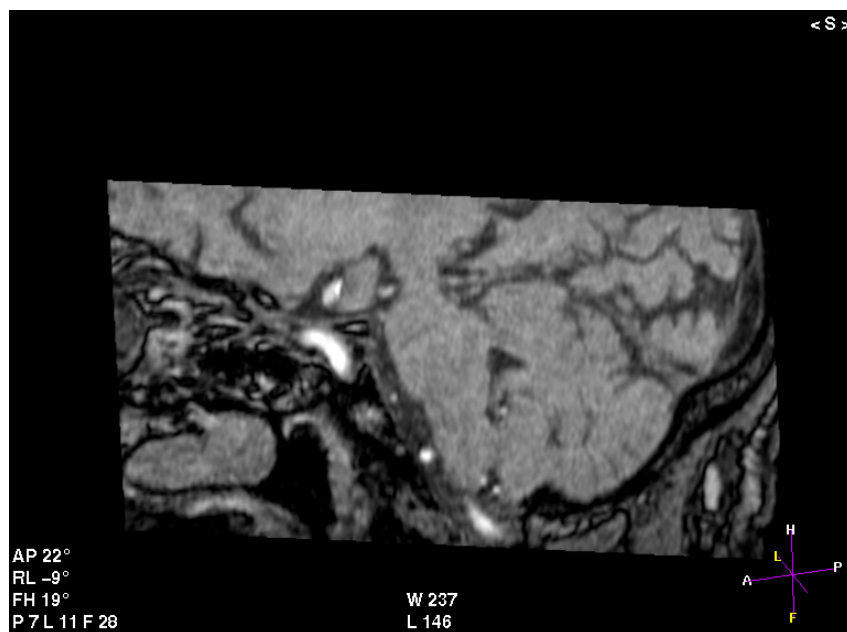


Image No (8)

Sagittal MRI showing
 1. Ophthalmic

2. Maxillary
3. Mandiblar

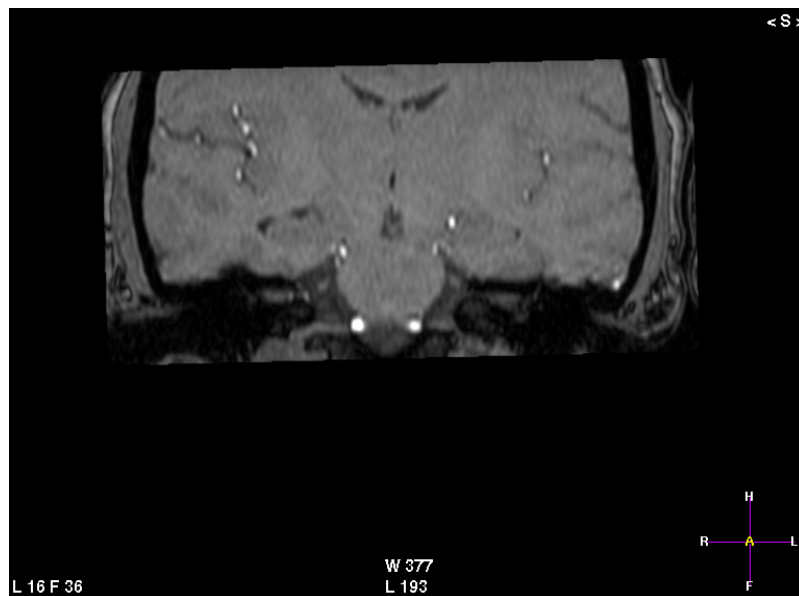


Image No (9)

Coronal MRI showing

1. Trigeminal nerve
1. Trigeminal nerve

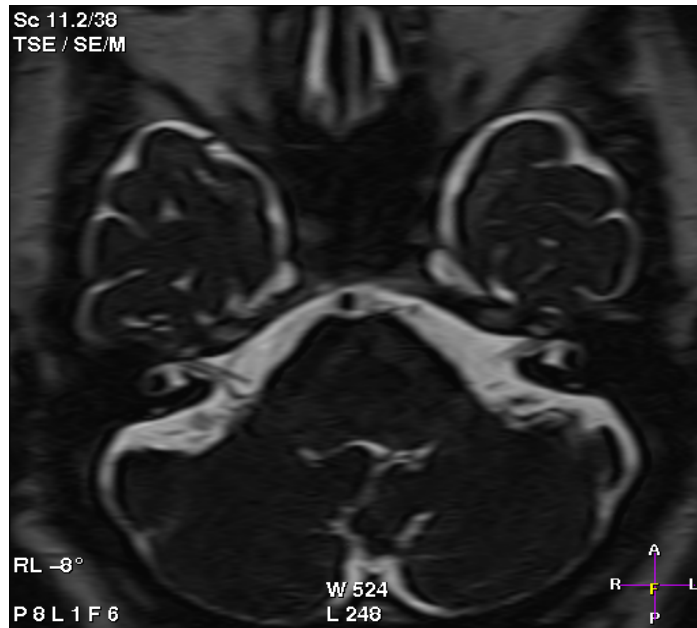


Image No (10)

Axial MRI showing

1. Facial nerve
2. Acoustic nerve

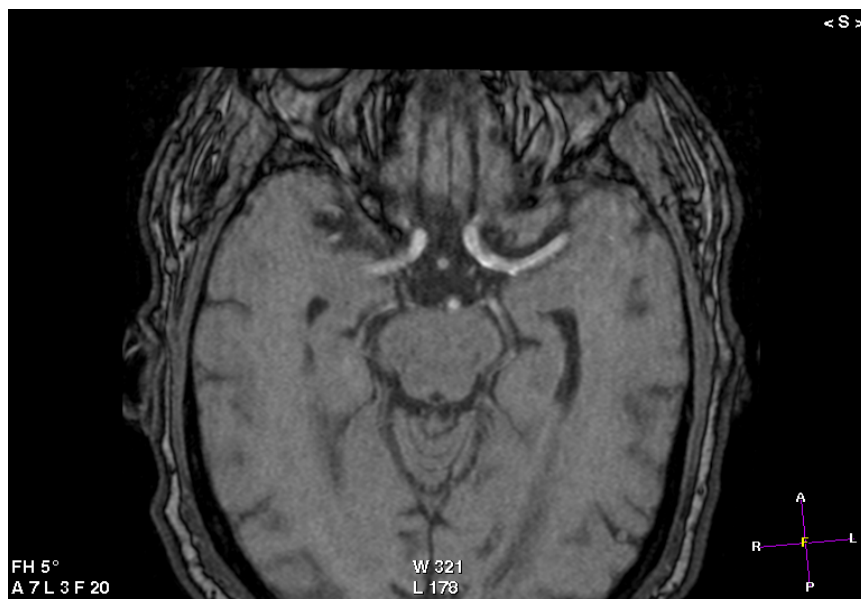

Image No (4)
Axial MIR Showing

1. Oculomotor nerve
1. Oculomotor nerve

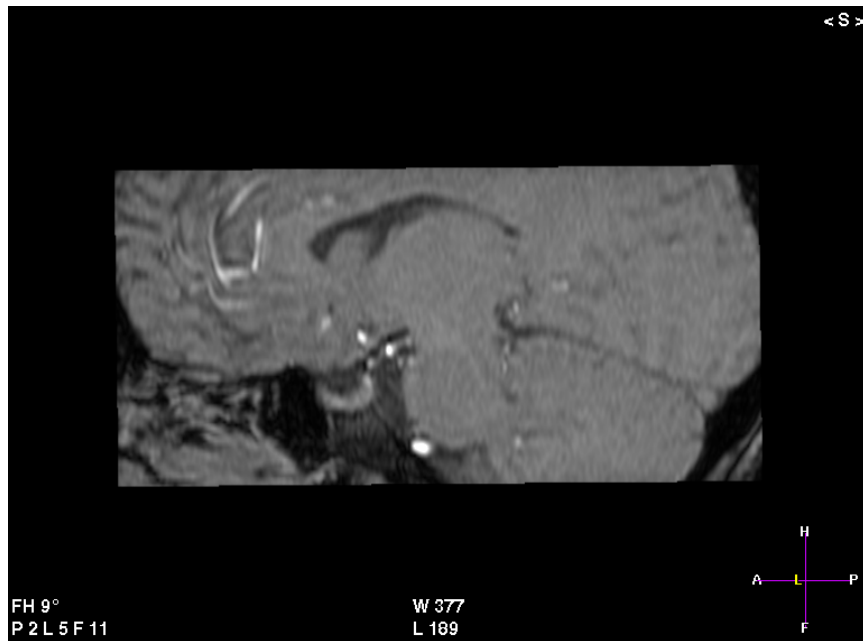


Image No (5)
Sagittal MRI showing

1. Oculomotor nerve

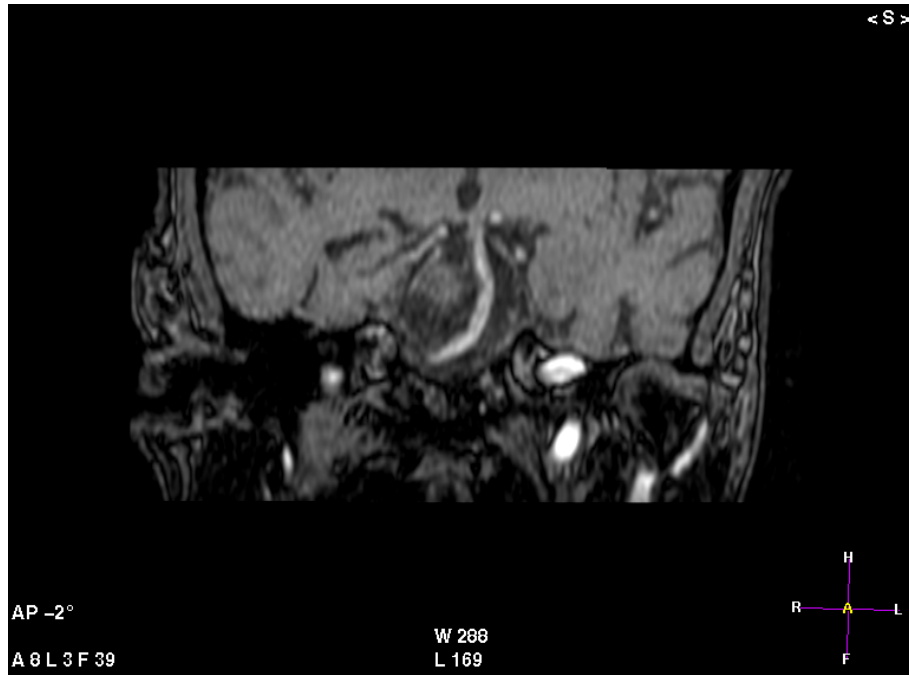


Image No (6)
Coronal MRI Showing
1. Oculomotor nerve