

# Chapter one

## Introduction

### 1.1 Introduction

Lasers are a relatively recent addition to laryngeal surgery. The use of lasers in laryngeal surgery has offered a time- and cost-efficient alternative to cold surgical techniques, and has been employed in the treatment of numerous laryngeal pathologies, including stenosis, recurrent respiratory papillomatosis, leukoplakia, nodules, malignant laryngeal disease, and polypoid degeneration (Reinke's edema). However, lasers can incur adjacent tissue damage and vocal fold scarring. These problems can be minimized through understanding the mechanisms by which lasers function and correctly manipulating the parameters under a surgeon's control. By varying fluence, power density, and pulsation, tissue damage can be decreased and lasers can be used with greater confidence.

The diode laser has been frequently used in the management of laryngeal disorders. The portability and functional diversity of this tool make it a reasonable alternative to conventional lasers. The diode laser has excellent hemostatic properties as a result of high absorption by hemoglobin and particularly by oxyhemoglobin. It is also absorbed by water(Saetti R et al ,2008).Furthermore it is portable, small, relatively inexpensive, and simple to use. It also has stable power output, long lifetime, and low installation and maintenance costs(Ferri E, ArmatoE,2008).Moreover, the diode laser

is delivered down by a fine glass fiber that allows the surgeon to hold it in a pencil-like holder for accurate manipulation. The fiber guidance system tip can be angled, which allows access to areas that are difficult to handle (Bajaj Yet al.2010). As a result, the use of diode laser in endolaryngeal microsurgery has increased in recent years (Karasu M F, Gundogdu R, Cagli S. et al.2014). Nonetheless, the ideal parameters of diode laser in endolaryngeal microsurgery and long-term results remain unclear.

## **1.2 Research Problem**

The main concept of this study is to provide some reliable evaluation of the use of diode laser in laryngeal diseases, trying to clarify its ideal parameters in the larynx, as well as its outcomes and complications.

## **1.3 Objectives of this Dissertation:**

- To provide a reliable evaluation of the use of 980 nm diode laser in laryngeal diseases
- Trying to clarify ideal parameters of diode laser in the larynx
- Outcomes and complications.

## **1.4 Dissertation layout**

The dissertation contains four chapters; chapter one introduction and literature review, the objective of the study and research methodology, chapter two consist of basic concept of laser and light interaction with matter. Chapter three consist of experimental part (the materials and devices and method), chapter four consist of results, discussions conclusions, recommendations and finally references.

## 1.5 Literature reviews

Lasers have been used in laryngeal surgeries since 1972, when Strong and Jako first reported the use of carbon dioxide laser (CO<sub>2</sub>) in the human larynx (Strong MS, Jako GJ. 1972). Despite initial criticism, endoscopic laser treatments have achieved universal acceptance and been successfully used in endolaryngeal microsurgery (EMS) (Bajaj Yet al. 2010). Most of the laser procedures involve either excision or tissue vaporization, depending on the interaction between the wavelength ( $\lambda$ ) and the chromophores of the tissue. For years, the CO<sub>2</sub> ( $\lambda$  = 1060 nm) seemed to be the preferred laser for transoral laser microsurgery due to its precise cut (Fanjul M, García-Casillas MA, Parente A, et al. 2008) given that it is better absorbed by water. However, there are some disadvantages of the CO<sub>2</sub> device, namely, its straight line beam delivery from surgical microscope, narrow penetration depth to tissue, difficult transportation, and increased cost. These drawbacks favored the study and application of other wavelengths in larynx, such as Thulium YAG ( $\lambda$  = 2000 nm), Nd:YAG (neodimium:yttrium-aluminum-garnet -  $\lambda$  = 1064 nm), diode ( $\lambda$  = 805 - 980 nm), PDL (pulsed dye laser -  $\lambda$  = 585 nm) and KTP (potassium titanyl phosphate -  $\lambda$  = 532 nm) (Fanjul M, García-Casillas MA, Parente A, et al. 2008) (Vilaseca I, Bernal-Sprekelsen M, Luis Blanch J. 2010).

As mention in the past, for the treatment of the larynx pathologies, were utilized various genres of lasers (argon, Nd: yag), actually the most chosen for this kind of intervention is the CO<sub>2</sub> laser. The energy delivered by this laser is decidedly better than the one delivered by the argon laser. The CO<sub>2</sub> laser is considered a very advantageous instrument for the microsurgery, offering, compared with the traditional techniques, substantial and

undeniable advantages. The pathologies treated by the CO<sub>2</sub> laser are wide-ranging: inflammatory, degenerative, neoplastic, and obstructive. The CO<sub>2</sub> laser finds special applications for the treatment of: vascular cord disease, hemangiomas, granulomas, reinke edema, and iatrogenic post-radiotherapy or post-surgery edemas. The use of the CO<sub>2</sub> laser for the treatment of larynx lumps, initially disputed for the functional outcomes that were not always the best because of vaporization, today has a reliable application thanks to the aging of the instruments (micro- spot) and of the surgical techniques. Catalano was one of first's users of the CO<sub>2</sub> laser for the treatment of the benign larynx pathology. The laryngeal papillomas are treated by the majority of laryngologist with the CO<sub>2</sub> laser: the little lesions are vaporized; the big ones are removed from the base. The chronic laryngeal stenosis represents a valid indication for the CO<sub>2</sub> treatment. It is necessary to excise the fibrin depository that was formed in the post-operative time, because they could be the starting point for the formation of bridge and scar stenosis. Depending on the pathogenesis the results are better for the treatment of the post traumatic and post-surgical stenosis, worse for the post radio- therapy and post-caustically ingestion stenosis. Depending on the site of the stenosis, results are good for the supraglottic level, uncertain for the glottic level, poor for the subglottic level. The bilateral chords palsy in abduction could be treated by the CO<sub>2</sub> laser use; it allow the performance of a total arytenoidectomy associated with the vaporization of the posterior portion of the unilateral vocal chords and of the false vocal chords. The CO<sub>2</sub> laser technique shows, compared with traditional methods, the advantage of being of easy execution, it avoids the tracheotomy and assures good breathing and fonator results. The larynx dysplastic lesions require the performance of an excisional diagnostical-

therapeutical biopsy that requires a good experience for conciliate the complete excision of the lesion with the smaller functional damage. Some surgeon use the CO<sub>2</sub> laser for underpericondrial way to perform a radical intervention on the carcinomas of the glottic plan limited on one true vocal chords, or rather that affect one chords and the surrounding region (anterior commissural, Morgagni ventricle, false vocal chords, contralateral vocal cords) and on carcinomas of larynx vestibule localized on the upper edge of the epiglottis, on the edge of the aryepiglottical folds or on the false vocal chords. The only inconvenient is represented by the possibility of the formation of granulations in correspondence to the areas where the cartilaginous skeleton was deprived of his pericondrial cover. The contraindications of the use of the CO<sub>2</sub> laser are represented by the neoplastic infiltration of the cartilaginous skeleton, of the cricothyroid membrane or thyroepiglottical lodge or by the presence of local metastatic adenopathy.

From the technical point of view the endoscopic laser-surgery could be performed in substitution of all the partial or total larynx interventions: the laser ray it is only a peculiar scalpel by that could be performed from an internal way the same action provided in the traditional interventions for an external way.

As laser, introduced in ENT surgery, it has been object of ceaseless improvements and constant technological evolution.

Diode laser contributes to a more selective and less invasive surgery, minimizing the risk and post-operative period in hospital, it is indeed able

to transmit to the fabric up to 60 W of laser energy at a wavelength of 810 nm; this ensures a precise cutting/coagulation and a excellent tissue vaporization. The possibility of using different sizes optical fibers (400, 600 and 1000) nm, both in “contact” and “no contact” modality, allows a very effective use in endoscopy.

The diode laser emits wavelengths that are absorbed predominantly by hemoglobin and melanin (near infrared spectrum). The penetration depth depends on the concentration of these chromospheres and, generally, it reaches (0.3–1.0) mm which makes it ideal for photocoagulation(Vilaseca I, Bernal-Sprekelsen M, Luis Blanch J.2010)(Ferri E, Armato E.2008)(Sullins K E. 2002).In conformity to that, the diode laser (~3–5) W allows thermal coagulation that had been unimaginable with the CO<sub>2</sub> laser(Saetti R et al. 2003).All of these characteristics, confer on diode laser as surgical precision with only slightly inferior to the CO<sub>2</sub> laser, but with a superior coagulation capability for treating laryngeal vascular lesions.Compared with other devices, diode laser also appears to be more precise and less invasive. For instance, the cutting precision of the NdYAG (1064 nm) is considerably lower, and the instrument also led to greater immediate and deferred inflammatory damage due to thermal diffusion (high penetration capacity of up to 4 mm)(Fanjul M, García-Casillas MA, Parente A, et al. 2008).

Furthermore, the diode lasers beam, in contrast to the carbon dioxide laser, is carried by flexible optic fibers that can be coupled with telescopes permitting access to sites that are difficult to explore with other techniques, such as the subglottic region (Saetti R, Narne S et al.2008) Recently, a CO<sub>2</sub> laser beam delivered through a flexible hollow tube has

become available that delivers the beam closes to the target(Rubinstein M, Armstrong W B.2011). However, the use of diode laser by contact (or extremely close distance) makes it much safer than other laser sources by avoiding damage due to “beam escape” in an open field(Saetti R, Narne S et al.2008).

An additional property that can affect the severity of tissue damage is thermal relaxation time, the time required for tissue to lose 50% of its heat through diffusion(Benninger MS. 2000). One can decrease tissue damage by allowing heated tissue to cool during a procedure. However, it could be accomplished through the use of a pulsed laser, spacing out laser impact, even for a continuous incision, that decreases thermal damage by allowing time for the tissue to cool between impacts and this can do easily with diode laseror by manual tissue cooling(Yan Y, Olszewski AE, Hoffman MR, et al. 2010).

Special attention must be given to laser surgery for the treatment of glottic cancer when use diode laser, once it can be more cost-effective than ‘cold surgery’ when managing laryngeal tumors, as they allow briefer hospital stays and shorter wound recovery periods(Xu W, et al.2007) .

Case study was done in the Catania University the diode laser was employed for the surgical treatment of the patients in the care of the Ear Nose and Throat Clinic. The case study has concerned subjects aged between (32 and 81) years, of male and female genders, affected by various pathologies of otolarygological pertinence concerning nose and

paranasal sinuses, pharynx, larynx and trachea affections. With regard to the rhino-sinuses pathology, were treated subjects suffering from turbinate hypertrophy, chronic sinusitis with polyps, antrostomy. The pharynx pathology concerned subjects with adenoidal relapse. In larynx-tracheal field were treated benign and malignant transformations of larynx and polypoidal formations of the trachea. The follow-up of the treated subjects was very poor and so considered only the post-operative results obtained immediately after the treatment. The surgical diode laser was with a wavelength of 810 nm, power transmit to the tissue up to 60 W. The diode laser was utilized both in the “in contact” and in the “not in contact” modality, depending on the entity and on the localization of the lesions. The “not in contact” modality required more energy and the evacuation of the smoke produced utilizing a continuous aspiration, for this reason they utilized more the “in contact” method. The utilization was performed with dissectory and photocoagulative proceeding. The optical fiber utilized for the “in contact” and for the “not in contact” treatments was of two size (600 and 1000)mm; moreover, the “in contact” ones had a conical (300)mm or a spherical (800 and 1200)mm tip. In some cases the optical fiber was utilized through a handful, in other cases was set on traditional pincer, in others it was introduced through the operative channel of the fibroscopy. The anesthesia practiced was local in the majority of cases; the general anesthetic was practiced for the treatment of subjects with benign and malignant transformations of the larynx. The surgical diode laser was utilized taking advantage of the photothermal effects and interactions to obtain the excision (so the laser ray was utilized as a cutter) or the vaporization, i.e. the destruction of tissues through coagulation necrosis. Both the alternative had met requirements. The vapo-coagulation action



was especially employed for the performance of the turbine-plastic, which is made on well vascularized tissues. Only in few cases and for a precautious purpose was performed a tamponation of the nasal fossa. In laryngeal field were utilized both the cut action and the vapo-coagulation action. In particular the treatment regarded a subject with a Reinke edema and collapse of the false chords and a subject affected by a supraglottic carcinoma (T2 N0 M0) that underwent a tracheotomy for breathing difficulty. In the first case the false chords plastic was easy tank to the vapo-coagulation possibility, whereas the chords mixomatosis was treated with the cutter function performing a linear cut on the mucosa of the superior surface of the vocal chords. In the supraepiglottic carcinoma (carcinoma of the false left cord extended to the inferior part of the subiodal epiglottis and to the beginning of the contralateral false chord - T2 N0 M0), after the charging of the supra-iodal epiglottis utilizing a Warda laryngoscope, were exposed the ariepiglottical folders and the laryngeal face of the epiglottis. The section was made starting from the left, on the anterior edge of the arytenoid and going up till the pharynx-epiglottis fold. On the right the section involved the anterior side of the false chords till down to the true chords without touch it and till up to almost the pharynx-epiglottis fold. So was performed a horizontal section from the left pharynx-epiglottis fold to the right one passing through the epiglottis; the section was made at a minimal distance of 0.5 cm from the neoplastic lesion. The section was made deep in medium-lateral sense in the tissue of the superior paraglottis space and of the anterior pre-epiglottis tissue till to arrive to the superior edge of the tiroidealcartilagine; then was performed the section for inner pericondrial way till down to arrive in the bottom of the ventricular. So it was realized a left vestibulectomy enlarged to

the ipsilateral aryepiglottic fold and extended to the inferior portion of the epiglottis and of the pre-epiglottic tissue and a partial right vestibulotomy. During the performance of the section on the inner perichondrium, or because of the traction of the pincer on the operating piece, or because of the coagulation necrosis, a piece of the operating piece broken away. The surgical trauma in the treatment of this pathology has been drastically reduced; the post-surgical course was fast. In relation to the use of the diode laser as cutter, also if in a small amount of cases, it seems to us that the cut section it is not as linear as other instruments (scalpel, CO<sub>2</sub> laser), having the impression that the surfaces surrounding the section had a certain depth of carbonization. In relation to the vapo-coagulation aspect the result was very satisfactory, having the possibility of obtain the result without hemorrhages (Salvatore Ferlito, et al. 2011).

Also systemic review study done by Helena Hotz Arroyo and his group in 2016 included eleven studies in the final analysis. From the included articles, they collected data on patients and lesion characteristics, treatment (diode laser's parameters used in surgery), and outcomes related to the laser surgery performed. Their search strategy yielded a total of 284 articles, 234 articles was excluded. The 13 eligible articles were full-text assessed, but two more were excluded due to failure to meet eligibility criteria, left 11 articles appropriate for inclusion in the review. A total of 357 subjects made up the study population from the 11 included studies. The average number of participants per study was 32.45 (range: 8–72) year. The laryngeal pathologies included were supraglottic granuloma, Laryngomalacia, ventricular dysphonia, vocal polyp, glottic web, papillomas, glottic carcinoma, bilateral cord palsy, subglottic cysts,

subglottic stenosis, and subglottic hemangiomas /lymphangioma. One of article was for fanjul et al in 2008 in Spain which include 22 patients , with 11 male and 11 female , he was utilizing wave length of (820 +20) nm fiber diameter 400-600µm power range from (10-15) w , pathologies that involves was bilateral cord palsy, subglottic cyst , subglottic stenosis subglottic hemangiomas/lymphangioma ,suprastomal granuloma and Laryngomalacia,the main outcome finding was : saccular lesions, mucous membranes, granulomas and arytenoid abnormalities resolved by the exclusive application of laser (78.6% with a single procedure). In other situations, such as vascular anomalies (hemangiomas and lymphangiomas) and subglottic stenosis, we have pointed to other treatments (surgical and medical in 87.5% and 12.5% respectively) for resolution(Helena hortzarroyo,et al. 2016).Ferri et al 2008 Italy did study with 45 patients with glottic cancer used wave length 810 nm, length of fiber (600-1000)µm ,power (5-30) w ,frequency 60hz with continuous mode and direct contact,Their outcome were 5 recurrences (11.1%): 4 local (8.9%), in which 3 were salvaged, and 1 (2.2%) regional (N2<sub>a</sub>). Three patients (6.7%) developed second primary cancers on the opposite cord after a mean of 18 months (range, 9– 47 months) (1 was salvaged with total laryngectomy, 1 with repeat laser surgery and RT, 1 with partial laryngectomy with open surgery)(Helena hortzarroyo,et al. 2016). Bajaj et al 2008 UK did study with 31 patient with pathology which include suprastomal granuloma , Laryngomalacia, v.c polyp, glottic web ,papillomas, bilateral v.c palsy ,subglottic cyst and stenosis they use 805 wavelength fiber diameter 400 power 3-5 w with continuous and direct contact their outcome was 19/31 (61.3%) patients have been cured of their initial pathologies and were not under further review,another 9/31 (29.0%)

had to undergo different operations, the remaining 3/31 (9.6%) (all three recurrent respiratory papillomatosis) are undergoing repeated laser and other adjuvant treatments (Helena hortzarroyo, et al. 2016). Edizer et al 2013 turkey had 58 patient in their study all had glottic cancer with power range from 6-12 w continues mode the outcome and complication in their study was , The involvement of the anterior-commissure was present in 13 (22%) of the patients, during the follow-up period 8 of these patients granulation tissue or synechia developed at the anterior part of the larynx. Local recurrence was encountered in 5 (8%) patients (1 case with T1a, 3 with T2 and one patient with T3 primary tumor at the initial presentation), thyroid cartilage exposure in 1 patient, intraoperative laser-induced fire occurred due to thermal injury of the laser on the intubation tube in 1 patient, 2 patients developed cutaneous emphysema which resolved in one day without intervention, in the postoperative period, infection and foul smelling halitosis developed in 5 patients in whom relatively more extended laser surgery was performed, laryngeal stenosis was seen in 2 patients (Helena hortzarroyo, et al. 2016).

Various combinations of parameters between wavelength, fiber diameter was compared, the preferred wavelength changed from 810 nm to 980 nm since 2013. The minor fiber diameter described was 300  $\mu\text{m}$  and the isolated major one was 1400  $\mu\text{m}$ . The output power varied from 3 W to 60 W. special attention given to laser surgery for the treatment of glottic cancer, once it can be more cost-effective than 'cold surgery' when managing laryngeal tumors, as they allow briefer hospital stays and shorter wound recovery periods (Xu W, et al. 2007). The  $\text{CO}_2$  laser surgery was presented as one of the most accepted treatment options of early glottic

carcinoma due to its high local control rates, low morbidity, and good postoperative voice quality(LucioniM,et al.2011). However, if the surgeon has difficulty in managing laryngeal anterior commissure tumors, he or she is encouraged by some authors to avoid CO<sub>2</sub> laser microsurgery. Alternatively, the 810 nm diode laser has been recently used for the treatment of glottic tumors and may allow better exposure and resection of tumors in the anterior commissure. The first to establish long-term results for glottic cancer treatment were (Ferri et al, in 2008). However, it seems that diode laser has not been well accepted worldwide for laryngeal surgery, as review shows a gap of publications between 2008 and 2013. According to that, speculate that most institutions continued using the CO<sub>2</sub> laser, due to doctors' familiarity with its use, capabilities, and limitations (Yan Y, Olszewski AE, Hoffman MR, et al.2010)(Cömert E, et al 2014).On the other hand, the 980 nm diode laser is a new technology, and has been reported for the treatment of early glottic tumors and vocal fold polyps since 2013(Cömert E, et al 2014) (Tunçel U, Cömert E.2013)(Karasu MF, Gundogdu R, Cagli S, et al.2014) .The main difference between these two diode laser wavelengths is their distinct absorption by the vocal fold, as the 980 nm is slightly more absorbed by water than the 810 nm one.

Regarding safety issues, five authors reported no complications or side effects by the use of the diode laser, but none of these studies was related to glottic cancer or extensive procedures. The major complications were related to more extensive surgeries and with anterior commissure involvement(Tunçel U, Cömert E.2013).Possibly the most feared complication is the endotracheal tube airway fire, which can be

catastrophic or even fatal(Dhar P, Malik A,2011).To avoid that, some authors use reinforced tubes for laser surgery (Ferri E, Armato E.2008). While others described the tube being inflated using saline with methylene blue dye, so that a puncture could be immediately diagnosed(Tunçel U, Cömert E.2013).

This review highlights the lack of good evidence for the use of diode laser in laryngeal surgery. Furthermore, it is clear that there is wide variation in how it is used around the world. The 980 nm diode laser seems to be a promising laser device, so we would expect that, as experience increases, it will be more extensively used as well as new lasers wavelengths can emerge(Karasu MF, Gundogdu R, Cagli S, et al. 2014). Despite the heterogeneous populations, varied inclusion criteria, and retrospective designs of most the studies considered in this review, they do provide useful information to the surgeon who intends to use diode laser for transoral laser microsurgery. The evidence from recent studies suggests an improvement in diode laser technology (especially the 980 nm wavelength). Further long-term multicenter prospective research is needed, although the findings of this review suggest that diode laser is a useful tool that should be considered in laryngeal surgeries.

## **Chapter two**

### **Basic concepts**

## **2-1laser**

Laser is an acronym for light amplification by stimulated emission of radiation. A laser is created when the electrons in atoms in special glasses, crystals, semiconductor or gases absorb energy from an electrical, optical or another laser and become excited. The excited electrons move from a lower-energy orbit to a higher-energy orbit around the atom's nucleus. When they return to their normal or groundstate, the electrons emit photons (Iris Elias et al., 1976).

### **2.1.1 Properties of laser**

Laser photons are all at the same wavelength and are “coherent” meaning the troughs of the light waves are all in lockstep. In contrast, ordinary visible light comprises multiple wavelengths and is not coherent.

Laser light is different from normal light in other ways as well. First, it contains only one wavelength (monochromatic). The particular wavelength of light is determined by the amount of energy released when the excited electron drops to a lower orbit. Second, laser light is directional. Whereas a laser generates a very tight beam, a flashlight produces light that is diffuse. Because laser light is coherent, it stays focused for vast distances (James Bow, 2017).

### **2.1.2 Element of laser**

Technically four elements are required to generate laser namely the gain medium, the pumping energy, cavity reflections and the output coupler:

The gain medium also called lasing medium is the source of optical gain within a laser. The gain results from the stimulated emission of electronic or molecular transitions to a lower energy state from a higher energy state previously populated by a pump source (Siegman, Anthony E.1986).

The pumping energy is the act of energy transfer from an external source into the gain medium of a laser. The energy is absorbed in the medium, producing excited states in its atoms. When the number of particles in one excited state exceeds the number of particles in the ground state or a less-excited state, population inversion is achieved. In this condition, the mechanism of stimulated emission can take place and the medium can act as a laser or an optical amplifier. The pump power must be higher than the lasing threshold of the laser.

Cavity reflections in order to optimize the overall process of building a laser, need to add reflectors to either end of stimulation to capture the excited photons and return them back to gain medium to further create additional stimulation.

Output coupler this device allows a percentage of light reflection back to the gain medium and a percentage to be extracted from the optical resonator (the gain medium).

### **2.1.3 Laser types**

Lasers may be classified according to the type of active medium, excitation mechanism, and region of emitted wavelength or mode of operation



According to the active medium lasers are classified into solid, gas, liquid and semiconductor lasers. Whilst classification according to the spectral region of the emitted laser the classification is UV, visible and I.R. lasers.

Based on the mode of operation lasers are classified to continuous wave (CW), chopped, pulsed and ultra-short pulsed lasers.

## **2.1.4 Laser applications**

Many scientific, military, medical and commercial laser applications have been developed since the invention of the laser in 1958. The coherency, high monochromaticity, and ability to reach extremely high powers are all properties which allow for these specialized applications.

### **2.1.4.1 Scientific applications**

In science, lasers are used in many ways, including Spectroscopy, heat treatment, photochemistry, laser scanner, laser cooling, nuclear fusion and microscopy

### **2.1.4.2 Military applications**

Military uses of lasers include applications such as target designation and ranging, defensive countermeasures, communications and directed energy weapons

### **2.1.4.3 Industrial and commercial applications**

Industrial laser applications can be divided into two categories depending on the power of the laser: material processing and micro-material processing.

In material processing, lasers with average optical power above 1 kW are used mainly for industrial materials processing applications. Beyond this power threshold there are thermal issues related to the optics that separate these lasers from their lower-power counterparts. Laser systems in the (50-300) W range are used primarily for pumping, plastic welding and soldering applications. Lasers above 300W are used in brazing, thin metal welding, and sheet metal cutting applications (W.demotroder.2009).

#### **2.1.4.4 Medical applications of laser**

Laser are used in medical diagnosis, treatments, or therapies like:  
-laser photodynamic therapy.

-Cosmetic surgery (removing tattoos, scars, stretch marks, sunspots, wrinkles, birthmarks, and hairs).

-Eye surgery and refractive surgery.

-Soft tissue surgery.

-Laser scalpel (General surgery, gynecological, urology, laparoscopic),Photobiomodulation.

-In dentistry for caries removal,endodontic/periodontic.

-ENT surgery (laryngeal surgery, oral surgery, ear surgery).

## **2.2 laryngeal surgeries by laser**

Larynx is voice box and airway way that found in neck, it vital organ in breathing and vocalization, it can be affected by many disease that treated by conventional

method, laser can be used to treat many laryngeal pathology that had high failure rate when use conventional method e.g. laryngeal papillomatosis, glottic tumor and laryngeal web.

## **2.3Laser tissue interaction**

Tissue interaction with the specific laser wavelength is the key to laser selection. The interaction of an electromagnetic wave with a biological instrument will depend on the wavelength of the radiation itself, optical properties of the tissue.

In a first approximation the organic tissues can be regarded from the optical point of view as homogeneous mediums in which the propagation of the light radiation is described via fundamental optical properties such as Reflection, absorption, transmission, diffusion(Jacques SL.2013).

### **2.3.1Mechanisms of laser interaction with human tissues**

Types of interactions that are developed can be classified to:

- Low photochemical
- Medium photo thermic
- Greater Photo fragmentation

### **2.3.2Selective absorption of laser light by human tissues**

Selective absorption occurs when a given color of light is strongly absorbed by one type of tissue, while transmitted by another. Lasers' pure color is responsible for selective absorption. The main absorbing components of tissues are:

Oxyhemoglobin (in blood) Melanin Water

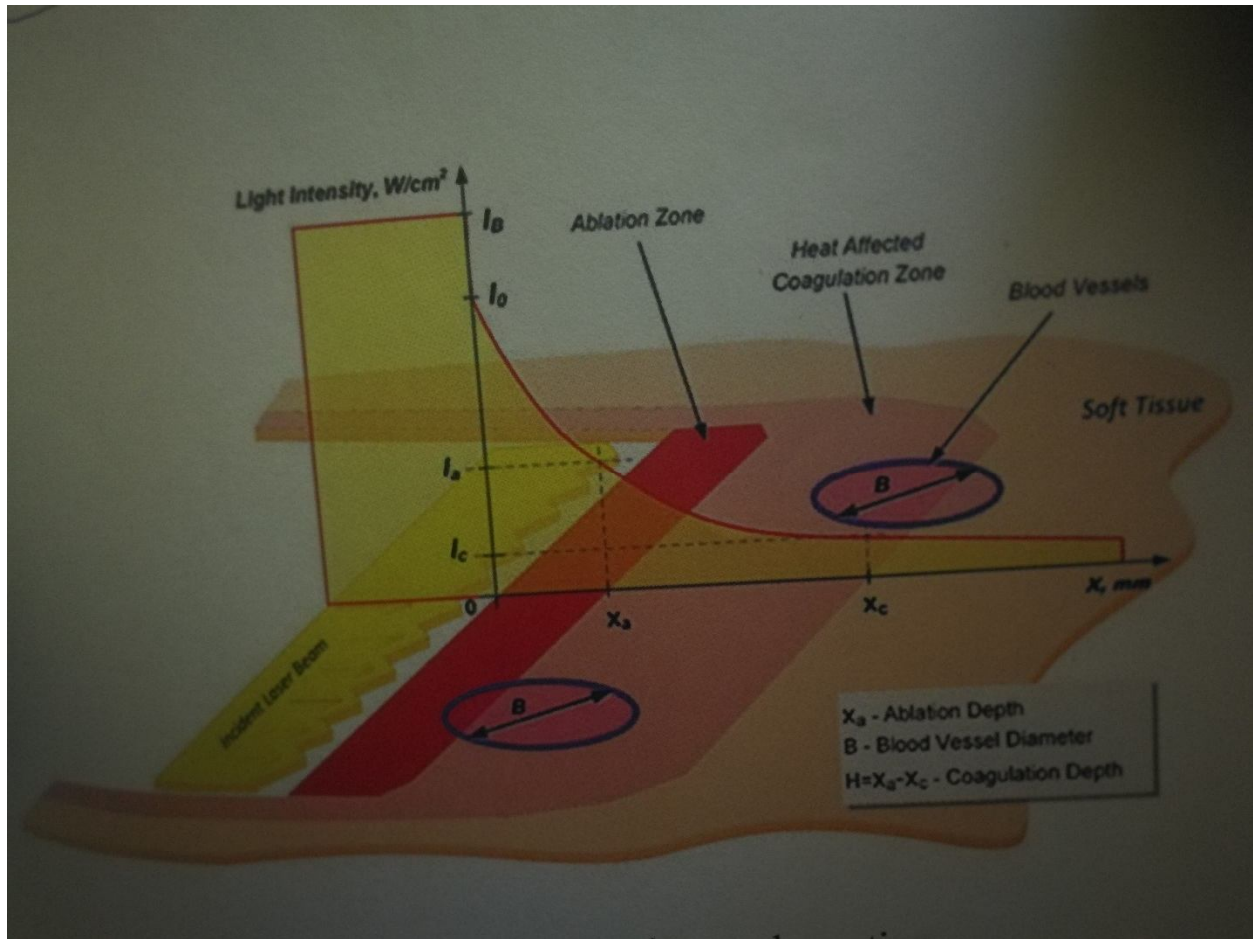


Figure.1: laser-energy-tissue- absorption

### 2.3.3 Laser tissue interactions parameters:

Parameter of tissue interaction include: wavelength band of that particular laser source.

Physical properties of the tissue irradiated with that particular wavelength or wavelength band.

Irradiance or pulse energy.

Continuous wave or pulsed irradiation.

Laser beam size on the tissue.

Irradiation duration or laser pulse length and repetition rate

Any change in the physical properties of the tissue as a result of laser irradiation with the parameters above.

### **2.3.4 Factor determine type and level of interactions**

Laser tissue interactions depend on many factors which is essential to determine type and level of interaction this include:

-The physical mechanism of interaction

Photochemical Photothermal Photomechanical

-The biological level of interaction

Tissue Organ Cellular Organellar

-, The time course of the interaction

Immediate physical effect

Short-term biological response

Long- term healing and structure/function

#### **2.3.4.1 Photochemical interaction**

The selective photochemical interaction between laser radiation and tissue may be obtained by means of endogenous chromophores, like hemoglobin and melanin for example, and also by means of exogenous chromophores. If the laser pulse has a duration lasting less than the thermal relaxation time of the chromophores (from several ns to approx. 10 ms) and is capable of exciting electronic or vibration transitions, photochemical interactions may be produced.

#### **2.3.4.2 Photothermic Interaction**

A large part of surgical applications with laser is based on the conversion of optical radiation into thermal energy. At a microscopic level The Photothermic processes are represented by the absorption of a photon by an organic molecule that takes it into an excited vibrational state, followed by de-excitation due to the inelastic impact with a molecule in the surrounding medium that increases its own kinetic energy. This process of takes place extremely quickly (1-100)ps and the consequent rapid thermalization produces an increase in local temperature (Jacques sl.2013).

#### Effects of low temperatures (43-100 °C)

The first hyperthermia effect on the biomaterial is the denaturation (breaking down of the hydrogen links) of the bio molecules and their aggregates (proteins, collagen, lipids, hemoglobin). At around 45 °C conformational changes can be observed with the breaking down of the links and-alterations-of-the-membranes. The single cells and the various tissues heated to a temperature of (43-45) °C are able to tolerate this damage momentarily. The damage becomes irreversible (cellular death) following periods of prolonged, and will depend on the minutes to several hours<sup>25</sup> exposition that may vary from type of tissue and the radiance conditions. In the case of cells of an oncological nature the cell death is particularly high under these thermal conditions. These processes can be applied in the interstitial hyperthermia techniques for the treatment of tumors (Shapshay S med.1987).

Coagulative      The coagulative and vacuolization necrosis process (cellular) takes place at temperatures exceeding the denaturation temperature. Between 50 and 60°C the enzymatic activities are modified (reduced), with the onset of a denaturation of the macromolecules like (proteins, collagens, lipids, hemoglobin), that is at the basis of the coagulation process. The denaturation of collagen is important, this being a fibrous protein widely diffused in mammals composed of four polypeptide chains united together to form a connecting rod structure. The increase in temperature destroys the spatial organization of the macromolecular chains; the spires distribute themselves in a casual manner with forceful changes in the absorption and diffusion spectrums of the optical radiation, and the appearance of a visible structural contraction of the collagen fibers.

Thermal denaturation and the contraction of the intercellular proteins, together of the shrinking with a possible collapse of the cytoskeletons, all produce the coagulated cells. The breaking of the membranes becomes predominant in cells of all types when these are seriously damaged by the thermal effect. These photocoagulation processes are used in dermatology for the treatment of vascular and pigmented lesions. Recently, techniques have also been proposed involving laser welding on the skin, blood vessels, based on the modifications induced on the collagen fibers due to laser heating at low temperatures (45-50°). Thermal denaturation and the contraction of the intercellular proteins, together of the shrinking with a possible collapse of the cytoskeletons, all produce the coagulated cells. The breaking of the membranes becomes predominant in cells of all types when these are

seriously damaged by the thermal effect. These photocoagulation processes are used in dermatology for the treatment of vascular and pigmented lesions. Recently, techniques have also been proposed involving laser welding on the skin, blood vessels, based on the modifications induced on the collagen fibers due to laser heating at low temperatures (45-50°).

The effects of temperature on various tissue of more than 100°C the effect dominated by the presence of water. We can assume, very qualitatively, that the vaporization process begins at 100 °C, mainly due to the heating of the free water in the tissues. With continuous radiance the tissue heating is characterized by the following:

- Energy absorption due to the transition of the liquid-vapor phase,
- Drying-of-the-tissue.
- Formation of vapor vacuoles inside the tissue, with the consequent rapid expansion of the vapor vacuoles trapped in the tissues.

The damage caused under these conditions, apart from the purely thermal implications, may involve contributions of a mechanical nature, even in the case of continuous laser radiance by means of continuous heating (Cheong *et al.*, 1990; Prahl *et al.*, 1990; Welch *et al.*, 1990).

The macroscopic bubbles (vacuoles) in fact, that are formed in the hottest areas of the tissues underneath the radiated surface, compress the tissue due to the considerable increase in volume associated with



the liquid-vapor transformation - so that they reach a critical pressure at which the thin walls of the vacuoles break that makes them form agglomerates of greater dimensions, thus prolonging the radiance .

The bubbles keep on expanding until an explosive breakage is caused ("pop-corn" effect). The breaking of the vacuoles on the surface allows the aqueous vapor to escape externally, producing a momentary cooling of the surfaces. The histological analysis of the effects induced by the pop-corn effect indicates that the superficial craters produced in this way are not due to a loss of tissue mass but rather to the formation, expansion and breakage of the agglomerates of the vacuoles(Enricowarnt, Tobias Rkiebling, RolandStange et.al,.2014).

The removal of the hot tissue exposes a cooler stratum to the radiance, which remains at approximately 100 °C during the time employed by the radiance to dehydrate the tissue.

The loss of water diminishes the local thermal conductivity and limits the heat conduction to the surrounding areas. Once the water present in the cells has completely evaporated, the tissue temperature rapidly increases to approximately 300°C. The tissue burns and carbonizes. The vaporization together with the carbonization gives rise to the decomposition of the tissue constituents.

#### **2.3.4.3Photomechanical Effects**

Depending on the type of interaction, the pressure wave in the air may be of the acoustic type, in other words low pressure traveling at the

speed of sound, or shock waves, that travel at subsonic speeds and are characterized by a high pressure peak.

The pressure pulses in the tissue are generated during the laser radiance following a rapid local expansion due to induced heating. Under particular conditions, these may also be capable of removing or damaging the tissue they travel through, as happens in the processes photo ablation and photo fragmentation.

## **Chapter three**

### **Experimental part**

#### **3.1 Introduction**

This chapter demonstrates the experimental setup, materials, instruments and experimental procedure that were used during this work.

#### **3.2 Research Methodology**

**Study design:** This is a cross-sectional facility based prospective study.

**Study area:** This is a study conducted at Khartoum State areas. In Aldoha ENT Specialized Hospital

**Study population** the study targeted 10 patients who complain of laryngeal problem

**Inclusion criteria:**

Patients with symptoms and sign of laryngeal disease.

Patient did indirect laryngoscopy

Patients that had persist symptoms in spite medical treatment.

**Exclusion criteria:**

Patients with cardiopulmonary problem or not fit for general anesthesia.

**Data processing and analysis:** Data was collected in master sheets after the filling of each questionnaire. Data was analyzed using analytical computer software use (Microsoft Office Excel 2007).

### 3.3 Materials

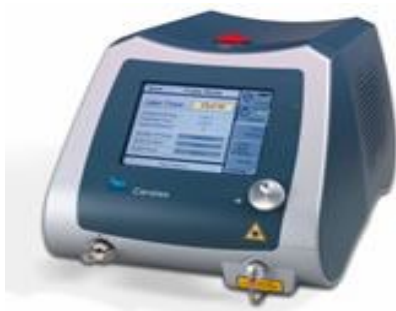Study population: The study targeted 10 patients who complain of laryngeal problem.

Each patient examine preoperatively at clinic and examine by direct larygeoscopy with lens 70, then diagnosis established and other investigation is requested

### 3.4 Method

Each patient underwent operation under general anesthesia, and by use diode laser 980nm .the pathology treated according to condition

**Using thebiolitec 980nm Diode type: Leonardo dual laser**



Power : (8.0-12.0) watt

Treatmentmode: Continues

Wavelength : 980 nm

Fiber diameter : 300  $\mu$ m

The wavelength of 980 nm has a high absorbance in hemoglobin. The thermal penetration depth of the Leonardo DUAL Laser therefore can be adjusted to the needs of the particular ENT application. This allows safe and precise procedures to be performed close to delicate structures while protecting the surrounding tissue.

Compared to the CO<sub>2</sub> laser, this special wavelength set exhibits a significantly better hemostasis and prevents bleeding during the operation, even in hemorrhagic structures such as nasal polyps and hemangioma. With the biolitec® Leonardo DUAL laser system, precise excisions, incisions and vaporization of hyperplastic and tumorous tissue can be performed effectively with almost no side effects.

#### Advantages

Microsurgical precision

Tactile feedback from the laser fiber

Minimal bleeding,

Optimal in situ overview during the operation

Few post-operative measures required

Short recovery period for the patient

## **Chapter four**

### **Result and discussions, conclusions and**

### **Recommendations**

#### **4.1 Introductions**

In this chapter the results of operation is followed immediately and up to 3month after operation. The results analyzed and discussed, comparison between results done.This chapter also include conclusion and recommendations.

#### **4.2 results**

Patient involved in this study their age ranged between (10 to 75) years with (20 or less) 3patients, (41-60) years 3patients, (61-80) years 3patients and one patient over thirty (20-40) years,with mean age of  $44 \pm SD$ , this shown in Table 1.

Male to female ratio 1:1,this shown in Figure 2.

Regarding the symptoms, shortness of breath(S.O.B) is commonest laryngeal symptoms (80%), followed by change of voice 70%, then stridor 60% , lump in throat 30%, sore throat 30% and dysphagia (Figure 3).

Commonest Clinical and pathological finding was masses or swelling found in 5 patient 50%, the first patient diagnosed as carcinoma in situ in left vocal cord after previous history of biopsy taken under general anesthesia, second patient had transglottic mass and fullness patient was received radiotherapy 6month before surgery after diagnosis of carcinoma of larynx, third patient had hypopharyngeal mass that extended to arytenoids area biopsy was taken 2 time by conventional method with no clear diagnosis and diagnosed as hypopharyngeal papillomatosis after laser surgery, the forth patient had fullness and swelling at vocal cord region and extend to subglottic region patient was enter laser section 5 time for debulking after completion of radio chemotherapy as goal to remove the tracheostomy, fifth patient had bilateral sub glottic mass which look like benign condition.

Other finding on clinical ground was laryngeal web found in one patient, bilateral vocal cord paralysis after history of thyroidectomy found in 2 patients, subglottic stenosis found in one patient how had history of cardiac surgery with long intubation in intensive care unit postoperative period, juvenile respiratory papillomatosis found in one patient with papilloma fill anterior commissures and both vocal cord with history of 3 previous operation done conventionally and last one by shaver and all failed and recurrence occur after short period (figure4).

Type of surgery done by laser in this study was total excision of carcinoma in situ, debulking of transglottic tumor with glottic gutter made mainly at left side of v.c to assist breathing and helping for removal of tracheostomy, good and enough biopsy taken after debulking by laser for large hypopharyngeal mass, removal of vocal cord fullness after completion of radio chemotherapy and negative biopsy as trial for weaning from tracheostomy, removal of benign subglottic mass, opening and excision of laryngeal web, right and left partial arytenoidectomy to patients of

bilateral vocal cord paralysis, removal of subglottic stenosis and adhesion with stent used post-operative , total removal of respiratory papilloma .(figure 5)

Parameter that used in biolitec diode type leonardo dual laser adjusted to need of particular ENT application with wavelength 980 nm, power ranging from (8-12) watt ,8 w used for vocal cord pathology in 6 patients, 10 w used for surrounding soft tissue and muscle in 2 patients , 12 w for vaporization of arytenoids cartilage used in 2 patients , 9 w for one patient with fibrosed tissue after radiotherapy, 7 w for web removal used in one patient,The diode laser was utilized both in the "in contact" and in the "not in contact" modality with more in contact type , (Figure 6) all procedure done under general anesthesia , with average time 338.28 second for all operation and 2636.56 joule as average for treatment energy,fiber diameter used was 300  $\mu\text{m}$  .

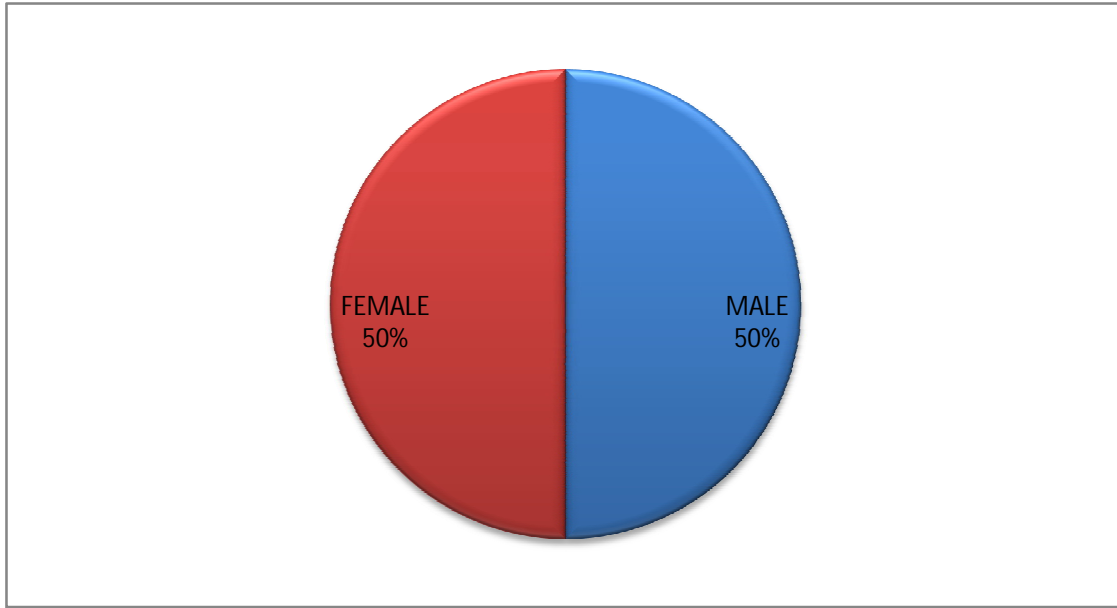
Evaluation to outcome after follow up for 3month , there good breathing for laryngeal web patient, no recurrence for patient with carcinoma in situ ,disappearance of stridor and good breath to patient of benign subglottic mass, reach to diagnosis after enough biopsy and patient receive proper treatment ,decannulation of tracheostomy for patient of partial arytenoidectomy, recurrence of respiratory papillomatosis after removal by laser after 2month ,failure of weaning from tracheostomy after debulking to patient of laryngeal tumor, failure of weaning of patient of subglottic stenosis.

There is no any complication occurred during or after this 10 operation with safty measure done by all staff.

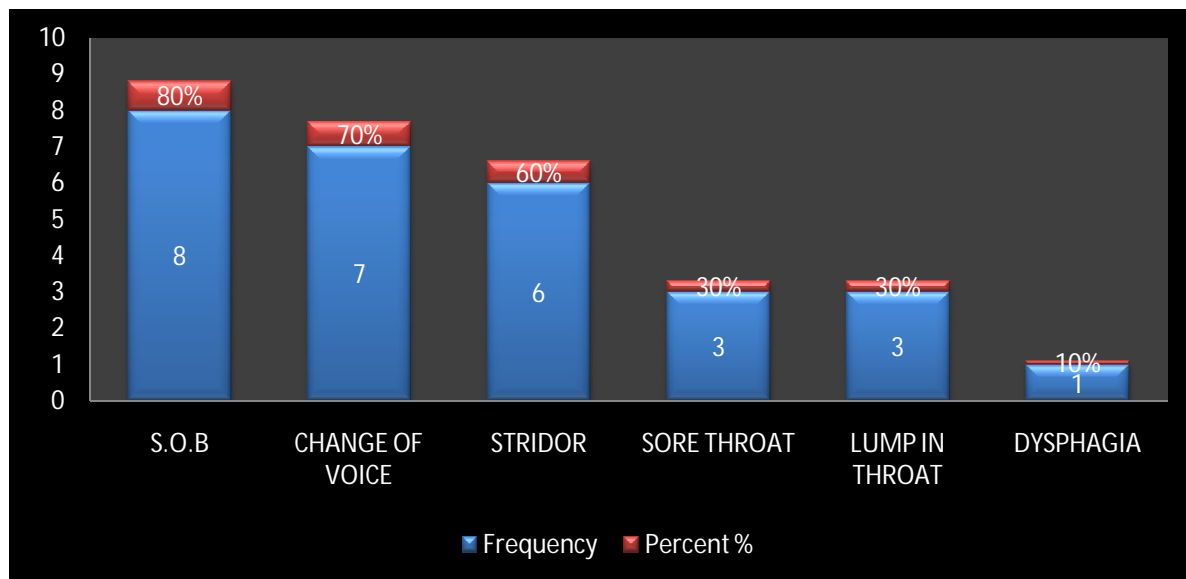


The age	Age groups	Frequency	Percent %
20years and less	First group	3	30%
20-40	Second group	1	10%
41-60	Third group	3	30%
61-80	Fourth group	3	30%
Total		10	100

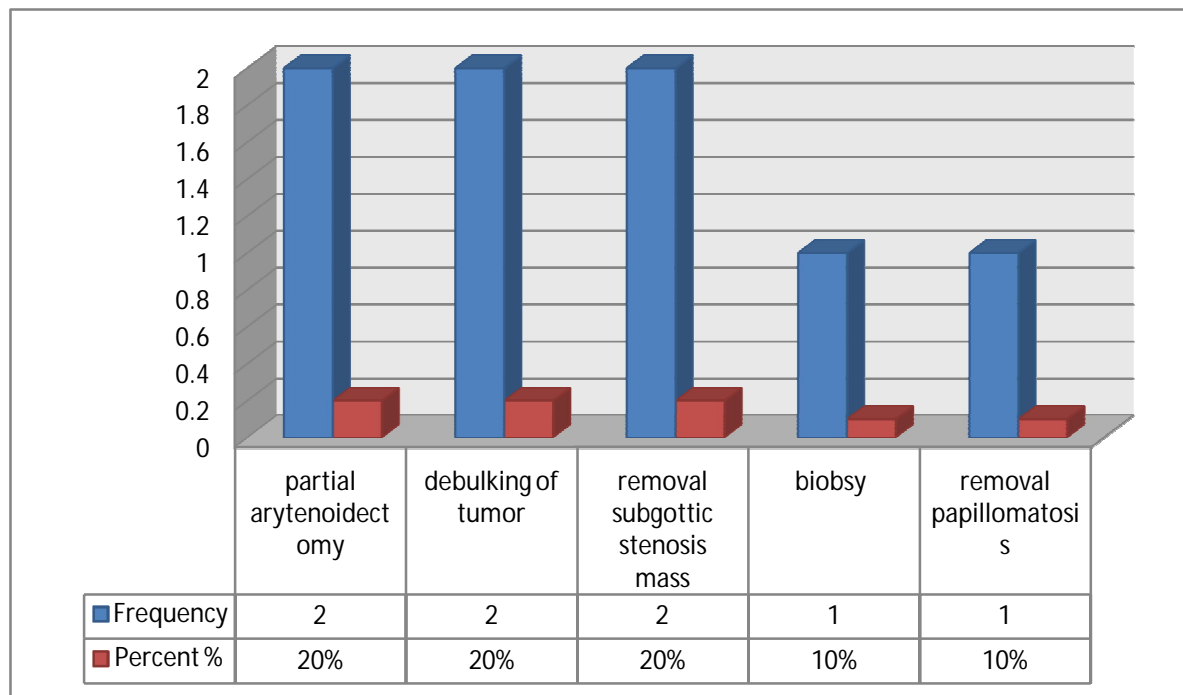
**Table 1:***Distribution of age group*



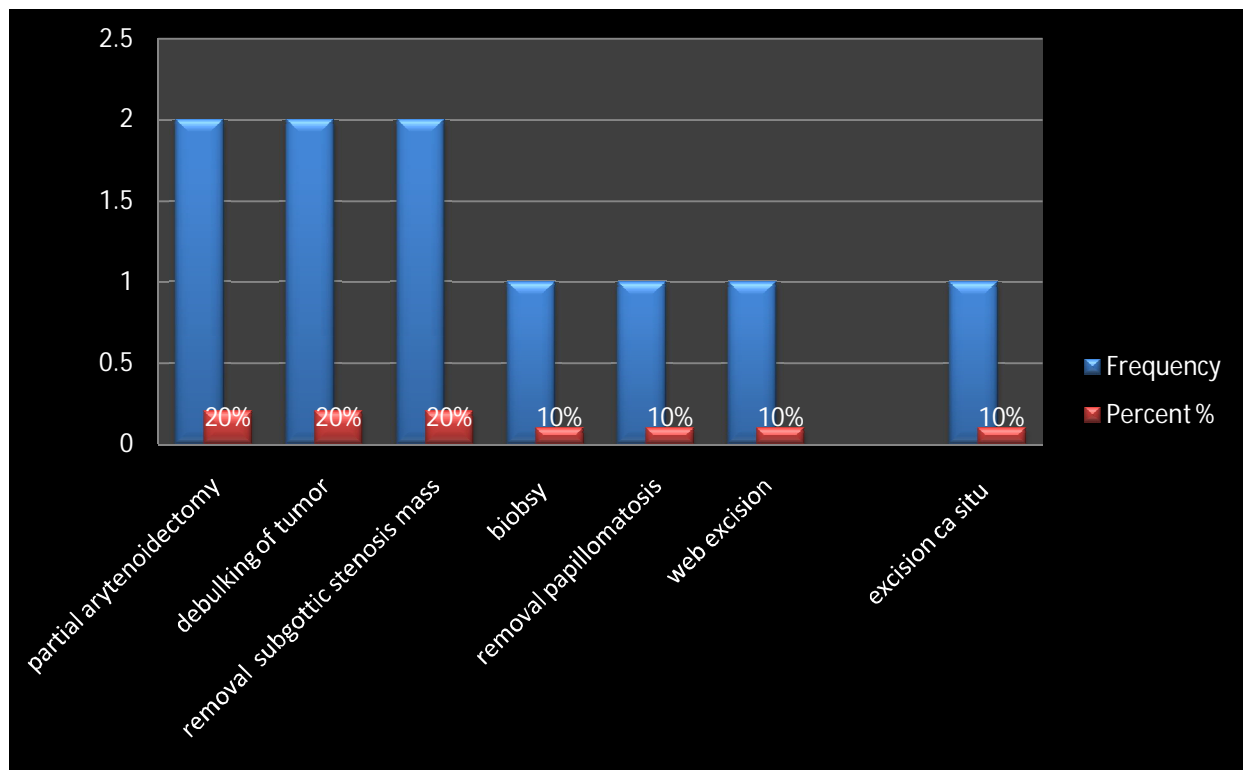
**Fig.1:** *Gender distribution*



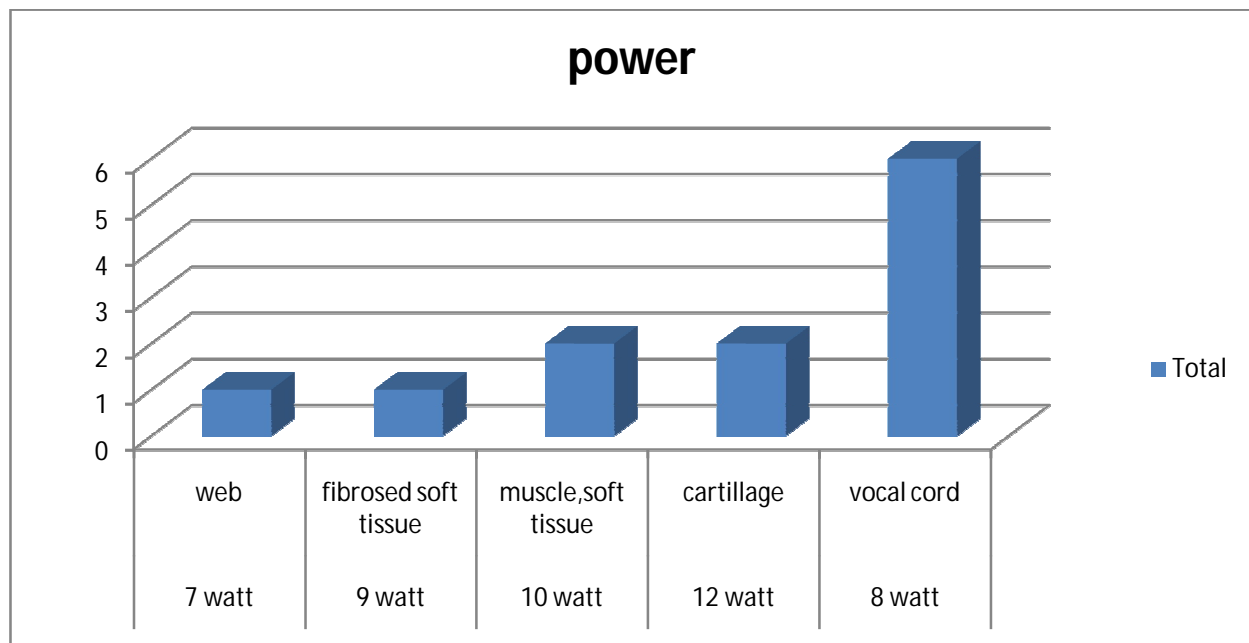
**Fig.2:** Common laryngeal symptoms in patient involved in laryngeal surgery by laser



**Fig.3:**Common clinical finding inpatient underwent laser laryngeal surgery



**Fig.4:**Type of surgery done by laser in larynx in our study



**Fig.5:**power used according to tissue in this study

### 4.3 discussions

In this study the patients age range between 10 years to 75 years so it involve all age group, with 3 patients less than 20 ,so involve younger age if compared with case study done in the Catania University their subjects aged between (32 and 81) years(Salvatore Ferlito,et al.2011).

In our study Male to female ratio 1:1, match with study of fanjul et all in 2008 in spain which include 22 patients, male no.11 female no. 11 with ratio 1:1 (Helena hortzarroyo,et al. 2016).

In our study the diode laser wave length was 980 nm which agree with systemic review inthree studies that used the 980 nm diode laser were among those with a better design in review(Tuncel U, Cömert E.2013). These studies showed good efficacy results and low rates of major complications(Xu W, et al.2007).

The laryngeal pathologies in our study included glottic web, papillomas, glottic carcinoma, bilateral cord palsy, subglottic stenosis and carcinoma in situ .which include most of pathology which cover byhelenahotz in their systemic review (Helena hortzarroyo,et al. 2016).

On the other hand, the 980 nm diode laser has been reported for the treatment of early glottic tumors and vocal fold polyps since 2013(CömertE,et al.2014)(Tunçel U, Cömert E.2013)(Karasu MF, Gundogdu R, Cagli S, et al.2014)as in our study we use 980nm diode laser to excise of early glottic tumor which include carcinoma in situ with good margin and good voice quality and no recurrence after follow up.

The output power in this study ranged from (8-12) watt , 8 w used for vocal cord pathologies , 10 w used for surrounding soft tissue and muscle, 12 w for vaporization of arytenoids cartilage, 9 w fibrosed tissue after radiotherapy, 7 w for web removal , this to some extend with agree with Edizer et al 2013 study that they used power range from 6-12 w, and their minor fiber diameter was 300 µm like our fiber which also 300 µm(Helena hortzarroyo,et al. 2016).

Evaluation ofoutcome after follow up of 3month in this study is good with sufficient result in decanulation of previously tracheotomies patients with bilateral vocal cord palsy this same result in study of saetti et al in 2003 which have same

result(Helena hortzarroyo,et al. 2016)and cure of patient with laryngeal web same result in bajajey al 2008 study.

failure of weaning of our patient of subglottic stenosis and plan for surgical intervention , this also happened in study of fanjul et al 2008 patient had subglottic stenosis, pointed to other treatments (surgical and medical in 87.5% and 12.5% respectively) for resolution(Helena hortzarroyo,et al. 2016).

recurrence of respiratory papillomatosis after removal by laser after 2 month and patient undergone to another session of laser by same parameter and removal of all papilloma , this also occurred in study of bajajey al 2008 their all three respiratory papillomatosis cases reoccurred and undergoing repeated laser and other adjuvant treatments(Helena hortzarroyo,et al. 2016).

failure of weaning from tracheostomy after debulking to patient of laryngeal cancer , to some extend match with study of ferri et al 2008 for glottic cancer managed by diode laser There were 5 recurrences (11.1%): 4 local (8.9%), in which 3 were salvaged, and 1 (2.2%) regional (N2a) with failure of weaning(Helena hortzarroyo,et al. 2016) .

#### **4.4Conclusions**

- 980 nm diode laser seems to be a promising laser device for transoral Laryngeal laser microsurgery.
- Partial arytenoidectomy performed by contact diode laser is an effective and reliable method for the treatment of dyspnea secondary to bilateral laryngeal paralysis.
- Diode laser has good result in managing benign laryngeal lesion.
- Diode laser not very useful in managing advance laryngeal cancer even in salvage and debulking with failure of weaning.
- Diode laser had unpretendingresult in subglottic stenosis and papillomatosis.



- 980nm diode with power 8 watt suitable for vocal cord ,10 w for muscle and surrounding soft tissue 12 w for cartilage .
- Diode laser have low complication intraoperative or postoperative.

#### **4.5 Recommendations**

1. It's recommended for long-term multicenter prospective research to know more about ideal parameter and outcome in use 980 nm diode laser in laryngeal pathology.
2. There should be a high specialist laser center for ENT subspecialty with involvement of all type of laser and different procedure to more advance quality of management and researches.
3. Training for large number of ENT specialist for more evolution in laser ENT specialty in Sudan.
4. Special attention must be given to laser surgery for the treatment of early and advance glottic cancer when use diode laser, once it can be more cost-effective than 'cold surgery' when managing laryngeal tumors, as they allow briefer hospital stays and shorter wound recovery periods .

## *References*

Bajaj Y, Pegg D, Gunasekaran S, Knight L C. Diode laser for paediatric airway procedures: a useful tool. *Int J ClinPract*. 2010; 64(1):51–54.

Benninger MS. Microdissection or microspot CO<sub>2</sub> laser for limited vocal fold benign lesions: a prospective randomized trial. *Laryngoscope* 2000; 110(2 Pt 2, Suppl 92)1-17.

Cömert E, Tunçel Ü, Dizman A, Güney YY. Comparison of early oncological results of diode laser surgery with radiotherapy for early glotticcarcinoma. *Otolaryngol Head Neck Surg* 2014; 150(5):818-823.

Dhar P, Malik A. Anesthesia for laser surgery in ENT and the various ventilatory techniques. *Trends AnaesthCrit Care*. 2011; 1:60–66.

Ferri E, Armato E. Diode laser microsurgery for treatment of Tis and T1 glottic carcinomas. *Am J Otolaryngol*. 2008; 29(2):101–105.

Fanjul M, García-Casillas MA, Parente A, et al. Utilización del láserdiodo en la vía aérea pediátrica. *Cir Pediatr* 2008; 21(2):79-83.

Helena hartz arroyo, Larissa neri, carina Yuri fussuma , rui Imamura, diode laser for laryngeal surgery : systemic review (table 1,2,3) ,hospital das clinicas , brazil ,june 2016,vol no 20.

Karasu MF, Gundogdu R, Cagli S, et al. Comparison of effects on voice of diode laser and cold knife microlaryngology techniques for vocal fold polyps. J Voice 2014; 28(3):387-392.

Lucioni M, Marioni G, Bertolin A, Giacomelli L, Rizzotto G. Glottic laser surgery: outcomes according to 2007 ELS classification. Eur Arch Otorhinolaryngol 2011; 268(12):1771-1778.

Motta G. IL LASER CO<sub>2</sub> nella chirurgia endoscopica della laringe. A.O.O.I, 1995.

Rubinstein M, Armstrong W B. Transoral laser microsurgery for laryngeal cancer: a primer and review of laser dosimetry. Lasers Med Sci. 2011; 26(1):113–124.

Saetti R, Silvestrini M, Cutrone C, Narne S. Treatment of congenital subglottic hemangiomas: our experience compared with reports in the literature. Arch Otolaryngol Head Neck Surg. 2008; 134(8):848–851.

Strong MS, Jako GJ. Laser surgery in the larynx. Early clinical experience with continuous CO<sub>2</sub> laser. Ann OtolRhinolLaryngol 1972; 81(6):791-798.

Saetti R, Silvestrini M, Galiotto M, Derosas F, Narne S. Contact laser surgery in treatment of vocal fold paralysis. Acta Otorhinolaryngol Ital. 2003; 23(1):33–37.

Sullins K E Diode laser and endoscopic laser surgery Vet Clin North Am Small Anim Pract 2002, 323639–648., vii vii .

Salvatore Ferlito, Sebastiano Nane, Caterina Grillo, Marisa Maugeri, Salvatore Cocuzza, Calogero Grillo Università degli Studi di Catania - Dipartimento di Specialità Medico-Chirurgiche - Clinica Otorinolaringoiatrica Acta Medica Mediterranea, 2011, 27: 79.

Vilaseca I, Bernal-Sprekelsen M, Luis Blanch J. Transoral laser microsurgery for T3 laryngeal tumors: Prognostic factors. Head Neck 2010; 32(7):929-938.

Xu W, Han D, Hou L, Zhang L, Yu Z, Huang Z. Voice function following CO<sub>2</sub> laser microsurgery for precancerous and early stage glottic carcinoma. Acta Otolaryngol 2007; 127(6):637-641.

Yan Y, Olszewski AE, Hoffman MR, et al. Use of lasers in laryngeal surgery. J Voice 2010; 24(1):102-109.

# Appendix

## QUESTIONNAIRE

### laser –in microscopic laryngoscopy

Age

Sex                      Male                      ☐

Female                      ☐

Presenting Complain

#### LARYNGEAL SYMPTOMS

Shortness of breath                      ☐

Change of voice                      ☐

Sore throat                      ☐

Stridor                      ☐

Lump in throat

#### HYPOPHARYNGEAL SYMPTOMS

Dysphagia                      ☐

Sore throat                      ☐

#### SOCIAL HABIT

Smoker                      ☐                      alcoholic                      ☐

Snuffing                      ☐                      exposure to specific carcinogen                      ☐

## Examination

Laryngeal

Mass ☐

Vocal cord paralysis ☐

Fullness ☐

Laryngeal crepitus ☐

## Neck examination

Neck mass ☐

Site ☐

Size ☐

Origin ☐

Consistency ☐

Lymph node

primary site of lesion

History of previous surgery

## Type of laser used in this surgery

Power

Treatment mode

Wave length

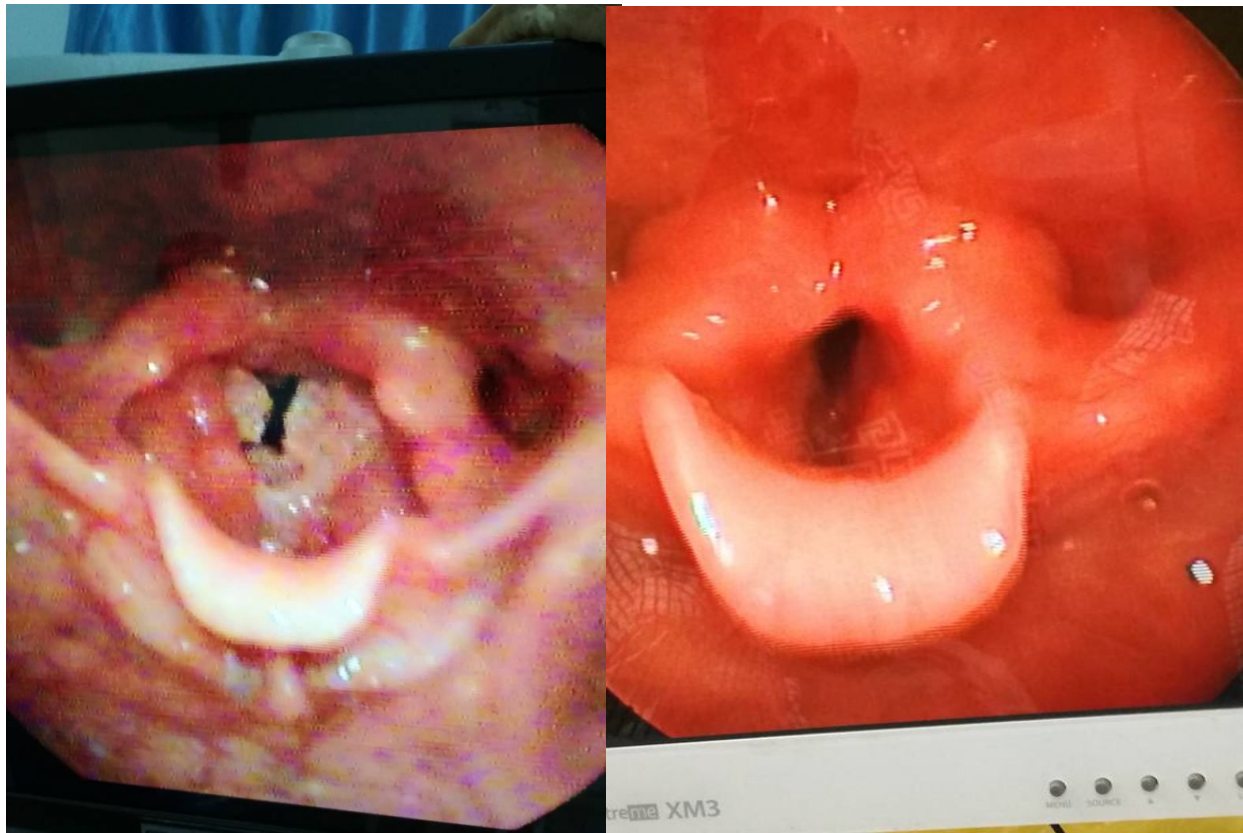
Fiber type exposure time

Postoperative outcome immediately after surgery

post-operative out come after one month

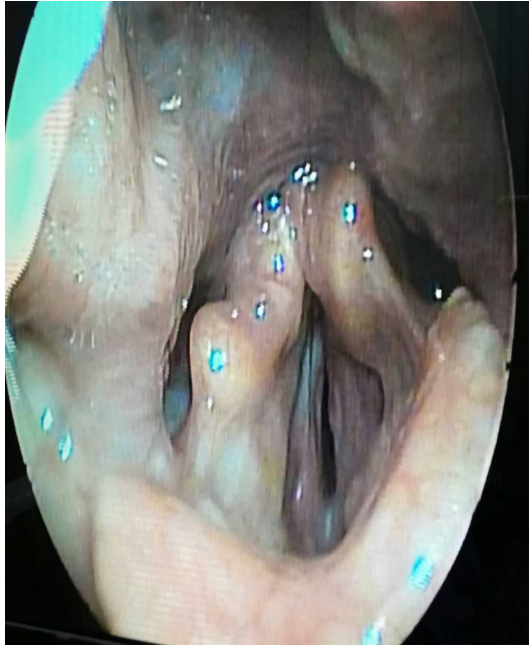
## ***Pictures***



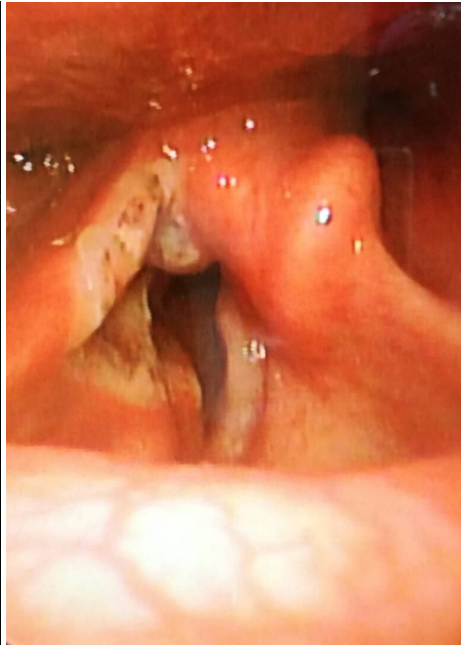

Before laser surgery After laser surgery

## Respiratory papillomatosis

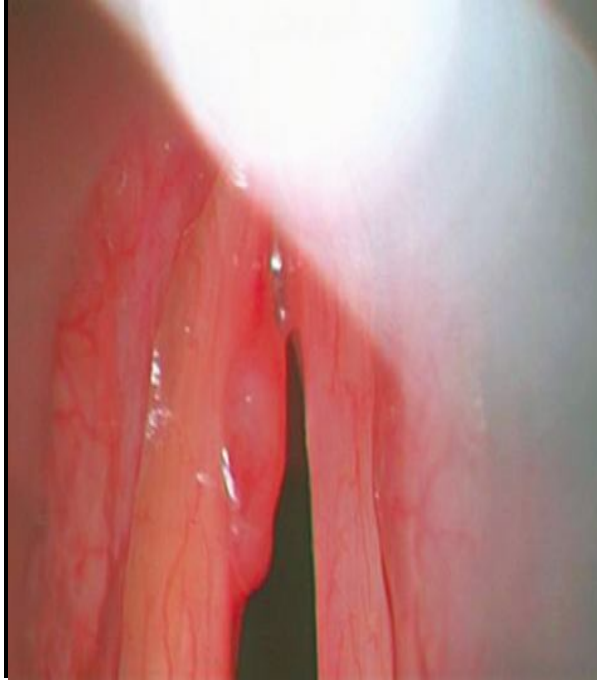


Before laser surgery

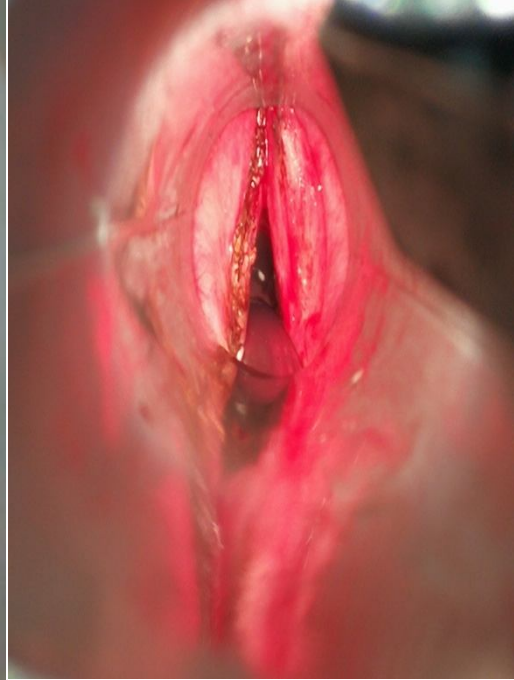


After laser surgery

## Right partial arytenoidectomy



Before laser surgery



After laser surgery

Carcinoma in situ