

CHAPTER ONE

INTRODUCTION

Chapter one

Introduction

1.1 Introduction

Portal hypertension is the most common complication and also one of the important causes of death in chronic liver diseases. Increased resistance to portal blood flow due to alteration of the hepatic architecture leads to dilatation of portal vein, splenomegaly, and formation of oesophageal and gastric varices, variceal haemorrhage, ascites, hypersplenism, encephalopathy, etc. (Bathal PS, *et al* 1985)

In cirrhosis, increased intrahepatic vascular resistance is thought to be located mainly in the hepatic sinusoids. Recent studies have demonstrated that in addition to the increased resistance caused by the morphologic changes of chronic liver diseases, a dynamic component of increased resistance (resulting from the active contraction of vascular smooth muscle cells, myofibroblasts, and hepatic stellate cells) is also present. (Bathal PS, *et al* 1985)

Portal hypertension leads to dilatation of portal vein, splenomegaly, and formation of portal systemic collaterals at different sites. The portal system and the systemic venous circulation are connected at several locations. (Bosch J, *et al*.1989)

Gastro-oesophageal collaterals develop from connections between short gastric and coronary veins and the oesophageal, azygos, and intercostal veins; the result is the formation of oesophageal and gastric varices. Collaterals develop in areas

where anatomic connections exist between the portal venous and systemic circulation. (Bosch J, *et al.*1989)

These are vascular channels that are functionally closed in normal conditions but become dilated in portal hypertension as a consequence of increased intravascular pressure and blood flow. . (Bosch J, *et al.*1989)

These gastro-oesophageal varices are responsible for the main complications of portal hypertension and massive upper GI bleeding. It is a well-known fact that portal vein diameter is usually increased in cirrhosis of liver with portal hypertension, and spleen is also enlarged in size. . (Bosch J, *et al.*1989)

1.2 Problem of study:

Portal hypertension is the most common complication and also one of the important causes of death in chronic liver diseases. So by measuring the diameter of the portal vein by real time sonography in Sudanese population, can estimate reference value in different age group and gender.

1.3 Study Justification:

Portal vein diameter is important in diagnosis of portal hypertension. This study was conducted to find out the correlation of portal vein diameter in Sudanese population with different age group and gender.

1.4 Research questions:

What is normal portal vein diameter?

Does age affected the diameter of the portal vein?

Does gender affected the diameter of the vein?

1.5 Aim & Objectives

1.5.1 General objective:

Measure the diameter of the portal vein by real time sonography in Sudanese population.

1.5.2 Specific objective:

1. To measure the mean diameter of portal vein.
2. To estimate reference value of portal vein diameter for Sudanese.
3. To correlate the mean diameter of portal vein with age.
4. To correlate the mean portal vein diameter with gender.

1.5 Over view of study :

This study consisted of five chapters, with chapter one is an introduction which includes; problem of the study, question study objective and significance of the study. Chapter tow well present comprehensive literature review about different measurement studies, while chapter three is a methodology which include

material used to collect the data and method of data acquisition and analysis. Chapter four includes presentation of the result using tables and figures, finally chapter five included discussion, conclusion and recommendation.

CHAPTER TWO

LITERATURE REVIEW

Chapter two

Literature review

2.1 Portal vein anatomy

The portal vein or hepatic portal vein is a [blood vessel](#) that carries blood from the [gastrointestinal tract](#) and [spleen](#) to the [liver](#). This blood is rich in nutrients that have been extracted from food, and the liver processes these nutrients; it also filters toxins that may have been ingested with the food. 75% of total liver blood flow is through the portal vein, with the remainder coming from the [hepatic artery proper](#). The blood leaves the liver to the heart in the [hepatic veins](#). (Henry Gray *et al* 1901)

The portal vein is not a true [vein](#), because it conducts blood to [capillary](#) beds in the liver and not directly to the heart. It is a major component of the [hepatic portal system](#), one of only two

portal venous systems in the body - with the hypophyseal portal system being the other. (Henry Gray et al 1901)

Conditions involving the portal vein cause considerable illness and death. An important example of such a condition is elevated [blood pressure](#) in the portal vein. This condition, called [portal hypertension](#), is a major complication of [cirrhosis](#). (Henry Gray et al/ 1901)

Figure (2.1): The **portal vein** and its tributaries. (www.wikipedia.org)

2.1.1 Structure of portal vein

Measuring approximately 8 cm (3 inches) in adults, the portal vein is located in the [right upper quadrant](#) of the abdomen, originating behind the neck of the [pancreas](#). (*Harold M, al 2008*)

In most individuals, the portal vein is formed by the union of the [superior mesenteric vein](#) and the [splenic vein](#). For this reason, the portal vein is occasionally called the splenic-mesenteric confluence. Occasionally, the portal vein also directly communicates with the [inferior mesenteric vein](#), although this is highly variable. Other tributaries of the portal vein include the [cystic](#) and [gastric veins](#). (Plinio Rossi, *et al* 2000) (Benjamin L, *et al* 2008)

Immediately before reaching the liver, the portal vein divides into right and left. It ramifies further, forming smaller venous branches and ultimately portal venules. Each portal venule courses alongside a hepatic arteriole and the two vessels form the vascular components of the [portal triad](#). These vessels ultimately empty into the [hepatic sinusoids](#) to supply blood to the liver. (Henry Gray *et al* 1901)

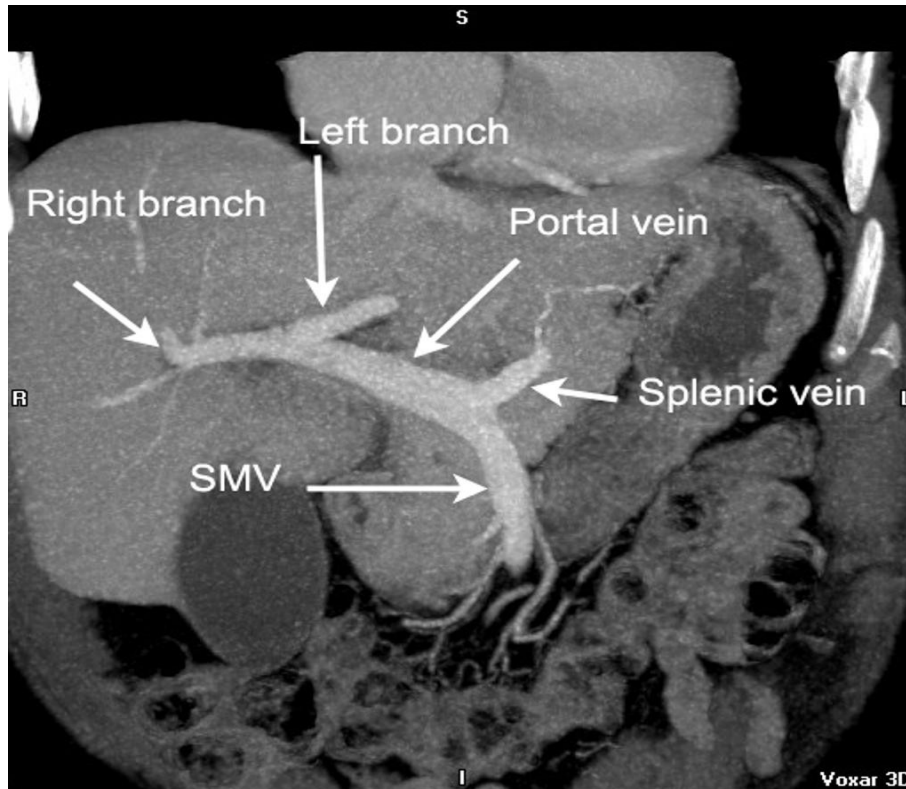


Figure (2.2): Coronal CT abdomen Porto-venous phase.
<http://radiopaedia.org>

2.1.2 Accessory hepatic portal veins

Accessory hepatic portal veins are those veins that drain directly into the liver without joining the hepatic portal vein. These include the [paraumbilical veins](#) as well as veins of the [lesser omentum](#), [falciform ligament](#), and those draining the [gallbladder](#) wall. (*Plinio Rossi, et al 2000*)

2.2 Portal vein function

The portal vein and [hepatic arteries](#) form the liver's dual blood supply. Approximately 75% of hepatic blood flow is derived from the portal vein, while the remainder is from the hepatic arteries. (*Plinio Rossi, et al 2000*)

Unlike most veins, the portal vein does not drain into the [heart](#). Rather, it is part of a [portal venous system](#) that delivers venous blood into another [capillary system](#), the [hepatic sinusoids](#) of the liver. In carrying venous blood from the gastrointestinal tract to the liver, the portal vein accomplishes two tasks: it supplies the liver with metabolic substrates and it ensures that substances ingested are first processed by the liver before reaching the [systemic circulation](#). (*Plinio Rossi, et al 2000*)

This accomplishes two things. First, possible toxins that may be ingested can be detoxified by the hepatocytes before they are released into the systemic circulation. Second, the liver is the first organ to absorb nutrients just taken in by the intestines. After draining into the liver sinusoids, blood from the liver is drained by the [hepatic vein](#). (*Plinio Rossi, et al 2000*)

2.3 Hepatic portal system

In [human anatomy](#), the hepatic portal system is the system of [veins](#) comprising the [hepatic portal vein](#) and its tributaries. It is also called the portal venous system, although it is not the only example of a [portal venous system](#), and splanchnic veins, which is not [synonymous](#) with hepatic portal system and is imprecise (as it means [visceral](#) veins and not necessarily the veins of the [abdominal](#) viscera). (<http://cancerweb.ncl.ac.uk>)

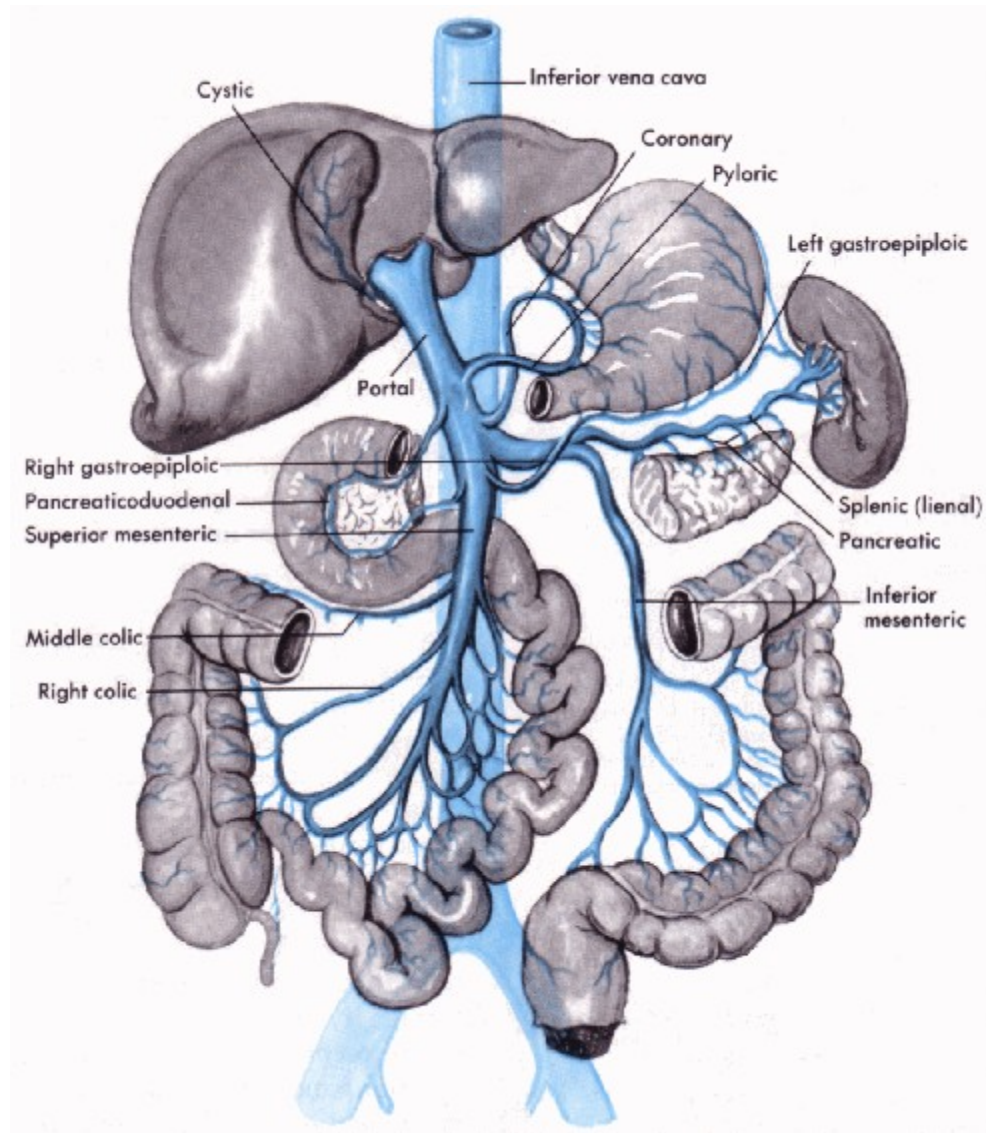


Figure (2.3): The portal vein and its tributaries.
<http://www.daviddarling.info>

2.3.1 Function

The portal venous system is responsible for directing blood from parts of the [gastrointestinal tract](#) to the [liver](#). Substances absorbed in the small intestine travel first to the liver for processing before continuing to the heart. Not all of the [gastrointestinal tract](#) is part of this system. The system extends from about the lower portion of the [esophagus](#) to the upper part

of the [anal canal](#). It also includes venous drainage from the [spleen](#) and [pancreas](#). (<http://cancerweb.ncl.ac.uk>)

Many drugs that are absorbed through the [GI tract](#) are substantially metabolized by the liver before reaching general circulation. This is known as the [first pass effect](#). As a consequence, certain drugs can only be taken via certain routes. (<http://cancerweb.ncl.ac.uk>)

For example, [nitroglycerin](#) cannot be swallowed because the liver would inactivate the medication, but it can be taken [under the tongue](#) or transdermal (through the skin) and thus is absorbed in a way that bypasses the portal venous system. Inversely, [dextromethorphan](#), a cough suppressor, is best taken orally because it needs to be metabolised by the liver into [dextrorphan](#) in order to be effective. (<http://cancerweb.ncl.ac.uk>)

This latter principle is that of most [prodrugs](#). The use of [suppositories](#) is a way to by-pass partially the [portal vein](#): the upper 1/3 of the [rectum](#) is drained into the [portal vein](#) while the lower 2/3 are drained into the [internal iliac vein](#) that goes directly in the [inferior vena cava](#) (thus by-passing the liver). (<http://cancerweb.ncl.ac.uk>)

Blood flow to the liver is unique in that it receives both oxygenated and (partially) deoxygenated blood. As a result, the [partial gas pressure](#) of oxygen (pO_2) and perfusion pressure of portal blood are lower than in other organs of the body. (<http://cancerweb.ncl.ac.uk>)

Blood passes from branches of the portal vein through cavities between "plates" of [hepatocytes](#) called [sinusoids](#). Blood also flows from branches of the [hepatic artery](#) and mixes in the sinusoids to supply the hepatocytes with oxygen. This mixture [percolates](#) through the sinusoids and collects in a central vein which drains into the [hepatic vein](#). (<http://cancerweb.ncl.ac.uk>)

The hepatic vein subsequently drains into the [inferior vena cava](#). The [hepatic artery](#) provides 30 to 40% of the oxygen to the liver, while only accounting for 25% of the total liver blood flow. The rest comes from the partially deoxygenated blood from the [portal vein](#). The liver consumes about 20% of the total body oxygen when at rest. That is why the total liver blood flow is quite high, at about 1 liter a minute and up to two liters a minute. That is on average one fourth of the average [cardiac output](#) at rest. (<http://cancerweb.ncl.ac.uk>)

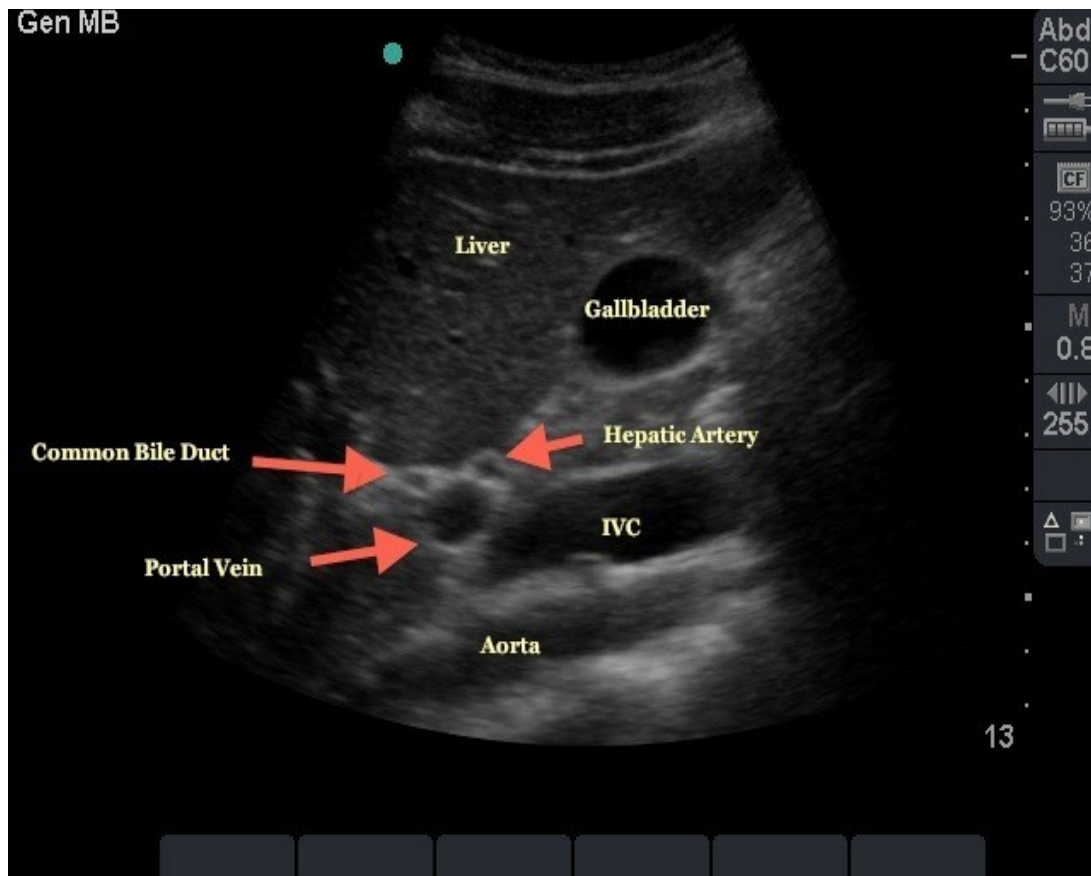


Figure (2.4): "Mickey Mouse" view of Portal Triad.
<http://www.em.emory.edu>

2.4 **Ultrasound**

Ultrasounds are [sound waves](#) with [frequencies](#) higher than the upper audible limit of human [hearing](#). Ultrasound is no different from 'normal' (audible) sound in its physical properties, except in that humans cannot hear it. This limit varies from person to person and is approximately 20 [kilohertz](#) (20,000 hertz) in healthy, young adults. Ultrasound devices operate with frequencies from 20 kHz up to several gigahertz. (Novelline, Robert, et al 1997)

Ultrasound is used in many different fields. Ultrasonic devices are used to detect objects and measure distances. [Ultrasound imaging](#) or sonography is often used in [medicine](#). In the [nondestructive testing](#) of products and structures, ultrasound is used to detect invisible flaws. Industrially, ultrasound is used for cleaning, mixing, and to accelerate chemical processes. Animals such as [bats](#) and [porpoises](#) use ultrasound for locating [prey](#) and obstacles. (Novelline, Robert, et al 1997)

2.4.1 Modes of sonography

Several modes of ultrasound are used in medical imaging. These are:

A-mode: A-mode (amplitude mode) is the simplest type of ultrasound. A single transducer scans a line through the body with the echoes plotted on screen as a function of depth. Therapeutic ultrasound aimed at a specific tumor or calculus is also A-mode, to allow for pinpoint accurate focus of the destructive wave energy. (Cobbold, et al 2007)

B-mode or 2D mode: In B-mode (brightness mode) ultrasound, a linear array of transducers simultaneously scans a plane through the body that can be viewed as a two-dimensional image on screen. More commonly known as 2D mode now. (Cobbold, et al 2007)

C-mode: A C-mode image is formed in a plane normal to a B-mode image. A gate that selects data from a specific depth from an A-mode line is used; then the transducer is moved in the 2D plane to sample the entire region at this fixed depth. When the transducer traverses the area in a spiral, an area of 100 cm² can be scanned in around 10 seconds. (Cobbold, et al 2007)

M-mode: In M-mode (motion mode) ultrasound, pulses are emitted in quick succession – each time, either an A-mode or B-mode image is taken. Over time, this is analogous to recording a

video in ultrasound. As the organ boundaries that produce reflections move relative to the probe, this can be used to determine the velocity of specific organ structures. (*Cobbold, et al 2007*)

Doppler mode: This mode makes use of the Doppler Effect in measuring and visualizing blood flow

Color Doppler: Velocity information is presented as a color-coded overlay on top of a B-mode image

Continuous Doppler: Doppler information is sampled along a line through the body, and all velocities detected at each time point are presented (on a time line)

Pulsed wave (PW) Doppler: Doppler information is sampled from only a small sample volume (defined in 2D image), and presented on a timeline

Duplex: a common name for the simultaneous presentation of 2D and (usually) PW Doppler information. (Using modern ultrasound machines, color Doppler is almost always also used; hence the alternative name Triplex. (*Cobbold, et al 2007*))

2.4.2 Abdominal ultrasonography

Abdominal ultrasonography (also called abdominal ultrasound imaging or abdominal sonography) is a form of [medical ultrasonography](#) ([medical](#) application of [ultrasound](#) technology) to visualise [abdominal anatomical](#) structures. (*Bisset et al January 2008*)

It uses transmission and reflection of ultrasound waves to visualise internal organs through the [abdominal wall](#) (with the help of gel which helps transmission of the sound waves). For this reason, the procedure is also called a transabdominal ultrasound, in contrast with [endoscopic ultrasound](#), the latter combining ultrasound with [endoscopy](#) through visualize internal structures from within hollow organs. (Bisset *et al* January 2008)

Abdominal ultrasound examinations are performed by [gastroenterologists](#) or certain other specialists in [internal medicine](#), [radiologists](#) or [sonographers](#) trained for this procedure. (Bisset *et al* January 2008)

2.5 Portal Veins

The main portal vein enters the liver at the porta hepatis, also referred to as the liver hilum. The portal vein provides the liver with approximately 70% of its total blood supply. (Nyberg D, *et al* 2003)

The blood within the portal vein is partially oxygenated, as it is derived from the intestines. The remainder of hepatic perfusion is via the hepatic artery. As the main portal vein enters the liver, it splits into the right and left portal veins. (Nyberg D, *et al* 2003)

The right portal vein, like the right hepatic lobe, is separated into an anterior and posterior division. The left portal vein, like the left hepatic lobe, is separated into a medial and lateral division. These vessels supply blood to their related segments. (Nyberg D, *et al* 2003)

The diameter of the main portal vein can vary with respiration, although typically it measures less than 13 mm in the anteroposterior dimension. Enlargement of the portal vein is indicative of portal hypertension. (Nyberg D, *et al* 2003)

Normal portal veins decrease in size as they approach the diaphragm. They are also considered intrasegmental because they course within the segments of the liver. (Curry R, *et al* 2004)

On a sonogram, their walls appear much brighter than those of the hepatic veins. This may be because of an increase in the amount of collagen within their walls compared with the hepatic veins. (Curry R, *et al* 2004)

Normal flow within the portal veins should be hepatopetal and monophasic, with some variation noted with respiratory changes and after meals. (Curry R, *et al* 2004)

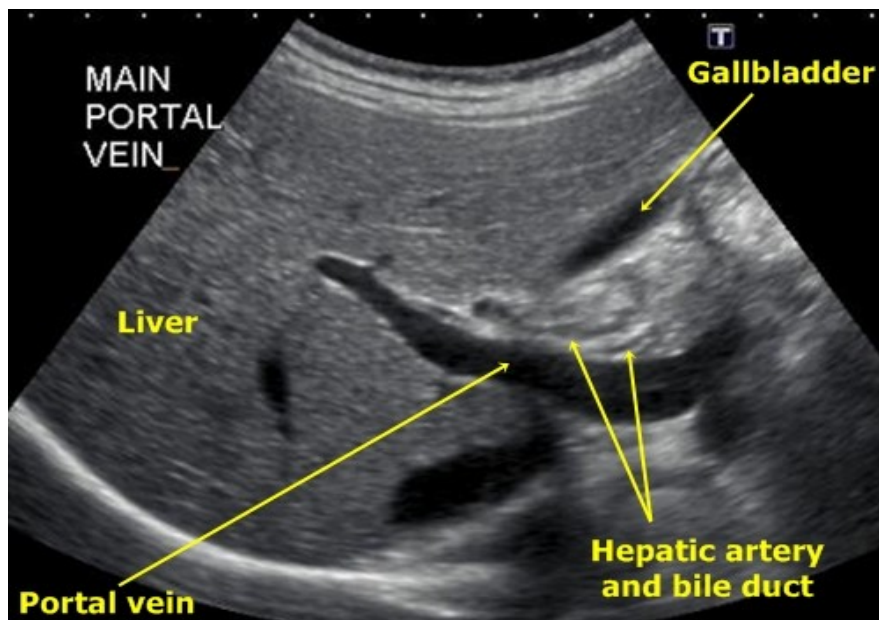


Figure (2.5): Portal vein entering the liver. {<http://www.stefajir.cz>}

2.5.1 Portal vein diameter measurement

The portal venous supply for the left lobe can be visualized using an oblique, cranially angled sub-xiphoid view (recurrent subcostal oblique projection). The main and right portal veins are best seen in a sagittal or oblique sagittal plane. (Lafortune M, *et al* 1991)

In normal individuals, the portal vein diameter does not exceed 13 mm in quiet respiration, measured where the portal vein crosses anterior to the IVC. This assessment is usually conducted with ultrasound views along the long axis of the portal vein. (Bolondi L, *et al* 1984)

Respiration and patient position greatly affect the size of the portal vein and its tributaries; therefore, diagnostic measurements must be standardized by examining the patient in the supine position and in a state of quiet respiration. (Bolondi L, Gamrolfi L, *et al* 1982)

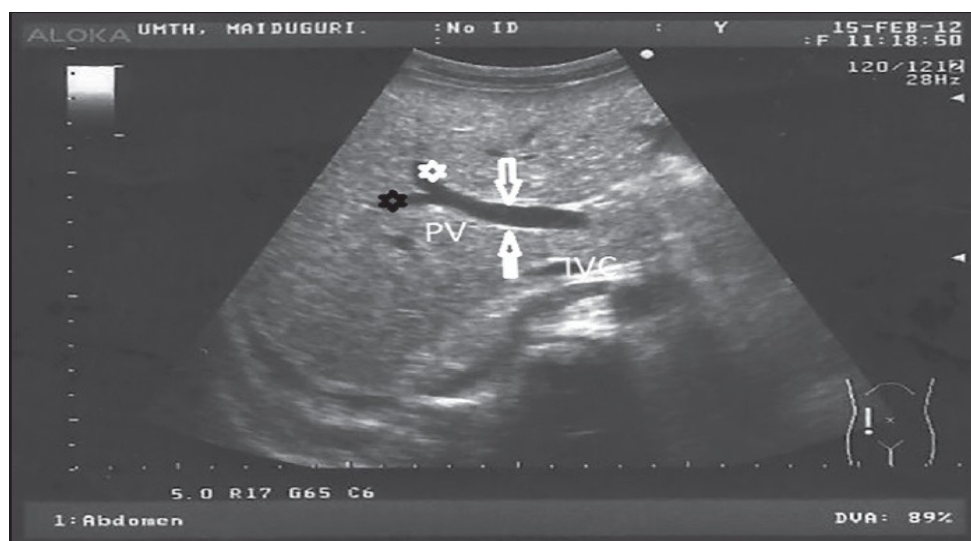


Figure (2.6): Longitudinal view of the abdomen showing the levels of measurement of the portal vein (PV) (white arrows), right PV (black star), and left PV (white star). IVC represents the inferior vena cava. {<http://www.ssajm.org>}

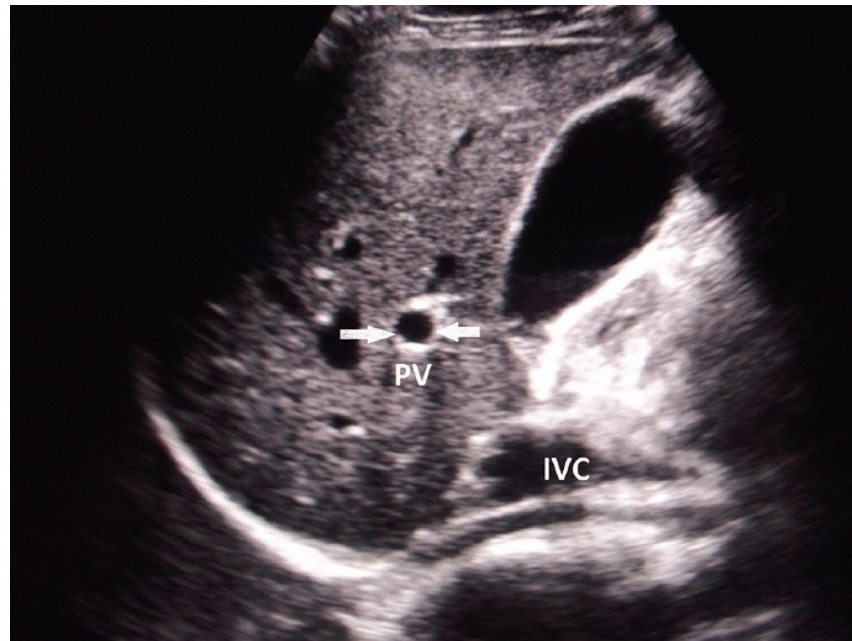


Figure (2.7): Transverse view of the portal vein showing the levels of measurement (white arrows). IVC represents the inferior vena cava. {<http://www.ssajm.org>}

2.5.2 Portal Veins Doppler

In terms of complexity, the portal venous waveform is somewhere between those of the hepatic artery and hepatic veins. A model for understanding portal venous flow requires accepting two pieces of information. (Abu-Yousef MM, *et al* 1992)

First, physiologic flow should always be antegrade, which is toward the transducer and therefore creates a waveform that is above the baseline. Second, hepatic venous pulsatility is partially transmitted to the portal veins through the hepatic sinusoids,

which accounts for the cardiac variability seen in this waveform. It should also be kept in mind that the flow velocity in this vessel is relatively low (16–40 cm/sec) compared with that in the vessel coursing next to it, namely, the hepatic artery. (Abu-Yousef MM, *et al* 1992)

The normal portal venous waveform should gently undulate and always remain above the baseline. The peak portal velocity (V_1) corresponds to systole, and the trough velocity (V_2) corresponds to end diastole. At first, one may incorrectly reason that systole should cause back pressure and create the trough; however, such is not the case. (Abu-Yousef MM, *et al* 1992)

The primary influence on variation in portal venous pressure is atrial contraction, which occurs at end diastole. Atrial contraction, toward end diastole, transmits back pressure, first through the hepatic veins, then to the hepatic sinusoids, and ultimately to the portal circulation, where forward portal venous flow (velocity) is consequently decreased (the trough). (Abu-Yousef MM, *et al* 1992)

In fact, prior studies of patients with increased portal venous pulsatility secondary to tricuspid regurgitation have noted that the portal venous waveform resembles an inverted hepatic venous waveform. Therefore, at end diastole, the atrium contracts and the portal venous waveform reaches a low point (trough). (Abu-Yousef MM, *et al* 1992)

The degree of undulation is highly variable but may be quantified with a PI. It is important to note that the PI calculation for the portal vein is different from that for the hepatic arteries (arterial

$PI = (V_1 - V_2) / M_{ean}$). In the portal veins, the PI is calculated as V_2 / V_1 , with V_1 normally being greater than 0.5. (Abu-Yousef MM, *et al* 1992)

Abnormal (pathologic) portal venous flow usually manifests in one of four ways:

Increased pulsatility (pulsatile waveform). As mentioned earlier, the normal portal venous waveform is described as phasic; therefore, the word pulsatile is reserved for describing pathologic flow in portal veins. Pulsatile portal venous flow occurs when there is a large difference between flow velocity at peak systole and at end diastole. (Owen C, *et al* 2006)

Slow portal venous flow .Abnormally slow flow occurs when back pressure limits forward velocity. Slow flow is diagnostic for portal hypertension, which is diagnosed when peak velocity is less than 16 cm/sec. Portal hypertension is caused by cirrhosis in the vast majority of cases; however, the exhaustive list of causes is generally divided into prehepatic (eg, portal vein thrombosis), intrahepatic (eg, cirrhosis from any cause), and posthepatic (right-sided heart failure, tricuspid regurgitation, Budd-Chiari syndrome) causes. (Owen C, *et al* 2006)

Hepatofugal (retrograde) flow. Hepatofugal flow occurs when back pressure exceeds forward pressure, with flow subsequently reversing direction. This results in a waveform that is below the baseline. As with slow flow, this finding is diagnostic for portal hypertension from whatever cause. (Owen C, *et al* 2006)

Absent (aphasic) portal venous flow. Absent flow in the portal vein may be due to stagnant flow (portal hypertension) or occlusive disease, usually caused by bland or malignant thrombosis. Although absent portal venous flow is the sine qua non of occlusive portal vein thrombosis, it must be remembered that intraluminal filling defects may also be nonocclusive if they fail to occupy the entire lumen. In such cases, there will be some degree of flow, which may be increased at the stenosis, turbulent immediately beyond the stenosis, or decreased farther downstream, in the poststenotic portion of the vessel. (Owen C, *et al* 2006)

2.6 Previous study

Weinreb et al, was found in 21 pt aged 0-10 yr, the mean diameter of portal vein was 8.5 ± 2.7 mm. In 20 pt aged 11-20 yr the mean diameter was 10 ± 2 mm. In 49 pt aged 21-30 yr the mean diameter was 11 ± 2 mm. In 58 pt aged 31-40 yr the mean diameter was 11 ± 2 mm. The overall mean diameter in 107 pt was 11 ± 2 mm. And there was no difference between male and female pt.

Tanya Raza Siddiqui et al, study the Impact of anthropometrical parameters on portal vein diameter and liver size in a subset of Karachi based population. Four hundred and fifty nine apparently healthy subjects were included in this cross sectional study. After recording weight and height of each subject,

Portal vein diameter and both liver lobes were measured by gray scale ultrasonography. Students T test and ANOVA were applied for statistical analyses.

With increasing age, portal vein diameter and right lobe of liver increased significantly (p value < 0.001). Increase in portal vein diameter was also observed with rise in body mass index (0.8 cm in underweight - 1.1 cm in obese subjects). Sizes of right and left liver lobes also increased with a rise in body mass index (p value < 0.001 and 0.001). Gender, however, did not have any effect on portal vein diameter and liver size.

Age and body mass index are reliable parameters to consider for avoiding false positive diagnosis of hepatomegaly and portal hypertension. Knowing the right and left liver size with respect to anthropometrical measurements also assist a clinician in selecting a subject for liver transplantation.

Brown HS, et al. The volume flow rate of blood in the portal vein was measured using a duplex ultrasound system. The many errors inherent in the duplex method were assessed with particular reference to the portal vein and appropriate correction factors were obtained by in vitro calibration.

The effect of posture on flow was investigated by examining 45 healthy volunteers in three different positions; standing, supine and tilted head down at 20 degrees from the horizontal. The mean volume blood flow in the supine position was 864 (188)ml/min (mean 1SD). When standing, the mean volume blood

flow was significantly reduced by 26% to 662 (169) ml/min. There was, however, no significant difference between flow when supine and when tilted head down at 20 degrees from the horizontal.

Martínez-Hernández FJ, et al. The portal vein was measured in 244 children from under a year old to 18 years of age in order to have normal measurement values for the vein according to age groups. No tables seem to be available containing this information. From the group, 164 patients were selected and were placed in six different groups according to their ages. The tables show the values obtained a percentile curve, averages with standard deviations and ranges.

Ghosh T, et al. Total 306 healthy children between the age of < 1 month and 12 years, visiting our outpatient department or accompanying their siblings were enrolled in the study. The children were distributed into ten age-groups. Each group was further divided in two sub-groups based on gender. Anthropometric parameters including weight, height and chest circumference were measured. Portal vein diameter was assessed by ultrasonography.

The portal vein diameter increases with age, height, weight and chest circumference. But the values are similar in boys and girls. Multiple logistic regression (adjusted R- square: 0.922) revealed age ($p = 0.002$), height/length ($p < 0.0001$), weight ($p = 0.011$), and chest circumference ($p < 0.0001$), as independent determinants of portal vein diameter. However, height/length emerged as the most consistent determinant (coefficient of

regression: 1.536; $p < 0.001$; 95% confidence interval: 0.066-0.092).

Results provide a normal range of portal vein diameter according to age, gender and anthropometric parameters. They conclude that portal vein diameter strongly correlates with age and anthropometric variables like height, weight and chest circumference, with height being the strongest determinant.

Aminu Umar Usman, et al. Study the Ultrasound Determination of Portal Vein Diameter in Adult Patients with Chronic Liver Disease in North-Eastern Nigeria. This cross-sectional prospective study was carried out at the University of Maiduguri Teaching Hospital between January and June, 2013.

Two hundred and fifty adult male and female CLD patients and equal number of age and sex matched controls aged 18 years and above had abdominal ultrasonography for measurement of their main, right and left PV diameter in both inspiration and expiration. Transverse and longitudinal measurements were obtained, and the averages of the two measurements were used to determine their final diameter.

There were 187 (74.8%) male and 63 (25.2%) female CLD patients aged between 19 and 77 years (mean \pm standard deviation [SD], 43.78 ± 12.97 years). The mean diameter of the main PV (\pm SD) in CLD was 18.68 ± 2.59 mm which is higher than that of the control (10.87 ± 0.81 mm). The mean diameter of the right and left PVs in CLD were 9.04 ± 1.26 mm and 8.58 ± 1.23 mm respectively, which were higher than the respective values of

4.35 \pm 0.52 mm and 4.12 \pm 0.52 mm in the control. The PV diameter correlated with age and respiratory phases in both CLD and the control group ($P < 0.05$). There was statistically significant difference in PV diameter between males and females ($P < 0.05$) with values higher in females.

CHAPTER THREE

MATERIALS AND METHODS

Chapter three

Materials and Methods

3.1 Materials

3.1.1 Sample size and sampling

Sample was number of 100 Sudanese patients admitting to all flowing hospitals for abdominal ultrasound scan. Or normal individuals aged between 18-65 yrs, female 53 and male 47.

3.1.2 Study area and Ultrasound machines used

The study was conducted in Khartoum state, including hospitals:

1. Alakadimy teaching hospital. Toshiba xario 100 (USA 2011).
2. Dar el elaj specialist hospital. Philips (German 2010).
3. Alenjaz Sudanese-German hospital. Philips (German 2010).
4. Aliaa specialist hospital. Toshiba xario 100 (USA 2011).
5. Yastbshron hospital. Toshiba xario 100 (USA 2011).

All machines used with 3.5 MHz curvilinear transducer.

3.2 Methods

3.2.1 Methodology

Number of 100 abdominal ultrasound was performed for Sudanese patient aged between 18-65 yrs. The age grouped to six groups as flow ([18-25], [26-33], [34-41], [42-49], [50-57] and [58-60]), with commercially available real time machine using a 3.5 MHz transducer.

3.2.2 Technique

The main portal vein is scanned in a sagittal or oblique sagittal plane and the mean of main portal vein diameter was calculated from three measurements for each patient. The patients were scanned in the supine position and in a state of quiet respiration.

3.2.3 Study design

Descriptive, measurementive and analytical study.

3.2.4 Inclusion criteria:

1. Sudanese patient.
2. Aged between 18-65 yrs.
3. Patient have ultrasound scan.
4. Absence of biliary, liver and cardiac diseases.

3.2.5 Exclusion criteria:

1. Patient with biliary, liver and cardiac diseases.
2. Hypertensive and diabetic patient.

3.2.6 Data collection & Analysis

Data will collect randomly and statistical analysis will be conducted using Statistical Package for Social Sciences (SPSS), where t student test and correlation test are used for analysis.

3.2.7 Ethical Consideration

Informed consent obtained by chief of radiology department for each hospital.

CHAPTER FOUR

RESULT

Chapter four

Result

Number of 100 abdominal ultrasound was performed for Sudanese patient aged between 18-65 yrs. The age grouped to six groups as flow ([18-25], [26-33], [34-41], [42-49], [50-57] and [58-60]), with commercially available real time machine using a 3.5 MHz transducer. The result after data analysis was:

Table (4.1): Show age and portal vein diameter statistical information for all patients

	Mean	Median	STD	Min	Max
Age	40.79	42.50	14.1	18	65
Diameter	10.53	10.45	1.68	7.20	13.70

Table (4.2): Show frequency of male and female

Gender	frequency
Male	47
Female	53

Total 100

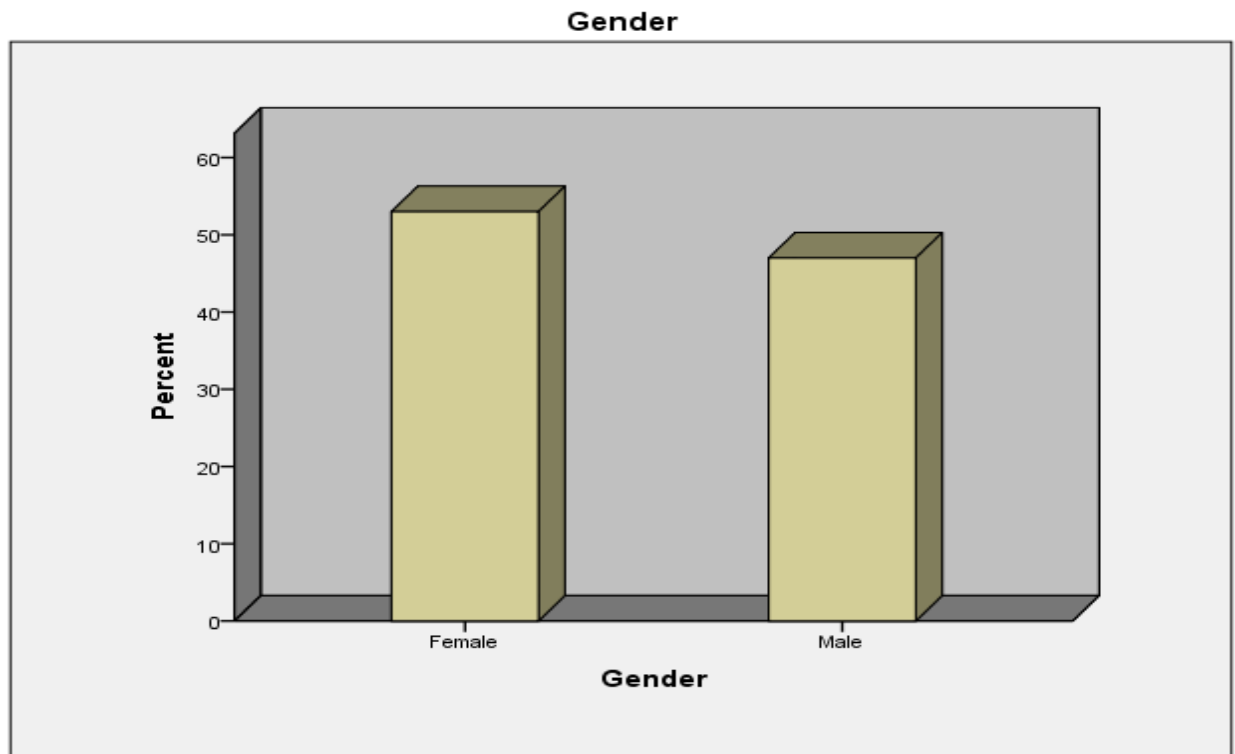


Figure (4.1): Show distribution of males and females.

Table (4.3): Show age and portal vein diameter statistical information for males

	Mean	Median	STD	Min	Max
Age	43.57	45.00	13.89	18	65

Diameter 10.99 11.20 1.67 8.10 13.70

r

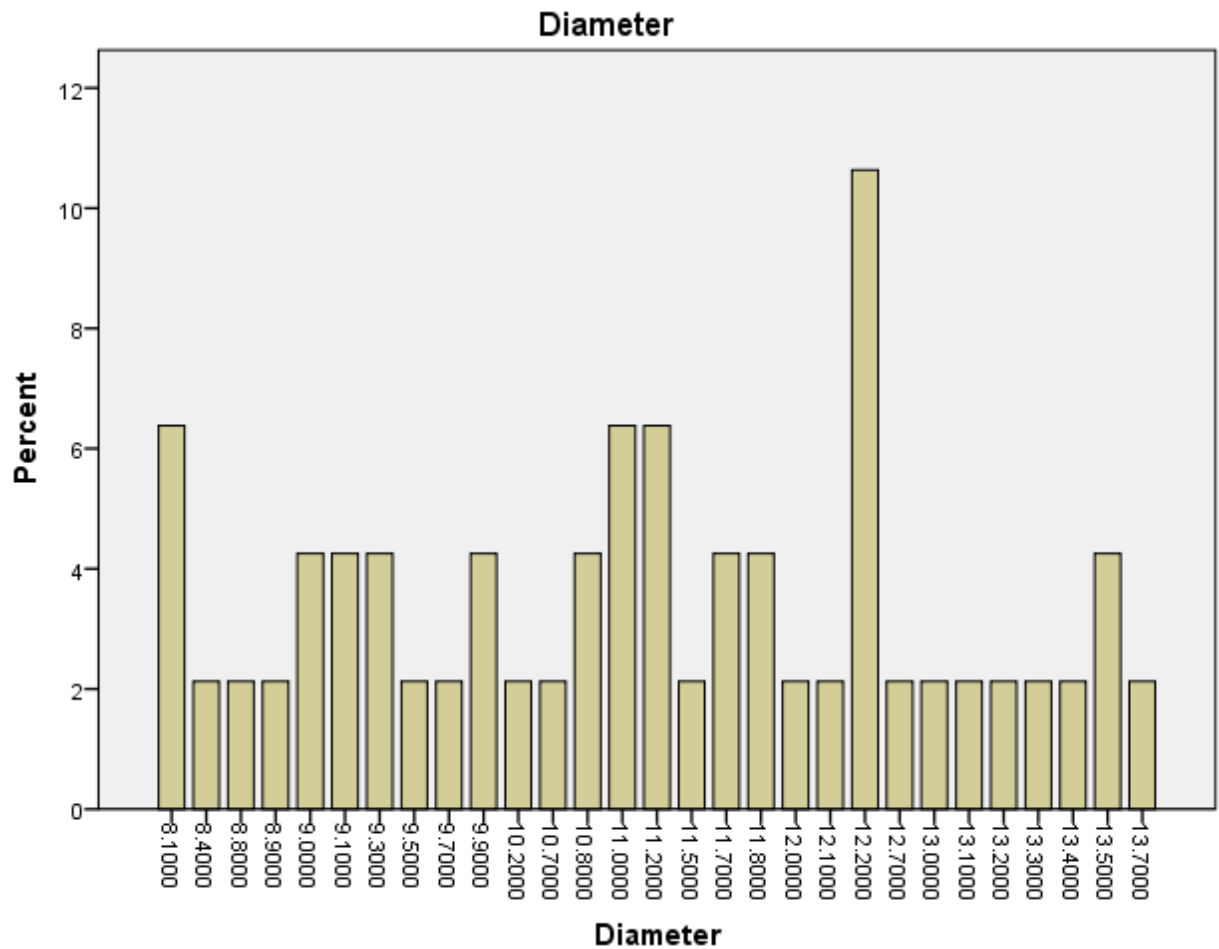


Figure (4.2): Show distribution of main portal vein diameter for males.

Table (4.4): Show age and portal vein diameter statistical information for females

	Mean	Median	STD	Min	Max
Age	38.32	39.00	13.83	18	64
Diameter	10.13	10.20	1.60	7.20	13.50

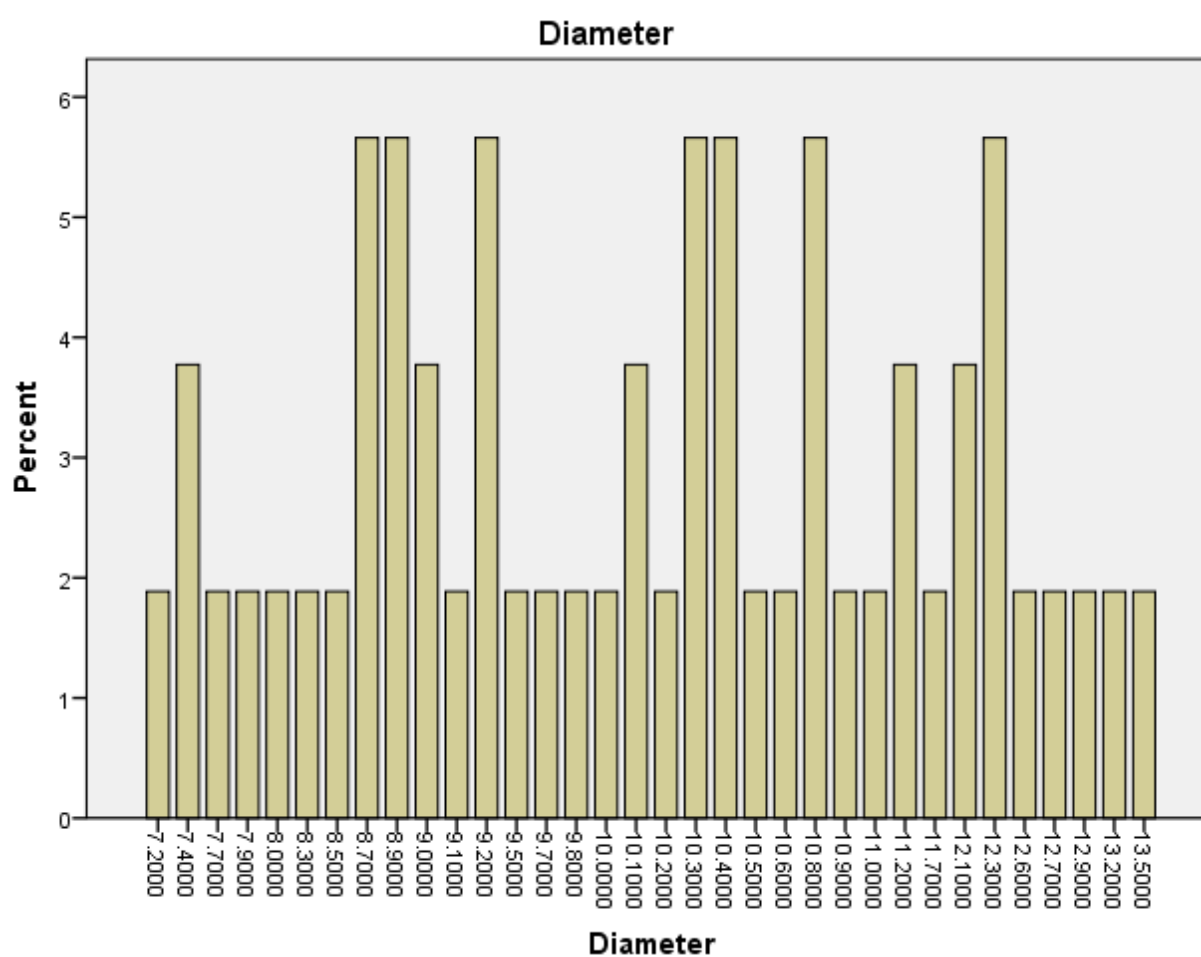


Figure (4.3): Show distribution of main portal vein diameter for females.

Table (4.5): Show frequency of age groups

Age group(yrs)	Frequency
18-25	23
26-33	9
34-41	17
42-49	20
50-57	17
58-65	14
Total	100

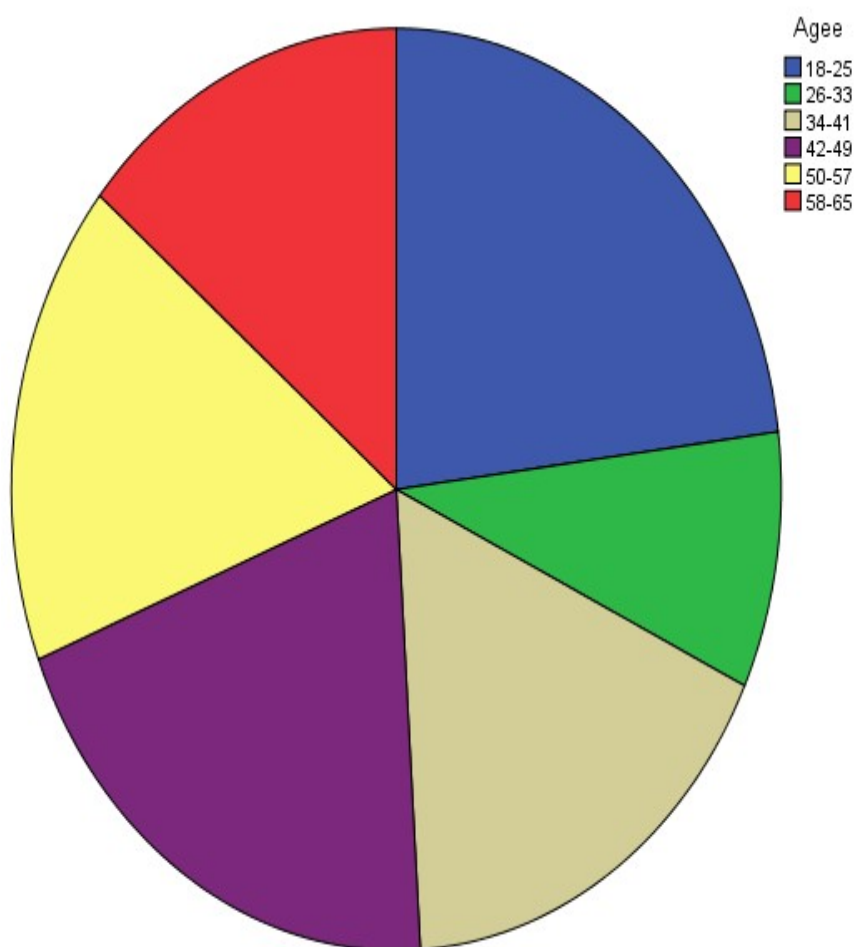


Figure (4.4): Show distribution of age groups.

Table (4.6): Show portal vein diameter statistical information for age groups

Age groups(yrs)	Mean	STD
18-25	8.47	0.68
26-33	9.53	0.73
34-41	10.51	1.06
42-49	10.67	0.80
50-57	11.57	0.87
58-65	13.14	0.40

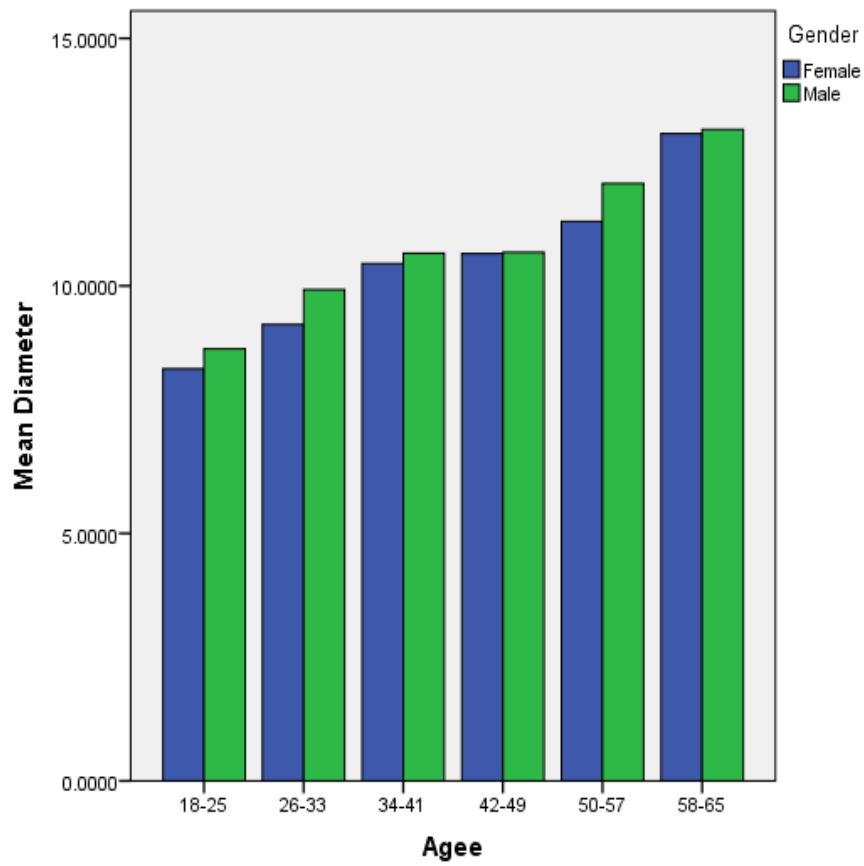


Figure (4.5): Show mean of portal vein diameter for all age groups.

Figure (4.6): Show correlation between age and portal vein diameter.

CHAPTER FIVE

DISSECTION, CONCLUSION AND RECOMMENDATION

Chapter Five

Dissection, Conclusion and Recommendation

5.1 Dissection

Number of 100 abdominal ultrasound was performed for Sudanese patient aged between 18-65 yrs. The age grouped to six groups as flow ([18-25], [26-33], [34-41], [42-49], [50-57] and [58-60]) female 53 and male 47, with commercially available real time machine using a 3.5 MHz transducer.

The main portal vein is scanned in a sagittal or oblique sagittal plane and the mean of main portal vein diameter was calculated from three measurements for each patient. The patients were scanned in the supine position and in a state of quiet respiration.

The result after data analysis was found in 23 pt aged (18-25) yr, the mean diameter of main portal vein was $[8.47 \pm 0.68]$ mm. In 9 pt aged (26-33) yr the mean diameter was $[9.53 \pm 0.73]$ mm. In 17 pt aged (34-41) yr the mean diameter was $[10.51 \pm 1.06]$ mm. In 20 pt aged (42-49) yr the mean diameter was $[10.67 \pm 0.80]$ mm. In 17 pt aged (50-57) yr the mean diameter was $[11.57 \pm 0.87]$ mm. In 14 pt aged (58-65) yr the mean diameter was $[13.14 \pm 0.40]$ mm.

The overall mean diameter of main portal vein in 100 pt was $[10.53 \pm 1.68]$ mm. with minimum diameter [7.20 mm] and maximum diameter [13.70 mm].

From these results there is a strong correlation between main portal vein diameter and age, as age increase the portal vein diameter increase.

The mean portal vein diameter for male $[10.99 \pm 1.67]$ mm, is slightly higher than mean diameter for female $[10.13 \pm 1.60]$ mm.

This study was quite similar to study of **Weinreb et al.** in sample size and results. They were found in 21 pt aged 0-10 yr, the mean diameter of portal vein was 8.5 ± 2.7 mm. In 20 pt aged 11-20 yr the mean diameter was 10 ± 2 mm. In 49 pt aged 21-30 yr the mean diameter was 11 ± 2 mm. In 58 pt aged 31-40 yr the mean diameter was 11 ± 2 mm. The overall mean diameter in 107 pt was 11 ± 2 mm. And there was no difference between male and female pt.

Aminu Umar Usman, et al. Study the Ultrasound Determination of Portal Vein Diameter in Adult Patients with Chronic Liver Disease in North-Eastern Nigeria. They found the mean portal vein diameter for normal (control group) was $(10.87 \pm 0.81$ mm). and I disagree with their result in that the found there was statistically significant difference in PV diameter between males and females ($P < 0.05$) with values higher in females. In my study the diameter was higher in males.

Also they take more parameters like respiratory phase (inspiration and expiration), but in my study I was scanned the patient only in quite respiration.

5.2 Conclusion

This study was conducted to find out the mean portal vein in Sudanese population.

The overall mean diameter of main portal vein in 100 Sudanese pt was $[10.53 \pm 1.68]$ mm. with minimum diameter $[7.20 \text{ mm}]$ and maximum diameter $[13.70 \text{ mm}]$.

There is a strong correlation between main portal vein diameter and age, as age increase the portal vein diameter increase.

The mean portal vein diameter for male $[10.99 \pm 1.67]$ mm, is slightly higher than mean diameter for female $[10.13 \pm 1.60]$ mm.

5.3 Recommendation

- The maximum main portal vein diameter for Sudanese must not exceeds [13.70 mm].
- The minimum main portal vein diameter for Sudanese must not exceeds [7.20 mm].
- The best technique to measure the main portal vein diameter by ultrasonography when is scanned in a sagittal or oblique sagittal plane and the mean of main portal vein diameter was calculated from three measurements.
- The patients must scan in the supine position and in a state of quiet respiration.
- The age and gender are important parameters that affect the diameter of portal vein.
- I recommend for next studies to correlate the portal vein diameter with body mass index and respiratory phases for furtherer evaluations.
- Also I recommend using a larger sample size, from difference state of the country.

References

1. Abu-Yousef MM 1992. Normal and respiratory variations of the hepatic and portal venous duplex Doppler waveforms with simultaneous electrocardiographic correlation. *J Ultrasound Med* 1992;11(6):263–268.
2. Bathal PS, Grossman HJ. 1985 Reduction of the increased portal vascular resistance of the isolated perfused cirrhotic rat liver by vasodilators. *J Hepatol* 1985; 1: 325-9.
3. Benjamin L. Shneider; Sherman, Philip M. (2008). *Pediatric Gastrointestinal Disease*. Connecticut: PMPH-USA. p. 751. [ISBN 1-55009-364-9](#).
4. Bisset (1 January 2008). [Differential Diagnosis in Abdominal Ultrasound, 3/e](#). Elsevier India. p. 257. [ISBN 978-81-312-1574-6](#). Retrieved 10 April 2011.
5. Bolondi L, Gamrolfi L, Arienti V et al 1982. Ultrasonography in the diagnosis of portal hypertension: diminished response of portal vessels to respiration. *Radiology* 1982; 142: 167-72.

6. Bolondi L, Mazziotti A, Arienti V et al 1984. Ultrasonographic study of portal venous system in portal hypertension and after portosystemic shunt operations. *Surgery* 1984; 95: 261-9.
7. Bosch J, Navasa M, Garcia-Pagan JC et al 1989. Portal hypertension. *Med Clin North Am* 1989; 73: 931-53.
8. Cobbold, Richard S. C. (2007). [Foundations of Biomedical Ultrasound](#). Oxford University Press. pp. 422-423. [ISBN 978-0-19-516831-0](#).
9. Curry R, Tempkin B. 2004 Sonography: Introduction to Normal Structure and Function. 2nd Ed. St. Louis: Saunders, 2004:356-363.
10. Harold M Chung; Chung, Kyung Won (2008). *Gross anatomy*. Philadelphia: Wolters Kluwer Health/Lippincott Williams & Wilkins. p. 208. [ISBN 0-7817-7174-9](#).
11. Henry Gray (1901). *Anatomy, Descriptive and Surgical* (16 ed.). Philadelphia: Lea Brothers. p. 619. Harold
12. <http://cancerweb.ncl.ac.uk/cgi-bin/omd?splanchnic+circulation>
13. <http://radiopaedia.org/cases/portal-vein-anatomy>
14. http://www.daviddarling.info/encyclopedia/P/portal_vein.html
15. http://www.em.emory.edu/ultrasound/ImageWeek/Abdominal/mickey_mouse.html
16. http://www.ssajm.org/viewimage.asp?img=Sub-SaharanAfrJMed_2015.
17. <http://www.stefajir.cz/?q=liver-sonography>

18. Lafortune M, Madore F, Patriquin HB *et al.* 1991 Segmental Anatomy of the liver: A sonographic to Coinaud nomenclature. *Radiology* 1991; 181: 443-8.
19. *Novelline, Robert (1997). Squire's Fundamentals of Radiology (5th ed.). Harvard University Press. pp. 34-35. ISBN 0-674-83339-2.*
20. Nyberg D, McGaham J, Pretorius D, *et al* 2003. Diagnostic Imaging of Fetal Anomalies. Philadelphia: Lippincott Williams & Wilkins, 2003:85-132.
21. Owen C, Meyers P 2006. Sonographic evaluation of the portal and hepatic systems. *J Diagn Med Sonogr* 2006;22(5):317-328.
22. *Plinio Rossi; L. Broglia (2000). Portal Hypertension: Diagnostic Imaging and Imaging-Guided Therapy. Berlin: Springer. p. 51. ISBN 3-540-65797-5.*
23. www.wikipedia.org

Appendices

Data collection sheet

Basic information

Date:

Hospital name:

Pt age:

Pt gender:

Nationality:

Is the patient having any diseases?

Yes No , if yes specify the
disease.....

Ultrasound information:

Type of transducer used:

Pt position:

Scanning view:

Scanning angel:

Breathing technique:

Mean portal vein diameter at the porta heptis in mm:

- هذه المعلومات مأخوذه للبحث العلمي فقط , وتحت إشراف كلية الأشعه بجامعة السودان للعلوم والتكنولوجيا.