



Sudan University of Science and Technology

College of Graduate Studies



Early Detection of Thyroid Disorders using Ultrasonography

الاكتشاف المبكر لأمراض الغدة الدرقية باستخدام

التصوير بالموجات فوق الصوتية

**A thesis submitted for partial fulfillment of
the requirements of master degree in
medical ultrasound.**

By:

Salma Mohamed Adam Ahmed

Supervised by:

Dr. Asma Ibrahim Ahmed Elamin

2016

الاية

قال تعالى:

بسم الله الرحمن الرحيم

چ چ چ چ چ چ چ چ چ چ چ چ

ڈ ڈ ڈ ڈ ڈ ڈ ڈ ڈ ڈ ڈ ڈ ڈ

ک گ گ چ

صدق الله العظيم

العلق

(5-1)

Dedication

I dedicated to my Father
To my mother
To my brothers
To my sisters
To my Friends
To my teachers
To my great family

Acknowledgement

First great thanks to Allah almighty who made all things possible and gave me power success of this research. I would like to present heartfelt gratitude to my supervisor Dr. Asma Ebrahim Ahmed Elamin for her guide support. Also I like to extend heartfelt gratitude to Sudan University of Science and Technology.

The successful completion of this study would not have been accomplished without the guidance, assistant and support of faculty staff of teachers, so I would like to render them for their effort.

Abstract

This across sectional descriptive study carried out in order to Early detection of thyroid diseases especially those have mutability to malignant diseases the study was

the study was done in College of Medical Radiological Sciences and Academic hospital using Alpinion E-CUBE 7 device in the period from May 2016 until August 2016.

The study was conducted 55 cases were 65.5% females and 34.5% males were aged (16-75 years) has been selected random samples do not suffer from any diseases of the thyroid gland, was analyzed using Statistical package for Science program system social (SPSS), the results found 67.3% are normal, 18.2% suffer from (cyst) in the gland and 14.5% with (Nodule), also found that females suffer thyroid disease more than men.

The study recommended the use of ultrasound early detection of diseases of the thyroid gland, and increased research in this direction by increasing the number of samples and the use of ultrasound technology with high facility for more accurate results.

ملخص البحث

أجريت هذه الدراسة كدراسة مقطعية تفصيلية وقد تم مقارنتها مع الدراسات السابقة التي أجريت في دول العالم المختلفة في الاكتشاف المبكر لأمراض الغدة الدرقية خاصة التي لها قابلية التحول إلى أمراض خبيثة، وقد أجريت هذه الدراسة في جامعة السودان ومستشفى الأكاديمي باستخدام جهاز Alpinion E-CUBE 7 في الفترة من شهر مايو 2016م حتى أغسطس 2016م.

وقد أجريت الدراسة علي 55 حالة كانت 65.5% من الإناث، و 34.5 من الذكور وقد تراوحت أعمارهم بين (16 - 75) سنة وقد تم اختيار عينات عشوائية لا تعاني من أي أمراض في الغدة الدرقية , وقد تم التحليل باستخدام نظام برنامج الحزم الإحصائية للعلوم الاجتماعية (SPSS) ووضحت النتائج أن 67.3% سليمين و 18.2% يعانون من أكياس في الغدة , و 14.5% يعانون من عقد (Nodule) ووجد أن الإناث يعانون من أمراض الغدة أكثر من الرجال.

وقد أوصت الدراسة باستخدام الموجات فوق الصوتية في الكشف المبكر لأمراض الغدة الدرقية, وزيادة البحوث في هذه الاتجاه بزيادة عدد العينات واستخدام الموجات فوق الصوتية بتقنية أعلى للحصول علي نتائج أكثر دقة.

Pag	Name	Table
NO		
32	Classification of volunteers according to gender	(4-1)
33	Classification of volunteers according to age	(4-2)
34	Classification of volunteers according to weight	(4-3)
35	Classification of volunteers according to length	(4-4)
36	Classification of volunteers according to Occupation	(4-5)
37	Classification of volunteers according to Finding	(4-6)
38	Classification of volunteers according to Echogenicity	(4-7)
39	Cross tabulation between Finding and gender	(4-8)

List of tables

List of Abbreviations

DIT	Diodotyrosine
DNA	Deoxy ribonucleic acid
ERK1/2	Extracellular single regulator kinesis'
MCT8	Monocarboxylate trans porters
MIT	Mono iodotyrosin
PTH	Para thyroid hormone
SPSS	Static package for social sciences
SRIH	Somatostation messenger ribonucleic acid hormones
TBO	Thyroxin binding globulin
TRH	Thyrotropin releasing hormone
TSH	Thyroid stimulating hormones

TSI	Thyroid stimulating immunoglobulin
TG	Thyroid globulin
TPO	Thyroid peroxidase
U/S	Ultrasound

Contents

الأية	I
Dedication	II
Acknowledgment	III
Abstract (English)	IV
Abstract (Arabic)	V
List of table	VII
List Of figure	VIII
List of Abbreviations	X
List of Contents	XI

Chapter one

1.1 Introduction	1
1.2 Problem of the study	3
1.3 Objective of the study	3

Chapter Two

2.1 Anatomy of the thyroid gland	5
2 .2 The thyroid physiology	8
2.3 Ultrasound technique of the thyroid gland	14
2.4 Normal Sonographic appearance of the thyroid gland	15
2.5 Thyroid pathology and Sonographic appearances	17
2.6 Previous study	27

Chapter Three

3-1 materials	29
3-1-1: Population, area, variable duration of study	29

3-1-2: Inclusion criteria	29
3-1-3 Exclusion criteria	29
3-1-4 Machine	29
3-2 Method	30
3-2-1: Technique	30
3-2-2 data presentation	31
3-2-3: data analysis	31
3-2-4: Ethical consideration	31

Chapter Four

4.1-Result	32
------------	----

Chapter Five

5.1 Discussion	40
5.2 Conclusion	41
5.4Recommendation	42
Reference	43
Appendices	

- I U/S Images from sample of the study
- II Data collection sheets

Pag	Name	No of
NO		

	Figure
32 Classification of volunteers according to gender	(4-1)
33 Classification of volunteers according to age	(4-2)
34 Classification of volunteers according to weight	(4-3)
35 Classification of volunteers according to length	(4-4)
36 Classification of volunteers according to Occupation	(4-5)
37 Classification of volunteers according to Finding	(4-6)
38 Classification of volunteers according to Echogenicity	(4-7)

List of Figures

Chapter One

Chapter One

1-1 Introduction

The thyroid gland is first one of the body's endocrine glands, which is developed on approximately the 24th day of gestation

The cells originating in the endoderm of the primitive pharynx, the thyroid initially develops from caudal to the tuberculum impar, which is also known as the median tongue bud, this embryonic swelling arises from the first pharyngeal arch and occurs at midline on the floor of developing pharynx.

The sonographer's examination of the thyroid gland are considered much safer and easier for application and patient preparation, and early detection of disorders of the thyroid gland in largest age group will lead to early treatment of discovered cases, which will improve life status. (Bruneton J.N. 1994).

The advantage of using ultrasound imaging is its mobility and low cost as well as ability to measure the dimension of the gland, check for the presence of masses or cyst and evaluate the structure and echogenicity of the parenchyma. Therefore, thyroid ultrasound examination provides an objective and precise method for detection of change in the size of the nodule, evaluation of features which include hypoechoic or hyperechoic and composition, cystic, solid or mixed as well as presence or absence of coarse or a halo and irregular margins. Ultrasound of thyroid must be done early to discover the abnormality if present and look for suitable solution also its

accurate modality for detecting thyroid gland abnormality. (www.Wikipedia.org January 2015).

The possibility of obtaining an estimate of the thyroid gland disorder is generally considered to be an important in several pathologic situations such as thyroiditis and multinodular goiter,thyroid ultrasound was initially thought to be the essential imaging test for the thyroid gland providing clinically important information of benign and malignant conditions, focal masses or diffuse masses, single or multiple cystic or solid masses,thyroid measurement is the primary physical signs and symptoms which explain if the thyroid normal or abnormal, the sonographers ability to recognize anatomical structures within the neck is extremely useful in identifying thyroid structure and to understand the anatomic variation of the thyroid lobes and their measurement, the sonographer must be able to identify the thyroid anatomy correctly on the ultrasound image. (www.Wikipedia.org January 2015).

1-2 Problem:

Spread out of thyroid disorder's which have high risk for malignancy and suggest an optimal diagnostic approach and early treatment.

1-3 Objective:

1-3-1 General Objective:

Early Detection of Thyroid Disorders using
Ultrasonography

1-3-2 specific objectives:

- 1- To provide more information about ultrasound as a tool in detect thyroid disorders.
- 2- correlation between thyroid disorders and gender.

1-4 Justification:

This study will help in early detect thyroid disorder to avoid complication and reduce cost and time of examination.

1-5 Over view of study:

This study is concerned with early detect of thyroid disorder's it divided into five chapters. chapter one is an introduction which included introductory notes on

thyroid anatomy, physiology, pathology, as well as statement of the problem and study objectives while chapter tow will include literature reviews concurring to previous study, chapter three deals with the methodology, where it provides on outline of material and methods used to acquire the data in this study as well as the methods of analysis approach while the result are presenting chapter four, and finally chapter five include discussion of result, conclusion and recommendation followed by references and appendix.

Chapter Tow

Chapter tow

literature reviews

:Anatomy of thyroid gland-2-1

The thyroid gland is a butterfly-shaped organ and is composed of two cone-like lobes or wings, lobus dexter (right lobe) and lobus sinister (left lobe), connected via the isthmus. Each lobe is about 5 cm long, 3 cm wide and 2 cm thick. The organ is situated on the anterior side of the neck, lying against and around the larynx and trachea, reaching posteriorly the oesophagus and carotid sheath. It starts cranially at the oblique line on the thyroid cartilage (just below the laryngeal prominence, or 'Adam's Apple'), and extends inferiorly to approximately the fifth or sixth tracheal ring. It is difficult to demarcate the gland's upper and lower border with vertebral levels because it moves position in relation to these during swallowing. There is occasionally (28%-55% of population, mean 44.3%). (Kim DW et al 2013). A third lobe present called the pyramidal lobe of the thyroid gland. It is of conical shape and extends from the upper part of the isthmus, up across the thyroid cartilage to the hyoid bone. The pyramidal lobe is a remnant of the fetal thyroid stalk, or thyroglossal duct. It is occasionally quite detached, or may be divided into two or more parts. The pyramidal lobe is also known as Lalouette's pyramid. (Dorland's 2012).

The thyroid gland is covered by a thin fibrous sheath, the capsulaglandulaethyreoideae, composed of an internal and external layer. The external layer is anteriorly continuous with the pretracheal fascia and posterolaterally continuous with the carotid sheath. The gland is covered anteriorly with infrahyoid muscles and laterally with the sternocleidomastoid muscle also known as sternomastoid muscle. On the posterior side, the gland is fixed to the cricoid and tracheal cartilage and cricopharyngeus muscle by a thickening of the fascia to form the posterior suspensory ligament of thyroid gland also known as Berry's ligament.(Lemaire 2008).

The thyroid gland's firm attachment to the underlying trachea is the reason behind its movement with swallowing. In variable extent, the pyramidal lobe is present at the most anterior side of the lobe. In this region, the recurrent laryngeal nerve and the inferior thyroid artery pass next to or in the ligament and tubercle. Between the two layers of the capsule and on the posterior side of the lobes, there are on each side two parathyroid glands. The thyroid isthmus is variable in presence and size, can change shape and size, and can encompass the pyramidal lobe (lobus or processuspyramidalis. The thyroid is one of the larger endocrine glands, weighing 2-3 grams in neonates and 18-60 grams in adults, and is increased in pregnancy. In a healthy person the gland is not visible yet can be palpated as a soft mass. Examination of the thyroid gland includes the search for abnormal masses and the assessment of overall thyroid size.(Fehrenbach 2012).

The thyroid is supplied with arterial blood from the superior thyroid artery, a branch of the external carotid artery, and the inferior thyroid artery, a branch of the thyrocervical trunk, and sometimes by the thyroid ima artery, branching directly from the subclavian artery. The venous blood is drained via superior thyroid veins, draining in the internal jugular vein, and via inferior thyroid veins, draining via the plexus thyroideus impar in the left brachiocephalic vein. Lymphatic drainage passes frequently the lateral deep cervical lymph nodes and the pre- and paratracheal lymph nodes. The gland is supplied by parasympathetic nerve input from the superior laryngeal nerve and the recurrent laryngeal nerve. (www.Wikipedia.org/wiki/di-thyroid 2015).

In the embryo, at 3-4 weeks of gestation, the thyroid gland appears as an epithelial proliferation in the floor of the pharynx at the base of the tongue between the tuberculum impar and the copula linguae at a point later indicated by the foramen cecum. The thyroid then descends in front of the pharyngeal gut as a bilobed diverticulum through the thyroglossal duct. Over the next few weeks, it migrates to the base of the neck, passing anterior to the hyoid bone. During migration, the thyroid remains connected to the tongue by a narrow canal, the thyroglossal duct (Berbel P et al 2010).

At the microscopic level, there are three primary features of the thyroid, first discovered by Geoffery Websterson in 1664. It consist of three components there are: Follicles; the thyroid is composed of spherical follicles that selectively absorb iodine (as iodide ions, I^-) from the blood for production of thyroid hormones, and also for storage of iodine in thyroglobulin. Twenty-five percent of the body's iodide ions are in the thyroid gland. Inside the follicles, in a region called the follicular lumen, colloid serves as a reservoir of materials for thyroid hormone production and, to a lesser extent, acts as a

reservoir for the hormones themselves. Colloid is rich in a protein called thyroglobulin, Follicular cells which are surrounded the follicle by a single layer of follicular cells, which secrete T_3 and T_4 . When the gland is not secreting T_3 and T_4 (inactive), the epithelial cells range from low columnar to cuboidal cells. When active, the epithelial cells become tall columnar cells and the last component is Parafollicular cells ;Scattered among follicular cells and in spaces between the spherical follicles are another type of thyroid cell, parafollicular cells (also called "C cells"), which secrete calcitonin. (Fawcett et al 2002).

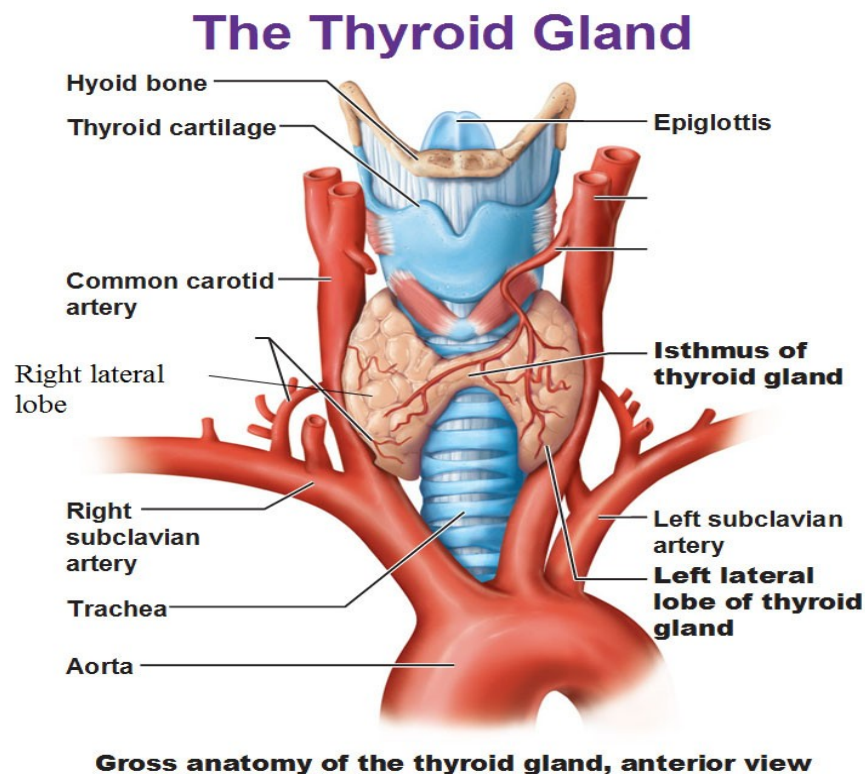


figure 2-1 anatomy of thyroid gland

(www.antranik.org 2015)

2-2-physiology:

The primary function of the thyroid is production of the hormones T_3 , T_4 and calcitonin. Up to 80% of the T_4 is converted to T_3 by organs such as the liver,

kidney and spleen. T_3 is several times more powerful than T_4 , which is largely a prohormone, perhaps four or even ten times more active. (Stephen et al. 2001).

Iodide—the ionized form of iodine—is essential for proper thyroid function. Iodide is taken up by follicular cells through the sodium-iodide symporter (NIS) present on the basolateral membrane, which transports two sodium cations and one iodide ion into the cell. It works against the iodide concentration gradient and uses energy of sodium gradient (maintained by the sodium-potassium pump) and therefore acts by secondary active transport. Thus, NIS help to maintain a 20- to 40-fold difference in iodide concentration across the membrane. This iodide is transported to the follicular space through the apical membrane of the follicular cell with the help of the iodide-chloride [antiporterpendrin](#). This iodide is then oxidized to iodine and attached to thyroglobulin by the enzyme thyroid peroxidase to form the precursors of thyroid hormones. (Boron et al 2012).

: T_3 and T_4 production and action-2-2-1

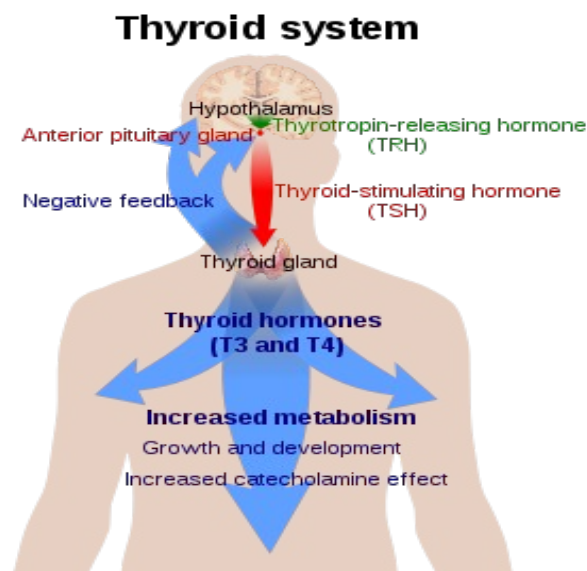


Figure 2-2The system of the [thyroid hormones](#) T_3 and

T_4 . https://commons.wikimedia.org/wiki/File%3AThyroid_system.png

Synthesis of the thyroid hormones, as seen on an individual thyroid follicular cell (fig 2-3); Thyroglobulin is synthesized in the rough endoplasmic reticulum and follows the secretory pathway to enter the colloid in the lumen of the thyroid follicle by exocytosis. Meanwhile, a sodium-iodide (Na/I) symporter pumps iodide (I^-) actively into the cell, which previously has crossed the endothelium by largely unknown mechanisms. This iodide enters the follicular lumen from the cytoplasm by the transporter pendrin, in a purportedly passive manner. In the colloid, iodide (I^-) is oxidized to iodine (I^0) by an enzyme called thyroid peroxidase. Iodine (I^0) is very reactive and iodinates the thyroglobulin at tyrosyl residues in its protein chain (in total containing approximately 120 tyrosyl residues). In *conjugation*, adjacent tyrosyl residues are paired together. The entire complex re-enters the follicular cell by endocytosis. Proteolysis by various proteases liberates thyroxine and triiodothyronine molecules, which enters the blood by largely unknown mechanisms. (Boron WF et al. 2003)

Thyroxine (T_4) is synthesised by the follicular cells from the tyrosine residues of the protein called thyroglobulin (Tg). It has 123 tyrosine residues, but only 4-6 are active. Iodine is captured with the "iodine trap" by the hydrogen peroxide generated by the enzyme thyroid peroxidase (TPO) and

linked to the 3' and 5' sites of the benzene ring of the tyrosine residues on Tg sequentially on tyrosine residue forming monoiodotyrosine (MIT) and then diiodotyrosine (DIT) (iodination). Two DIT can couple (coupling) to form T₄ hormone attached to thyroglobulin releasing one alanine. Upon stimulation by the thyroid-stimulating hormone (TSH), the follicular cells reabsorb Tg and cleave the iodinated tyrosines from Tg in lysosomes, forming free T₄, DIT, MIT, T₃ and traces of RT₃ (in T₃ and RT₃ has three iodine atom while T₄ has four), and releasing T₃ and T₄ into the blood. Deiodinase releases the sequestered iodine from MIT and DIT. Deiodinase enzymes convert T₄ to T₃ and RT₃, which is a major source of both RT₃ (95%) and T₃ (87%) in peripheral tissues. Thyroid hormone secreted from the gland is about 80-90% T₄ and about 10-20% T₃. (Stephen et al .2001).

Cells of the developing brain are a major target for the thyroid hormones T₃ and T₄. Thyroid hormones play a particularly crucial role in brain maturation during fetal development. A transport protein that seems to be important for T₄ transport across the blood-brain barrier (OATP1C1) has been identified. A second transport protein (MCT8) is important for T₃ transport across brain cell membranes. (Jansen et al 2005).

Non-genomic actions of T₄ are those that are not initiated by liganding of the hormone to intranuclear thyroid receptor. These may begin at the plasma membrane or within

cytoplasm. Plasma membrane-initiated actions begin at a receptor on the integrin α V β 3 that activates ERK1/2. This binding culminates in local membrane actions on ion transport systems such as the Na^+/H^+ exchanger or complex cellular events including cell proliferation. These integrins are concentrated on cells of the vasculature and on some types of tumor cells, which in part explains the proangiogenic effects of iodothyronines and proliferative actions of thyroid hormone on some cancers including gliomas. T_4 also acts on the mitochondrial genome via imported isoforms of nuclear thyroid receptors to affect several mitochondrial transcription factors. Regulation of actin polymerization by T_4 is critical to cell migration in neurons and glial cells and is important to brain development. T_3 can activate phosphatidylinositol 3-kinase by a mechanism that may be cytoplasmic in origin or may begin at integrin α V β 3. In the blood, T_4 and T_3 are partially bound to thyroxine-binding globulin (TBG), transthyretin, and albumin. Only a very small fraction of the circulating hormone is free (unbound) - T_4 0.03% and T_3 0.3%. Only the free fraction has hormonal activity. As with the steroid hormones and retinoic acid, thyroid hormones cross the cell membrane and bind to intracellular receptors (α_1 , α_2 , β_1 and β_2), which act alone, in pairs or together with the retinoid X-receptor as transcription factors to modulate DNA transcription. (Bowen, R. (2000).

:T₃ and T₄ regulation-2-2-2

The production of thyroxine and triiodothyronine is primarily regulated by thyroid-stimulating hormone (TSH), released by the anterior pituitary. The thyroid, and thyrotropes in the anterior pituitary, form a negative feedback loop: TSH production is suppressed when the free T₄ levels are high. The negative feedback occurs on both the hypothalamus and the pituitary, but it is of particular importance at the level of the pituitary. The TSH production itself is modulated by thyrotropin-releasing hormone (TRH), which is produced by the hypothalamus. This is secreted at an increased rate in situations such as cold exposure (to stimulate thermogenesis) which is prominent in case of infants. TSH production is blunted by dopamine and somatostatin (SRIH) which act as local regulators at the level of the pituitary, in response to rising levels of glucocorticoids and sex hormones (estrogen and testosterone), and excessively high blood iodide concentration. An additional hormone produced by the thyroid contributes to the regulation of blood calcium levels. Parafollicular cells produce calcitonin in response to hypercalcemia. Calcitonin stimulates movement of calcium into bone, in opposition to the effects of parathyroid hormone (PTH). However, calcitonin seems far less essential than PTH, as calcium metabolism remains clinically normal after removal of the thyroid (thyroidectomy), but not the parathyroids. (Johannes W et al. 2002).

:Physiological action of T₃ and T₄-2-2-3

T₃ of particular physiological importance produced mainly in tissue after deiodination. It has calorigenic, cardiovascular, neural and other metabolic actions, It increases oxygen consumption of all tissues except brain, uterus,

testis (though it is important for normal fertility) lymph node, spleen, and its source, anterior pituitary, mainly by its action on sodium potassium pump and fat metabolism, It is helps in conversion of carotene into vitamin A in hepatic cells, therefore, hypothyroidism may lead to high levels of carotene in the blood, resulting in yellowish tint of only skin (and not the mucous membrane, like sclera). It increases growth and results in positive nitrogen usage. (Protein anabolism). But high levels result in protein catabolism. Produced potassium due to catabolism appears in urine. Decreased level of thyroid hormone result in retention of hyaluronic acid and chondroitin sulfuric acid in the skin, which results in water retention (due to polyolic nature) and myxedema). It also has significance in proper mentation. Increased levels results in irritability. Decreased levels results in poor mentation and increased protein level in CSF. It has significance in proper development of cochlea, and hypothyroidism may lead to low IQ and deaf mutism. Many cardiovascular effects are reported. Increased peripheral resistance, increased rate and force of heart beat occurs by effects of circulatory T_3 . It increases carbohydrate absorption. It is also reported to decrease cholesterol levels. ([www.Wikipedia, the free encyclopedia.htm](http://www.Wikipedia,the free encyclopedia.htm) 2014)

2-3- ultrasoundTechnique of thyroid gland:

The thyroid should be examined with a real time linear array transducer having a short focal zone (1 to 4 cm). Most patients can be adequately imaged with 7.5 to 10 MHz frequencies. The theoretic axial resolution of these systems is 1 mm. The patient should be examined in the supine position with the neck extended. Scanning should be done in sagittal, transverse, and oblique planes to optimally visualize

both lobes of the thyroid as well as the isthmus. Extended field of view imaging provides a panoramic transverse view which is useful for comparing the size and echogenicity of the lobes. Patient swallowing tends to raise the thyroid gland in the neck and may be helpful to image the lower poles (Dean D. 2007).

Intrathoracic extension of the thyroid gland can be demonstrated by angling the transducer inferiorly into the mediastinum from a supramanubrial position. If the neck is thin and the thyroid is very superficial, an offset gel pad may help to place the gland in the focal zone and improve detail. However, ample gel applied to the patient's neck usually ensures good performance of the transducer. Color Doppler is used to confirm any focal abnormalities and assess general vascularity, neoplastic nodules (adenomas, carcinomas) usually contained intranodular flow signals. The majority of the colloid nodules are either avascular or have halo flow signals while many of them show a comet-tail artifact (Gilani S.A2003).

2-4-Normal Sonographic Appearances of thyroid gland:

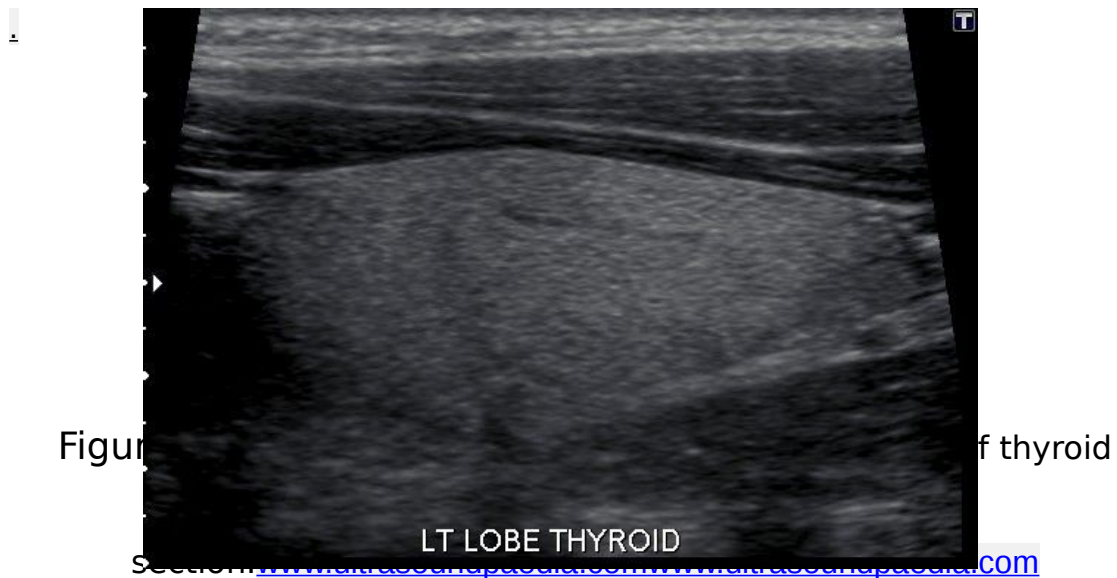
Sonographically the normal thyroid gland is homogeneously fine textured with medium to high levels of echogenicity. The echogenicity is usually greater than the normal neck

muscles. The capsule is the hyperechoic line that forms the margins of the gland. It should be smooth and well defined. On transverse section, a normal gland has a concave (or straight) anterior border, indented by the sternothyroid muscle; (figure 2-4) had demonstrate thyroid gland in transverse section. Longitudinal section through a normal gland also demonstrates a flat or minimally bulged anterior border as in (figure 2-5). The superior thyroid artery and vein are located at the upper pole of each lobe. The inferior thyroid vein is located at the lower pole of each lobe. The inferior thyroid artery is located posterior to the lower third of each lobe. "These arteries (1-2 mm diameter) and their accompanying veins (6-8 mm diameter) course between the thyroid lobes and the longuscolli muscles (Gilani S.A2003)

Thyroid Volume are calculated using the standard formula for an ellipse (length x width x height x 0.52). "In approximately one-third of cases, the sonographic measurement of volume differs from the physical size estimate derived from examination. Normal volume in adults is 10 to 11 + 3 ml.⁷ Thyroid volume is larger in patients with iodine deficiency or who have acute hepatitis or chronic renal failure. Thyroid volume is smaller in patients with chronic hepatitis or who have been treated with thyroxine or radioactive iodine.(Gilani S.A 2003).

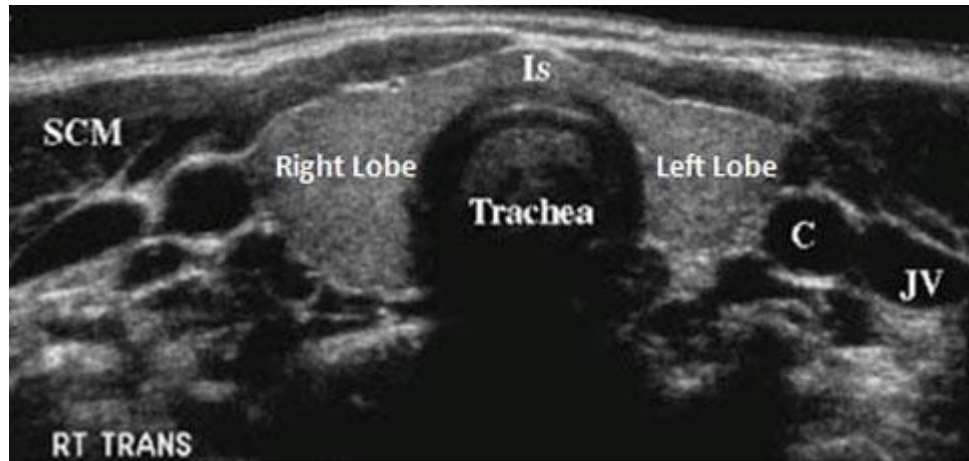

Figure 2-3 Sonographic appearance of normal thyroid gland in transverse section (Is isthmus, C carotid artery, JV jugular vein, SCM sternocleidomastoid muscle). www.chop.edu



2-5-Thyroid pathology and sonographic appearances :

Ultrasound is used to determine the solid or cystic nature of a cold nodule but it is unable to differentiate benign from malignant lesions. A definitive diagnosis requires either fine needle aspiration and biopsy or surgery. Fine needle aspiration or biopsy is performed to determine whether the nodule is benign or malignant. Hot nodules may require surgical intervention or nonradioactive ablation therapy. "Diffuse homogeneous goiters from hyperthyroidism are usually treated with radioactive ablation therapy."¹⁰

Functional ectopic thyroid tissue will also be demonstrated using technetium-99m scans. There are some thyroid abnormality with sonographic appearance (Can.A.S. 2008).

2-5-1- Goiter

Any form of thyroid enlargement is called a goiter. "The increase in volume is gradual and may be associated with normal thyroid function (euthyroid) or diffuse toxic goiter with increased hormonal production (hyperthyroidism) or decreased function (hypothyroidism). Euthyroid goiter is the most common and iodine deficiency is usually the cause. Many thyroid diseases can present with one or more thyroid nodules." Benign thyroid nodules outnumber malignant thyroid nodules approximately 500 to 1 (Can.A.S. 2008).

2-5-1-1-Diffuse Colloid (Simple) Goiter - Zones of glandular hyperplasia result in dilated follicles filled with colloid. These dilated follicles appear as cold nodules. They can undergo hemorrhage and necrosis. "Colloid nodules are

the most common type of thyroid nodule.”¹⁰ Thyroid function is normal.

Sonographically: the gland is symmetrically enlarged with normal echogenicity. (Gilani S.A (2003).

2-5-1-2-Adenomatous or Multinodular Goiters (MNG):

Sometimes hyperplasia and dilatation of follicles with colloid does not affect the thyroid uniformly and results in a multinodular goiter. Thyroid function is usually normal. The patient presents with an enlarged gland and pressure symptoms related to the trachea and esophagus ,Multiple cold nodules are demonstrated on NM scans. MNG's can grow to enormous sizes and are often asymmetrical due to nodule masses of various sizes(Gilani S.A2003).

Sonographically, the gland may be diffusely inhomogeneous with no recognizable normal thyroid tissue or there may be multiple discrete nodules scattered throughout an otherwise normal gland. The nodules may have isoechoic, hypoechoic or hyperechoic echogenicities. They may also have mixed echogenicity if they undergo hemorrhage or necrosis. Coarse calcifications may be present (Gilani S.A (2003).

2-5-2-Thyroiditis:

This is inflammation of the thyroid gland. There are several kinds of *thyroiditis* the main two types are:

2-5-2-1- Hashimoto's Thyroiditis:

This is the most common form of thyroiditis and is characterized by often painless, moderate, symmetrical enlargement, mild hypothyroidism, massive infiltration of lymphatic cells and the presence of serum autoantibodies against the thyroid gland. It is more common in young and middle aged women.⁷

Sonographically a diffuse micronodular pattern is characteristic as (figure2.7). The micronodules are hypoechoic and range in size from 1-6 mm although most are 2-3 mm size. The gland is usually enlarged but may be normal. Distinct nodules may be present. CD demonstrates marked hypervascularity. (Gilani S.A (2003).

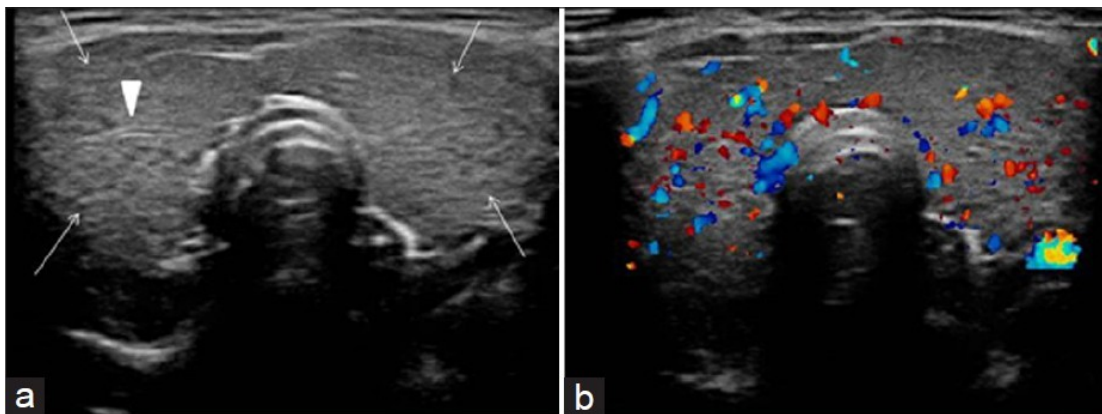


Figure2-5 Diffuse Hashimoto's thyroiditis in transverse gray-scale ultrasound neck (a) demonstrates diffuse enlargement of thyroid gland with heterogeneous echotexture. Multiple tiny and discrete hypoechoic nodules (micronodules, arrows) Color Doppler sonogram (b) demonstrates mildly increased parenchymal vascularity. (www.ijem.in)

2-5-2-2-Subacute (de Quervain's) Thyroiditis:

This is believed to be caused by a virus rather than autoimmunity and is also more common in women. The gland is swollen and painful usually 2-3 weeks after an upper respiratory infection. "Severe destruction of the gland releases hormone, resulting in a period of hyperthyroidism, followed by a short period of hypothyroidism caused by hormone depletion. Most patients recover fully.

Sonographically the gland is enlarged initially but as the disease progresses, the gland becomes atrophic. The gland appears heterogeneous with both hyperechoic and hypoechoic nodules, demonstrate in (figure2-7). There is an overall decrease in parenchymal echogenicity. (Gilani S.A (2003).

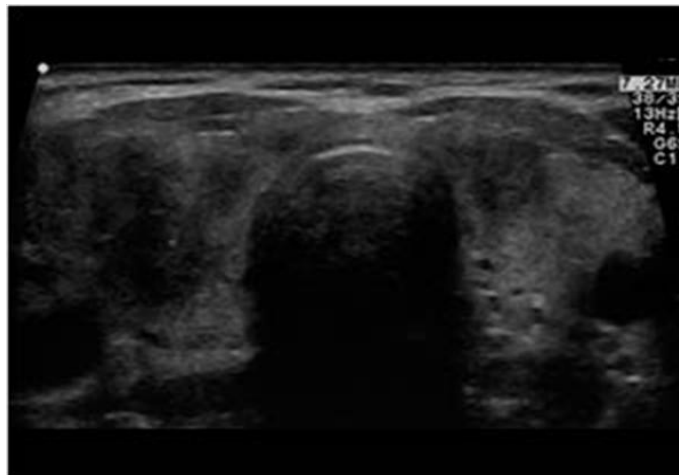


Figure 2-6: Subacute (de Quervain's) Thyroiditis in transverse gray-scale ultrasound neck shows bilaterally enlarged thyroid lobes with heterogeneous echo pattern.

(www.ultrasoundcases.info 2015)

2-5-3- thyroid nodules:

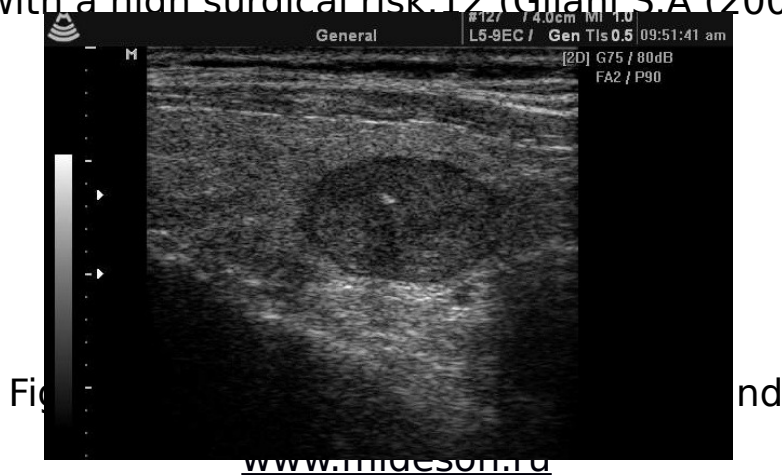“Evaluation of thyroid nodules is particularly annoying because thyroid nodules are exceedingly common and US detects most of them, even as small as 1-2 mm, but can rarely unequivocally differentiate benign from malignant nodules. (Gilani S.A2003).

US is used to evaluate nodules and indicate whether a biopsy is necessary. It is also used to direct aspiration biopsies of thyroid nodules and to guide alcohol ablation of thyroid lesions. There are many thyroid lesion seen below:

2-5-3-1-Adenomas - Adenomas are benign tumors of thyroid follicles. Usually the adenoma is a solitary, well encapsulated lesion. The remainder of the gland appears normal. Occasionally adenomas are hyperfunctioning and result in hyperthyroidism with suppression of the rest of the gland. Hyperfunctioning adenomas usually result in "hot" lesions on radioisotope nuclear medicine scans.

Sonographically most adenomas are solitary, solid, homogeneous lesions with regular margins and an oval or round shape (figure 2-9). Adenomas can be hypoechoic, isoechoic or hyperechoic to the normal thyroid tissue. They tend to undergo cystic degeneration. An anechoic peripheral halo may be seen with adenomas however, it may also be present with malignant lesions and is therefore nonspecific. Adenomas may have localized peripheral calcification or may be entirely calcified resembling a calculus. Treatment of pretoxic and toxic adenomas has been successful using

power Doppler guided percutaneous ethanol injection (PEI). Power Doppler guidance permits detection of blood flow in very small vessels, permits ethanol to be guided toward the main afferent vessels of the adenoma and enables monitoring of the diffusion and effects of ethanol on nodular (adenoma) vascularization. The treatment is well tolerated and hormone levels returned to normal one month after PEI treatment. The previously “hot” nodule became “cold” within 6 months. Power Doppler demonstrated the extinction of intranodular vascularization in the 6 month follow-up evaluation. PEI under power Doppler guidance has been recommended for young patients, to prevent either surgery or treatment using radioactive iodine therapy, and for patients with a high surgical risk.¹² (Gilani S.A (2003)).



2-5-3-2-Carcinomas:

Thyroid cancer is the most common malignancy of the endocrine glands, it remains a rare disease accounting for less than 1% of all malignancy, and is the cause of death in only 0.005% of the United States population. Most thyroid

cancers are relatively nonaggressive and have a good prognosis with 90% 10-year survival for early disease. (Gilani S.A2003)

Thyroid carcinoma is 2-3 times more common in women. Neck irradiation, especially as a child, is a major risk factor, greatest 20 years after radiation. In the USA, 80% of thyroid cancers are papillary, 10% are follicular, 5% medullary and 5% anaplastic plus metastatic. The most common age for developing papillary carcinoma is 30 years of age and for follicular carcinoma, 45 year of age. A thyroid nodule found in a very young or very old patient is probably malignant. The most common presentation is an asymptomatic neck lump. The commonest metastatic sites for thyroid carcinomas are the local cervical lymph nodes. They can also metastasize to the overlying neck muscles, larynx and lungs.

Sonographic Features - The ultrasound appearances of thyroid cancer are highly variable , most sonographic feature are poorly defined margins, Hypoechoic (or isoechoic), Punctate (micro) calcifications (50-80%), Cervical adenopathy and CD shows marked intranodular blood flow (figure 2-9)

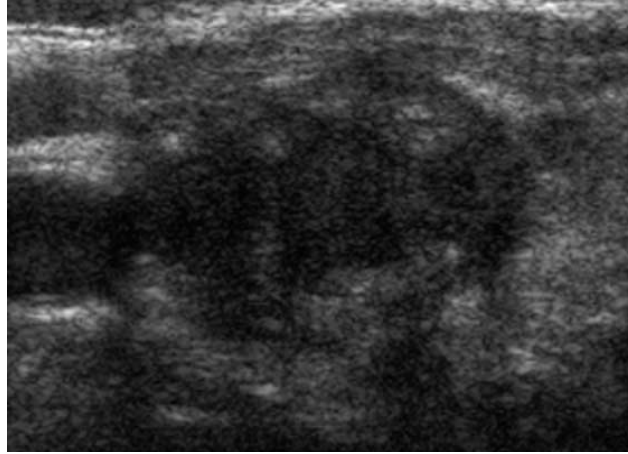


Figure 2-8: Transverse sonogram of thyroid carcinoma with irregular margins and heterogeneous echopattern. (Bryan et al 2003).

2-5-4-thyroid cyst:

2-5-4-1-Colloid Cysts :are collections of colloid in large thyroid follicles which appear as tiny cysts (<5mm in size) with no solid component. They are benign, can be considered a normal finding and are of no clinical significance.

2-5-4-2-Simple cysts: of the thyroid are rare. Most thyroid cysts are complex and represent degeneration of either an adenoma or a colloid nodule. Because of the rare occurrence of pure simple thyroid cysts and because both benign and malignant lesions can have cystic components, doing a thyroid ultrasound scan to distinguish a cyst from a solid mass is generally not of much clinical value.

2-5-4-3-Hemorrhagic cysts: are most often the result of acute hemorrhage within a follicular adenoma according to pathologic analysis. These lesions appear complex (cystic

and solid). Septations and fluid fluid levels can sometimes be seen in the cystic component. Fluid in a thyroid nodule is most consistent with a degenerating adenoma however, malignancy cannot be excluded. (Gilani S.A (2003). The three types are demonstrate in (fig 2-11).

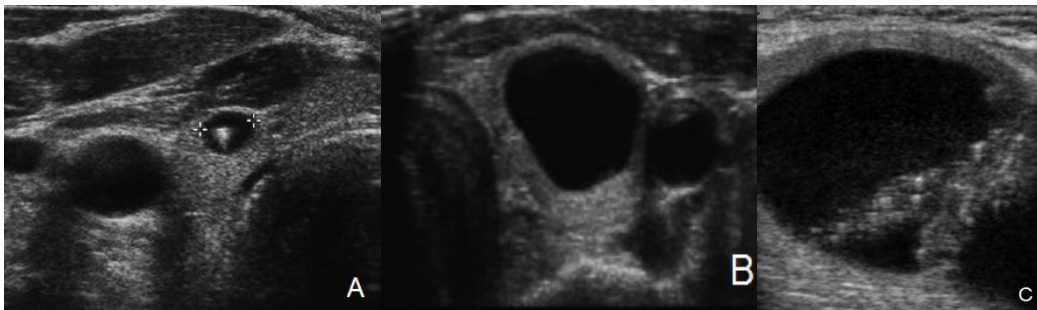


Figure 2-9: sonographic appearance of different cystic lesions of thyroid gland ;(A) colloid cyst ,(B) simple cyst,(C) hemorrhagic cyst.

www.cram.com

2-5-5 Hyperthyroidism:

This is a state of hypermetabolism and hyperactivity of the cardiovascular and neuromuscular systems induced by excessive levels of thyroxine in the blood. Primary hyperthyroidism may be due to a focal hyperfunctioning adenoma or to the more common diffuse condition called Graves' disease.

Graves' disease is a chronic autoimmune disease characterized by hyperthyroidism, diffuse hyperplasia of the thyroid gland and ocular changes. The gland is only modestly enlarged---up to three times normal size, and

remains symmetrical. Graves' disease is also known as **diffuse toxic goiter**. Nuclear medicine scans indicate uniform increased uptake of the radioisotope. Antibodies to thyroid stimulating hormone are in the patient's blood. Clinical manifestations of hyperthyroidism are an elevated body temperature, increased heart rate and systolic blood pressure, increased heat sensitivity, irritability, fine hand tremors, increased appetite and weight loss. (Gilani S.A2003) **Sonographically**, the gland is diffusely enlarged (2 to 3 times normal size) and homogeneous with normal or decreased echogenicity. Color Doppler imaging of these patients has demonstrated the thyroid inferno (figure 2-11), characterized by multiple tiny areas of flow throughout the entire gland in both systole and diastole. Color Doppler imaging after thyroid therapy showed a decrease in thyroid vascularity. (Gilani S.A (2003).



Figure (2-12): Shows eye manifestations of Graves' disease, thyroid ophthalmopathy (eye changes) which include; lid retraction, exophthalmos and weakness of eye muscles (ophthalmoplegia) (Delange et al, 1972)

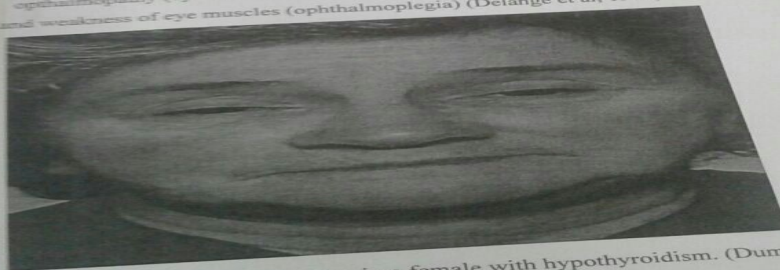


Fig. (2-13). Shows apathetic face in a female with hypothyroidism. (Dumont et al, 1963)

Figure2-10:Shows eye manifestations of Graves' disease thyroid ophthalmopathy (eye changes) weakness of eye muscles (Delange et al, 1972).

2-5-6-Hypothyroidism:

This is a depressed metabolic state caused by a deficiency of thyroid hormones. Body functions are slowed, the heart may enlarge, speech and mental processes are impaired and the patient feels cold. In adults, when it is associated with generalized interstitial edema, it is known as myxedema. The causes may be Hashimoto's thyroiditis, iodine deficiency, inborn errors of metabolism, surgical removal or chemical suppression of the thyroid as a treatment for Graves' disease. Hypothyroidism may cause thyroid gland hyperplasia. Hypothyroidism, if present from birth, can result in a severe form of mental retardation called cretinism. If the condition is diagnosed early and treated with thyroid extract drugs, the child will develop normally (Gilani S.A (2003).

2-6-Previous studies:

2-6-1: Early Detection of Thyroid Gland Disorders for Students in the Faculty of Applied Medical Sciences :

Ibrahim – et al in 19 march (2015) University department diagnostic radiology in Jedda Saudi Arabia ,among total number of 70 students, 26% was found with abnormal ultrasound finding,17% of them with cystic

nodules, while solid and mixed nodules represented 4% for each (Ibrahim – et al 2015).

2-6-2: Role of ultrasound in thyroid pathology

This is a retrospective study of thyroid patients referred for ultrasound for the period of 2007 to 2009 at different hospitals and dispensaries in the Kingdom of Saudi Arabia (Eastern area).

This study was carried out on 303 patients of various types of thyroid diseases in King Saudi Arabia. 232 (77 %) were female patients and 71 (23 %) were males. Along this series there were 25 % of enlarged thyroid gland which act as the most common ultrasound findings of thyroid disorders followed by, 23 % solitary thyroid nodules, 10 % multinodular goiters, 8 % simple cyst, 7 % nonpalpable thyroid nodules, 4 % goiter and Hashimoto's thyroiditis. The most common ultrasound findings of thyroid gland enlarged of thyroid. The least common is nodal enlargement, adenoma, thyroiditis, microcalcifications, small size thyroid, multiple thyroid nodules, thyroglossal cyst and Graves disease

.

2-6-3 Thyroid nodule Detected by ultrasonography:

Dr. Nalaa. M et. Al in June 2016 study was done in Cameroon, 180 participants 110 females and 70 male range of age from (15-65), Found total of 46.7% of participant had abnormal

Finding, commonest abnormality was multinodular goiter (54%).

Chapter Three

Chapter Three

Materials and Method

3-1 materials

3-1-1: Population, area, variable duration of study:

This is descriptive cross-sectional study where 55 volunteers selected randomly, 65.5% females 34.5% males with different weight, height, age gender and occupation, study was done in Sudan University clinic and Academic hospital in a period from May 2016 to August 2016, the data collected of subjects not suffer from any thyroid disease.

3-1-2: Inclusion criteria:

Subject not suffer from thyroid disease with different weight, height, age, gender and occupation.

3-1-3 Exclusion criteria :

- Patient with history of thyroid disease.
- Pregnant women.
- Children.

3-1-4 Machine:

procedure was done by Alpinion ultrasound machine Ecube 7 in Academic hospital and Sudan university clinic using liner transducer which provide both penetration and high resolution.

3-2 Method:

3-2-1: Technique :

To visualize thyroid gland optimally the patient is placed in supine position with a pillow underneath the shoulders to extend the neck slightly,

allowing the head to rest on the examination table. The normal thyroid gland is uniformly echogenicity relative to overlying strap muscles of the neck.

Thyroid gland examined in both transverse and longitudinal planes. Imaging to the lower poles is enhanced by asking the patient to swallow , which rise the thyroid gland in the neck. The examination extends laterally to examine the carotid artery and jugular veins to identify any enlargement. Intra thoracic extension of the thyroid gland can be demonstrate by angling the transducer inferiorly to the mediastinum from supramandibular position. Being with put the transducer on the sternal notch .move the transducer slightly to the superior and toward right of the patient, laterally enough to view right lobe of the thyroid from medial to lateral margin and measure the width and anteroposteior dimension

Keep the transducer perpendicular and scan superiorly through and beyond the right lobe to the level of mandible. Move the transducer inferior from the mandible back through and beyond the inferior margin of the right lobe to the level of sternal notch. Scan by the same manner the left lobe of thyroid. Put the transducer perpendicular of the sterna notch and scan superiorly until you scan through and beyond the isthmus being with the transducer perpendicular at the midline of the sterna notch. Move transducer slightly superior and toward the patient right lateral enough to view the right lobe from its superior and inferior margin. Keep the transducer perpendicular and scan toward the patient right laterally through and beyond the right lobe. Move back onto the lobe and scan through the midline and the isthmus scan by the same manner the left lobe.

3-2-2 data presentation:

data presented by figures and tables .

3-2-3: data analysis :

Data was analyzed by used statistical package for social studies(SPSS) and excel under windows.

3-2-4: Ethical consideration:

All data concern to population of the study written by their verbal agreement.

Chapter Four

Chapter four

Results

Table (4-1): Classification of volunteers according to gender

Gender	Frequency	%
Male	19	34.5
Female	36	65.5
Total	55	100%

Fig (4 -1) Gender

Table (4-2): Classification of volunteers according to age

Years	Frequency	%
16 -27	30	54.5
28 - 39	17	30.9
40 - 51	5	9.1
52 -63	1	1.8
64 - 75	2	3.6
Total	55	100%

Fig . (4 - 2): Age (Years)

Table (4-3): Classification of volunteers according to Weight

Kgs	Frequency	%
45 - 57	14	25.5
58 - 70	21	38.2
71 - 83	12	21.8
84 - 96	6	10.9
97 - 109	2	3.6
Total	55	100%

Fig . (4 - 3): weight (Kgs)

Table (4-4): Classification of volunteers according to Length

Length (m)	Frequency	%
1.4 - 1.56	9	16.4
1.57 - 1.73	37	67.3
1.74 - 1.9	9	16.4
Total	55	100%

Fig . (4 - 4): Length

Table (4-5): Classification of volunteers according to Occupation

Occupation	Frequency	%
Student	20	36.4
Housewife	12	21.8
Worker	13	23.6
Technologist	10	18.2
Total	55	100%

Fig . (4 - 5): Occupation

Table (4-6): Classification of volunteers according to Finding

Finding	Frequency	%
Normal	37	67.3

Cyst	10	18.2
Nodule	8	14.5
Total	55	100%

Fig . (4 - 6): Finding

Table (4-7): Classification of volunteers according to Echogenicity

Echogenicity	Frequency	%
Midgray	37	67.3
Hypo echoic	6	10.9
Anechoic	10	18.2
Hyper	2	3.6
Total	55	100%

Fig . (4 - 7): Echogenicity

Table (4-8): Cross tabulation of volunteers according to Finding and Gender

Finding	Gender		Total
	Male	Female	
Normal	13	24	37
Cyst	3	7	10
Nodule	3	5	8
Total	19	36	55

Chapter Five

Chapter Five

5.1: Discussion

The statically relationships between study variables are shown inTable (4.8) , shows relationship between of thyroid and selected variables Positive correlation was detected when comparing finding and gender.

The present study in comparing with the study conducted in march 2015,Saeed et al. King AbdalazizUniversity ,Jedda ,Saudi Arabia ,among total number of 70 subjects , 26% was found with abnormal ultrasound finding ,17% of them with cystic nodules,while solid and mixed nodules represented 4% for each.

Finding in females more than males, so that there is positive relationship between two studies. I agree with (Saeed et al 2015).

Present study comparing with Dr. Awad Mohammed study of thyroid patients referred for ultrasound for the period of 2007 to 2009 at different hospitals and dispensaries in the Kingdom of Saudi Arabia (Eastern area). Importance of the study is ; to create a reliable reference for the role of ultrasound in thyroid pathologies in King Saudi Arabia.

Study aimed to detect the Ultrasonic Differential Diagnosis of Thyroid pathologies. This study was carried out on 303 patients of various types of thyroid diseases in King Saudi Arabia.232 (77 %) were female patients and 71(23 %) were males. Along this series there were 25 % of enlarged thyroid gland which act as the most common ultrasound findings of thyroid disorders followed by, 23 % solitary thyroid nodules, 10 % multinodular goiters, 8 % simple cyst,

7 % nonpalpable thyroid nodules, 4 % goiter and Hashimoto's thyroiditis. The most common ultrasound findings of thyroid gland enlarged of thyroid. The least common is nodal enlargement, adenoma, thyroiditis, microcalcifications, small size thyroid, multiple thyroid nodules, thyroglossal cyst and Graves disease. Out of this study we believe more that ultrasound should be the first-line test owing to its safety and availability.

There is negative correlation between tow study I disagree with this study.

5.2 Conclusion:

The aim of this study is early detection of thyroid disorder in people using ultrasound. Data was presented in tables and graphic forms with the aim of enabling a more practical evaluation during a sonographic examination. The study found statistically significant correlation between finding and gender, females more finding than males, cystic nodules more than solid nodules this result usefulness of ultrasound in early detect of thyroid disorder.

5.4 Recommendations

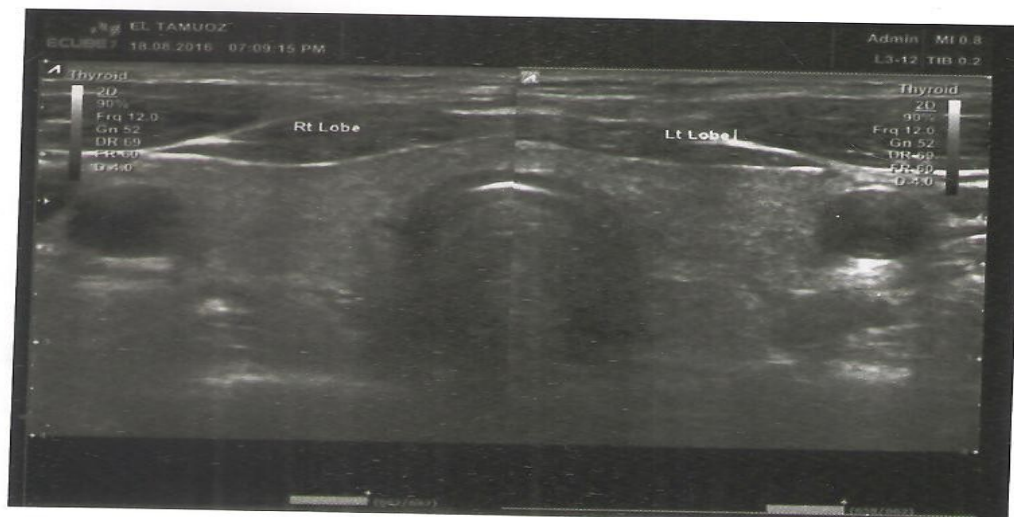
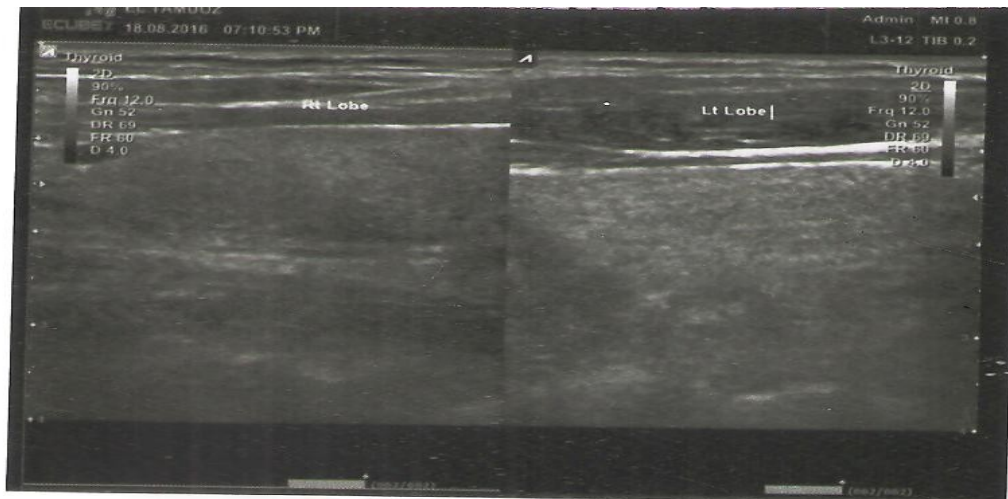
- Thyroid scan should be routine scan every 6 month to early detect of disorder to get plane for treatment if need special nodules which have high tendency for malignancy.
- All health care centers and Ear, nose, thought (ENT) clinics should be provided by ultrasound units.
- The study found high incident of significant findings, future study should concern with effect of this findings .
- Departments should be provide with more facilities like Doppler to evaluate effect of finding in vessels
- Another research studies should be done with expanding period of time and include more sample data for precise and accurate results.

References

- Bruneton, J.N., Balu-Maestro, C., Marcy, P.Y., Melia, P. and Mourou, M.Y. (1994) Very High Frequency (13 MHz) Ultrasonographic Examination of the Normal Neck: Detection of Normal Lymph Nodes and Thyroid Nodules. *Journal of Ultrasound in Medicine*.

- Berbel P, Navarro D, Ausó E, Varea E, Rodríguez AE, Ballesta JJ, Salinas M, Flores E, Faura CC, et al. (2010). "Role of late maternal thyroid hormones in cerebral cortex development: an experimental model for human prematurity". *Cereb Cortex* 20 (6): 1462-75.
- Can, A.S. and Peker, K. (2008) Comparison of Palpation-Versus Ultrasound-Guided Fine-Needle Aspiration Biopsies in the Evaluation of Thyroid Nodules. *BioMed Central Research Notes*, **1**, 12.
- Carroll, B.A. (1982) Asymptomatic thyroid Nodules: Incidental Sonographic Detection. *American Journal of Roentgenology*.
- Dean D. 2007. Abdominal small parts ultrasound. *Burwin institute of ultrasound* 49-55.
- *Dorland's (2012). Illustrated Medical Dictionary 32nd edition. Elsevier Saunders. pp. 999 redirect to 1562. ISBN 978-1-4160-6257-8.*
- http://fitsweb.uchc.edu/student/selectives/Luzietti/Thyroid_hyperthyroid.htm
- <http://www.ultrasoundpaedia.com/normal-thyroid>.
- Nabriski, D., Ness-Abramof, R., Brosh, T., Konen, O., Shapiro, M.S. and Shenkman, L. (2003) Clinical Relevance of Non-Palpable Thyroid Nodules as Assessed by Ultrasound-Guided Fine Needle Aspiration Biopsy. *Journal of Endocrinological Investigation*, **26**, 61-64.
- <http://dx.doi.org/10.1007/BF03345124>
- Lemaire, David (2005-05-27). "eMedicine - Thyroid anatomy". Retrieved 2008-01-19.

- Steele, S.R., Martin, M.J., Mullenix, P.S., Azarow, K.S. and Andersen, C.A. (2005) The Significance of Incidental Thyroid Abnormalities Identified during Carotid Duplex Ultrasonography. *Archives of Surgery*, 981-985.
- <http://dx.doi.org/10.1001/archsurg.140.10.981>
- Zapanta, P.E. and Shokri, T. (2010) Embryology of the Thyroid and Parathyroids, Thyroid Embryology Clinical Correlations. <http://emedicine.medscape.com/article/845125 overview#aw2aab6b5>



le

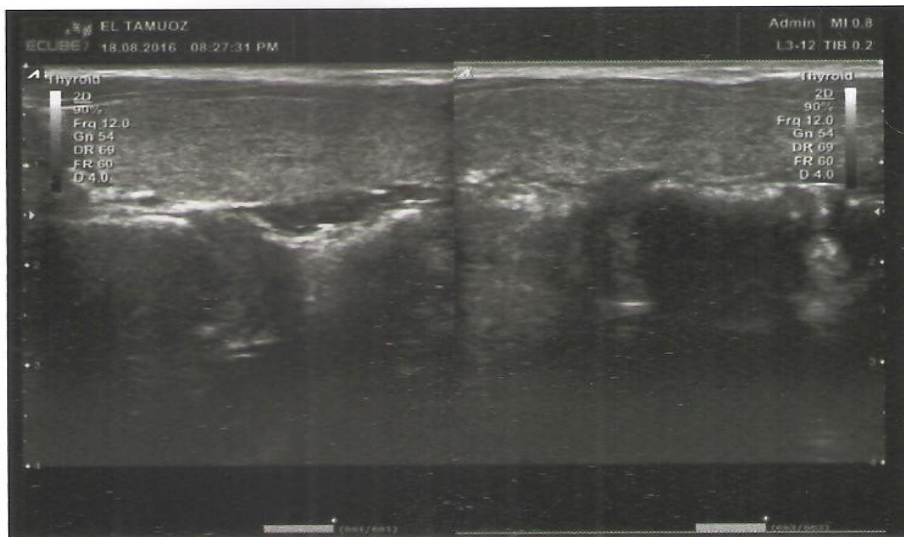
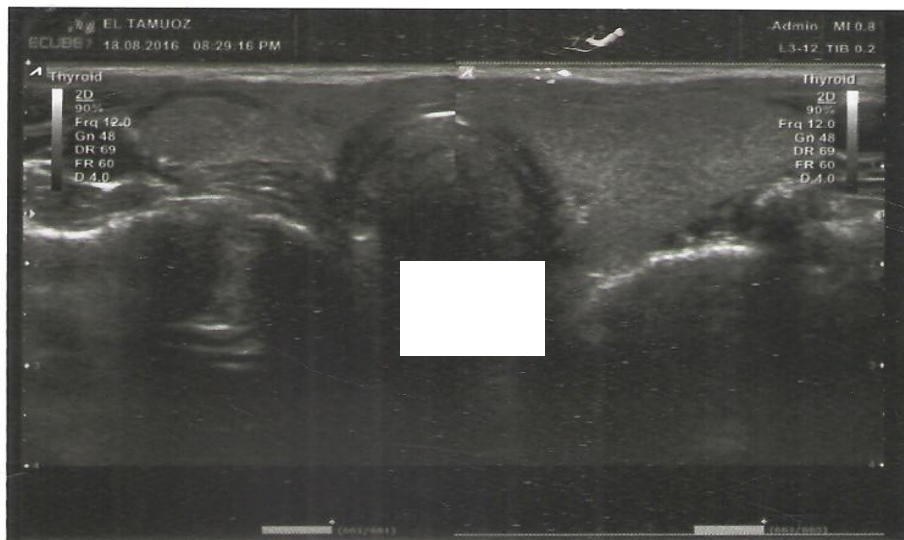
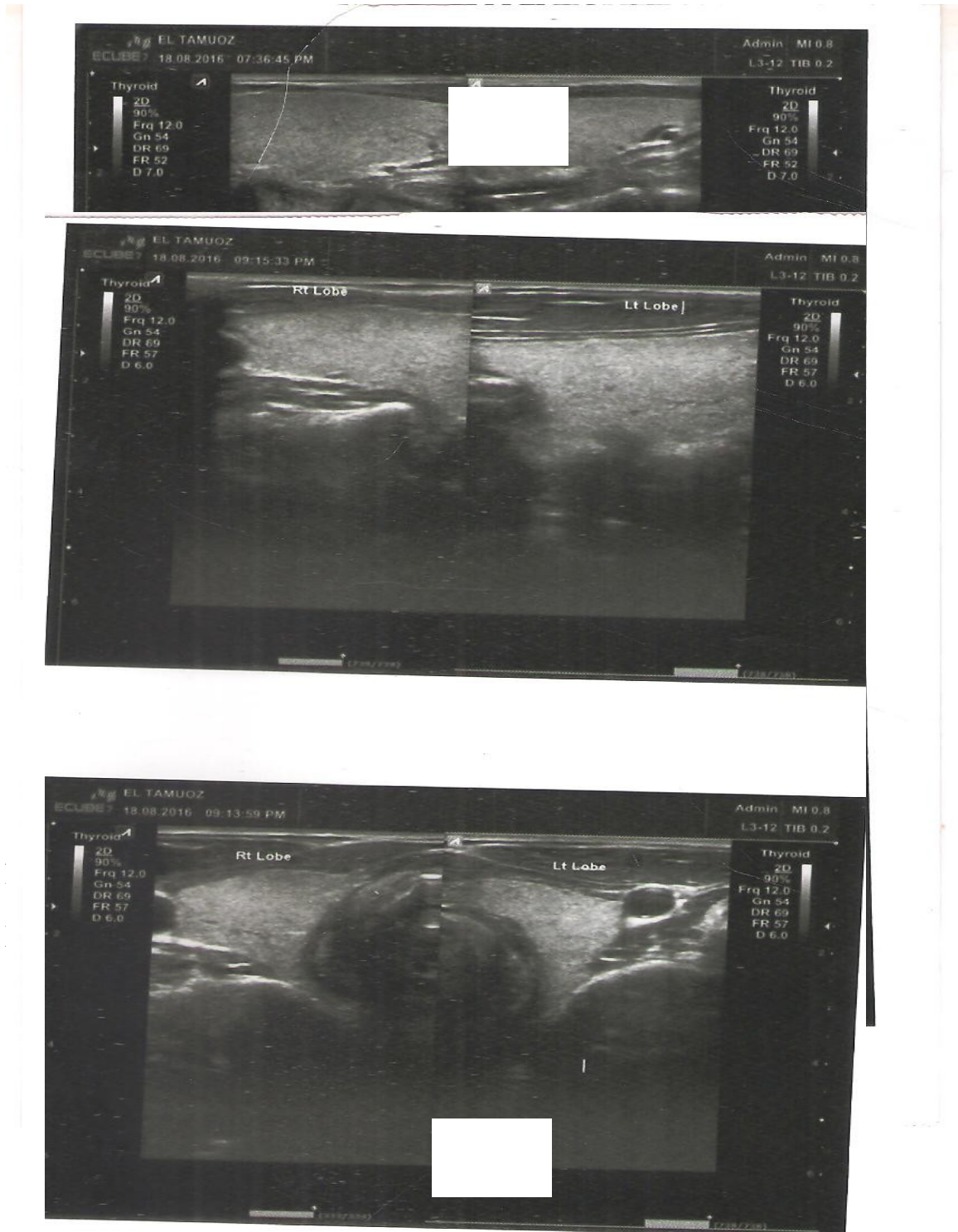


Fig 1.2 Sagittal and transvers scan to Rt and Lt lobe in 23 year male, length 170^{cm}, weight 75^{kg},normal scan.



I
I

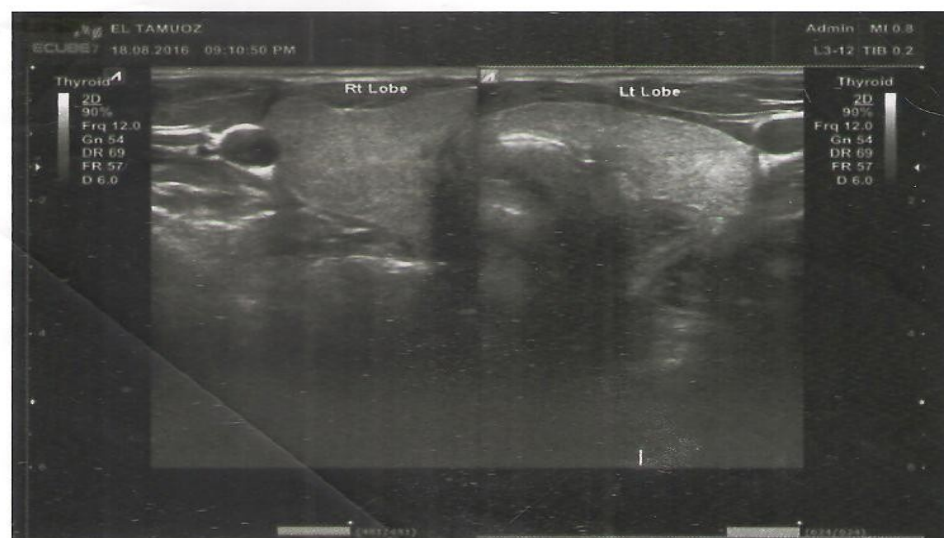
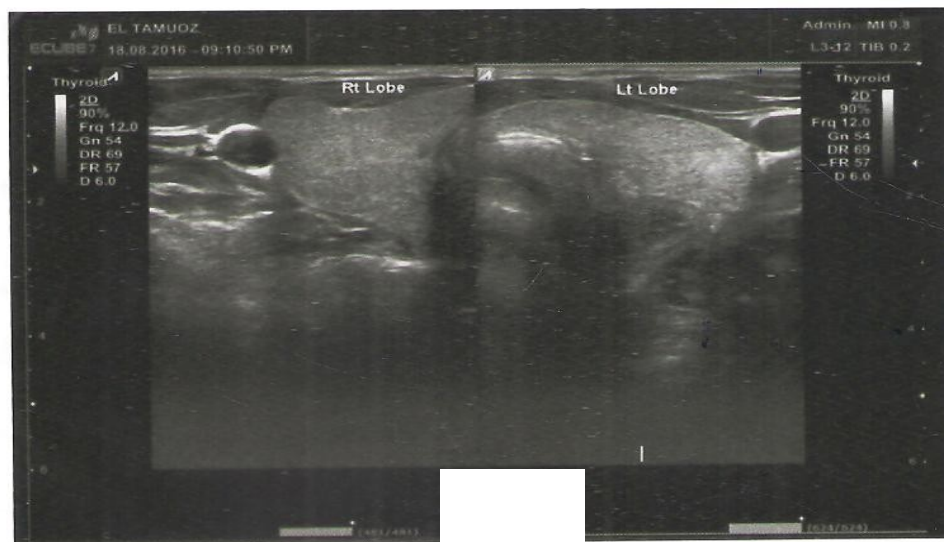


Fig 1.5 Sagittal and transvers scan to Rt and Lt lobe in 20 year female, length 165^{cm}, weight 78^{kg}, normal scan.

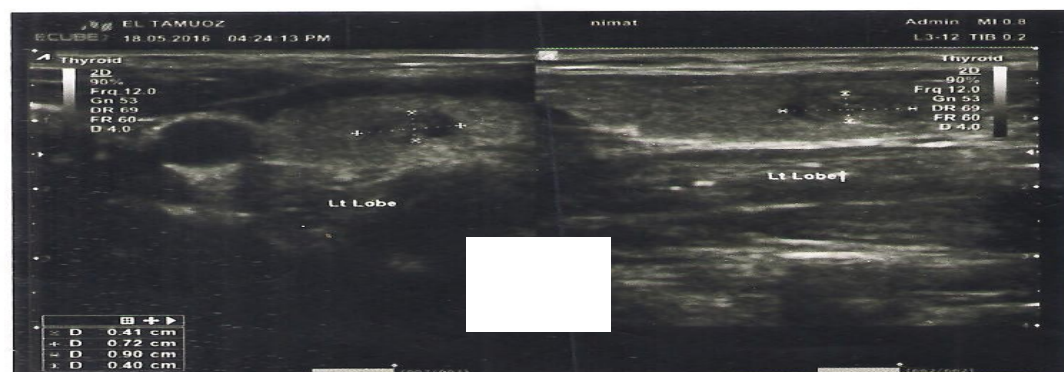
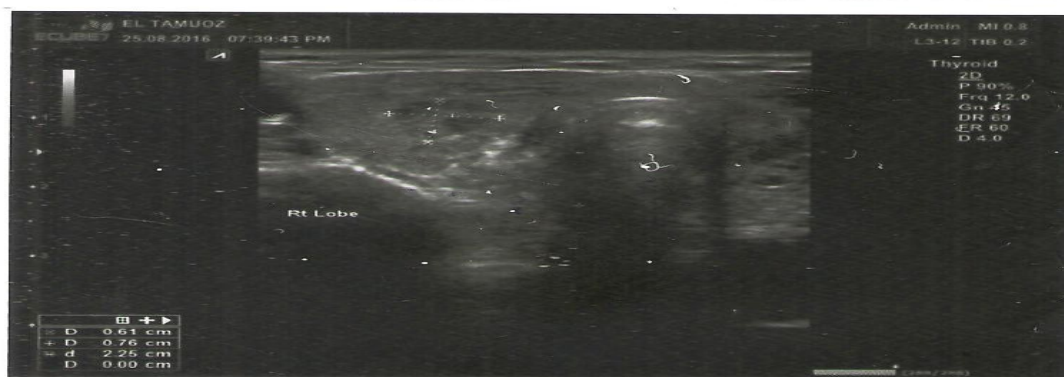
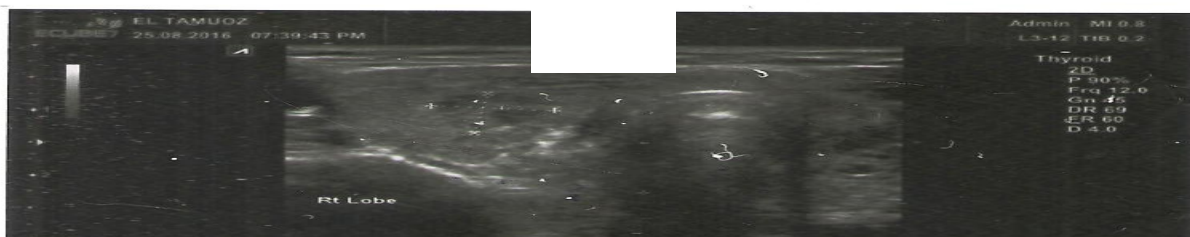


Fig 1.7 Sagittal and transvers scan to Rt and Lt lobe in 28 year female, length 158^{cm}, weight 55^{kg} with Lt lobe nodule

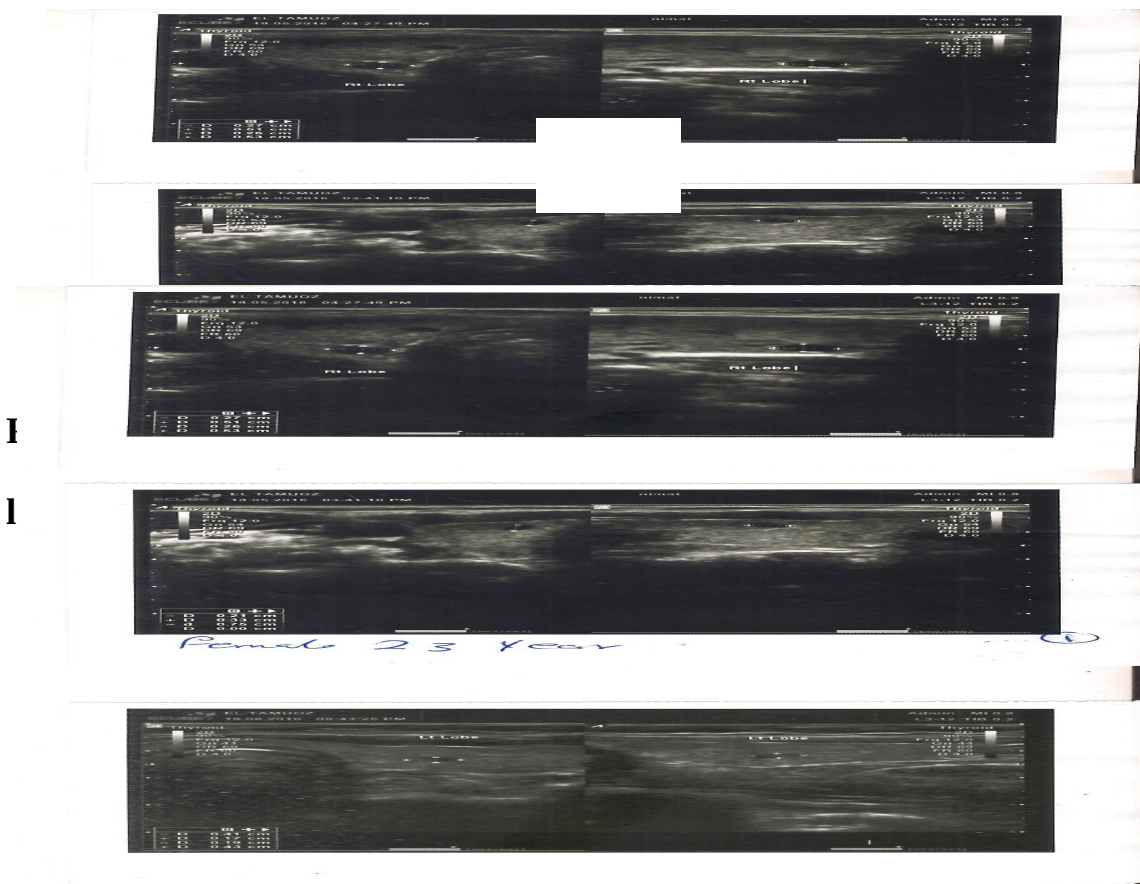
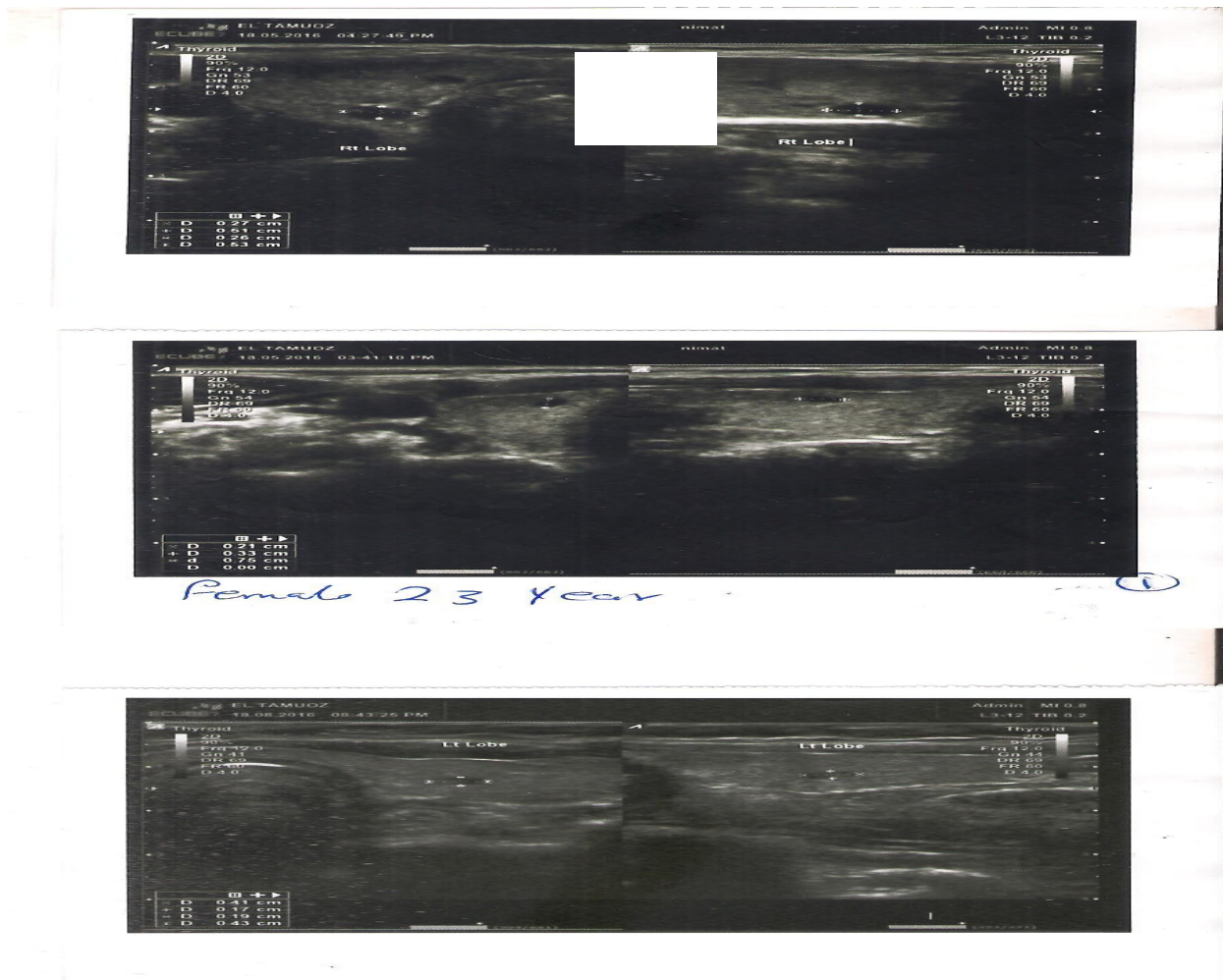


Fig 1.9 Sagittal and transvers scan to Rt and Lt lobe in 30 year female, length 158^{cm}, weight 65^{kg} with Rt lobe cyst



Sudan University of Science and Technology

College of Graduate Studies Early Detection of Thyroid Disorders using Ultrasonography

Data Collection Sheet Salma Mohamed Adam

No	age	sex	length	weight	occupation	findin g	echogenici ty
1							
2							
3							
4							
5							
6							
7							
8							
9							
10							
11							
12							
13							
14							
15							