

**Sudan University of Science and Technology**

**Collage of Graduate Studies**

**Study of MRI Image Artifacts in Khartoum State  
Centers**

**دراسة الشوائب الشائعة في صور الرنين المغناطيسي بمراكز ولاية الخرطوم**

A thesis submitted for partial Fulfillment for the Requirement of the M.SC Degree  
in Diagnostic Radiologic Technology

*-:By*

**AL-Motasem Bellah Yagoub**

*-:Supervisor*

**Dr. Ahmed Mostafa Abukonna**

January 2016



## الآية

قال تعالى :

(تَبَارَكَ الَّذِي بِيَدِهِ الْمُلْكُ وَهُوَ عَلَى كُلِّ شَيْءٍ قَدِيرٌ \* الَّذِي خَلَقَ الْمَوْتَ  
وَالْحَيَاةَ لِيَبْلُوَكُمْ أَيُّكُمْ أَحْسَنُ عَمَلًا وَهُوَ الْعَزِيزُ الْغَفُورُ )

صدق الله العظيم

سورة تبارك الآية 1 - 2

# **Dedication**

**.To my Mother**

**Brother..... and Sisters**

**.To my Fiancé**

**To my**

**.Friends**

**To my**

**.Colleagues**

# Acknowledgments

**First I would like to thank our God for enabling me to complete this thesis. I give my great pleasure to my supervisor Dr. Ahmed Abukonna for his Continuous .helping, guiding and supervision**

**Am also deeply grateful to Dr. Hussein Ahmed Hassan, Am also very grateful to many individuals who played a part in preparing this Work, Thanks to my family who always .encourages & supports me**

## Abbreviations

<b>MRI</b>	Magnetic Resonance Imaging
<b>NMR</b>	Nuclear Magnetic Resonance
<b>FSE</b>	Fast Spin Echo
<b>FOV</b>	Field of View
<b>PERU</b>	Physiological Electro-Cardiography Respiratory Unit
<b>ECG</b>	Electro- Cardiography
<b>RF</b>	Radio Frequency
<b>T</b>	Tesla
<b>SE</b>	Spin Echo
<b>CSF</b>	Cerebro Spinal Fluid
<b>TE</b>	Echo Time
<b>MRA</b>	Magnetic Resonance Angiography
<b>EPI</b>	Echo Planar Imaging
<b>KADC</b>	Khartoum Advance Diagnostic Center
<b>MR</b>	Magnetic Resonance

## List of tables

<b>Table</b>	<b>Title</b>	<b>page</b>
Table 3.1	MRI machine in AL-Zaytona Specialist Hospital	20
Table 4.1	Distribution of subjects by type of Artifacts in Brain site	26
Table 4.2	Distribution of subject by causes of Artifacts in Brain site	27
Table 4.3	Distribution of subject by type of Artifacts in Pelvis site	28
Table 4.4	Distribution of subject by causes of Artifacts in Pelvis site	29
Table 4.5	Distribution of subject by type of Artifacts in Cervical site	30
Table 4.6	Distribution of subject by causes of Artifacts in Cervical site	31
Table 4.7	Distribution of subject by type of Artifacts in Other Areas	32
Table 4.8	Distribution of subject by causes of Artifacts in Other Areas	33

### **List of Figure**

Figure	Title	Page
--------	-------	------



Fig 2.1	(Parts of Magnets (Shim coils	5
Fig 2.2	Gradient coils	6
Fig 2.3	(RF coils (Head coils	8
Fig 2.4	Ferromagnetic material+ A metal artifact	10
Fig 2.5	Phase Mismapping	11
Fig 2.6	Chemical shift Artifact	12
Fig 2.7	Truncation Artifact	14
Fig 2.8	Zipper Artifact	14
Fig 2.9	(Aliasing Artifact (Wrap around	15
Fig 2.10	Cross excitation and crosstalk	17
Fig 4.1	Distribution type of Artifacts in Brain site	27
Fig 4.2	Distribution of causes of Artifacts in Brain site	28
Fig 4.3	Distribution type of Artifacts in Pelvis site	29
Fig 4.4	Distribution of causes of Artifacts in Pelvis site	30
Fig 4.5	Distribution type of Artifacts in Cervical site	31
Fig 4.6	Distribution of causes of Artifacts in Cervical site	32
Fig 4.7	Distribution type of Artifacts in Other Areas site	33
Fig 4.8	Distribution of causes of Artifacts in Other Areas site	34
Fig A.1	Coronal SE T1 weighted image of the Abdomen showing Motion Artifact	39
Fig A.2	Axial SS-FSE T2 through the Liver showing	39

## .Phase Mismmapping Artifact

Fig A.3	Coronal FSE T2 Weighted image of the .Brain showing Motion Artifact	40
Fig A.4	Sagital SE T1 Weighted image of the Brain .showing Motion Artifact	40
Fig A.5	Sagital SE T1 Weighted image of the Brain .showing Aliasing Artifact	41
Fig A.6	Axial/oblique Flair image of the Brain .showing Aliasing Artifact	41
Fig A.7	Sagital T2 Weighted image of the Shoulder .showing Phase Mismmapping Artifact	42
Fig A.8	Sagital SE T1 Weighted image of the Brain .showing Phase Mismmapping Artifact	42

## ***CONTENTS***

10.....CONTENTS

## **Abstract**

The aim of this study was to evaluate the common Artifacts in MR images in Khartoum State centers and detecting their Causes in order to give a solution for each if possible. Using observation to calculate the data along 3 month on Khartoum specialist hospitals , Artifacts in magnetic resonance images, as in different Radiologic imaging Modalities are common and lead to misdiagnosis or at least decrease the Image quality. The causes are different and as a result there are many Types of Artifacts and The result showed that the most common Artifact is Motion record High percentage 63%, the second common Artifacts was Phase mismapping 30%, then Truncation 7%

Through my search for most common Artifacts in the magnetic resonance imaging centers in Khartoum state we found most common artifacts that is of patient movement (motion Artifacts) due to differentials reasons e.g.: unconscious patient ,lack cooperation .And Phase mismapping Artifacts appear from involuntary motion e.g.: chest moving during respiration, also Truncation Artifacts caused by different signals high and low signals duplication transition signals, common sites appear that's artifacts in cervical spine T1 sagittal . But there are some Artifacts such as lower rates e.g.: Cross Excitation Artifacts appears in spine (Lumbar) due to not Ensuring that there is at least a 30% gap between slices. There is a previous study in Sudan; I spoke on the subject but at different rates

## الملخص :-

الهدف من هذه الدراسة هو تقييم أشهر أنواع الشوائب التي تظهر في صور الرنين المغناطيسي, في مراكز ولاية الخرطوم, والكشف عن أسبابها من أجل إعطاء حل لكل إذا كان ذلك ممكنا. وذلك بالملاحظة لحساب البيانات على مدى 3 أشهر في المستشفيات المتخصصة في ولاية الخرطوم. الشوائب في صور الرنين المغناطيسي تؤدي إلى تشخيص خاطئ فتقلل من جودة الصورة. لذلك الشوائب لها أنواع وأسباب مختلفة. فنجد أكثر أنواع الشوائب انتشارا ناتجة عن حركة المريض سجلت أعلى نسبة تصل إلى 63%, ويأتي تانيا من حيث تسجيل أعلى نسبة الشوائب الناتجة من الحركة الإرادية وتصل نسبة حدوثها ل 30%, وثالثا اختلاف الإشارات في الصورة من أعلى إشارة إلى أقلها ناتجة من تكرار الإشارة في موضع معين وتصل نسبته إلى 7%.

من خلال بحثي عن أشهر أنواع الشوائب في مراكز التصوير بالرنين المغناطيسي في ولاية الخرطوم, وجدت أن أكثر أنواع الشوائب ظهورا ناتجة عن حركة المريض ناتجة عن: المريض فاقد للوعي, وعدم تعاون المريض. ومن ثم النوع الثاني من أنواع الشوائب ناتجة عن الحركة الإرادية, مثل: تحرك الصدر أثناء التنفس. ثالثا ناتج عن إشارات مختلفة عالية ومنخفضة ناتجة عن إندواج الإشارات, وأكثر منطقة يظهر بها هي منطقة العنق, لكن هناك بعض أنواع الشوائب تظهر بنسب منخفضة, مثل: عدم التخطيط السليم لصورة الرنين المغناطيسي, وتظهر خاصة في صورة الفقرات البطنية نتيجة لأنه يجب أن لاتقل الفجوة عن 30% بين الشرائح. هناك دراسة سابقة في السودان, تحدثت عن الموضوع ولكن بمعدلات مختلفة.

# Chapter one

## -:Introduction 1-1

Artifacts in MR images refer to pixels that do not faithfully represent the anatomy being studied. (Mark. Brown, 2010). In the images, the general appearance is that the underlying anatomy is visualized, but spurious signals are present that do not correspond to actual tissue at the location. The artifact may or may not be easily discernible from normal anatomy, particularly if they are of low intensity, and may or may not be reproducible. Artifacts can be categorized in many ways. (Mark. Brown, 2010). Artifact is a structure that is not anatomically present but is visible in a MRI examination; they are sometimes present in MR images and tend to affect them. Radiologists should be able to recognize them in order to avoid diagnostic pitfalls but also try to prevent them from happening. (Zhu. Gullapalli, 2006). MRI artifacts, however, can also have clinical utility and even help radiologists to reach a diagnosis (Zhu. Gullapalli, 2006). To remedies of the artifacts that are controlled by operator variable parameters. (Boxerman. Weiss. Rosen, 1996). These artifacts can usually be ameliorated or avoided by altering parameters that are under operator control and employing remedial measures, thus maintaining good image quality and avoiding diagnostic errors, thereby enhancing the usefulness of MRI in clinical practice. (Boxerman. Weiss. Rosen, 1996)

Finally the high information content of MRI exams brings with it unintended effects, which we call artifacts. The purpose of this review is to promote understanding of these artifacts; so they can be prevented or properly interpreted to optimize diagnostic effectiveness. We begin by addressing static magnetic field .(uniformity. (Martin. Graves PhD, 2013

## **:Problems of the study 1.2**

There are many MRI artifacts their causes are unknown, in this .study there is a trial to know some of them

## **:Objectives of the study 1.3**

### **:General objectives 1.3.1**

The aim of this study was trying to understand the Artifacts to be in magnetic Resonance devices and find a way to remove them from the images because it causes problems in the proper diagnosis of .MRIs

### **:Specific objectives 1.3.2**

To determine the MR images artifacts in MR centers in Khartoum  
state.

To know and evaluate the causes of the causes of the MR images  
artifacts in MR centers.

To recommend how to avoid or treat the MR images artifacts

### **:Importance of the study 1.4**

.List the MRI artifacts and their causes in order to avoid them

.To gain a high images quality without any artifacts

## **Literature Review-2**

### **:The MR component 2.1**



## **:The magnet 2.1.1**

The homogeneous magnetic field required for MR imaging is generated by a strong magnet. This magnet is the most important and expensive component of the MR System. The strength of the magnetic field, expressed by the notation (B), or in the case of more than one field, primary field ( $B_0$ ) and the secondary field ( $B_1$ ), can be measured in one of three units: gauss

.(G), Kilogauss (Kg), and Tesla (T)

Tesla is the unit used to measure higher magnetic field strength. One Tesla equals 10,000 G. Most MR systems operate from as low as 0.3 T to as high as 2 T range. There are many hazards created by the presence of the magnetic field. Ferrous objects are attracted by the magnetic field and can act as projectiles, being pulled by the magnetic field if brought too close to the magnet. Serious injury or damage could result. Also, common hospital equipment may be adversely affected when in proximity to the magnetic field, or image quality may be affected

.by the presence of this equipment

-:There are three basic types of magnets used in MR systems

### **:Resistive magnets 2.1.1.1**

The magnetic field strength in a resistive magnet is dependent upon the Current which passes through its coils of wire the direction of main magnetic Field in resistive magnet follow the right hand thumb rule, and produces lines of flux running .horizontally from the head to the foot of the magnet

As resistive system primarily consists of loops carrying current, it is lighter in weight than the permanent magnet and although its capital quite high due to the large quantities of power required to maintain the magnet field. The maximum field strength in a system of this type is less than 0.3 T due to its excessive power .(requirement. (Catherine Westbrook. Et al 1998

### **:Permanent magnet 2.1.1.2**

Its magnet field is always there and always on full strength, so it costs nothing to maintain the field. The major drawback is that these magnets are extremely Heavy – many, tons in weight at the 0.4 Tesla level. A stronger field would require a magnet so heavy it would be difficult to construct. Permanent Magnets are getting smaller, but are still limited to low field strength. (Catherine .(Westbrook. Et al 1998

### **:Superconducting magnets 2.1.1.3**

Are the most commonly used a resistance decrease the current dissipation also decreases. A superconducting magnet is somewhat similar to resistive Magnet coils or windings of wire through which current electricity is passed create the magnet field. The important difference is that the wire is Continually bathed in liquid helium at 452.4 degrees below zero cold causes The resistance in the wire to be drop to zero, reducing cold causes the Resistance in the wire to be drop to zero; reducing the electrical requirement For the system and making it much more economical to operate. Superconductive systems are very expensive, but they can easily generate 0.5 Tesla to 2T field allowing for much high quality imaging. (Catherine Westbrook. Et .(al 1998

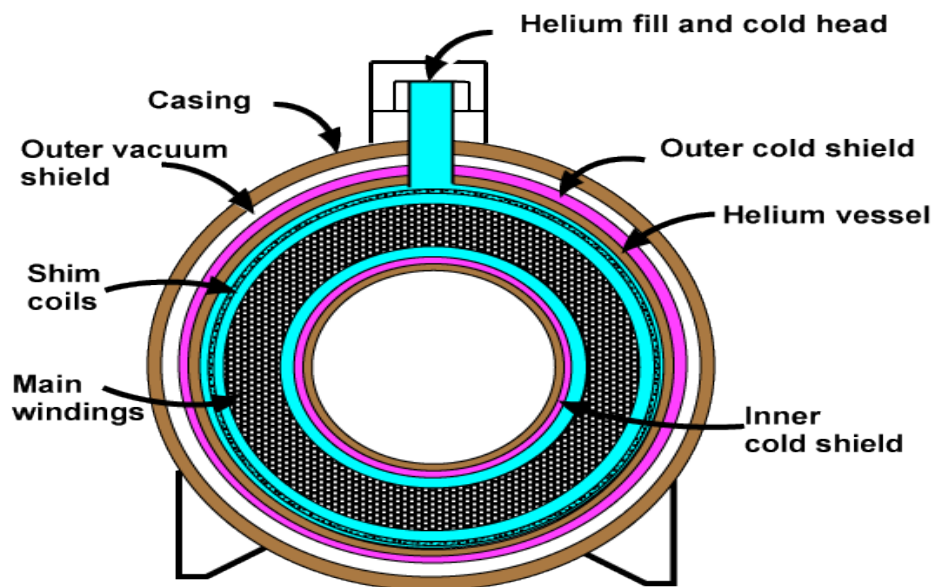
## **:The coils 2.1.2**

### **:Shim coil 2.1.2.1**

Due to design limitations it is almost impossible to create an electromagnet which produces a perfectly homogeneous magnetic field, to correct for these in homogeneities, other loops of current carrying wire are placed around the Bore, This process is called Shimming and the extra loop of wire is called a shim coil, Shim coils produce magnetic field evenness of homogeneity. For imaging Purpose, homogeneity of the order of 1.0 pmm is

required. Spectroscopic Procedures require a more homogeneous environment of 1 pmm.The shim system requires a power supply which is separate from the other Power supplies within the system. This is important because a fault in the shim Power supplies within the system. This important because a fault in the shim Power supply compromises image quality. (Catherine

.(Westbrook. Et al 1998



**(Fig (2.1): Parts of magnet (Shim coil**

### **:Gradient coils 2.1.2.2**

The gradient coils are the three sets coils within the magnet housing. Running through these coils in a specified manner creates controlled And graded variations in the static magnetic

field, thus affect nuclear Precessional frequency in away given voxel of anatomy and allowing for spatial Detection of signal within slice. An MRI systems uses three gradient coils, each affects a different plane, the XY, YZ or XZ plane, as it is turned on and off at different points in a pulse Sequence. How all three are used depends on the scan plane and the pulse Sequences being .used, the system calculated this automatically



**.Fig (2.2): Gradient Coils**

### **:RF coils 2.1.2.3**

MRI machines come with many different coils designed for different Parts of the body: knees, shoulders, wrists, head necks and so on. These coils usually conform to the contour of the body part being imaged, or at least reside very close to it during the exam. At approximately the same time. The three gradient magnets jump into the act. They are arranged in such a manner inside the main magnet that when they are turned on and off very rapidly in a specific manner, they alter the main magnetic field on a very low level. What this means is that we can pick exactly what area we want a picture of an MRI we speak of "slices". We can "slice" any part of the Body in any direction giving us huge advantage over any other imaging Modality. This means the machine will not move to get an image from a Different direction; the machine can manipulate everything with the gradient Magnets. RF coils are the "antenna" of the MRI system that broadcasts the RF signal to the patient and/ or receive the return signal. RF coils can be receive only, in which case the body coils is used as a transmitter, or transmit and receive (Transceiver). Surface coils are the simplest design of coil. They are simply a loop of wire, either circular or rectangular, that is placed over the region of interest. The depth of the image of a surface coils is generally limited to about one Radius. Surface coils are commonly used for spines, shoulders, TMJ's, and Other relatively small body parts. Paired saddle coils are commonly used for imaging of the

knee. These Coils provide better homogeneity of the RF in the area of interest and are used as volume coils, unlike surface coils. Paired saddle coils are also used for the X and Y gradient coils. By running current in opposite directions in the two halves of the .gradient coil



**(Fig (2.3): RF coils (Head coils**

### **:The Helmholtz pair's coils consist of 2.1.2.4**

Two circular coils parallel to each other. They are used as z gradient coils In MRI scanners. They are also used occasionally as RF coils for pelvis Imaging and cervical spine imaging. The bird cage coil provides the best RF homogeneity of all the RF coils. It has the appearance of a bird cage; hence, its name. This coil is commonly used as a transceiver coil for imaging of the head. This

type of coil is also used occasionally for imaging of the  
.extremities, such as the knees

### **:The Computer systems 2.1.3**

We have the computer that directs all of the action in the MRI acquisition and acquires and processes the data. The computer tells the gradient Amplifiers and RF transmitter when to run on and off to obtain the proper Pulse sequence. The RF receiver amplifier is also controlled by the computer and relays the signal received by the RF coil from the patient to the A-D Converter that digitizes the signal, and from there to the computer to be  
.reconstructed into an image

### **:MRI artifacts 2.2**

Items of magnetic resonance (MR) image, artifact is an abnormal area of Signal in the image that does not normally arise from patient anatomy or pathology. An artifact may be defined as an object that has been intentionally made or Produced for a certain purpose. Also an artifact' is sometimes used to refer to experimental results which are not manifestations of the natural Phenomena under investigation, but are due to the particular  
(experimental Arrangement. (Catherine Westbrook, 1999

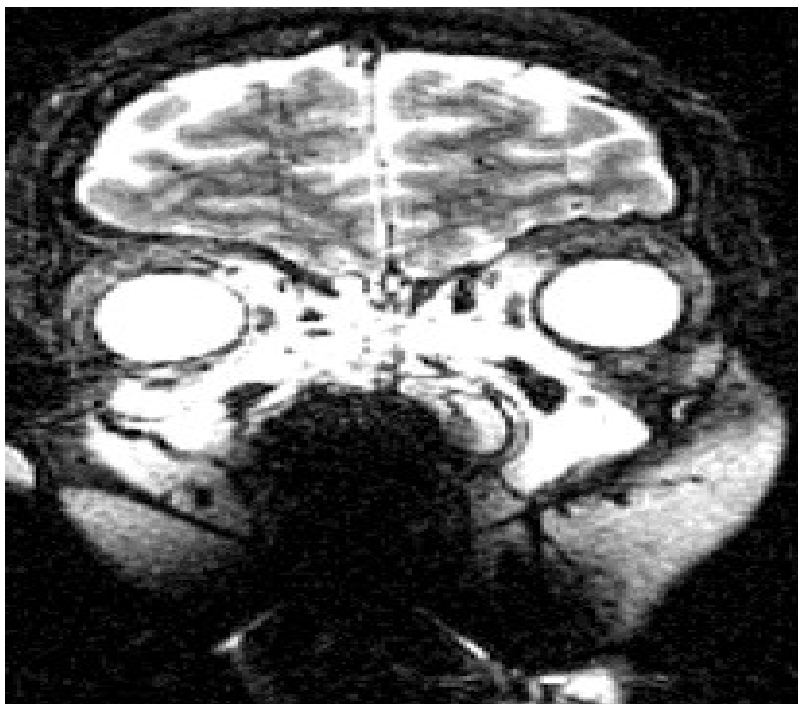


## **:MRI Artifacts: causes and their compensation 2.2.1**

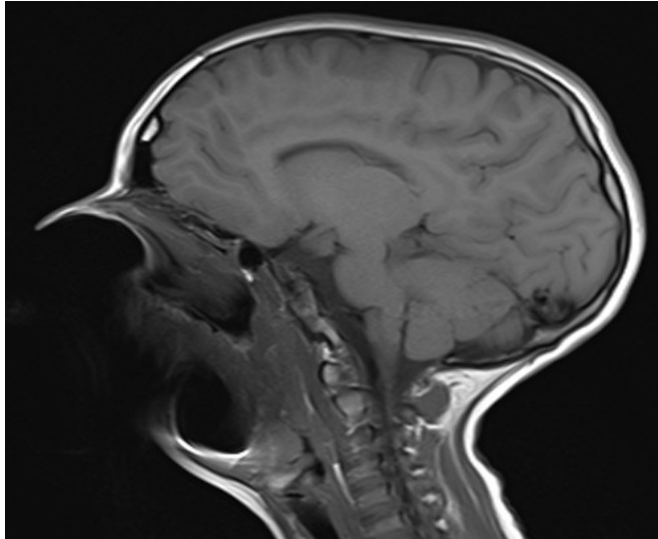
### **:Ferromagnetic Artifacts 2.2.1.1**

Magnetic susceptibility artifact) Magnetic susceptibility is the ability of a substance to be magnetized. Is caused by focal distortions in the main magnetic field due to presence of ferromagnetic objects such as orthopedic devices, surgical clips and Wire, dentures, and metallic foreign bodies in the patient. The artifact is seen as signal void at the location of the Meta implant, often with aim of increased intensity and distortion of the image

.in the vicinity



**.Fig (2.4): Ferromagnetic material**



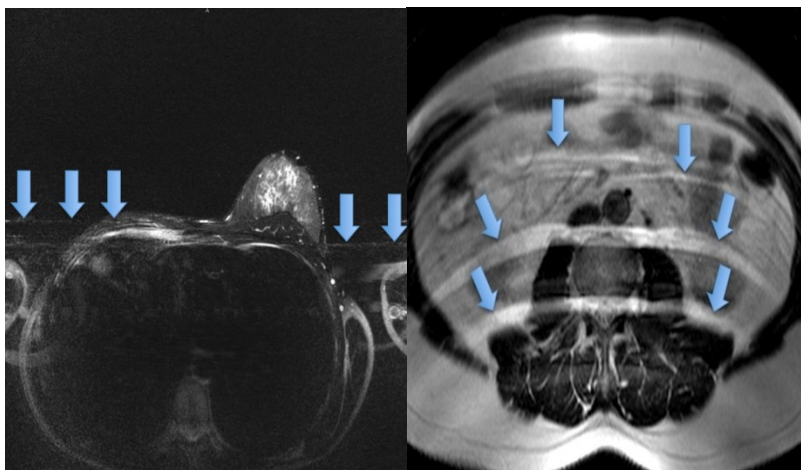
**.Fig (2.5): A metal artifact**

### **:The remedy of M.S 2.2.1.1.1**

- .A. Removed all metal items where possible before scan
- .B. The use of spin echo sequences reduces the artifact
- .C. MS can be used to aid diagnosis in case of hemorrhage

### **:(Phase mismapping (Motion Ghosting 2.2.1.2**

Is produced and originates from any structure that moves during Acquisition of data, for example, chest wall during respiration, Pulsate movement of vessels, swallowing, eye movement...etc. This artifact may result in fuzziness on the image or a lack of Details. Phase mismapping always occurs during along the phase encoding Axis. This due to the inherent time delay between phase .(encoding and readout. (Catherine Westbrook, 1999



**.Fig (2.6): Phase Mismapping**

**:The remedy of ghosting artifact 2.2.1.2.1**

Changing direction of phase encoding axis, so that the artifact

.does not interfere with area of interest

.Process known as pre-saturation null signal from specified areas

.Placing pre-saturation volumes over the area producing artifact

.Nullified signal and reduces the artifact

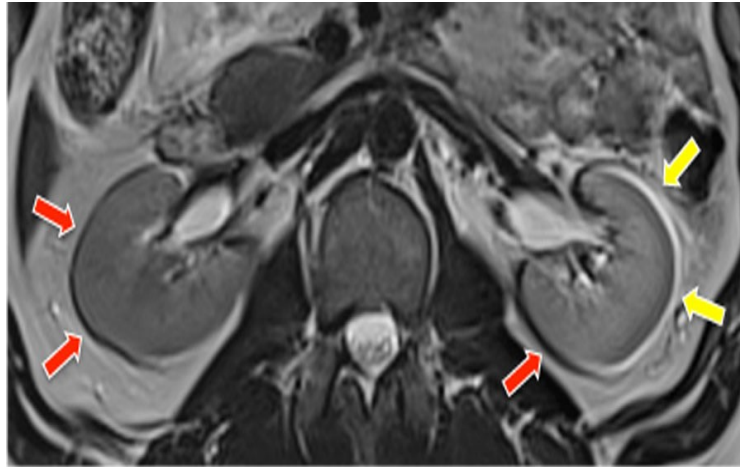
.Used respiration compensation

.(Gating (ECG, Peripheral

### **:Chemical shift Artifact 2.2.1.3**

Occurs at bound interfaces between fat and water. Proton in lipid molecules Experience a slightly lower magnetic influence than protons in water when exposed to an externally applied gradient magnetic field resulting in Misregistration of signal location. This occurs along the frequency encoding Axis. (Catherine Westbrook,

.(1999



**.Fig (2.7): Chemical Shift Artifact**

### **:The remedy of chemical shift 2.2.1.3.1**

.Scanning at low field

.Keeping (FOV) to minimum

At high field strengths the size of receive band width is the one

.way of Limiting chemical shift. Widest band width

### **:Chemical misregistration 2.2.1.4**

This artifact is caused by the difference in precessional frequency between Fat and water, which are in phase at certain times and out of phase at others. Fat and water in phase their signal is added, fat and water out of phase their signal cancel each other

out, this cancellation causes a ring of a dark signal around certain  
.organs where fat and water interface occur within the same voxel

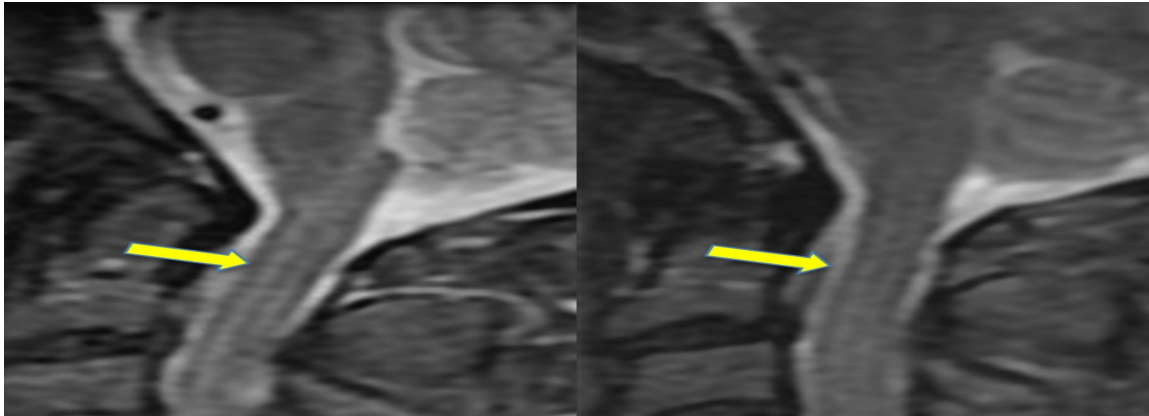
### **:The remedy of chemical misregistration 2.2.1.4.1**

.Use (SE) or fast spin echo (FSE) pulse sequences

Use a TE that matches the periodicity of fat and water so that the  
.echo is generated when fat and water are in phase

### **:Truncation artifact 2.2.1.5**

This artifact results from under sampling of data at the interface of high and low signal, which are incorrectly represented on the image. A common site for this artifact is in T1 sagittal image of cervical spine, where There CSF and spinal cord (Gibbs artifact). Occurs in phase direction. The truncation artifact appears as multiple rings of regular periodicity or duplication at transition between high and low intensity signals. (Catherine Westbrook, .(1999



**.Fig (2.8): Truncation Artifact**

### **:The remedy of truncation 2.2.1.5.2**

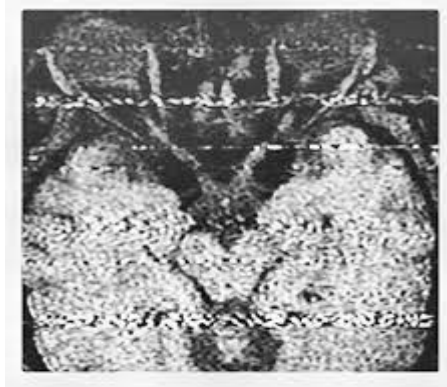.A. Increase the number of phase in coding steps

.For example, use 256\*256 matrixes instead of 256\*128

### **:Zipper artifact 2.2.1.6**

This artifact appears as a dense line on the image at a specific point. This is caused by extraneous RF entering the room at certain frequency, and interfering with the inherent weak signal coming from the patient. It is caused by a leak in the RF shielding

.(of the room. (Catherine Westbrook, 1999



**.Fig (2.9): Zipper Artifact**

### **:The remedy of zipper artifact 2.2.1.6.1**

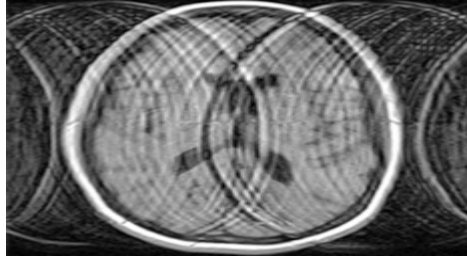
.Call the engineer to locate the leak and require it

### **:(Aliasing artifact (Wrap around 2.2.1.7**

Aliasing is an artifact produce when anatomy that exists outside the F.O.V is mapped inside the F.O.V. for example: on a midline sagittal brain MR image, the patient nose may artifactually displayed over the area of Posterior fossa. Aliasing can occur along both the frequency and phase axis. The appearance is as though the image that was not properly sampled has been folded

.(over on the opposite of the image. (Catherine Westbrook, 1999





**.(Fig (2.10): Aliasing Artifact (Wrap around**

### **:Frequency wrap 2.2.1.7.1**

Aliasing along the frequency encoding axis this is caused by under sampling the frequencies that are present in the echo, these frequencies originate from any signal. Regardless of whether the Anatomy producing it is inside or outside the  
 .(selected F.O.V. (Catherine Westbrook, 1999

### **:Phase wrap 2.2.1.7.2**

Aliasing along the phase encoding axis. This is caused by under sampling along

The phase axis, every phase value must be mapped into FOV in  
the phase encoding direction

### **:Anti-aliasing 2.2.1.7.3**

#### **:Anti-aliasing along frequency axis**

Termed on frequency wrap uses digital RF phase to cut off signal  
frequencies

At the edges of the F.O.V along the frequency axis. (Catherine  
(Westbrook, 1999

#### **:Anti-aliasing along the phase axis 2.2.1.7.4**

Termed no phase wrap. No phase wrap over samples along the  
phase Encoding axis by increase the number of phase encoding  
axis by Increasing the number of phase encoding perform. This  
(done by Enlarging the F.O.V. (Catherine Westbrook, 1999

### **:Shading artifact 2.2.1.8**

Appears as a loss of signal intensity in one part of the image. Its  
main cause is uneven excitation of nuclei within the patient due  
to RF pulses applied at Flip angles other than 90 degree and 180  
degree, may occur with a large patient, who touches side of the

body coil and couples it at the point. Can also be caused by inhomogeneities in main magnetic field. (Catherine Westbrook, 1999).

### **:The remedy of Shading 2.2.1.8.1**

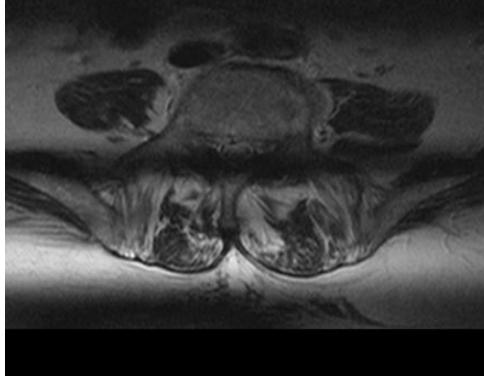
.Always ensure that the coil is loaded correctly

.Patient is not touching the coil at any point

Ensure that appropriate pre-scan parameters have been obtained before the Scan, as these determine the correct excitation frequency and amplitude of Applied RF pulses

### **:Cross excitation and cross talk 2.2.1.9**

Energy given to nuclei in adjacent slices by the RF pulse, so that they become saturated when they themselves are excited. The effect is produced by energy dissipation to adjacent slices, as nuclei within the selected slice relax to  $B_0$ . Cross excitation and crosstalk affect image contrast



**.Fig (2.11): Cross excitation and crosstalk**

## **The remedy of cross excitation and 2.2.1.9.1 :crosstalk**

.Ensuring that there is at least a 30% gap between slices

.Squaring off the RF pulses by software

## **:Motion of the patient 2.2.1.10**

Any motion of the patient causes artifact – motion is usually either Involuntary (twitching, pulsation, bowel motion) or voluntary (Swallowing, nervousness), and cause image degradation. Motion artifacts are always propagated in the phase – encoding direction. Random patient motion appears as a blurring of the image.

.((Catherine Westbrook, 1999

## **:The remedy of Motion 2.2.1.10.1**

Involuntary motion can often be compensated for bowel motion can be reduced by giving the patient an anti - spasmodic agent .prior to the scan when imaging the abdomen or pelvis

Pulsation can be reduced by the use of pre - saturation gating or .gradient moment nulling techniques

Increasing NEX may also help, as this increases the number of times the signal is averaged. Motion artifact is averaged out of .the image s it is more random in Nature than the signal itself

Voluntary motion can be reduced by making the patients as comfortable as Possible and immobilizing them with pas and .straps

A nervous patients always benefits from thoughtful explanation of the Procedure, and a constant reminder over the system inter .come to keep still

A relative or friend in the room can also help in some .circumstances

### **:Previous study 2.3**

In one previous study done by Zohal Mubarak Ali, showed that the most common Artifacts are motion, Aliasing, Zipper, metallic, cross Artifacts. But the motion Artifacts record high percentage 65%, the second common Artifacts was metallic Artifacts 17%, .then Aliasing Artifacts 7%, cross 6% and Zipper was 5%

## Chapter Three

### Material and Methods .3

#### :Materials 3.1

##### :Machine used 3.1.1

**Table (3.1) MRI machine in AL-Zaytona Specialist Hospital**

<b>Coils</b>	<b>Magnet power</b>	<b>Magnet type</b>	<b>Company</b>	<b>Center</b>
All the coils used, except Peripheral Vascular MR Angiograph .hy	T 1.5	Superconduc tive	Toshiba	Al- Zaytona specialist hospital

### **:Area and duration 3.1.2**

.Area: Al-Zaytona Specialist hospital -

.Duration: from November 2015 to January 2016-

## **:Methods of data collection 3.2**

### **:Practical Observation 3.2.1**

By observation and analysis of MR images which has common artifacts by Continuous visits to the AL-Zaytona Specialist

### **:Coils used method 3.2.2**

Coils design to optimize the RF spatial distribution and sensitivity. Specifically, two basic requirements must be fulfilled for obtaining high quality images: in the transmission mode, RF coils must be able to produce a uniform magnetic field in the volume of interest so that the nuclei can be properly excited; in the receiving mode, a high signal to noise ratio is needed, and the coil must be able to collect the signal emitted by the nuclei with better sensitivity throughout the volume of interest. A number of analytical and



numerical methods are reported in the literature to simulate the  
.RF field distributions of surface and volume coils

### **:Method of Instructions 3.2.3**

The main aspect of patient safety in any MRI facility is magnetic safety. It's essential that all patients, relatives, and other medical or non-medical Personnel are prevented from entering the magnetic field until they have been properly screened. Physical barriers, such as doors and large warning Signs are common ways of achieving this. Clerical personnel (who are usually at the entrance to the unit) should be aware of who is present in the facility and whether they have been checked for magnetic Safety. Thorough screening of each patient and anyone who is to enter the Field is extremely important. Failure to do so may result in  
.injury or even Death

### **:Patient care 3.2.4**

The main aspect of patient care in any MRI facility is magnetic safety. It is essential that all patients, relatives, and other medical or non-medical personnel are prevented from entering the magnetic field until they have been properly screened. Physical barriers, such as doors and large warning signs, are common ways of achieving this. Clerical personnel (who are usually

situated at the entrance to the unit) should be aware of who is present in the facility and whether they have been checked for magnetic safety. Thorough screening of each patient and anyone who is to enter the field is extremely important. Failure to do so may result in injury or even death. All centers should have a :proper screening policy which includes checking for

**.Pacemakers**

**.Aneurysm clips**

**.Intra-ocular foreign bodies**

**.Metal devices or prostheses**

**.Cochlear implants**

**.Spinal implants**

**.Possibility of early pregnancy**

**.Removal of all jewelers, credit cards, money, watches, etc**

There are many other aspects to patient safety within the unit. Care must be taken when transferring patients either on to trolleys or into the examination room. This is especially important if the patient is physically disabled, traumatized or in pain. Non-slip flooring, and trolleys with an adjustable height and lockable

brakes, not only ensures that patients are transported in safety, but also prevent injury to unit personnel. In addition, any equipment that comes into contact with the patient during the examination must be carefully checked on a regular basis. This includes Gating cables monitoring equipment and other devices such as coil holders. Properly informed patients are usually more comfortable with the examination than those who are fearful of the unknown. An information leaflet sent with the appointment time is a very effective way of preparing a patient for their visit to the unit. Once they have arrived, a careful explainedure including positioning, gradient noise, contrast of the injections, .and the approximate length of the examination is necessary

### **:Type of Fixation 3.2.5**

.External fixation devices- Internal fixation devices

### **:(Respiratory compensation (RC 3.2.6**

:There are many forms of respiratory compensation including

**Breath-holding (patient holds their breath during the  
.(acquisition**

**Navigators (a ROI is placed over the diaphragm and the  
system**

**Throws out data that coincide to maximum chest wall  
.(motion**

**Respiratory triggering (acquisition of data is limited to  
minimum**

**.(Chest wall motion**

**Respiratory compensation (RC) (phase encodings and  
therefore K**

**Space lines filled are re-ordered during the acquisition to  
minimize**

**.(Artifact**

### **:Leads placement 3.2.7**

There are usually four leads that are color coded for easy use.

Some systems

May only use three leads. In addition, not all systems use the  
same Color coding but the principle of their placement is the

same. Leads can be placed either anterior on the chest, or posterior on the patient's Back. Anterior placement is usually simpler as the landmarks are easier to Find. In addition if the leads are placed posterior, the patient lies on them during the examination, which may be uncomfortable. The anterior lead Placement is described here but if the trace on the ECG monitor is poor, the leads can be placed posterior in a mirror image to the anterior leads. This may improve the trace. Lay the patient supine on the examination Couch. The patient wears a front opening gown for easy access. The lead Stickers are then firmly attached to the patient's skin. The leads are usually Color coded thus

**Black**

**White**

**(Red (live**

**).(Green (ground or earth**

The white and the red leads are placed across the heart, as the voltage Difference between the two produces the ECG trace. The green lead is positioned as close as possible to, but not touching, the red lead as this Acts as a ground. The black lead also acts as ground. Some systems may not have color coding, but directions on lead placement are usually given by the manufacturer. Leads can be placed in a variety of ways as long as the above criteria are met

### **:The Data sheet 3.2.8**

Data Sheet for all technologists who work in the MR department  
.(4 technologists

By distribution of the data sheet to the technologist in the MR department which their number is (4) technologists, the findings of the data analysis was 100% of the staff proved that the most common Artifacts are motion, Phase mismapping, cross .excitation, truncation

### **:Data analysis 3.3**

By analysis of MR Image we found the motion artifact and phase mismmapping artifact, also cross excitation artifact. But the motion artifact is highest ratio and it is the common artifact in Khartoum .centers

## Chapter four

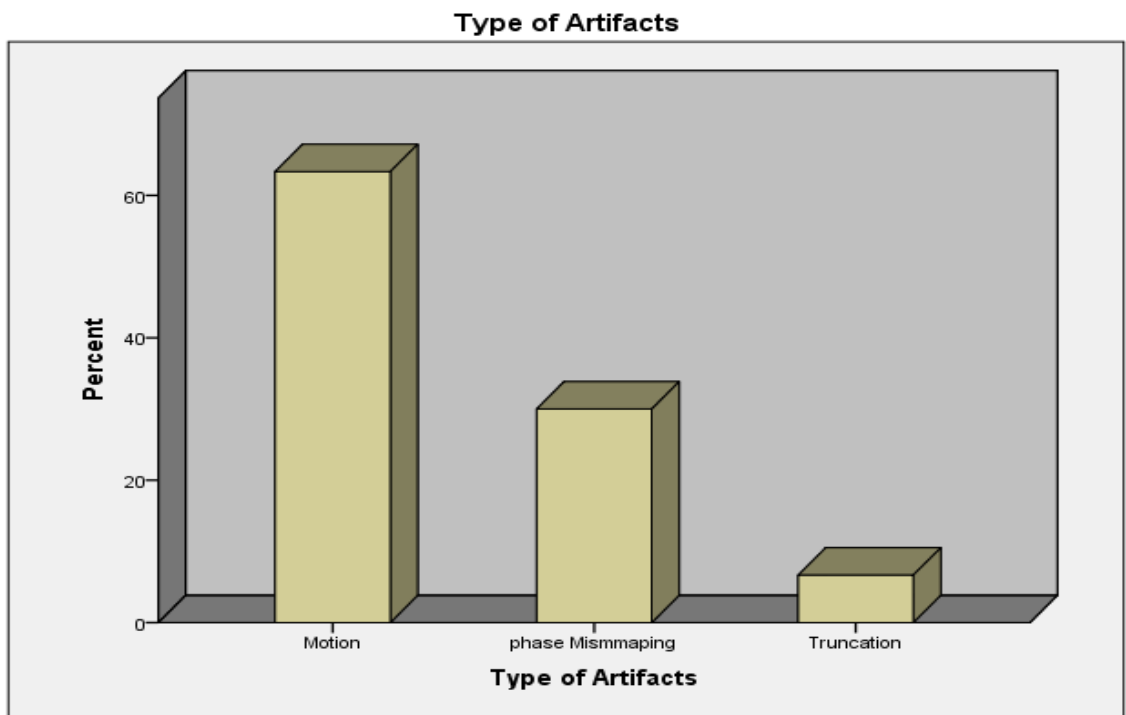
### Result .4

This study has been done in MRI department at the Al-Zaytona Specialist Hospital, for 60 subjects. The Total of the subjects 60 was classified into 2 groups, group one (Type of Artifacts), group two by (Causes of Artifacts) in different Organs (Brain, Pelvis, .(Cervical, Other areas

**Table (4.1): Distribution of subjects by type of Artifacts in .Brain site**

Percent	Frequency	Type of Artifact
63%	19	Motion
30%	9	Phase Mismmapping

7%	2	Truncation
100%	30	<b>Total</b>



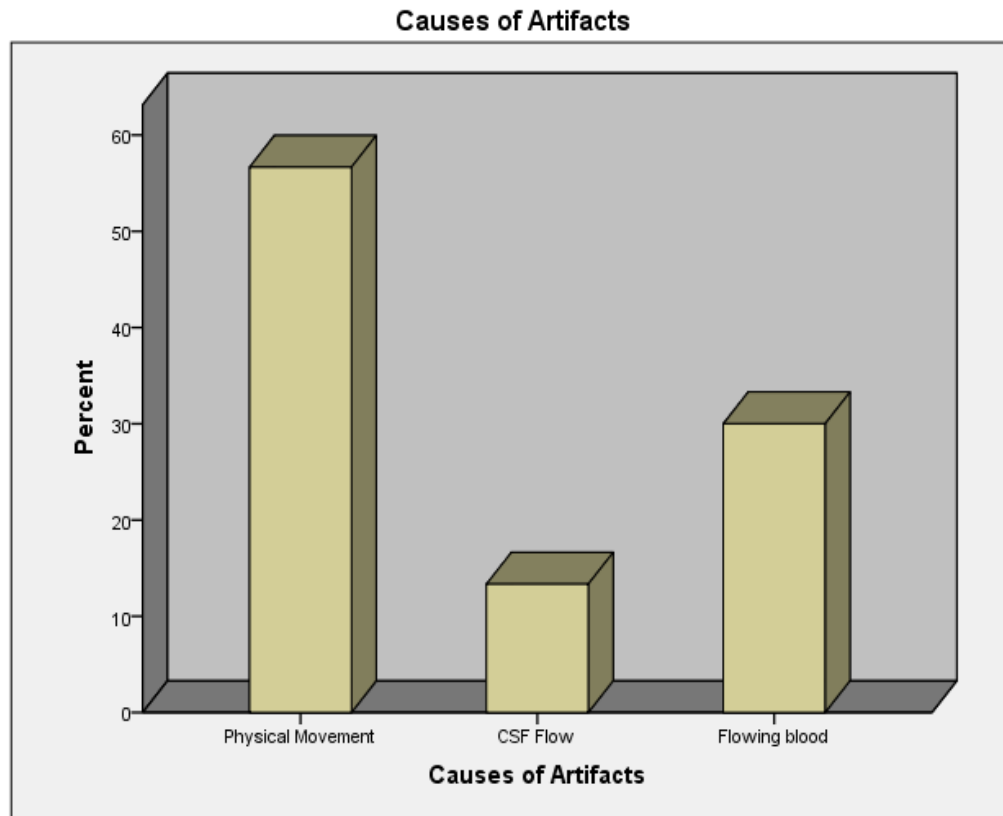
**.Figure (4.1): Distribution type of Artifacts in Brain site**

**Table (4.2): Distribution of subject by causes of Artifacts in**

**.Brain site**



Percent	Frequency	Causes of Artifacts
57%	17	Movement of the Patient
13%	4	From CSF Flow
30%	9	Flowing Blood in the Sagittal Sinus
<b>100%</b>	<b>30</b>	<b>Total</b>

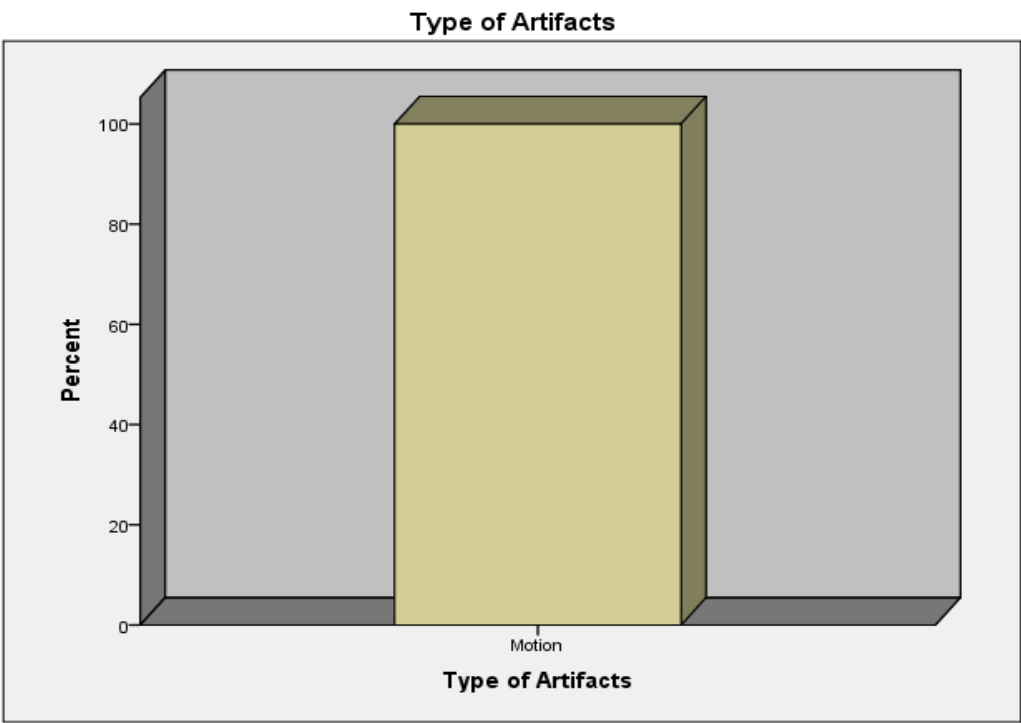


**Figure (4.2): Distribution of causes of Artifacts in Brain**

**.site**

**Table (4.3): Distribution of Subjects by Type of Artifacts in  
.Pelvis site**

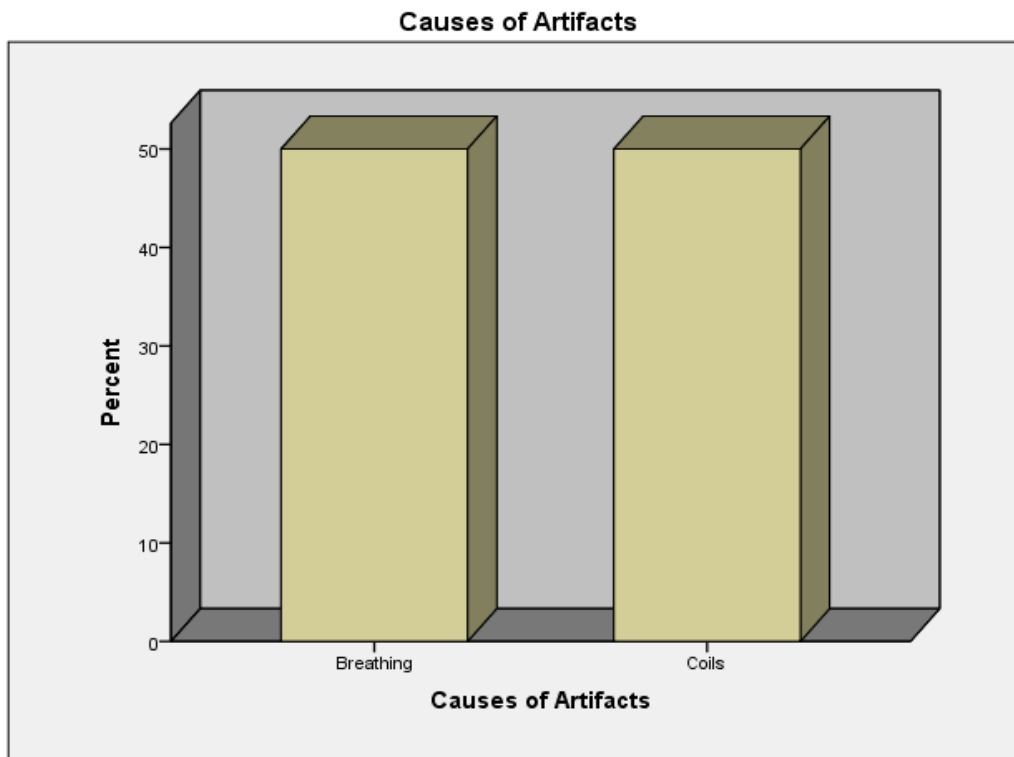
Percent	Frequency	Type of Artifact
100%	10	Motion
<b>100%</b>	<b>10</b>	<b>Total</b>



**.Figure (4.3): Distribution type of Artifacts in Pelvis site**

**Table (4.4): Distribution of Subjects by causes of Artifact  
.in Pelvis site**

Percent	Frequency	Causes of Artifacts
50%	5	Breathing
50%	5	Coils
<b>100 %</b>	<b>10</b>	<b>Total</b>




**.Figure (4.4): Distribution causes of Artifacts in Pelvis site**

**Table (4.5): Distribution of Subjects by type of Artifacts in**

**.Cervical site**

Percent	Frequency	Type of Artifacts
100%	9	Motion
100%	9	<b>Total</b>

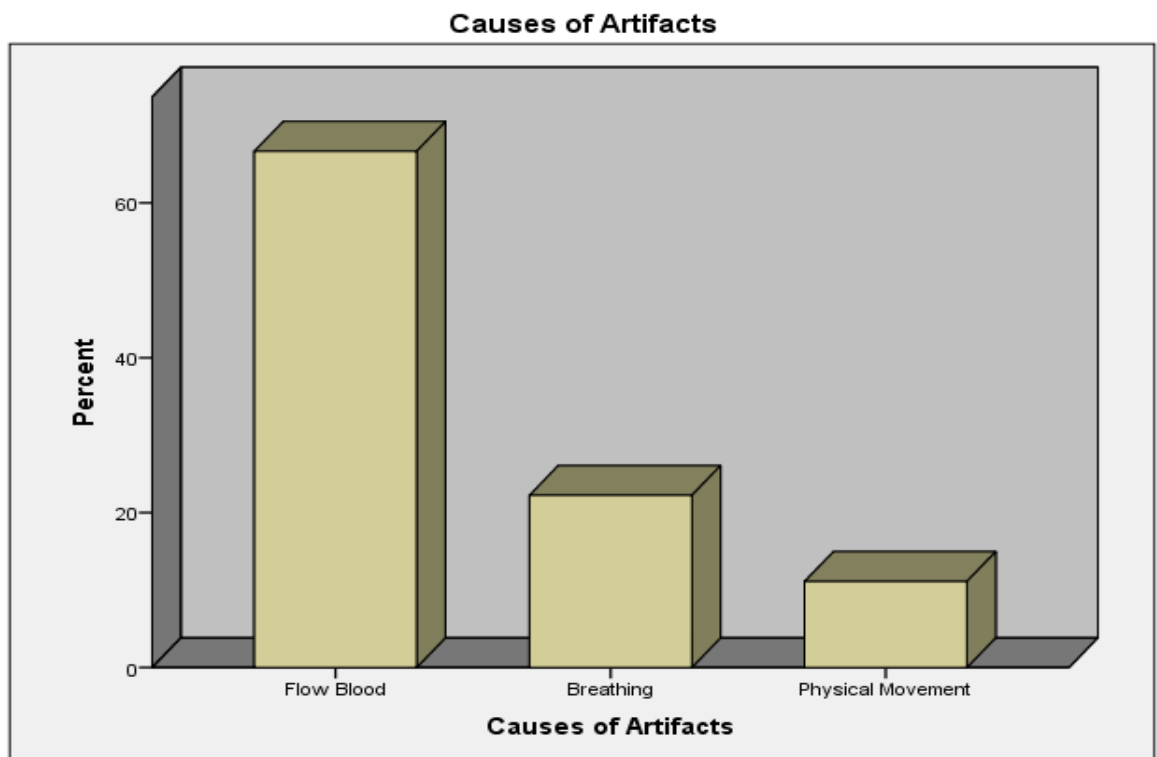


**.Figure (4.5): Distribution type of Artifacts in Cervical site**

**Table (4.6): Distribution of Subjects by causes of Artifact  
.in Cervical site**

Percent	Frequency	Causes of Artifacts
---------	-----------	---------------------

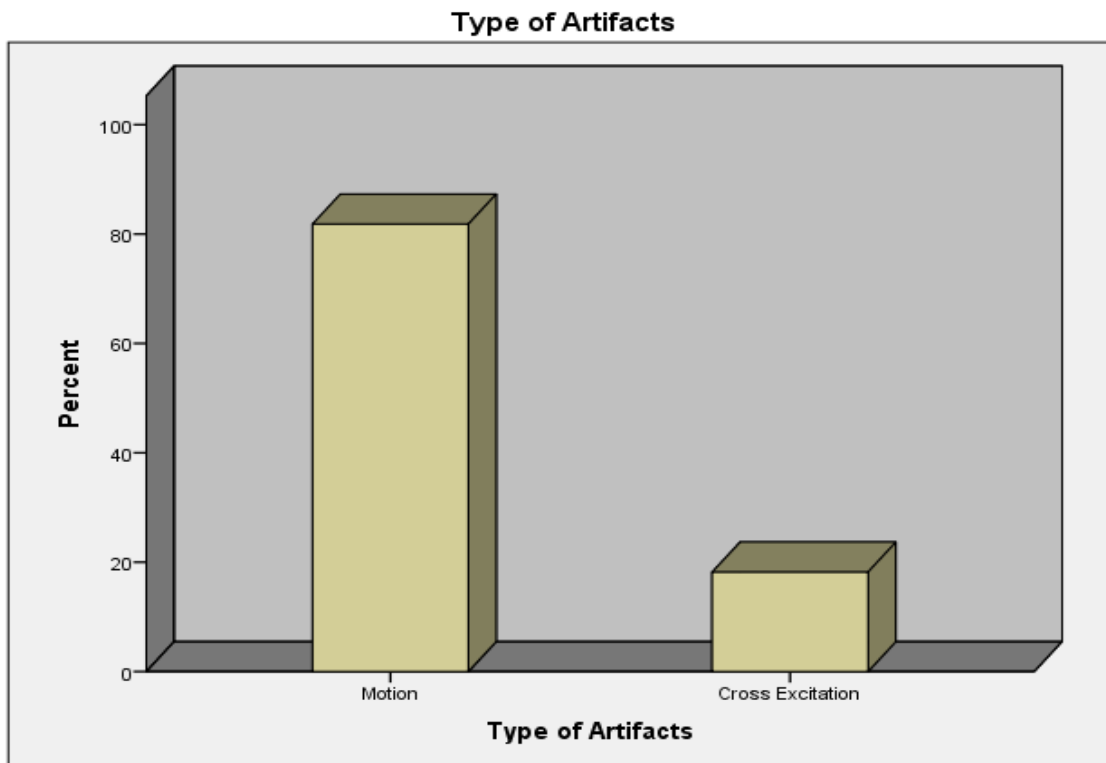
67%	6	Flow Blood in Carotid Artery
22%	2	Breathing
11%	1	Movement of the Patient
<b>100%</b>	<b>9</b>	<b>Total</b>



**Figure (4.6): Distribution causes of Artifacts in Cervical .site**

**Table (4.7): Distribution of Subject by type of Artifacts in .Other Areas site**

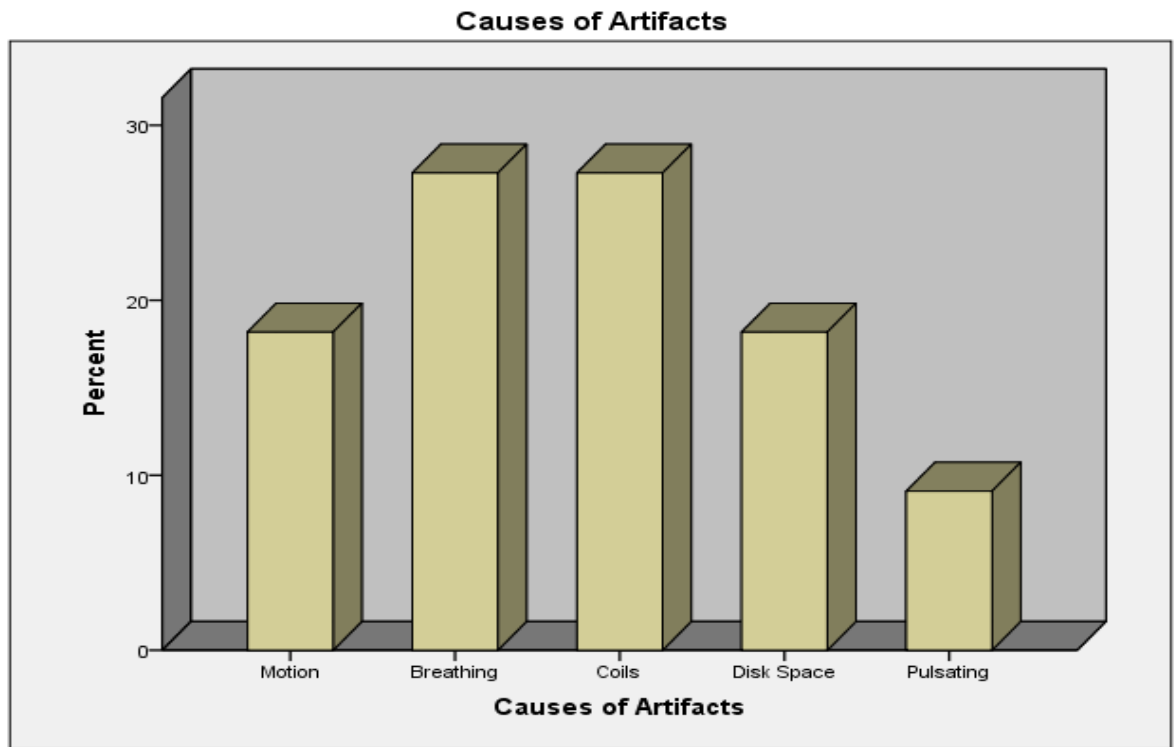
Percent	Frequency	Type of Artifacts
82%	9	Motion
18%	2	Cross Excitation
<b>100%</b>	<b>11</b>	<b>Total</b>



**Figure (4.7): Distribution type of Artifacts in Other Areas**  
**.site**

**Table (4.8): Distribution of Subjects by causes of Artifacts in  
.Other Areas Site**

<b>Percent</b>	<b>Frequency</b>	<b>Causes of Artifacts</b>
18%	2	Motion
27%	3	Breathing
27%	3	From the Coils
18%	2	Different disk space
9%	1	From pulsating in Popliteal Artery
<b>100%</b>	<b>11</b>	<b>Total</b>



**Figure (4.8): Distribution causes of Artifacts in Other .Areas site**



## **Chapter Five**

### **Discussion, conclusion and recommendations .5**

#### **:Discussion 5.1**

Artifacts in magnetic resonance images, as in different Radiologic imaging Modalities are common and lead to misdiagnosis or at least decrease the Image quality. The causes are different and as a result there are many Types of Artifacts. This aim of this study was to evaluate the common Artifacts in MR images in Khartoum State centers and detecting their Causes in order to give a solution for each if possible. We found the motion artifact has the highest ratio, and Phase mismapping artifact, also the Truncation artifact, and cross excitation artifact. More Organs have multiplied artifacts e.g.: the Brain lacks the patient's cooperation- and then the breathing. We found that Pelvis artifacts appear because of the Following reasons: the return from the coils is not stabile. And also we found Artifacts in the Cervical because of the following reasons: Motion of the patient-the flow of blood in the carotid artery. It also the artifacts appears in the: Shoulder- Abdomen- L/S- MRCP- Knee- Elbow- Orbits, that's because of the: Breathing- and Coils are not stabile- added to the motion of the Patient. Accordingly most technologists used FSE Sequence to reduce the Artifacts. All the Examination in department is done on Adults .because of the lack of the Anesthetic for children

## **Conclusion 5.2**

The result of statistical analysis showed the most common Artifacts (Motion) That is common causes of the patient motion are: Phobia, unconscious Patients, pain (especially in spine exam), a thematic 4 patients, long Scan time, cooling condition in examination room and case with head First like brain examination. There is a traffic Artifact which affects the MR image, and fortunately found the MR examination rooms support with shielding to prevent RF coming from round traffic and position of MR room in the center of Hospital departments. The rest of Artifact has programs in software that reduce them. Also, phase mismapping artifacts, Truncation artifact, and cross excitation artifact that the main factor to the control them is the technologies by his good skills and good instruction for the .patients

The most cases which has high ratio of Artifact are Brain, Pelvis, cervical, And Shoulder, the artifacts which caused by involuntary motion controlled By software and hardware and accessories added to the MR machines, and The Artifacts caused by voluntary

motion, controlled by technologists. High power of magnet play main role in improves image quality. Accessories added to machines reduced the ratio of Artifacts such as (PERU). Most of medical materials which used now a day- except electronic- to Insert in patient body, are made of non magnetic mineral, which allow the Patient to have MR image in time of necessity, without any side effect on Patient health. These types of materials are .pools, clips, and nails

### **:Recommendations 5.3**

Good instruction and explanation should be given for the •  
.patient

The patient must be comfortable as possible and •  
.immobilizing them with Pads and straps

- MR machine must be supported by essential accessories (PERU) such as (Respiratory compensation, cardiac and .peripheral gating) to avoid Involuntary motion •
- MR machine with magnetic power (1.5 T to above) should be .available in the centers •
- .Continuous education should be held for Technologists •
- .FSE) pulse sequence must be used as standard technique) •
- Technologists must take care to close the door of MR examination room tightly during the examination to prevent .extraneous RF entering the Room •
- The coils should be used according to the organs, and close the clips tightly during the preparation of the patient for .examination •
- The patient who has a Phobia to enter magnetic centre during Examination, optical system must be used, in order to withdraw the idea of their staying in magnetic centre. In .addition to head phone conducts with Relax audio source •

If the equipments mentioned above not offer, the patient •  
.should be Anesthesia and supervised during examination

## References

Catherine Westbrook Msc, DCR, CTC, and Carolyn Kaut RT ® (MRI)  
Technologist Instructor, MRI in Practice, 2nd edition, Oxford:

.Library of Congress, 1998

Catherine Westbrook, Training and Education, Health South (UK)  
PLC, Hand Book of MRI Technique, 2<sup>nd</sup> edition, Library of Congress,  
.1999

John A. Markisz, MD, PHD and Joseph P. Walen, MD, DSC Professor  
of Radiology, Principles of MRI, 2<sup>nd</sup> edition. London: Library of  
.Congress Cataloging- in - Publication date, 1998

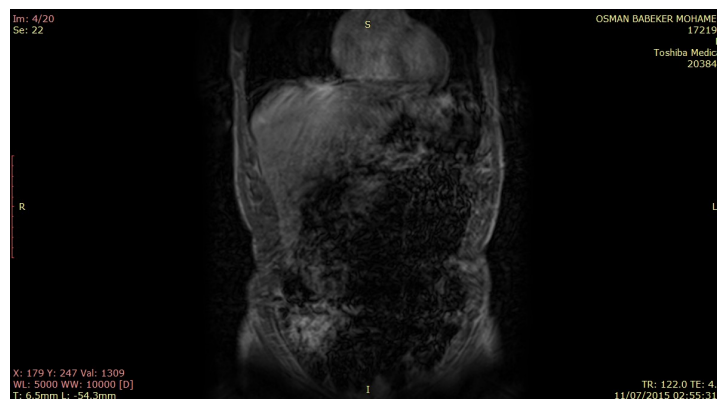
Mark A. Brown PhD, Richard C. Semelka M.D, MRI Basic Principles  
.and Applications, 4<sup>nd</sup> Edition, Wiley. Blackwell, 2010

Martin J. Graves PhD, Donald G. Mitchell M.D, Head of MR Physics  
And Radiology IT, Body MRI artifacts in clinical practice: A  
.Physicists And radiologists perspective, 1<sup>st</sup> Edition, 2013

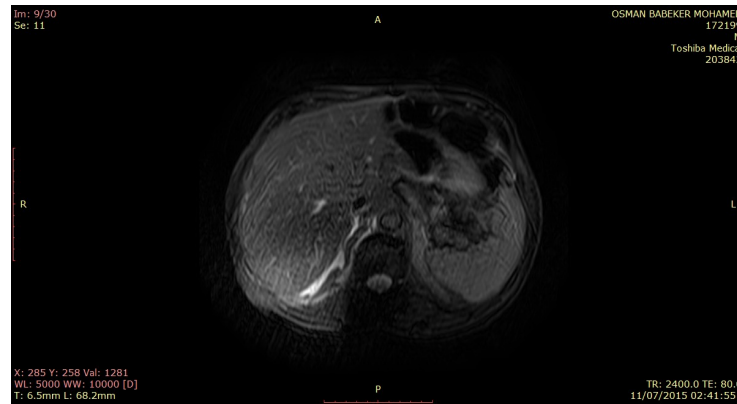
Pul M.Mattews,, Peter Jezard, and Stephen M. Smith, Department  
of Clinical Neurology, University of Oxford, UK, functional MRI, 1<sup>st</sup>  
.Edition, Oxford: Library of Congress, 2001

Zhu J, Gullapali RP. “Physics Tutorial for Residents: MR Artifacts,  
.Safety, and Quality control”, Radiographic, 2006

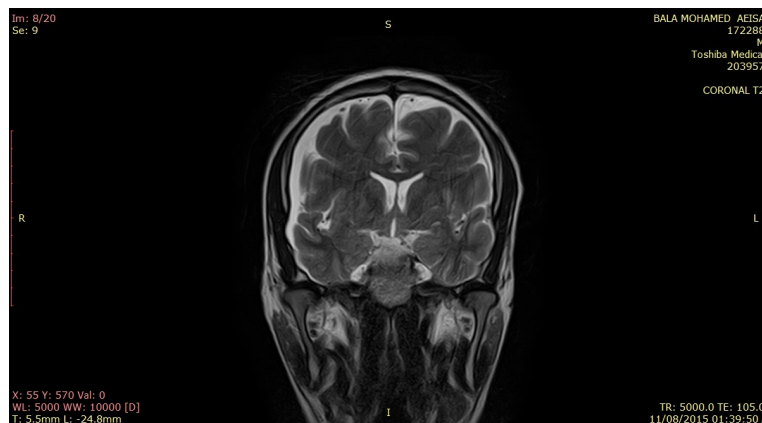
## (Appendices (A



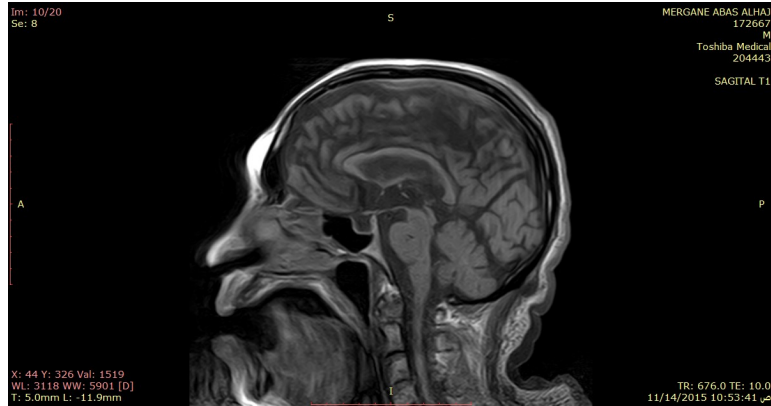**Figure (A.1) Coronal SE T1 weighted image of the  
.Abdomen showing Motion Artifact**



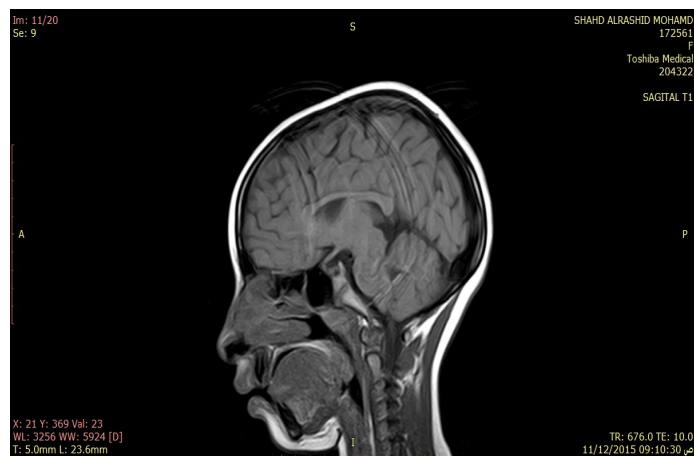**Figure (A.2) Axial SS-FSE T2 through the Liver showing  
.Phase Mismatching Artifact**



**Figure (A.3) Coronal FSE T2 Weighted image of the Brain  
.showing Motion Artifact**

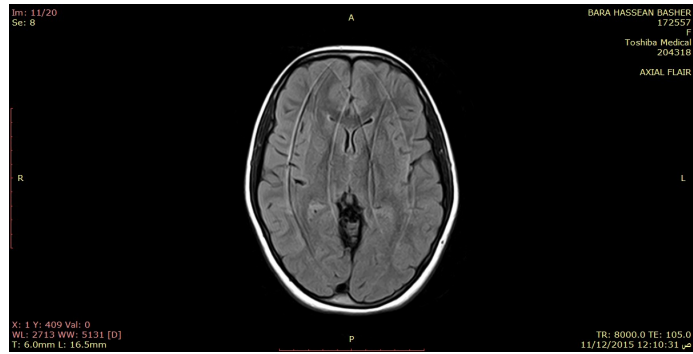


**Figure (A.4) Sagittal SE T1 Weighted image of the Brain  
 .showing Motion Artifact**

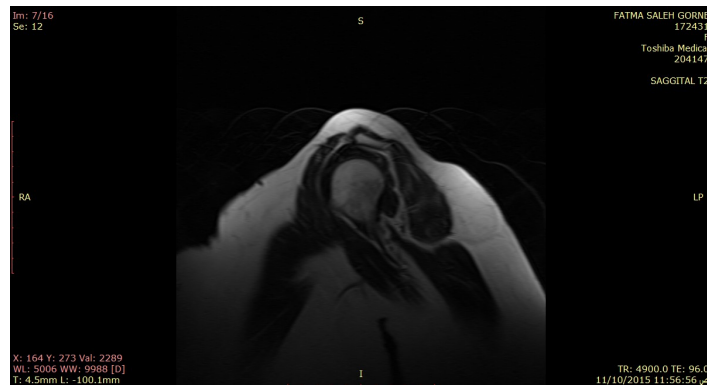


**Figure (A.5) Sagittal SE T1 Weighted image of the Brain  
 .showing Aliasing Artifact**

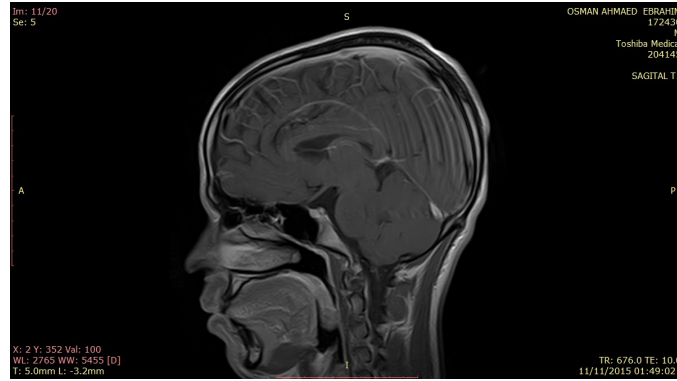




**Figure (A.6) Axial/oblique Flair image of the Brain showing  
.Aliasing Artifact**



**Figure (A.7) Sagital T2 Weighted image of the Shoulder  
.showing Phase Mismatching Artifact**



**Figure (A.8) Sagital SE T1 Weighted image of the Brain  
 .showing Phase Mismmapping Artifact**

## **(Appendices (B**

### **Study of MRI Image Artifacts in Khartoum state centers Data collection sheet**

:Hospital\*

.....

?Machine type \*

.....

?Magnetic type and power \*

.....

:Common artifacts\*

.....

.....

.....

?Causes of artifacts\*

.....

.....

.....