

Chapter One

1-1 Introduction

Chest trauma is classified as blunt or penetrating, with blunt trauma being the cause of most thoracic injuries (90%). The main difference lies in the presence of an opening to the inner thorax in penetrating trauma, created by stabbing or gunshot wounds, which is absent in blunt chest trauma (Shanmuganathan et al, 2006). Blunt thoracic injuries are the third most common ones in polytrauma patients following head and extremities injuries (Kaewlai et al, 2008). Although half of thoracic injuries are minor, 33% require hospital admission (Scaglione et al, 2008). Overall, blunt chest trauma is directly responsible for 25% of all trauma deaths (Scaglione et al, 2008) and is a major contributor in another 50% of trauma-related deaths. Moreover, chest trauma is the second most common cause of death, following only head trauma, and is by far the most common cause of death in the young age group between 15 and 44 years old (ACSCTL, 2007). Most blunt thoracic injuries are caused by motor vehicle crashes (MVC; 63–78%), with the remainder (10–17%) caused by falls from heights and a minority from blows from blunt objects or explosive devices (Mayberry, 2000).

Portable chest radiography is the initial imaging method used at the emergency workup of the polytrauma patient, and it is useful for detecting serious life-threatening conditions, such as a tension pneumothorax or haemothorax, mediastinal haematoma, flail chest or malpositioned tubes. However, the superiority of CT over chest radiography has been documented in the literature; CT detects significant disease in patients with normal initial radiographs and in 20% will reveal more extensive injuries compared with the abnormal initial radiographs, necessitating a change of management (Exadaktylos et al, 2001). CT is far more effective than chest radiography in detecting pulmonary contusion, thoracic aortic injury and osseous trauma, especially at the cervicorthoracic spine. MDCT has dramatically decreased imaging times and offers readily available multiplanar reformatted images or more sophisticated volume-rendered and MIP images. Therefore, it has been established as the gold standard for the imaging evaluation of chest trauma and trauma in general (Peters et al, 2010).

This review focusses mainly on the typical CT findings as well as the pitfalls associated with the wide spectrum types of injury in the thorax, including injury of the

pleura (haemothorax, pneumothorax), the lung parenchyma (contusion, laceration, lung herniation and blast lung), the trachea and airways, the aorta, the heart and pericardium, the oesophagus, the diaphragm and the thoracic wall. The possible coexistence of multiple types of injury is stressed.

1.2 Statement of the problem:

The increasing incidence of chest trauma, limitations of conventional x-ray facilities in emergency department are considered as main problems of this study.

1.3 General Objectives:

The general objective of this study is to study the chest trauma using CT and diagnostic radiography and to determine the accuracy, sensitivity, and specificity.

1.3.1 Specific Objectives:

- To determine the accuracy, sensitivity, specificity of CT in detection of vague chest trauma
- To compare between the conventional x-ray and CT findings
- To estimate the frequency of chest trauma in view of No%, gender, and age wise.
- To categorized the types, causes and anatomical site of chest trauma.

1.4 Thesis outlines:

The following thesis will be sketched in five chapters: Chapter one will deal with introduction, problem of the study, objectives and methodology. Chapter two will highlight the literature review, chapter three will shows the methodology. Chapter four will shows the results and discussion. Chapter five will introduce the conclusion, recommendation, references and appendices.

Chapter Two

Literature Review

Blunt trauma has been considering as very common worldwide with significant cause of mortality in younger adults. According to the World Health Organization data (WHO, 2012), in the United States, it is estimated that trauma is responsible for approximately 100,000 deaths annually. Most cases are related to high-energy mechanisms, such as motor vehicle accidents, motor cycle collisions, and falls (Karmy-Jones et al, 2001).

Biomechanics of injury/trauma

Four main mechanisms of injury are responsible for chest trauma: direct impact to the chest, thoracic compression, rapid acceleration/deceleration and blast injury.

Injuries from a *direct impact* are usually less dangerous and affect mainly the soft tissues of the chest wall (haematomas, rubbings). Occasionally, a localised injury to the osseous part of the chest wall can occur (rib fracture, sternal fracture and sternoclavicular dislocation) or, rarely, direct impact forces may be transmitted through the chest wall to the deeper organs, causing serious injury to the heart, lung or large mediastinal vessels.

In *thoracic compression* injuries intrathoracic structures strike a fixed anatomical structure—such as the chest or the spine—causing organ contusion or rupture. Thoracic compression may cause contusion or laceration of the lung parenchyma, pneumothorax or haemothorax, tracheobronchial fractures as well as rupture of the diaphragm.

In *deceleration injuries* the production of shearing forces causes direct compression against fixed points. This type is the most common and potentially lethal injury, and may cause major tracheobronchial disruption, cardiac contusions, aortic and diaphragmatic rupture (Scaglione et al, 2008).

Finally, with the increasing use of improvised explosive devices in terrorist attacks, *blast injuries* are occurring at an increasing rate. Explosion results from the instantaneous conversion of a solid or liquid material into gas after detonation of an explosive material. The blast pressure wave that is created exerts forces and pressure differentials mainly at air-tissue interfaces within the body, mostly affecting the pulmonary, gastrointestinal and auditory systems (primary blast injury). Secondary

blast injuries result from objects propelled by the explosion, impacting the individual, while tertiary injuries follow when the individual is being propelled by the explosion (Wolf et al, 2009; Wanek and Mayberry, 2004).

Accidents (unintentional injuries) are the fifth most common cause of death after heart disease, cancer, chronic lower respiratory diseases, and cerebrovascular accidents. In the United States, accidents (including motor vehicle accidents) continue to be the most common cause of death among people ages 15–44 accounting for approximately 40,000 deaths in 2010. Among people ages 15–24, motor vehicle accidents are by far the most common cause of death (Murphy et al, 2010).

In Sudan, recently the chest trauma noted to be increased with considerable victims, most of them due to traffic accident TA, or wars and other factors based on the general observation working field.

The general trend of diagnosis has been recon on the facilities of the emergency and traumatic sections within the hospitals and clinics, which are commonly equipped with conventional x-ray systems that show some shortening in view of blunt trauma diagnosis relative to CT imaging.

In previous studies related to this realm, there were considerable number of authors, wrote about this matter. For instant; Saugster et al, (2007), stated that: the information provided by multi detectors CT (MDCT) may lead to critical changes in patients' management and the clinicians and radiologist should be familiar with different aspects of MDCT evaluation of this subset of patient. While karmy-jones et al, (2001) stated that: Blunt chest trauma is very common in the united states and is a significant cause of mortality in younger adults. most cases are related to high energy mechanism, such as motor vechile accidents among people age 15-44 and falls 1.21 million people world-wide died from car accidents. 25% of death arise from chest injuries most common thoracic injury is a rib fracture.

In the study carried out by Ward et al, (2001); Bergin et al, (1981) to determine the accuracy of single detector helical CT (including coronal & sagittal reconstructions) for the diagnosis of diaphragmatic injury, 25 patients of CT scan surgically and 22 with surgical confirmed un injured diaphragm have been studied. The result showed that: the sensitivity, specificity, positive predictive value PPV and negative predictive value NPV and accuracy of helical CT were 84%, 77%, 81% and 83% in 2 patients to correctly identify diaphragmatic injury and the reconstructed images confirmed in 3 patients but supported an in correct diagnosis in 2 respectively. Such study prove that:

helical CT has good sensitivity, specificity and accuracy for the diagnosis of diaphragmatic injury.

The insensitivity of the AP chest radiograph in the diagnosis of pneumothorax in supine patients has invited research looking for other possible clues for suspecting the diagnosis. The clues that help in raising the suspicion of pneumothorax in the AP chest radiograph if the classic signs are not evident include (Hesham et al, 2010; Grainger et al, 2001; Armstrong et al, 2000; Gordon, 1980); The high visibility of the cardiophrenic sulcus, The deep sulcus sign which represent lucency of the lateral costophrenic angle extending toward the hypochondrium, Depression of the ipsilateral hemidiaphragm due to increased intrapleural pressure, Double-diaphragm appearance due to air outlining of the anterior costophrenic angle and aerated lung outlining the diaphragmatic dome, Improved sharpness of the cardiomediastinal border with a distinct cardiac apex due to anteromedial collection of air, which may appear as lucency. A sign known as crisp cardiac silhouette, Increased sharpness of the pericardial fat pads, which become rounded and lobulated in the presence of air in the pleural space because they are no longer flattened by contact with the adjacent lung, Visible inferior border of a collapsed lower lobe. A thin, sharp line may be detected which represents the inferior surface of the lung (visceral pleura) elevated and outlined by the inferior pneumothorax, A band of air in the minor fissure bounded by two visceral pleural lines and Visible lateral edge of the right middle lobe due to medial retraction in the presence of anterior pneumothorax.

There are several clinical markers that can predict for an increased incidence of pneumothorax even if not detected on the initial anteroposterior chest radiograph. These markers should be well known to emergency and ICU physicians for early suspecting the diagnosis. In this realm A level III retrospective study carried out by Ball et al, (2005), with a purpose to determine the incidence, predictors, and outcomes for occult pneumothorax after trauma concluded that: the presence of subcutaneous emphysema, pulmonary contusions, rib fractures and female sex were crudely associated with the presence of occult pneumothorax with an odds ratio of 5.47 for subcutaneous emphysema, 3.25 for pulmonary contusions and 2.65 for rib fractures. Although only 16% of patients with occult pneumothorax had subcutaneous emphysema, 98% of the patients with subcutaneous emphysema had an underlying pneumothorax whether overt (82%) or occult (16%).

Also in relation to such literature, Hesham et al, (2010) stated that: subcutaneous emphysema has a very high specificity for diagnosis of occult pneumothorax but its absence is insufficient to rule out the diagnosis. Therefore they suggested that any traumatic patient presented with subcutaneous emphysema, pulmonary contusion or rib fractures should be further evaluated with CT chest to exclude any underlying pneumothorax not visible on the regular chest radiograph, as Figure (2.1) demonstrates the predictability of occult pneumothorax. The presence of lung contusions and subcutaneous emphysema has prompted further evaluation with CT chest, which revealed a pneumothorax.

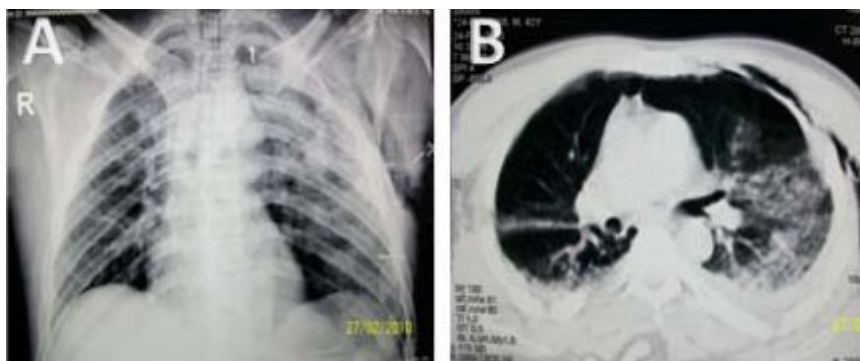


Figure 2.1: shows an AP chest X-ray revealing evidence of bilateral lung contusions and left subcutaneous emphysema (Panel A). Chest CT confirmed both the lung contusions and the subcutaneous emphysema and demonstrated a left sided pneumothorax not initially appearing on the anteroposterior chest X-ray (Panel B) (Hesham et al, 2010).

In the study carried out by Mivis et al, (1987) deals with the Role of CT in the diagnosis of major vascular rupture following blunt decelerating trauma during 12 month period in 20 patient with blunt decelerating Thoracic trauma who had abnormal on chest radiography. They revealed that: (2) Patients CT scans should evidence of direct aortic arterial injury in which the CT scan was considered equivocal; both patients had normal thoracic angiograms. CT excludes direct vascular injury mediastinal heamatoma in 10 patients. All 10 patients had normal thoracic angiograms. The preliminary study suggested that: in patients sustaining blunt thoracic CT may be more valuable than chest Radiography in excluding major vascular injury. In some cases, may reduce the need for Thoracic angiography.

As previously noted, chest CT is much more accurate than a chest radiograph in evaluating blunt thoracic trauma. It is such a trusted modality in detecting thoracic trauma that much of the literature treats contrast-enhanced chest CT as a gold standard (Traub et al, 2007; Barrios et al, 2010). However, given the increased cost and radiation dose from chest CT, some have questioned the routine use of chest CT in all cases of blunt trauma (Barrios et al, 2009; Tillou et al, 2009; Traub et al, 2007; Brink et al, 2010). Unfortunately, there are conflicting data on whether routine chest CT is necessary in the setting of blunt trauma.

In a prospective study of 464 consecutive patients with severe blunt trauma, all were scanned with contrast enhanced CT of the chest—routine multi detector CT (MDCT) algorithm (Brink et al, 2008). A selective MDCT algorithm subgroup of 164 patients was identified. This group was defined as patients in whom clinical or radiographic findings suggested a possible thoracic injury. Additional diagnoses (compared to radiography) were found more often in the selective group than in the routine group (59% compared with 43%, respectively). However, the routine MDCT algorithm resulted in 104 extra patients in whom radiographically occult findings were identified. In 34 of these 104 patients, there was a change in management, usually from additional pulmonary and mediastinal injuries.

In a small retrospective study of 93 patients with blunt trauma who were evaluated with AP chest radiography and chest CT, the authors identified 25 patients with normal chest radiographs (Exadaktylos et al, 2001). In 13 of these 25 patients, CT scans showed multiple injuries, including 2 aortic lacerations. The authors concluded that the routine use of chest CT is prudent to detect rare but important thoracic injuries.

Other studies, however, have found that routine use of chest CT may not be necessary in the setting of blunt trauma (Millo et al, 2011). In a retrospective study of 542 patients with a history of motorized blunt trauma who underwent full body CT, the researchers identified 108 patients who experienced no tenderness, deformity, or bruising over the chest, abdomen, or pelvis and no hemodynamic compromise. CT identified acute thoracic injuries in 11 of those 108 patients, but none required direct and immediate intervention. Eight of the 11 patients were either intoxicated or had distracting injuries. Based on their findings, the authors suggested that CT use is

likely of low yield in patients with normal examinations, with no distracting injuries, and with normal mental status.

Another group created a predictor of chest injury using chest CT based on a logistic regression analysis of 9 clinical and radiographic variables in 1,047 patients who suffered high-energy blunt trauma (Brink et al, 2010). They found that chest CT identified chest injuries in 13% of patients, who would not have been predicted to have chest injuries, and only 2% had injuries that were considered clinically relevant. The authors concluded that a selective model of chest CT use in the setting of blunt trauma is acceptable, given the low rate of clinically significant injuries detected by using their model, in addition to the low morbidity and mortality that arises from most chest injuries (small pneumothoraces, pulmonary contusions, and rib fractures). A similar study supported use of a predictive model based on radiographic, clinical, and demographic data to select patients in whom chest CT would be more likely to identify injuries (Kaiser et al, 2011)

A recent Appropriateness Criteria ACR topic on “Blunt Chest Trauma—Suspected Aortic Injury” (Demehri et al, 2012), supports the use of chest CT angiography (CTA) in combination with chest radiography without reservation. The authors reported evidence that CTA is highly sensitive (with a high negative predictive value) in evaluating suspected traumatic aortic injury when there are no signs of direct aortic injury. CTA is also highly specific for aortic injury, such that most centers have now abandoned invasive aortography in the initial assessment of patients with suspected aortic injury from trauma.

Sarita et al, (2009) carried out study to assess the role of multidetector spiral CT in patients with blunt chest trauma among Forty-two patients (38 males and four females), age range from 6 to 80 years, of blunt chest trauma were evaluated with multidetector computed tomogram (MDCT) after initial radiographs and the results showed that: various signs and symptoms were chest pain or tenderness, respiratory distress, surgical emphysema, decreased air entry, vomiting and abdominal guarding. Rib fracture was detected on chest radiograph in 25 patients and on CT scan in 26 patients. Scapular fractures were detected in four patients on chest radiograph and in seven patients on CT scan. Sternal fractures were detected in seven patients on CT,

which were not detected on radiography. Clavicular fractures were detected in four patients on chest radiograph and CT scan. Table 2.1 shows the sensitivity, specificity, positive predictive value, negative predictive value and accuracy for chest radiograph and CT for thoracic cage injury.

Table 2.1: Sensitivity, specificity, positive predictive value, negative predictive value and accuracy of chest radiograph and CT for thoracic cage injury (n=42) (Sarita et al, (2009)).

Finding	Sensitivity		Specificity		Positive		Negative		Accuracy	
	Chest Radiograph	CT	Chest Radiograph	CT	Predictive		Predictive		Chest Radiograph	CT
					Value		Value			
					Chest Radiograph	CT	Chest Radiograph	CT		
Rib fracture	96%	100%	100%	100%	100%	100%	94%	100%	97%	100%
Scapular fracture	57%	100%	100%	100%	100%	100%	92%	100%	92%	100%
Clavicular fracture	100%	100%	100%	100%	100%	100%	100%	100%	100%	100%

Also there were 15 patients of fracture of thoracic outlet, of these two (13%) had subclavian injury and one patient had brachial plexus injury. Spinal injury was seen in 17 patients (five thoracic and two lumbar). Pleural fluid was detected in 30 patients on ultrasound and in 35 patients on CT scan. In five patients, pleural fluid was not detected on ultrasound due to suboptimal scan because of surgical emphysema. Pneumothorax was detected in 23 patients, 14 patients had associated rib fracture and 19 patients had associated pleural effusion. In two patients, pneumothorax was found bilaterally due to a tracheal tear. Eleven patients were associated with surgical emphysema. In nine patients, underlying lung parenchymal injury was present. Pneumomediastinum was detected in six patients while pneumopericardium was not seen in any case. Table 2.2 shows the location of pneumomediastinum and associated injuries detected on CT in these patients.

Table 2.2: Location of pneumomediastinum and associated injuries detected on CT in six patients (Sarita et al, (2009).

Patient No.	Location of Pneumomediastinum	Associated Injuries				
		Lung Parenchymal Injury	Tracheal Tear	Oesophageal Rupture	Chest Wall Injury	Neck Structures Injury
1	Central pulmonary arteries and aorta	-	+	+	-	-
2	Arch of aorta	-	-	-	+	-
3	Ascending aorta central pulmonary arteries	-	-	-	+	-
4	Arch of aorta	+	-	-	+	-
5	Arch of aorta	+	+	-	-	-
6	Central pulmonary arteries	+	-	-	-	-

Pulmonary contusion was detected in 12 patients. The most common location of pulmonary contusion was at the site of impact usually adjacent to solid structures. Of the 12 patients, five were put on mechanical ventilator support. In three patients lung laceration was seen in association with pulmonary contusion. Out of 42 patients of blunt thoracic trauma, pulmonary laceration (Figures 2.2a and 2.2b) was detected in four patients.

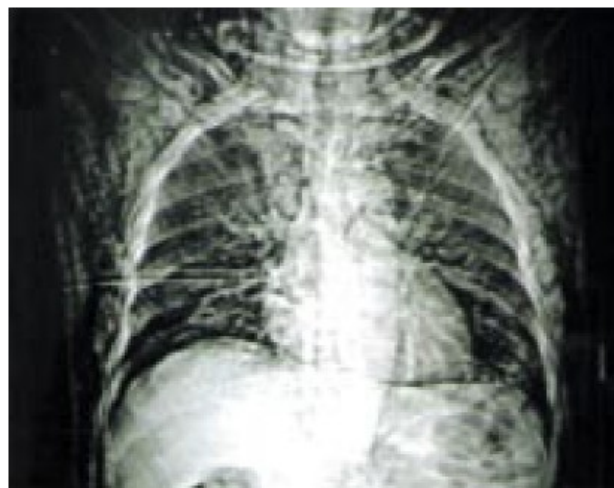

Figure 2.2a: Chest radiograph in a 46-year-old male patient with chest tenderness and increasing dyspnoea after blunt injury with a stone during an assault. It reveals extensive subcutaneous emphysema in neck and chest wall with chest tube *in situ* (Sarita et al, (2009).

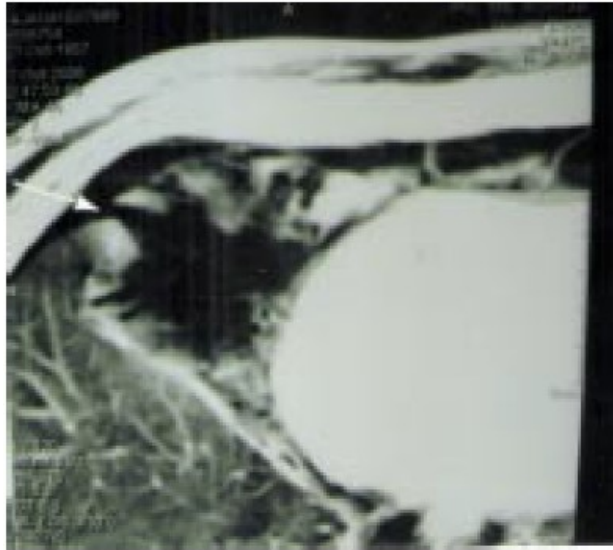


Figure 2.2b: Axial CT section showing linear tear through lung parenchyma seen as air containing line (arrow)-laceration Type 1 in the medial segment of the right middle lobe (Sarita et al, (2009).

Tracheobronchial injuries (TBI) were detected in two patients and were within 2.5cm of carina, and these were associated with pneumomediastinum and cervical emphysema (Figures 2.3a and 2.3b). Thoracic aortic injury (Figures 2.4a and 2.4b) was suspected on chest radiograph in three patients.

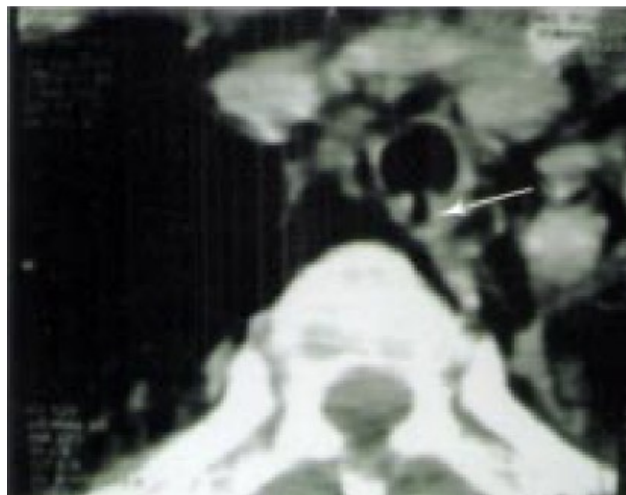


Figure 2.3a: Axial CT section at the level of the aortic arch in a 28-year-old male who sustained blunt force trauma in a fist fight. It shows discontinuity of posterior tracheal wall (arrow) with communication with oesophagus and air

tracking into mediastinum-tracheal tear with tracheo-oesophageal fistula (Sarita et al, (2009).

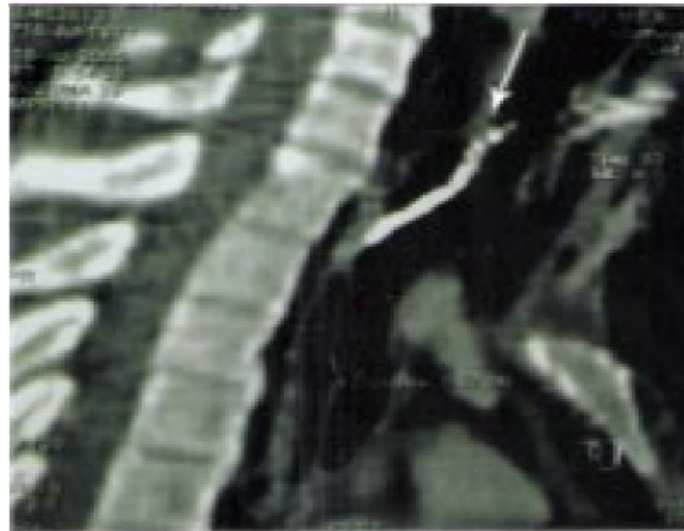


Figure 2.3b: Sagittal MPR showing tracheal tear with tracheoesophageal fistula (arrow) in the same patient (Sarita et al, (2009)).

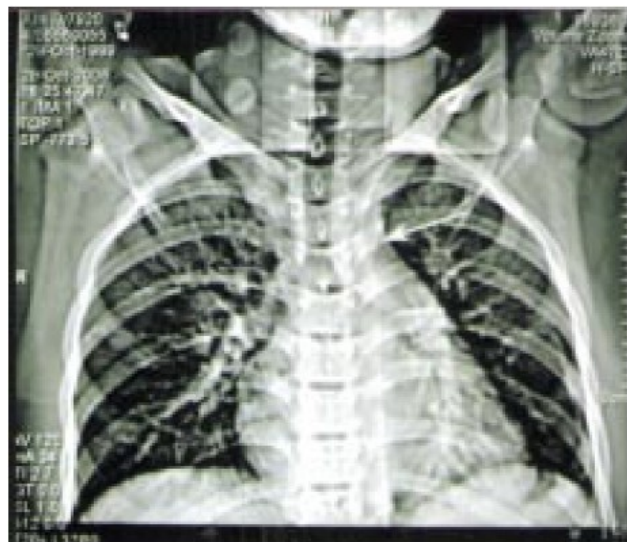

Figure 2.4a: Supine chest radiograph in a 17-year-old patient with blunt trauma due to fall while climbing a tractor. It reveals poorly defined aortic anatomy with widened superior mediastinum (arrow) (Sarita et al, (2009)).

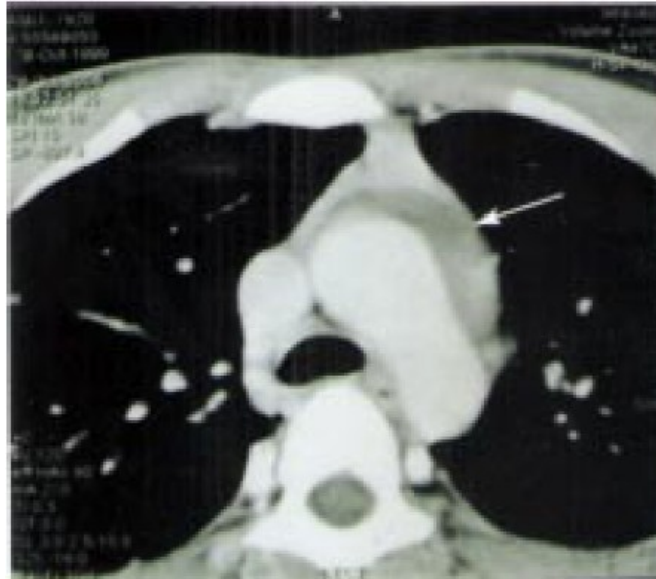

Figure 2.4b: Axial CT section at the level of the aortic arch showing periaortic mediastinal haematoma (arrow) (Sarita et al, (2009).

Computed tomography was performed in all. On radiographs, superior mediastinal widening, right-sided pleural effusion and fullness of the right paratracheal stripe were seen in two patients each, while bilateral pleural effusion and widening of the right paraspinal stripe were seen in one each. On CT, mediastinal/periaortic haematoma was seen in two patients, while indistinctness of mediastinal fat planes, fracture clavicle with fluid in adjacent tissues and subtle focal irregularity of aortic wall in ascending aorta were seen in one each. Diaphragmatic injury (Figures 2.5a and 2.5b) was detected in six patients on chest radiograph and in 13 patients on CT. In seven patients, diaphragmatic injury was not detected on the initial chest radiograph due to concurrent pulmonary contusion, pleural effusion, right sided injury and one patient on the left side without associated visceral herniation.

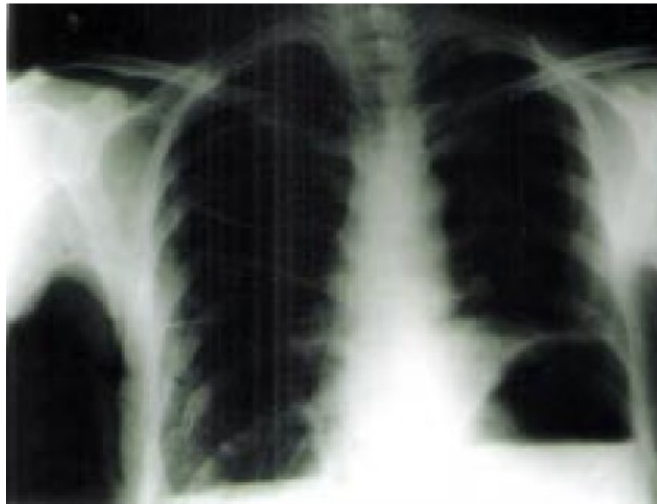

Figure 2.5a: Chest radiograph in a 40-year-old male patient involved in a road-side accident. It shows fracture ribs on right side with elevation of left dome of the diaphragm and air fluid level in left lower zone (Sarita et al, (2009))

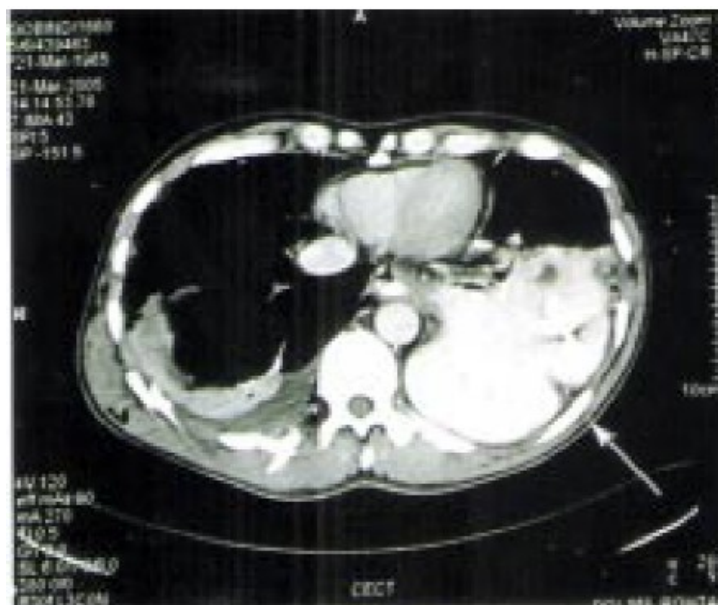


Figure 2.5b: Axial CT section at the level of lung base which shows stomach in left hemithorax with nasogastric tube in it. ‘Dependent viscera’ sign and ‘Collar sign’ (arrow) as seen in this figure are suggestive of diaphragmatic hernia (Sarita et al, (2009)).

Many cases of the chest traumas could be diagnosis and characterized precisely by MDCT, for instance: Pulmonary Contusion (*It is a focal parenchymal injury of the alveolar epithelium, with interstitial edema and alveolar hemorrhage, produced at the time of injury and usually adjacent to the area of trauma, but can also occur in a countercoup location*) (Mullinix and Foley, (2004); Oikonomou and Prassopoulos, (2011)). It is the most common pulmonary lesion and is seen in 30%–70% of patients

with blunt chest trauma (Sangster et al, (2007); Yan et al, (1998)). The appearance of pulmonary contusions depends on the severity of the parenchymal injury. In mild contusion, ill defined, patchy, “ground-glass” areas of heterogeneous opacities are generally seen and are related with interstitial or partial alveolar compromise (Figure 2.6). When alveolar injury is moderate to severe, it is seen as poorly defined areas of consolidation, with no air bronchogram sign, as a result of bronchial obstruction caused by secretions and/or blood. Massive pulmonary contusion may lead to the development of adult respiratory distress syndrome (Sangster et al, 2007). Pulmonary contusions may be associated with other lesions, such as chest wall contusions or fractures in the overlying area of impact, hemothorax (Figure 2.7), pneumothorax, or lacerations.

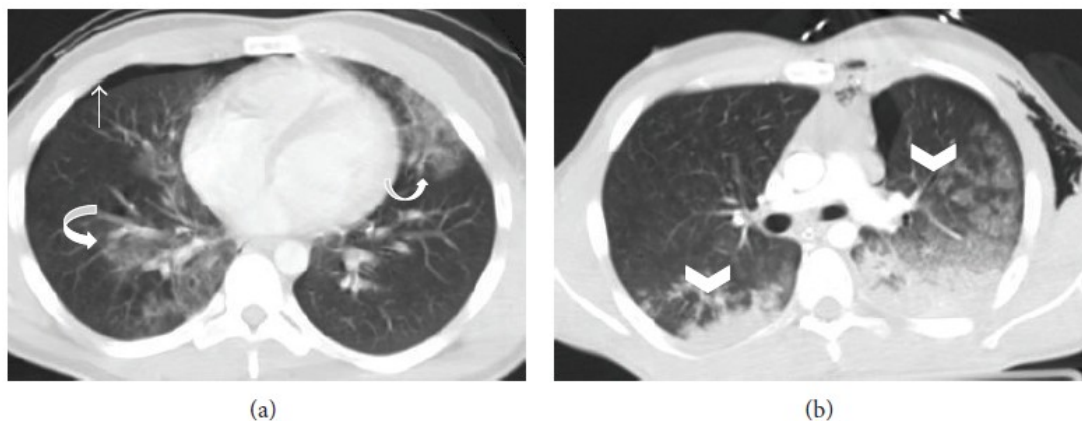


Figure 2.6: Bilateral pulmonary contusion. Axial MDCT in lung window reveals (a) ill-defined nonsegmental areas of “ground glass” attenuation in middle lobe, right inferior lobe, and lingula in a polytraumatized patient, consistent with bilateral contusion focus (curved arrows). Also note a small right pneumothorax (straight arrow). Axial MDCT of another patient (b) shows “ground glass” lung contusions (arrowheads) and bilateral nonsegmental air space consolidations with a posterior distribution due to blood filling of the alveolar spaces.

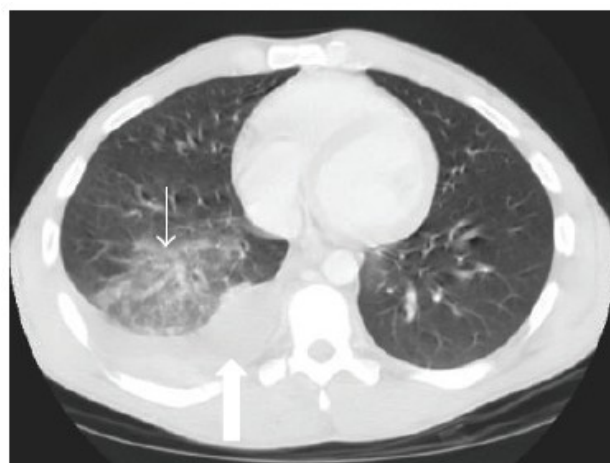

Figure 2.7: Pulmonary contusion and hemothorax in a patient who fell down of his bike. Axial MDCT in lung window at the level of left cardiac chamber shows right lower lung contusion (thin arrow) associated with ipsilateral hemothorax (thick arrow).

Also Lung Laceration: refers to a traumatic disruption of alveolar spaces with cavity formation filled with blood (hematoma), air (pneumatocele), or, more frequently, a combination of both (hemato-pneumatocele) (Figure 2.8) (Sangster et al, (2007); Yan et al, (1998)). Lacerations are commonly solitary, but multiple lacerations may occur. It appears relatively common in blunt chest trauma (Mirka et al, 2012). And they are most commonly caused by penetrating traumas such as stab or bullet wounds (Moore et al, 1981).

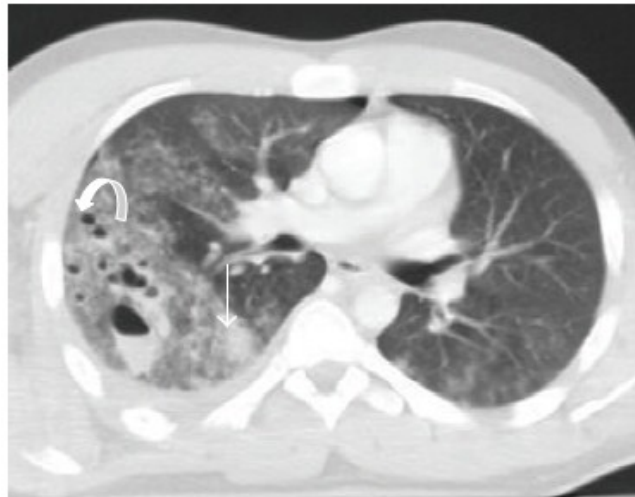

Figure 2.8: Pulmonary lacerations. Axial MDCT in lung window at the level of pulmonary trunk. Multiple focus of pulmonary lacerations can be depicted, some of them are filled with air (pneumatocele, curved arrow), others filled with blood (hematocele, straight arrow), and some filled with both, making an air-liquid level (pneumo-hematocele, arrowhead). Surrounding pulmonary contusions are appreciated. Associated left pulmonary contusions and a small right pneumothorax are also depicted.

MDCT is superior to CXR to detect lacerations. The laceration may be lucent and filled with air, completely opacified as a result of blood accumulation within the cavity, or demonstrate an air-fluid level related to variable amounts of blood within its lumen (Kang and Müller, 1996). The resultant pneumatocele has a variable course; it may persist for several weeks, although it usually resolves within one to three weeks, resulting in a pulmonary parenchymal scar (Moore et al, 1981).

Other finding of CT is the Tracheobronchial Laceration which occurs in less than 1.5% of blunt chest trauma patients. Bronchial tear is more common than tracheal tear and more often on the right side. Approximately 85% of tracheal lacerations occur 2 cm above the carina and are usually located at the cartilage-membranous junction (Sangster et al, 2007). Blunt trauma may cause an abrupt increase in intrathoracic airways pressure. If this happens against a closed glottis, a tracheobronchial laceration may occur (Kang and Müller, (1996); Kuhlman et al, (1998)).

Discontinuity of the tracheal or bronchial wall may be seen, although infrequently, with air leaking around the airway (Figure 2.9). Other less specific signs of tracheobronchial tear include collapsed lung ("fallen lung" sign), persistent

pneumothorax, and herniation or over distention of an endotracheal cuff in an intubated patient (Sangster et al, (2007); Kerns and Gay, (1990); Chen et al, (2001)). MDCT is also very effective in evaluating central airway permeability.

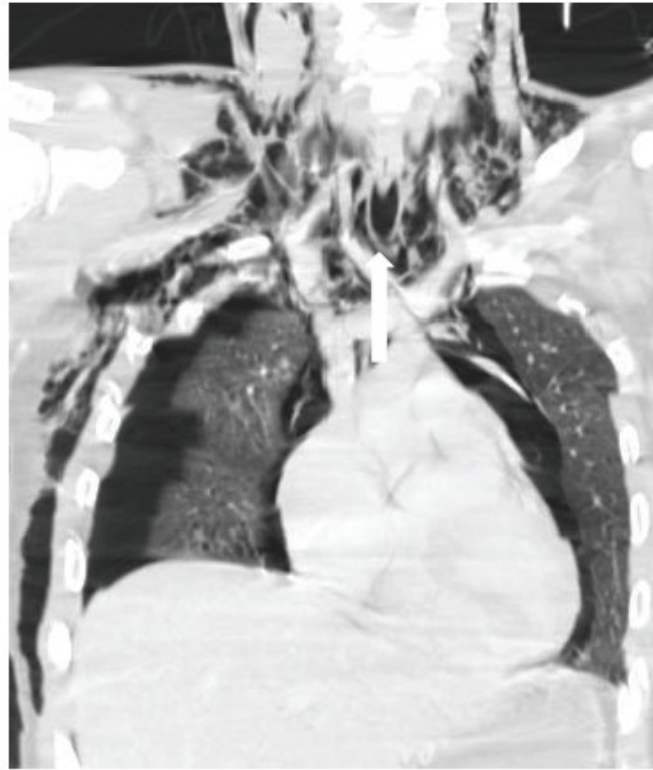

Figure 2.9: Tracheal rupture, Coronal reconstruction of axial MDCT in lung window. An extensive subcutaneous emphysema, bilateral pneumothorax, and pneumomediastinum are observed. Close attention to the tracheal wall depicted a small leak of air to the mediastinum (arrow).

Findings associated with aortic lesions include mediastinal hemorrhage (Figure 2.10), aortic-contour deformity, intimal flap, intramural hematoma, direct evidence of a tear, thrombus into the aortic lumen, pseudoaneurysm (Figure 2.11), abrupt tapering of the descending aorta relative to the ascending aorta (“pseudocoarctation”), and rupture with extravasation of contrast material (Kuhlman et al, (1998); Ho and Gutierrez, (2009)). Injuries to the supraaortic and pulmonary arteries and large venous vessels (vena cava, azygos) may be associated with cardiac tamponade or hypovolemic shock from massive hemorrhage (Ho and Gutierrez, (2009)).

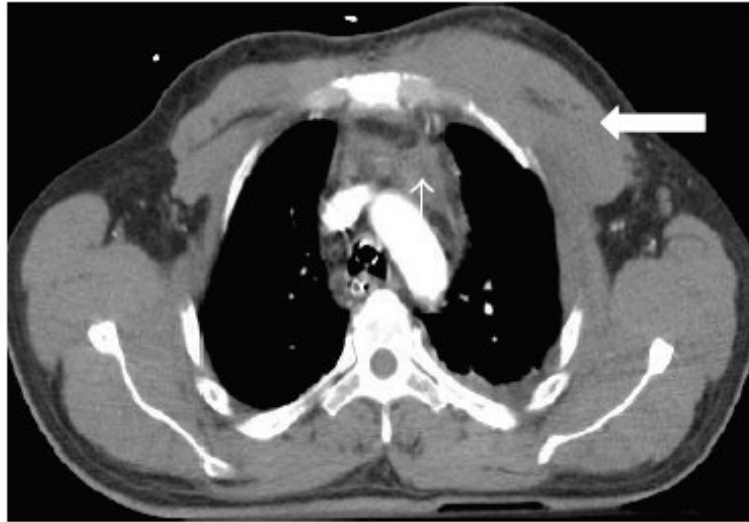


Figure 2.10: Polytraumatized patient who was hit by a car. Axial MDCT after intravenous contrast administration, at the level of aortic arch, demonstrates mediastinal hemorrhage (thin arrow) and left anterior chest muscle wall hematoma (pectoralis major, thick arrow).

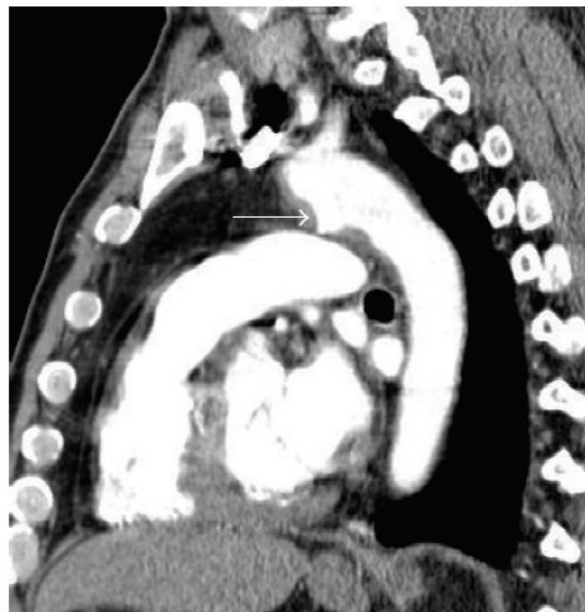

Figure 2.11: Thoracic aortic pseudoaneurysm in the context of blunt chest trauma. Sagittal reconstruction of arterial phase MDCT demonstrates an abnormal contour of the thoracic aorta. A sacculation filled with iodinated contrast material involving the anterior aspect of transition of the aortic arch with the descending aorta, immediately after the emergence of the left subclavian artery, consistent with aortic pseudoaneurysm (arrow).

Hemopericardium: is a rare condition in the setting of blunt chest trauma, usually caused by venous hemorrhage but may also be caused by cardiac injury or secondary to ascending aorta rupture. MDCT can detect hemopericardium before the onset of pericardial tamponade (Kerns and Gay, 1990). MDCT findings include pericardial

blood effusion (Figure 2.12), with or without dilation of the superior and inferior vena cava. Other findings include reflux of contrast material into the azygos vein and inferior vena cava, deformation and compression of cardiac chambers and other intrapericardial structures, and bulging of the interventricular septum (Restrepo et al, 2007).

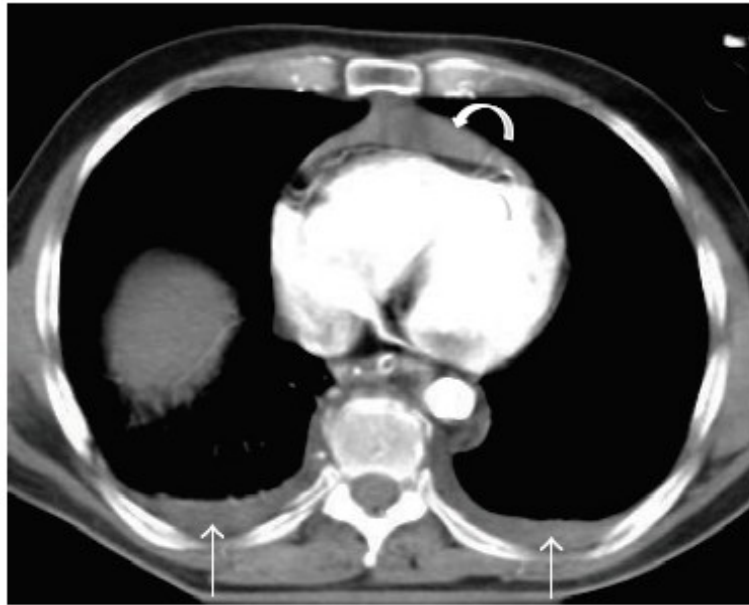


Figure 2.12: Hemopericardium and bilateral hemothorax. Postcontrast axial MDCT of a polytraumatized patient reveals a pericardial (curved arrow) and a bilateral pleural effusion (straight arrows), with high attenuation consistent with fresh blood content.

Pneumopericardium, Esophageal ruptures or pleuropericardial fistulas may initiate air into the pericardial cavity (Ho and Gutierrez, 2009). It is a very rare finding, but if large, it may result in cardiac tamponade (Mirka et al, 2012). Findings include air around the heart that does not rise above the level of pericardial reflection at the root of the great vessels (Figure 2.13).

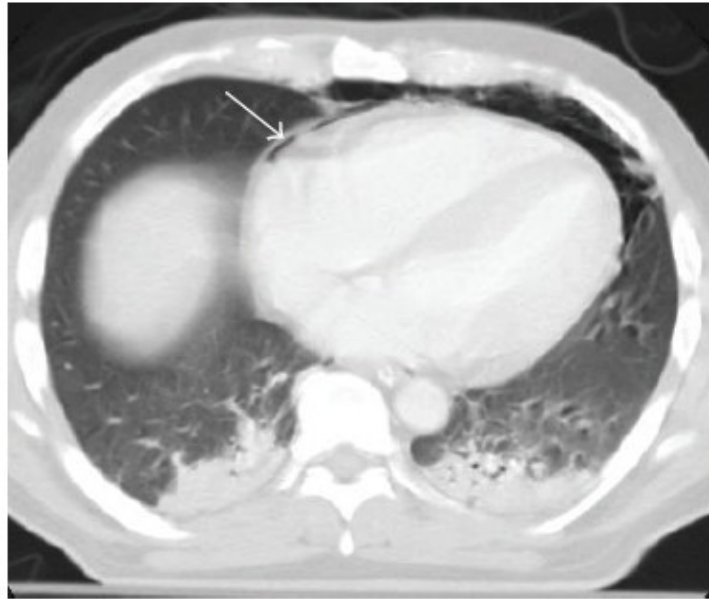


Figure 2.13: Pneumopericardium. A thin line of air is appreciated between the pericardium layers (arrow). Bilateral parenchymal contusions were also present.

Hemothorax is defined as a collection of blood in the pleural space, usually due to lesions of the lung parenchyma, pleura, chest wall, mediastinum, or abdomen (liver and splenic injuries with diaphragmatic rupture). It occurs in 30%–50% of patients who suffer blunt chest trauma (Sangster et al, 2007).

MDCT easily characterizes the pleural fluid and determines the value of attenuation (typically presents with an attenuation of 35–70H.U.) (Kaewlai et al, 2008). Blood can be seen in the pleural space at different degrees of coagulation, giving rise to a layered appearance, called the “hematocrit sign” (Figure 2.14). MDCT is also more sensitive than CXR in detecting small hemothoraces (Miller, 2006). The combination of pneumothorax and hemothorax is common (Figure 2.15) (Gilart et al, 2011).

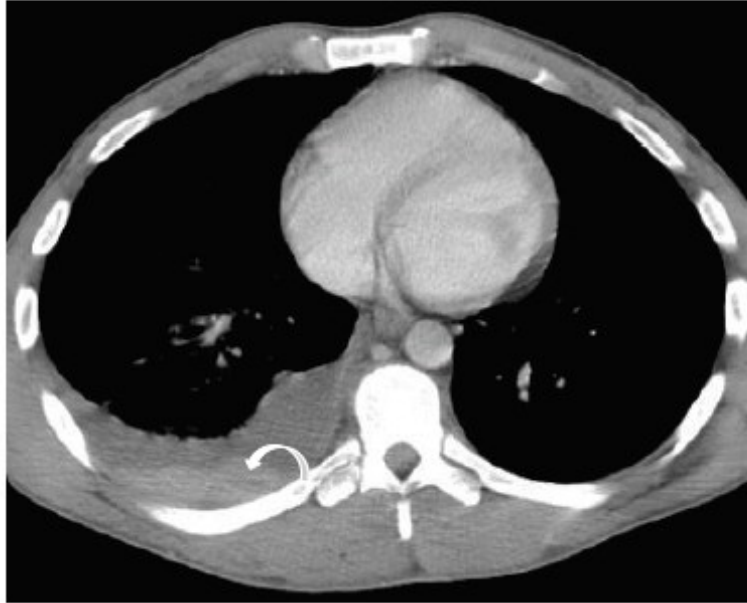


Figure 2.14: Right hemothorax with the “hematocrit sign.” Postcontrast axial MDCT at the level of ventricular chambers demonstrates a right pleural effusion with a liquid-liquid level (curved arrow), giving an aspect of layered effusion, consistent with right hemothorax with different degrees of blood coagulation (“hematocrit sign”).

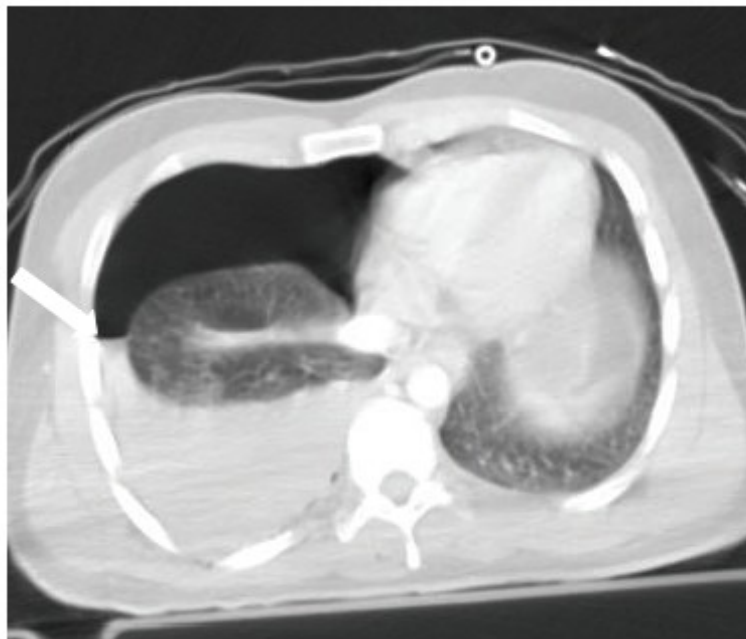

Figure 2.15: Right hemothorax and pneumothorax. Postcontrast axial MCDT shows a right hemopneumothorax creating an air-liquid level (arrow).

Tension pneumothorax develops when air enters the pleural space but cannot leave and progressively accumulates as a result of a one-way valve mechanism. It expands the ipsilateral hemithorax, collapses the associated lung, depresses the associated

hemidiaphragm, displaces the mediastinum to the opposite side, produces atelectasis in the contralateral lung, and prevents adequate diastolic filling of the heart, by compressing of the vena cava. These imaging features might be depicted with MDCT (Figure 2.16). The cardiorespiratory distress caused by tension pneumothorax might be severe (Moore et al, 1981).

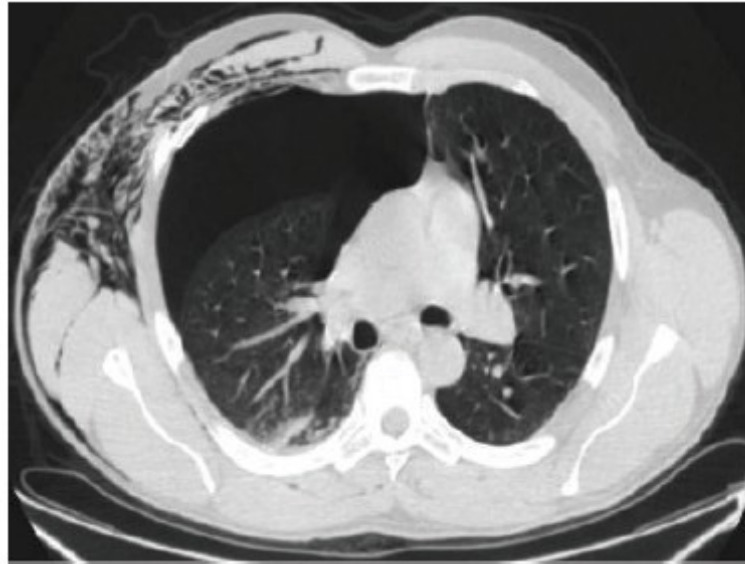


Figure 2.16: Tension pneumothorax. Axial MDCT in lung window at the level of the pulmonary trunk shows increased volume of the right hemithorax due to a large pneumothorax. This finding reduces the ipsilateral pulmonary volume and shifts the mediastinum to the left. A small contusion focus in the posterior segment of the right upper lobe and subcutaneous emphysema are also seen. This is an indication for immediate chest drainage.

Rib Fractures: Rib fractures are the most common lesion occurring in the setting of blunt chest trauma. They are usually identified on MDCT scans obtained following blunt chest trauma, being observed in 50% of patients (Figure 2.17) (Prassopoulos, (2011). The fourth to the eighth arches are the most commonly affected ribs (Prassopoulos, 2011). Fractures involving the first through the third ribs are a marker of high-energy trauma, as they are mostly protected by the clavicle, scapula, and upper chest wall musculature. Injury to the brachial plexus and subclavian vessels may be seen in 3% to 15% of patients who have upper rib fractures (Fermanis et al, (1985). Fractures of the eighth to eleventh ribs should prompt careful evaluation for upper abdominal organ injuries (Sangster et al, (2007); Kaewlai et al, 2008)). Flail chest is a traumatic condition in which there are three or more consecutive ribs with fractures in two or more places, often requiring surgical treatment (Figure 2.18) (Sangster et al, (2007); Mirka et al, (2012)). Many of these rib fractures are not shown on the initial CXR. MDCT can determine the site and number of fractures, as well as other associated injuries (hemothorax, pneumothorax, subcutaneous emphysema, and pulmonary contusion) (Kerns and Gay, 1990).

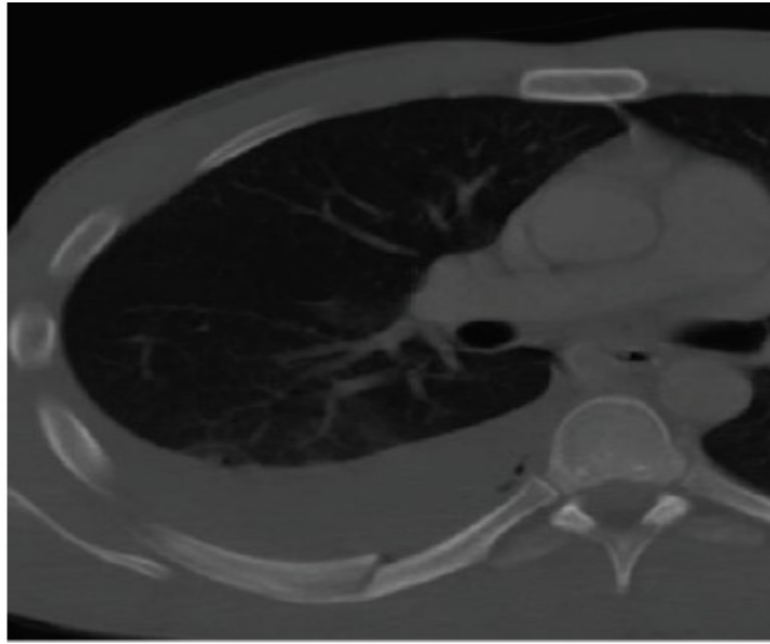


Figure 2.17: Rib fracture. Axial MDCT in bone window at the level of pulmonary trunk clearly demonstrates a fracture bone line of 8th posterior right arch associated with ipsilateral hemothorax.

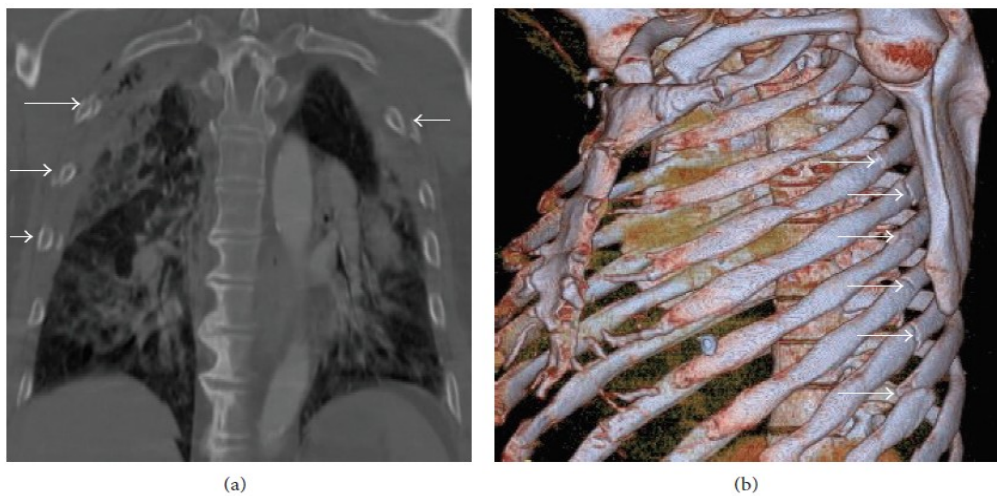
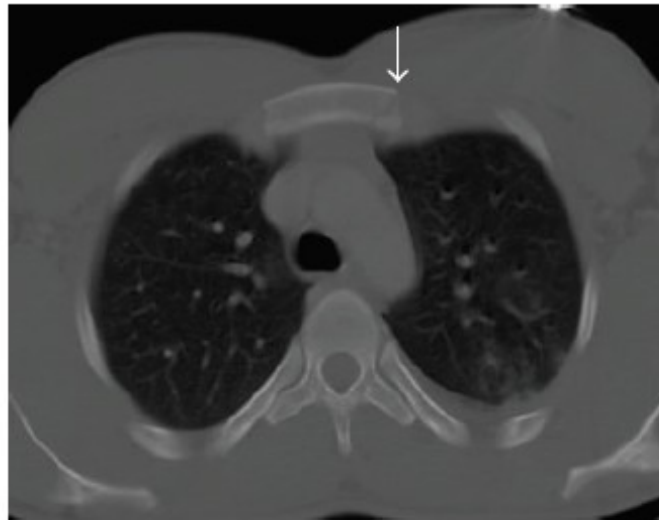


Figure 2.18: Rib fractures in 2 polytraumatized patients. Coronal MDCT in bone window (a) in a case of “flail chest” with four displaced rib fractures (straight arrows) in three consecutive right costal arches and in one left costal arc. Note the associated pulmonary contusions. Another patient (b) presenting with multiple left rib fractures (arrows), shown with oblique sagittal volume-rendering reconstruction.

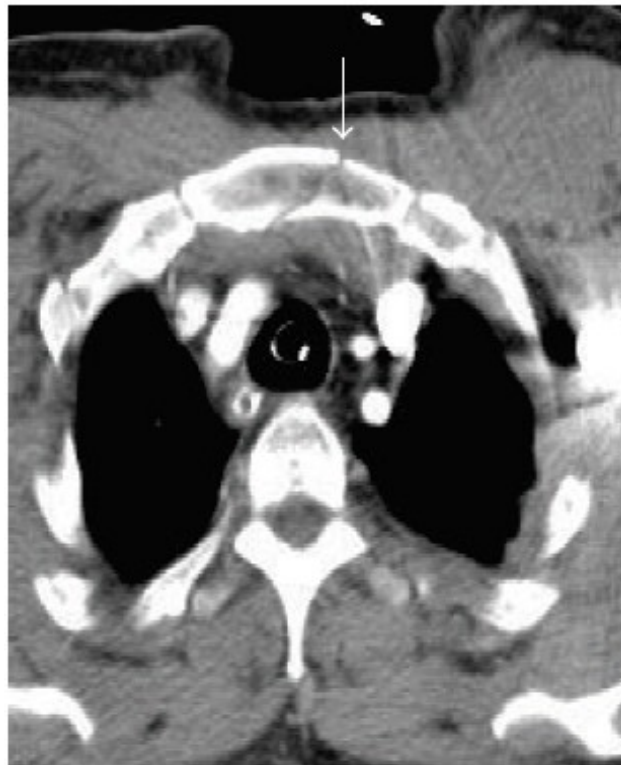Sternal Fractures: Sternal fractures have been reported in approximately 8% of blunt chest trauma patients (Shanmuganathan and Mirvis, 1999). Approximately 90% of such fractures are secondary to motor vehicle accident (due to seat belt or air bag trauma) (Sangster et al, (2007). They usually involve the sternal body and manubrium (Figure 2.19) and are often associated with mediastinal hematoma, lung lesions, and

cardiac or spinal injuries. If vascular compromise or impingement is a concern, intravenous contrast should be administered.

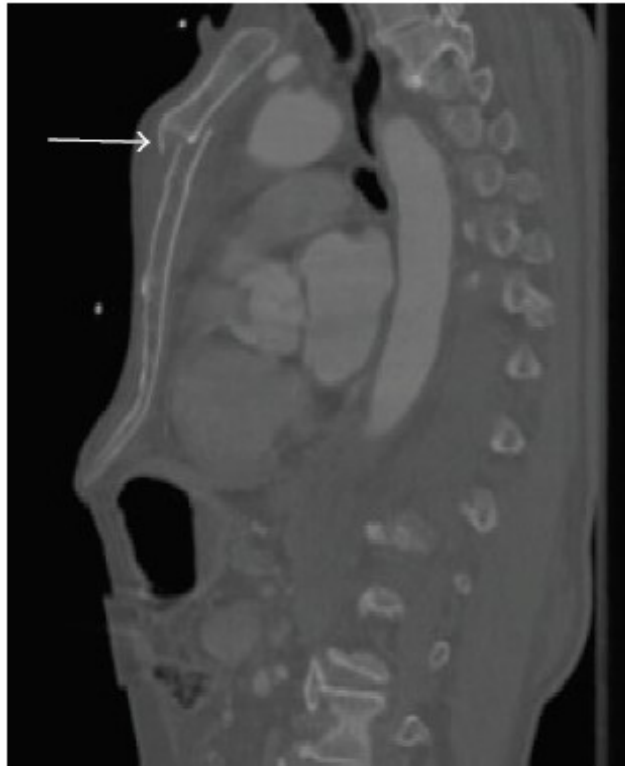The fracture is usually obvious at MDCT, often with an associated retrosternal mediastinal hematoma (Yan et al, (1998). Multiplanar and three-dimensional reconstructions greatly improve accuracy and diagnostic confidence. In this setting, sagittal images are particularly helpful for the detection of sterna fractures; however, stair-step artifacts of the sternum may be seen on sagittal reformations due to respiration. Another common pitfall is the presence of constitutional abnormalities of the sternum segmentation, mimicking sterna fractures. Treatment is usually based on pain control and chest physical therapy (Gilart et al, 2011).



(a)



(b)



(c)

Figure 2.19: Sternum fracture in two different patients. Axial MDCT (bone window) in patient one (a) shows a complete sternum fracture at the level of the body, without displacement of the fragments (arrow). Axial MDCT (b) and sagittal reconstruction in bone window (c) in a second patient show a displaced sternal body fracture (arrows). A small retrosternal hematoma is also seen (b).

Clavicle Fractures: Clavicle fractures are usually obvious on the clinical examination. The most important role of MDCT in clavicle fracture evaluation relies in the assessment of medial fractures and injuries affecting the sternoclavicular joint, especially in the diagnosis of sternoclavicular dislocation (Mirka et al, 2012). Anterior sternoclavicular dislocation is more common and it is a marker for high-energy trauma as patients usually have other chest injuries (Figure 2.20). A posterior sternoclavicular dislocation may be a cause of serious morbidity, but it is often clinically and radiographically occult, only being detected on chest CT (Sangster et al, (2007). Impingement of the underlying mediastinal vessels and nerves, such as the brachial plexus and recurrent laryngeal nerve, esophagus, and trachea, can occur by the displaced clavicle (Miller, (2006); Prassopoulos, (2011)). If vascular compromise or impingement is a concern, the study should be performed with intravenous contrast enhancement. Treatment often requires open reduction (Miller, 2006).

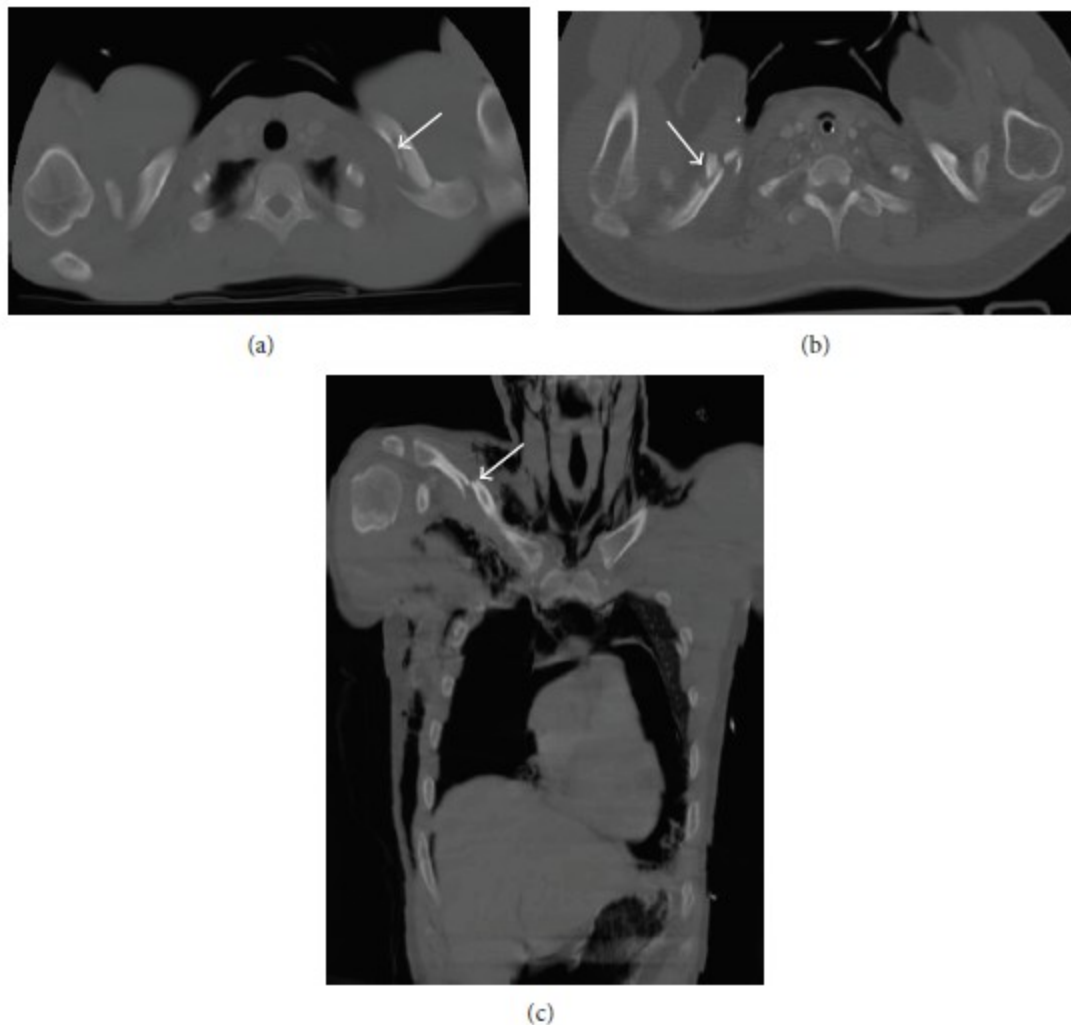


Figure 2.20: Three cases of clavicle fractures. Axial MDCT reconstruction in bone window ((a), (b)) and coronal reconstruction in bone window (c). A two-fracture line is seen in the left clavicle (a); a comminuted fracture is seen in the right clavicle, with multiple fragments (b); and a middle third fracture with dislocation is seen in the right clavicle (c). In (c) there are associated left anterior costal arc fracture, right pneumothorax, pneumomediastinum, and subcutaneous emphysema.

Subcutaneous Emphysema: Air can spread through the fascial planes to the remainder of the chest wall, abdomen, or even into the head, neck, and extremities (Figure 2.21) (Ho and Gutierrez, 2009). Most of the times it has a tracheobronchial tear origin, but it can also be a consequence of esophageal rupture.

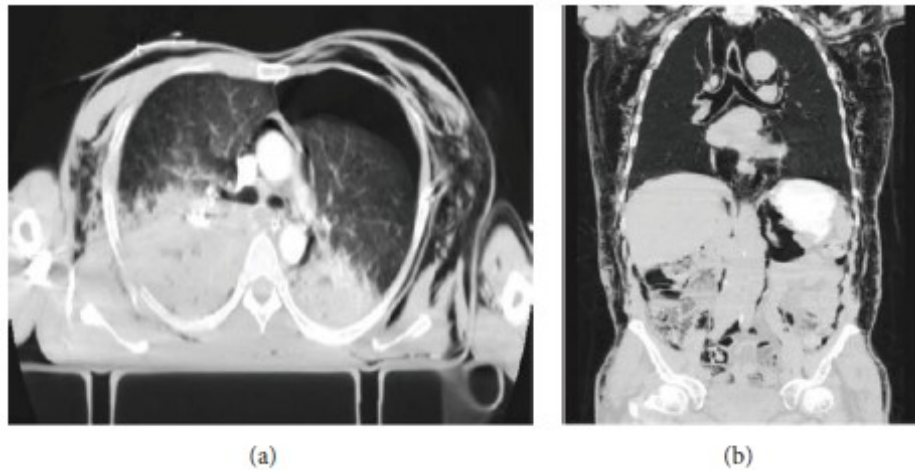


Figure 2.21: Subcutaneous emphysema. Axial MDCT (a) and coronal reconstruction (b) in lung window. Extensive subcutaneous emphysema is observed. A pneumomediastinum and retroperitoneum are also associated.

Diaphragmatic Trauma: Diaphragmatic rupture occurs in 0.8–7% of patients hospitalized with a blunt trauma (Meyers and McCabe, 1993). It is a frequently overlooked injury but it is clinically very serious. Mechanisms of diaphragmatic rupture after blunt trauma include a sudden increase in intrathoracic or intraabdominal pressure while the diaphragm is immovable by a crushing force (Kang and Müller, (1996).

MDCT not only detects small diaphragmatic discontinuities, but also identifies the herniated fat or viscera. Usually there is a waist like constriction of the herniated stomach or bowel (collar sign) or lack of visualization of the hemidiaphragm (Kang and Müller, (1996); Ho and Gutierrez, (2009)). Coronal and sagittal reformations are essential in detecting diaphragmatic rupture (Figure 2.22). Most diaphragmatic ruptures originate in the posterolateral portion of the diaphragm at the site of embryonic diaphragmatic fusion (Prassopoulos, (2011) and it is more common on the left side (77–90%), presumably because the liver protects the right hemidiaphragm (Kang and Müller, 1996). Notably, the stomach is the most common herniated abdominal organ.

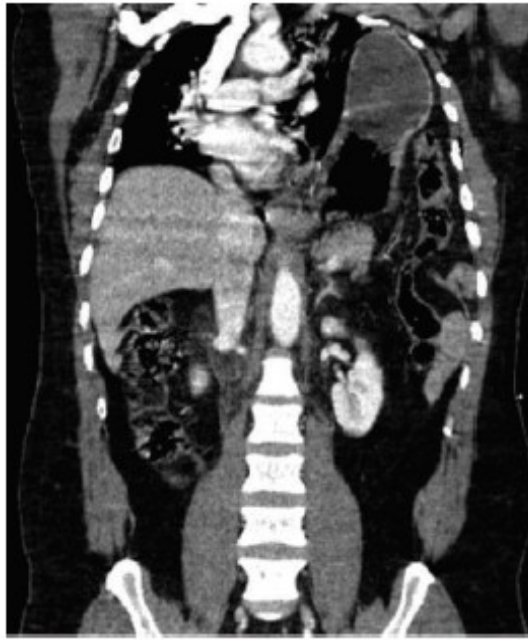

Figure 2.22: Signs of rupture of the diaphragm. Coronal MDCT reconstruction. A massive left diaphragmatic hernia with herniation of the stomach and left colon content is seen in a patient who suffered a car accident. It decreases left pulmonary volume and shifts the mediastinum towards right.

Chapter Three Methodology

3.1 Tools and equipments:

- Conventional x-ray
- CT system
- CPU with SPSS program.

3.2 Method:

The study has been carried out as a retrospective study; and the data has been collected from picture archiving systems of different hospitals including Niyala teaching hospitals, Kosti teaching hospital, Khartoum teaching hospital, and Omdurman military hospital. The sample of the study which consists of 280 cases of chest trauma was targeting the patients who referred to those hospitals for thoracic injuries diagnosis. The reviewed variables were the gender, types of trauma, causes of chest trauma, anatomical site of injury, signs and symptoms, and the common radiographic appearance. The data analyzed using EXCELL software which shown in forms of bars and correlation in addition to test of sensitivity, specificity and accuracy.

Chapter Four

The results:

The results presenting the data related to chest trauma in Sudan and the potential diagnosis and highlighting the gender, types of trauma, age, causes of trauma, anatomical site, sign and symptoms and the common radiographic appearance.

Figure 4.1: shows the frequency of blunt chest trauma distributed based on gender.

Figure 4.2: shows the frequency % of the chest trauma distributed based on the types of trauma.

Figure 4.3: shows the frequency% of chest trauma distributed based on the age group for male (31.9 ± 14.8 years) and female (32.9 ± 14.6 year).

Figure 4.4: shows the frequency percent of common causes of chest trauma in Sudan.

Figure 4.5: shows the frequency% of the common anatomical sites of chest trauma

Figure 4.6: shows the frequency% of the common signs and symptoms of chest trauma (H = Heamoptysis, D = Dysphonea, CP = Chest Pain, F = Fever, RF = Rib fracture)

Figure 4.8 shows the sensitivity, specificity, and the accuracy of chest radiography relative to CT scan,

Chapter five

Discussion, Conclusion and Recommendations

5.1 Discussion

Figure 4.1 the Frequency of blunt chest trauma distributed based on Gender. It reveals that the chest trauma predominated among male with a percent of 66.4% relative to the female group that represents 33.6%, such high incidence of chest trauma among male could be ascribed to the fact that: male are more susceptible to chest traumatic factors than female e.g.in football, car accidents, violent entertainments and acrobatic games. In relation to this results, Oikonomou and Prassopoulos, (2011) stated that: traffic accidents are the major source of blunt chest trauma representing approximately two thirds of the cases. Also among those traumatic victims, the mortality rate is high; hence the traumatic deaths tend to deplete the pool of human resources as the majority of the victims are working males and youth.

Figure 4.2 the Frequency % of the chest trauma distributed based on the types of trauma. It reveals that: the blunt chest trauma is more common than penetrating one and representing about 73.6% while the penetrating represents only 26.4% of the cases. The increasing incidence of blunt cases has a relation with mode of accidents, and in this realm Wong et al, (2004) stated that blunt thoracic trauma causes 20% of trauma related deaths which caused by motor vehicle crashes in 63% to 78%, while only 10% to 17% are related to fall from height. Also Sarita et al, (2009) stated that the common type of chest trauma was the blunt (64%) of the cases and was due to motor vehicle accidents.

Also the result showed in Figure (4.3), that highlighted the frequency% of chest trauma distributed based on the age group for male and female, the incidence of chest trauma found even during childhood i.e. age group of 4-8 years, however the incidence increases rapidly following aging and plateau of incidence occurs at the age group of 24-28 years old, which represent the early youth that famous for violence, adventures and subjection to different causative traumatic factors. Indeed the incidence is higher among male relative to female during the whole range of ages and the average age of patient was (31.9 ± 14.8) and (32.9 ± 14.6) year years for male and female respectively. This result is agreed with study carried out by EL-Menyar et al, (2013) in which they found that the chest trauma is common among age groups of 33 ± 15 years and males comprised 94% of cases.

In Figure (4.4) the study showed that: the frequency% of the common causes of chest trauma were the road traffic accidents (RTA) represents 56.5%, Gunshot represents 19.4%, stab wound 13.0% and the least was the fall-down which represents 11.1%. The high incidence of chest trauma related to traffic accidents is depend on the area of the research, which ascribed to dramatic increase in the number of cars in the country as well as to the narrow constructed roads which ruined by rains and flood, as well the raising tribal and political wars and conflicts in some sectors of Sudan. In relation to this result Omert et al, (2001) stated that: motor and vehicles accidents and falls down have high incidence causes and mortality in younger adults in the united state.

Figure (4.5) shows the frequency% of the common anatomical sites of chest trauma. It reveals that: the common involved side in chest trauma was the right lung 55.5%, then the left lung 20.9%, middle 13.6% and both lung 11%. The justification could be ascribed on the fact that: many vehicle drivers manage to save the left side depending on the rules of driving in Sudan i.e. the vehicles are left direct-soon which leading to increase the traffic accident at right site of the common cars and vehicles.

Figure (4.6) shows the frequency% of the common signs and symptoms of chest trauma. Hence the study revealed that: 53.6% of the patients presented with Heamoptysis, Dysphonea, Chest Pain, and Rib fracture. A 21.8% presented with Chest Pain, and Rib fracture. A 12.7% presented with Chest Pain and dysphnea. And 11.8% of patients presented with chest pain. The consequences of blunt trauma such as heamoptysis commonly indicates the piercing of the lungs with the broken ribs in the sample, and however due to interference of some signs and symptoms only a CT scan can reveals the pattern of the trauma, in this realm: the common signs and symptoms shown above have been mentioned by Vyhnánek et al, (2011). in which they stated that CT is considered as an imaging modality of choice in the assessment of patients with clinical or symptoms following blunt chest trauma. In this study some findings only being revealed by CT scan were emphysema and consolidation while pneumothorax has been shown in CT and CXR as highlighted in Figure (4.7).

Figure 4.8 which is dealing with the sensitivity, specificity, and the accuracy of chest radiography relative to CT scan, the study showed that: chest radiography had 38% sensitivity, 100% specificity, and about 70% as accuracy. Such result is agreed with the study carried out by Kevin et al, (2002).

5.2 Conclusion

A retrospective study on chest trauma in Sudan and potential diagnosis has been carried out in a sample consists of 280 cases collected from Niyala teaching hospital, Kosti teaching hospital, Khartoum teaching hospital and Omdurman military hospital. The data analysis showed that: that the chest trauma predominated among male with a percent of 66.4% relative to the female group that represents 33.6%, and the incidence is higher among male relative to female during the whole range of ages and the average age of patient was (31.9 ± 14.8) and (32.9 ± 14.6) year). The blunt chest trauma is more common than penetrating one and representing about 73.6% while the penetrating represents only 26.4% of the cases and the incidence of chest trauma found even during childhood i.e. age group of 4-8 years, and increases rapidly following aging and peaking at age group of 24-28 years old. The common causes of chest trauma were the road traffic accidents (RTA) represents 56.5%, Gunshot represents 19.4%, stab wound 13.0% and the least was the fall-down which represents 11.1% and the common involved side in chest was the right lung 55.5%, then the left lung 20.9%, middle 13.6% and both lung 11%. The patient presentation was 53.6% as Hemoptysis, Dysphonia, Chest Pain, and Rib fracture. A 21.8% as Chest pain and Rib fracture. A 12.7% as Chest pain and dysphnea, and 11.8% of patients presented with chest pain only. The findings only being revealed by CT scan were liver-hematoma, sternum fracture, emphysema and pneumothorax. The study also reveal that: chest radiography had 38%, 95% and 70% as sensitivity, specificity and accuracy respectively.

5.3 Recommendations:

The worth points to be recommended after successful achievements of the thesis's objectives are the following points:

- Increasing the number of the sample in different hospitals and clinics
- Introducing the same study using different modalities such as MRI, CT and ultrasound
- Utilizing the thesis out come as a true patriotism contribution
- Implic the treatment mode of chest trauma.

References:

- Ball CG, Kirkpatrick AW, Laupland KB, Fox DI, Nicolaou S, Anderson IB, Hameed SM, Kortbeek JB, Mulloy RR, Litvinchuk S, Boulanger BR: Incidence, risk factors and outcomes for occult pneumothoraces in victims of major trauma. *J Trauma* 2005, 59:917-25.
- Barrios C, Jr., Pham J, Malinoski D, Dolich M, Lekawa M, Cinat M. (2010). Ability of a chest X-ray and an abdominal computed tomography scan to identify traumatic thoracic injury. *Am J Surg*. Vol. 200(6), P :741-744; discussion 744-745.
- Barrios C, Malinoski D, Dolich M, Lekawa M, Hoyt D, Cinat M. (2009). Utility of thoracic computed tomography after blunt trauma: when is chest radiograph enough?. *Am Surg*. Vol. 75(10), P: 966-969.
- Bergin D, Ennis R, Keogh C, Fenlon H. M. Murray J. G. (2001). The dependent viscera"sign in CT diagnosis of blunt traumatic diaphragmatic rupture. *AJR*, Vol. 177, P: 1137-1140.
- Brink M, Deunk J, Dekker HM, et al. (2008). Added value of routine chest MDCT after blunt trauma: evaluation of additional findings and impact on patient management. *AJR Am J Roentgenol*. Vol. 190(6), P: 1591-1598.
- Brink M, Deunk J, Dekker HM, et al. (2010). Criteria for the selective use of chest computed tomography in blunt trauma patients. *Eur Radiol*. Vol. 20(4), P: 818-828.
- Chen J.-D., K. Shanmuganathan, S. E. Mirvis, K. L. Killeen, and R.P. Dutton, (2001). "Using CT to diagnose tracheal rupture," *American Journal of Roentgenology*, vol. 176, no. 5, P: 1273–1280.
- Demehri S, Rybicki FJ, Desjardins B, (2012). ACR Appropriateness Criteria (R) blunt chest trauma-suspected aortic injury. *Emerg Radiol*; Vol. 19(4), P: 287-292.
- E.-Y. Kang and N. L. Müller, (1996). "CT in blunt chest trauma: pulmonary, tracheobronchial, and diaphragmatic injuries," *Seminars in Ultrasound CT and MRI*, vol. 17, no. 2, P: 114–118.
- Exadaktylos AK, Sclabas G, Schmid SW, Schaller B, Zimmermann H (2001) Do we really need routine computed tomographic scanning in the primary evaluation of blunt chest trauma in patients with "normal" chest radiograph? *J Trauma* vol. 51, P:1173–1176.
- Exadaktylos AK, Sclabas G, Schmid SW, Schaller B, Zimmermann H. (2001). Do we really need routine computed tomographic scanning in the primary evaluation of blunt chest trauma in patients with "normal" chest radiograph? *J. Trauma*. Vol. 51(6), P: 1173-1176.
- Fermanis G., S. Deane, and P. Fitzgerald, (1985). "The significance of first and second rib fractures," *Australian and New Zealand Journal of Surgery*, vol. 55, no. 4, P: 383–386.
- Gilart J., M. Gil, G. Valera, and P. Casado, (2011). "Traumatismos torácicos," *Archivos de Bronconeumología*, vol. 47, supplement 3, P: 9–14.
- Hesham R Omar, Hany Abdelmalak, Devanand Mangar, Rania Rashad, Engy Helal, Enrico M Camporesi. (2010). Occult pneumothorax, revisited. *Journal of Trauma Management & Outcomes*, Vol. 4(12), P: 1-6.
- Ho M.-L. and F. R. Gutierrez, (2009). "Chest radiography in thoracic polytrauma," *American Journal of Roentgenology*, vol. 192, no. 3, P: 599–612.
- Kaewlai R, Avery LL, Asrani AV, Novelline RA (2008) Multidetector CT of blunt thoracic trauma. *Radiographics* vol. 28, P: 1555-1570.
- Kaewlai R., L. L. Avery, A. V. Asrani, and R. A. Novelline, (2008). "Multidetector CT of blunt thoracic trauma," *Radiographics*, vol. 28, no. 6, P: 1555–1570.
- Kaiser ML, Whealon MD, Barrios C, Jr., et al. (2011). Risk factors for traumatic injury findings on thoracic computed tomography among patients with blunt trauma having a normal chest radiograph. *Arch Surg*. Vol. 146(4), P: 459-463.
- Kevin R. Rowan, Andrew W. Kirkpatrick, David Liu, Kevin E. Forkheim, John R. Mayo, Savvas Nicolaou. (2002). Traumatic Pneumothorax Detection with Thoracic US: Correlation with Chest Radiography and CT—Initial Experience. *Radiology*, Vol. 225, P: 210–214.

- karmy-jones R, T. Ur Kovick G. Nathen Sab. (2001). Timing of urgent thoracotomy for hemorrhage after trauma multicenter study. *Arch surg*. Vol. 136(5); P: 513-518.
- Kerns S. and S. Gay, (1990). "CT of blunt chest trauma," *The American Journal of Roentgenology*, vol. 154, no. 1, P: 55-60.
- Kuhlman J. E., M. A. Pozniak, J. Collins, and B. L. Knisely, (1998). "Radiographic and CT findings of blunt chest trauma: aortic injuries and looking beyond them," *RadioGraphics*, vol. 18, no. 5, P: 1085-1106.
- Mayberry J. C. (2000) Imaging in thoracic trauma: the trauma surgeon's perspective. *J. Thorac Imaging*, vol. 15, P:76-86.
- Meyers B. and C. McCabe, (1993). "Traumatic diaphragmatic hernia: occult marker of serious injury," *Annals of Surgery*, vol. 218, no. 6, P: 783-790.
- Miller L. A., (2006). "Chest wall, lung, and pleural space trauma," *Radiologic Clinics of North America*, vol. 44, no. 2, P: 213-224.
- Millo NZ, Plewes C, Rowe BH, Low G. (2011). Appropriateness of CT of the chest, abdomen, and pelvis in motorized blunt force trauma patients without signs of significant injury. *AJR Am J Roentgenol*. Vol. 197(6), P: 1393-1398.
- Mirka H., J. Ferda, and J. Baxa, (2012). "Multidetector computed tomography of chest trauma: indications, technique and interpretation," *Insights into Imaging*, vol. 3, no. 5, P: 433-449.
- Mivis S. E., Kostrubiak, Nowhitley. L D Goldstein and Arodriguez. (1987). *American Journal of Roentgenology*; Vol. 149, P: 601-605.
- Moore A. V., C. E. Putnam, and C. E. Ravin, (1981). "The radiology of thoracic trauma," *Bulletin of the New York Academy of Medicine*, vol. 57, no. 4, P: 272-292.
- Mullinix A. J. and W. D. Foley, (2004). "Multidetector computed tomography and blunt thoracoabdominal trauma," *Journal of Computer Assisted Tomography*, vol. 28, supplement 1, P: S20-S27.
- Murphy SL, Xu J, Kochanek KD. Deaths: Preliminary Data for (2010). National vital statistics reports; vol 60, No 4. Hyattsville, MD: National Center for Health Statistics.
- Oikonomou A. and P. Prassopoulos, (2011). "CT imaging of blunt chest trauma," *Insights Imaging*, vol. 2, P: 281-295.
- Peters S, Nicolas V, Heyer CM (2010) Multidetector computed tomography-spectrum of blunt chest wall and lung injuries in polytraumatized patients. *Clin Radiol*. Vol. 65, P: 333-338.
- Restrepo C. S., D. F. Lemos, J. A. Lemos et al., (2007). "Imaging findings in cardiac tamponade with emphasis on CT," *Radiographics*, vol. 27, no. 6, P: 1595-1610.
- Sangster G. P., A. Gonz'alez-Beicos, A. I. Carbo. (2007) "Blunt traumatic injuries of the lung parenchyma, pleura, thoracic wall, and intrathoracic airways:multidetector computer tomography imaging findings," *Emergency Radiology*, vol. 14, no. 5, P: 297-310.
- Sarita Magu, Ashok Yadav and Shalini Agarwal. (2009). Computed Tomography in Blunt Chest Trauma, *Indian Journal of Chest Dis Allied Sci*, Vol. 51, P: 75-81.
- Saugster G. P., A. Conzalez-beicos, A. I. Carbo. (2007). Blunt traumatic injuries of lung parenchyma pleura, thoracic wall and intrathoracic air ways, multi-detector computer tomography imaging findings. *Emergency Radiology*, Vol. 14 (5), P: 297-310.
- Scaglione M, Pinto A, Pedrosa I, Sparano A, Romano L (2008). Multi-detector row computed tomography and blunt chest trauma. *Eur J. Radiol*. Vol. 65, P: 377-388.
- Shanmuganathan K, Matsumoto J. (2006) Imaging of penetrating chest trauma. *Radiol Clin North Am*. Vol. 44, P: 225-238, Review.
- Shanmuganathan K. and S. E. Mirvis, (1999). "Imaging diagnosis of nonaortic thoracic injury," *Radiologic Clinics of North America*, vol. 37, no. 3, P: 533-551.
- The American College of Surgeons Committee on Trauma Leadership ACSCTL, (2007). In: Clark DE, Fantus RJ (eds) National Trauma Data Bank (NTDB) Annual Report 2007. American College of Surgeons, Chicago, IL, P: 1-64.

Tillou A, Gupta M, Baraff LJ, et al. (2009). Is the use of pan-computed tomography for blunt trauma justified? A prospective evaluation. *J. Trauma*. Vol. 67(4), P: 779-787.

Traub M, Stevenson M, McEvoy S, et al. (2007). The use of chest computed tomography versus chest X-ray in patients with major blunt trauma. *Journal of Injury*; Vol. 38(1), P: 43-47.

Wanek S, Mayberry JC. (2004). Blunt thoracic trauma: flail chest, pulmonary contusion, and blast injury. *Crit Care Clin*, vol. 20, P: 71–81.

Ward R. E., Flynn TC, Clark W. P. (1981). Diaphragmatic disruption secondary blunt abdominal trauma. *J. Trauma*, Vol. 21, P: 35-38.

Wolf SJ, Bebartha VS, Bonnett CJ, Pons PT, Cantrill SV (2009). Blast injuries. *Lancet* vol, 374, P: 405–415.

World Health Organization. The top 10 cause of death. Available at: <http://www.who.int/mediacentre/factsheets/fs310/en/index.html>. Accessed December 27, 2012.

Yan Hise M. L., S. L. Primack, R. S. Israel, and N. L. Müller, (1998). “CT in blunt chest trauma: indications and limitations,” *Radiographics*, vol. 18, no. 5, P: 1071–1084.

Appendices

International Journal of Science and Research (IJSR)

ISSN (Online): 2319-7064

Index Copernicus Value (2013): 6.14 | Impact Factor (2013): 4.438

Studying of Blunt Chest Trauma in Sudan and Potential Diagnosis

Nuha H. Mohamed¹, Mohammed A. Ali Omer^{1,2}, Ghada A. Edam¹

¹College of Medical Radiologic Science -Sudan University of Science & Technology- Khartoum -Sudan.

²College of Applied Medical Science-Department of Radiologic Technology- Qassim University - Buraidah - KSA

Abstract: A retrospective study on chest trauma in Sudan and potential diagnosis has been carried out in a sample consists of 280 cases collected from Niyala teaching hospital, Kosti teaching hospital, Khartoum teaching hospital and Omdurman military hospital. The data analysis showed that: that the chest trauma predominated among male with a percent of 66.4% relative to the female group that represents 33.6%, and the incidence is higher among male relative to female during the whole range of ages and the average age of patient was (31.9±14.8) and (32.9±14.6) year. The blunt chest trauma is more common than penetrating one and representing about 73.6% while the penetrating represents only 26.4% of the cases and the incidence of chest trauma found even during childhood i.e. age group of 4-8 years, and increases rapidly following aging and peaking at age group of 24-28 years old. The common causes of chest trauma were the road traffic accidents (RTA) represents 36.3%, Gunshot represents 19.4%, stab wound 13.0% and the least was the fall-down which represents 11.1% and the common involved side in chest was the right lung 55.3%, then the left lung 20.9%, middle 13.6% and both lung 11%. The patient presentation was 53.6% as Hemoptysis, Dysphonia, Chest Pain, and Rib fracture. A 21.8% as Chest pain and Rib fracture. A 12.7% as Chest pain and dysphonia, and 11.8% of patients presented with chest pain only. The findings only being revealed by CT scan were liver-hematoma, sternum fracture, emphysema and pneumothorax.

Keywords: Chest, Blunt, Trauma, CT, x-ray.

1. Introduction

Recently chest trauma has been dramatically increases in Sudan following the high number of natives who possess private cars for transportation, motor cycles and in addition to other factors such as violence attitudes in driving and internal wars in some sectors of Sudan. Chest trauma which has been commonly encountered in Sudanese hospitals and clinics is classified as blunt or penetrating. The penetrating trauma is characterized with an opening to the inner thorax caused by stabbing, fractured ribs or gunshot wounds [1].

Blunt thoracic injuries represent the 3rd injury among polytraumatic patients i.e. after the head and extremities injuries [2] and as a second common cause of death, following head trauma, and mostly for young age group between 15 and 44 years old [3].

With special consideration, blunt chest trauma is directly responsible for 25% of all traumatic deaths [4]. Most blunt thoracic injuries are caused by motor vehicle crashes (MVC; 63–78%), with the remainder (10–17%) caused by falls from heights and a minority from blows from blunt objects or explosive devices [5].

Portable chest radiography is the initial imaging method used at the emergency workup of the polytrauma patient, and it is useful for detecting serious life-threatening conditions, such as a tension pneumothorax or haemothorax, mediastinal haematoma, flail chest or malpositioned tubes. However, the superiority of CT over chest radiography has been documented in the literature,

CT detects significant disease in patients with normal initial radiographs and in 20% will reveal more extensive injuries

compared with the abnormal initial radiographs, necessitating a change of management [6]. CT is far more effective than chest radiography in detecting pulmonary contusion, thoracic aortic injury and osseous trauma, especially at the cervicothoracic spine. Multi-Detector CT (MDCT) has dramatically decreased imaging times and offers multi-planar reformatting images. Therefore, it has been established as the gold standard for the imaging evaluation of chest trauma and trauma in general [7].

The general trend of this study was to study the blunt chest trauma in Sudan with consideration to diagnosis with conventional x-ray and CT and their relative findings.

2. Methodology

The study has been carried out as a retrospective study; and the data has been collected from picture archiving systems of different hospitals including Niyala teaching hospitals, Kosti teaching hospital, Khartoum teaching hospital, and Omdurman military hospital. The sample of the study which consists of 280 cases of chest trauma was targeting the patients who referred to those hospitals for thoracic injuries diagnosis. The reviewed variables were the gender, types of trauma, causes of chest trauma, anatomical site of injury, signs and symptoms, and the common radiographic appearance. The data analyzed using EXCEL software which shown in forms of bars and correlation.

3. Results

The results presenting the data related to chest trauma in Sudan and the potential diagnosis and highlighting the gender, types of trauma, age, causes of trauma, anatomical

Volume 4 Issue 7, July 2015

www.ijer.net

Paper ID: SJUB150603

Licensed Under Creative Commons Attribution CC BY

1225

site, sign and symptoms and the common radiographic appearance.

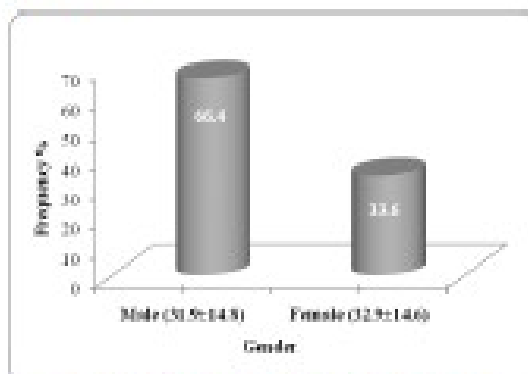


Figure 1: shows the frequency of blunt chest trauma distributed based on gender.

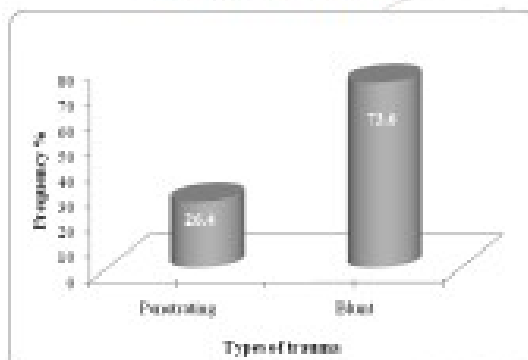


Figure 2: shows the frequency % of the chest trauma distributed based on the types of trauma

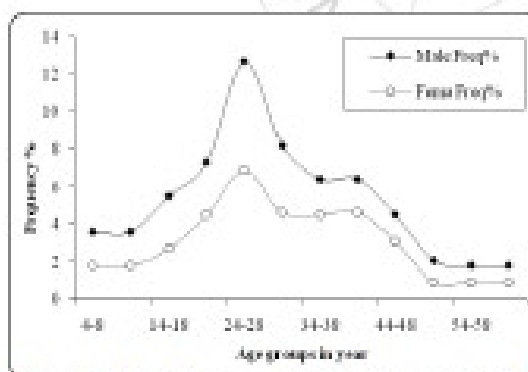


Figure 3: shows the frequency % of chest trauma distributed based on the age group for male (31.5%±14.8 years) and female (32.9%±14.6 year).

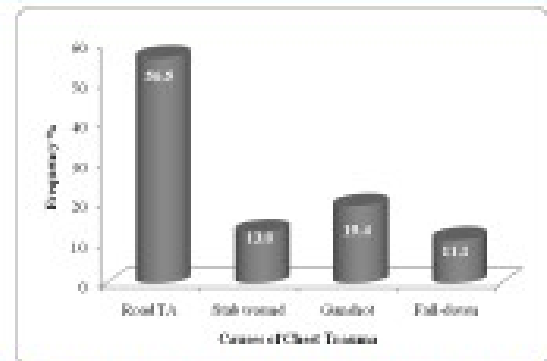


Figure 4: shows the frequency percent of common causes of chest trauma in Sudan.

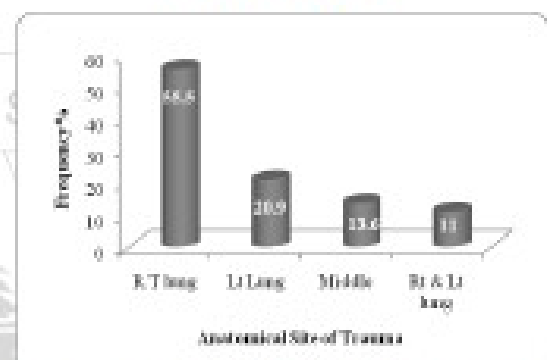


Figure 5: shows the frequency % of the common anatomical sites of chest trauma

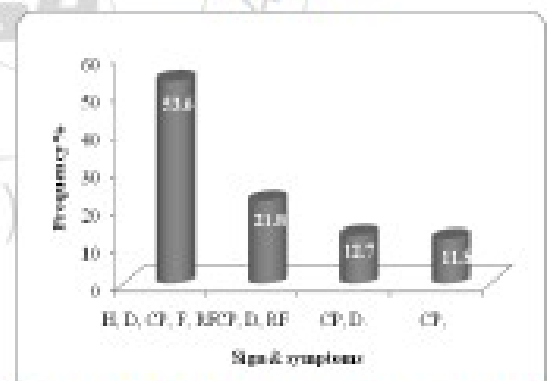


Figure 6: shows the frequency % of the common signs and symptoms of chest trauma (H = Hemoptysis, D = Dyspnoea, CP = Chest Pain, F = Fever, RF = Rib fracture)

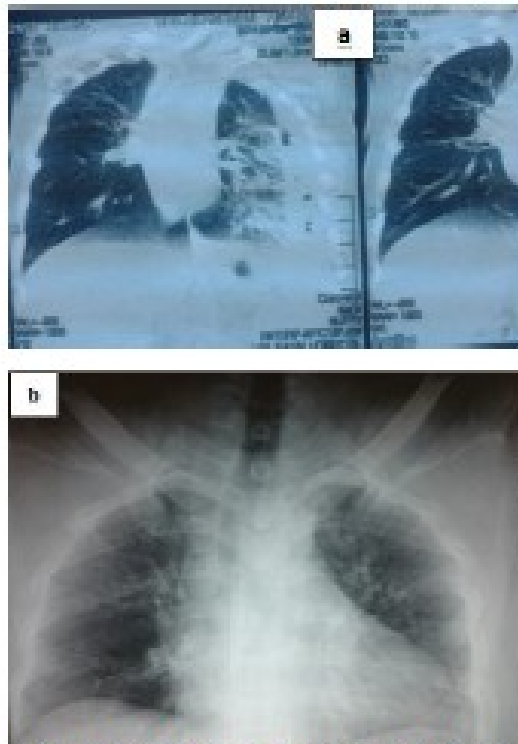


Figure 4.7: CT image showing (a) L1 Lingual and lower lobes consolidation, L1 obvious Emphysema thoraces, and fracture L1 6th Rib posterior, (b) CXR shows mild pneumothorax in the left side, multiple left posterior 3rd, 4th, 6th, and 8th ribs fracture

4. Discussion

Figure 4.1 the Frequency of blunt chest trauma distributed based on Gender. It reveals that the chest trauma predominated among male with a percent of 66.4% relative to the female group that represents 33.6%, such high incidence of chest trauma among male could be ascribed to the fact that male are more susceptible to chest traumatic factors than female e.g in football, car accidents, violent entertainments and acrobatic games. In relation to this results, Oikonomou and Prassopoulos, [8] stated that: traffic accidents are the major source of blunt chest trauma representing approximately two thirds of the cases. Also among those traumatic victims, the mortality rate is high, hence the traumatic deaths tend to deplete the pool of human resources as the majority of the victims are working males and youth.

Figure 4.2 the Frequency % of the chest trauma distributed based on the types of trauma. It reveals that: the blunt chest trauma is more common than penetrating one and representing about 73.6% while the penetrating represents only 26.4% of the cases. The increasing incidence of blunt cases has a relation with mode of accidents, and in this realm Wong et al, [9] stated that blunt thoracic trauma causes 20%

of trauma related deaths which caused by motor vehicle crashes in 63% to 78%, while only 10% to 17% are related to fall from height. Also Sarita et al, [10] stated that the common type of chest trauma was the blunt (64%) of the cases and was due to motor vehicle accidents.

Also the result showed in Figure (4.3), that highlighted the frequency% of chest trauma distributed based on the age group for male and female, the incidence of chest trauma found even during childhood i.e. age group of 4-8 years, however the incidence increases rapidly following aging and plateau of incidence occurs at the age group of 24-28 years old, which represent the early youth that famous for violence, adventures and subjection to different causative traumatic factors. Indeed the incidence is higher among male relative to female during the whole range of ages and the average age of patient was (31.9±14.8) and (32.9±14.6 year) years for male and female respectively. This result is agreed with study carried out by El-Menyar et al, [11] in which they found that the chest trauma is common among age groups of 33±15 years and males comprised 94% of cases.

In Figure (4.4) the study showed that the frequency% of the common causes of chest trauma were the road traffic accidents (RTA) represents 56.5%, Gunshot represents 19.4%, stab wound 13.0% and the least was the fall-down which represents 11.1%. The high incidence of chest trauma related to traffic accidents is depend on the area of the research, which ascribed to dramatic increase in the number of cars in the country as well as to the narrow constructed roads which ruined by rains and flood, as well the raising tribal and political wars and conflicts in some sectors of Sudan. In relation to this result Omer et al, [12] stated that: motor and vehicles accidents and falls down have high incidence causes and mortality in younger adults in the united state.

Figure (4.5) shows the frequency% of the common anatomical sites of chest trauma. It reveals that: the common involved side in chest trauma was the right lung 55.5%, then the left lung 20.9%, middle 13.6% and both lung 11%. The justification could be ascribed on the fact that: many vehicle drivers manage to save the left side depending on the rules of driving in Sudan i.e. the vehicles are left direct-son which leading to increase the traffic accident at right site of the common cars and vehicles.

Figure (4.6) shows the frequency% of the common signs and symptoms of chest trauma. Hence the study revealed that: 53.6% of the patients presented with Hemoptysis, Dysphoea, Chest Pain, and Rib fracture. A 21.8% presented with Chest Pain, and Rib fracture. A 12.7% presented with Chest Pain and dysphoea. And 11.8% of patients presented with chest pain. The consequences of blunt trauma such as hemoptysis commonly indicates the piercing of the lungs with the broken ribs in the sample, and however due to interference of some signs and symptoms only a CT scan can reveals the pattern of the trauma, in this realm: the common signs and symptoms shown above have been mentioned by Vylmansk et al, [13] in which they stated that CT is considered as an imaging modality of choice in the assessment of patients with clinical or symptoms following blunt chest trauma. In this study some findings only being

revealed by CT scan were emphysema and consolidation while pneumothorax has been shown in CT and CXR as highlighted in Figure (4.7)

References

- [1] Shanmaganathan K, Matsumoto J. (2006). Imaging of penetrating chest trauma. *Radiol Clin North Am.*, Vol. 44, P: 225-238.
- [2] Kacwli R, Avery L. I., Amasi A. V., Novelline R. A. (2008). Multidetector CT of blunt thoracic trauma. *Radiographics*. Vol. 28, P: 1555-1570.
- [3] Clark D. E., Fantes R. J. National Trauma Data Bank (NTDB) Annual Report. (2007). Chicago, I. L: American College of Surgeons, P: 1 - 64.
- [4] Scapellato M, Pinto A, Pedroni I, Sperano A, Romano L. (2008). Multi-detector row computed tomography and blunt chest trauma. *Eur. J. Radiol.* Vol. 65, P: 377-388.
- [5] Mayberry J. C. (2000). Imaging in thoracic trauma: the trauma surgeon's perspective. *J. Thorac Imaging*. Vol. 15, P: 76-86.
- [6] Exadaktylos A K, Schizas G, Schmid SW, Schaller B, Zimmermann H. (2001). Do we really need routine computed tomographic scanning in the primary evaluation of blunt chest trauma in patients with "normal" chest radiograph? *J. Trauma*. Vol. 51, P: 1173 -1176.
- [7] Peters S, Nicolas V, Heyer CM. (2010). Multidetector computed tomography-spectrum of blunt chest wall and lung injuries in polytraumatized patients. *Clin Radiol*. Vol. 65, P: 333 - 338.
- [8] Oikonomou A. and P. Protopoulos. (2011). "CT imaging of blunt chest trauma", *Insights Imaging*. Vol. 2, P: 281-295.
- [9] Wong H, Gutway MB, Sutton AD, Jeffery RB. (2004). Periaortic hematomas at diaphragmatic crura: helical CT sign of blunt aortic injury in patients with mediastinal hematoma. *Radiology* Vol. 231, P: 185-189.
- [10] Sarita Magu, Ashok Yadav and Shalini Agarwal. (2009). Computed Tomography in Blunt Chest Trauma. *Indian J. Chest Dis. Allied Sci.* Vol. 51, P: 75-81.
- [11] El-Menyar A., R. Latifi , H. Abdulrahman , A. Zarour , M. Tuma, A. Parchari, R. Peralta, and H. Al Thaiti. (2013). Age and traumatic chest injury: a 3-year observational study. *Eur J. Trauma. Emerg. Surg.* Vol. 28, P: 1-7.
- [12] Orner L, Yonney W. W, Protetch J. (2001). Efficacy of Thoracic computerized tomography in blunt chest trauma. *Am Surg*. Vol. 67, P: 660-664.
- [13] Vyháček F, Škála P, Škrabalová D. (2011). A contribution of multidetector computed tomography to indications for chest wall stabilization in multiple rib fractures. *Acta Chir Orthop Traumatol Cech.* Vol.78(3), P: 258-261.

Author Profile



Nala Hassan Mohamed: received a B. Sc. in Diagnostic Radiology from Sudan university of Science and Technology in 2006. She has been working as Radiologic Specialist at Diagnostic Radiology department in Khartoum Medical Centre and at different

clinics during 2007-2011. Then she has been working for three years as Radiologic Specialist in Saudi Arabia up to date.



Mohammed Ahmed A. Omer: Award the B. Sc. -1. in Radiotherapy and Nuclear Medicine, B. Sc.-2 in Medical Equipments Technology and M.Sc. degrees in Medical Physics from Sudan University of Science and Technology in 1993, 1998 and 2001, respectively. He has been working as medical and radiation technologist at Radiation and Isotopes Center of Khartoum as well as a lecturer at College of Medical Radiologic Sciences, Sudan University of Science and Technology (1996 - 2013). And he received a Ph. D. degree from University Putra Malaysia - 2007 in Medical physics-Applied Radiation as well; now working as a lecturer (Associate Prof.) at Qassim University-Humailah-KSA.



Ghada A. E. Sakin: Awarded B. Sc. Degree in Nuclear Medicine in 2010 from National Ribat University-Sudan and M. Sc. from College of Medical Radiologic Science-Sudan University of Science and Technology. She has been working as a lecturer (part time) at Sudan University of Science and Technology department of Radiotherapy and Nuclear Medicine as well as NM technologist at RICK. Now as a Ph. D. candidate in same field.

Figure 4.7: CT image showing (a) Lt Lingual and lower lobes consolidation, Lt obvious Emphysema thoraces, and fracture Lt 6th. Rib posterior, (b) CXR shows mild pneumo-thorax in the left side, multiple left posterior 3rd., 4th., 6th. and 8th. ribs fracture.

