

Chapter one

Introduction

1.1 Introduction

Childhood renal scarring is widely believed to be an important cause of renal failure and hypertension. Development of scarring has been associated with vesicoureteric reflex (VUR) and urinary tract infection (UTI). (Makenzie JR,1996)

In the past, intravenous urography (IVU) was considered the best method for diagnosing renal scars. This technique was superseded by dimercaptosuccinic acid scintigraphy (DMSA) the most sensitive method of detecting renal scarring and ultrasonography (US). The noninvasive nature of ultrasound, its lack of ionizing radiation and the ease with which investigations can be repeated are advantages of this method, which are often both used in the work-up of children who present with UTI. Renal scarring is major complication of UTI detected by these techniques. (Makenzie JR. 1996)

DMSA (dimercaptosuccinic acid scintigraphy), can be performed by obtaining planar images, by performing single photon emission CT (SPECT), or both. The ability to detect scars with US is partly dependent on the equipment used. Modern equipment and techniques, including the use of high frequency transducers, permit greater sensitivity and due to its low cost and feasibility, some authors have suggested the use of renal ultrasound as the examination of choice in children who have VUR and UTI, being excretory urography and DMSA performed only in selected cases.(Makenzie JR,1996)

Manish D.Sinha 2007 found that if the detection of renal scars is aprime reason for imaging in children with Urinary Tract

Infection (UTI), ultrasonography alone is inappropriate at any age and DMSA Scintigraphy ought to be the primary investigation.

1.2 Objectives

1.2.1 General objective

To evaluate the renal scarring using ultrasound and renal scan (DMSA) in order to avoid radiation hazards.

1.2.2 Specific Objectives of the study

1. To analyze the accuracy of renal ultrasound in detecting renal scarring in patients who had urinary tract infection (UTI) in Fujairah.
2. To minimize the radiation exposure to the children using ultrasound.
3. To provide accurate, safe and cheap test.

1.3 Problem of the study

The problem that we were facing patient's long waiting list, radiation hazard and they were coming from long distances because the department is serving all the north states. So to avoid all this problems we need to put ultrasound as modality for follow up.

1.4 Significant of the study

Children with UTI need imaging repeatedly for follow up. So we can use Ultrasound as primary test instead of DMSA, since Ultrasound is noninvasive, cheap, safe (lack of ionizing radiation)

and easily can be done. So we can reduce radiation exposure to the children.

Chapter two

Literature review

2-1 Kidneys Anatomy

The kidneys are bean shaped, retroperitoneal organ that lie on each side of the spine between the peritoneum and the back muscles. The liver displace the right kidney inferiorly, hence it is located lower than the left kidney and has a slightly shorter ureter. The kidneys lie in the lower thoracic and lumbar area, between the twelfth thoracic and fourth lumbar vertebrae. Each kidney consists of an upper and lower pole, anterior and posterior surface a convex lateral margin and concave medial margin. Right kidney section. (Richart.S.Snell.2005)

The kidney lie high up on the posterior abdominal wall behind peritoneum, largely under the cover of the costal margin, each kidney lies obliquely, with its long axis parallel with lateral border of Psoas major. The kidney lies well back in the Para vertebral gutter, so that the hilum, a vertical slit, like depression at the medial border transmitting the renal vessels and nerve to the renal pelvis. It faces forward as well as medially. The normal kidney measure about (12*6* 3) cm, and weighs about 130 grams. The right kidney is 0.5 inch lower than the left kidney; its lower end is 1.5 inches from the iliac crest. The upper pole of the left kidney reaches the 11 rib, while the upper pole of the right kidney reaches the twelfth rib.(Richart.S.Snell.2005)

The kidneys have the following coverings, fibrous capsule; this surround the kidney and closely applied to its outer surface, Perirenal fat; it covers the fibrous capsule, Renal fascia; this is a condensation of connective tissue that lies outside the Perirenal fat, Para renal fat; lie external to renal fascia and is often in the large quantity renal fats. (Richart.S.Snell.2005)

STRUCTURE OF KIDNEY

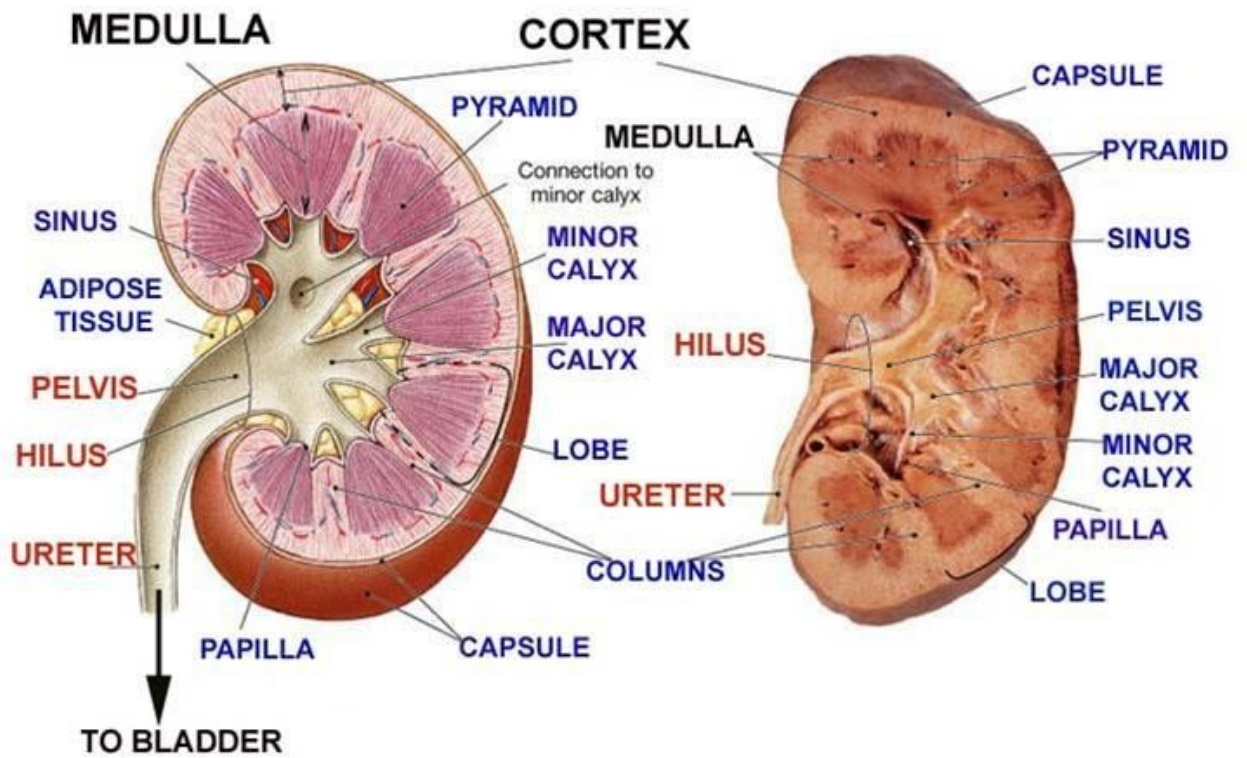


Figure 2-1 Left kidney anatomy. (Richart.S.Snell.2005)

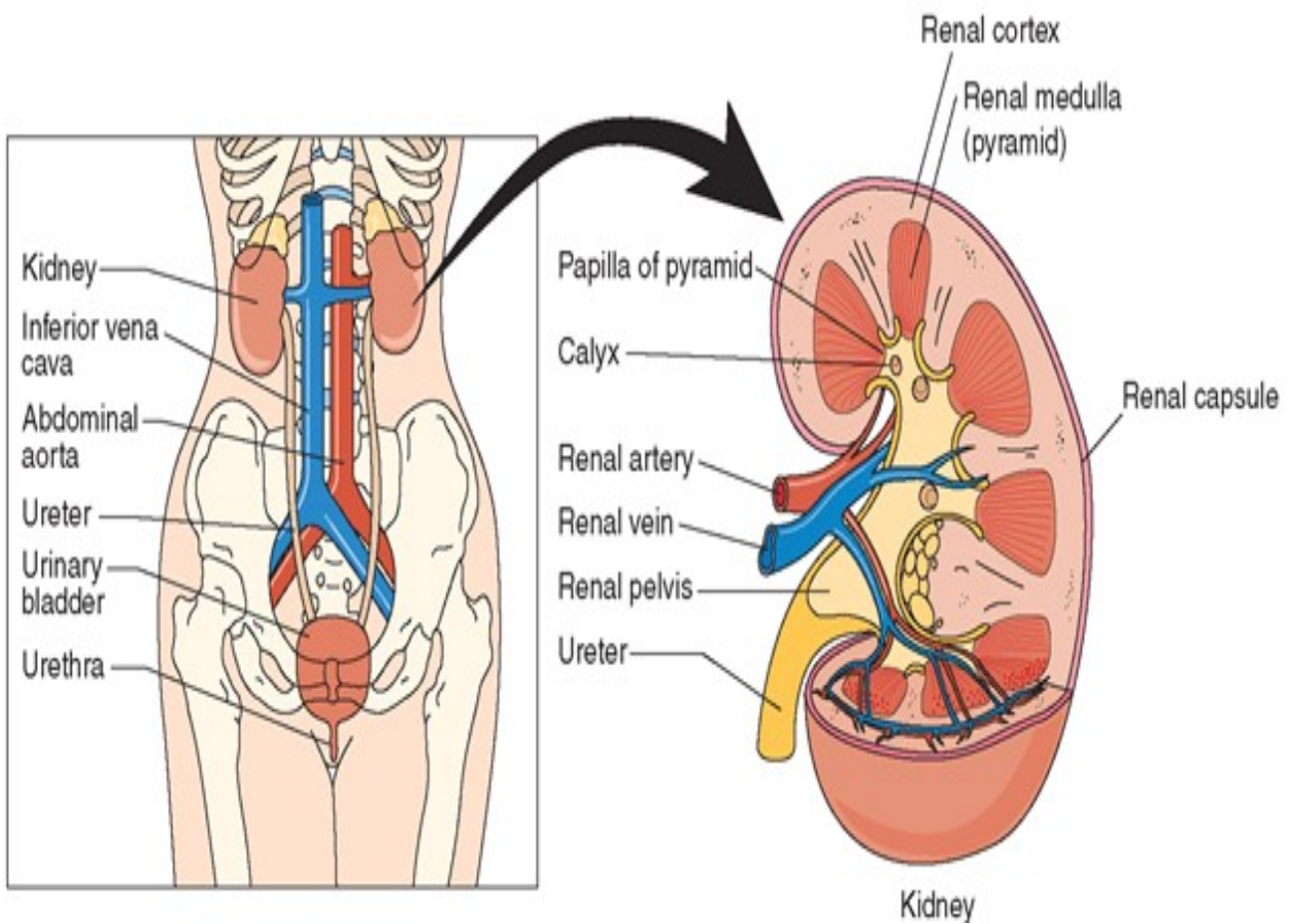


Figure 2-2 longitudinal section of the urinary system and relation with great vessels.(Richart.S.Snell.2005)

2.1.1 Renal Structure:

Each kid has a dark brown outer cortex and a light brown the medulla. The medulla is composed of about 10 conical structures known as renal pyramids; each having its base facing towards the cortex and its apex is the renal papilla projecting medially. The cortex extends into the medulla between adjacent pyramids as the renal columns. The renal sinus, which is the space within the hilum, contains the upper expanded end of the ureter, the renal pelvis. This divided into two or three major calyces, each of which divided into two or three minor calyces. Each minor calyx is intended by apex of the renal pyramids, the renal papilla. (Richart.S.Snell.2005)

Right kidneys; anteriorly: the suprarenal gland, the right lobe of the liver, the second part of the duodenum and the right hepatic flexure of the colon. Posteriorly: the diaphragm, the costodiaphragmatic recess of the pleura, the twelfth rib, the psoas major muscle, quadratuslumborum and transverses abdominis muscles.

Left kidney: Anteriorly: the suprarenal gland, the spleen, the stomach, the pancreas, the left coil of the j ejunum, quadratuslabarum, and the transverses abdomens Muscle. Posteriorly: the diaphragm, the costodiaphragmatic recess of the pleura, the eleventh (the left kidney is higher than the right) and the twelfth ribs and the psoas major muscle. (Richart.S.Snell.2005)

2.1.2 Arteries:

The renal artery arises from the aorta at the level of the second lumbar vertebra. Each renal artery usually divided into five segmental arteries that enter the hilum of the kidney, four in front of one behind renal pelvis. Interlobular arteries arise from each segmental artery one for each renal pyramid, before entering the renal substance, each interlobular artery gives off two or three interlobular arteries, the interlobular arteries run towards the cortex on each side of the renal pyramid. At the junction of the cortex and medulla. The interlobular arteries give off the arcuate arteries which arch over the bases of the pyramids. The arcuate arteries give several interlobular arteries that ascend in the cortex. The afferent glomerular arteries arise as branches of interlobular arteries. (Richard.S.Snell.2005)

2.1.3 Veins

The renal vein emerges from hilum in front of the renal artery and drains into the I.V.C.

2.1.4 Lymph drainage

Lateral aortic lymph node around the origin of the renal artery.

2.1.5 Nerve supply

Renal sympathetic plexus.

2.1.6 Normal variants

Dromedary hump either kidney, but more commonly the left, can demonstrate a lateral bulge at its mid portion. If the internal architecture is normal, the variant is not clinically significant. Sonographically Dromedary humps appear the same as normal renal cortex. Renal column hypertrophy It is a common anatomic variant and is a double layer of renal cortex that is folded toward the center of the kidney, displacing a portion of the renal sinus. The echo texture is exactly the same as the adjacent renal cortex.

Double collecting system is very common cause of unilateral renal enlargement. The ultrasound scan demonstrates a large cortical area between two renal sinuses and an enlarged kidney. Incomplete duplications is most common and involves two complete renal pelvis with fusion of ureters so only one ureters into the bladder. The bladder insertion site is normal. Since non dilated ureters are seldom seen on u/s. Complete duplication consists of two renal pelvis and two ureters will have an ectopic insertion to the bladder. Horse shoe kidney is the most common renal fusion anomaly. The lower poles of the kidneys fuse, and this fused area is called the isthmus. The blood supply is abnormal and often is from regional vessels. Their abnormal position after impairs drainage resulting in higher incidence of infection, obstruction and stone formation. Sonographically Horse shoe kidney appears as normal renal cortex. Ectopic kidney is a kidney

located outside the renal bed. Most ectopic kidneys are located in the pelvis and are called pelvic kidneys. An abnormal kidney position causes the ureter to be bent to some degree. This also impairs the flow of urine and is associated with infection and calculus. Ectopic kidneys often exhibit ureteropelvic junction obstruction and calculi. Ectopic kidney doesn't receive their blood supply from usual source but from regional vessels which are common or internal iliac arteries. Congenital ectopic kidney is due to failure of the kidney to ascend from its fetal pelvic location whereas ptosis of the kidney is due to trauma which has torn the supporting attachments of the kidney and permitted the kidney to fall. Ptosis is associated with a redundant ureter whereas ectopia is associated with ureter of normal length for its location in the body. A redundant ureter is a ureter that is too long for the position of the kidney relative to the urinary bladder. Crossed fused Ectopia in this case both kidneys are found on the same side. In 85% to 90% of cases, the ectopic kidney will be fused to other kidney. Usually the lower pole of the ectopic kidney. The pelvis of ectopic kidney is directed inferiorly. The ectopic ureter crosses mid line and inserted on the contralateral side of the bladder. The fused kidneys have a normal transverse diameter but are unusually long. There is often notch defect at the fusion point. There are two separate renal sinuses and pelvis and the ureteropelvic junction are normally located. The opposite kidneys are absent. (Richart.S.Snell.2005)

2.1.7 Histology

Renal histology studies the structure of the kidney as viewed under a microscope. Various distinct cell types occur in the kidney, including: Kidney glomerulus parietal cell, Kidney glomerulus podocyte, Kidney proximal tubule brush border cell, Loop of Henle thin segment cell, Thick ascending limb cell, Kidney distal tubule cell, Kidney collecting duct cell and Interstitial kidney cell. (Richart.S.Snell.2005)

2.1.8 Embryology:

The kidneys are developing from a common mesodermal ridge intermediate mesoderm. Three slightly overlapping kidney systems are formed in cranial to caudal sequence during intrauterine life; the pronephrosis which is rudimentary and non-functional, mesonephros may function for short time during the early fetal period, and metanephrosis which is from the permanent kidney. (Richart.S.Snell.2005)

2.2 Physiology

The kidneys play a major role in the control of the internal environment. The blood flowing in the kidney is first filtered by the glomerulus, so that all the blood constituents, except blood cells

and plasma protein, go into the micro tubular system, in these tubules, filtration take place so that useful substances, including most of filtrate water, are quickly reabsorbed(tubular reabsorption) back into the blood unwanted substances that escaped filtration are actively secreted into tubular lumen (tubular secretion) the final concentration of electrolytes and other constituents of urine is adjusted according the requirement of the regulation of extra cellular fluid composition.

Glomerular filtration, tubular reabsorption, and tubular secretion are rightly described as renal mechanism that allows the kidney to undertake its various homeostatic functions. Several hormones especially anti diuretic hormones act on the kidney to enable it to adjust the final composition of the urine in response to internal environment. (Tarig hakim.2008)

2.2.1The nephron:

Are the functioning unites of the kidney, there are about 1.3 million nephrons in each kidney the glomerulus is a tuft of capillaries covered by fibrous capsule (Bowman's capsule). It's supplied by afferent arterioles and drainage efferent .its diameter is about 200um and its function is filtration. All glomeruli are found in the cortex, most of them are located in the juxtaposition to the medulla, and accordingly there are two types of nephrons, cortical nephrons: is about 28% of all nephron, their glomeruli are found higher up in the cortex, and characterized by short loop of henle.Juxtamedullary nephrons: about 15% of all nephrons, their

glomeruli are located close to the medulla, and characterized by long loop of henle. They play important role in concentration of urine. The tubules are specialized for reabsorption and secretion, they include: proximal convoluted tubule, loop of henle, distal convoluted tubule, and collecting duct. (Tarig hakim.2008)

2.2.2 Function of the kidneys:

The removal from the body of waste products of protein metabolism, such as urea uric acid, creatinine , phosphates and sulphur, Control of extra cellular fluid (by excretion of more or less water in the urine), Control of extra cellular fluid electrolytes (by regulation of electrolyte excretion in the urine), Control of extra cellular fluid osmolarity by regulation of sodium and water excretion), The maintenance of acid-base balance by the body (control of pH), The removal of toxic substances and drugs from the body, Metabolic functions including the maintenance of blood pressure (long term effect), red blood cell production and calcium metabolism and Endocrine function: - synthesis and secretion of erythropoietin - activation of vitamin D - and release of renin enzyme.

The kidneys perform the first four of these functions by the production of urine. The urine consists mainly of water and contains urea, uric acid, creatinine, sodium chloride, potassium, calcium, phosphates and sulphate. Normally 1-2 liter of urine is produced per day. The volume depends upon the fluid intake and

the amounts of fluid lost by sweating and in the stool. (Tarig hakim.2008)

2.2.3 Renal blood flow:

The renal blood flow is 1-2 liter per minute this is about 20-25 % of the cardiac output; it's directed mainly to the cortex (90% to the cortex and 10% to the medulla. This low blood flow to the medulla maintains its high osmolarity. The renal blood flow is auto regulated (i.e. its maintained constant in spite of the change in main arterial pressure between 80-180 mmHg) this is due to myogenic response or hormonal factors (e.g. angiotensin). (Tarig hakim.2008)

2.2.4 Glomerulus filtration:

It is the transportation of fluid and crystalloid from glomerular capillaries to bowman space. The blood entering the glomeruli is under high pressure and, at rest, up to 25% of the cardiac output flows through the kidneys .the fluid filtered in to the Bowman's capsule is plasma minus the plasma protein and 'cells. The fluid filtered at the glomerulus is altered during its passage down the tubules by removal of some of its constituents and by the addition of some others. The processes involved are, respectively, reabsorption and secretion .Thus the fluid which enters the ureter is very different in composition from that which was filtered at the glomerulus. By the processes of reabsorption

and the secretion the composition of the extra cellular fluid is kept constant. (Tarig hakim.2008)

2.2.5 Reabsorption:

Some of the constituents of the fluid which is filtered at the glomerulus are reabsorbed into the blood stream. This process may be active or passive, active transport requiring energy expenditure. For example, Glucose is present in the glomerular filtrate but is normally absent from the urine. The glucose is completely reabsorbed from the glomerular filtrate and returned to the blood stream by the action of the cells of the proximal convoluted tubule, i.e. it is actively reabsorbed. Urea on the other hand, passes out of the tubule back in to the blood by diffusion, i.e. it is passively reabsorbed. Sodium chloride is actively and virtually completely reabsorbed by the renal tubule, the reabsorption in the distal tubule occurring under the control of aldosterone. Approximately 5-6 liters of fluids are filtered at the glomerulus in each hour, but only 1-2 liters of urine are produced every 24 hours. Therefore nearly all the water filtered must be reabsorbed from the renal tubules. The reabsorption of water occurs at such a rate as to keep the osmotic pressure (osmolality) of the body fluids constant. The rate of reabsorption of water from the tubule is controlled by the secretion of Antidiuretic hormone (ADH) from the posterior pituitary gland. The loop of henle dips deep in to the medulla of kidney, where there is a high osmotic pressure due to active transport of sodium out of the tubule at the

point .ADH is increases the permeability of water to distal tubular cells and the cells lining the collecting ducts .Water therefore passes in to the area of high osmotic pressure i.e. out of the renal tubule. (Tarig hakim.2008)

2.2.6 Secretion

The cells of the tubules remove potassium and hydrogen ion from the venous blood and secrete them in to the tubules .The secretion of the hydrogen ions into the tubules causes the production of acid urine. Since metabolic processes generate a great deal of hydrogen ions i.e. acidity, this function of the kidney is very important in maintaining the correct PH of extra cellular fluids. Tubular secretion is the method by which the kidney rids the body of drugs such as penicillin. (Tarig hakim.2008)

2.2.7 The kidneys and the blood pressure

Cells in the region of the glomerulus produce an enzyme rennin, which converts angiotensin2 in. the blood to aniotensinl. A further enzyme causes the oroduction of angiotensin2 from angiotensini .Angiotensin2 is powerful constrictor of blood vessels and arises the arterial blood pressure by this action. It also stimulates the production of aldosterone, the sodium retaining hormone, from the zonaglomerulosa of the adrenal cortex. The secretion of rennin is stimulated by a fall in the blood pressure within the kidney or by a fall in the plasma sodium concentration. (Tarig hakim.2008)

2.2.8 The Kidney and calcium metabolism

The kidney is the site of formation of 1, 25-dihydroxycholecalciferol the most active of vitamin D. The most important of this renal metabolite is to increase calcium absorption from the intestine especially to meet the demands of growth, pregnancy and lactation. (Tarig hakim.2008)

2.2.9 Renal clearance

Defined as the volume of plasma, which is completely cleared of substance per unit time. The efficiency of the glomerulus may be investigated by studying the clearance of creatinine, a product of protein metabolism. Creatinine is filtered at the glomerulus and is then neither reabsorbed nor secreted into renal tubule. Certain other substances such as the radiological contrast are not only filtered but are also secreted into the tubules. The high iodine content of these drugs makes them radio-opaque and this allows them to be used to visualize the renal tract on radiographs. The clearance of such substances is equal to the renal blood flow. So it can be used for Measurement of glomerular filtration, Measurement of renal blood flow and Assessment of renal function.(Tarig hakim.2008)

2.3Pathology

Progression of renal disease is associated with a number of factors. Reduced renal mass may lead to hyperfiltration injury in the glomeruli. Tubulo-interstitial damage may be due to proteinuria and local ischaemia. Chronic renal failure is a gradual reduction in glomerular filtration rate. An international classification describes five stages of chronic kidney disease. (David A Levison.2008)

2.3.1Glomerulosclerosis

Glomerulosclerosis refers to a hardening of the [glomerulus](#) in the [kidney](#). It is a general term to describe scarring of the kidneys' tiny blood vessels, the glomeruli, the functional units in the kidney that filter urine from the blood. Proteinuria (large amounts of protein in urine) is one of the signs of glomerulosclerosis. Scarring disturbs the filtering process of the kidneys and allows protein to leak from the blood into urine. However, glomerulosclerosis is one of many causes of proteinuria. Both children and adults can develop glomerulosclerosis and it can result from different types of kidney conditions. One frequently encountered type of glomerulosclerosis is caused by diabetes. Drug use or infections may cause focal segmental glomerulosclerosis (FSGS), a very chronic kidney condition. FSGS may also occur in patients with AIDS but most are of unknown cause. (<http://webmd.com>)

Early stages of glomerulosclerosis may not produce any symptoms but the most important warning sign is proteinuria, usually discovered in routine medical exams. Losing large amounts of protein may cause swelling in the ankles and accumulation of fluid in the abdomen.

1. Scarred glomeruli cannot be repaired and many patients with glomerulosclerosis get worse over time until their kidneys fail. This condition is called end-stage renal disease (ESRD) and the patients must begin dialysis treatment or endure a kidney transplant. ESRD may be reached within a year or up to ten or more of diagnosis of glomerulosclerosis but time will vary. More specifically, glomerulosclerosis can refer to [Focal segmental glomerulosclerosis](#) and [Nodular glomerulosclerosis](#) (diabetic). (<http://www.webmd.com/a-to-z-guides/glomerulosclerosis>)

2.4 Renal Investigations

2.4.1.1 Laboratory tests related to kidney function

2.4.1.2 Serum creatinine

Is nitrogenous compound formed as an end product of muscle metabolism. It is formed in small amount in the muscle, passed into the blood stream and excreted in the urine. Blood creatinine level measure renal function, normally it is produced in regular consistently small amount, therefore an elevation means a disturbance in renal function, so renal impairment is virtually the only cause of creatinine elevation.

2.4.1.3 Blood urea nitrogen (BUN)

Urea is an end product of protein metabolism and is readily excreted by the kidney; therefore the blood urea concentration normally is fairly low. Blood urea nitrogen level, measures renal function, the BUN level rises when the kidneys ability to excrete urea is impaired, it also rises with reduced renal blood flow as with dehydration and urinary tract obstructions, elevated level of

BUN may lead to mental confusion, disorientation and coma. (Tarig hakim.2008)

2.4.2Ultrasound

Ultrasound is energy generated by sound waves of 20,000 or more vibrations per second. Ultrasound is used in a large array of imaging tools. Often used for medical diagnostics, ultrasound uses sound waves that are far above the frequency heard by the human ear. A transducer gives off the sound waves and reflected back from organs and tissues, allowing a picture of what is inside the body to be drawn on a screen. Ultrasound can be used to look for tumors, analyze bone structure, or examine the health of an unborn baby. Diagnostic sonography is an ultrasound based diagnostic [imaging](#) technique used for visualizing subcutaneous body structures including [tendons](#), [muscles](#), joints, vessels and internal organs for possible pathology or [lesions](#). A renal ultrasound is a safe and painless test that uses sound waves to make images of the kidneys, ureters, and bladder. (Crowin, Elizabeth 2008)

Normal renal sonography and techniques
ultraSonography is used for anatomy, intra venous urography for anatomy and function, and nuclear medicine for function. Evaluation the kidney with u/s is noninvasive approach. It delineates retroperitoneal masses or fluid collection such as haematomas or abscesses, it's also rules out the hydronephrosis and fluid filled structure like cysts. It determines the renal size and parenchymal details, detect

also upper ureter and renal congenital abnormalities. (Crowin, Elizabeth2008)

2.4.2.1 Patient preparation

Patient fasting six hours prior exam with drinking water to fill the bladder before examination. When the patient is over hydrated, the internal collecting system will become distended but if the patient is dehydrated renal pelvic will be collapsed.

2.4.2.2 Patient position

The examination begins with the patient in the supine position or decubitus position scans are performed in the sagittal and transverse planes from the anterior approach using the liver and spleen as acoustic windows for the right and left kidneys respectively.

For adults use 3.5 MHZ transducer, children and thin adults use a 5.0 MHZ start by placing the transducer over the right upper abdomen, then angle the beam as necessary and adjust the time gain compensation (TGC) with adequate sensitivity setting to allow uniform acoustic pattern, thus obtaining the best image of renal parenchyma. Gain is amplification of the reflective ultrasound waves by the unit. The near gain control amplifies echoes returning from tissue above the focal point of the beam. While the far gain control amplifies echoes returning from beyond the focal point of the beam. E.g. echoes coming from deeper

tissues need more amplification. These controls can be adjusted to allow the proper comparison of echogenicity at different level.

The kidneys are imaged by U/S as organs with smooth outer contours surrounded by highly echogenic perirenal fat. The renal capsule appears as a bright echogenic line surrounding the cortex which is homogenous with smooth counter, its echogenicity is moderated (mid to lower level echoes). In an even texture that is less echogenic than the normal liver or spleen but more echogenic than the adjacent renal medullary pyramids. The renal contains the pyramids which appear as triangular or blunted hypo echoic to an echoic area (it should not be mistaken for renal cyst or tumors). (P.E.S Palmer.1995)

2.4.3 Nuclear medicine

Nuclear medicine is a [medical specialty](#) involving the application of [radioactive](#) substances in the diagnosis and treatment of [disease](#). In nuclear medicine procedures, [radionuclides](#) are combined with other elements to

form chemical compounds, or else combined with existing [pharmaceutical](#) compounds, to form [radiopharmaceuticals](#). These radiopharmaceuticals, once administered to the patient, can localize to specific organs or cellular receptors. This property of radiopharmaceuticals allows nuclear medicine the ability to image the extent of a disease process in the body, based on the cellular function and [physiology](#), rather than relying on physical changes in the tissue anatomy. (Crowin, Elizabeth2008)

A typical nuclear medicine study involves administration of a radionuclide into the body by intravenous injection in liquid or aggregate form, ingestion while combined with food, inhalation as a gas or aerosol, or rarely, injection of a radionuclide that has undergone micro-encapsulation. Some studies require the labeling of a patient's own blood cells with a radionuclide ([leukocyte scintigraphy](#) and [red blood cell](#) scintigraphy). Most diagnostic radionuclides emit [gamma rays](#), while the cell-damaging properties of [beta particles](#) are used in therapeutic applications. Refined radionuclides for use in nuclear medicine are derived from [fission](#) or fusion processes in [nuclear reactors](#), which produce radionuclides with longer half-lives, or [cyclotrons](#), which produce radionuclides with shorter half-lives, or take advantage of natural decay processes in dedicated generators, i.e. molybdenum/technetium or strontium/rubidium. The most commonly used radionuclides are [technetium-99m](#) ([technetium-99m](#)), [Iodine-123](#), [131I](#), [Thallium-201](#), [Gallium-67](#), [Fluorine-](#)

18 [Fluorodeoxyglucose](#), [Indium](#)-111 Labeled [Leukocytes](#), [Xenon](#)-133 and [Krypton](#)-81m. (Crowin, Elizabeth2008)

SO It is uses small amounts of radioactive material to diagnose and determine the severity of or treat a variety of diseases, including many types of cancers, heart disease, gastrointestinal, endocrine, neurological disorders and other abnormalities within the body. It is used in Nephro-Urology since 1960s. Nuclear medicine Studies offer both functional and anatomical information. (Fred A.Mettler.2012)

The limitations of General Nuclear Medicine: Nuclear medicine procedures can be time consuming. It can take several hours to days for the radiotracer to accumulate in the body part of interest and imaging may take up to several hours to perform, though in some cases, newer equipment is available that can substantially shorten the procedure time.

The resolution of structures of the body with nuclear medicine may not be as high as with other imaging techniques, such as CT or MRI. However, nuclear medicine scans are more sensitive than other techniques for a variety of indications, and the functional information gained. There are no contra indications. (Fred A.Mettler.2012)

2.4.3.1Techniques

2D Scintigraphy - use of internal radionuclides to create two-dimensional images, 3D SPECT - tomographic technique using

gamma camera data from many projections and reconstructed in different planes and HYBRID SCAN - SPECT/CT and PET/CT. A DMSA renal scan is a nuclear medicine imaging test that helps doctors look at the position, shape, scarring and function of the kidneys. The test uses Technetium-99m DMSA (dimercapto succinic acid). This is radioisotope that is given to the child through an intravenous prior to the scan. Several hours after the DMSA is injected, a special camera is used to take pictures of the kidneys. This part of the test takes about 45 minutes.

The major clinical indications for this investigation are the detection and/or evaluation of a [renal scar](#), the small or absent kidney ([renal agenesis](#)), an occult [duplex system](#), certain [renal masses](#), systemic [hypertension](#) or suspected [vasculitis](#). Common Indications, Detection of focal renal parenchymal abnormalities, detection of renal sequelae, 6 months after acute infection, detection of acute pyelonephritis, detection of associated abnormalities: abnormal duplex kidney, small kidney, dysplastic tissue, horseshoe kidney, Detection of ectopic kidney and confirmation of non-functional multicystic kidney. (Crowin, Elizabeth 2008)

2.4.3.2 Nuclear medicine findings

Central photopenic area with or without cortical scar, it occurs also in vascular phase tracer accumulation within hydronephrotic collecting system with delayed drainage.

2.4.4 Intravenous urography (IVU)

Provide both functional and anatomical information. The major limitation of IVU is reliance of renal function.

2.4.4.1 Radiographic finding (IVU)

Increasingly dense nephrogram in acute obstruction, Diminished nephrographic density in chronic hydronephrosis, Delayed opacification of collecting system, Dilated collecting system with or without dilatation of ureter, Widening of forniceal angles, Site of obstruction demonstrated at end of persistent column of contrast in dilated system and reduced parenchymal thickness in chronic hydronephrosis.

2.4.5 Computed Tomography (CT)

CT provides exquisite anatomical details and is able to differentiate between types of masses based on differences in their radio density. The disadvantages of CT are it is expensive and ionizing radiation may be a concern with young children or pregnant patients, and contrast collection and excretion rely on renal function.

2.4.5.1 CT finding

Dilation of renal collecting system with or without ureter, inflammation or perinephric or periureteral fat, ureteral rim sign. Thickening of ureteral wall secondary to edema from stone impaction.

2.5 Previous Studies

Manish D.Sinha, Paul Gibson, Tom Kane and Malcolm A. Lewis, 2007 found that if the detection of renal scars is a prime reason for imaging in children with Urinary Tract Infection (UTI), ultrasonography alone is inappropriate at any age and DMSA Scintigraphy ought to be the primary investigation. (Annals of nuclear medicine Vol. 8. 1994)

Mohkam M et al, find that ultrasonography is a sensitive method for detection of renal cortical defects and ultrasonography can also predict the presence of vesicoureteral reflex in pyelonephritic patients. (Ped, Nephrology 2015 July),

Adriano A. Calado et al, suggests that a high - resolution ultrasound performed by experienced ultrasound technicians is able to accurately detect diffuse renal scarring. When focal was presents, the correlation was poor.(Brazilian journal urology, june-may 2002)

Chapter Three

Material and methods

Introduction

In this chapter a brief descriptions of the present work is out lined. In total, 60 patients with urinary tract infection (UTI) underwent both renal DMSA scintigraphy and ultrasonography. This study was done from Jan. 10, 2014 to Apr. 30, 2015. Sixty

patients were referred by the pediatricians of north state of Emirates general hospitals.

3.1Material

3.1.1Patients

60 patients from Fujairah- UAE (different nationality) were undergoing renal ultrasound and DMSA (dimercaptosuccinic acid scintigraphy). The patient age vary from 6 month to 6 years old. The median age is 2 years. This study includes all children less than six years and has urinary tract infection and excludes the children above this age.

3.1.2 Machines

For nuclear medicine equipment &energy Window:

Gamma camera: large field of view

Collimator: Low energy , high resolution, parallel hole

Energy window: 20% window centered at 140KeV

For ultrasound For children and thin adults use a 5.0 MHZ transducer start by placing the transducer over the right upper abdomen, then angle the beam as necessary and adjust the time gain compensation (TGC) with adequate sensitivity setting to allow uniform acoustic pattern, thus obtaining the best image of renal parenchyrna.

3.3 Methods

3.2.1 Renal DMSA scintigraphy

3.2.1.1. Radiotracer

^{99m}Tc-DMSA. Dose is 15MBq. The tracer is bound to proximal tubular cells present in the cortex 2 hours after the injection. Pyelonephritis impairs tubular uptake of radiotracer, these areas appear as cold. Persisting areas on follow up indicates irreversible renal damage or scarring.

National regulations may indicate different reference activities; it is suggested to scale the administered activity according to the lower one.

Injection Technique a fine Butterfly needle (gauge 23-25 according to child's age) is recommended.

3.2.1.2 Patient Preparation

No preparation is needed if sedation is not required, but before injection of the radiopharmaceutical:

The procedure is explained to parents and to children old enough to understand and continual communication and reassurance with explanation of each step are essential for cooperation and successful intravenous injection of the radiopharmaceutical.

Pre-sedation evaluation is necessary for sedation (An informed consent, patient preparation, and presedation evaluation are necessary for administration of sedation).

3.2.1.4 Image Acquisition

2 hrs post-injection

Ant, Posterior and Post Oblique views, Pinhole post. + SPECT

Imaging Time: 10-15 minutes + 30 minutes if SPECT

3.2.1.5 Processing

Relative function of each kidney cortical scar may have relatively sharp edges with contraction and reduced volume of the affected cortex. A. Scarring can manifest as cortical thinning, flattening, or an ovoid or wedge-shaped defect .images were reported by the nuclear medicine physician.

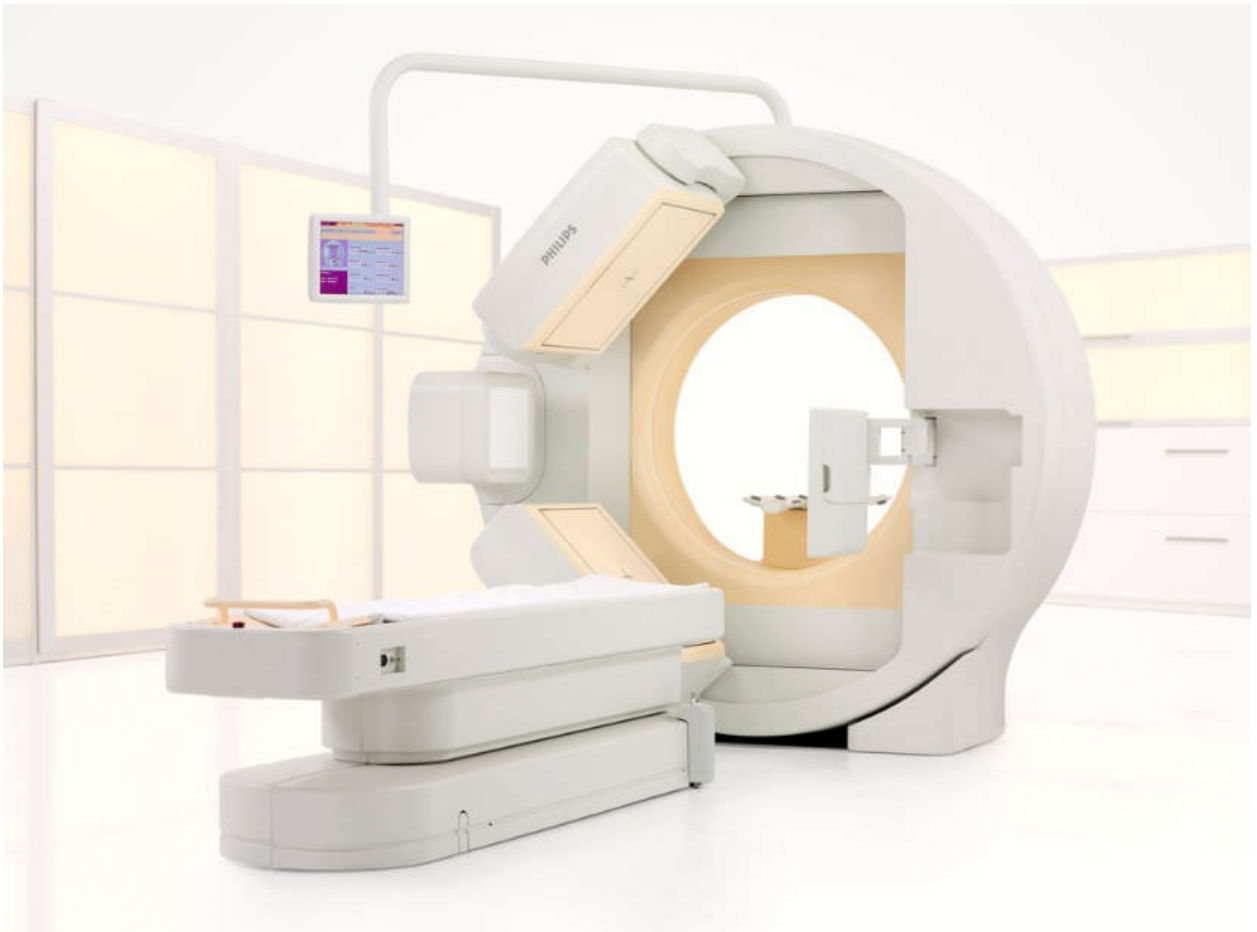

Figure (3-1) BrightView SPECT gamma camera

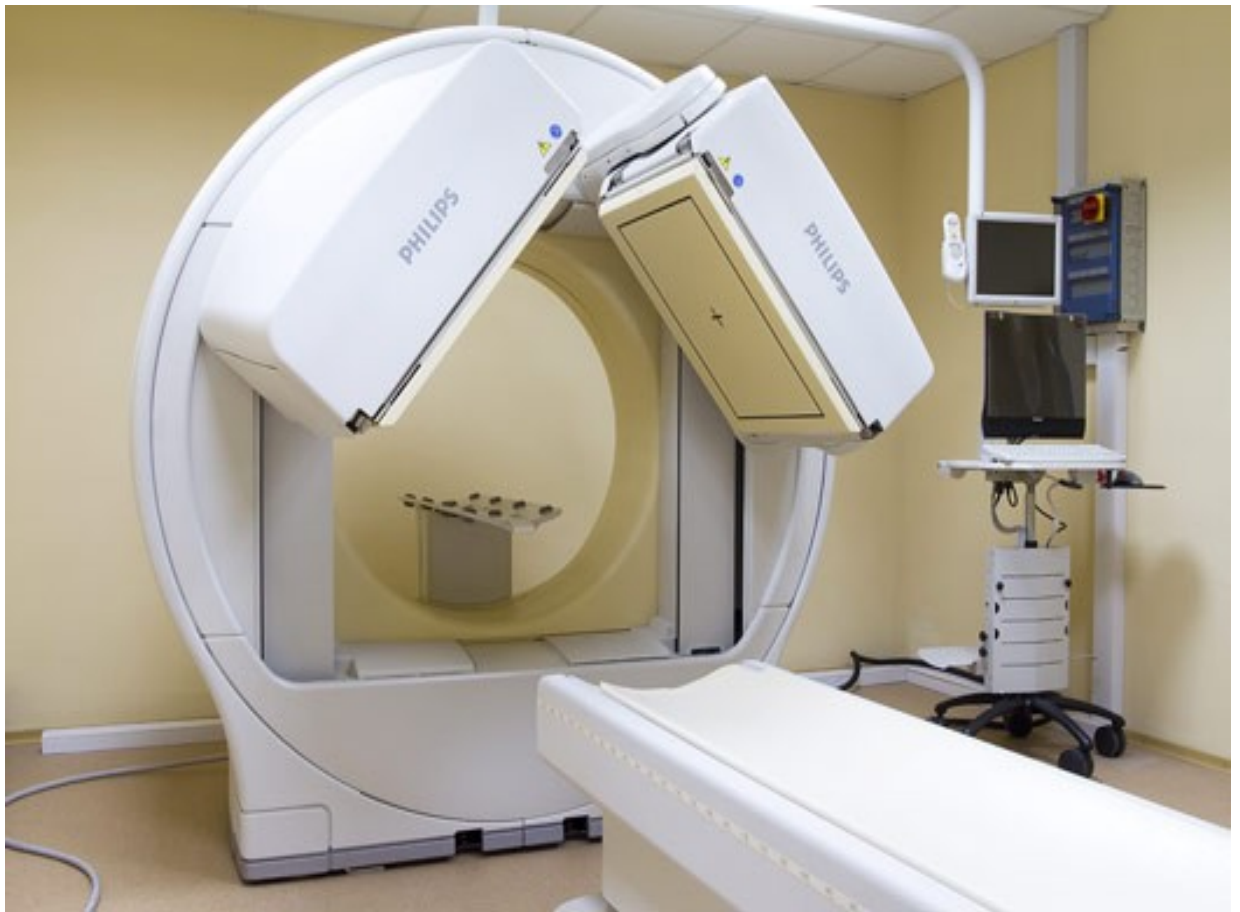

Figure (3-2) BrightView SPECT is variable angle gamma camera. This is the camera used for imaging patients.

3.2.2 Renal Ultrasound procedure:

3.2.2.1 Preparation: There is no preparation for this procedure.

3.2.2.2 Procedure:

The renal ultrasound was done in the radiology department of a hospital or in a radiology center. Parents are usually able to accompany their child to provide reassurance and support. A technologist (sonographer) trained in ultrasound imaging will spread a clear, warm gel on the child's abdomen over the kidney area.

3.2.2.3 Patient's position:

Begin with the patient supine. Each kidney may need to be examined in decubitus position. Raise the ipsilateral arm above the patient's head.

3.2.2.4 Technique:

A 5 MHz probe is typically used to scan the kidney. Scan longitudinally right subcostally. Visualize the kidney inferior to the right lobe of the liver (RT) or spleen (LT). Place the probe between iliac crest and the lower costal margin to examine in coronal plane. The images were reported by Radiologist.

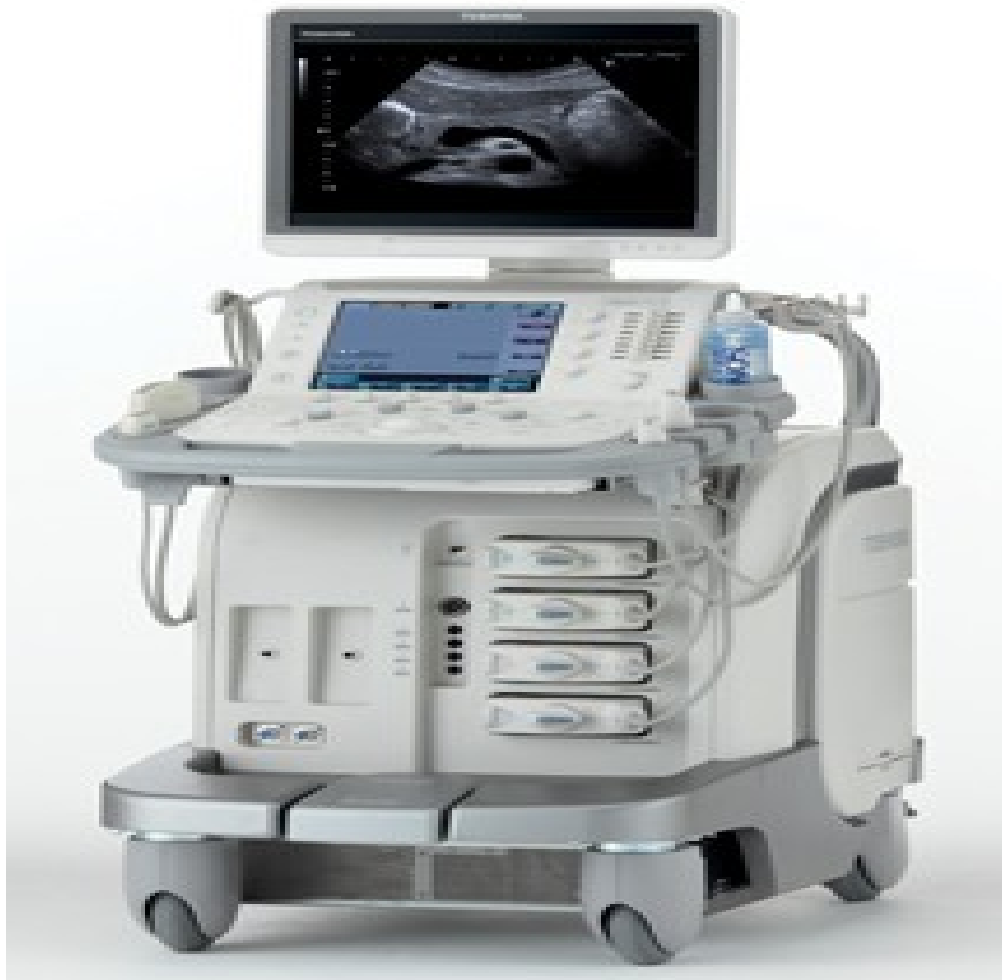

Figure (3-3)
Toshiba
Ultra sound
machine

Figure (3-4) Toshiba Ultra sound machine

Chapter four

Results

In total, 60 patients with urinary tract infection (UTI) underwent both renal DMSA scintigraphy and ultrasonography. According to this study; among this 60 patients 80% were female (48) and 20% were male (12), table (4-1). The mean age of our patients was 2 years. DMSA scan results were normal in 45% (27 patients) and abnormal in 55% (33 patients) (showing decreased cortical uptake), table (2). Renal ultrasonographies were reported as normal (no scar) in 85% (51 patients) and abnormal in 15% (9 patients) (showing scar formation or decreased cortical thickness).

Table (4-1) Numbers of male and female patients

Patients	Numbers
Male	12
Female	48
Total numbers	60

Figure (4-1) Numbers of male and female patients

Number
Of patients

Table (4-2) patient's ages

Age group	Numbers of patients
< 2	40
< 4	16
< 6	4
Total number of patients	60

Figure (4-2) Percentage of patient's ages.

Table (3)The numbers of patients with renal scarred in each test

Test	No Patients	Scar scar Patients
DMSA Scan	27	33

Figure (4-3) Percentage of patients in each test with or without renal scar

Table (4-4) the gender of the patients with renal scar

Test	Female	Male
DMSA	24	9
US	6	3

Figure (4-4) The numbers of male and female with renal scar in each test

Chapter five

Discussion, Conclusion and Recommendation

Discussion

Renal ultrasound examination has been playing an important role in the evaluation of urinary tract pathologies, mainly due to its feasibility, low cost, absence of morbidity, besides the high resolution of the most modern equipment. It is well known that the evaluation of renal parenchyma plays a fundamental role in patients with UTI, as the presence of renal scarring is determinant of worse prognosis and in more severe cases may lead to chronic renal failure. Excretory urogram for evaluating the renal parenchyma has been replaced in the last years by the scintilographic study (DMSA). Several studies have stated the superiority of the DMSA in detection of renal scarring, and nowadays this method is considered the “gold standard”

In our study we observed that ultrasound examination was not able to detect scars in 30% Of the patients. However, when the kidney presented scars classified as diffuse with DMSA, the ultrasound was able to detect the cases.

So when the ultrasound shows a scar, it will probably be confirmed by the DMSA. On the other hand, when the ultrasound examination is normal, we can infer that probably it does not exist diffuse scars.

In spite of some limitations of this, ultrasound examination plays an important role for patients with UTI.

Regarding the previous studies Manish D.Sinha, et al, 2007 agreed with this study, they found that if the detection of renal scars is a prime reason for imaging in children with Urinary Tract Infection (UTI), ultrasonography alone is inappropriate at any age and DMSA Scintigraphy ought to be the primary investigation. His Results: Renal ultrasound detected focal or diffuse renal scarring in 41 patients. Ultrasound examination correlated with the DMSA study in 36 patients. On the other hand, of the 47 patients with normal ultrasonography, the DMSA study showed renal scars in 14 patients. The sensitivity, specificity, positive and negative predictive value were 66%, 84%, 87.5% and 61%, respectively. Of the focal scars, ultrasound examination correlated in only 8 patients (32%). On the other hand, of the 29 patients with diffuse scarring, ultrasound scanning demonstrated scars in 28 (96.5%). (Annals of nuclear medicine Vol. 8. 1994).

In the other hand Mohkam M et al, disagree with this study because he found that ultrasonography is a sensitive method for detection of renal cortical defects and ultrasonography can also predict the presence of vesicoureteral reflex in pyelonephritic patients. His results of DMSA scans showed 70.2% of cases as being abnormal. Renal ultrasonographies were reported to be normal in 72.45. There was a significant difference in ultrasonography reports between patients with normal and abnormal DMSA scans ($P < 0.012$) but there was no significant difference in detection of scar formation between DMSA scan results and those of ultrasonography in our patients. Among patients with severe abnormalities on DMSA scintigraphy the percent of cases with vesicoureteral reflux was significantly higher than those with normal scans or mild to moderate changes on DMSA scintigraphy. (46.3% vs 26.9%) (Ped, Nephrology 2015 July).

Also Adriano A. Calado et al, suggests that a high - resolution ultrasound performed by experienced ultrasound technicians is able to accurately detect diffuse renal scarring. When focal was presents, the correlation was poor. The results: Renal ultrasound detected focal or diffuse renal scarring in 41 patients. Ultrasound examination correlated with the DMSA study in 36 patients. On

the other hand, of the 47 patients with normal ultrasonography, the DMSA study showed renal scars in 14 patients. The sensitivity, specificity, positive and negative predictive value were 66%, 84%, 87.5% and 61%, respectively. Of the focal scars, ultrasound examination correlated in only 8 patients (32%). On the other hand, of the 29 patients with diffuse scarring, ultrasound scanning demonstrated scars in 28 (96.5%). (Prazilian journal urology, june-may 2002)

CONCLUSION

When the ultrasound examination is performed by an experienced operator with high resolution equipment, it presents good accuracy in detecting diffuse scars. Consequently, ultrasound can be used for evaluation and follow up. DMSA scintigraphy examination would be indicated for patients with alterations in ultrasound examination or when there is a higher possibility of detecting new renal scars. Renal cortical scintigraphy (DMSA scan) is a highly sensitive and specific method to detect renal cortical defect.

Recommendation

- Renal DMSA Scans should be routinely done in patients with recurrent UTI.
- Renal ultrasound can play an important role for patient with UTI if the technologist is well trained.
- Further studies with large sample size are advised,

Appendix

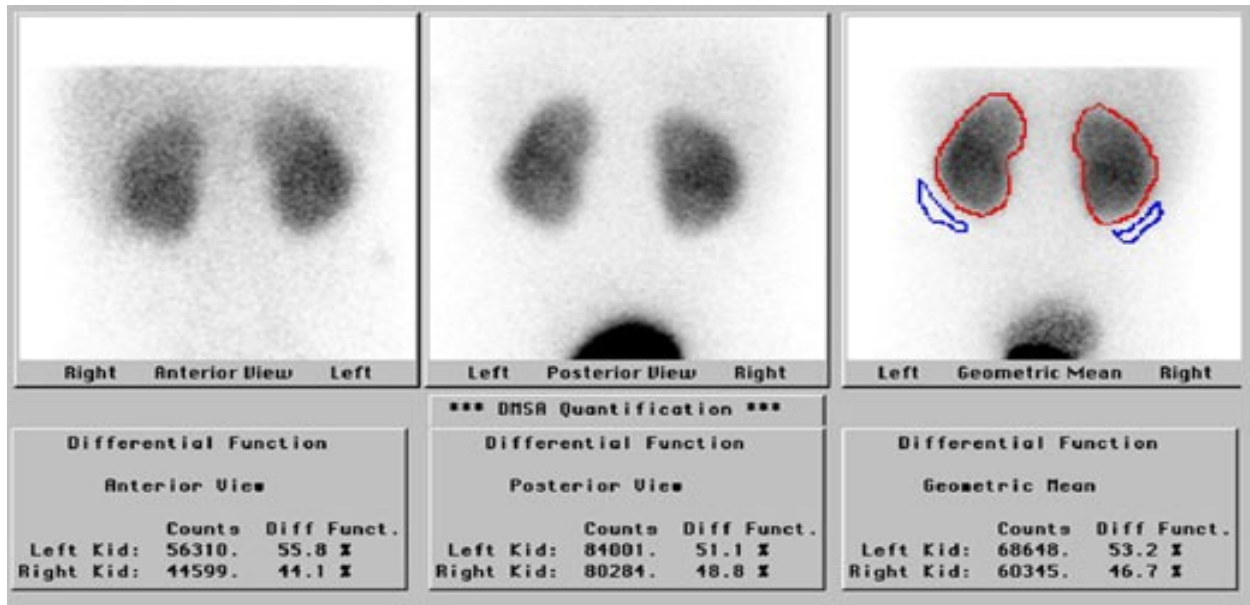
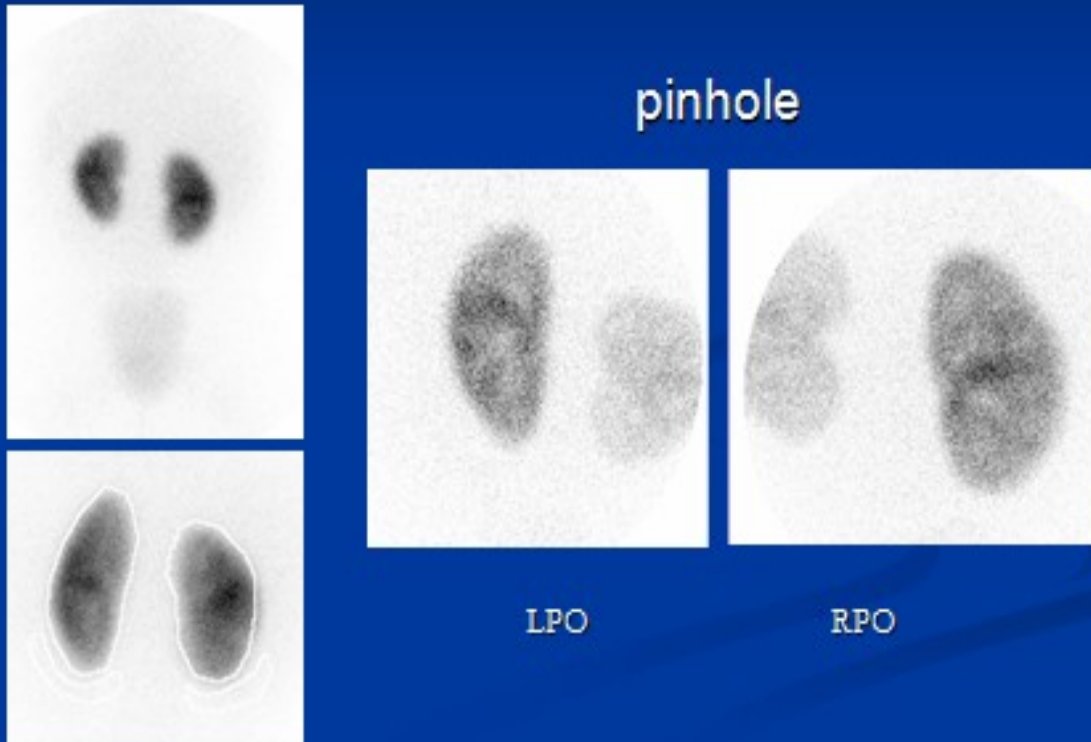


Image (1) normal DMSA scan

Normal DMSA



Image(2) Normal DMSA Scan appearances

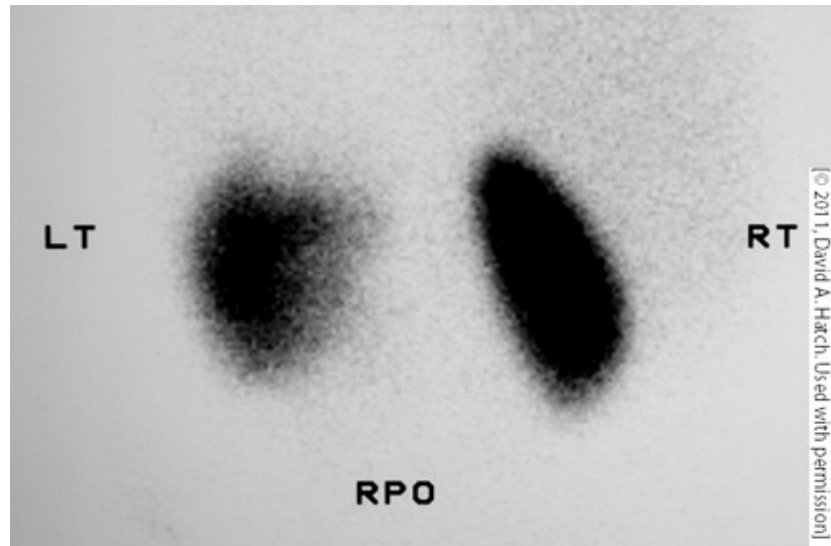


Image (3) Abnormal DMSA Scan (cold defect)

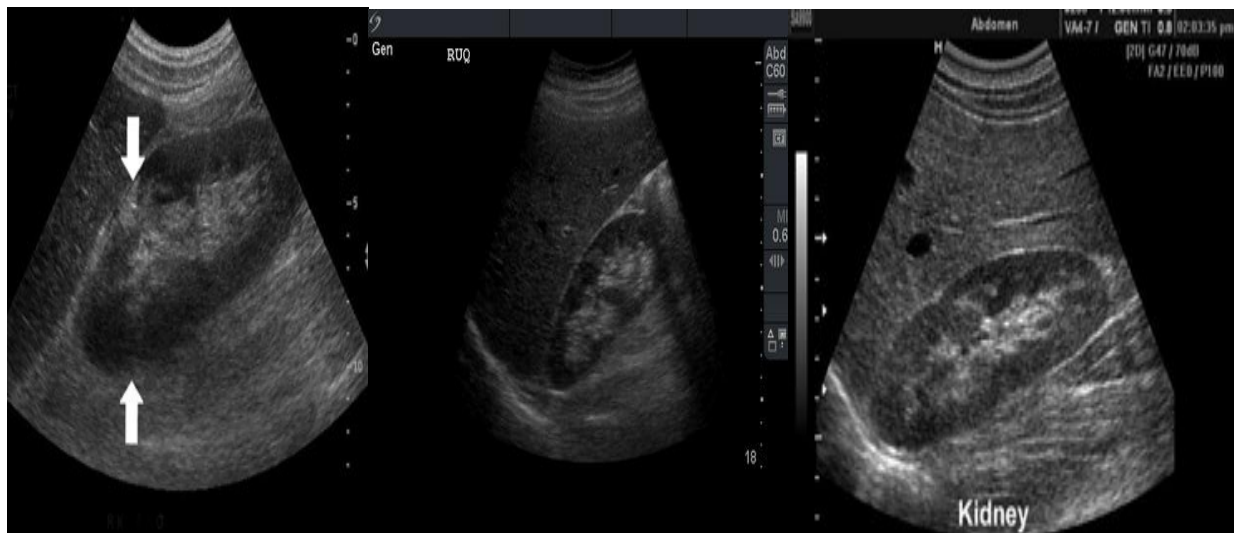
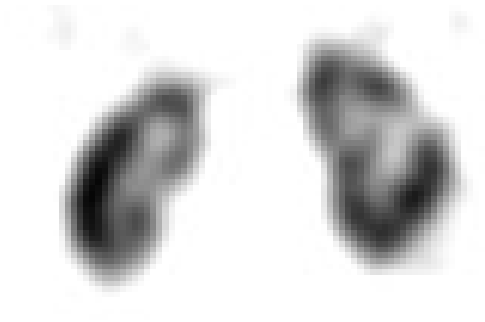
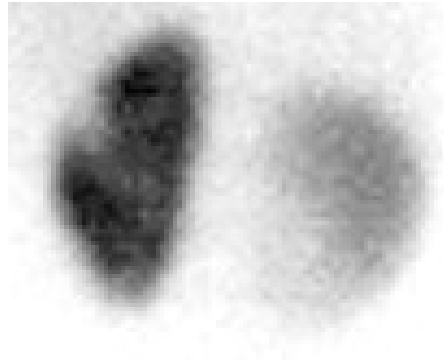


Image (4) normal RT kidney Ultrasound and scarred LT kidney

Planar image



Posterior SPECT



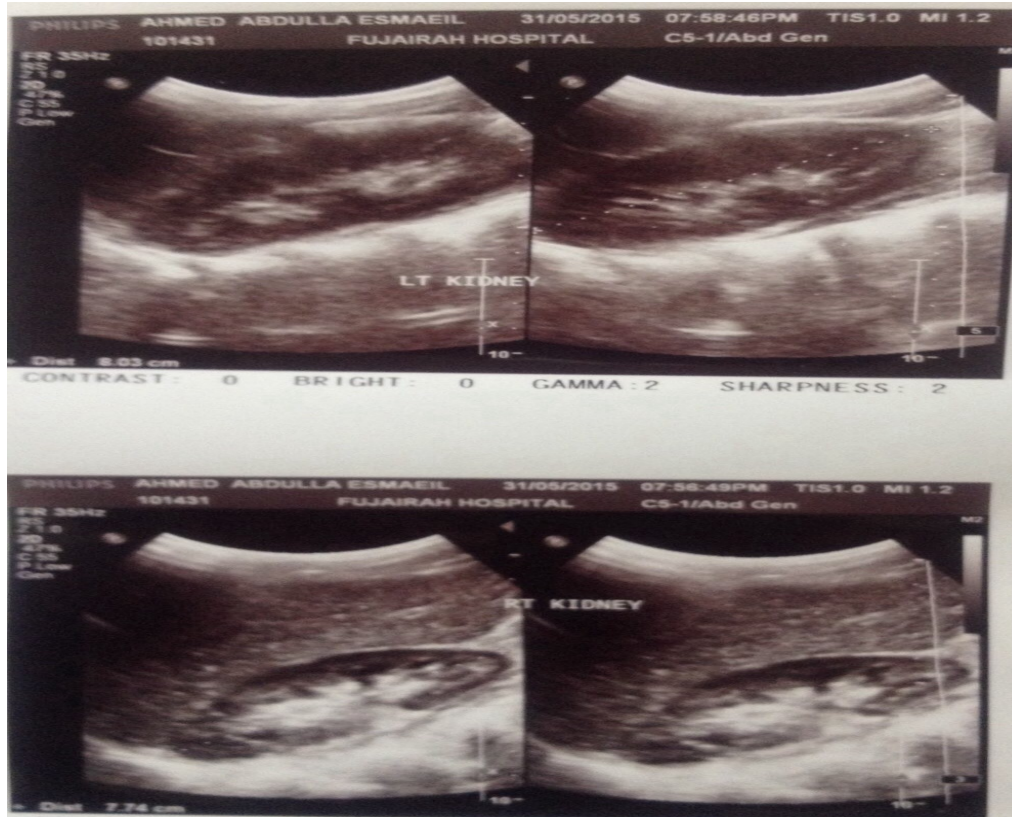


Image (4)Renalcortical scintigraphy of a 6years oldboy with acute pyelonephritis. High resolution planar images show a cortical defect in midzone of left kidney (arrow). In SPECT image, the defect is most clearly visualized in posterior slices (arrowhead). In Ultrasound it reported scarred left kidney.

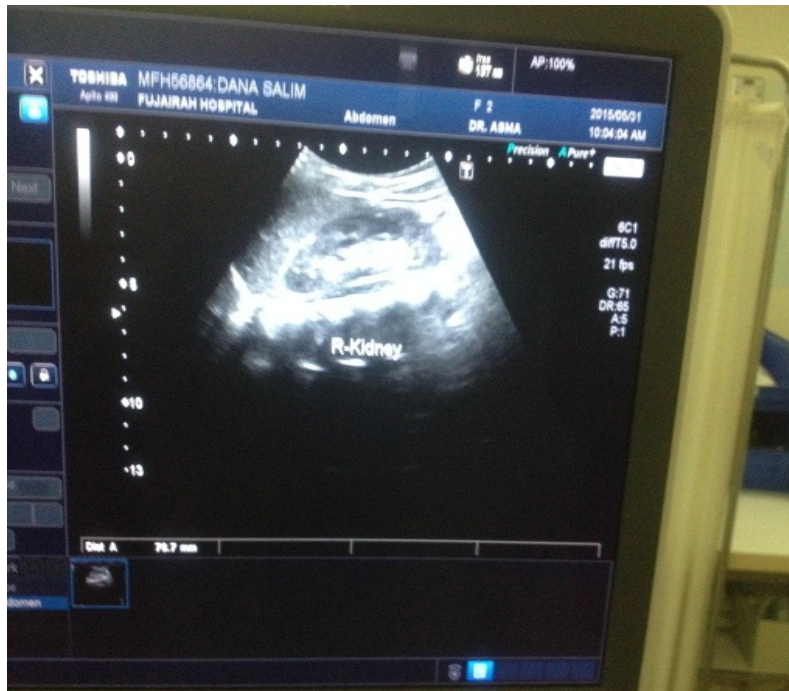

Image (5) Tc99m-DMSA renal SPECT scintigraphy for 3 years old girl with recurrent urinary tract infection(UTI), Ectopic left kidney with multiple scars which is reported in ultrasound left is not seen Kidney not seen.

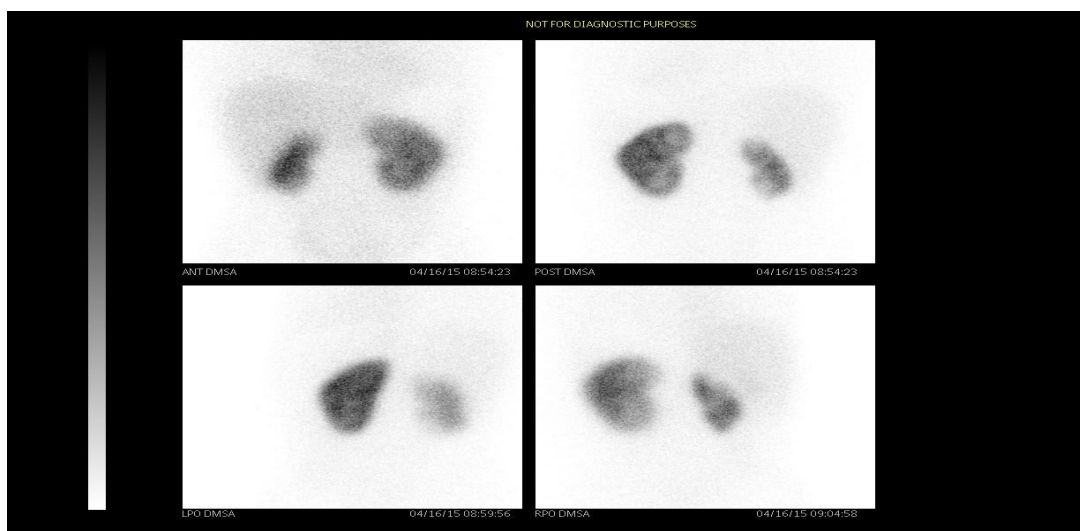
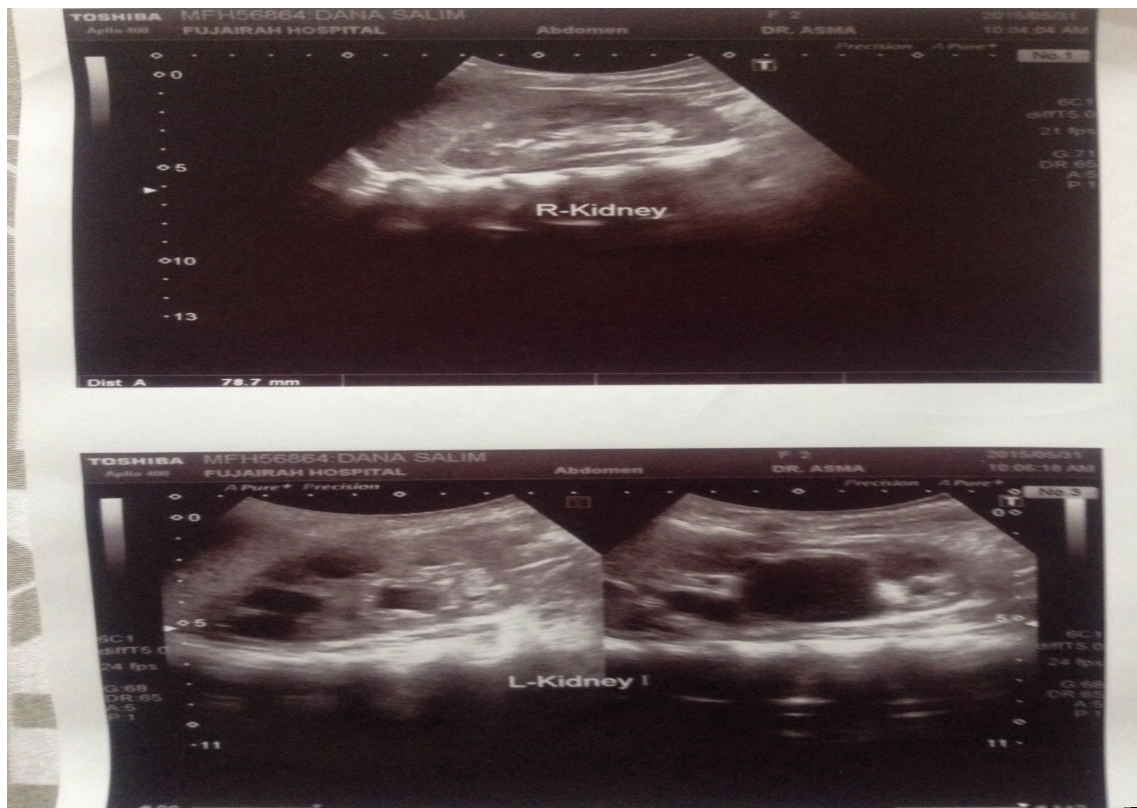
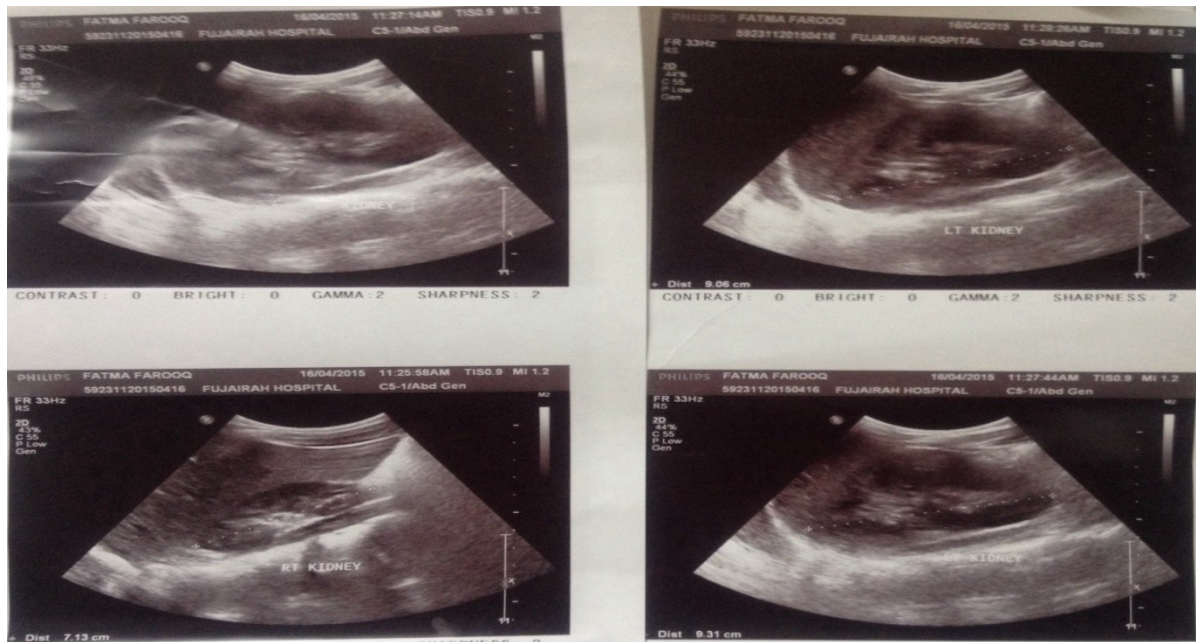


Image (6) Renal cortical scintigraphy of a 2 years old boy with acute pyelonephritis. High resolution planar images show a cortical defect in upper zone of left kidney (arrow), hydronephrosis of the right kidney. same diagnosis was reported In Ultra sound.



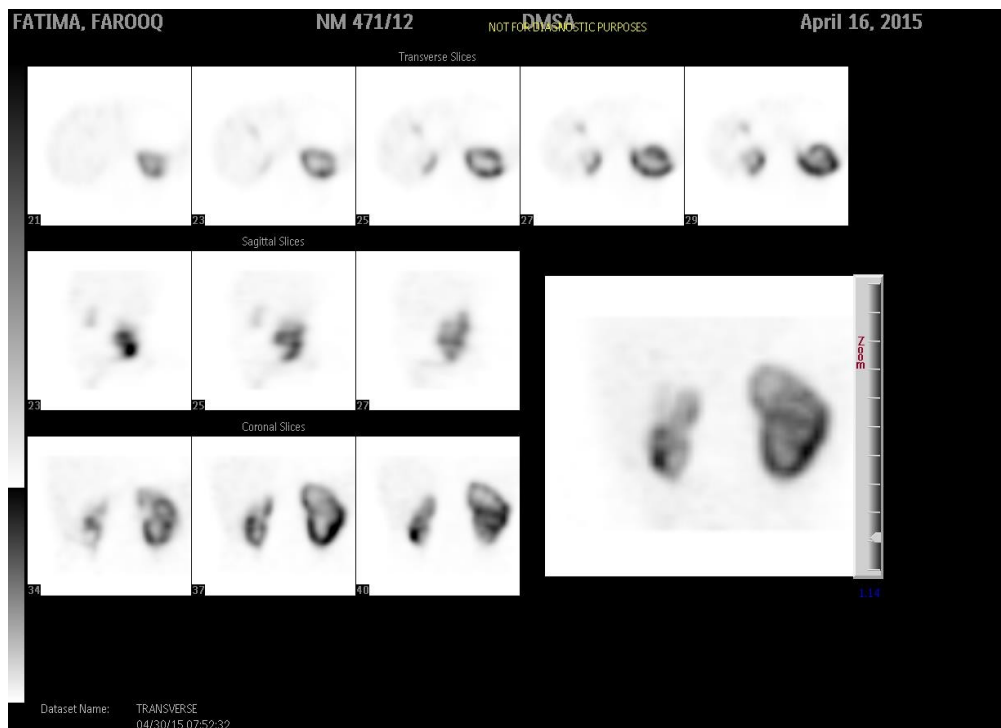


Image (7) Abdominal Ultrasound with Renal cortical scintigraphy of a 5 years old girl with acute pyelonephritis and grade four Vesicoureteric reflux (VUR). In SPECT images shows multiple cortical defect in left kidney (arrow) and hydronephrosis of right kidney. In Ultrasound it reported normal left kidney, hydronephrosis of right kidney.

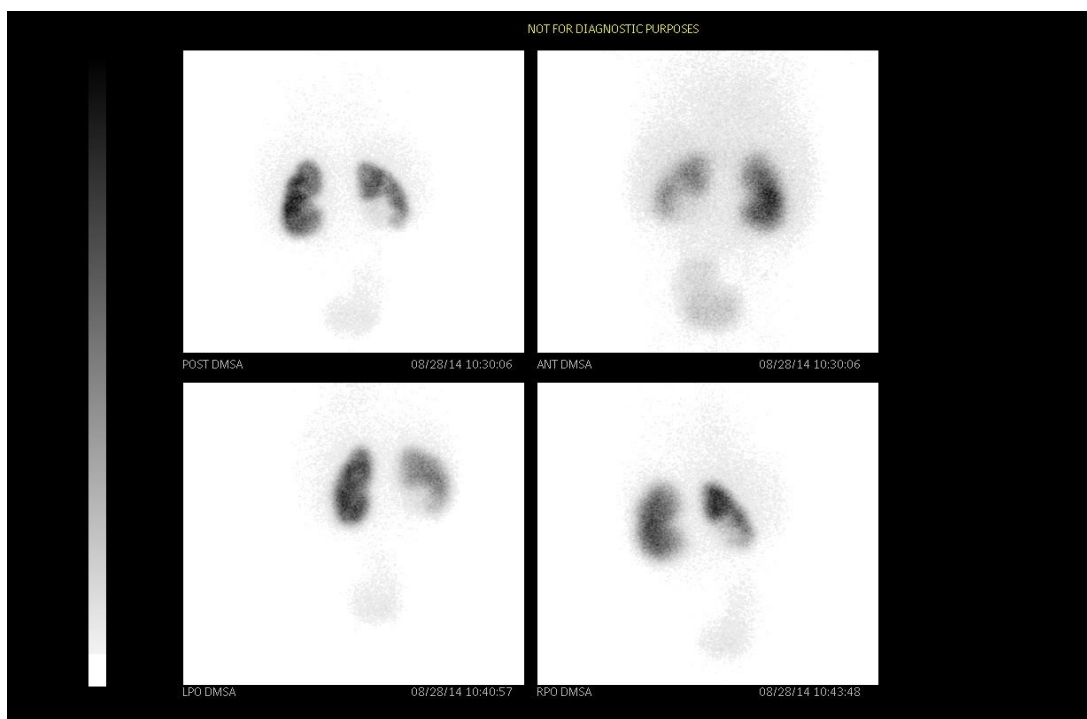
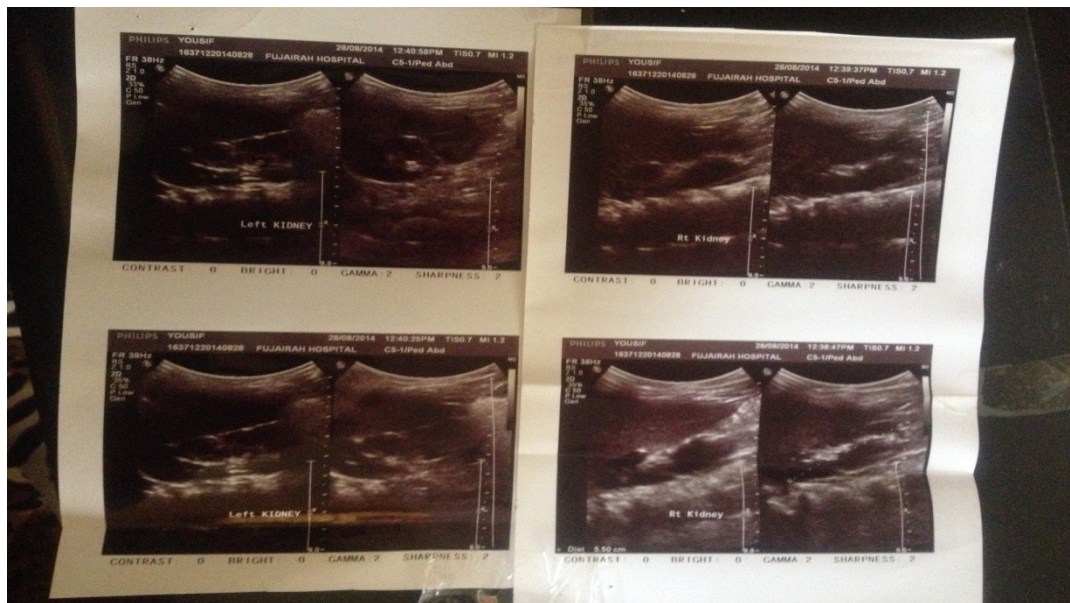
Image (8) Abdominal Ultrasound with Renal cortical scintigraphy of a 1 years old girl with acute pyelonephritis and grade four Vesicoureteric reflux (VUR).The Ultrasound images reported that scarred Rt kidney lower pole and normal left Kidney. High resolution planar images show a cortical defect in lower zone of right kidney and upper zoon of left kidney (arrows).

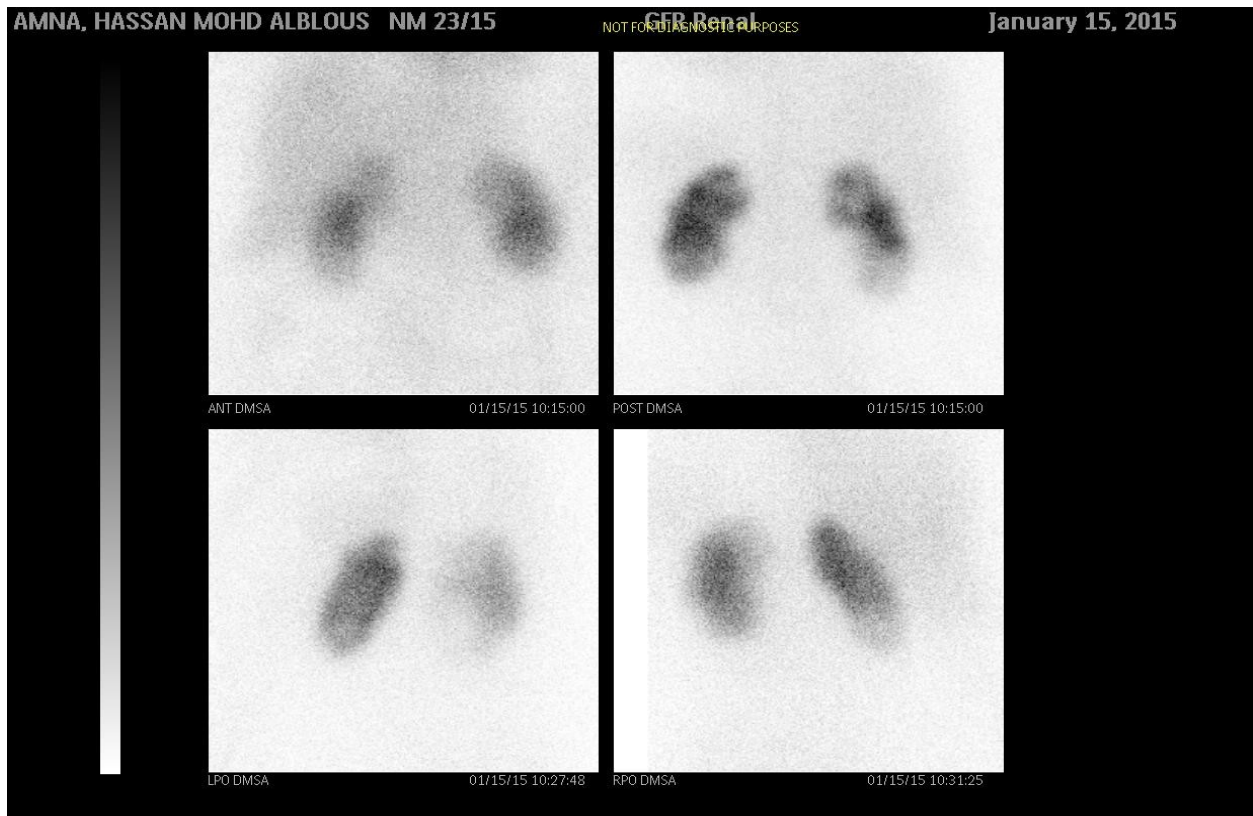

Image (9)Renal cortical scintigraphy of a 18 months old girl, with recurrent Urinary Tract Infection. The scan shows multiple scarred both kidneys, will the Ultrasound reported normal kidneys.

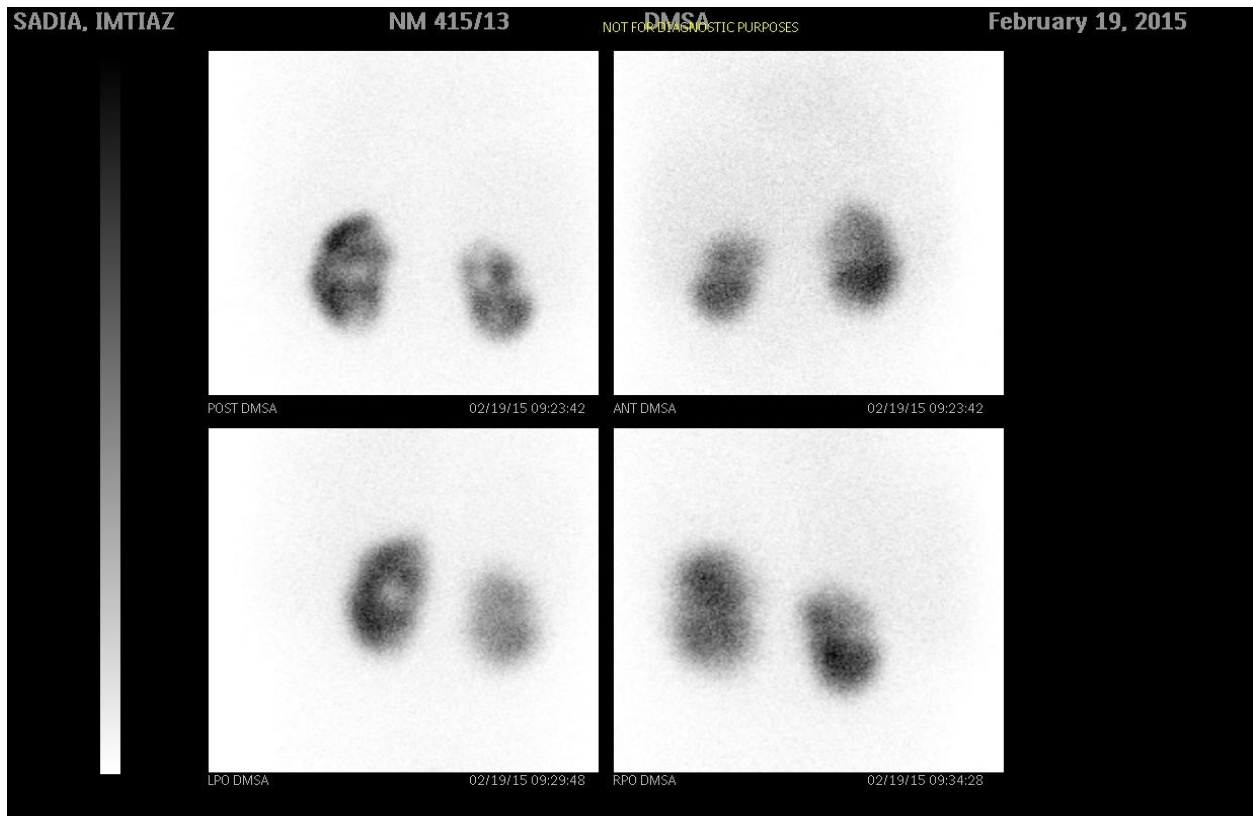


Image (10) Renal cortical scintigraphy of a 1 years old girl, with Urinary Tract Infection. The scan shows multiple scarred both kidneys, will the Ultrasound reported normal right kidney and scarred left kidney.

References

2. Corwin, Elizabeth, 2008, Hand book of pathophysiology, 3ed Edition, Lippincott Williams & Wilkins, Ohio, USA.
3. David et al. 2008 Pathology – Edward Arnold ,14th ed, London, UK.
4. [Harvey A. Ziessman](#), et al. 04 April 2013, Nuclear Medicine: The Requisites, 4th edition, USA, Philadelphia.
5. <http://inventors.about.com/library/inventors/blultrasound.htm>
6. <http://pediatrics.aappublications.org>
7. http://www.umm.edu/patiented/articles/how_serious_a_urinary_tract_infection
8. <http://www.webmd.com/a-to-z-guides/glomerulosclerosis>
9. [Isky Gordon](#), 2004, Ultrasonography in the evaluation of renal scarring using DMSA scan as the gold standard, Journal pediatric Nephrology, Volume 19, Issue 2, 19:153-156.
10. Jr. Fred A. Mettler, 17 Jan 2012, [Essentials of Nuclear Medicine Imaging](#) , 6th edition, USA , Philadelphia
11. MacKenzie JR, 1996, A review of renal scarring in children. Nucl Med Commun, Springer, Berlin, Germany.
12. Mohkam M, Maham S, Rahmani A. et al. Technetium Tc 99m Dimercaptosuccinic Acid Renal Scintigraphy in Children With Acute Pyelonephritis IJKD , 2010;4:297-301.
13. M-R-E, 12 OCT 1987, Basic Anatomy and Physiology for Radiographer – Wiley Blackwell. 3rd ed. Oxford, UK.

- 14.P.E.S Palmer, 1995, Manual of Diagnostic Medical Ultrasound, California USA.
- 15.Richart.S.Snell, 2005, Clinical Anatomy for Medical Student – Mosby. 8th ed, New York, USA.