

Appendices One

Data Sheet

Appendices Two Images

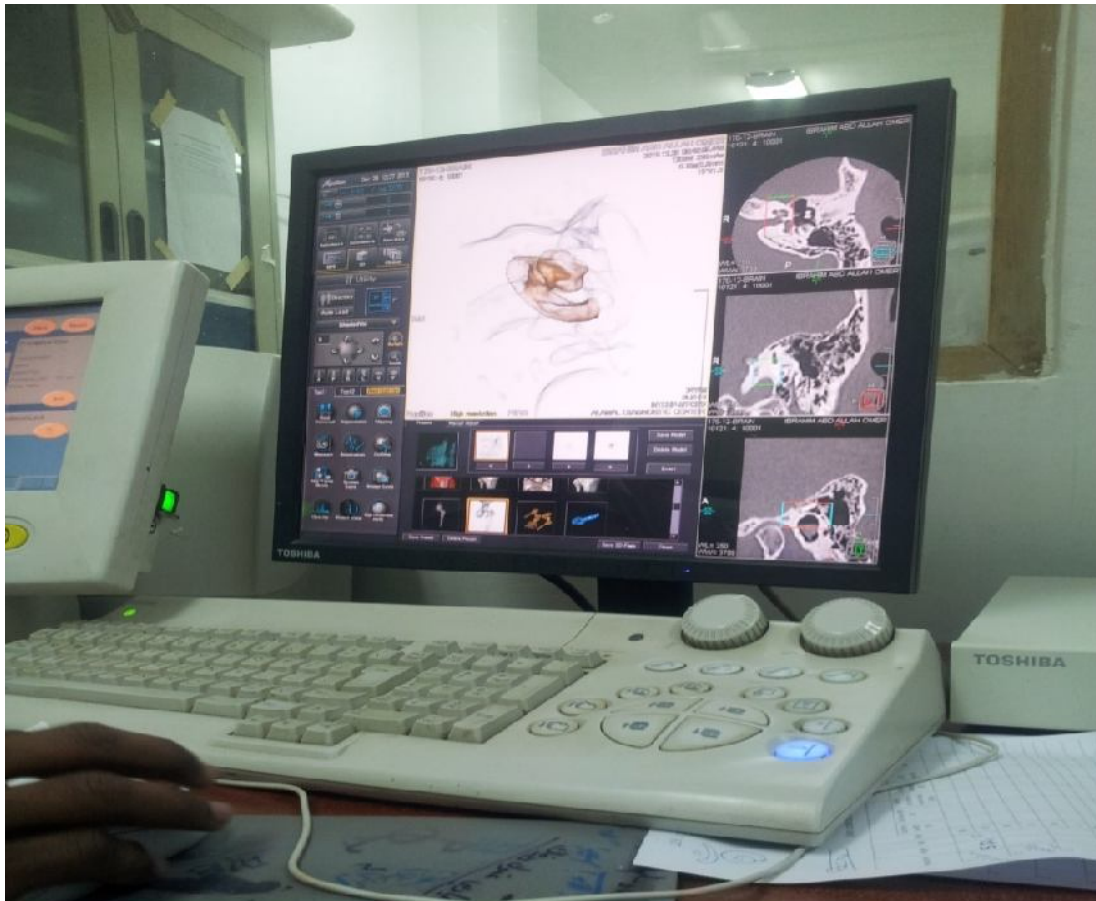

Image 1: Shows HRCT at Alamal Diagnostic center during cochlea measurements

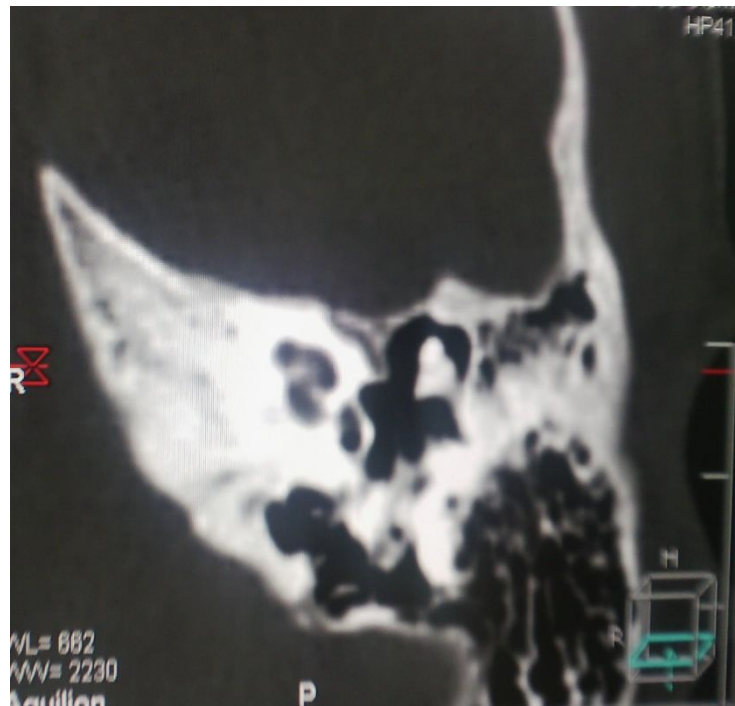


Image 2: Axial left cochlea section at the measured level

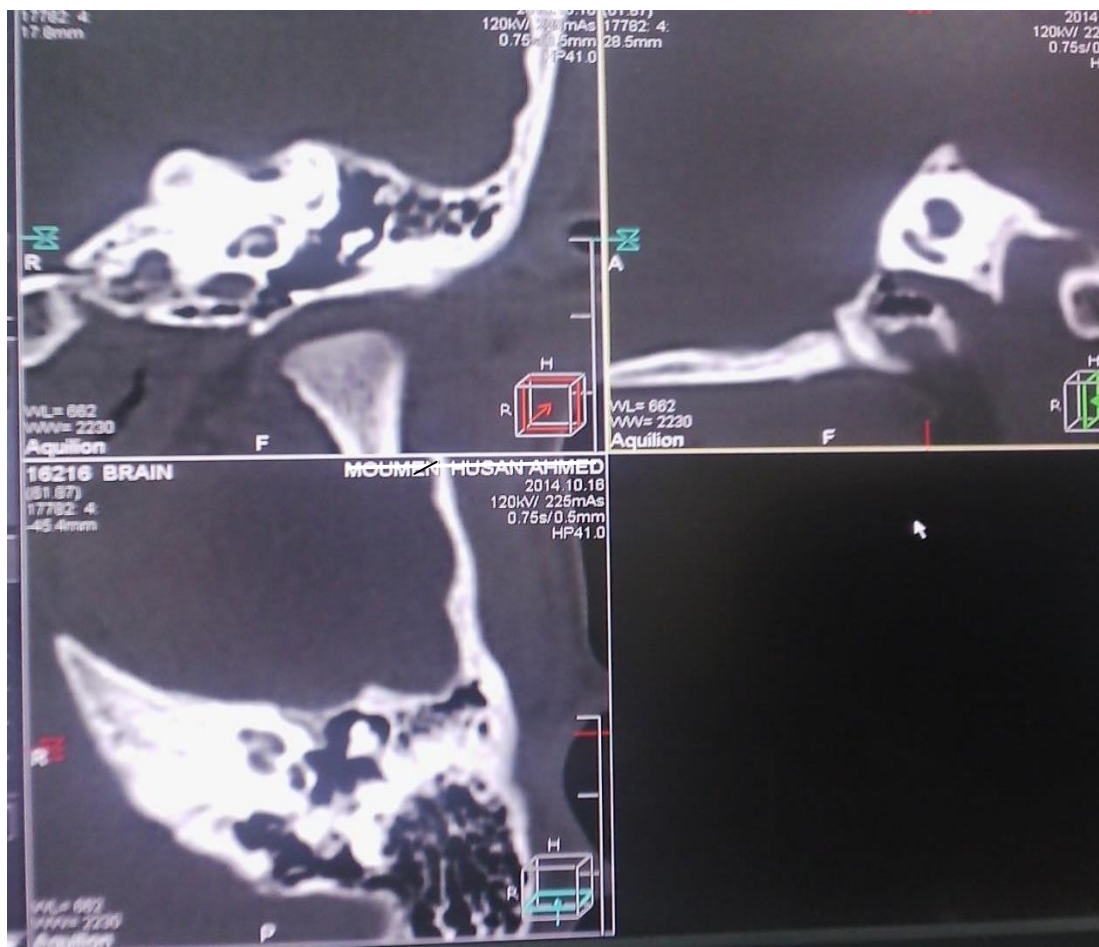


Image 3: Measured case male 21 years old left cochlea in coronal, sagittal and axial (MPR)

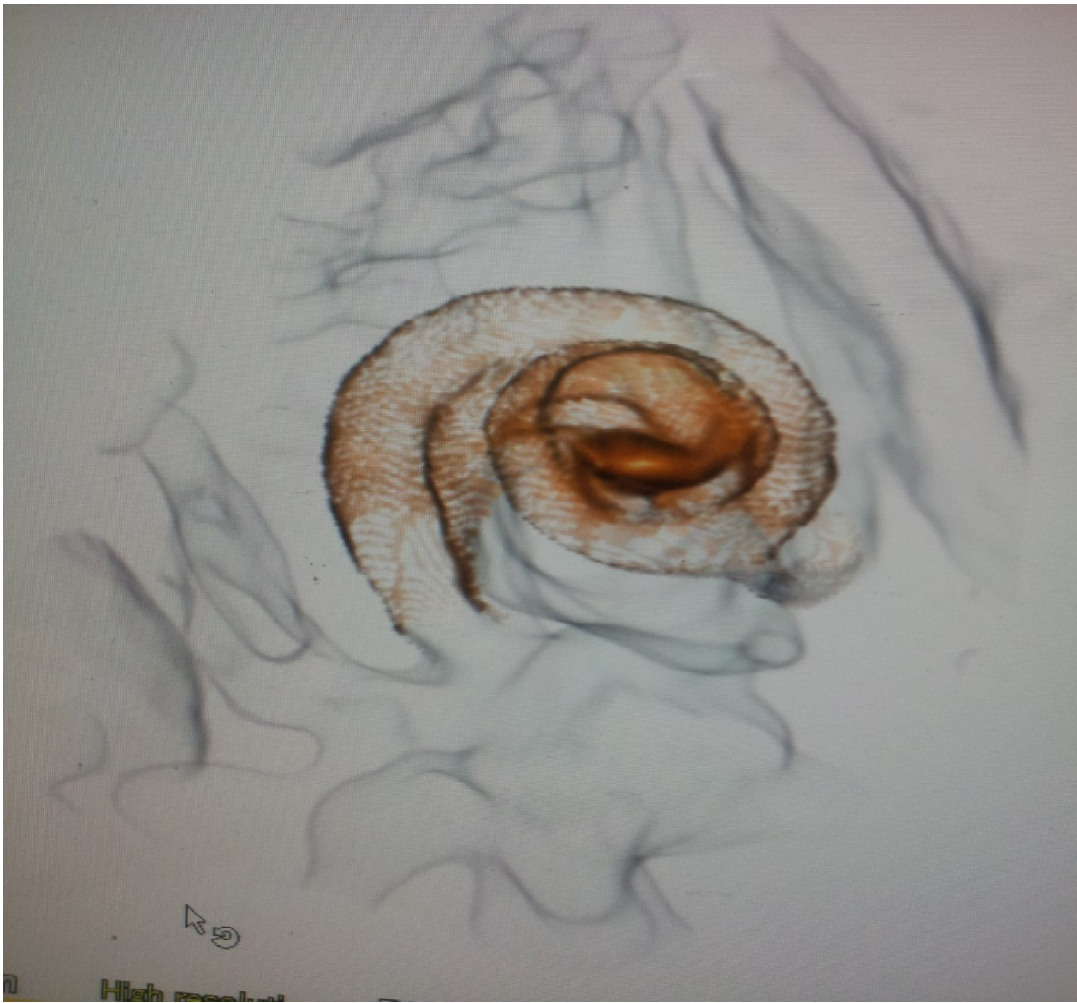


Image 4: Rt cochlea 3D male -27year

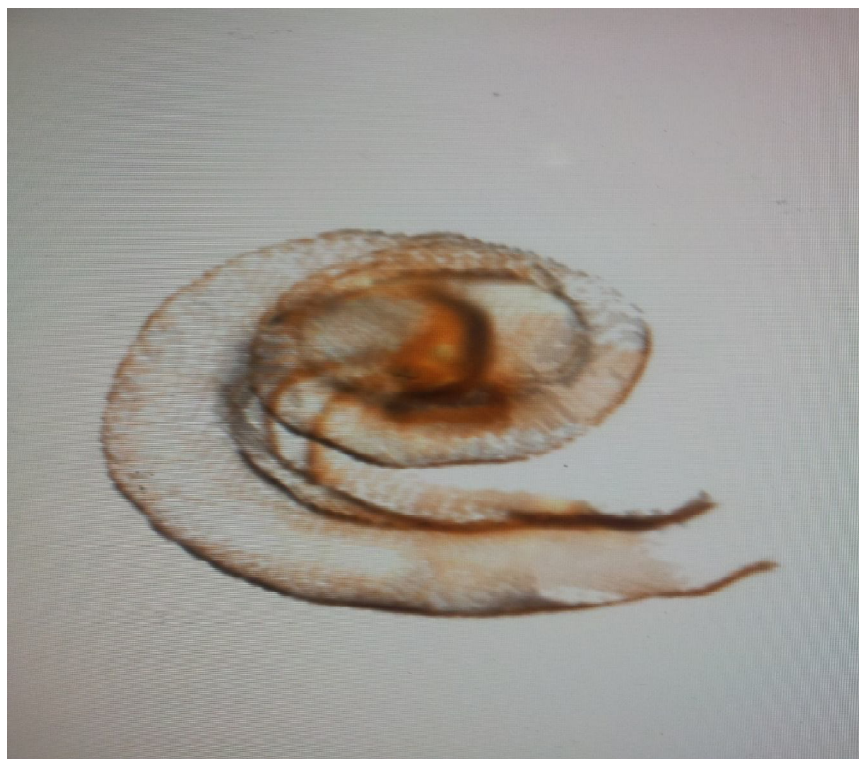

Image 5 :3D cochlear view reconstructed by HRCT

Rt cochlea 3D male -27years subtracted image

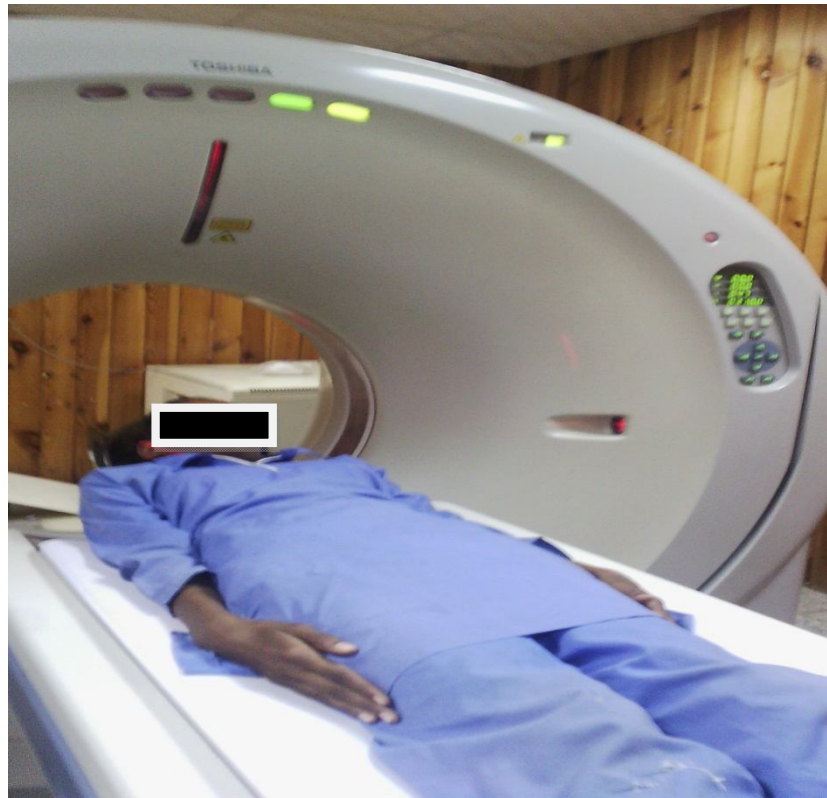

Image 6: Hearing loss volunteer durring brain scan