

بِسْمِ اللَّهِ الرَّحْمَنِ الرَّحِيمِ

Sudan University of Science and Technology

College of Medical Radiologic Sciences

Assessment of Prostate Gland Size Using
Ultrasonography

تقدير حجم غدة البروستاتا باستخدام الموجات فوق الصوتية

Research Submitted for Partial Fulfillment of Requirement of B.sc Degree in
Diagnostic Radiologic Technology

: Prepared by

- Sara HifzAllah Awad
- Riham Ahmed Abdullah
- RashaDamra

: Supervised by

Dr. El-Safi Ahmed Abdullah

قال الله تعالى :

"إِنَّ فِي خَلْقِ السَّمَوَاتِ وَالْأَرْضِ وُجُوهً لِّتَلَّافٍ لِّلنَّاسِ
وَالنَّهَارِ لآيَاتٍ لِّأُولِي الْأَبْصَارِ الَّذِينَ يَتَذَكَّرُونَ اللَّهَ قِيَامًا
وَقُؤْمًا وَعَلَىٰ جُؤْمِهِمْ وَيَتَفَكَّرُونَ فِي خَلْقِ السَّمَوَاتِ
وَالْأَرْضِ رَبَّنَا مَا خَلَقْتَ هَذَا بَاطِلًا ۗ - بِحَاثِكَ فَقَرَّبْنَا
عَذَابَ النَّارِ"

آل عمران آية (190-191)

Dedication

This work is dedicated to our parents, brothers and sisters for their endless support, our friends who stood side by side with us through the past Academic years. And everyone who offered their assistance to complete this humble work.

Acknowledgement

Most gratefulness to Allah, our Lord and Cherisher, for guiding us to complete this work. Indeed, without His help and will, nothing was accomplished.

Deep gratitude to Dr. El-Safi Ahmed our research supervisor, for his patient guidance, enthusiastic encouragement and useful critiques of this research work. And many thanks to Dr. Mohammed Al-Fadhil for his advice and assistance.

Finally, thanks to our parents for their support and encouragement throughout my study.

Abstract

This study aims to analyze the utility of ultrasound in the estimation of the size of the prostate gland. And to show the relationship between the size of the prostate gland with age. This study was conducted in Sudan University of Science and Technology, Ultrasound Department. And a sample of 30 adult male patient with an age between 30-43 years old (35.3 ± 4.1), and transabdominal ultrasound was used to measure the length, depth and width of the prostate gland, from which the size of prostate for all patients was obtained through the formula:

$$L * W * D * 0.052 \text{ mm}$$

Where L is the length of the prostate, W is the width of prostate, and D is the depth of Prostate.

Our results shows that length, width, depth and size of the prostate has linear relationship with the age.

الملخص

هذه الدراسة تهدف لوضوح فائدة استخدام الوجات فوق الصوتية في تقدير حجم ندوة البروستاتا و لوضوح العلاقة بين حجم ندوة البروستاتا و العمر. هذه الدراسة أجريت في جامعة الوكان للعلوم والتكنولوجيا، قسم الوجات فوق الصوتية. تم استخدام عينة تتكون من 30 وضا، تقو ح أعمارهم بين 30 عاما إلى 43 عاما (35.3 ± 4.1) و تم استخدام جهاز الوجات فوق الصوتية عن طيق البطن لقياس طو ل و عرض عمق ندوة البروستاتا لكل الوضى و منها تم تقدير حجم البروستاتا لكل الوضى باستخدام المعادلة : $L*W*D*0.52$ مم

حيث L تمثل طو ل ندوة البروستاتا ، W تمثل عرض ندوة البروستاتا، D تمثل عمق ندوة البروستاتا.

وأوضحت هذه الدراسة أن الطو ل و العرض و العمق و الحجم لهم علاقة خطية طردية مع العمر.

Table of Contents

Subject	.Page
الآية	
Dedication	I
Acknowledgement	II
(Abstract)English	III
(Abstract)Arabic	IV
Abbreviation	V
Table of contents	VI
List of tables	VII
List of figures	VIII

Chapter One

Subject	.Page
Introduction	1
Overview of the Study	4

Chapter Two

Subject	.Page
Anatomy	5
Physiology	8
Pathology	10
Sonographic Appearance	16

Physical Aspects of Ultrasound	19
Liretature Review	24

Chapter Three

Subject	.Page N
Materials & Methods	26

Chapter Four

Subject	.Page N
Results	27

Chapter Five

Subject	.Page N
Discussion	31
Conclusion	33
Recommendation	34
Reference	35
Appendix	36

List of Tables

Table} 4-1 { shows the means and the standard deviations of the age of patients, and the length, width, depth, volume and weight of the prostate	27.....
Table} 5.1 { Example of master data sheet used incalculation..	36

List of images

Image } 2-1 { : side view of the prostate	5
Image } 2-2 { : shows anatomy of prostate gland	9
Image } 2-3 { : Shows difference between normal prostate and prostatitis 11.....	
Image } 2-4 { : shows normal prostate vs. Enlarged prostate	13
Image } 2-5 { : Normal sonographic appearance of prostate gland	16
Image } 2-6 { : Benign prostatic hypertrophy	17
Image)2.7.(Shows a Trans rectal ultrasound image of chronicprostatiti.....	18

List of Figures

- Figure } 4-1 { is a scatter plot shows a direct linear relationship of patient age and the length of the prostate. the trend line depicts the linear proportionality correlation28
- Figure} 4-2 { scatter plot shows a direct linear relationship of patient age and the width of the prostate. the trend line depicts the linear proportionalitycorrelation28
- Figure } 4-3 { scatter plot shows a direct linear relationship of patient age and the depth of the prostate. the trend line depicts the linear proportionalitycorrelation....29
- Figure} 4-4 { scatter plot shows a direct linear relationship of patient age and the prostate volume of the prostate. the trend line depicts the linear proportionality correlation29
- Figure} 4-5 { scatter plot shows a direct linear relationship of patient age and the prostate weight of the prostate. the trend line depicts the linear proportionality correlation30

Chapter One

1.1 Introduction:

Prior to World War II, sonar, the technique of sending sound waves through water and observing the returning echoes to characterize submerged objects, inspired early ultrasound investigators to explore ways to apply the concept to medical diagnosis. In 1929 and 1935, Sokolov studied the use of ultrasonic waves in detecting metal objects. Firestone (1940) and Simons (1945) developed pulsed ultrasonic testing using a pulse-echo technique. Shortly after the close of World War II, researchers in Japan began to explore the medical diagnostic capabilities of ultrasound.

M. H. Rapacholi 1982.

The first ultrasonic instruments used an A-mode presentation with blips on an oscilloscope screen. That was followed by a B-mode presentation with a two dimensional, gray scale image Japan's work in ultrasound was relatively unknown in the United States and Europe until the 1950s. Researchers then presented their findings on the use of ultrasound to detect gallstones, breast masses, and tumors to the international medical community. Japan was also the first country to apply Doppler ultrasound (an application of ultrasound that detects internal moving objects such as blood coursing through the heart for cardiovascular investigations) in 1980. M. H. Rapacholi 1982.

Prostate volume measurement is frequently used to diagnose the abnormalities of the prostate. Abnormal enlargement of the prostate may be due to inflammation or virus infection. In a more severe case, the abnormal enlargement may indicate prostate cancer. The measurement of the prostatic gland is commonly performed by using transrectal scanning. However, this scanning method causes uncomfortable feeling. Therefore, this study proposes the use of transabdominal scanning in the measurement of prostatic volume. The subjects are requested to fully fill their urinary bladder to obtain clear prostatic gland images. M. H. Rapacholi 1982..

Prostate is a compound tubuloalveolar exocrine gland of the male reproductive system. The function of prostate is to secrete slightly acidic fluid, which has the characteristic of milky or white in appearance. The secretion usually constitutes 20% to 30% of the volume of the semen along with spermatozoa and seminal vesicle fluid. In medical practice, most of the prostate abnormalities are diagnosed by measuring their volume. Normally, the prostate volume range has the size of 250mm at birth to 100000 mm sized at puberty. After puberty, the prostate volume will continuously grow as the age increase for most of the male's life. The American Cancer society found that prostate cancer is one of the most common cancers affecting the older men in developed countries. It is getting a serious attention from the world as it has become a significant cause of death for elderly men. M. H. Rapacholi 1982..

Ultrasound is safe and painless, and produces pictures of the inside of the body using sound waves. Ultrasound imaging, also called ultrasound scanning or sonography, involves the use of a small transducer (probe) and ultrasound gel placed directly on the skin. High-frequency sound waves are transmitted from the probe through the gel into the body. M. H. Rapacholi 1982.

The transducer collects the sounds that bounce back and a computer then uses those sound waves to create an image. Ultrasound examinations do not use ionizing radiation (as used in x-rays), thus there is no radiation exposure to the patient. Because ultrasound images are captured in real-time, they can show the structure and movement of the body's internal organs, as well as blood flowing through blood vessels. M. H. Rapacholi 1982.

The early applications of ultrasonography in medicine involved sound-wave generators, cathode-ray tubes, Polaroid photography, or 35-mm film recording. However, the invention of the silicone microchip gave birth to the modern ultrasonography revolution. M. H. Rapacholi 1982.

Early investigators in prostatic ultrasonography conducted experiments with ultrasound probes and recording devices. One of the earliest devices was a chair-type apparatus with a probe mounted in the center of the chair. The patient sat on the probe, which was guided into the rectum.

Improvements in gray-scale ultrasound display and multiplanar scanning have resulted in user-friendly hand-held probes. M. H. Rapacholi 1982.

Ultrasound imaging is a noninvasive medical test that helps physicians diagnose and treat medical conditions. Prostate ultrasound, also called transrectal ultrasound, provides images of a man's prostate gland and surrounding tissue. The exam typically requires insertion of an ultrasound probe into the rectum of the patient. The probe sends and receives sound waves through the wall of the rectum into the prostate gland which is situated right in front of the rectum. M. H. Rapacholi 1982. Earlier studies concentrated on the ultrasonographic appearances of prostate abnormalities such as benign prostatic hyperplasia (BPH), carcinoma of the prostate (CAP), prostatitis, prostatic abscess, and prostatic calculi. Since the introduction of the prostate-specific antigen (PSA) screening test and early detection of prostate cancer, the role of TRUS has changed; it is mainly used to visualize the prostate (see the image below) and to aid in guided needle biopsy. M. H. Rapacholi 1982.

1.2 Overview of the study

1.2.1 Problem of the study :

Benign prostatic hyperplasia (BPH) or prostate gland enlargement is a common disease that has been reported to occur in 19-30% of men in their 30s. This study concentrates on obtaining the normal prostate gland's size to compare with other abnormal cases.

1.2.2 Objectives of the study:

1.2.2.1 General objectives:

- To measure the size of the prostate gland.
- To correlate the size of the prostate gland with age.

1.2.2.2 Specific objectives:

- To assess the mean and the standard deviation of prostate gland by measuring the length, width and depth, and age.
- To estimate the size of the gland in mm.
-

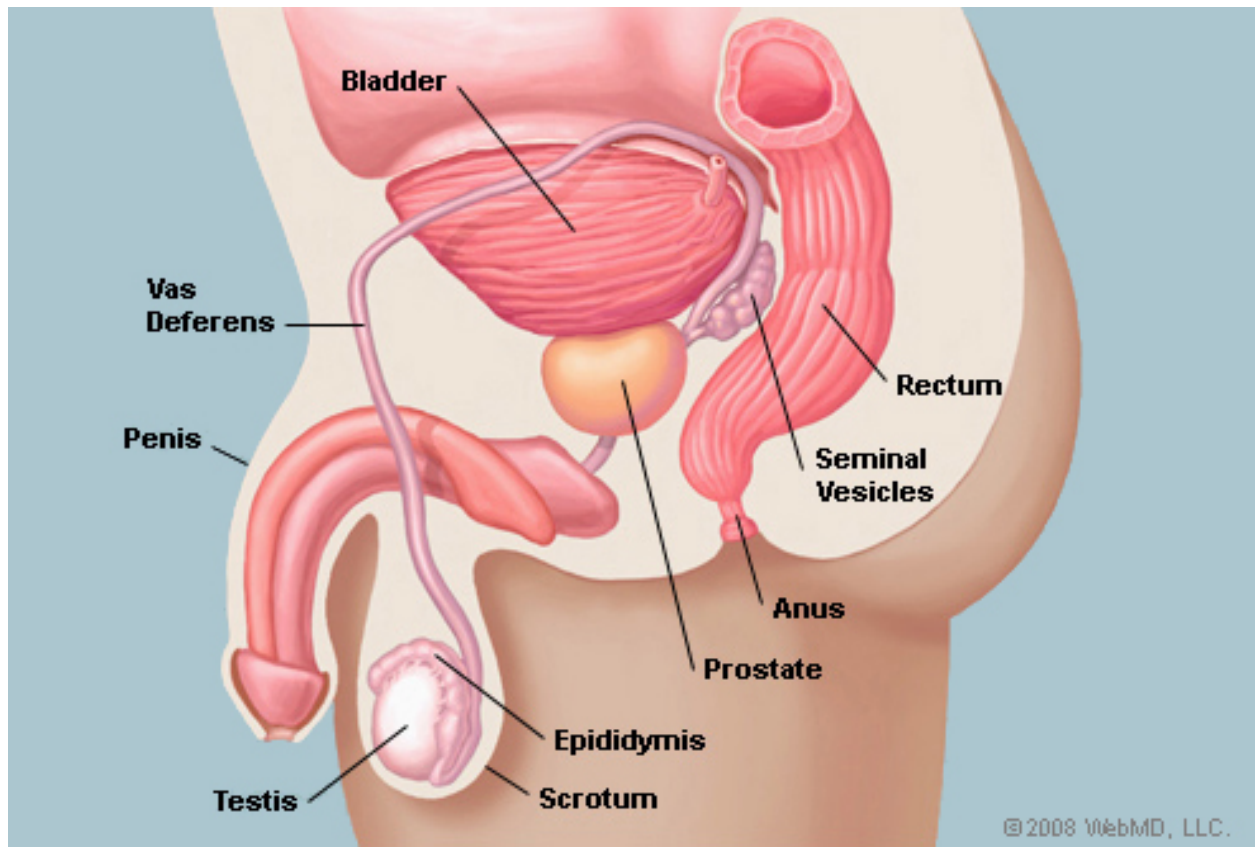
1.2.3 Area of study:

Sudan University of Science and Technology, College of Medical Radiologic Science, ultrasound department.

Chapter Two

2.1 Anatomy:

2.1.1 Structure of the prostate:



Image{2-1}: side view of the prostate. Hiraoaka Y, Akimoto M 1997.

The prostate gland is shaped like a donut, weighs about an ounce and is the size of a chestnut. It consists 30% muscular tissue and 70% glandular tissues. **Hiraoaka Y, Akimoto M 1997.**

2.1.2 Prostate location:

The prostate gland is just below the bladder, behind the pubic bone and just in front of the rectum. The prostate wraps around the urethra, which is the tube that carries urine from the bladder to the penis. **Hiraoaka Y, 1987.**

2.1.3 Relation:

The relations of the prostate are:

- Superiorly, contiguous with the neck of the bladder.
- Anteriorly, with the pubo-prostatic ligaments, prostatic venous plexus, and symphysis pubis
- Posteriorly, separated from the rectum by the prostatic fascia and the mesorectum.
- Postero-superiorly, with the seminal vesicles, ejaculatory ducts and ductus deferens.
- Laterally, with the levator, separated by the prostatic plexus of veins.
- Inferiorly, with the deep transverse perineal muscle and sphincter urethrae, bulbourethral glands, and the bulb of the penis. **Hiraoaka Y, 1987.**

2.1.4 Zonal anatomy:

2.1.4.1 The peripheral zone:

Constitutes over 70% of the glandular prostate. It forms a disc of tissue whose ducts radiate laterally from the urethra lateral and distal to the verumontanum. Almost all carcinomas arise here. **Hiraoaka Y, 1987.**

2.1.4.2 The central zone

Constitutes 25% of the glandular prostate. Its ducts arise close to the ejaculatory duct orifices and follow these ducts proximally, branching laterally near the prostate base. Its lateral border fuses with the proximal peripheral zone border, completing in continuity with the peripheral zone, a full disc of secretory tissue oriented in a coronal plane. Marked histologic differences between central and peripheral zones suggest important biologic differences. Hiraoka Y, 1987.

2.1.5 Lobes of prostate gland:

- 1- Anterior lobe (or isthmus): roughly corresponds to part of transitional zone.
- 2- Posterior lobe: roughly corresponds to peripheral zone.
- 3- Lateral lobes: spans all zones.
- 4- Median lobe (or middle lobe): roughly corresponds to part of central zone. Hiraoka Y, Akimoto M 1997.

2.1.6 Preprostatic region:

The urethral segment proximal to the verumontanum is kinked anteriorly at a 35-degree angle to the distal segment. No major ducts arise in the proximal segment, but the lateral rows of peripheral zone orifices continue. Duct development is aborted here, producing only a small transition zone and several tinier periurethral ducts. The development of these small ducts is possibly determined and limited by their intimate relationship to a periurethral smooth muscle sphincter that exists only proximal to the verumontanum. These small ducts in a restricted area are the exclusive site of nodular hyperplasia (BPH) origin. . Hiraoka Y, 1987.

The anterior fibromuscular stroma forms the entire anterior surface of the prostate as a thick, non-glandular apron, shielding from view the anterior surface of the three glandular regions. Its inseparable fusion to the glandular prostate has probably delayed recognition of the anatomic features described here. Hiraoka Y, Akimoto M 1997.

2.1.7 Development:

The prostatic part of the urethra develops from the pelvic (middle) part of the urogenital sinus (endodermal origin). Endodermal outgrowths arise from the prostatic part of the urethra and grow into the surrounding mesenchyme. The glandular epithelium of the prostate differentiates from these endodermal cells, and the associated mesenchyme differentiates into the dense stroma and the smooth muscle of the prostate.[12] The prostate glands represent the modified wall of the proximal portion of the male urethra and arises by the 9th week of embryonic life in the development of the reproductive system. Condensation of mesenchyme, urethra and Wolffian ducts gives rise to the adult prostate gland, a composite organ made up of several glandular and non-glandular components tightly fused. Jakobsen H, Torp-Pedersen S 1997.

2.2 Physiology:

2.2.1 General:

- The function of the prostate is to secrete a slightly alkaline fluid, milky or white in appearance, that usually constitutes 50–75% of the volume of the semen along with spermatozoa and seminal vesicle fluid. Semen is made alkaline overall with the secretions from the other contributing glands, including, at least, the seminal vesicle fluid. The alkalinity of semen helps neutralize the acidity of the vaginal tract, prolonging the lifespan of sperm. The alkalization of semen is primarily accomplished through secretion from the seminal vesicles. The prostatic fluid is expelled in the first ejaculate fractions, together with most of the spermatozoa. In comparison with the few spermatozoa expelled together with mainly seminal vesicular fluid, those expelled in prostatic fluid have better motility, longer survival and better protection of the genetic material. The prostate also contains some smooth muscles that help expel semen during ejaculation.

- Male sexual response.

Secretions: Prostatic secretions vary among species. They are generally composed of simple sugars and are often slightly acidic. In human prostatic secretions, the protein content is less than 1% and includes proteolytic enzymes, prostatic acid phosphatase, beta-microseminoprotein,

and prostate-specific antigen. The secretions also contain zinc with a concentration 500–1,000 times the concentration in blood.

- Regulation: To function properly, the prostate needs male hormones (testosterones), which are responsible for male sex characteristics. The main male hormone is testosterone, which is produced mainly by the testicles. Some male hormones are produced in small amounts by the adrenal glands. However, it is dihydrotestosterone that regulates the prostate **Jakobsen H, Torp-Pedersen S**

- The prostate helps to control the flow of urine. During sexual activity, the seminal vesicles that are attached to the prostate produce a protein that mixes with prostatic fluid which forms semen. The tubes from the testicles carry sperm up to the prostate where sperm is mixed with the seminal vesicle and prostatic fluids. This fluid is ejaculated during orgasm through ejaculatory ducts that connect to the urethra. **Jakobsen H, Torp-Pedersen S**

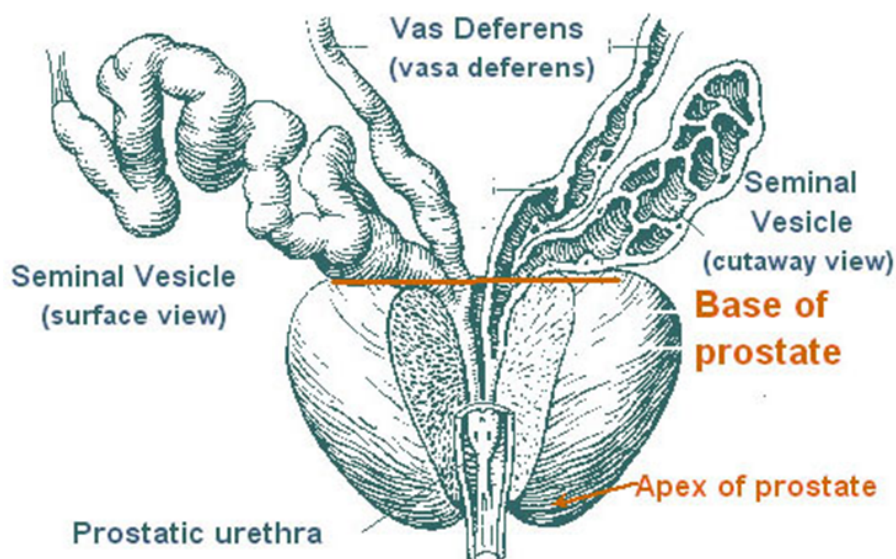


Image {2-2}: shows anatomy of prostate gland. Jakobsen H, Torp-Pedersen S

2.2.2 Blood supply of the prostate:

* Arteries: Branches of the inferior vesical and middle rectal arteries supply by the prostatic covesical arteries arising from the internal iliac arteries on each side. These vessels then gives rise to the prostatic arteries and inferior vesical artery.

* Veins: The veins form the prostatic venous plexus, lies is between the capsule of the prostate and the fibrous sheath. The prostatic plexus receives blood from the deep dorsal vein of the penis and numerous vesical veins and drains into the internal iliac veins.

* Lymph drainage: The lymph vessels from the prostate drain into the internal iliac nodes.

* Nerve Supply: The nerve supply to the prostate is from the inferior hypo gastric plexuses. The sympathetic nerves stimulated the smooth muscle of the prostate during ejaculation. **Jakobsen H, Torp-Pedersen S 1997.**

2.3 Pathology of the prostate gland:

2.3.1 Prostatitis:

An inflammation of the prostate gland.

There are two types: acute and chronic.

Acute prostatitis is not common, but is most likely to occur in young men. Causative agents include bacterial organisms similar to those causing urinary tract infections, as well as Neisseria gonorrhoea. A related complication of prostatic abscess is uncommon.

Chronic prostatitis may follow acute prostatitis, but is more likely to occur without prior history in older men, and may suggest an underlying obstructive urinary tract abnormality. There can be intermittent urinary frequency and dysuria **Jakobsen H, Torp-Pedersen S 1997**

2.3.1.1 Acute bacterial prostatitis:

A sudden bacterial infection marked by inflammation of the prostate. This is the least common form of prostatitis but the symptoms are usually severe. Patients with this condition have an acute urinary tract infection

with increased urinary frequency and urgency, a need to urinate a lot at night, and have pain in the pelvis and genital area. They often have fever, chills, nausea, vomiting, and burning when urinating. Acute bacterial prostatitis requires prompt treatment, as the condition can lead to bladder infections, abscesses in the prostate or, in extreme cases, completely blocked urine flow. Left untreated, the condition can cause confusion and low blood pressure, and may be fatal. The condition is usually treated in the hospital with intravenous antibiotics, pain relievers, and fluids. **Jakobsen H, Torp-Pedersen S 1997**

2.3.1.2 Chronic bacterial prostatitis:

This condition is the result of recurrent urinary tract infections that have entered the prostate gland. It is thought to exist for several years in some men before producing symptoms. The symptoms are similar to acute bacterial prostatitis, but are less severe and can fluctuate in intensity. The diagnosis of this condition is often challenging. It's often difficult to find the bacteria in the urine. Treatment includes antibiotics for four to 12 weeks and other treatment for pain. Sometimes men are given suppressive low-dose, long-duration antibiotic therapy. **Jakobsen H, Torp-Pedersen S 1997**

2.3.1.3 Chronic nonbacterial prostatitis/chronic pelvic pain syndrome:

This is the most common form of the disease, accounting for 90% of the cases. The condition is marked by urinary and genital pain for at least three of the past six months. Patients have no bacteria in their urine, but may have other signs of inflammation. The condition can be confused with interstitial cystitis (a chronic inflammation of the bladder).

How the prostate becomes infected is not clear. The bacteria that cause prostatitis may get into the prostate from the urethra by backward flow of infected urine or stool from the rectum. **Jakobsen H, Torp-Pedersen S 1997**

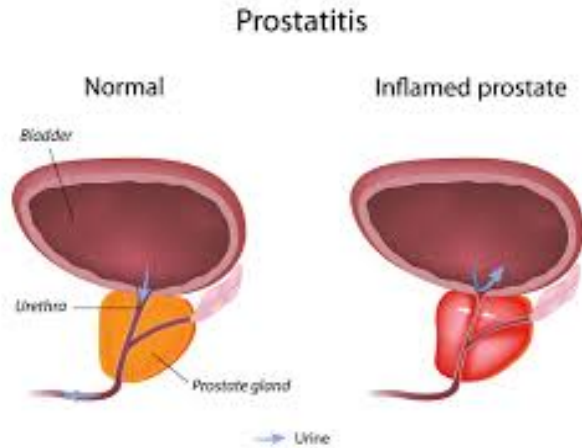


Image {2-3}: Shows difference between normal prostate and prostatitis. Jakobsen H, Torp-Pedersen S 1997

2.3.2 Tuberculosis:

Tuberculosis of the prostate shows characteristic glaucomatous reseating lesions and may involve the whole gland. Tuberculosis may extend in either direction along the vas, depending on whether the initial site of infection of the genital tract was by haematogenous involvement of the epididymis, or by asterism from the kidney to the urinary bladder and then to the prostate and vas deference. **Jakobsen H, Torp-Pedersen S 1997**

2.3.2.1 Symptoms:

- Nonspecific symptoms, including irritative voiding, may be the only complaints.
- Dysuria.
- Perianal pain.
- Sterile urethral discharge.
- Terminal hematuria. **Jakobsen H, Torp-Pedersen S 1997**

2.3.3 Benign Nodular Hyperplasia (BNH) (or benign prostatic hyperplasia (BPH) :

Benign prostatic hyperplasia (BPH) is a histologic diagnosis that refers to the proliferation of smooth muscle and epithelial cells within the prostatic transition. The exact etiology is unknown; however, the similarity between BPH and the embryonic morphogenesis of the prostate has led to the hypothesis that BPH may result from a “reawakening” in adulthood of embryonic induction processes.[3] The enlarged gland has been proposed to contribute to the overall lower urinary tract symptoms (LUTS) complex via at least two routes: (1) direct bladder outlet obstruction (BOO) from enlarged tissue (static component) and (2) from increased smooth muscle tone and resistance within the enlarged gland (dynamic component). Voiding symptoms have often been attributed to the physical presence of BOO. Detrusor overactivity is thought to be a contributor to the storage symptoms seen in LUTS. This Guideline attempts to globally encompass the concept of LUTS in a broad spectrum of etiologies, and focuses treatment (e.g., active surveillance, medical and surgical) on the management of such symptoms.

The prostate gland helps make semen, the fluid that contains sperm. The prostate surrounds the tube that carries urine out of the body. As men age, their prostate grows bigger. If it gets too large, it can cause problems. An enlarged prostate is also called benign prostatic hyperplasia (BPH). Most men will get BPH as they get older. Symptoms often start after age 50.

BPH is not cancer, and it does not seem to increase your chance of getting prostate cancer. But the early symptoms are the same. The prevalence and the severity of LUTS in the aging male can be progressive, and is an important diagnosis in the healthcare of our patients and the welfare of society Jakobsen H, Torp-Pedersen S 1997

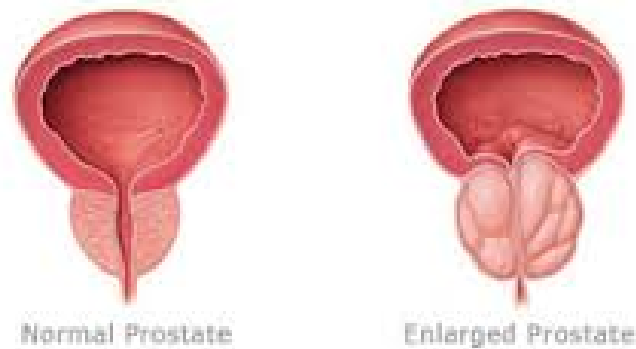


Image {2-4} : shows normal prostate vs. Enlarged prostate. Jakobsen H, Torp-Pedersen S 1997

2.3.3.1 Symptoms:

- A frequent and urgent need to urinate, especially at night
- Trouble starting a urine stream or making more than a dribble
- A urine stream that is weak, slow, or stops and starts several times
- The feeling that you still have to go, even just after urinating
- Small amounts of blood in your urine
- Severe BPH can cause serious problems over time, such as urinary tract infections, and bladder or kidney damage. If it is found early, you are less likely to develop these problems.

BPH represents an over growth of prostatic glandular tissue and smooth muscle and is comparable to conditions such as nodular goiter and cystic hyperplasia of the breast, It is very common and the incidence with age by the age of 80 over 75% of the males are affected to some degree although only some 5% have significant symptoms. Jakobsen H, Torp-Pedersen S 1997

The cause is obscure but hormonal factors must be important:

- BNH does not occur in eunuchs or castrated men.
- BNH is not regarded as premalignant.

The process starts in the periurethral prostatic glands and the growth occurs mainly on each side of the urethra (in the so- called lateral lobes),

although often there is a localized hyperplasia of the tissue just behind the urethra to form a rounded mass which projects into the bladder (the so-called Median lobe. **Jakobsen H, Torp-Pedersen S 1997.**

The hyperplastic tissue is usually firm, white and nodular but it may sometimes show areas of inflammation, abscess formation or infarction. Microscopically there is an increase in both the glandular elements and the stroma. The glands are usually arranged in well defined lobules and the acini are lined by tall columnar cells beneath which there is a basal cell layer the hyperplastic epithelium may extend into the lumina of the acini forming small papillary projections. Some of the acini may be dilated and small retention cysts can form. Tiny concentric concretions known as corpora amyloidea, formed from inspissated secretion, are commonly found, and deposition of oxalates and phosphates may produce prostatic calculi. The connective tissue stroma usually contains a substantial proportion of smooth muscle fibers. Fibromuscular hyperplasia is most prominent in the earlier stages of the process but in some cases it may be predominant, forming nodules in which glandular elements are scant. **Jakobsen H, Torp-Pedersen S 1997.**

2.3.4 Carcinoma of the prostate:

Is a form of cancer that develops in the prostate, a gland in the male reproductive system. Most prostate cancers are slow growing; however, there are cases of aggressive prostate cancers. The cancer cells may metastasize (spread) from the prostate to other parts of the body [6], particularly the bones and lymph nodes. Prostate cancer may cause pain, difficulty in urinating, problems during sexual intercourse, or erectile dysfunction. Other symptoms can potentially develop during later stages of the disease. The presence of prostate cancer may be indicated by symptoms physical examination prostate specific antigen PSA or biopsy. **Jakobsen H, Torp-Pedersen S 1997.**

2.3.4.1 Signs and symptoms

Early prostate cancer usually causes no symptoms. Sometimes, however, prostate cancer does cause symptoms, often similar to those of diseases such as benign prostatic hyperplasia. These include frequent urination, nocturia (increased urination at night), difficulty starting and maintaining a

steady stream of urine, hematuria (blood in the urine), and dysuria (painful urination). A study based on the 1998 Patient Care Evaluation in the US found that about a third of patients diagnosed with prostate cancer had one or more such symptoms, while two thirds had no symptoms. **Jakobsen H, Torp-Pedersen S 1997.**

Prostate cancer is associated with urinary dysfunction as the prostate gland surrounds the prostatic urethra. Changes within the gland, therefore, directly affect urinary function. Because the vas deferens deposits seminal fluid into the prostatic urethra, and secretions from the prostate gland itself are included in semen content, prostate cancer may also cause problems with sexual function and performance, such as difficulty achieving erection or painful ejaculation **Jakobsen H, Torp-Pedersen S 1997.**

Advanced prostate cancer can spread to other parts of the body, possibly causing additional symptoms. The most common symptom is bone pain, often in the vertebrae (bones of the spine), pelvis, or ribs. Spread of cancer into other bones such as the femur is usually to the proximal part of the bone. Prostate cancer in the spine can also compress the spinal cord, causing leg weakness and urinary and fecal incontinence. **Jakobsen H, Torp-Pedersen S 1997.**

2.4 Sonographic appearance:

2.4.1 Normal :

The overall sonographic appearance of the prostate is symmetric as the probe is swept side to side the anterior fibro muscular stroma is anechoic to hypo echoic the peri-urethral tissues are hypo echoic the urethra may appear echogenic with in this zone the reminder of the prostate is

homogeneous hypo echoic to isoechoic the seminal vesicle are hypo echoic multiseptated symmetric structures the angle of the seminal vesicle are formed by the entrance of the ejaculatory ducts into the prostate beak appearance. I Simon, PK Landis 1999.

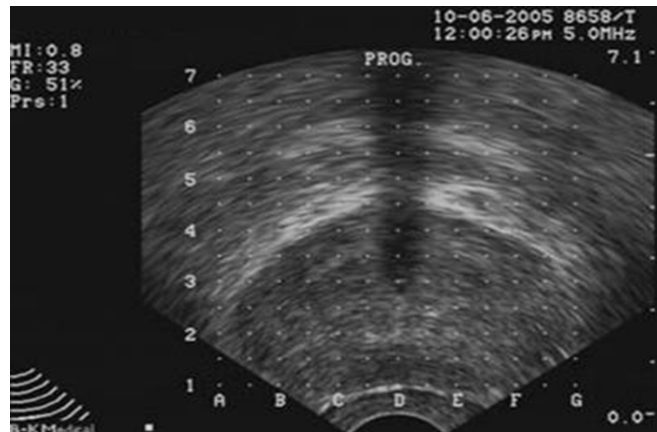


Image {2-5} : Normal sonographic appearance of prostate gland. I

Simon, PK Landis 1999.

2.4.2 Abnormal sonographic appearance:

2.4.2.1 Benign prostatic hyperplasia:

Ultrasound finding: enlarge homogeneous gland in the continuous border one third of cases have demonstrated echogenic structure other cases have

reported an inhomogeneous pattern cystic change within the central gland also seen I Simon, PK Landis 1999.

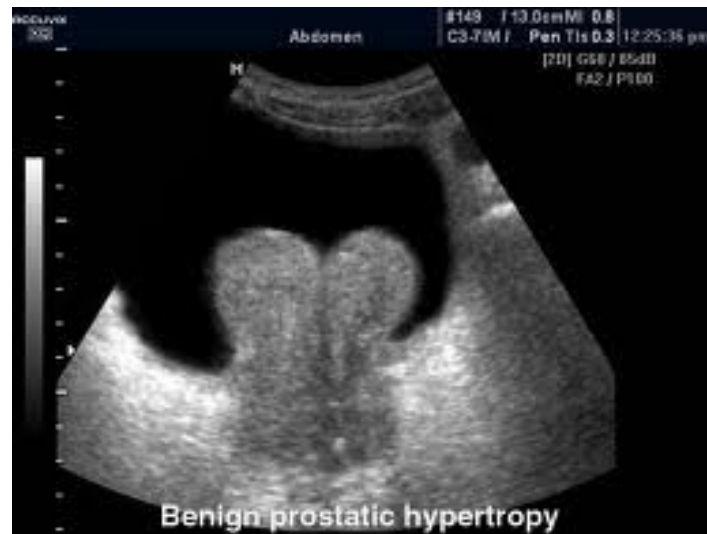

Image {2-6} : Benign prostatic hypertrophy. I Simon, PK Landis 1999.

2.4.2.2 Prostatitis :

Ultra sound finding: hypo echoic or anechoic mass within the prostate that may look similar to the cyst with thick wall and septations. I Simon, PK Landis 1999.

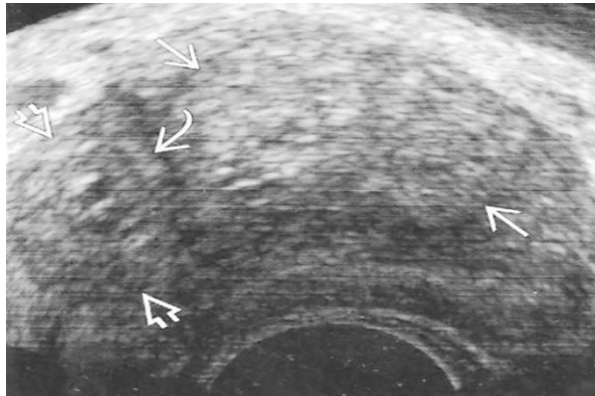


Image (2.7). Shows a Trans rectal ultrasound image of chronic prostatitis. I Simon, PK Landis 1999.

2.5.3 Cancer :

Ultrasound finding: may vary according to the cancer type but usually present as hypo echoic area within the homogeneous gland. I Simon, PK Landis 1999.

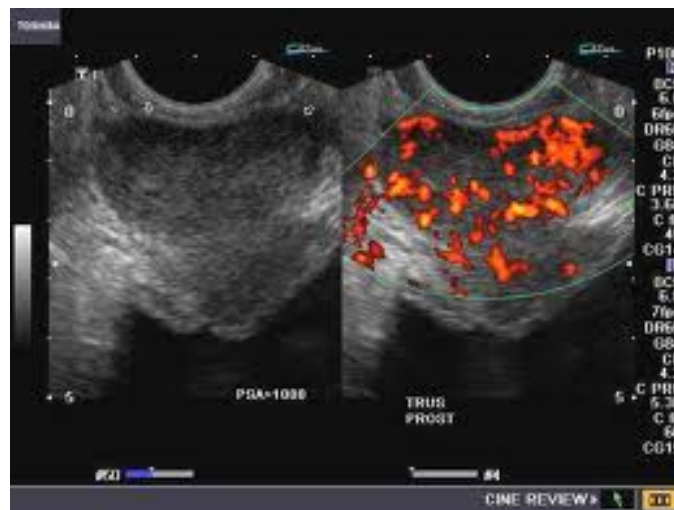


Image {2-8} : ultrasonography pf prostate cancer. I Simon, PK Landis 1999.

2.6 Physical Aspects of Ultrasound :

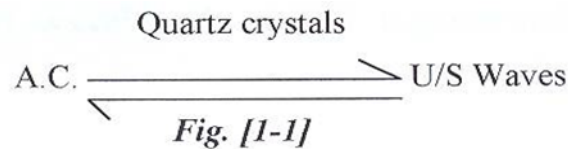
2.6.1 History:

Knowledge has its own chain reaction. The discovery of one important phenomenon usually leads to another. (Semat, 1959). X-ray was discovered by Wilhelm Conrad Roentgen on November 8th 1895, and immediately he produced the first radiograph which was of his wife hand (Ali, 1996). On 1896 Becquerel discovered the phenomenon of the radioactivity which afterwards made the basis of what is now known as Nuclear Medicine. However 15 years before the discovery of X-ray and exactly in 1880 U/S mechanical waves were produced by the Curie brothers, who demonstrated the piezoelectric effect, but, was only successfully applied medically in 1949 when Ludwig, and Stretchers proved the possibility of showing gallstones and soft tissue foreign bodies. Only then were the first cross-sectional ultrasonography produced by Howry from Denver, Colorado in 1950 with subjects immersed in a water bath. Direct contact ultrasonography was pioneered by Ian Donald of Glasgow who, together with Mac Vicar and Brown, developed the first two – dimensional contact scanner in 1958 followed by its immediate application to obstetrics and gynecology. The modern high resolution picture taken with U/S use the gray-scale technique first described by Kossoff of Australia in 1972, imaging both the small echoes from tissues as well as the large echoes from organs boundaries. Modifications and progresses are continually followed soon after we reached the age of eye ultrasonography, echo- cardiography, and colour Doppler U/S system. Jakobsen H, Torp-Pedersen S 1988.

2.7 Ultrasound production:

It is well known that energy cannot be created or lost but it is converted from one form into another, thus (e.g.) the X-ray is a type of radiant energy being converted from the electrical energy by a method of electron interaction with specified matter; tungsten target. This is also true concerning the matter of U/S beam where the electrical energy is converted to U/S energy. U/S is a form of energy consisting of mechanically produced waves with frequencies above the range of human

hearing. The production of U/S waves depends on the phenomena of the piezoelectric effect which is the property of certain crystal –like material to produce U/S mechanical waves when they are subjected to electrical pulsating current and vice versa. It is also found that the quartz crystals are the suitable material for U/S generation. **Jakobsen H, Torp-Pedersen S 1988.**



Fundamental of U/S probe “transducer”.
(Adam, 1995)

The probe or the transducer is the hand – held part of the U/S machine. It is the most important part of the system because it contains the elements capable of production of U/S and detection of the reflected portion. The material from which the elements are made is said to have piezoelectric properties or material crystals. Currently, used elements are sliced from a special ceramic (lead zirconate barium titanate) or plastic (polyvinylidene ditluride).The slice is permanently polarized across its thickness when manufacture. If an electric current is applied in pulses to its surfaces, it change in thickness and, therefore, compresses or rarefies the molecules of the surrounding medium. **Jakobsen H, Torp-Pedersen S 1988.**

Conversely, if it is placed in medium with pressure waves, it can generate an electric impulse from the potential difference between its surfaces. This voltage can be measured, amplified, printed as signal or reconstructed into an image. Therefore the same element in the transducer can be used for the generation and detection of U/S. **Jakobsen H, Torp-Pedersen S 1988.**

2.8. U/S Resolution:

Resolution is defined as ability of U/S beam to demonstrate and show clearly the U/S image. It then represents the image quality measure.

In general resolution is of two main types; contrast resolution and spatial resolution. **Jakobsen H, Torp-Pedersen S 1988.**

2.8.1 Contrast resolution:

This is the ability to differentiate anatomic structure having similar tissue characteristic and here the U/S contrast resolution is incomparable and high than the conventional X-ray, though it comes next to the Magnetic Resonance Imaging and Computed Tomography, and this is beside the real time image which U/S can give. If we take the liver as an example the best description may be what was stated by professor Qurashi in his concise text, routine ultrasonography. He stated that; before the advent of U/S the liver was regarded as one of the silent organs in the abdomen. The information provided by hepatic sonography can only be appreciated if we remember the imaging technique used before U/S. The liver is shown as vague soft-tissue mass in plain X-rays, calcification give some clues.

Parenchymal disease was difficult to detect. Periportal fibrosis is suspected from barium studied showing varices. Masses is suspected when they displace bowel gas or barium in contrast studies. Vascularity is investigated by invasive techniques. More information about the liver was given indirectly by studied on the biliary system. Radionuclide imaging of the liver using technetium sulfur colloid or technetium phylate remained as an important line of investigation indicated by U/S findings. CT provides valuable information. The various liver diseases require different diagnostic techniques, and among this U/S is the first line and one of the most information gaining techniques.

This detailed information of the liver are only gained due to the high contrast resolution that U/S can give. **Jakobsen H, Torp-Pedersen S 1988.**

2.8.2 Spatial resolution:

This ability of U/S to demonstrate and show the smallest size of an object in the high contrast that can be imaged. Here U/S is the worst and X-ray is the best. The smallest object we can clearly see is 0.1mm in X-ray, 0.5 mm in M.R.I and CT, and 1mm in U/S. This spatial resolution is of two types; axial resolution and lateral resolution. **Jakobsen H, Torp-Pedersen S 1988.**

2.8.3 Axial resolution:

As its name implies it is defined as the ability of U/S to image closely spaced interfaces lying on the longitudinal axis of the U/S beam. Therefore it is, sometimes, called longitudinal resolution and it expresses range and depth. It depends on the following:

(i) spatial pulse length 'SPL' where U/S pulse with less cycles appear better than much pulse length .In practice 3 to 5 pulse cycles is normal.

(ii) U/S frequency; where high frequency gives better resolution but low penetration and this is due to the reduction of pulse length which is in turn due to reduction in wave-length in high frequency usage .

(iii) Damping factor: damping or backing layer material shortens or quickly stops the pulse duration and therefore sharpens the transmitted echo pulse and improves axial resolution.

Here it is necessary to state that U/S beam does not undergo the process of superimposition as it is the matter in X-ray, and this is due to the physical property of US reflectivity. During its passage through different tissue and interfaces U/S reflected echoes carried back to us knowledge, information, or say news about every object they pass through and all these are recorded (not sliced) in the same image when in X-ray CT we cannot see objects all together but we sliced them by using windows and blurred out the surrounding upper and beneath objects.

It is also necessary to add the fact that generally, in body tissues "safe for bones and lungs " attenuation increases in a linear fashion with the frequency of U/S. Attenuated beams with higher frequencies do not penetrate deep enough and are only suitable for small superficial structures" e.g. thyroid, breast, testis etc" or in small children where depth is not needed. Frequencies as high as 10MHz are used for the eye because of their lower attenuation coefficients and shorter imaging depth.

A beam with suitable frequency passes through tissue with low coefficients" e.g. water", suffers little loss and is capable of further "enhanced" penetration, however deep penetration and good resolution should be compromised .Due to low U/S speed in gas "330m/s",the beam is almost totally reflected back and no penetration occurs, while in bones the U/S speed is very high "4080 m/s" and the beam is almost totally absorbed. In both situations the image is degraded and no informative image can be gained. **Jakobsen H, Torp-Pedersen S 1988.**

2.8.4 lateral resolution:

It is the ability of U/S to image closely spaced interfaces lying perpendicular to the axis of U/S beam .for this reason it is called azimuthal or transverse resolution and it deals with width.

It depends on transducer element size and the operating frequencies. Lateral resolution is the parameter that limits U/S image quality. In high frequency beam the near field is deeper and the far filed is more collimated, this contributes to improve axial and lateral resolution in near field. **Jakobsen H, Torp-Pedersen S 1988.**

2.9 U/S equipment:

The main component of the U/S equipment are the transducer, pulse rate generator, receiver, memory, monitor, and keyboard.

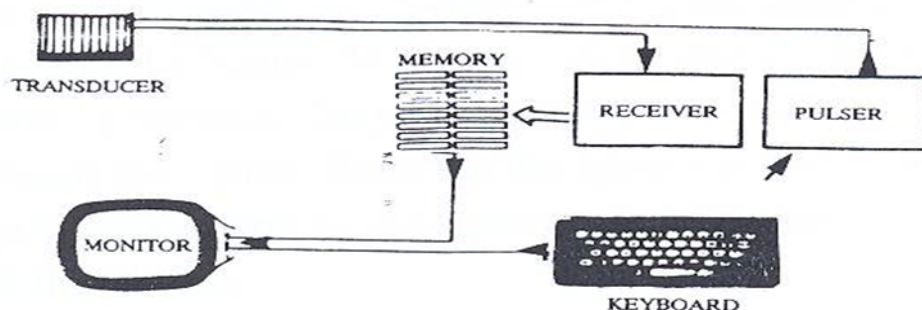


Image {2-9} : Shows reconstruction of ultrasound image. Jakobsen H, Torp-Pedersen S 1988.

It also converts the returning U/S echo "from the tissue" into an electric impulse. This is taken by the receiver which, in consultation with the memory, produces an image on the monitor. The keyboard is used for labeling and giving simple commands to change image characteristics, etc. The electric connection and other components are made to serve these main components mentioned above.

2.10 Literature Review:

- 1. Akmal et al, 1997** stated show that ultrasound is an easy and safe way to measure the prostate size. From the results, we can conclude that the size of prostate is larger for a man with larger body size. Also, it is suggested that another research is needed for computation to obtain the standard prostate size comparison which not only focuses on the age but also considers the body size of a man. It may help the researchers who intend to examine the prostate size analysis.
- 2. Berry et al 1995** described the normal value of prostate volume, which is 20.06 g in subjects aged 21 to 30 years.
- 3. Kodzo 1978 [8]** stated that prostatic calculi quite often are asymptomatic. Prostatic calculi may also co-exist with prostatitis or benign prostatic hyperplasia (BPH) in elderly men. These patients suffer LUTS for underlying prostatic disease, such as prostatitis or BPH. It is unclear whether prostatic calculi independently produce LUTS. Recurrences of prostatic calculi may be observed after treatment of prostatic calculi for a number of reasons. Plain radiographs or ultrasound scans should be performed post-operatively to ensure there are no residual stones before the patients are discharged.

4. **Peters TJ 1988** reported that there is considerable variation in repeated measurements of prostatic volume and the variation is greatest for 2 observers compared to 1 observer.
5. **Patel AR, et al 1987** stated that a healthy human male prostate has the volume of 100000mm . The prostate is located above the base of the penic and below the urinary bladder and backs into the front wall of rectum. The prostate evolves in this tight-wedged position to aid reproduction. The prostate secretes some of the fluid for semen, stops urination during ejaculation, and enhances sexual pleasureable sensations.
6. **Toyoshima et al 1993** stated that the men with a normal PSA and DRE did not undergo a biopsy. Although there was the potential for a missed diagnosis of prostate cancer, justifying a biopsy in the setting of a normal PSA and DRE is difficult. Thus, additional histological studies are needed to confirm such suspicions. Other studies had failed to find a relationship between prostate cancer and prostatic calculi, concluding that prostatic stromal calculi are a dystrophic, inflammation-mediated, benign process.
7. **Willams et al 1995** indicated that overall prostatic growth rate was 2.36 / 3.52 ml per year and that the growth was increasing with age with the peak of 4.154.98 ml per year at the age of 56~65 years and declined rapidly with the further advancement of age. Based on autopsy data.

Chapter Three

3.1 Materials and Methods

This study was conducted in Sudan University of Science and Technology, Ultrasound department, and was done among 30 Sudanese adult males, their ages between 30 to 43, to diagnose the prostate gland and calculate the size of the gland using ultrasonography.

Transabdominal ultrasound was used instead of transrectal ultrasound using convex transducer with variable frequencies (2.5-4.5) MHz is used for the diagnosis of the gland. All patients were requested to lie supine, and a coupling gel is used for scanning. The sagittal plane was recorded for all patients to represent the length of the gland. The cross-section plane was recorded for all patients representing the width of the gland. The antro-posterior plane was recorded for the depth which represents the middle lobe of the gland.

All measurements were recorded, and the size of the gland was calculated by the equation :

$$L*W*D*0.52 \dots\dots\dots \text{equation No. 1}$$

L=Length

W=Width

D=Depth

Analysis was done using Excel Program.

Chapter Four

4.1 Results


The results are shown in the in the following tables :

Variables	mean±SD
Age of patients	35.3±4.1
Length of prostate	03.1±0.2
Width of prostate	03.5±0.2
Depth of prostate	03.3±0.2
Volume of prostate	19±3.0
Weight of prostate	09.9±1.5

Table{4-1 } shows the means and the standard deviations of the age of patients, and the length, width, depth, volume and weight of the prostate.



Figure {4-1} is a scatter plot shows a direct linear relationship of patient age and the length of the prostate, the trend line depicts the linear proportionality correlation.



Figure{ 4-2} scatter plot shows a direct linear relationship of patient age and the width of the prostate, the trend line depicts the linear proportionality correlation



Figure { 4-3} scatter plot shows a direct linear relationship of patient age and the depth of the prostate, the trend line depicts the linear proportionality correlation




Figure { 4-4} scatter plot shows a direct linear relationship of patient age and the prostate volume of the prostate, the trend line depicts the linear proportionality correlation.




Figure { 4-5} scatter plot shows a direct linear relationship of patient age and the prostate weight of the prostate, the trend line depicts the linear proportionality correlation.

Chapter Five

5.1 Discussion

Because prostate size is easily measured by noninvasive means, this parameter would be valuable for choosing optimal therapy if it could predict outcome as suggested in some recent studies. Unfortunately, studies relating prostate weight to outcome have had conflicting results. Some studies have evaluated clinical outcomes in patients with peripheral zone cancer and found no difference in recurrence rates between groups with large or small prostate glands. **AM Willams 1995.**

In the current study, we found that prostate length, width, depth, volume and weight increased significantly in older patients. This is an expected finding and makes intuitive sense. The association between prostate size and age is well established.

Most of the previous studies had almost the same result.

From figure {4-1} it is obvious that the prostate length (sagittal plane) is increasing by age, which is about 0.03 cm/yr in this study. On the other hand the length is directly proportional to the age, which matches a previous study that correlated that showed age-related longitudinal changes of the prostate.

Figure {4-2} shows a definite proportionality between age and width of the prostate. This study proved that width increases by 0.026 cm/yr.

Also figure{4-3} shows a direct linear relationship of patient age and the depth of the prostate, the increase rate is about 0.025 cm/yr.

Figure {4-4} also shows a direct relationship of patient age and the prostate volume which increases by 0.44 mm/yr.

A study made by **Muhmmmed Akmal et al 2000** showed that ultrasound is an easy and safe way to measure the prostate size. From the results, we can conclude that the size of prostate is larger for a man with larger body size. Also, it is suggested that another research is needed to obtain the standard prostate size comparison with the age. Which was proved in our study.

Another study shows that Between the ages of 31 and 50 it doubles in size every 4.5 years, which is almost ~0.5 mm/yr. While our study shows that size increases by 0.4 mm/year.

AM Willams et al 1995 indicated that overall prostatic growth rate was 2.36 /3.52 mL per year and that the growth was increasing with age with the peak of 4.154.98 mL per year at the age of 56~65 years and declined rapidly with the further advancement of age. Based on autopsy data,.

Berry et al 1995 described the normal value of prostate volume, which is 20.06.0 mm in subjects aged 21 to 30 years, which almost matches the mean prostate volume in our result which is about 19.04 mm.

5.2 Conclusion

Prostate volume measurement is frequently used to diagnose the abnormalities of the prostate. Abnormal enlargement of the prostate may be due to inflammation or virus infection. In a more severe case, the abnormal enlargement may indicate prostate cancer. The measurement of the prostatic gland is commonly performed by using transrectal scanning. However, in this study transabdominal scanning is used in the measurement of prostatic volume.

Transrectal ultrasound is the best method to assess the prostate gland volume but, transabdominal ultrasound is also a very useful, less painful and a comfortable mean in the Assessment of prostate volume.

In healthy adult males it has been found that the Length of prostate gland, depth of prostate gland, width of the prostate gland and the volume of the prostate gland are directly proportional with age.

The study shows that between 30-43 year old Sudanese adult males, the mean prostate volume is 19.0 mm, with a standard deviation of ± 3.0 .

The prostate gland is an important part of the male genital tract. Thus it is very important to estimate an accurate prostate size to detect any changes or abnormalities.

5.3 Recommendations

- 1- Ultrasound should be used to as a routine investigation for adult patients to estimate the prostate size, because it is noninvasive, has less radiation dose and it is less painful and more comfortable for the patient.
- 2- The weight of the patient should always be written within the ultrasound report.
- 3- Accurate prostate size must be estimated to be able to diagnosis any related changes in the prostate.
- 4- For further studies we recommend a similar study including the Benign Prostatic Hyperplasia of the prostate.
- 5- Also transrectal ultrasound is the most recommended mean for the prostate gland measurements and diagnosis.

5.4 References

- AM Williams, I Simon, PK Landis, W Chistens-Bary, HB Carter, EJ Metter, *et al.* Prostatic growth rate determined from ultrasound data: age-related longitudinal changes. *J Androl* 1999; 20: 474-80.
- Berry SJ, Coffey DS, Walsh PC. The development of human benign prostate hyperplasia with age. *J Urol* 1984; 132: 474.
- Hiraoaka Y, Akimoto M. Anatomy of the prostate from fetus to adult-origin of benign prostatic hyperplasia. *Urol Res* 1987; 15: 177.
- J T Isaacs, Coffey D S. Etiology and disease process of benign prostatic hyperplasia. *Prostate Suppl* 1989; 2: 33-50.
- Jakobsen H, Torp-Pedersen S, Juul N. Ultrasonic evaluation of age-related human prostate growth and development of benign prostatic hyperplasia. *Scand J Urol Nephrol* 1988; s107: 26.
- McNeal J E. Origin and evolution of benign prostatic enlargement. *Invest Urol* 1978; 15: 340.
- M. H. Rapacholi, Humana Press 1982 *Essentials of Medical Ultrasound: A Practical Introduction to the Principles, Techniques and Biomedical Applications*,.
- Xia SJ, Teng JB, Xu XX. Comparison research regarding the volume, the structure of zones and the weight of prostatectomy specimen in prostate. *Chn J Urol* 1984; 10: 305.
- Xia SJ, Xu CX, Tang XD, Wang WZ, Du DL. Apoptosis and hormonal milieu in ductal system of normal prostate and benign prostate hyperplasia. *Asian J Androl* 2001; 3: 131-4.
- Xia SJ, Tang XD, Ma QZ. Androgen receptor isoforms in human prostatic cancer tissue and LNCap cell line. *Asian J Androl* 2001; 3: 223-5.

5.6 Appendix

(A)

Table{ 5.1} Example of master data sheet used in calculation:-

Pt No.	Age	Prostate Size			Volume(mm ³) L*W*D*0.0
		Length (L)cm	Width (W)cm	Depth (D)cm	
1	34	2.9	3.4	3.2	16.4
2	31	2.8	3.4	3.3	16.3
3	36	3.4	3.6	3.5	22.2
4	40	3.0	3.4	3.3	17.5
5	32	2.8	3.2	3.4	15.8
6	32	2.9	3.4	3.2	16.4
7	30	3.0	3.3	3.0	15.4
8	29	2.8	3.2	2.9	16.4
9	36	3.1	3.4	3.4	15.4
10	35	3.2	3.4	3.3	13.5
11	36	3.2	3.6	3.4	18.7
12	31	3.0	3.4	3.2	20.4
13	34	3.2	3.5	3.3	17
14	38	2.9	3.4	3.1	19.2
15	41	3.1	3.6	3.4	15.9
16	39	3.3	3.7	3.5	16.4
17	37	3.2	3.8	3.3	22.2
18	38	3.3	3.8	3.4	20.9
19	30	2.9	3.3	3.0	22.1
20	33	3.1	3.4	3.2	14.9
21	42	3.4	3.9	3.5	19.2
22	34	3.2	3.6	3.4	24.1
23	32	3.0	3.4	3.3	20.4
24	38	3.3	3.6	3.3	17.5
25	43	3.4	3.2	3.5	20.4
26	30	3.2	2.5	3.4	19.8
27	32	3.1	3.6	3.3	19.1
28	35	3.4	3.7	3.6	23.5
29	40	3.3	3.9	3.4	22.8
30	42	3.5	3.8	3.6	24.9

(B)

Example of the prostate gland measurements used in the study:

Name : Mohammed Ibraheem Awad.

Age : 33 years old.

Weight : 78 Kg.



