

Appendix (A-1)

Data collecting form :

Age:
Marital status :
Duration :
Symptoms:
Shape of the mass:
Echogenicity of the mass:
The number of masses:
Consistency of the mass:
Wall of the mass:
Location of the mass:
Calcification of the mass:
Posterior phenomena:
Combination of the mass with axillary lymph nodes:
U/S findings
FNAB findings

Appendix (A- 2) Patients Data

N	AGE	M.s	H.O.D	W	L	SH	ECH	N.O.L	P.PH	CON	WA	MO	S	LOC	AC	CAL	U/S	FNA
1	35y	1	3m	3	3	1	2	1	4	2	1	1	2	2	1	1	2	2
2	40y	1	2m	3	4	2	3	1	1	1	1	1	2	2	1	1	1	1
3	20y	2	2m	1.5	0.9	2	2	1	2	1	1	1	2	5	1	1	1	1
4	22y	2	5y	1.2	1.2	1	2	1	2	1	1	1	2	7	1	1	2	2
5	20y	2	3m	1.6	0.6	2	2	1	0	0	1	1	2	6	1	1	2	2
6	25y	2	2m	4	6.5	2	2	1	3	1	3	1	2	7	1	1	1	2
7	18y	2	1y	5.6	3.2	2	2	1	2	1	1	1	2	5	1	1	6	6
8	21y	1	2m	1.1	8.5	2	3	1	1	1	1	1	2	1	1	1	1	1
9	28y	1	1m	1.8	2	1	2	1	1	1	1	1	3	5	1	1	3	3
10	28y	2	5m	2	2	1	3	1	3	1	1	1	2	6	1	1	1	1
11	29y	1	7m	1	1.7	2	2	1	1	1	1	1	3	7	1	1	3	3
12	35y	1	2d	5.8	5.8	1	4	1	1	1	1	1	1	1	1	1	4	4
13	19y	2	2m	3	4	1	3	1	0	0	1	1	2	8	1	1	1	1
14	30y	1	3m	3	1	2	2	1	2	2	1	1	2	1	1	1	3	3
15	35y	1	4m	7.	0.7	1	2	1	1	1	1	1	2	4	1	1	2	2
16	38y	1	2m	7	7	1	2	1	1	1	1	1	2	2	1	1	2	2
17	39y	1	1m	2	5	2	4	1	2	2	1	1	2	6	1	1	7	2

18	30y	1	2m	1.1	1.6	2	2	1	1	1	1	1	2	3	1	1	6	3
19	20y	2	1m	2	2	1	3	1	2	2	1	1	2	4	1	1	1	1
20	30y	1	3m	0	0	0	5	0	2	2	0	1	2	1	1	1	8	2
21	21y	2	1m	0	0	0	5	0	1	1	0	1	2	1	1	1	8	1
22	19y	2	2m	0	0	0	5	0	3	1	0	1	2	1	1	1	8	1
23	30y	1	1m	1.9	1.1	2	2	1	2	2	1	1	2	1	1	1	1	1
24	22y	2	1m	1.8	1.1	1	2	1	2	2	1	1	2	5	1	1	2	2
25	18y	2	1m	0	0	0	5	0	0	0	0	0	2	2	0	0	8	1
N	AGE	M.s	H.O.D	W	L	SH	ECH	N.O.L	P.PH	CON	WA	MO	S	LOC	AC	CAL	U/S	FNA
26	35y	1	2m	1.5	2	2	2	1	2	2	1	1	2	2	1	1	2	2
27	2y4	2	2m	1.7	1.2	1	2	1	4	2	1	1	2	7	1	1	2	2
28	27y	2	1m	2	2	1	3	1	1	1	1	1	2	6	1	1	1	1
29	23y	2	3d	3	3	1	1	1	2	1	1	1	1	7	2	1	4	4
30	30y	1	1m	2	2	1	2	1	2	2	1	1	1	8	1	1	6	2
31	20y	2	1m	0	0	0	5	0	0	0	0	1	2	6	1	1	8	1
32	27y	1	1m	1	6	2	3	1	3	1	1	1	2	2	1	1	1	1
33	27y	2	1m	2	2	1	2	1	2	2	1	1	2	6	1	1	6	6
34	18y	2	2m	6	3	2	3	1	1	1	1		2	3	1	1	1	1

35	35y	1	2m	1.1	8	2	3	1	1	1	1	2	1	1	1	1	1
36	24y	2	1m	3	2	2	3	1	3	1	1	1	2	7	1	1	1
37	23y	2	2m	1	2	2	3	1	1	1	1	2	3	1	1	1	3
38	34y	1	3m	1.6	2.5	2	3	1	1	1	1	2	1	1	1	1	1
39	26y	1	4d	0	0	0	5	0	0	0	0	2	7	1	1	8	3
40	32y	1	2d	2	3	2	4	1	2	1	1	1	5	1	1	4	4
41	22y	1	3m	1.4	1.5	1	3	1	1	1	1	2	5	1	1	1	1
42	23y	2	2m	2	1.9	1	2	1	1	1	1	2	5	1	1	1	1
43	35y	1	3m	2	2	1	2	1	2	2	1	2	7	1	1	2	2
44	33y	1	4m	1.4	2	1	2	1	1	1	1	2	6	1	1	1	1
45	19y	2	1m	2	3	2	2	1	2	1	1	2	2	1	1	2	2
46	29y	1	4y	1.5	2	2	2	1	2	2	1	2	1	1	1	2	2
47	18y	2	2y	4	3	2	3	1	1	1	1	2	2	1	1	1	1
48	35y	1	1w	1	1	1	3	1	3	1	1	2	6	1	1	1	1
49	36y	1	3m	2	3	2	2	1	2	2	1	2	5	1	1	2	2
50	33y	1	2m	1	2	2	2	1	2	2	1	2	4	1	1	2	2

Key for patients data

1 Marital status 1 = Married 2= Un married

Appendix (B)
Ultrasound images of benign masses

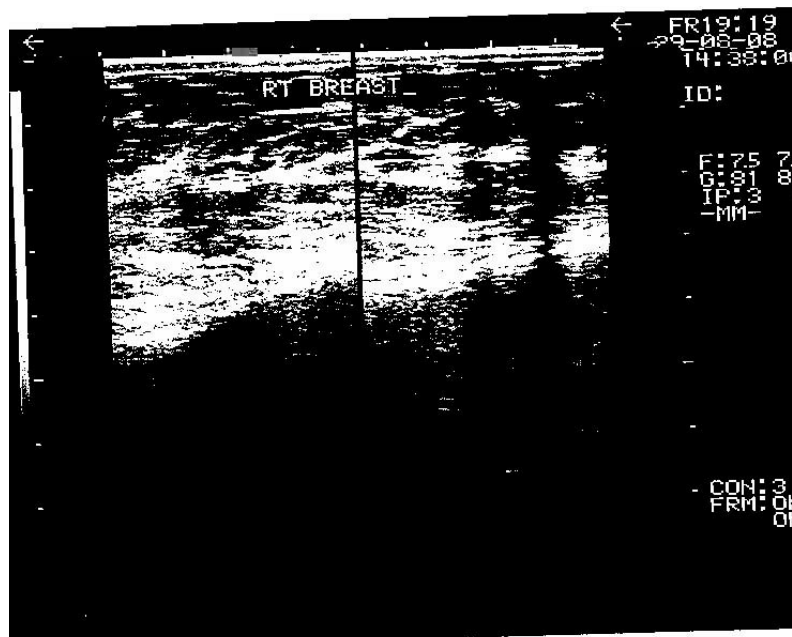


Image (1) showed patient of age 26 years had normal breast tissue

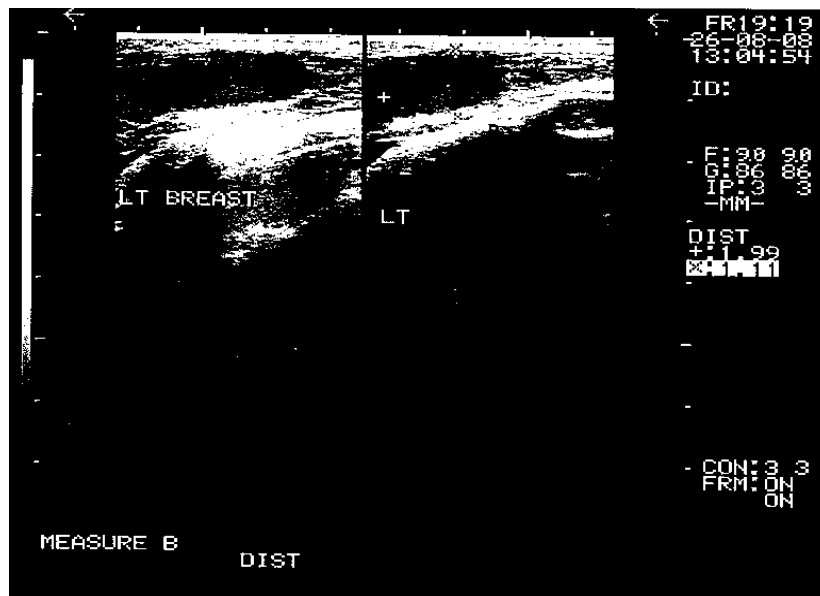


Image (2) showed patient of age 20 years had fibro adenoma

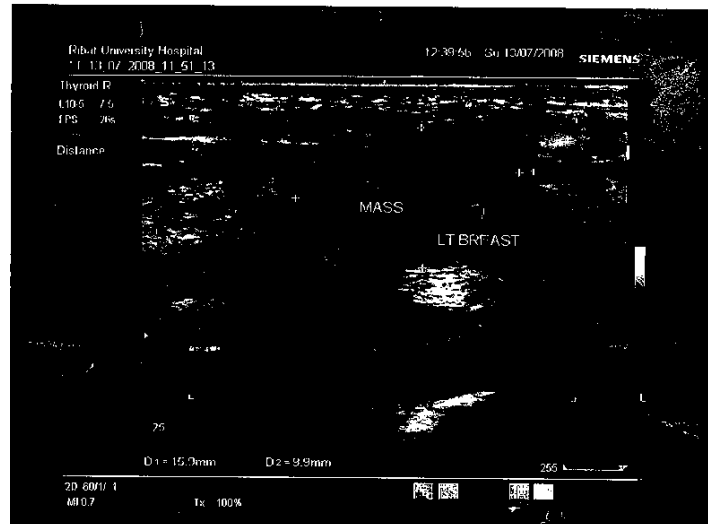


Image (3) showed patient of age 20s years had fibro adenoma

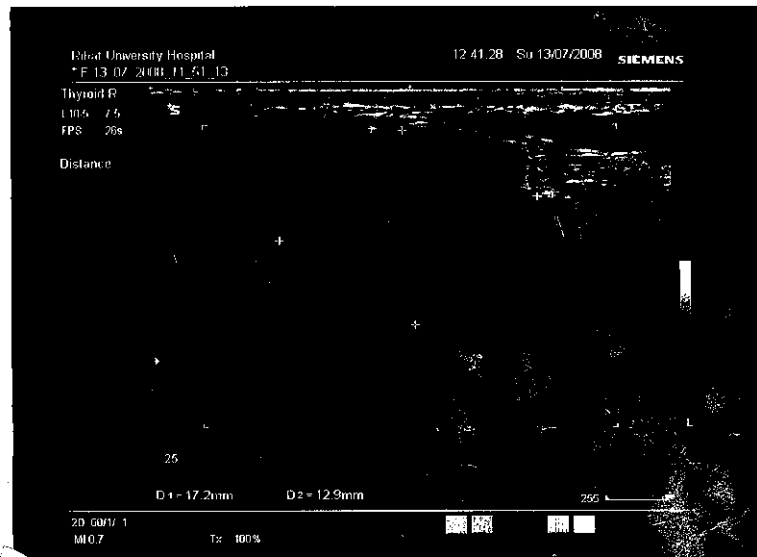


Image (4) showed patient of age 30 years had fibro adenoma

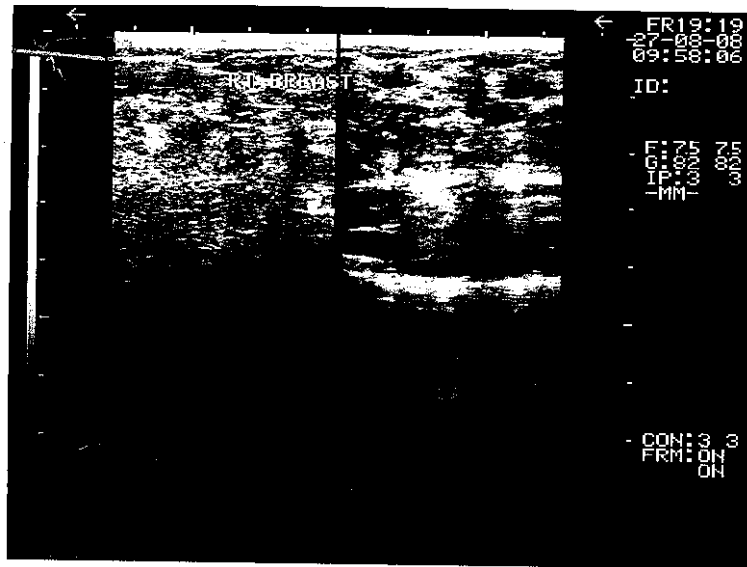


Image (5) showed patient of age 18 had normal breast tissue

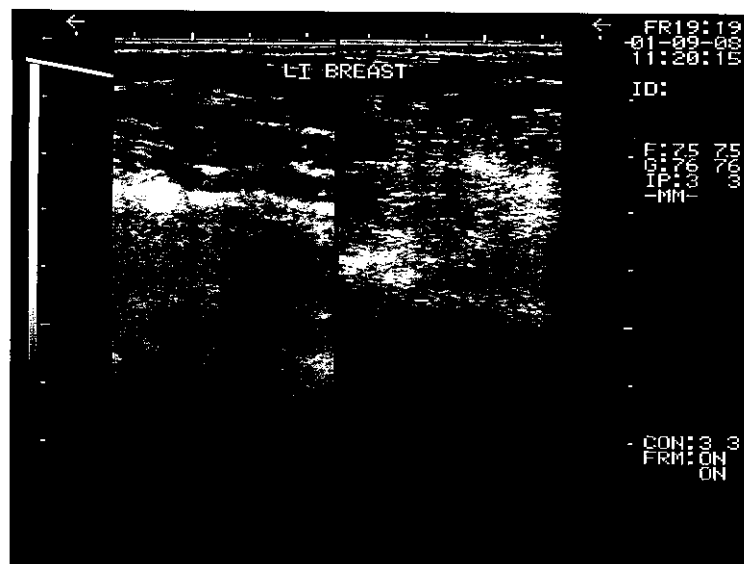


Image (6) showed patient of age 20 years had normal breast tissue

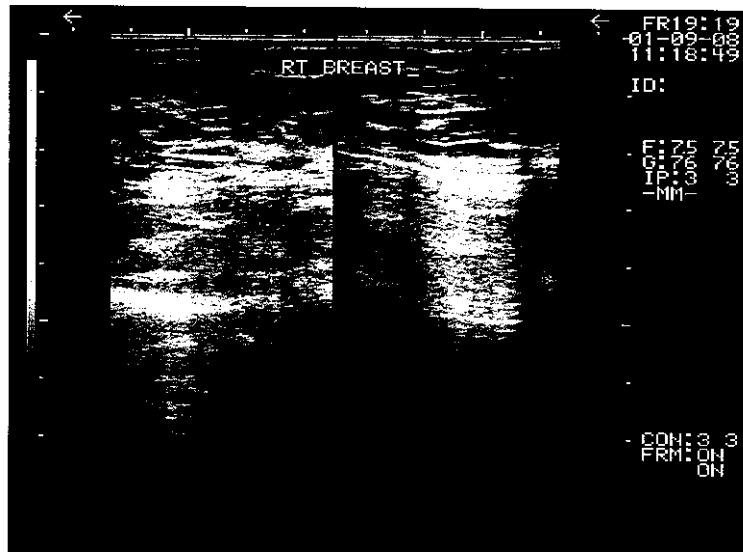
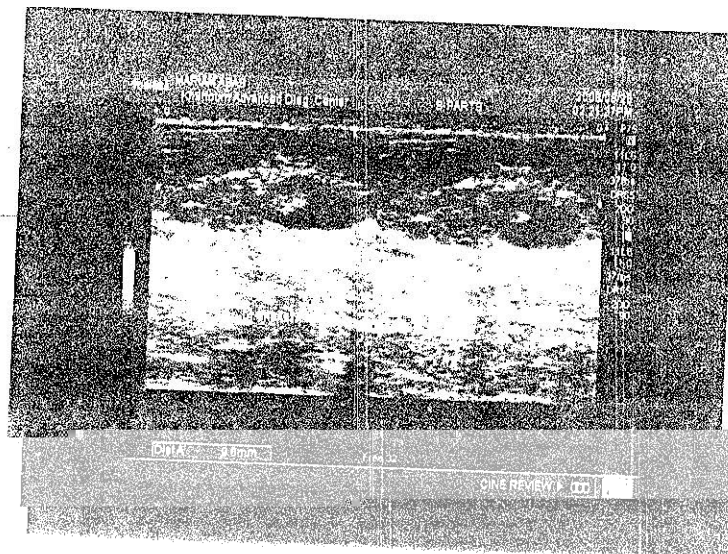


Image (7) showed patient of 26 years had normal breast tissues



Image(8) showed patient of age 28 had galactoceles

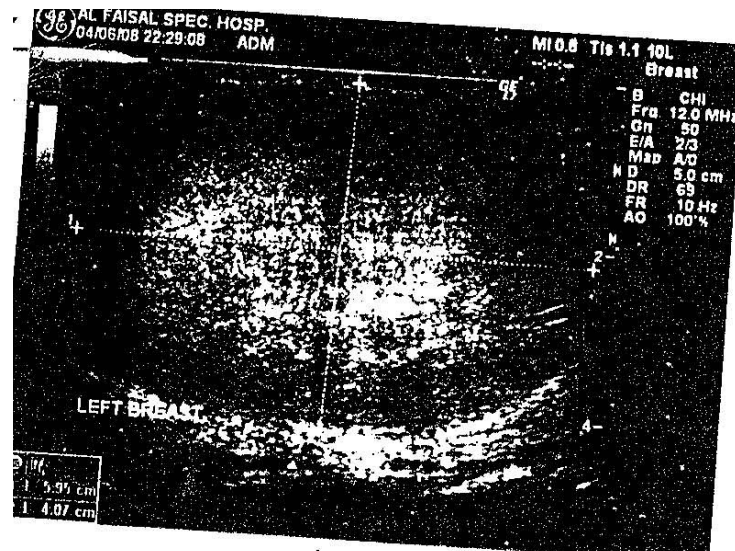
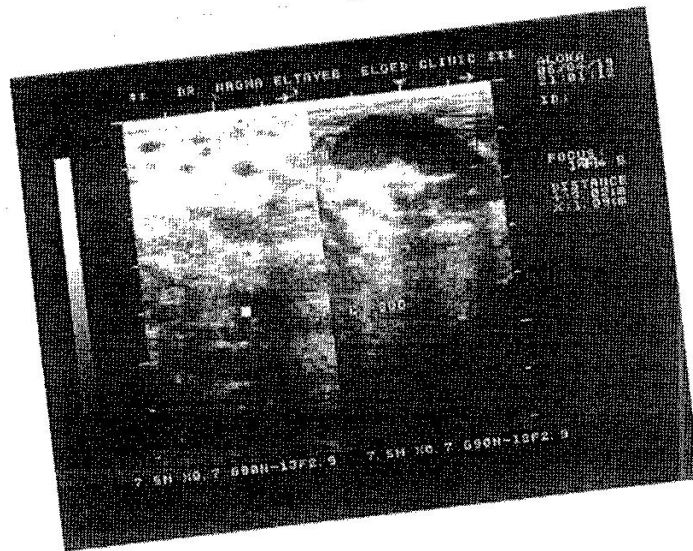
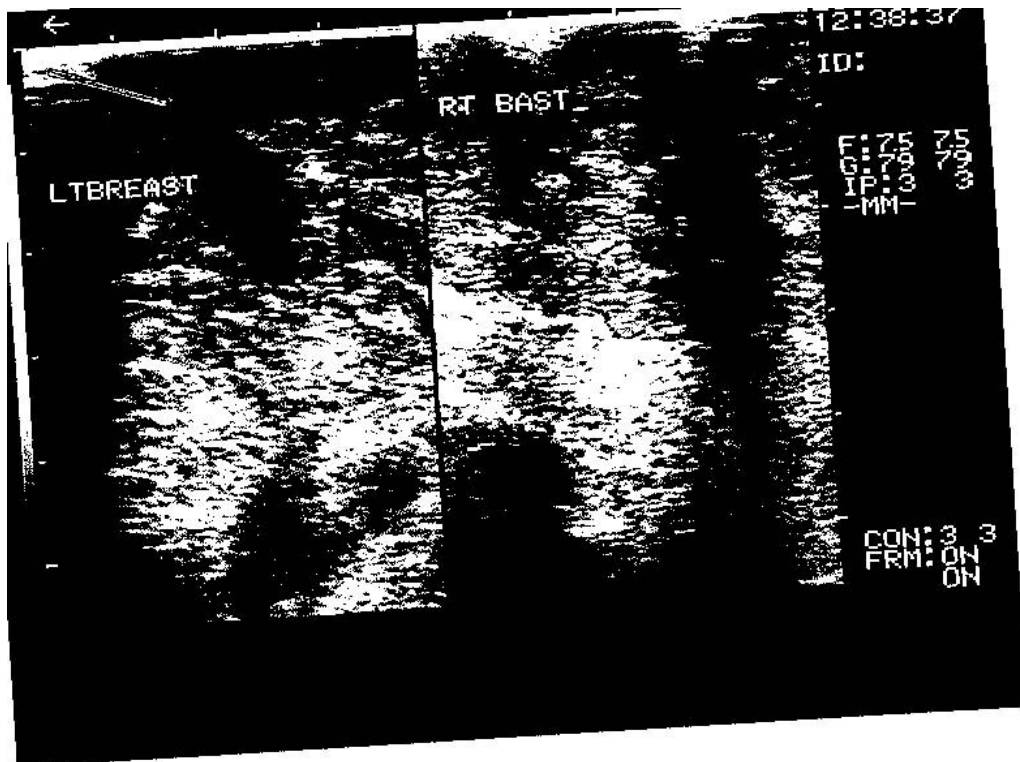


Image (9) showed patient of age 32 years had an abscess

Image (10) showed patient of age 27 years had fibro adenoma



Image(13) showed patient 30 years had galactocele



image(14) showed patient of age 26 years had normal breast tissue

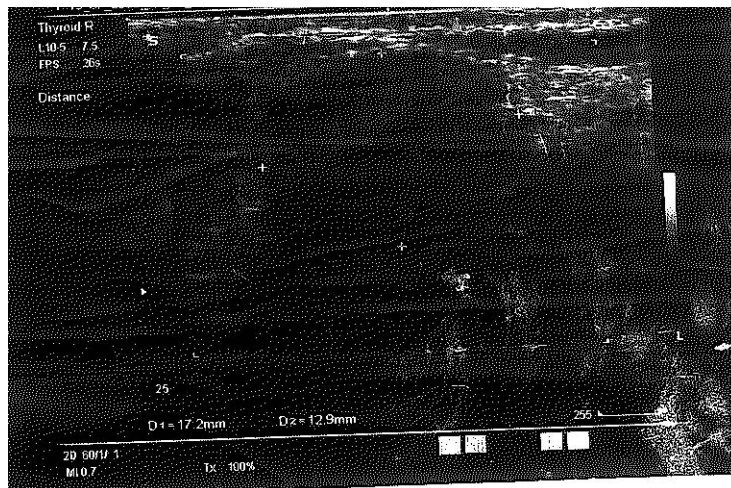


Image (15) showed patients of age 22 years had fibro adenoma

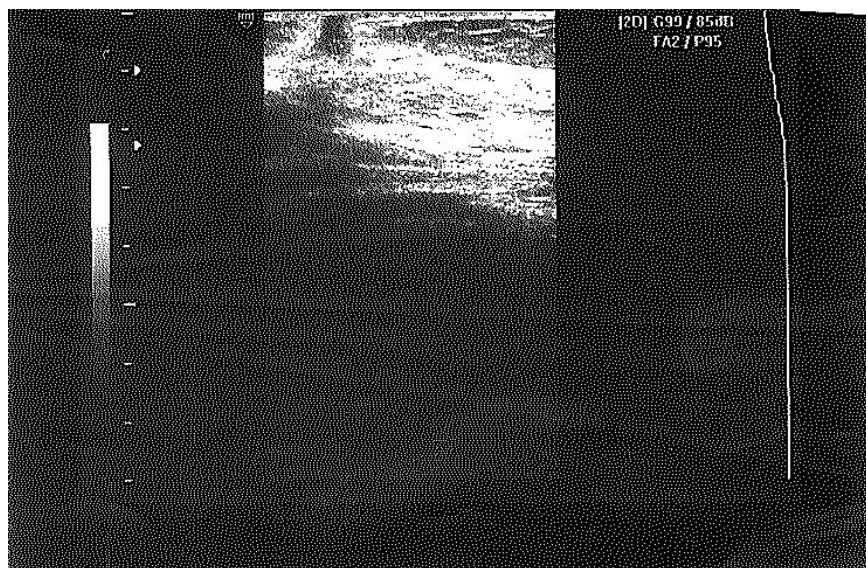


Image (16) showed patients of 25years had fibro adenoma

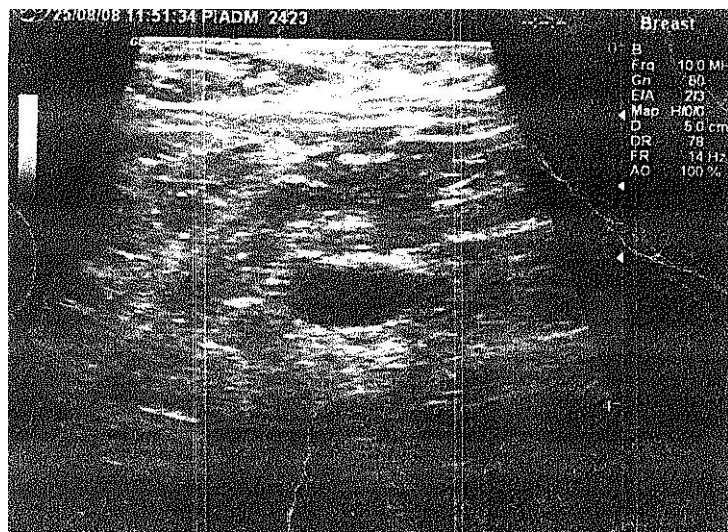


Image (17) showed patient of age 30 years had ductectia

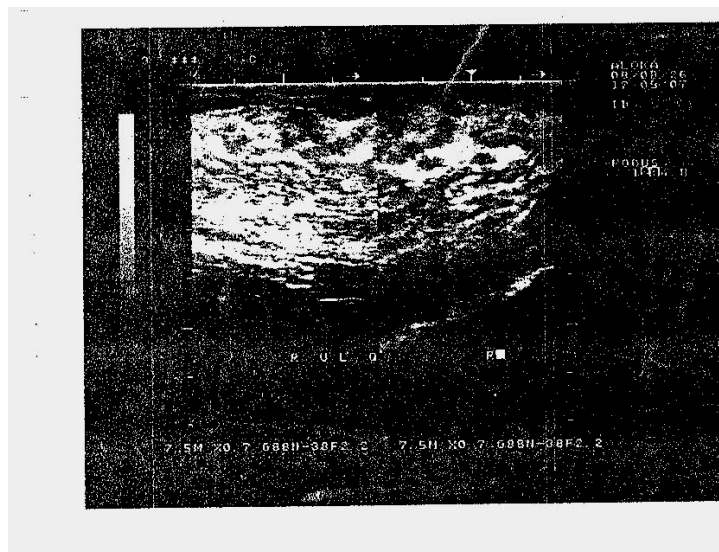


Image (18) showed patient of 19 years had fibro adenoma




Image (19) showed patient of 20 years had fibro adenoma

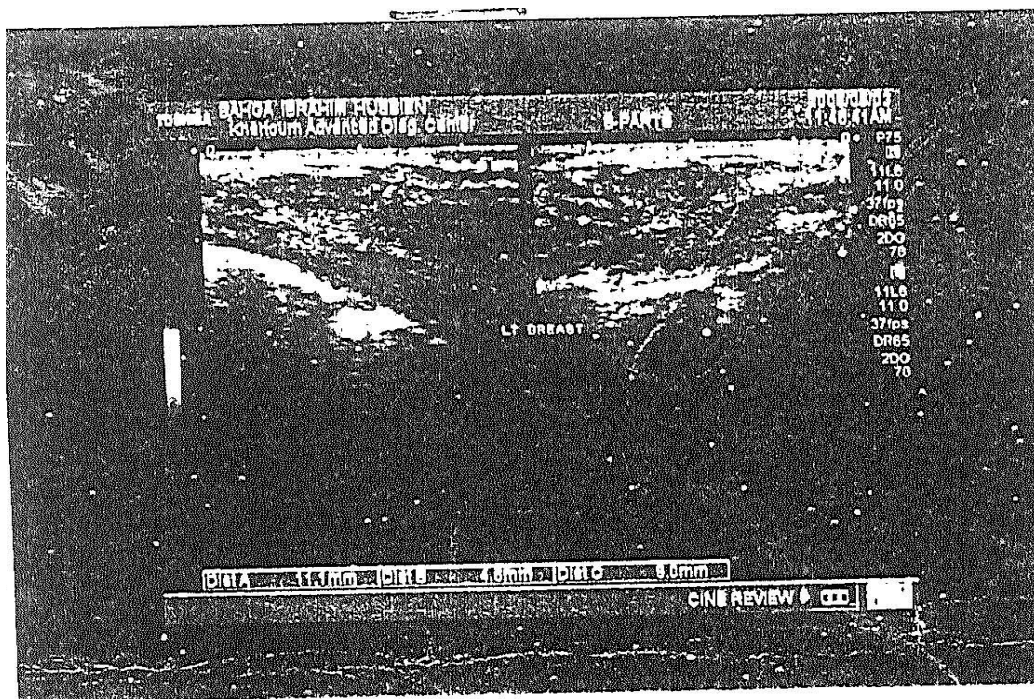


Image (20) showed patient of 35 years had fibro adenoma

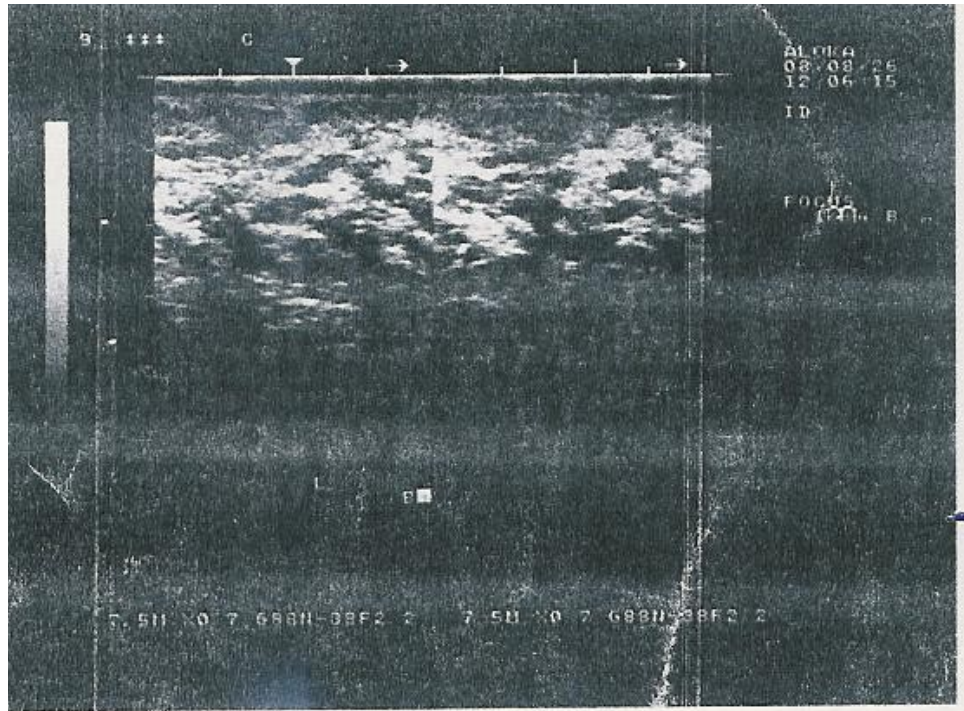


Image (21) showed patient of 35 years had fibrocystic adenoma

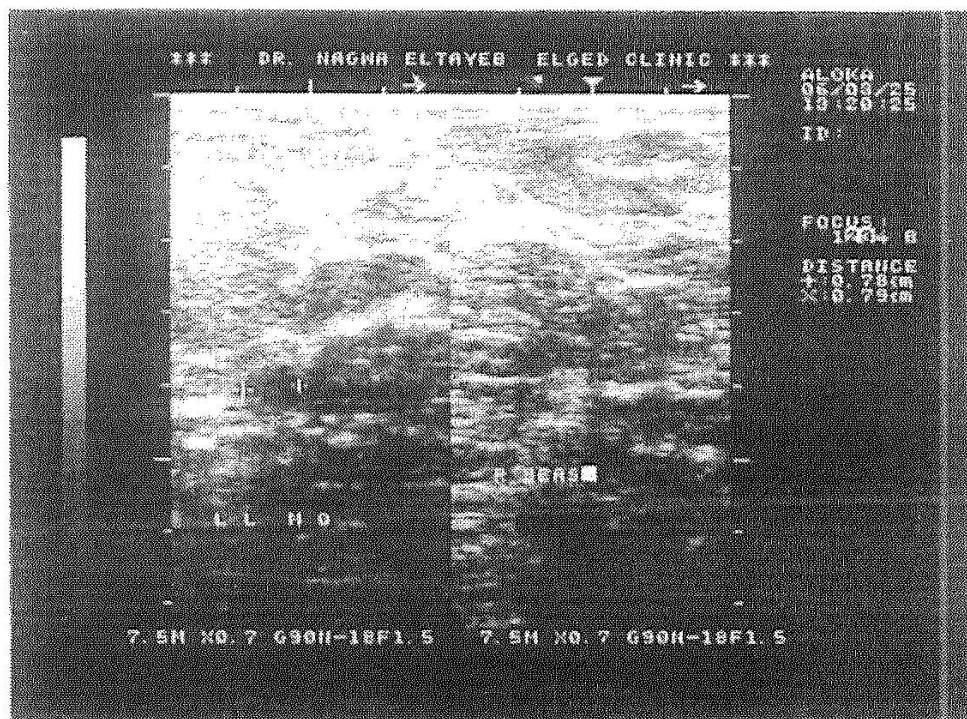


Image (22) showed patient of 35 years had fibrocystic adenoma

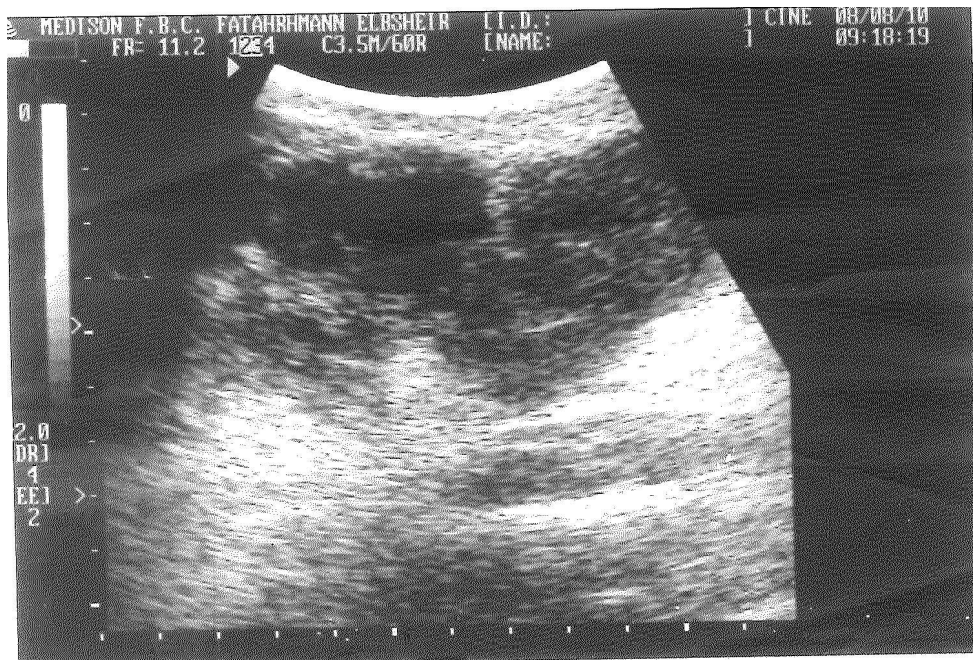

Image (23) showed patient of 23 years had axillary lymph nodes enlargement

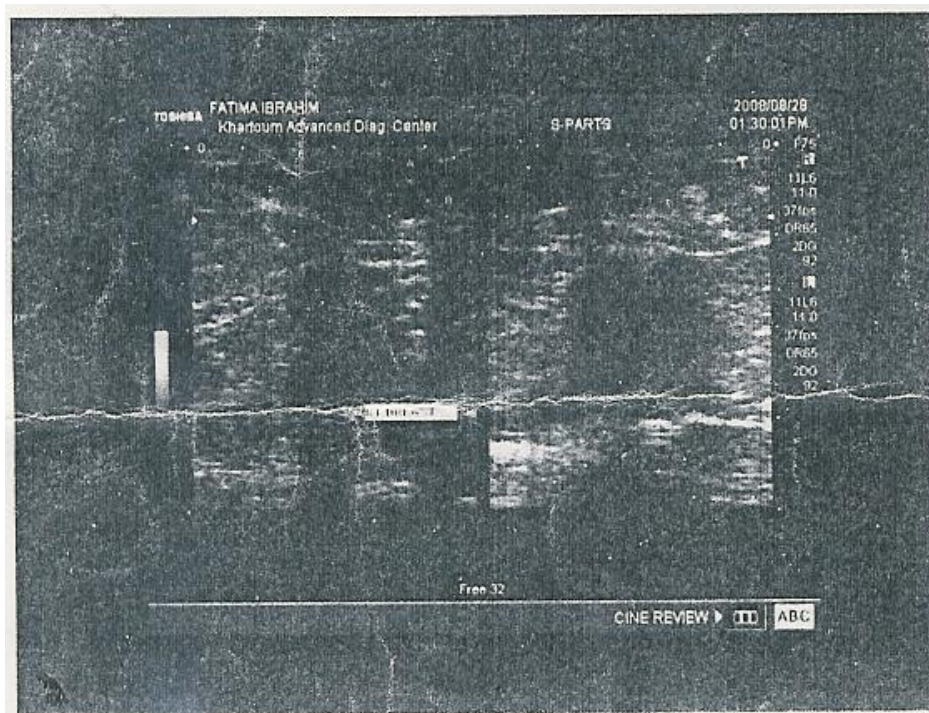


Image (24) showed patient of 27 years had fibroadenoma