

CHAPTER ONE

1-1 Introduction:

In medicine, "imaging" is the general term for any technique used to provide pictures of bones and organs inside the body. Imaging techniques consist of x-rays, ultrasound, magnetic resonance imaging (MRI), and computerized tomography (CT) scans. Evaluation of the kidneys and pelvicalyceal system (PCS) can be achieved by several possible protocols. **(Rodgers, 2006)**

Ultrasonography is often the initial imaging technique because it can be done safely even when kidney function is impaired. It is noninvasive and painless and requires no radiopaque contrast agent. Ultrasonography provides some indirect information about kidney function, is an excellent way to estimate kidney size and position, readily detects obstruction, and helps diagnose structural abnormalities. But ultrasonography inferior to computed tomography (CT) in the diagnosis of kidney tumors. **(Rodgers, 2006)**

Intravenous Urography: Intravenous urography (IVU), also called intravenous pyelography or (IVP) uses a radiopaque contrast agent given through a vein to provide an x-ray image of the kidneys, ureters, and bladder. However, IVU can better detect small abnormalities of the ureters and some abnormalities of the kidneys. IVU is often done for people with blood in the urine, even if the blood is not visible to the naked eye. It is also often done for people whose doctors' suspect may have cancer involving the ureters or other urinary passages. Use of contrast agents may result in allergic-type reactions or, rarely, kidney damage. **(Rodgers, 2006)**

Magnetic Resonance Imaging (MRI) can provide three-dimensional images of the kidneys, blood vessels, and structures surrounding the kidneys. MRI helps

distinguish tumors from cysts. When used with a paramagnetic contrast agent to enhance images, MRI can identify disorders of kidney blood vessels. People who require evaluation of the kidney blood vessels and who are at risk of reactions to radiopaque contrast agents can undergo MRI rather than CT. **(Rodgers, 2006)**

Computed tomography since its introduction 30 years ago computed tomography (CT) has evolved from a prime imaging tool to one capable of volumetric scanning. The impact of this development has been felt in everything from clinical application to workflow, which has even affected the computer tomography vernacular. (Gaafer, 2004) .

Today's multidetector scanners represent a huge technical leap since dedicated brain imager was unveiled in 1972. The clinical advances by these devices, which are capable of acquiring four CT slices rotation, have been impressive. Foremost among them is CT and new 16-slice units. (Gaafer, 2004) .

Prior to multidetector computed tomography (MDCT), the last major innovation in CT came with the introduction of spiral scanning in 1989. The developed CT from step-and-shot technology in which patients were moved incrementally between slices, to new acquisition in which patient slide through a rotation in spiraling pattern. (Gaafer, 2004) .

The ability to acquire a constant flow of data was CT's first step volumetric data collection and represented the first shift in thinking data-away from "slices" and toward the concept of volume. (Gaafer, 2004) .

Helical CT (sometimes called spiral CT), performed by continuously moving the person through the CT scanner, permits special images of certain structures and more rapid completion of the scanning process.

Helical CT without the use of a radiopaque contrast agent is useful for people who may have kidney stones or for people who have suffered trauma in whom bleeding into the kidney or surrounding tissues must be identified rapidly. A radiopaque contrast agent is often used in CT examinations. The intravenous contrast agent provides extra detail about the kidney arteries and veins, about certain kidney tumors (such as renal cell cancer), and about polycystic kidney disease. (Nagel, 2004)

1-2 Problem of study:

There is direct impact of variation of kidney size and shape in acquisition of renal pathology. Estimation of renal size for Sudanese population may help in predict of any pathological condition according to kidney size.

1.3 Objectives:

- 1- To define the role of the multidetector computed tomography and its technique in evaluation of kidney size.
- 2- To measure the kidney size and PCS, and estimate the variations in kidneys and in some possible pathological condition.
- 3- List the type of anomalies affected the kidney size in relation to the CT finding.

1-4 Outlines of the study:

Chapter one include introduction.

Chapter two shows background.

Chapter three explains material and methods.

Chapter four shows the analysis and results.

Chapter five discusses the results of the study, conclusion and recommendations.

CHAPTER TWO

2-Background

2-1 Anatomy of the kidneys:

In humans the kidneys are located in the abdominal cavity, more specifically in the paravertebral gutter and lie in a retroperitoneal position at a slightly oblique angle. There are two, one on each side of the spine. The asymmetry within the abdominal cavity caused by the liver typically results in the right kidney being slightly lower than the left, and left kidney being located slightly more medial than the right. The left kidney is approximately at the vertebral level T12 to L3 (Dragomir, Hjortberg and Romans, 2007), and the right slightly lower. The right kidney sits just below the diaphragm and posterior to the liver, the left below the diaphragm and posterior to the spleen. Resting on top of each kidney is an adrenal gland. The upper (cranial) parts of the kidneys are partially protected by the eleventh and twelfth ribs, and each whole kidney and adrenal gland are surrounded by two layers of fat (the perirenal and pararenal fat) and the renal fascia. Each adult kidney weighs between 125 and 170 grams in males and between 115 and 155 grams in females.(Walter and F. Boron, 2004) The left kidney is typically slightly larger than the right.(Glodny, Unterholzner, Taferner, et al, 2009)

The kidneys are dark-red, bean-shaped organs. One side of the kidney bulges outward (convex) and the other side is indented (concave). There is a cavity attached to the indented side of the kidney, called the Renal Pelvis... which extends into the ureter. Each Kidney is enclosed in a transparent membrane called the renal capsule... which helps to protect them against infections and trauma. The kidney is divided into two main areas a light outer area called the renal cortex, and a darker inner area called the renal medulla. Within the medulla there are 8 or more cone-

shaped sections known as renal pyramids. The areas between the pyramids are called renal columns. (www.comprehensive-kidney-facts.com)

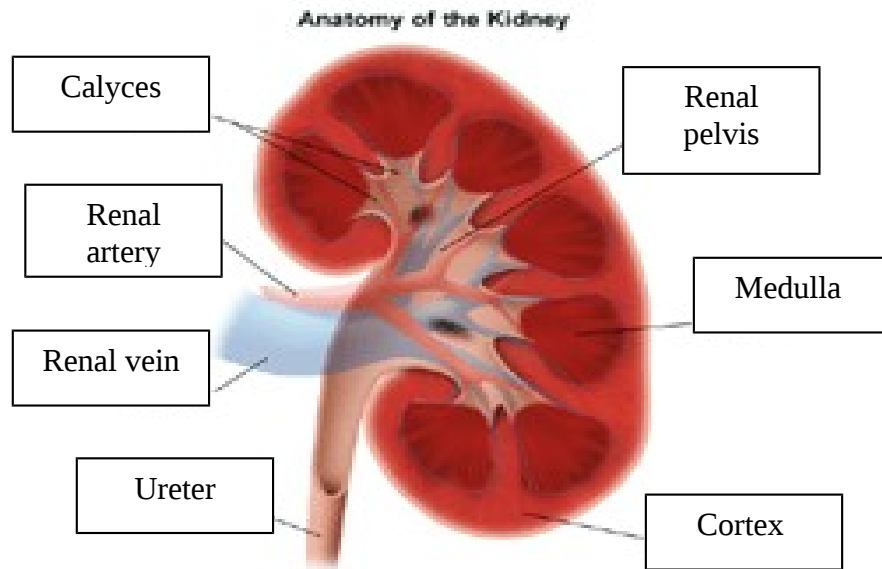


Figure (2-1): anatomy of the kidney. (www.comprehensive-kidney-facts.com)

The normal kidney size of an adult human is about 10 to 13 cm (4 to 5 inches) long and about 5 to 7.5 cm (2 to 3 inches) wide. (www.comprehensive-kidney-facts.com)

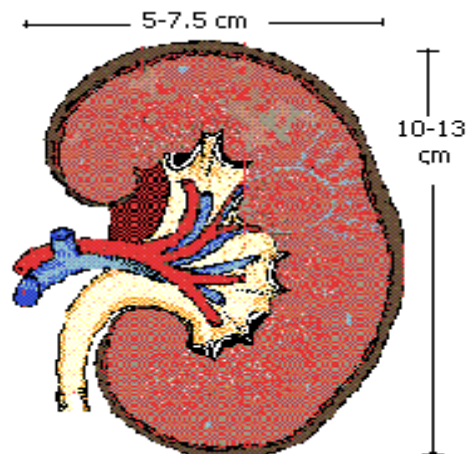


Figure (2-2): size of the kidney. (www.comprehensive-kidney-facts.com)

2-1-1 Blood supply:

The kidneys are full of blood vessels. Blood vessels are integral to efficient kidney function. Every function of the kidney involves blood; therefore, it requires a lot of blood vessels to facilitate these functions. Together, the two kidneys contain about 160 km of blood vessels. The renal circulation receives around 20% of the cardiac output. It branches from the abdominal aorta and returns blood to the ascending vena cava. (www.comprehensive-kidney-facts.com)

2-1-2 Nerve supply:

Stimulation of the spinal parasympathetic fibres in the greater and lesser splanchnics causes vasodilatation of the renal blood-vessels, but the spinal parasympathetic fibres in the lumbar sympathetic trunk do not play a prominent part in such vasodilatation.(Kur , Kanda, Akibumi and Shigeo, 1993)

The spinal parasympathetic fibres exert specific secretory effects upon the kidney. The greater splanchnics contain fibres which promote elimination of the total nitrogen; the lesser splanchnics excite the elimination of phosphate; while fibres in the lumbar sympathetic trunk play a less significant part in the elimination of both total nitrogen and phosphate. The greater and lesser splanchnics, as well as fibres from the lumbar sympathetic trunk, have a markedly excitatory influence on the elimination of sodium chloride, although there are individual differences as to the extent of this influence.(Kur , Kanda, Akibumi and Shigeo, 1993)

2-2 Pathology:

2-2-1 Renal stone:

A kidney stone, also known as a renal calculus, is a solid concretion or crystal aggregation formed in the kidneys from dietary minerals in the urine. Urinary stones are typically classified by their location in the kidney (nephrolithiasis) or by their chemical composition (calcium-containing, struvite, uric acid, or other compounds). Kidney stones are a significant source of morbidity. 80% of those with kidney stones are men. Men most commonly experience their first episode between ages 30–40 years, while for women the age at first presentation is somewhat later. (Stoller , JW Mc and Aninch, 2008)

Kidney stones typically leave the body by passage in the urine stream, and many stones are formed and passed without causing symptoms. If stones grow to sufficient size (usually at least 3 millimeters (0.12 in)) they can cause obstruction of the ureter. Ureteral obstruction causes postrenal azotemia and hydronephrosis (distension and dilation of the renal pelvis and calyces), as well as spasm of the ureter. This leads to pain, most commonly felt in the flank (the area between the ribs and hip), lower abdomen and groin (a condition called renal colic). Renal colic can be associated with nausea, vomiting, fever, blood in the urine, pus in the urine, and painful urination. Renal colic typically comes in waves lasting 20 – 60 minutes, beginning in the flank or lower back and often radiating to the groin or genitals. The diagnosis of kidney stones is made on the basis of information obtained from the history, physical examination, urinalysis, and radiographic

studies. Ultrasound examination and blood tests may also aid in the diagnosis.
(www.wikipedia.com)

2-2-2 Renal mass:

Renal masses and cysts comprise a group of benign and cancerous tumors that arise in the kidneys. Most common among these are simple renal cysts (60-70% of all renal masses), which are benign, fluid-filled structures that generally produce no symptoms and are identified incidentally after radiology testing that is performed for other reasons.(<http://www.med.umich.edu>)

The most important distinction for patients with a renal mass or cyst is to determine whether or not the abnormality represents a cancer. Fortunately, a variety of radiological tests are available (including ultrasound, CT scan and MRI) that may permit distinction between benign and malignant kidney cysts and solid masses. In cases where a simple (benign) cyst is diagnosed, no additional treatment or follow-up is generally required. However, when a solid kidney mass or a cyst that is suspicious for cancer is noted, follow-up imaging studies and/or surgical intervention is often recommended. (<http://www.med.umich.edu>)

2-2-3 Hydronephrosis:

Literally "water inside the kidney" - refers to distension and dilation of the renal pelvis and calyces, usually caused by obstruction of the free flow of urine from the kidney. Untreated, it leads to progressive atrophy of the kidney. In cases of hydroureteronephrosis, there is distention of both the ureter and the renal pelvis and calices. (Kumar, Fausto, Abbas and Abul, 2005)

The signs and symptoms of hydronephrosis depend upon whether the obstruction is acute or chronic, partial or complete, unilateral or bilateral. Hydronephrosis that occurs acutely with sudden onset (as caused by a kidney stone) can cause intense pain in the flank area (between the hips and ribs), while a chronic occurrence that develops gradually will present with no pain or attacks of a dull discomfort. Nausea and vomiting may also occur. An obstruction that occurs at the urethra or bladder outlet can cause pain and pressure resulting from distension of the bladder. Blocking the flow of urine will commonly result in urinary tract infections which can lead to the development of additional stones, fever, and blood or pus in the urine. If complete obstruction occurs, kidney failure may follow.(Porter, 2009)

2-2-4 Compensatory renal hypertrophy:

Increased kidney size and function in circumstances where there is a reduction in nephron number. The causes include: congenital, as in the oligomeganefronia, unilateral renal agenesis, and unilateral nephrectomy due to illness or living kidney donation. A special case without nephron reduction occurs in the early stages of diabetes (hypertrophy, hyperfiltration and hyperperfusion). After unilateral renal clearance, the contralateral kidney undergoes a phenomenon of morphological and functional hypertrophy, reaching a glomerular filtration rate of 60-70% of prenefrectomía to seven days, which may progress over time to six or twelve months (http://www.wikbio.com)

2-2-5 Chronic Pyelonephritis:

Chronic pyelonephritis is characterized by scarring and shrunken volume (atrophy) of the kidneys.

Unlike acute pyelonephritis in which there is bacterial infection of the kidney, chronic pyelonephritis is a kidney condition that develops over time due to damage of kidney tissue. In adults, infection usually plays a role, but the underlying disorder usually involves an underlying structural or functional abnormality in the urinary tract that predisposes an individual to kidney infections. It results in decreased ability of the kidneys to function (renal failure). Abnormalities that increase the risk of chronic pyelonephritis with repeated urinary tract infections include diabetes, kidney stones (calculi), use of certain analgesics, and urinary tract obstruction. (<http://www.mdguidelines.com>) .Infection alone rarely leads to chronic pyelonephritis and loss of kidney function.

Chronic pyelonephritis can develop without infection. Individuals with an abnormality of the junction between the ureter and bladder (vesicoureteral junction) in childhood may develop chronic pyelonephritis. Abnormality of the vesicoureteral junction, a congenital condition in which the juncture between the ureters and bladder is weak, allows urine to flow backward from the bladder to the ureter and up into the kidney. Severe reflux alone can lead to kidney scarring, even in the absence of other factors known to cause kidney scarring. The scarring of the kidneys associated with vesicoureteral reflux is similar to that seen with repeated infection combined with underlying structural abnormality. Some authorities theorize that kidney scarring due to reflux of urine (reflux nephropathy) may be an autoimmune process. Other noninfectious conditions that may scar the kidneys similarly to vesicoureteral reflux are long-standing high blood pressure (hypertension) and use of certain analgesics. Individuals with increased risk include those with congenital urinary tract abnormalities, and those with recurrent urinary tract infections. (<http://www.mdguidelines.com>)

2-3 Physiology:

2-3-1 Main functions of the Kidneys:

The main functions of the kidneys are regulation of the water and electrolyte content of the body, retention of substances vital to the body such as protein and glucose, maintenance of acid/base balance and Excretion of waste products, water soluble toxic substances and drugs. A kidney also acts as endocrine function. (Stewart, 1998)

2-3-2 Regulation of the Water & Electrolyte Content of the Body:

The kidney allows a person to eat and drink according to their habits without changing the composition of their fluid compartments.(Stewart, 1998)

Renal Blood Supply is normally is about 20% of the cardiac output. Approximately 99% of the blood flow goes to the cortex and 1% to the medulla. The cortex is the outer part of the kidney containing most of the nephrons. The medulla is the inner part of the kidney and contains the specialized nephrons in the juxta-medullary region, immediately next to the medulla. These nephrons have a greater concentrating ability, the mechanism being explained below. (Stewart, 1998)

The kidney is unique as it has two capillary beds arranged in series, the glomerular capillaries which are under high pressure for filtering, and the

peritubular capillaries which are situated around the tubule and are at low pressure this permits large volumes of fluid to be filtered and reabsorbed. (Stewart, 1998)

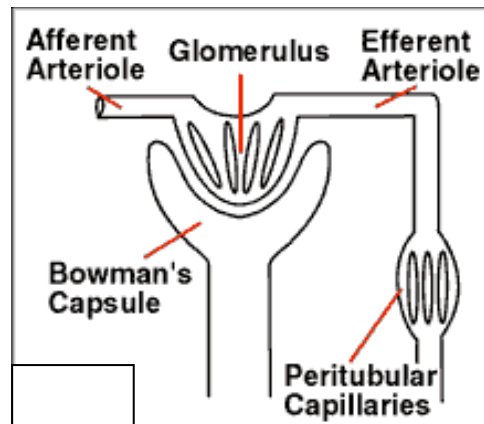


Figure (3-1): Bowman capsule. (Stewart, 1998)

Each kidney consists of about one million nephrons. The nephron is made up of a glomerulus and its tubule.

The tubule is made up of a number of sections, the proximal tubule, the medullary loop (loop of Henle), and the distal tubule which finally empties into the collecting duct. Urine is formed as a result of three phase processes which are Simple filtration, Selective and passive reabsorption and excretion. (Stewart, 1998)

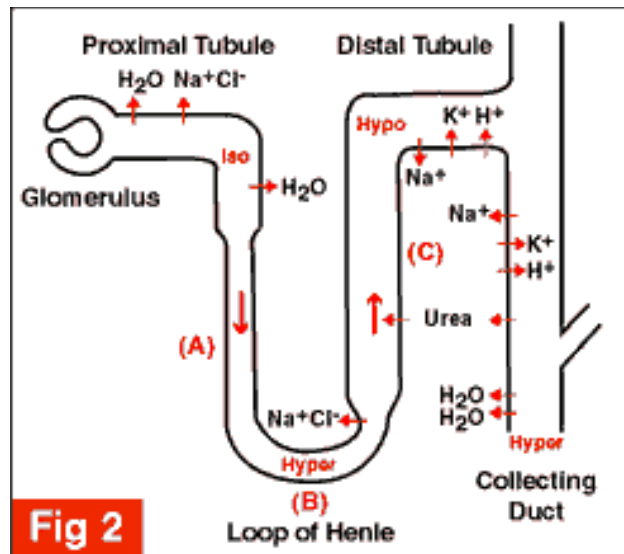


Figure (3-2): Regulation of the Water & Electrolyte Content of the Body. (Stewart, 1998)

Filtration takes place through the semipermeable walls of the glomerular capillaries which are almost impermeable to proteins and large molecules. The filtrate is thus virtually free of protein and has no cellular elements. (Stewart, 1998)

The glomerular filtrate is formed by squeezing fluid through the glomerular capillary bed. The driving hydrostatic pressure (head of pressure) is controlled by the afferent and efferent arterioles, and provided by arterial pressure. About 20% of renal plasma flow is filtered each minute (125 ml/min). This is the glomerular filtration rate (GFR). (Stewart, 1998)

At the loop of Henle, there is greater time for reabsorption of sodium and chloride ions. Therefore there is a decrease in the number of sodium and chloride ions reaching the distal tubule which is detected by the macula densa. This in turn decreases the resistance in the afferent arteriole which results in an increase in renal blood flow. (Stewart, 1998)

It also increases renin release from the juxtaglomerular apparatus which stimulates angiotensin II production causing constriction of the efferent arteriole. These both act to increase the hydrostatic pressure in the glomerular capillary bed and return GFR to normal. (Stewart, 1998)

The juxtaglomerular complex consists of macula densa cells, which are special distal tubular epithelial cells which detect chloride concentration and modified smooth muscle cells, juxtaglomerular cells, in the walls of the afferent and efferent arteriole. These cells produce renin. Renin is an enzyme which converts the plasma protein angiotensinogen to angiotensin I. Angiotensin converting enzyme (ACE) which is formed in small quantities in the lungs, proximal tubule and other tissues, converts angiotensin I to angiotensin II which causes vasoconstriction and an increase in blood pressure. Angiotensin II also stimulates the adrenal gland to produce aldosterone which causes water and sodium retention which together increase blood volume. (Stewart, 1998)

This is a negative feedback system. In other words the initial stimulus is a fall in blood volume which leads to a fall in perfusion pressure in the kidneys. When blood volume, renal perfusion and GFR improve the system feeds back to switch off or turn down the response to the stimulus. (Stewart, 1998)

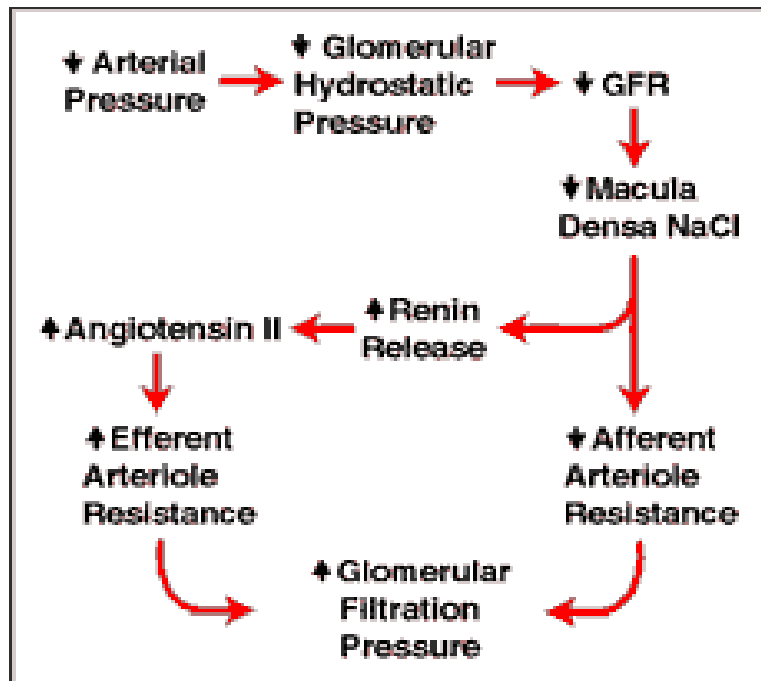


Figure (3-2) Regulation process. (Stewart, 1998)

2-4 Multidetector computed tomography:

‘Multidetector CT’ (MDCT) denotes the ability of CT scanner to acquire more than one slice simultaneously, to be capable of doing so the detector system most necessarily be composed of more than a single row of detector elements. Other terms often used, such as ‘Multidetector CT’, are somewhat misleading, as the number of detector rows generally larger than the number of slices. The latter, however, is the decisive feature of such a scanner. (Kalender, 2000)

The Multidetector CT is started in 1992 with the introduction of the Elscint CT Twin, a dual slice scanner. The advantages of a MDCT scanner can shortly be characterized by acronyms R, S, V, and P which stand for:

- 4- Resolution: improve spatial resolution along the z-axis.
- 5- Speed: reduce time for scanning.
- 6- Volume: increase length than can be Scand for a given set of scan parameters.
- 7- Power: increasing usage of x-ray tube power.

In 1988, the first four-slice scanners were presented, followed by the introduction of 16-slice scanner in 2001. The rapid development in this field is expressed by the presentation of 32- and 40-slice scanners and the announcement of 64-slice scanner at 2003 RSNA meeting. Not only the number of slice has increased, but also the rotational speed, from formerly is to presently 0.375 s per rotation. (Kalender, 2000)

Whereas dual-slice scanners allowed improving one specific aspect only (R or S or V or P), scanners with 16 and more slice are virtually unlimited (R and S and V and P). This has opened the filed for new or improved applications, such as cardiac CT, CT angiography, CT perfusion, polytaruma CT, and orthopedic, to only name the most important. (Kalender, 2000)

2- 5 Detector layout and slice definition:

The essential precondition for multidetector CT is a multirow detector array. Both gas detector and 4th generation scanners with 360° detector rings are no longer compatible with MDCT requirement. Consequently, all MDCT scanners are

of the 3rd generation rotate-rotate type and employ solid-state detectors. (Nagel, 2004)

With four slice scanners, various designs were used which differed in the number of detector rows, the dimension of the detector elements and the total width of the array. The universal matrix design used by GE (General Electric company) allowed using the same detector for an eight-slice scanner also, which was introduced in 2001, at the expense of a large number of septa which are not contributing to detection. The progressive design commonly employed by Philips and Siemens aimed to reduce the number of septa between the rows, thereby improving the geometric efficiency of the array. The hybrid design introduced by Toshiba was the only one that offered four slice in sub-millimeter acquisition mode, however at the expense of an even greater number of septa. In addition, the Toshiba layout provided a total width of 32 mm for scanning four slices each 8 mm thick simultaneously. (Nagel, 2004)

With 16-slice, all manufacturers employed a hybrid layout, allowing for sub-millimeter acquisition in 16-slice mode. Only the size of the smallest detector elements and the total width of the array differ, with each manufacturer claiming to offer the most optimal design. However, the question what is optimal depends on all aspects involved (z-resolution, volume coverage, dose), not only one (e.g. z-resolution). As in daily life, the optimum is the result of the best compromise. This becomes evident in cardiac CT, which is the most demanding new MDCT application. (Nagel, 2004)

Slice definition is achieved by combining adjacent detector rows and employing appropriate pre- and post-patient – collimation. Thus a variety of slice collimations can be offered, such as (4.5) mm, (4.25) mm, (4.1) mm and (2.5) mm

for the progressive design shown here. Similar considerations apply to the others designs. It is important to note that the slice thickness used for image presentation can differ from that during data acquisition (slice collimation). Thicker slices can be generated from thin slice data, either during reconstruction or by post-processing. However, once a certain slice collimation has been selected, it is not possible to reconstruct thinner slice later. (Kalender, 2000)

Hybrid designs are also used for the most recently presented scanners with 32 and more slices. However, when going to detector array with more than approximately 45 rows, a technological barrier appears. This is caused by the minimal spacing of the wirebonds linked to the data readout lines, which cannot be made smaller than 60 mm. In traditional, front-illuminated photodiode design, these lines must be arranged in a horizontal fashion, thus limiting the number of detector rows which can electrically be connected to the ASIC of the data acquisition system. This bottleneck has recently been overcome with the advent of back-illuminated photodiodes. As these can vertically be guided to the ASIC via a conductive epoxy, the number of the detector rows is no longer limited by spatial restrictions. (Kalender, 2000)

2- 6 Z-interpolation, pitch and mAs per slice conception:

MDCT can be used both in sequential and spiral scanning modes. As with single slice CT (SSCT), data acquired in single mode have to be interpolated in order to achieve axial slice. However, a different interpolation scheme is used in most MDCT implementation. While a two-point interpolation between a pair of data points closest to the reconstructed slice position is employed in SSCT, MDCT

scanners from Philips, Siemens and Toshiba make use of a multi-point interpolation (z-filtering). All data points falling inside a pre-selected filter width FW (which defines the reconstructed slice thickness) are taken in account, either equally or in a weighted fashion. (Kalender, 2000)

The new interpolation scheme offers significant advantages; other than for single slice scanners, slice profile width (effective slice thickness) can be kept constant independent of the pitch factor selected. However, also different from SSCT, image noise now changes with pitch, as the number of data points available for interpolation also changes. To avoid this, the electric tube current is automatically adapted proportional to the increase (or decrease) in pitch factor settings ('effective mAs' or 'mAs per slice' conception). (Kalender, 2000)

As a consequence, slice thickness, image noise and average patient dose are independent of the pitch factor setting for a pre-selected, constant value of mAs per slice i.e. electric mAs divided by pitch. So pitch merely serves to control the scan speed, this holds for MSCT scanners of Philips, Siemens, whereas Toshiba users need to adapt the mAs setting manually if felt necessary. By using pitch factors < 1 , greater data density is achieved which can be used to virtually increase the available mAs per slice value despite the limited loadability of the x-ray tube. In addition spiral artifacts are reduced to pitch factor settings < 1 , both at the expense of reduced volume coverage per unit time, however. Some manufacturers like GE and Toshiba also offer (or recommend) dedicated pitch factor settings only ('preferred pitch') in order to optimize data sampling and to minimize artifacts, while Philips and Siemens users are not restricted in this context. (Kalender, 2000)

The pitch factor used here follows the universal pitch definition given in IEC standards as the ratio of the table feed per rotation and the total collimation $N \backslash h$,

where pitch 1 denotes a ‘slice-by-slice acquisition’. Most manufacturers now comply with this definition instead of another one formerly (‘volume pitch’ $p^* = \text{table feed divided by slice collimation } h \text{ only}$), resulting in large values (1 to 8 for four-slice, 2 to 30 for 16-slice scanner). This was highly misleading, as a scanner can be used in different ‘number of slice’ configuration (e.g. 16-, 6-, 4-, and 2-slice modes with some 16-slice scanners). (Kalender, 2000)

2- 7 Multidetector CT of the kidney:

Multidetector CT (MDCT) scanners allow for fast investigation with high spatial resolution. (Foley WD, 2003) Narrow collimation results in isotropic voxels in 64-channel MDCT scanners of recent release. Images in arbitrarily reconstructed planes come close to the image quality in the original scan plane. Small slice thickness improves the detection of small structures and allows better discrimination of solid and cystic structures as partial-volume effects diminish. Slice fusion options improve contrast and contrast-to-noise ratio. Due to short scan times, the kidneys can be depicted in well-defined (dynamic) phases of contrast enhancement, so that lesions can be characterized more precisely. In practice, it is advisable to choose a reconstruction thickness of 3–5 mm as a compromise between spatial resolution and contrast-to-noise ratio. Depending on radiological findings, reconstructions in other planes and slice thickness down to the sub millimeter range can be added (depending on scanner type and number of detector rows available). Multidetector CT increases dose as a result of thinner collimation, over beaming, and over ranging effects. For example, in four-row scanners, effective dose is about 30% higher with a collimation of 1 mm than with a collimation of 2.5 mm, for that reason, and because the interval of breath-holding decreases, a collimation of 2.5 mm is recommended in these scanners. In current Multidetector scanners with more than four rows that allow for two different

collimations (millimeter and sub millimeter), radiation dose increases only by about 10% when the smaller collimation is chosen. In spiral technique, additional tube rotations have to be performed at the beginning and at the end of the scan range because adjacent data from both sides are necessary for image reconstruction (interpolation). Therefore, the scanned volume exceeds the reconstructed volume. The number of additional rotations depends on pitch, cone beam correction, and scanner type. The over ranging effect may cause considerable increase of dose. (Tzedakis, Damilakis, Perisinakis, Statakis and Gourtsoyiannis, 2005)

Dose limitation is possible with the application of dose modulation software. Dose modulation is based on the principle that decrease in body diameter (i.e., the anteroposterior diameter when compared to the lateral diameter) translates into decrease in radiation necessary to obtain a certain contrast-to-noise ratio in the resulting CT image data. (Tzedakis, Damilakis, Perisinakis, Statakis and Gourtsoyiannis, 2005). Images are usually reconstructed in the transversal plane. The coronal plane is suitable for reconstruction of an “insitu” perspective that resembles the view of the abdominal or urologic surgeon. The multiplanar reformation (MPR) describes the option of arbitrary plane reconstruction from voxel data sets. These planes can be chosen in an orthogonal plane (sagittal, coronal), oblique plane or even in a curved planar reconstruction (for example, for course of vessels). Best reconstruction results are obtained in a pseudo-two dimensional display with isotropic voxels. Maximum intensity projection (MIP) depicts the structures of highest CT density within a volume of interest. Volume rendering technique (VRT) is an image-processing option that emphasizes regions of selected CT density range, thereby accentuating specific tissues or organs. (Prokop, 2003), (Kemper, Adam and Ernsting, 2005)

2- 8 Technique and Scanning Protocol

For confident diagnosis and management of renal dimensions, a dedicated, multiphase CT evaluation of the kidney is mandatory .Non-contrast scans and non-helically prior to helical scans may be performed. Use comparable collimation and delayed non-helical sections should be done approximately 2 min after helix. Minimum suggested mA on general electric Hi-Speed adjust appropriately for other scanners and Lower mA may be used in thin patients. Increased pitch will cause undesirable partial volume averaging when used in conjunction with collimation beyond 5 mm. If cannot achieve adequate z-axis coverage, use 7 or 8 mm collimation may need to do additional thinner sections for CT numbers. Use non-contrast scans to localize starting location and this would be cephalic to caudal or vice versa. If combined exam to include thorax, start at bottom of kidney and scan cephalic. In need in reducing mA or completing thorax non-helically, if scanner permits include liver. If patient cannot hold breath, split helix with 7 sec pause after 15-20 sec.

Optimal for 3 mL/sec injection and delayed scans at 2-3 min. Finally, film images reconstructed with 5mm spacing, or read from workstation. (Federle, 1997)

2-7-1 protocol:

Scan mode: Helical, Scan parameters: 120 kVp, 280 mA, Length of helical exposure: 30-40 sec (approximate), Field of view: 30 to 40 cm, Pitch: 1:1, Collimation: 4-8 mm, Number of sections: 30-40 (approximate), Area of interest: From upper to lower pole of kidneys, Patient Instructions: Breath hold in mid-

inspiration, Contrast Prefer: non-ionic 300 mgI/mL, Volume :120 mL (ionic or non-ionic), Rate: 3 mL/ sec, Scan delay: 60 sec; then repeat at 100 sec delay, Reconstruction algorithm: Standard, Reconstruction spacing: 2 mm and equal to collimation intervals. (Federle, 1997)

2- 9 previous studies:

(Fernandes, Lemos, Lopes, Madeira, Santos, Bregman, 2002) division of Nephrology, School of Medicine, State University of Rio de Janeiro, Rio de Janeiro, Brazil. And result was: Renal length reduced with aging, excluding that

height was the only variable to show association with renal dimensions, and the left kidney was bigger than the right kidney.

(Bircan, Oner, Saka, Kavasoglu and Akaydin, 1993) Department of General Surgery, Faculty of Medicine, Akdeniz University, Turkey and the result was: there are strong relation between kidney length and physical condition of the body especially the length, the higher body the longer kidney.

(Harmse, 2011) Department of Diagnostic Radiology, Faculty of Health Sciences, University of the Free State, Bloemfontein and the result was: The mean renal length was 108 mm with a standard deviation of 9.82 mm. kidneys were generally larger in the white population than in the black, and also in males than females and Normal renal size varies according to patients' body habits. This variation can be expressed as a function of body weight and height.

(Peter, Buchholz, Abbas, Biyabani, Javed and Talati, 2000), departments of Surgery (Section of Urology), the Aga Khan University, Karachi, and the result was: The mean kidney length was 10.4 ± 0.8 cm, mean width 4.5 ± 0.6 cm and mean cortical thickness 1.6 ± 0.2 cm. The estimated mean renal size was 76 ± 22 cm³. Kidney length did not significantly differ between right and left, however, kidney width, cortical thickness and size did ($p < 0.05$). Right kidneys were smaller than the left ones.

(Shin, Chung, Kim, Ha, and Yang, Yonsei University College of Medicine, 2009) and the results were: mean kidney length was 10.80 ± 0.69 cm. The former correlated significantly with height, body weight, body-surface area, and total body water ($p < 0.05$, correlation coefficient: $\gamma = 0.328, 0.649, 0.640$, and 0.638 , respectively). The latter also correlated significantly with all body indexes, however the correlation was weaker, except with height ($p < 0.05$, correlation coefficient: $\gamma = 0.457, 0.473, 0.505$, and 0.503 , respectively). Only kidney volume

significantly predicted estimated GFR (adjusted $R^2 = 0.431$, $F = 85.90$ and $p < 0.05$).

(Glodny, Unterholzner, Taferner, Hofmann, Rehder, Strasak and Petersen. Austria, 2011) and the results were: Length from Pole to Pole was 108.5 ± 12.2 mm for the right, and 111.3 ± 12.6 mm for the left kidney ($p < 0.0001$ each). PW on the right side was 15.4 ± 2.8 mm, slightly less than 15.9 ± 2.7 mm on the left side ($p < 0.0001$), the cortical width was the same (6.6 ± 1.9 mm). The most significant independent predictors for LPP, CW, and parenchymal width were body size, BMI, age, and gender ($p < 0.001$ each). In men, the LPP increases up to the fifth decade of life ($p < 0.01$). It is also influenced by the position of the kidneys, stenoses and number of renal arteries (SRA/NRA), infarctions suffered, parapelvic cysts, and absence of the contralateral kidney; CW is influenced by age, position, parapelvic cysts, NRA and SRA, and the PW is influenced in addition by rotation status ($p < 0.05$ each). Depending on the most important factors, gender-specific normal values were indicated for these dimensions, the length and width in cross section, width of the renal pelvis, and parenchyma-renal pyelon ratio.

CHAPTER THREE

3- MATERIAL AND METHODS:

3-1 Patients:

Analytical descriptive study was carried out for (50) patients whose undergone CT KUB, 25 adult male and 25 adult female in different ages and all patients with hydronephrosis case were excluded. Following information about patients was reported; age, sex and clinical finding. And that was from Augusts 2011 until October 2011 in Nileain, Elsoni private centers CT departments.

3-2 Machine:

3rd generation Siemens Somatom emotion duo. The emotion due multislice helical CT scanners, featuring (380-415) out voltage, (365-435) input range. Scanner gantry 70(cm) aperture, maximum scan filed view 50 (cm) ,70(cm) option. Nominal slice width for axial scans 0.6, 0.75, 1.0, 1.5, 3, 4.5, 5, 6, 9, 10.

3-3 CT KUB protocol:

CT scans were performed including protocol of axial images from the xiphoid process covers all abdominal area and pelvic down to pubic bone with patient in supine position, head first. The images were made at 100/120 kv and 60/80 mAs, with 5 mm slice thickness. Reconstruction used 3mm to obtain coronal views of KUB. Light diets and fasting for 6 hr was preparation for patient who's undergone CT KUB.

3-4 image interpretation:

All images of the study are measured and analyzed for the length; which measure in coronal section, from pole to pole (figure 3-1).Depth which measure from anterior to posterior in axial section (figure 3-2), width which measure from

lateral aspect of the kidney to medial aspect (figure 3-1). Pelvic size calculates from equation of length multiply by width of the kidney pelvis.

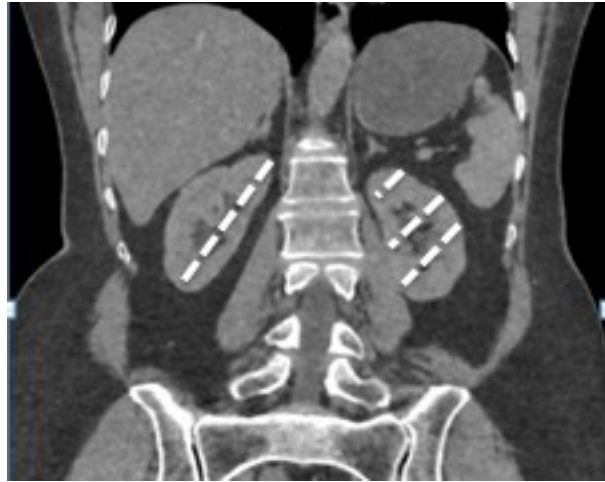

Figure (3-1): measurements of length and width.

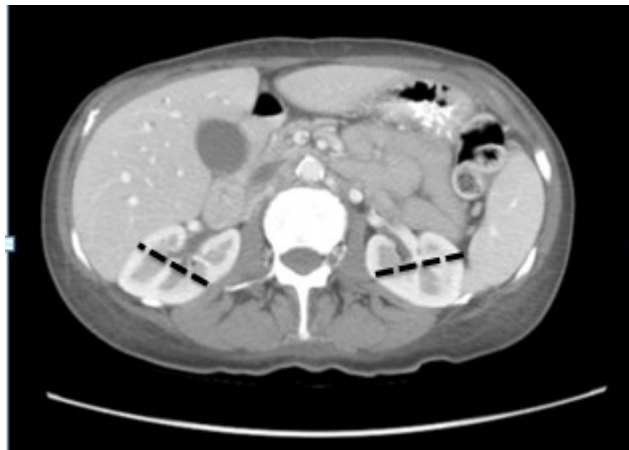

Figure (3-1): measurements of depth.

CHAPTER FOUR

RESULTS

The measurements of length, width, depth and kidney's pelvic size of both kidneys and others data were presented in the following tables and figures.

Table (4-1): gender distribution

Male	Female	Total
25	25	50

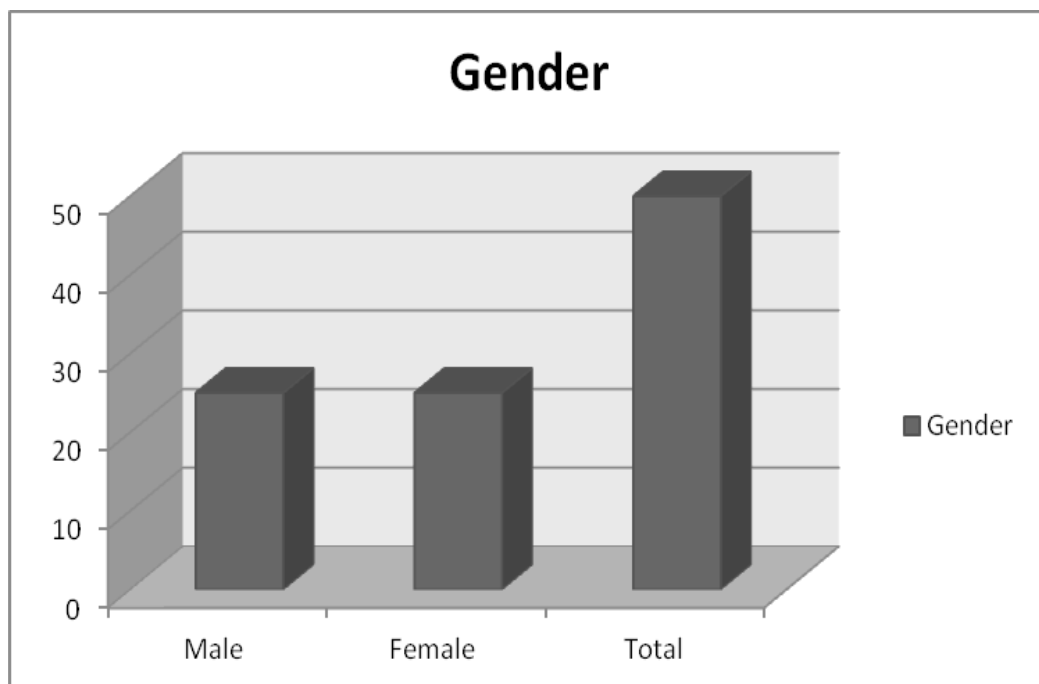


Figure (4-1): Gender distribution.

Table (4-2): Age distribution

Age (year)	Number of cases
16 – 30	7
31 – 45	12
46 – 60	14
61 – 75	11

76 – 90	6
---------	---

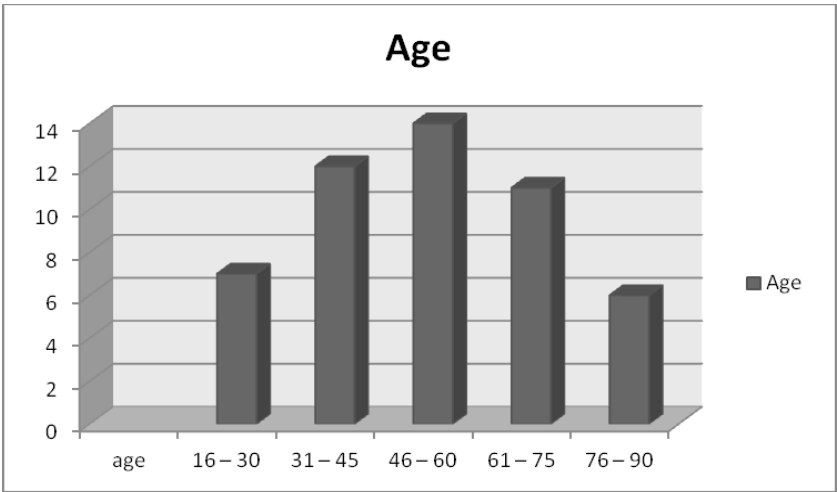


Figure (4-2): Age distribution.

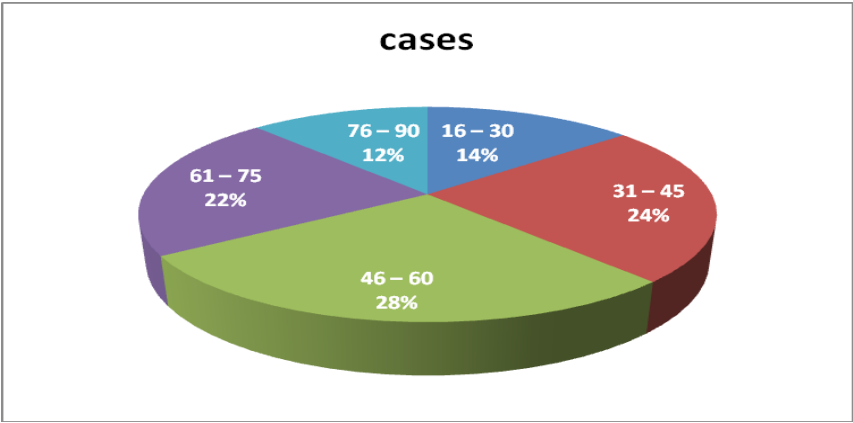


Figure (4-3): Age distribution in percentage.

Table (4-3): kidney length measured by computed tomography (mean±SD) .

Gender	Kidney length (mean ± SD) (cm)	
	RT	LT

Male	10.2 ± 1.13	10.3 ± 1
Female	9.8 ± 0.93	10.1 ± 1.1

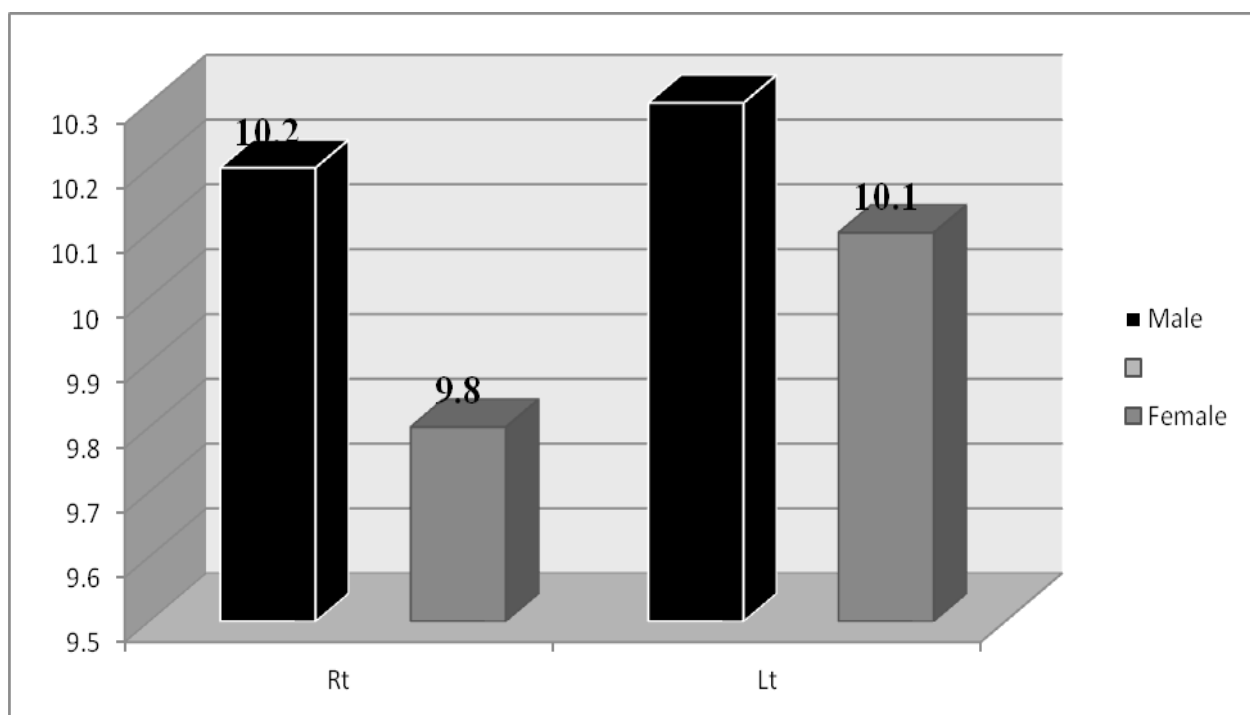


Figure (4-4): kidney length.

Table (4-4): kidney width measured by computed tomography (mean±SD).

Gender	Kidney width (mean ± SD) (cm)	
	RT	LT

Male	3.2± 0.5	3.5 ± 0.6
Female	3.1 ± 0.4	3.2 ± 0.7

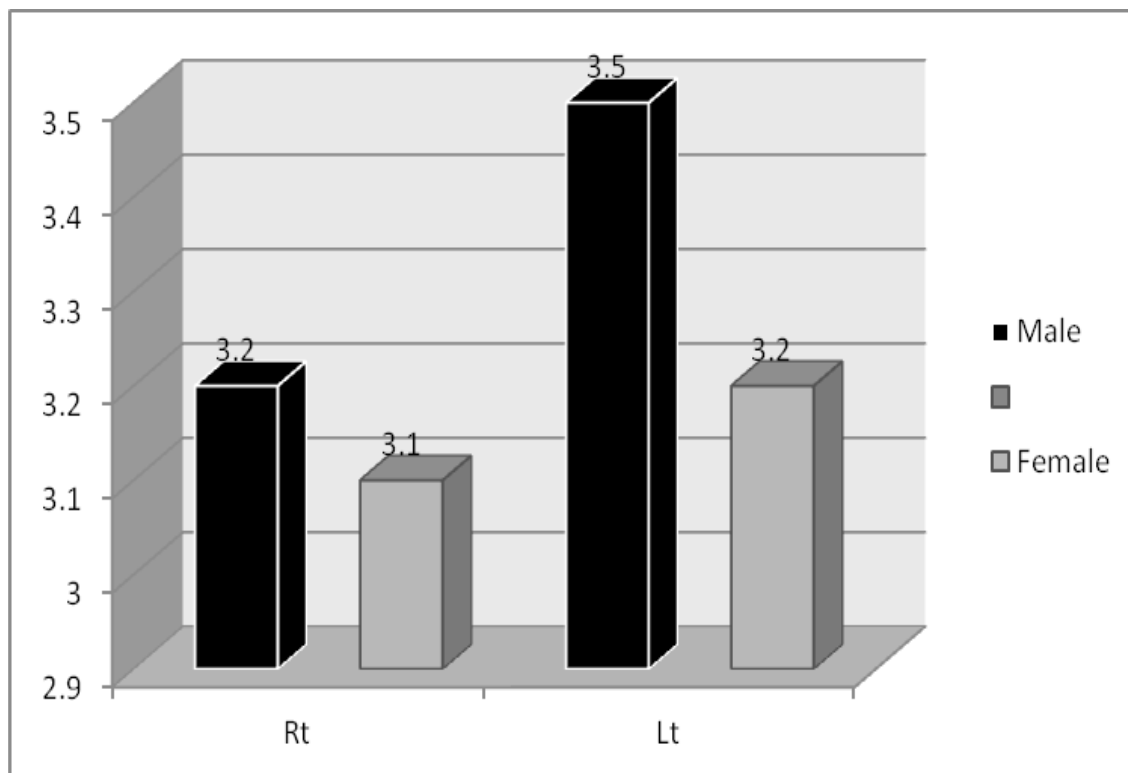


Figure (4-5): kidney width.

Table (4-5): kidney depth measured by computed tomography (mean±SD).

Gender	Kidney depth (mean ± SD) (cm)	
	RT	LT

Male	5 ± 0.9	5.3 ± 1.1
Female	4.8 ± 0.9	4.8 ± 0.9

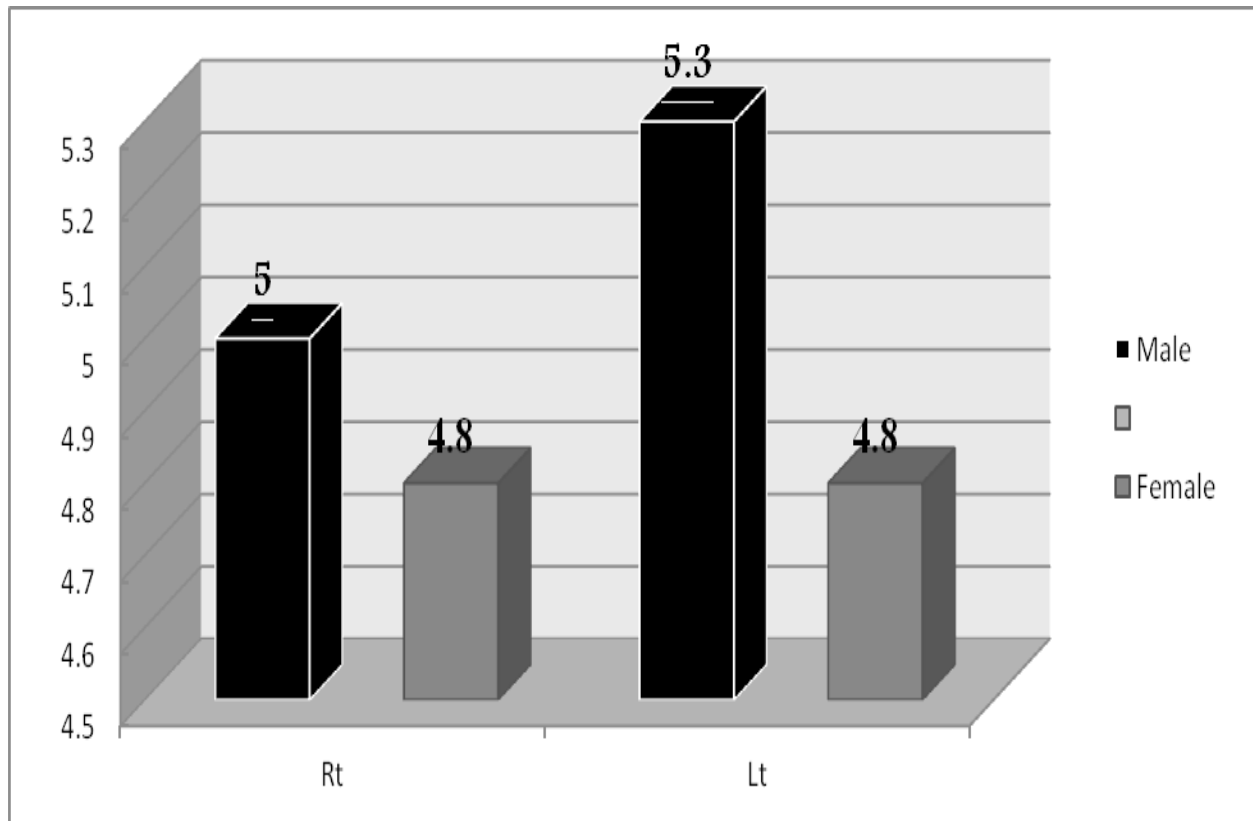


Figure (4-6): kidney depth.

Table (4-6): kidney's pelvis size measured by computed tomography (mean \pm SD).

Gender	Kidney's pelvis size (mean \pm SD) (cm ²)	
	RT	LT

Male	4.6 ± 2.6	4.1 ± 1.5
Female	3.8 ± 2.3	3.9 ± 1.2

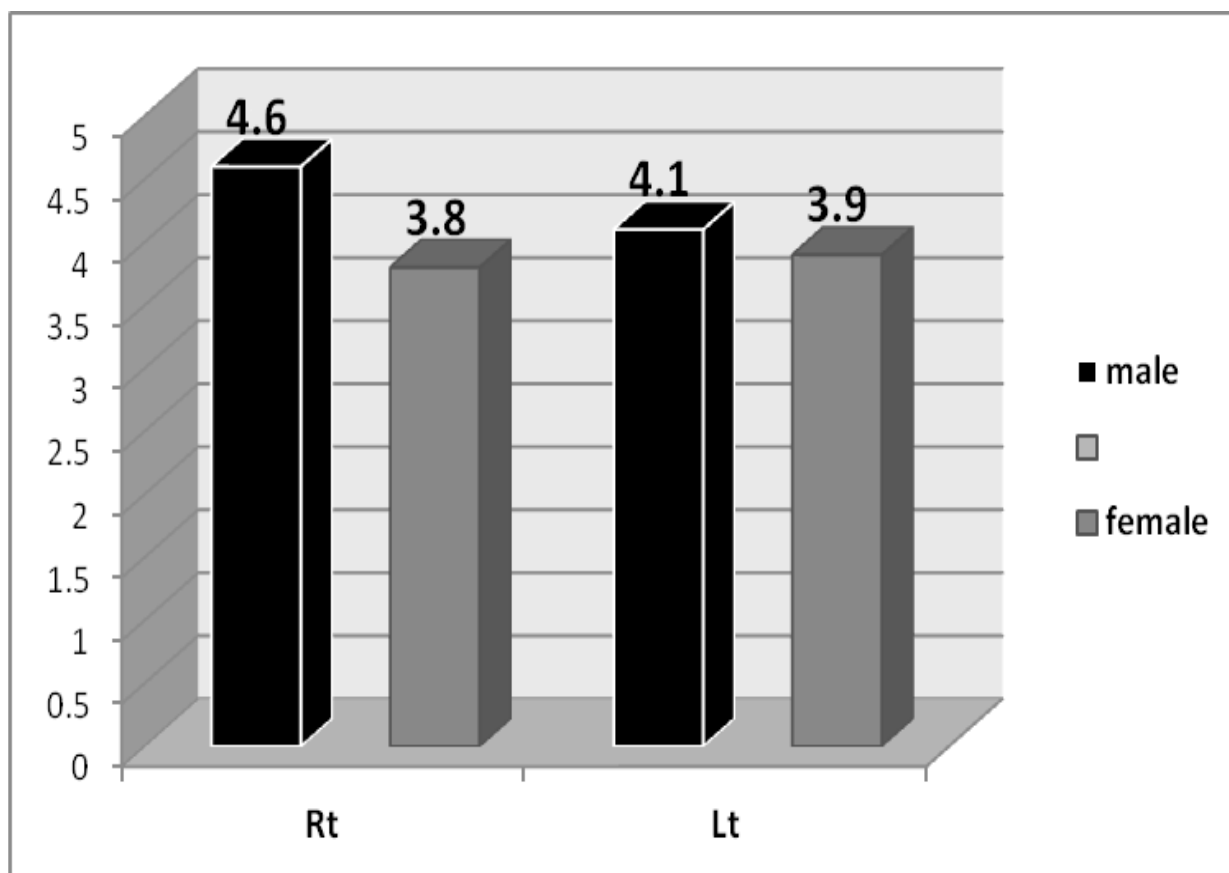


Figure (4-7): kidney's pelvis size.

Table (4-7): measurements of right kidney respecting to age (mean±SD).

Age (year)	Length (cm)	Width(cm)	depth(cm)	pelvis size (cm) ²
------------	-------------	-----------	-----------	-------------------------------

16 - 30	9.7± 0.6	3.2± 0.3	5.1± 0.7	3.6± 1.4
31 - 45	9.9± 2.2	3.3± 0.8	5.1± 1.3	5.4± 2.9
46 - 60	10.4± 2.2	3± 0.8	4.7± 1.3	3.9± 2.8
61 - 75	9.8± 2.2	3.2± 0.8	4.9± 1.2	3.7± 2.5
76 - 90	9.1± 2.3	2.9± 0.8	4.7± 1.3	3.3± 2.3

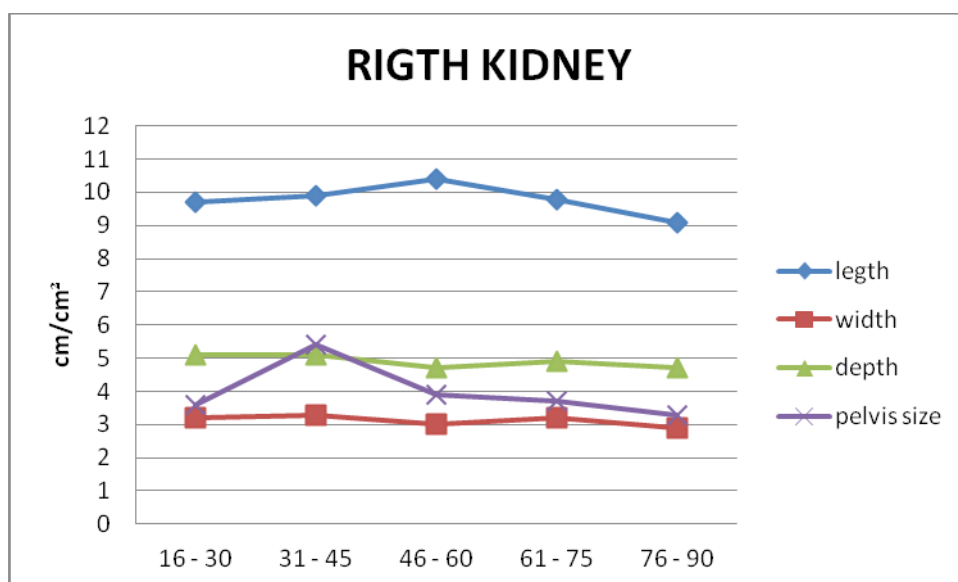


Figure (4-8): right kidney size respecting to age.

Table (4-8): measurements of left kidney respecting to age (mean±SD).

Age (year)	Length (cm)	Width(cm)	depth(cm)	pelvis size (cm) ²
------------	-------------	-----------	-----------	-------------------------------

16 - 30	9.9 ± 0.6	3.6± 0.6	4.9± 1.1	4.4± 1.2
31 - 45	10.1± 2.1	3.4± 0.8	5.2± 1.2	4.4± 1.5
46 - 60	10.2± 2.2	3.1± 0.8	4.7± 1.2	3.4± 1.4
61 - 75	10.6± 2.2	3.6± 0.8	5.3± 1.3	4± 1.4
76 - 90	9.6± 2.3	3.3± 0.9	5± 1.4	3.1± 1.4

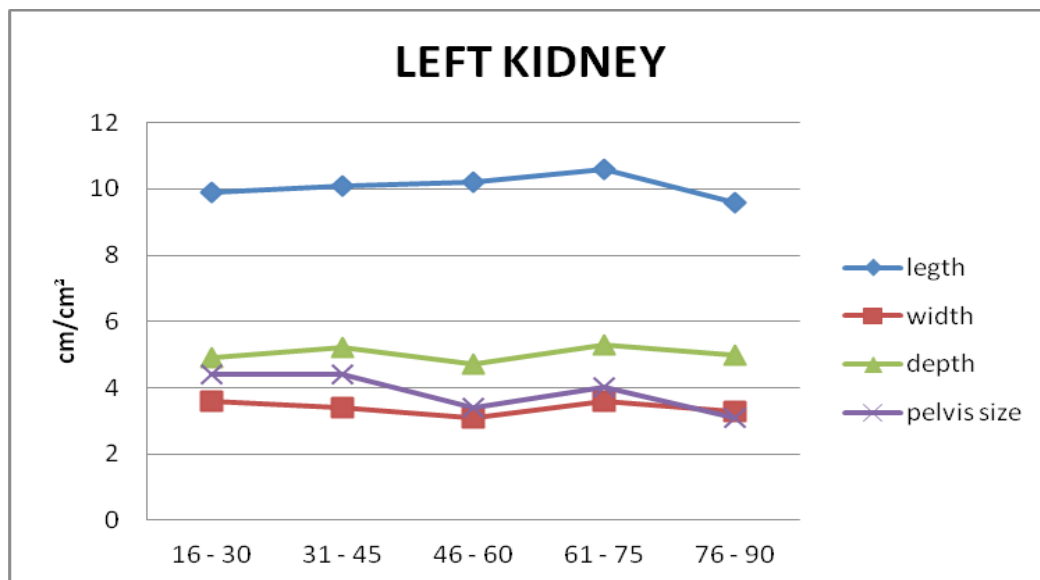


Figure (4-9): left kidney size respecting to age.

CHAPTER FIVE

5 - 1 DISSCUSION:

In this study, the analysis of renal and pelvic of the kidney measurements in terms of length, width, depth of the study group was performed.

In male the length of right kidney ($10.2 \pm 1.13\text{cm}$) is more than in female ($9.8 \pm 0.93\text{ cm}$). Also the result of the study shows that the length of Lt Kidney In female is less value ($9.8 \pm 0.93\text{ cm}$) than male ($10.1 \pm 1.1\text{cm}$), respecting to gender, that mean the male has large kidney length than female in both right and left kidneys ,these results agree with results from previous study. (Fernandes, Lemos, Lopes, Madeira, Santos and Bregman, 2002) Regarding to side, the left kidney length larger than right one in both gender.

Width of the right kidney in male ($3.2 \pm 0.5\text{cm}$) had a large value than in female ($3.1 \pm 0.4\text{cm}$), and left kidney also which is in male ($3.5 \pm 0.6\text{cm}$) and in female ($3.2 \pm 0.7\text{cm}$). In general and respecting to side the left kidney width is wider than right one and that agree with other studies results. (Fernandes, Lemos, Lopes, Madeira, Santos and Bregman, 2002), (Bircan, Oner, Saka, Kavasoglu and Akaydin, 1993)

For the depth of the kidney, in male the right kidney's depth had greater value ($5 \pm 0.9\text{cm}$) than in female ($4.8 \pm 0.9\text{cm}$) and the same in the left which in male ($5.3 \pm 1.1\text{cm}$) and in female ($4.8 \pm 0.9\text{cm}$), and respecting to side the left depth of the left kidney had larger value than in right in male and equaled in female. (Fernandes, Lemos, Lopes, et al, 2002), (Bircan, Oner, et al, 1993)

The measurements of renal pelvis reported slightly difference regarding to gender (Male, Female) and side (RT, Lt). The right renal pelvis in male ($4.6 \pm 2.6\text{cm}^2$) larger in size than in female ($3.8 \pm 2.3\text{cm}^2$) and left renal pelvis in male also had greater size ($4.1 \pm 1.5\text{cm}^2$) than in female ($3.9 \pm 1.2\text{cm}^2$).

Results that correlate with age, does not show any obvious change with increasing age, we attribute the differences in the dimensions of the kidneys to the

other reason, which perhaps related to physical condition (length & weight) which differ from person to other. (Harmse, 2011)

5- 2 CONCLUSION:

- Multidetector computed tomography is considered now as the modality of choice for the renal organs especially kidney imaging because it provides the precise view of anatomical structures.

- In male the length of right kidney is more than in female.
- Width of the right kidney in male had a large value than in female, and left kidney also which is in male and in female.
- In male the right kidney's depth had greater value than in female and the same in the left.
- Renal diminutions differ from patient to patient, leading to anatomical variations in kidney among general population.
- Proximally the Lt Kidney had greater dimensions than Rt kidney in both gender.
- The analyzed results in this study concluded that, the most individuals who have undergone CT KUB are in 4th, 5th and 6th decade of their age.
- Male has greater renal dimensions than female regardless the age.

5- 3 RECOMMENDATIONS:

The study end within the following recommendation:

- Further studies in evaluation renal dimensions with larger sample of population for more accurate results.

- Further studies must achieve bearing in mind the body weight and height.
- Race must take a place in further studies, for differentiation between black and white people in kidney measurement regarding to their environment.
- Correlation between age and kidney measurement in further studies.

References:

Anca Dragomir, Mats Hjortberg and Godfried M. Romans. "Superficial anatomy of the trunk". Section for human anatomy at the Department of medical biology, Uppsala University, Sweden.2007

Bernhard Glodny, Verena Unterholzner, Bernadette Taferner, Karin J. Hofmann, Peter Rehder, Alexander Strasak and Johannes Petersen. Normal kidney size and its influencing factors - a 64-slice MDCT study of 1.040 asymptomatic patients. Austria, 2011

Foley. WD, "Renal MDCT". EJR 45:S73–S78, 2003

Griffin P. Rodgers, M.D., M.A.C.P. By National Institute of Diabetes and Digestive and Kidney Diseases journal, "Imaging of the Urinary Tract" 2006

Glodny B, Unterholzner V, Taferner B, et al., "Normal kidney size and its influencing factors - a 64-slice MDCT study of 1.040 asymptomatic patients, 2009

Hans Dieter Nagel, clinical science CT, Philips Medial System, Germany, 2004

Ho Sik Shin, Byung Ha Chung, Sang Eun Lee, Woo Jin Kim, Hong Il Ha, and Chul Woo Yang. Yonsei University College of Medicine, Measurement of Kidney Volume with Multi-Detector Computed Tomography Scanning in Young Korean, 2009

Kemper. J, Adam. G, Nolte-Ernsting. C, "Multislice CT urography: aspects for technical management and clinical application", 2005

Kalender WA, "computed tomography – fundamentals, system technology, image quality, applications." Viley-VCH Verlag, Weinheim, 2000

Kumar, Fausto, Abbas, Abul. K, "Robbins and Cotran pathologic basis of disease, Volume 1", 2005

Ken Kuré, Koichi Kanda, Akibumi Wakabayashi and Shigeo Okinaka. " the spinal parasympathetic " , 1993.

Michael P. Federle, M.D., "Helical CT of the Kidney", 1997

Mergener. K; et al, Am. J .Gastroenterol "a syndrome of episodic abdominal pain of urologic origin that may present to a gastroenterologist", 1997

Niels-Peter Buchholz, Farhat Abbas, Syed Raziuddin Biyabani, Qaiser Javed, Jamsheer Talati (Departments of Surgery (Section of Urology), The Aga Khan University. Karachi.) **Masood Afzal and Imtiaz Rizvi** (Departments of Radiology, The Aga Khan University. Karachi), 2000

Preminger, G.M, "The Merck Manual of Medical Information Home Edition" 3rd edition, "Chapter 148: Stones in the Urinary Tract", 2007

Robert S. Porter, "Merck Manuals Home Health Handbook". Available from: [“Hydronephrosis”](#), 2009 updated of 2007

Robert S. Porter, "The Merck Manual Home Health Handbook", renal pathology. 2006

Schaefer-Prokop. C, Prokop. M, "Kidneys. In: Prokop M, Galanski M (eds) Spiral and multislice computed tomography of the body". Thieme, Stuttgart, pages 639–681, 2003

Salah Musa Mohammed Gaafer, anatomical variations in paranasal sinuses, October 2004.

Stoller M.L, JW Mc. Aninch, "Smith's General Urology/ Urinary stone disease", 17th ed, 2008

Tzedakis. A, Damilakis. J, Perisinakis. K, Statakis. J, Gourtsoyiannis. N , "The effect of Z over scanning on patient effective dose from multidetector helical computed tomography examinations" Med Physic, 2005

Walter. F, Boron "Medical Physiology: A Cellular And Molecular Approach".

Web sites:

- 1- <http://www.med.umich.edu> (urology department)
- 2- <http://www.wikbio.com> (en/dictionary/definition of compensatory renal hypertrophy)
- 3- <http://www.shands.org> ("Reflux Nephropathy." SHANDS Healthcare), 2004
- 4- <http://www.mdguidelines.com> (pyelonephritis-chronic)
- 5- <http://www.comprehensive-kidney-facts.com> (kidney-anatomy)

DATA COLLECTION SHEET

Pt ID:

Age:y

Gender:

☐

Male

☐

Female

Dimensions of the kidneys:

- Length:

Rt

cm

Lt

cm

-Width:

Rt

cm

Lt

cm

- Depth:

Rt

cm

Lt

cm

- Kidney's pelvic size (length x width):

Rt

cm

Lt

cm

- Clinical findings:

