



**Sudan University of Science and  
Technology**



**College of Graduate Studies**

**Measurement of Prostatic Gland Size Using  
Ultrasound**

**قياس حجم غدة البروستاتا باستخدام الموجات فوق  
الصوتية**

*A thesis Submitted for Partial Fulfillments of the requirement of M.sc Degree in  
Medical Diagnostic Ultrasound*

**By:**

Mohammed Ali Ahmed Elmukashfi Elsiddig

**Supervisor:**

Dr. Babiker Abd Elwahab Awad Allah

بِسْمِ اللَّهِ الرَّحْمَنِ الرَّحِيمِ

## الآية

قال تعالى:

(شَهِدَ اللَّهُ أَنَّهُ لَا إِلَهَ إِلَّا هُوَ وَالْمَلَائِكَةُ وَأُولُو الْعِلْمِ قَائِمًا بِالْقِسْطِ لَا إِلَهَ إِلَّا هُوَ الْعَزِيزُ الْحَكِيمُ)

صدق الله العظيم

سورة ال عمران – آية (18)

# Dedication

To my mother and to the pure spirit of my father

To My Wife and my family

To my colleagues

To all teachers, workers, tea makers, library staff, and anyone in this college for their cooperation and help.

# Acknowledgement

My deepest appreciation and sincerest gratitude

To my god for giving me a health to complete this thesis and still giving me more and more. Special thanks and gratefulness to my supervisor Dr. Babiker Abd

Elwahab Awad Allah for his advices and guidance.

To the staff of M.sc degree of US in Sudan university.

## **Abstract**

This was descriptive study done in Khartoum state Sudan in Bahri and Haj Elasafi Teaching Hospital, in addition to other health care centers, from July – to October 2018. The problem of study was that the prostate volume measurement is frequently used to diagnose the abnormalities of the gland and the normal size of the gland itself affected by age, weight, hormones etc. The main objective of the study was to measure prostate gland volume using ultrasound. 60 patients were randomly selected, their age ranged from 18 to 60 years; subjects with any symptoms related to prostate pathologies were excluded. Trans- abdominal ultrasound scanning by 3.5 MHz probes was performed, and the maximum length, width, and depth of the prostate diameters were obtained, as well as the prostate volumes. The data collected by data sheet specifically design for the study and including study variables then analyzed by Statistical Package for Social Sciences (SPSS)

The results of the study revealed that the prostate transverse, AP and longitudinal diameters mean values were (3.66) cm, (2.83) cm, and (3.05) cm respectively, the mean prostate volume obtained from the above parameters was  $16.85 \pm 4.7$ ml. The study also showed that, there was an increase in the prostate volume in relation to increase in the patient's age and weight. Furthermore, the study found out that the prostate volume was affected by the marital status and normal prostate has mid-grey level echogenicity, and homogenous in texture.

The study concluded that prostate volume affected by age, weight and marital status; the study recommended that further studies should be done with larger sampling for more accurate results

## المستخلص

اجريت هذه الدراسة الوصفية اجرية بولاية الخرطوم - السودان بمستشفى بحري وحاج الصافي التعليمي, بالإضافة الي مراكز صحية اخري في الفترة من يوليو الي اكتوبر 2018م. تمثلت مشكلة الدراسة في ان قياس حجم البروستاتا يستخدم كثيرا في تشخيص بعض الامراض وان الحجم يتأثر ذاته بالعمر والوزن والهرمونات. كان الهدف الاساسي من الدراسة قياس حجم غدة البروستاتا باستخدام الموجات فوق الصوتية. 60 مريض اختيروا عشوائيا اعمارهم ما بين 18 الى 60 سنة , أي مريض يعاني من اعراض متعلقة بأمراض البروستاتا تم استبعاده. وتم فحصهم بالموجات فوق الصوتية البطنية باستخدام مسبار 3.5 ميغا هيرتز, تم اخذ الابعاد القياسية (الطول , العرض والعمق ) لغدة البروستاتا وكذلك حجمها. تم جمع البيانات عن طريق ورقة بيانات صممت خصيصا بغرض الدراسة حوت متغيرات الدراسة ثم تم تحليلها بواسطة حزمة التحليل الاحصائي للعلوم الانسانية والاجتماعية .

أظهرت نتائج الدراسة ان متوسط الابعاد لهذه الغده هو للطول 3.05سم و العرض 3.66سم اما العمق 2.83سم , وان متوسط حجم هذه الغده طبقا لهذه الابعاد هو  $4.7 \pm 16.85$  سم مكعب. واثبتت الدراسة كذلك ان حجم غدة البروستاتا يزيد بزيادة العمر والوزن. ايضا اكتشفت الدراسة ان حجم غدة البروستاتا يتأثر بالحالة الاجتماعية للشخص. واثبتت الدراسة ايضا ان غده البروستاتا الطبيعية متجانسه وبدرجة متوسطة الرمادية.

خلصت الدراسة الى ان حجم البروستاتا يتأثر بالعمر والوزن والحالة الاجتماعية واوصت بأجراء دراسات اخرى بحجم عينة اكبر للحصول على نتائج اكثر دقة

## List of contents

<b>Content</b>	<b>Pages No</b>
Qur'an	I
Dedication	II
Acknowledgement	III
Abstract	IV
Abstract (Arabic)	V
List of contents	VI
List of tables	VII
List of figures	VIII
List of abbreviations	IX
<b>Chapter one</b>	
1-1: Introduction	1
1-2: Problem of the study	2
1-3: Objectives	2
1-4: overview of the study	3
<b>Chapter two</b>	
2-1: Prostate anatomy	4
2-1-1: Prostate development	4
2-1-2: Shape and location	4
2-1-3: Structure of prostate	5
2-1-4: Relations of the prostate	6
2-1-5: Prostatic urethra	7
2-1-6: Periurethral glands	8
2-1-7: Verumontanum	8
2-1-8: Seminal vesicles	9
2-1-9: Vas Deferens	10

2-1-10:Ejaculatory Ducts	11
2-1-11: Function of the prostate	11
2-1-12: Blood supply of the prostate	11
2-1-13:Lymphatic drainage of the prostate	12
2-1-14: Nerve supply	12
2-2: Prostate sonogram	13
2-2-1: Normal appearance	13
2-2-2: Ultrasound techniques	14
2-2-2-1: Trans-abdominal approach	14
2-2-2-2: Trans-perineal approach	14
2-2-2-3: Trans-rectal approach	15
2-2-2-4: Trans-urethral approach	15
2-2-3: Ultrasound and prostate biopsy	16
2-3: Previous studies	17
<b>Chapter three</b>	
3-1: Materials	20
3-1-1: Subjects	20
3-1-2: Machines used	20
3-2: Method	21
3-2-1: Technique used	21
3-2-2: Measurements	22
3-2-3: Data collection method	22
3-2-4: Data analysis	23
3-2-5: Data storage	23
3-2-6: Ethical Issues	23
Chapter four (Results)	24
<b>Chapter five</b>	
5-1: Discussion	31



5-2: Conclusion	33
5-3: Recommendations	34
References	35
Appendices	37

## List of tables

Table No	Table title	Page No
4-1	Model correlation test expressing the positive linear relationship between the patient's age and prostate volume:	27
4-2	Model correlation test expressing the positive linear relationship between the patient's weight and prostate volume:	28
4-3	Model expressing descriptive statistics of prostate volume	29
4-4	shows distributions of two groups (Married and Single) with their means and standard deviations calculated	29
4-5	t-test for Equality of Means of two groups	29
4-6	shows the frequency distribution of prostate Texture	30
4-7	shows the frequency distribution of prostate Echogenicity	30

## List of figures

Figure No	Figure title	Page No
2-1	Zonal anatomy of the prostate	7
2-2	Prostate, Seminal vesicles and Verumontanum	9
2-3	Normal prostate sonographic appearance	13
2-4	Diagram showing TAUS technique	14
2-5	Diagram showing TRUS technique	15
2-6	Diagram showing TUUS technique	16
2-7	Trans-rectal biopsy procedure	16
4-1	Bar graph displaying prostate length.	24
4-2	Bar graph displaying prostate width.	25
4-3	Bar graph displaying prostate depth	26
4-4	Scatter plot expressing the linear relationship between patient's ages and prostate volumes.	27
4-5	Scatter plot expressing the linear relationship between patient's weights and prostate volumes.	28

## **List of abbreviations**

AJCC.....	American Joint Committee on Cancer.
AUA.....	American Urological Association.
BPH.....	Benign prostatic hyperplasia.
CP/CPP.....	Chronic prostatitis/ chronic pelvic pain syndrome.
CZ .....	Central zone.
DRE.....	Digital per rectum examination.
EDOs.....	Ejaculatory duct obstructions.
HIV.....	Human immunodeficiency virus.
IPCN.....	International Prostatitis Collaborative Network.
LUTS.....	Lower urinary tract symptoms.
MHz.....	Mega-hertz.
NIDDK.....	National Institute of Diabetes and Digestive and Kidney Diseases.
NIH.....	National Institutes of Health.
NSAIDs.....	Non-steroidal anti-inflammatory drugs.
PSA.....	Prostate specific antigen.
PZ.....	Peripheral zone.
SS.....	Bahri City Khartoum State.
TAUS.....	Tarns-abdominal ultrasound.
TNM.....	Tumor-Node-Metastasis.
TRUS.....	Trans-rectal ultrasound.
TUUS.....	Trans-urethral ultrasound.
TURED.....	Transurethral resection of ejaculatory ducts.
US.....	Ultrasound.

# Chapter One

## Introduction

### 1-1 Introduction:

The prostate is a compound tubule-alveolar exocrine gland of the male reproductive system in most mammals. It differs considerably among species anatomically, chemically, and physiologically (Picut et al., 2018).

In humans the prostate is an unpaired accessory structure of a male reproductive system that surrounds the urethra (prostatic urethra) in the pelvic cavity (Kumar et al., 2005). It's shaped as an upside-down truncated cone with the base of the gland above related to the urinary bladder, and an apex inferiorly and four walls, anterior wall, posterior wall, and two inferiolateral walls (Ryan et al., 2011).

Structure of the prostate is described traditionally as having five lobes anterior, posterior, median, and two lateral lobes. But more usefully the gland is described based on its internal architecture as having three glandular zones (peripheral, central, and transition) with the non-glandular isthmus anteriorly (Ryan et al., 2011).

The normal size of the gland varies according to so many recourses: while it's 20g in young, more than 40g is Benign prostatic hypertrophy (Rumack et al., 2011). Or the mean weight is 11g ranging from (7-16)g. (Stamey et al., 1989). It's in some books up to 25g (Hofer, 1999). More over as the prostate volume is calculated with the "oblate spheroid" formula:  $\text{volume} = 0.5236 \times (W \times AP \times L)$ , where  $W$ ; is the maximal transverse width (right to left),  $AP$ ; is the anteroposterior plane (anterior midline to rectal surface), and  $L$ ; is the length (maximal head to foot) (Rumack et al., 2011).

Again there is also variations in the values of these above mentioned three dimensions; while in some recourses these dimensions were 3.5 x 4.5 x 3.5 (Block and Telger, 2004). Or 4 x 3 x 2 (Sinnatamby, 2011), they were 3 x 3 x 5 in others (Hofer, 1999). Prostate volume can be converted to prostatic weight because the

specific gravity of the prostate tissue is about 1, thus 1cc (1ml) is equivalent to 1gm(Rumack et al., 2011).

Estimation of prostatic gland size can be carried out clinically by doing digital per-rectal examination (DRE), or by trans-rectal US (TRUS), both of which are harmful techniques, and many patients get embarrassed from it, and may refuse them, moreover trans-urethral US (TUUS) is a useful technique but it's invasive and not widely used. So this study will help to respect trans-abdominal US (TAUS) as more practical, more acceptable and accurate technique. As well as it will help to put a reference values for normal dimensions and volumes of the prostate in Bahri City Khartoum State.

### **1-2 Problem of the study:**

The prostate volume measurement is frequently used to diagnose the abnormalities of the gland. But, as mentioned earlier in this chapter the normal size of the gland itself might reveal variations in overlap regions, in addition to that the gland volume is affected by so many factors (age, weight, hormones etc...). Therefore estimation of prostate size based on patient's characteristic should be studied. Also there is no reference value for prostate volume in Bahri City Khartoum State.

### **1-3 Objectives:**

#### **1-3-1 General Objective:**

Measurement of Prostatic Gland Size Using Ultrasound

#### **1-3-2 Specific Objectives:**

1. To establish standard measurements of the prostate gland in normal adults
2. To identify the relation between the prostate size and individual's age.
3. To correlate measurements of the gland to the weight of the patient.
4. To identify texture and echo-pattern of normal prostate size.
5. To correlate between marital status and volume .

## **1-4 Overview of the study:**

This study is concerned with the normal measures of the prostate gland by using trans-abdominal ultrasound, accordingly it falls into five chapters: chapter one is an introduction which includes: brief anatomy, the problem, the objectives of study and the overview. Chapter two includes: detailed background about the anatomy, and sonogram of the gland as well as the literature review. Chapter three deals with the materials and method used to conduct this study. Chapter four illustrates the results using figures and tables. And finally chapter five presents discussion, conclusion, and recommendations of the study followed by references and appendices.

## **Chapter Two**

### **Literature review previous studies**

#### **2-1 Literature review :**

##### **2-1-1 Prostate development:**

The prostate gland develops as (30-40) individual complex glands, which grow from the urethral epithelium into the surrounding wall of the urethra. Collectively, these glands enlarge the wall of the urethra into what known as the prostate (Kumar et al., 2005).

The pelvic part of the endodermic urogenital sinus gives rise to lateral epithelial buds which become the prostatic acini of the peripheral zone. Dorsal out growths from above the level of entry of the meso nephric ducts from the acini of the central zone. The fibro muscular stroma develops from the surrounding mesenchyme (Sinnatamby, 2011).

##### **2-1-2 Shape and location:**

The prostate is a fibro-muscular gland shaped like an upside-down pyramid, which surrounds the prostatic urethra, extending from the urinary bladder base to the urogenital diaphragm(Butler et al., 1999).

The base of the gland is related to the urinary bladder above, an apex inferiorly sitting on the pelvic (urogenital diaphragm), an anterior wall which is separated from the pubic symphysis by the retro-pubic fatty space (of Retzius), a posterior wall related to the rectum, and two infero lateral walls related to the muscles of the pelvic side wall and the anterior part of the levator ani muscles on either side(Ryan et al., 2011).

##### **2-1-3 Structure of prostate:**

According to traditional anatomy, the gland is described as having the following five lobes which are not well demarcated from one another: a muscular anterior lobe (or isthmus) which is anterior to the urethra and is composed mainly of fibro-muscular fibers, and contains little if any glandular tissue, a posterior lobe which



is posterior to the urethra and inferior to the insertion of the ejaculatory ducts, a median lobe between the urethra and the ejaculatory ducts, and two lateral lobes, which form the bulk of the gland. The five lobes can only be differentiated in the fetus up to twenty weeks gestation, in mature gland only three lobes- two lateral lobes and one median- can be distinguished, with the fibro-muscular stroma anteriorly. These lobes can be palpated from the rectum by doing digital per rectum examination (Ryan et al., 2011).

The prostate may more usefully be described based on its internal architecture as having three glandular zones(Fig.2-1) with the non-glandular isthmus anteriorly (Ryan et al., 2011) so as the following: the central zone comprises approximately 25% of glandular tissue, resistant to diseases, and it's a midline wedge at the base of the prostate between the peripheral and transitional zones, the peripheral zone comprises approximately 70% of glandular tissue, surrounds the distal urethral segment, separated from the central zone by the surgical capsule, occupies the posterior, lateral, and apical regions of the prostate and its site for most prostatic cancers, and finally the transitional zone comprises 5% of the glandular tissue and periurethral glands, consists of two small glandular areas adjacent to the proximal urethral sphincter, bound caudally by the verumontanum, separated laterally and posteriorly from the outer glands by the surgical capsule, and it's an area where benign prostatic hypertrophy (BPH) originates (Ovel, 2014).

Histologically, the prostate is a compound tubuloalveolar organ, which, in one plane of section, presents small to fairly large glandular spaces lined by epithelium. Characteristically, the glands are lined by two layers of cells: a basal layer of low cuboidal epithelium covered by a layer of columnar secretory cells. In many areas, there are small papillary inbuddings of the epithelium. These glands all have a distinct basement membrane and are separated by an abundant fibromuscular stroma(Kumar et al., 2005).

The prostate is contained within a sheath or false capsule derived from pelvic fascia. This sheath is composed of smooth muscle, skeletal muscle, and loose connective tissue, penetrated by numerous vessels and nerves(Ryan et al., 2011).

#### **2-1-4 Relations of the prostate:**

**Superiorly:** The base of the prostate is continuous with the neck of the bladder, the smooth muscle passing without interruption from one organ to the other. The urethra enters the center of the base of the prostate (Snell, 1995).

**Inferiorly:** The apex of the prostate lies on the upper surface of the urogenital diaphragm. The urethra leaves the prostate just above the apex on the anterior surface(Snell, 1995).

**Anteriorly:** The prostate is related to the symphysis pubis, separated from it by the extra peritoneal fat in the retro pubic space (cave of Retzius). The prostate is connected to the posterior aspect of the pubic bones by the fascial puboprostatic ligaments (Snell, 1995).

**Posteriorly:** The prostate is closely related to the anterior surface of the rectal ampulla and is separated from it by the recto vesical septum (fascia of Denonvilliers). This septum is formed in fetal life by the fusion of the walls of the lower end of the recto vesical pouch of peritoneum, which originally extended down to the perineal body(Snell, 1995).

**Laterally:** The prostate is embraced by the anterior fibers of the levator ani as they run posteriorly from the pubis(Snell, 1995) .

#### **2-1-5 Prostatic urethra:**

The prostatic urethra is about 1.25 inches (3cm) long and begins at the neck of the bladder. It passes through the prostate from the base to the apex, where it becomes continuous with the membranous part of the urethra. On its posterior wall is a longitudinal ridge called the urethral crest, on each side of these ridges is a groove called the prostatic sinus, the prostatic glands open into these grooves. On the summit of urethral crest is a depression, the prostatic utricle, which is an

analog of the uterus and vagina in females. On the edge of the mouth of the utricle are the openings of the two ejaculatory ducts (Snell, 1995).

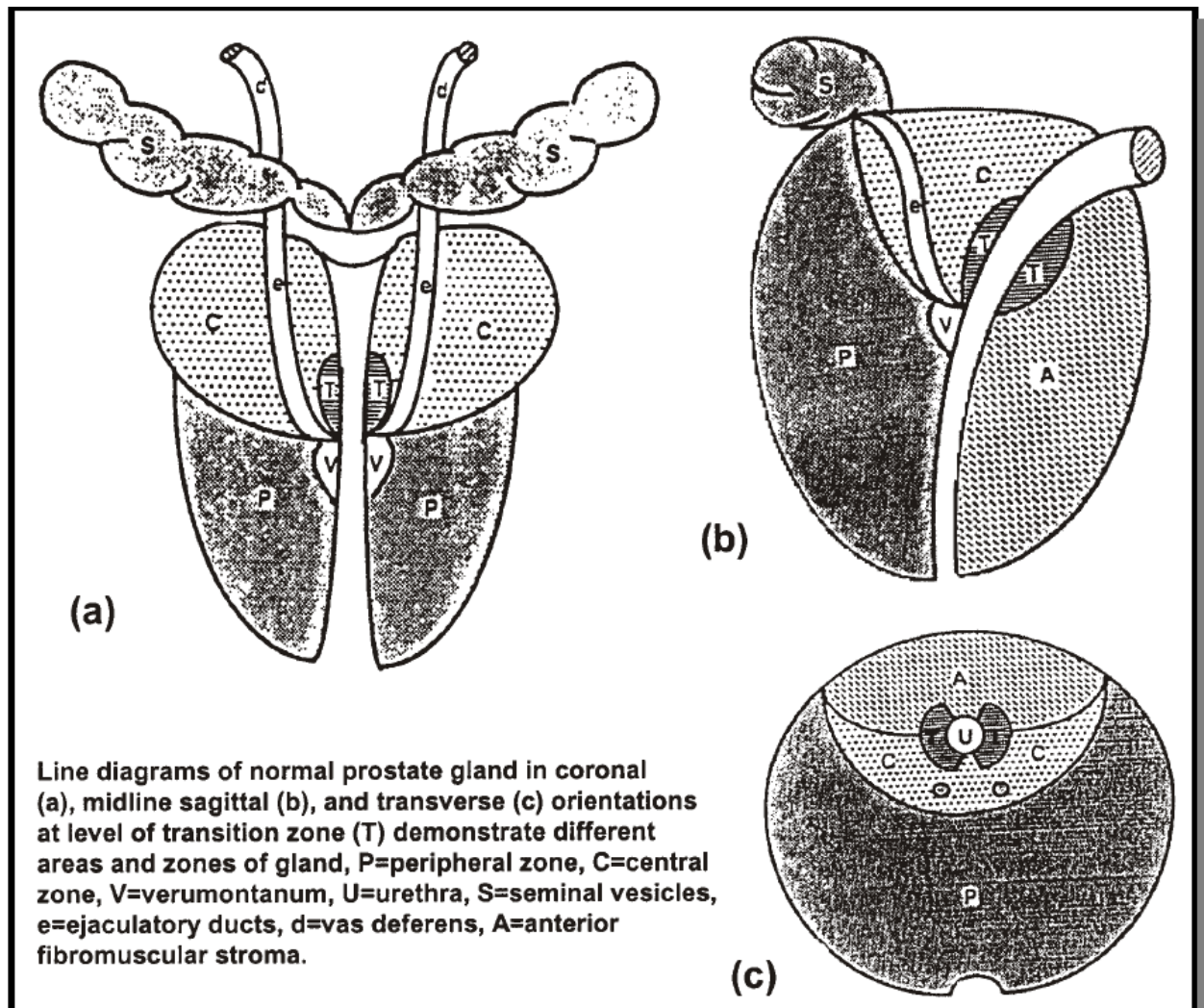


Figure (2-1): shows zonal anatomy of the prostate (Dean, 2005)

### 2-1-6 Periurethral glands:

The urethral or per urethral glands are glands that branch off the wall of the urethra of male mammals. The glands secrete mucus and are most numerous in the section of the urethra that runs through the penis. Urethral glands produce a colloid secretion containing glycosaminoglycans; this secretion protects the epithelium against urine. Untreated urethritis can lead to infection of the urethral glands, which can in turn result in impeding urethral strictures (Fahmy, 2017).

Comprise 1% of glandular tissue, also it's the tissue that lines the prostatic urethra (Ovel, 2014).

### **2-1-7 Verumontanum:**

It's the region where the ejaculatory ducts enter the urethra (Fig. 2-2), and divides the urethra into proximal and distal segments (Ovel, 2014).

The seminal colliculus, or verumontanum, of the prostatic urethra is a landmark near the entrance of the ejaculatory ducts (on both sides, corresponding vas deferens and seminal vesicle feed into corresponding ejaculatory duct). Verumontanum is translated from Latin to mean 'mountain ridge', a reference to the distinctive median elevation of urothelium that characterizes the landmark on magnified views. Embryologically, it is derived from the uterovaginal primordium. The landmark is important in classification of several urethral developmental disorders. The margins of seminal colliculus are the following:

1. The orifices of the prostatic utricle
2. The slit-like openings of the ejaculatory ducts.
3. The openings of the prostatic ducts (Shaw et al., 2011).

### **2-1-8 Seminal vesicles:**

These are paired anatomical structures (Fig. 2-2), lying superior to the prostate, posterior to the bladder, and lateral to the vas deferens. Ducts of the seminal vesicles enter the central zone of the prostate. It stores sperms, and joins the vas deferens to form the ejaculatory ducts (Ovel, 2014).

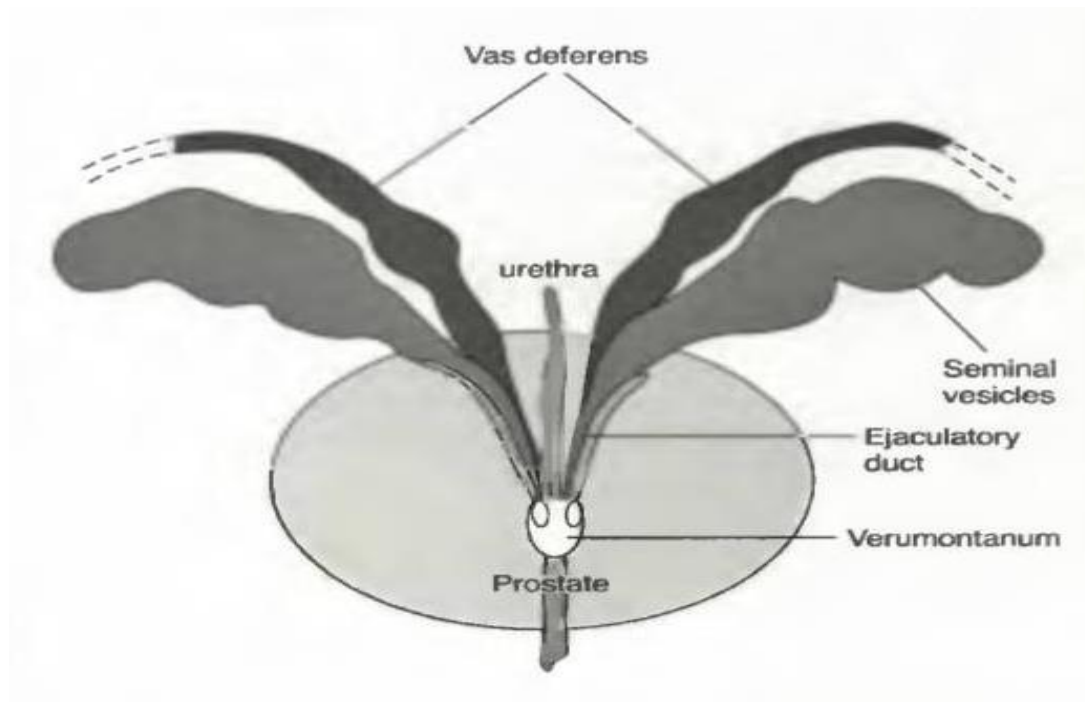


Figure (2-2): shows the seminal vesicles and vas deferens both end into ejaculatory duct that ends in Verumontanum (Sanders and Winter, 2007).

### **2-1-8-1 Blood Supply:**

#### **Arteries**

The inferior vesicle and middle rectal arteries (Snell, 1995).

#### **Veins**

The veins drain into the internal iliac veins(Snell, 1995).

### **2-1-8-2 Lymph Drainage:**

The internal iliac nodes(Snell, 1995).

### **2-1-8-3 Seminal vesicles Function:**

The function of the seminal vesicles is to produce a secretion that is added to the seminal fluid. The secretions nourish the spermatozoa. During ejaculation, the seminal vesicles contract and expel their contents into the ejaculatory ducts, thus washing the spermatozoa out of the urethra(Snell, 1995).

### **2-1-9 Vas Deferens:**

The vas deferens is a thick-walled tube about 18 in. (45 cm) long that conveys mature sperm from the epididymis to the ejaculatory duct and the urethra. It arises

from the lower end or tail of the epididymis and passes through the inguinal canal. It emerges from the deep inguinal ring and passes around the lateral margin of the inferior epigastric artery . It then passes downward and backward on the lateral wall of the pelvis and crosses the ureter in the region of the ischial spine. The vas deferens then runs medially and downward on the posterior surface of the bladder. The terminal part of the vasdeferens is dilated to form the ampulla of the vas deferens. The inferior end of the ampulla narrows down and joins the duct of the seminal vesicle to form the ejaculatory duct(Snell, 1995).

### **2-1-10Ejaculatory Ducts:**

The two ejaculatory ducts are each <1 in. (2.5 cm) long and are formed by the union of the vas deferens and the duct of the seminal vesicle . The ejaculatory ducts pierce the posterior surface of the prostate and open into the prostatic part of the urethra, close to the margins of the prostatic utricle; their function is to drain the seminal fluid into the prostatic urethra (Snell, 1995).

### **2-1-11Function of the prostate:**

The function of the prostate is the production of a thin, milky fluid containing citric acid and acid phosphatase. The smooth muscle in the capsule and stroma contract, and the secretion from the many glands is squeezed into the prostatic urethra. The prostatic secretion is alkaline and helps to neutralize the acidity in the vagina (Snell, 1995).

Moreover the prostatic secretion constitutes between 13% and 30% of the volume of semen (Penny, 2011).

### **2-1-12Blood supply of the prostate:**

In males, both the prostate and seminal vesicles are supplied with blood by the inferior vesical artery. It is comparable to the vaginal artery in females. The two are considered to be homologous, which means that they have the same basic structure and are likely closely related in terms of how they evolved. According to some research articles and medical texts, the inferior vesical artery is found in

both males and females, making the inferior vesical artery an artery that branches off the vaginal artery in women(Merland and Chiras, 2012).

This artery may have a common trunk with the superior gluteal and internal pudendal, or can branch off from the internal pudendal. This varies from person to person, and usually occurs as only one additional branch (Merland and Chiras, 2012).

The inferior vesical artery also supplies the ductus deferens, which is a section of the passage through which sperm travel in the male reproductive system (Merland and Chiras, 2012).

### **2-1-12-1 Prostatic vesical arteries:**

Arise from the internal iliac arteries. Branches include the prostatic and inferior vesical arteries(Ovel, 2014).

### **2-1-12-2 Capsular arteries:**

They supplies two third of the blood going into the prostate(Ovel, 2014).

### **2-1-12-3 Urethral artery:**

They supplies one third of the blood going into the prostate(Ovel, 2014).

### **2-1-12-4 Venous drainage:**

Via the periprostatic plexus to the internal iliac veins and also to the vertebral venous plexus (prostatic cancer spread to the vertebrae) (Butler et al., 1999).The veins form the prostatic venous plexus, which lies outside the capsule of the prostate. The prostatic plexus receives the deep dorsal vein of the penis and numerous vesical veins and drains into the internal iliac veins(Snell, 1995).

### **2-1-13Lymphatic drainage of the prostate:**

The lymphatic drainage is to the internal iliac, and obturator lymph nodes(Butler et al., 1999).

The lymphatic drainage of the prostate primarily drains to the obturator and the internal iliac lymphatic channels. There is also lymphatic communication with the external iliac, presacral, and the para-aortic lymph nodes (Mattei et al., 2008).

### **2-1-14 Nerve supply:**

The nerve supply of the prostate is from parasympathetic nerve fibers from pelvic splanchnic nerves (S2-S4) (Ryan et al., 2011).

### **2-1-15 Prostate sonogram:**

Now a day's prostate sonography is a frequently used imaging modality to detect its abnormalities. From this point of view here is some information about the normal appearance, different sonographic techniques, in addition to prostate biopsy.

#### **2-1-15-1 Normal appearance:**

In relation to the normal sonographic appearance the prostate gland has a homogeneous structure demonstrating a median-level echo pattern (Fig. 2-3). The peripheral zone (PZ) appears uniform in texture and slightly more echo-genic than the central zone (CZ). A hyper-echoic band (surgical capsule) separates the PZ from CZ. The seminal vesicles appear as hypo-echoic structures superior to the prostate gland. The verumontanum appears hyper-echoic compared with the parenchyma(Ovel, 2014).

Patients may have benign calcification and simple-appearing cysts within the prostate as well (Penny, 2011).



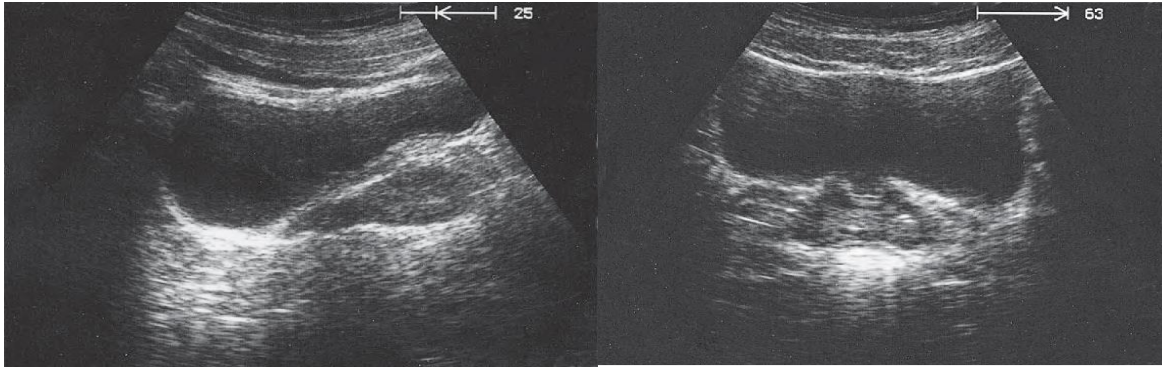


Figure (2-3): TAUS, longitudinal plane (left), and transverse plane (right), shows; normal prostate sonographic appearance (Block and Telger, 2004).

### **2-1-15-2 Ultrasound techniques:**

#### **2-1-15-3 Trans-abdominal approach:**

Done by using a 3.5 to 5-MHz transducers and a full bladder, the prostate may be identified by angling slightly inferior. Longitudinal and transverse images and measurements may be obtained; however a thorough evaluation of the prostate tissue is not possible. This approach allows post-void residual within the bladder to be determined by the equation (length x width x height x 0.523) (Sanders and Winter, 2007) .

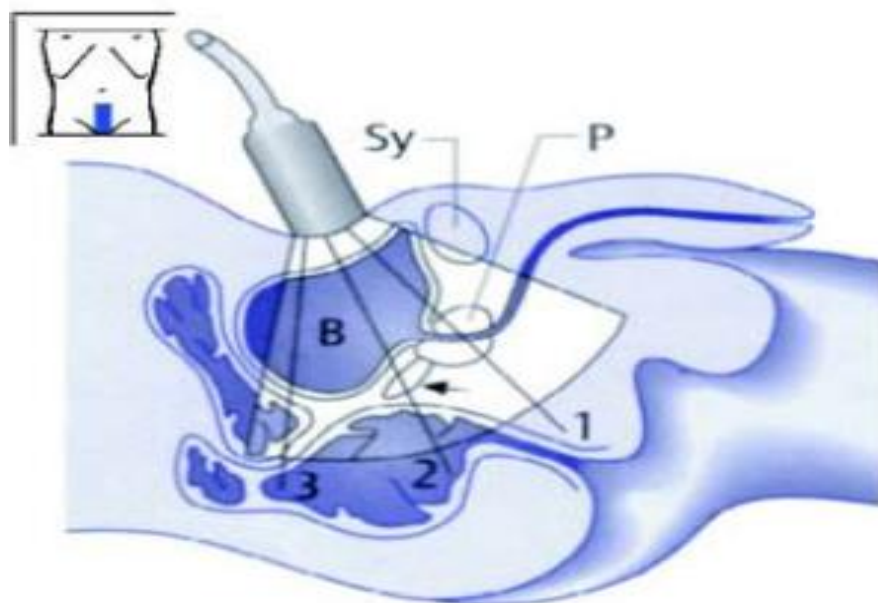


Figure (2-4): Diagram showing TAUS technique (Block, 2004).

#### **2-1-15-4 Trans-perineal approach:**

A perineal approach can be used scanning between the legs posterior to the scrotum, but this is not an ideal way to evaluate the prostate by US. Both transverse and longitudinal images can be obtained and the prostate volume can be calculated; however internal architecture may not be well appreciated. This approach can be used for biopsy if the patient has surgically removed rectum (Sanders and Winter, 2007) .

#### **2-1-15-5 Trans-rectal approach:**

The most accepted scanning approach when evaluating the prostate. It's done by using 5-9MHz endocavitary transducers. It's convenient, not invasive, and good image quality. Preparation; needed adequate defecation, bladder filling with up to 100cc , condom or protective sheath, careful probe water filling, and the patient should be placed in a left lateral decubitus position with the knees bent (Sanders and Winter, 2007) .

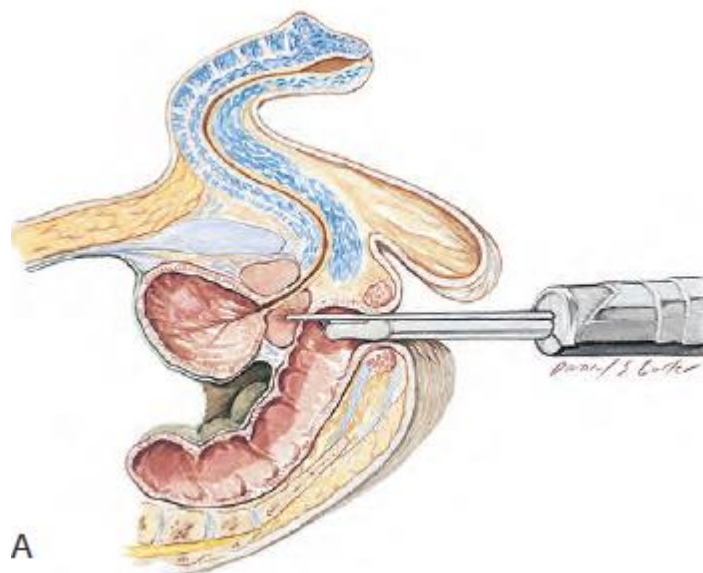


Figure (2-5): Diagram showing TRUS technique (Rumack et al., 2011).

#### **2-1-15-6 Trans-urethral approach:**

Require local anesthesia for intra-urethral insertion with rotation. There is good visualization of capsule and intra-capsular spreading tumor. Not appropriate

method because of no delineation of periurethral region and more or less invasive(Lee et al., 2011).

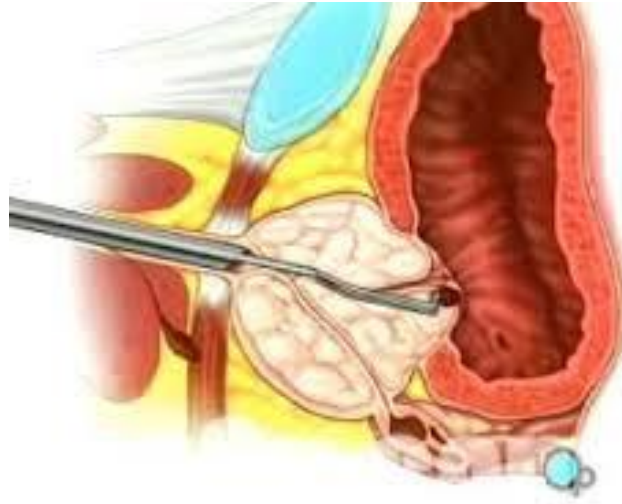

Figure (2-6): Diagram showing TUUS technique (Lee et al., 2011).

### **2-1-15-7 Ultrasound and prostate biopsy:**

Prostate biopsy is taking a sample from the gland to be sent for histopathological study to find out the definite diagnosis. Two methods of prostate biopsy may be used: trans-rectal and trans-perineal. The trans-rectal approach (Fig. 2-4) is more common and less painful but carries a greater risk of infection. The trans-perineal approach is generally only used if the rectum is absent e.g., surgically removed (Sanders and Winter, 2007) .

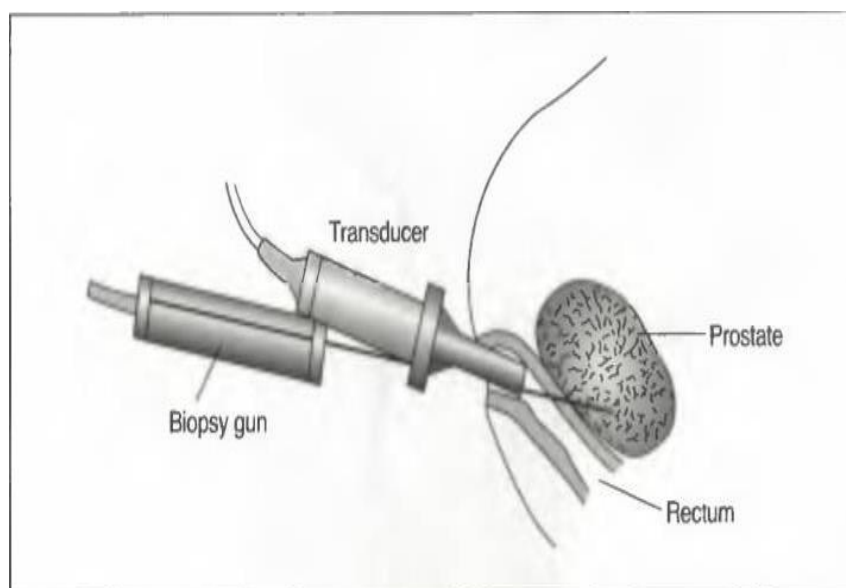


Figure (2-7): shows trans-rectal biopsy procedure(Sanders and Winter, 2007).

After either procedure, blood pressure and pulse are taken because hemorrhage is a possible complication. Infection on a delayed basis may occur after a trans-rectal biopsy, but is uncommon. It is expected that blood may be seen within the stool, urine, or sperm after the procedure, for up to 24 hours. Severe bleeding is extremely rare (Sanders and Winter, 2007) .

## **2-2 previous studies:**

One study was carried out to determine the range of volumes of the prostate gland in adult Sudanese males in our local environment using trans-abdominal ultrasound, and to provide acceptable range of normal prostate gland volumes. A randomly selected fifty asymptomatic adult males were recruited and measurements of the maximum length, depth and width of their prostate gland were obtained and the volumes were calculated. The results of this thesis were stated as follow: a transverse, AP and longitudinal diameters mean values were (2.68) cm, (3.56) cm, and (3.02) cm respectively, the mean prostate volume obtained from the above parameters was 15.24ml. Also the findings show that prostate volume increases linearly with body weight and age(Abdallah, 2015).

Also there was another thesis which was conducted to measure the normal prostate among Sudanese patients above fifty years old by using trans-abdominal ultrasound. The study was carried out in three hospitals: Bahri hospital, Police hospital, and Alzaiem Alazhari ultrasound clinic, at duration from (June, 2010 – to march, 2011). The study includes 100 cases aged from (50-to 89) years, with different complains. The results of this study shows that the accuracy of ultrasound in prostate measurements and diagnoses is up to 95%, and it's improved due to the use of more effective machines with better resolution. Also the study reveals that a well preparation is a significant factor to obtain good results, and that the ultrasound findings are critically depends on the examiner training and experience. Moreover, the results stated that there is significant proportional relation between patient's age and prostate size, and that there is an

inverse relation between the patient's height and the size of the prostate (Adam, 2010).

Moreover, a thesis which was also carried out in order to assess prostate volume measurement using trans-abdominal ultrasound scanning. In this study, 10 subjects from age of 20 years old to 25 years old were selected to undergo trans-abdominal scans. The subjects were randomly selected with different heights and weights. The subjects were the students whom do not have any bad habits like smoking and drinking. The subject's weights, and heights were measured and their body mass indexes were calculated, as well as their prostate volumes. The results of this thesis conclude that ultrasound is an easy and save way to measure the prostate size. In addition to that the results stated that there is an increase in the prostate volume by increasing the weight, or height of the patient. Moreover for the same height increment, the prostate volume was controlled by the weight of the subjects. And finally as this thesis concentrates on body mass indexes, the results find out that the volume of the prostate increases in relation to increase in body size (Hoo et al., 2012).

Also another study was carried out to determine the range of volumes of the prostate gland in adult North Kurdfan State males using trans-abdominal ultrasound, and to provide acceptable range of normal prostate gland volumes. A randomly selected 92 asymptomatic adult males were recruited and measurements of the maximum depth, height and width of their prostate gland were obtained and the volumes were calculated. The results of this thesis states that the prostate transverse, AP and longitudinal diameters mean values were (3.53) cm, (2.73) cm, and (2.98) cm respectively, the mean prostate volume obtained from the above parameters was  $15.27 \pm 4.7$  ml. The study also concludes that, there is an increase in the prostate volume in relation to increase in the patient's age, weight, and body mass indices by 0.09 ml/year, 0.11 ml/kg, and 0.3 ml/kg/m<sup>2</sup> respectively. Moreover the study reveals that the normal prostate has mid-grey level echogenicity, and homogeneous in texture (Fudal, 2016).

## **Chapter Three**

### **Materials and Method**

#### **3-1 Materials:**

##### **3-1-1 Subjects:**

This is a descriptive cross sectional study, carried out in order to state the normal measurements of prostate gland in Bahri City Khartoum State. It was carried out in Bahri and HajElasafi teaching hospitals, in addition to other Health Centers. This study was conducted in duration from July – to October 2018. The population of this study was an adult patient whom referred for abdominal Ultrasound scans in Bahri City Khartoum State , who were not suffering from any symptoms related to prostate diseases. The sample size of this study was consisted of 60 cases, and they were randomly selected. Any adult patient from (SS), who referred for abdominal US scans during the duration of the study (July- to October, 2018) was included. Patients who were not resident in (SS), pediatric age groups, patients who find to have prostatic diseases symptoms, or who are known cases, or detected to have prostatic pathology during US scan, and patients refused to be a candidate of study were all excluded from this study.

##### **3-1-2 Machines used:**

Ultrasound machines: Mindray DP50 made in china , KAIXIN 2600 made in china , Mindray DP10 made in china, all of which has major machine two probes, with full US department facilities, and coupling jell. Also we use a personal computer, Sony, Satellite, core I5, made in china, 2012. Moreover measurement equipment for the patient's weights were used.

#### **3-2 Methods:**

##### **3-2-1 Technique used:**

The study conducted by (TAUS) through the following steps: The patients needed optimal bladder filling if not, more than 40 ounces taken by the patient, note that

over distended bladder can push the pelvic organs out of view, so you may need to request the patient to void partially (Gilani, 2002).

The patient put supine in position, with the legs extended; no breathing technique is recommended (breathing gently) (Gilani, 2002).

Begin with the transducer perpendicular at the body, just superior to the symphysis pubis and angle inferiorly. The prostate is visualized here. Once the long axis of the prostate is located, angle the transducer inferiorly to scan apex of the prostate until come beyond it. Return to midline just superior to symphysis, with the transducer angled inferiorly-less than before- to locate the long axis of the prostate. When locating the long axis of the prostate, slowly move the transducer towards the patient's right, scan laterally through the prostate until you are just beyond it, going on with the right lateral scan through the pelvic side wall. Return to the midline superior to symphysis with inferior transducer angulations; locate the long axis of prostate. When locating the long axis of the prostate, slowly move the transducer towards the patient's left, scan laterally through the prostate until you are just beyond it. Continue to scan left lateral through the pelvic side wall until beyond it (Gilani, 2002).

Still in sagittal plane, locate the long axis of the prostate; rotate the transducer 90 degree into the transverse seaming plane. Begin with the transducer angle inferiorly, at the midline of the body, just superior to the symphysis pubis. Angle the transducer back into the pelvis; look first for the apex of the prostate. Then scan superiorly through the prostate until you are beyond the base of it (Gilani, 2002).

### **3-2-1-1 Measurements:**

The prostate width and depth were taken in a transverse plane, by measuring the maximum right to left diameter and the maximum antero-posterior diameter respectively, while the prostate length is from a sagittal one, by taking the maximum cranio-caudal diameter. The volume of prostate is calculated by the US machine automatically after measuring the above mentioned three dimensions. The prostate echogenicity and texture were observed all through the scan.

### **3-2-2 Data collection method:**

The data of this thesis was collected by using special data collection sheet, which contains ten variables, divided into two parts personal data, and sonographic findings. These data were collected in the following ways

The personal data consists of four variables: patient's index, age, weight, and marital status. The patient's age and marital status were picked up from the patient by direct questions to him (after taking permission). After completing the scan the patient is sent to a nurse so as to complete the other variable which is the weight. The nurse does this by using equipment that measures the weight automatically when the patient stands on it.

The sonographic finding data includes six variables which are: the length, width, depth, volume, echogenicity, and texture of the prostate gland. These variables are taken also by the sinologist from the US machine while they were doing the scan, also after the patient has been informed and agree of it.

### **3-2-3 Data analysis:**

The data was analyzed using Statistical Packaged for Social Studies (SPSS) version 20. Using frequency tables and bar graphs to inter present the variables used in the data collected. Alsoa correlation tests and scatterplots to find out the definite relationships between the prostate volumes and the other variables under study.

### **3-2-4 Data storage:**

Data was stored in personal computer, and data sheets were kept safely and responsibly.

### **3-2-5 Ethical Issues:**

Verbal permissions were taken from the patients before doing scans, and they were informed about the study, and accept it. Also the patients get sure that their details will not be exposed. Before that verbal permissions were also taken from the head mangers of the hospitals, and health centers where the study is conducted.



## Chapter Four

### Results

#### 4-1 Results:

About 60 cases having neither complain nor was pathology related to prostate selected for this study. The results of this study are presented into tables and figures below.

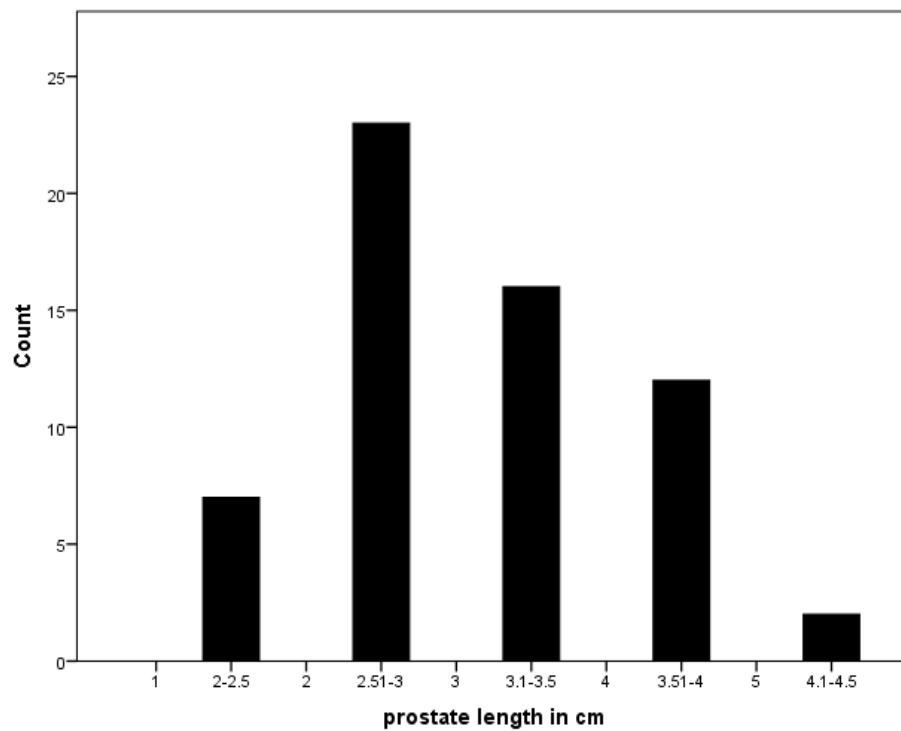


Figure (4-1): shows bar graph displaying frequency distribution of prostate length.

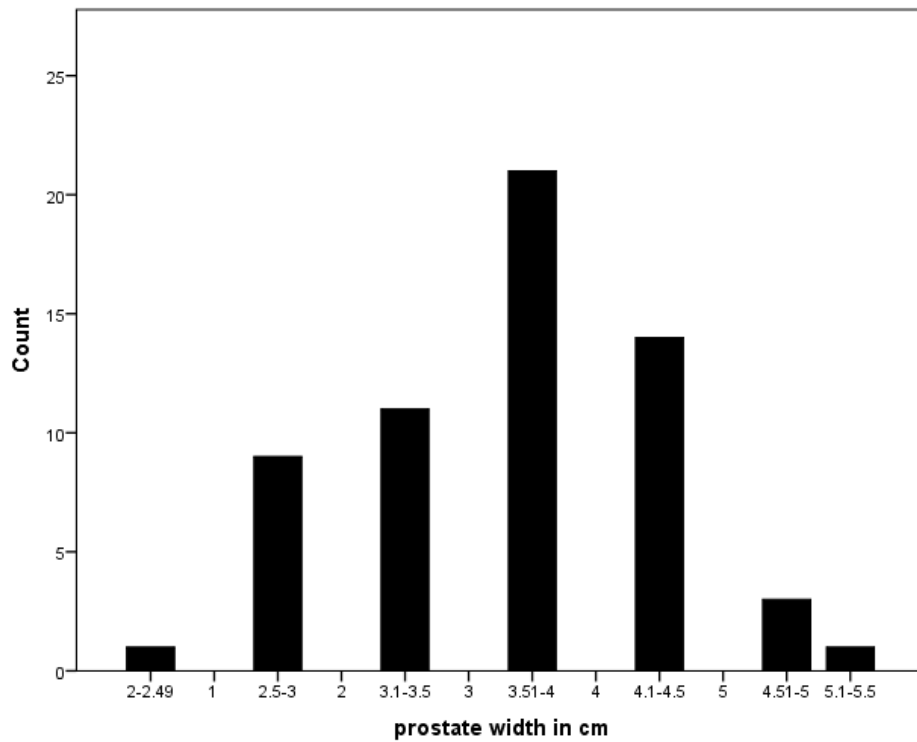


Figure (4-2): shows bar graph displaying frequency distribution of prostate width.

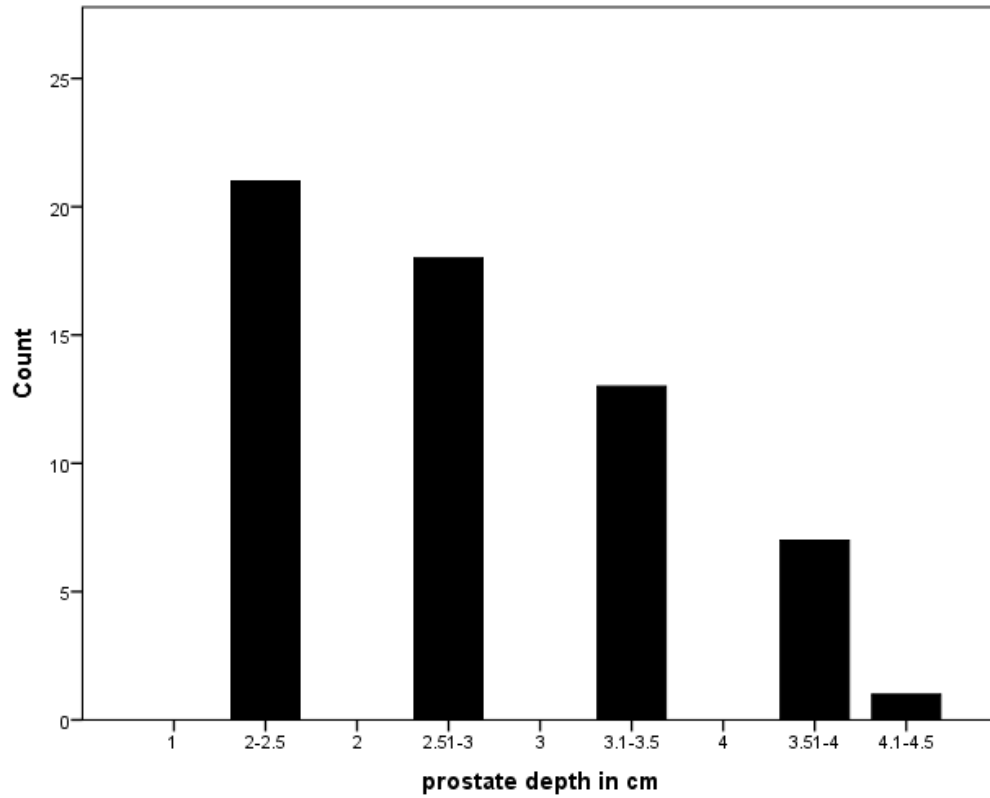


Figure (4-3): shows bar graph displaying frequency distribution of prostate depth.

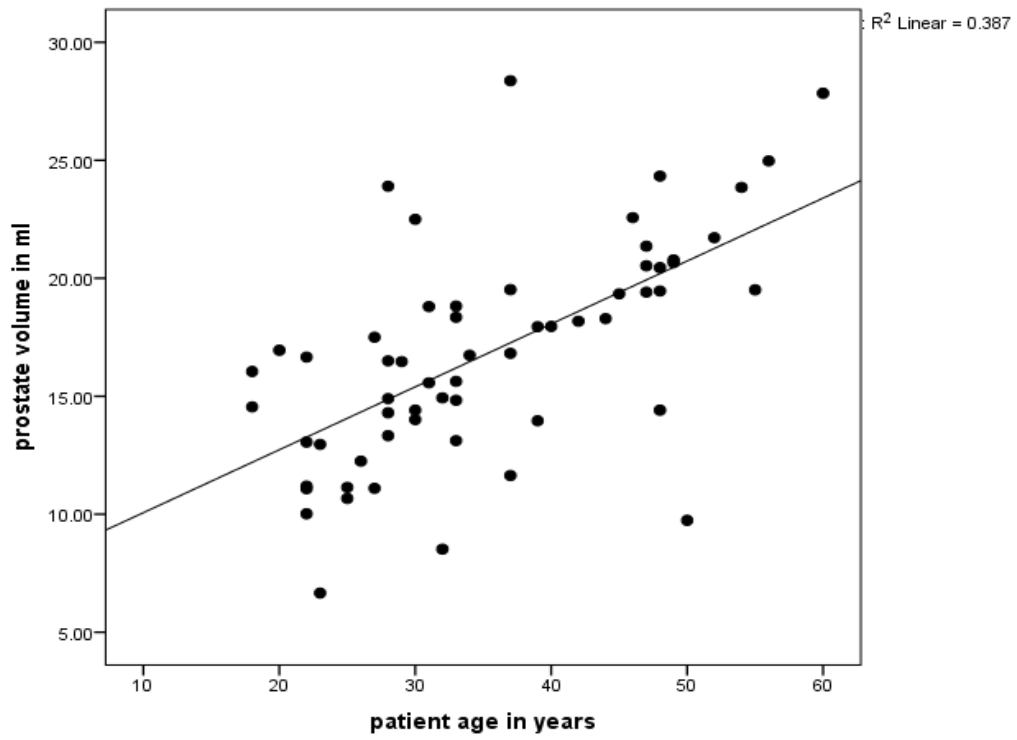


Figure (4-4): scatter plot shows the linear relationship between patient's age and prostate volumes.

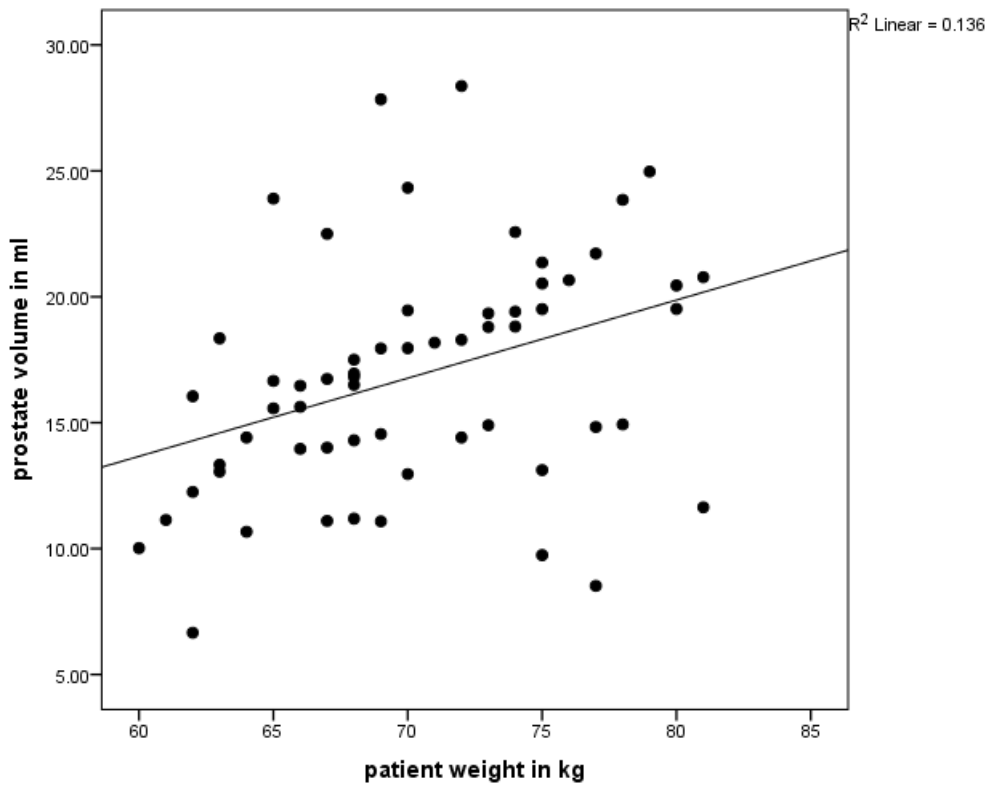


Figure (4-5): scatter plot shows the linear relationship between patient's weight and prostate volumes.

Table (4-1) Model correlation test expressing the positive linear relationship between the patient's age and prostate volume:

		Patient age in years	Prostate volume in ml
Patient age in years	Pearson Correlation	1	.622
	Sig. (2-tailed)		.000
	N	60	60

Correlation is significant at about 0.01

Table (4-2) Model correlation test expressing the positive linear relationship between the patient's weight and prostate volume:

		prostate volume in ml	patient weight in kg
prostate volume in ml	Pearson Correlation	1	.369
	Sig. (2-tailed)		.004
	N	60	60

Table (4-3) described statistics of prostate volume

	N	Range	Minimum	Maximum	Mean	Std. Deviation
Prostate volume/ml	60	21.71	6.66	28.37	16.8515	4.67439

Table (4-4): A) shows distributions of two groups (Married and Single) with their means and standard deviations calculated:

	marital status	N	Mean	Std. Deviation	Std. Error Mean
prostate volume in ml	No	20	14.0420	3.87429	.86632
	Yes	40	18.2563	4.43516	.70126

Table (4-4): B) t-test for Equality of Means of two groups:

	t-test for Equality of Means						
	T	Df	Sig.(2-tailed)	Mean Difference	Std.Error Difference	95% Confidence Interval of the Difference	
						Lower	Upper
Prostate volume	-3.6	58	.001	-4.2	1.17	-6.5	-1.9

Table (4-5): shows the frequency distribution of prostate Texture:

		Frequency	Percent	Valid Percent	Cumulative Percent
Valid	Homogenous	59	98.3	98.3	98.3
	Heterogenous	1	1.7	1.7	100.0
	Total	60	100.0	100.0	

Table (4-6): shows the frequency distribution of prostate Echogenicity:

		Frequency	Percent	Valid Percent	Cumulative Percent
Valid	mid grey	60	100.0	100.0	100.0



## Chapter Five

### Discussion, conclusion, and recommendations

#### 5-1 Discussion:

The results of this study showed that the prostate length, width and depth diameters were measured and displayed in Fig. (4-1,4-2and4-3), and their mean values were (3.05) cm, (3.66) cm, and (2.83) cm respectively, the mean prostate volume obtained from the above parameters was  $16.85 \pm 4.7$ ml this mean ranges from (6.6 to 28.3) ml table (4-1).These results was in line with (Fudal, 2016).

Also the results confirmed that there is positive linear relationship between the age of patients and their prostate volumes fig. (4-1) ( $R^2 = 0.387$ ), that's to say when patient's age increases the prostate volume also increases, see table (4-1).This positive relationship is expected because aging is main risk for prostate enlargement BPH as mentioned. And this result agrees with (Abdallah, 2015).

Moreover there is also another positive linear relationship between the prostate volume and patient's weight Fig. (4-5) ( $R^2 = 0.136$ ), that's to say an increase in body weight there should be an increase in prostate volume, see table (4-2).This positive relationship is also expected because an increase in patient weight increases fats concentration in the body, which was the main source of steroid hormones that influence the growth of the prostate gland. Also this result agrees with (Abdallah, 2015).

Relating to the effect of marital status on the prostate volume, we find that see table (4-4), the married patients were 40 persons, and the single ones were 20 persons, and that the mean prostate volumes for both were  $18.25 \pm 4.43$ , and  $14.04 \pm 3.87$  respectively. And that the difference in means between them is 4.21. We use T-test to test the difference in means between these two mean groups and the results tell us that there is significant difference because the values in the "Sig. (2-tailed)" Colum see table (4-5) is 0.001 which is less than 0.05. So, we can

conclude that marital status has effect in the prostate volume among this population.

Studying the echogenicity and texture of the prostate gland the results reveals that, table (4-6) shows the texture of the prostate and that 59 patients have homogenous texture, and 1 patient have heterogeneous texture. And Table (4-7) shows the echogenicity of the prostate and that all patients have normal echoes. So we can state that from the results the normal prostate sonographic appearance is mid-grey level echo's (100%), and at the same time homogenous texture (98.3%). And this result agrees with (Fudal, 2016).

## **5-2 Conclusion:**

The results of this Thesis states that the prostate length, width and depth diameters mean values were (3.05) cm, (3.66) cm, and (2.83) cm respectively, the mean prostate volume obtained from the above parameters was  $16.85 \pm 4.7$  ml. The study also concludes that, there was linear increase in the prostate volume in relation to increase in the patient's age and weight. Also, the study found out that the prostate volume was affected by the marital status of the patients among these populations. Moreover the normal prostate volume has mid-grey level echogenicity (100%), and homogenous in texture (98.3 %).

### **5-3 Recommendations:**

1. Trans-abdominal ultrasound is a respectful approach, and should be used confidently in the measurements and evaluation of the prostate gland size and pathologies among Sudanese.
2. In order to improve the image quality, the patients should be well prepared, and the ultrasound machines should be well adjusted to have better resolution.
3. There is another factors that might affect the prostate volume were not included here such as the ethnic group, hormones levels, personal habits e.g., alcohol, and coffee intake, environmental factors . There for other researches were recommended to cover these factors.
4. Also I think that we are in need for assessing the normal prostate measurements in the other different states in our country. So as to have our own local values, hence we are here in Sudan have different environments and very vary habits.
5. I notice that some sonologists measure the all three parameters of the prostate (transverse, AP, and length) from one plane, which may produces un accurate volume. Therefore it's better to follow standard protocols to improve our techniques.

## References:

- ABDALLAH, Y. H. Y. 2015. *Measurement of Normal Prostate Volume in Healthy Adult Sudanese Using Ultrasound*. Sudan University of Science and Technology.
- ADAM, A. M. M. 2010. *Trans Abdominal Sonographic Measurement of Normal Prostate Among Sudanese Male Above Fifty Year Old*. Alzaeim Alazhari University.
- BLOCK, B. 2004. *The Practice of Ultrasound*, Thieme Stuttgart.
- BLOCK, B. & TELGER, T. C. 2004. *Color atlas of ultrasound anatomy*, Thieme Stuttgart.
- BUTLER, P., MITCHELL, A. W. & ELLIS, H. 1999. *Applied radiological anatomy*, Cambridge University Press.
- DEAN, D. 2005. Abdominal Ultrasound and instrumentation. *The burwin institute of diagnostic medical ultrasound Lunenburg, Canada*, 13.16.
- FAHMY, M. 2017. *Urethral Cyst. Congenital Anomalies of the Penis*. Springer.
- FUDAL, I. M. N. 2016. *Measurement of Prostatic Gland Size in North Kurdfan State Using Ultrasound*. Sudan University of Science and Technology.
- GILANI, S. A. 2002. Guidelines and protocols for medical diagnostic ultrasound. *Burwin institute of ultrasound, Canada-Asian& middle east branch, Lahore*.
- HOFER, M. 1999. *Ultrasound Teaching Manual Hofer, Matthias*. Thieme.
- HOO, K., AYOB, M. A., MOHAMAD SALIM, M., ABDULJABBAR, H. N. & SUPRIYANTO, E. 2012. Prostat volume measurement using transabdominal ultrasound scanning. *Internat J Biol Biomed Engineering*, 4, 187-95.
- KUMAR, V., ABBAS, A. K., FAUSTO, N. & ASTER, J. C. 2005. *Robbins and Cotran pathologic basis of disease*. 7 th ed.: Philadelphia: Elsevier Saunders.
- LEE, Y. T., RYU, Y. W., LEE, D. M., PARK, S. W., YUM, S. H. & HAN, J. H. 2011. Comparative Analysis of the Efficacy and Safety of Conventional Transurethral Resection of the Prostate, Transurethral Resection of the Prostate in Saline (TURIS), and TURIS-Plasma Vaporization for the Treatment of Benign Prostatic Hyperplasia: A Pilot Stu. *Korean journal of urology*, 52, 763-768.
- MATTEI, A., FUECHSEL, F. G., DHAR, N. B., WARNCKE, S. H., THALMANN, G. N., KRAUSE, T. & STUDER, U. E. 2008. The template of the primary lymphatic landing sites of the prostate should be revisited: results of a multimodality mapping study. *European urology*, 53, 118-125.
- MERLAND, J.-J. & CHIRAS, J. 2012. *Arteriography of the pelvis: Diagnostic and therapeutic procedures*, Springer Science & Business Media.
- OVEL, S. 2014. *Sonography Exam Review: Physics, Abdomen, Obstetrics and Gynecology-E-Book*, Elsevier Health Sciences.
- PENNY, S. M. 2011. *Examination Review for Ultrasound: Abdomen & Obstetrics and Gynecology*, Lippincott Williams & Wilkins.
- PICUT, C. A., ZIEJEWSKI, M. K. & STANISLAUS, D. 2018. Comparative Aspects of Pre-and Postnatal Development of the Male Reproductive System. *Birth defects research*, 110, 190-227.
- RUMACK, C. M., WILSON, S. R., CHARBONEAU, J. W. & LEVINE, D. 2011. *Diagnostic ultrasound*, Elsevier/Mosby.
- RYAN, S., MCNICHOLAS, M. & EUSTACE, S. J. 2011. *Anatomy for Diagnostic Imaging E-Book*, Elsevier Health Sciences.
- SANDERS, R. C. & WINTER, T. C. 2007. *Clinical sonography: a practical guide*, Lippincott Williams & Wilkins.
- SHAW, A., SMITH, B. & HOWLETT, D. C. 2011. *FRCR Part 1 Anatomy Mock Examinations*, Cambridge University Press.
- SINNATAMBY, C. S. 2011. *Last's Anatomy e-Book: Regional and Applied*, Elsevier Health Sciences.
- SNELL, R. S. 1995. *Clinical anatomy for medical students*, Little, Brown Medical Division.
- STAMEY, T. A., KABALIN, J. N., MCNEAL, J. E., JOHNSTONE, I. M., FREIHA, F., REDWINE, E. A. & YANG, N. 1989. Prostate specific antigen in the diagnosis and treatment of adenocarcinoma of the prostate. II. Radical prostatectomy treated patients. *The Journal of urology*, 141, 1076-1083.

