

**Sudan University of Science and Technology**  
**College of Animal Production Science and Technology**  
**Department of Fisheries and Wildlife Science**

Recovery of internal parasitic ova from captive

Lion (*panthera leo*) in kuku Zoo Khartoum State.

التعرف علي الطفيليات الداخليه للاسد في حديقة حيوان كوكو بولاية الخرطوم

Dissertation submitted in partial fulfillment for the requirement of B.Sc{Hon} in  
Fisheries and Wildlife Science

By:

SHIMA ALFATEH YOUSEF

SAYDA MUHANNAD MAMOUN

SUPERVISOR:

Prof: ALI SAAD MOHAMMED

October 2018

بسم الله الرحمن الرحيم

(وقل ربي زدني علما)

صدق الله العظيم

سوره طه (114)

# DEDICATION

THE PRESENT STUDY IS DEDICATED

TO OUR PARENTS AND OUR COLLEAGUES

TO ANY PERSON WHO HELPED US DURING OUR STUDY

TO ALL STAFF OF FISHERIES AND WILDLIFE SCIENCE

## ACKNOWLEDGEMENT

First of all we thank Allah who gave us will and patience to complete this work. We are grateful to the supervisor Prof .Ali Saad Mohammed .alot of thanks to the staff members of the Department of Fisheries and wildlife Science.

## ABSTRACT

Apreliminary surveillancce was conducted for investigation of internal parasites of the lion( *panthera leo*). The methods used were direct smear and floatation tests of the faecal material of the lion

Both methods revealed that the order of parasitic prevalence was:*coccidia sp*(50% ); *Echinococcus sp*( 30% ) ;*Parascaris sp*(20%).

There was an adult parasite recoverd ( *Ascaris sp*)in number of (4),and *seudoparasites* plant hairs(3)

### **key words**

lion, parasitic ova ,intensity of parasitism ,Kuku Zoo.

المستخلص:

اجري مسح لطفيليات الاسد بحديقته حيوان كوكو استخدمت طريقتا المسح والطفو لبراز الاسد بالحديقته .  
اظهرت النتائج بالنسبه للطريقتين تقاربا كانت الطفيليات التي ظهرت بالمستويات التاليه : كوكسيديا(50%)  
, اكاينوكوكس (30%) , براسكارس ( 20%).

قد ظهرت دودة الاسكارس في عينه لبراز الاسد بحديقته حيوان كوكو وتمت رؤيتها بالعين المجرده . كما  
ظهرت احدى الطفيليات الكازبه تعرف بلانت هير(3)

يوصى ان تضاف اكلات اللحوم الاخرى والعواشب الموجوده بحديقته كوكو لمعامله مماثله للكشف عن  
طفيلياتها.

## Table of contents

Subject	Page
Privation	I
Dedication	II
Acknowledgement	III
Abstract in English	IV
Abstract in Arbaic	V
Table of Contents	VI
List of tables	VII
List of Plates	VIII
Chapter One	
Introduction	1
Chapter two	
Literature Review	2
Chapter Three	
Materials And Methods	5
Chapter Four	
Results	7
Chapter Five	
Discussion	9
Chapter Six	
Conclusion	11
Recommendation	12
References	14

## List of tables

Name of table	page
Table1 :Helminth parasitic ova recoverd in direct smear method	7
Table2:Helminth parasitic ova recovered in floatation method	8
Table3:Total number of ova recovered as %for the two method	8



## List of plates

NO:	Name of plate	page
1	Coccidia sp	<b>16</b>
2	Echinococcus	<b>16</b>
3	Ascaris worm	<b>17</b>
4	<b>Parascaris</b>	<b>9</b>
<b>5</b>	<b>Plante hairs</b>	<b>10</b>

# CHAPTER ONE

## Introduction

Captive animals kept in Kuku Zoo, need to be subjected to investigation of external as well as internal parasitic infestation. The lion is one of the captive animals kept in Kuku Zoo. It should be a routine procedure to identify helminthes infestation in zoo animals for the sake of animal health (Soulsby, 1982). The results of testing animals for internal parasites would help in improving their health by treatment (Soulsby, 1982). The present study is an attempt to recover ova of internal parasites of the (*Panthera leo*) (lion) from their feces by direct smear and floatation tests (Soulsby, 1982).

The objectives of the study were :

- 1\ To isolate and identify the parasitic eggs from the shape of of the eggs using reference catalogue
- 2\ To determine the efficiency of each method used .
- 3\ To determine which parasite has the highest prevalence

## CHAPTER TWO

### LITERATURE REVIEW:

The lion ( *Panthera leo*) is a species in the family felidae , it is a muscular ,deep ,chested cat with a short , rounded head , a reduced neck and round ears and a hairy tuft at the end of it is tail. The lion kept in Kuku Zoo are one male and two females , the male is larger than females with a rang of 150-250 kg body weight.

The body is covered with a sand brown coat in most sub species of lion . The lion has powerful legs , strong jaw and long canine teeth.

#### Classification:

Kingdom : Animalia

Phylum: chordata

Sub phylum: vertebrata

Class: mammalia

Order: carnivora

Family: felidae

Genus: *panthera*

Species:*Panthera leo*

Repopulation of endangered species and conservation of wild animals in wildlife parks and zoological gardens are management strategies (Ajibade *et al*, (2010)

Parasites can affect animals by reducing the population size ,especially under nutritional stresses.

They can also evict host behaviors to combact the parasites. Parasitic diseases form a major challenge to wild animal in captivity.( Adedokun *et al.*,( 2002),Emikape *et al.*,(2002).Singl *et al.*,(2006). Emikape *et al.*,(2007).

In the natural habitat animals might have a natural resistance to parasites or live mutually with them . Porkovkona,(2005).It was reported by (Singal *et al* (2006)and Goosensa *et al.*,(2005).That change in envirnoment and living condition from free ranging to captivity influences the animals ecology and might increase susceptibiliy to parasitic infection.

Some workers mentioned that many animals in capitive situation are exotic to the geographical location of parks and zoo gardens where they are kept. Mondgil and Singla,(2014),reported that keeping a number of animal species. in close proximity, which would normaly come in contact with such pathogens ,provides an opoprtnunity for the transmission of disease.Sever parasitoses can lead to blood loss ,tissue damag , spontaneous abortion ,congenital malformation and death. (Adedorun *et al.*,(2002).,Emikpe *et al.*, (2002).,(2007).,Despommier,(2003).

Moving animals from one enclosure to another , without proper parasite treatment,is also a means of parasite transmission .Addtional risks of parasite infections are brought by mixing different species of animals .(Goossensa *et al.*,(2005).Zoological garden staff members have also been reported to play an important role in the transmission of parasites

among animals in zoo through their shoes, clothes, hands, feet or with working tools. (Adeturji, (2014), Otgbade and (morenikeji, (2014).

Some of the parasites are zoonotic and pose a serious threat to human health. (Kashid et al., (2003). Carnivorous animals act as definitive hosts for many intestinal parasites, some of which are responsible for several zoonotic diseases such as ancylostomosis, echinococcosis, gnathostomiasis and toxocarosis. (Schantz and Kramer, (1995)., Eslami and Hussein (1998). Overgaauw (1997). Inadequate information on diseases and parasites of zoo animals is a major limiting factor in the management of zoological gardens. Investigation into prevalence, geographical distribution, systematic and biology of parasites of zoo animals are important for planning and control of parasitoses. Hence the need for a regular program of gastrointestinal parasite surveillance and measures of control based on correct diagnosis, effective treatment and proper prophylaxis to ensure sound health of zoo animals. (Abjbad et al., (2010)., Moudgil et al., (2014).

## CHAPTER THREE

### MATERIALS AND METHODS

The research was carried out in Kuku Zoological Garden College of Animal Production Science and Technology, Sudan University of Science and Technology .Kuku Zoo has an area of about 10 acre. In the zoo different animal species are kept in cages .There are also some domestic animals species: camel, horse and sheep. Three lion are kept in cages with diamention of 6X3X3 meter . The floor of the cage was made of mixture of gravel, sand and cement. A small portion of the cage was left for food contianers , and drinking water was provided in cement basin.Inside the cage there were two adult females and one adult male. Fresh faecal samples were collected in duplicates from fresh faecal dropping as follows :-

2 specimens on	8/7/2018
2 specimens on	10/7/2018
2 specimens on	14/7/2018
2 specimens on	18/7/2018
2 specimens on	21/7/2018
2 specimens on	25/7/2018
2 specimens on	30/7/2018
2 specimens on	3/8/2018
2 specimens on	6/8/2018

2 specimens on 8/8/2018

Total 20

Two methods were applied 20 specimens parasitic egg recovery : Direct smear on glass slides covered with silde covers and mounted for detection microscope stage 10x (Soulsby (1982)).

Floataion method by preparing a concentrated saline solution in a test tube to the brim , stirred with glass rod and placing the glass slide on top of the tube for trapping the floating parasite eggs on slide surface.

Identification to the species level was done according to (Soulsby (1982)).Descriptive procedure was adopted in representing results as frequency and percent of total infestation .

## CHAPTER FOUR

### RESULTS

The lion in Kuku Zoo was proved to be infected with four internal parasite sp. (Tables 1,2).The highest prevalence was for Coccidia( 50%) and (50%)of the total egg recovered for direct smear and floatation method respectively,and constituted the highest infestation rate of the total for both method as (50%).Generally the prevalence rate could be arranged in descending order as follows: Coccidia sp,Echinococcus sp, Parascaris sp.

Ascaris worm (4) had seen by naked eye in the faecal sample of lion in Kuku Zoo.Pseudoparasites plant hairs in number( 3)

Table1:Helminth parasitic ova recovered in direct smear method:

Method	Parasite	Frequency	%
	Coccidia	1	50
Direct smear	Echinococcus	1	50
	Parascaris	0	0
Total		2	100%

Table(1):The highest prevalence was for coccidia(50%)of the total eggs recovered for the direct smear,*Echinococcus*(50).



Table2:Helminth parasitic ova recovered in floatation method:

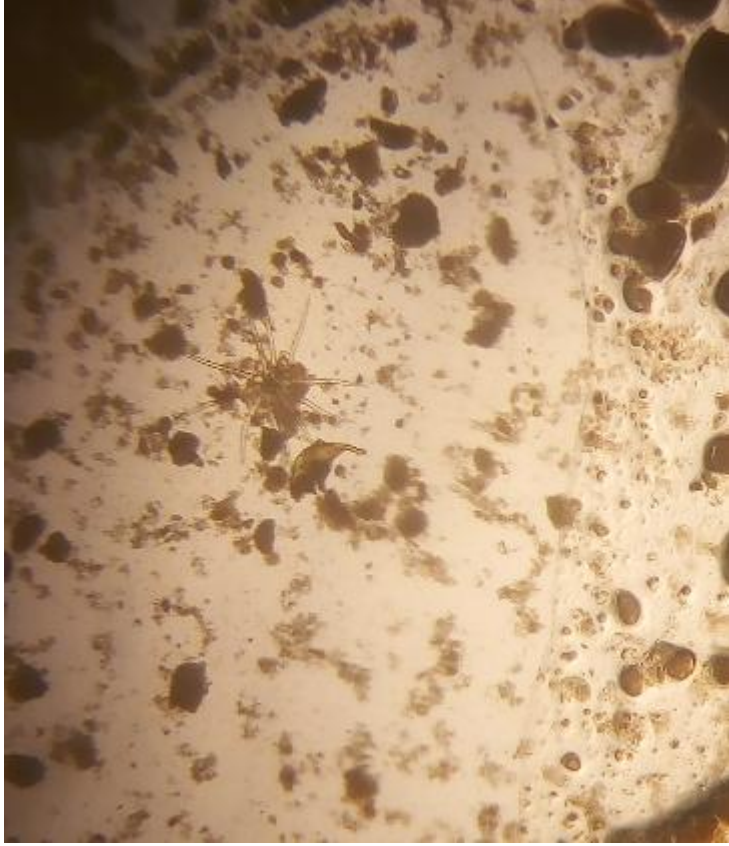
Method	Parasite	Frequency	%
	Coccidia	4	50
Floatation	Echinococcus	2	25
	Parascaris	2	25
Total		8	100%

Table(2):The highest prevalence was for coccidia(50%) of the total eggs recovered for the floatation method,*Echinococcus* (25%) ,*Parascaris* (25%).

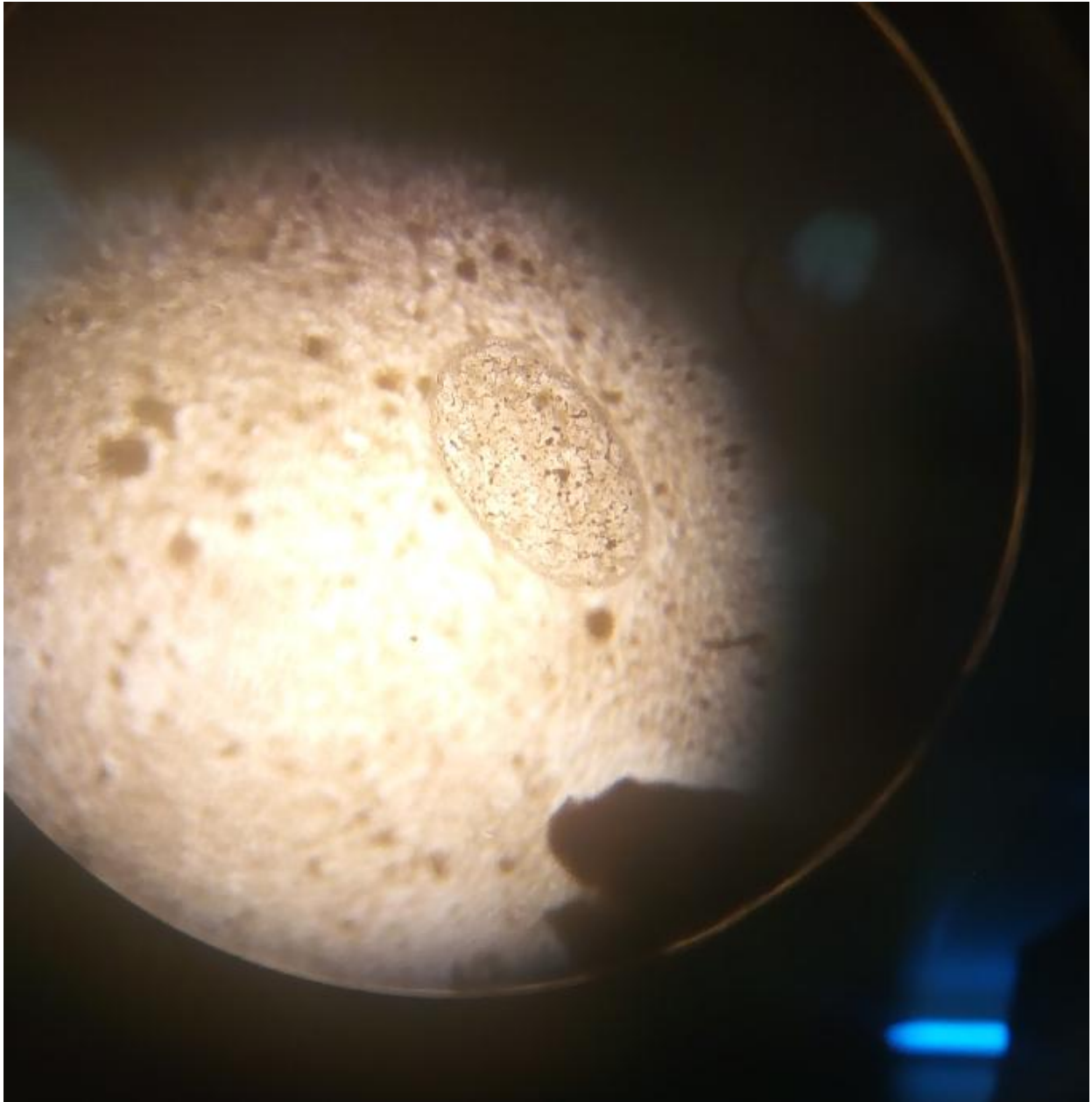
Table3:Total number of ova recovered as % for the two methods:

Parasite	Frequency	%
Coccidia	5	50
Echinococcus	3	30
Parascaris	2	20
Total	10	100%

Table(3) :Both methods revealed that the order of parasitic prevalence was for:coccidia(50%),*Echinococcus sp*(30%) ,*Parascaris sp*(20%).



Plate(5):Plante hairs



**Plate (5):Parascaris**

## CHAPTER FIVE

### DISCUSSION

The present study constituted a preliminary surveillance for prevalence of intestinal parasites in the lion (*Panthera leo*) of Kuku Zoo. The highest prevalence rate was observed for 5 coccidia (*Eimeria*) oocysts, 3 *Echinococcus* parasitic ova and 2 *Parascaris* ova were recovered from the lion faecal material (n=3). Other group notes that, one of cubs (female) suffers from anomaly in motion it might be due to infection by *Echinococcus*, (3) pseudoparasites plant hairs, also we had seen (4) *Ascaris* worm by naked eye in the faecal sample of lion in Kuku Zoo. The faecal floatation method was more efficient than the direct smear. Result of the present study was in agreement with the result of Smith, *et al.* (2006) who found three nematodes and two coccidia from intestines of the lion in Kalahari game reserve in South Namibia. The result of the present study were also, in agreement with other workers in carnivores in tropical countries, Smith, *et al.* (2006). The study constituted a preliminary surveillance for prevalence of intestinal parasites in the pride lion of Africa (*Panthera leo*) was conducted at Intu Africa Kalahari Game Reserve, Southwestern Namibia, during winter and summer of 2003-2004, respectively. The floatation technique was employed, for the diagnosis of parasites was: The highest prevalence rate was observed three nematod and two coccidians Smith y, et al {2006}

The results of the present study agreed with result reported by other workers, of the opinion that parasitic disease are common to zoo carnivores in countries of warm tropical climate due to the factors

that favor the development of parasites such as high temperature, and humidity .Direct smear and floatation methods revealed the recovery of similar species of helminth parasitic ova. These methods were complimentary,therefore the use of both methods was to confirm the results.

The veterinarian in Kuku Zoo said that lion were given many doses of tetramezol an medication against helmenths.

## CHAPTER SIX

### CONCLUSION AND RECOMMENDATIONS

#### 6.1 CONCLUSION

It has been shown that the lion was infected by some internal parasites. The prevalence of helminthic infection in the lion was in the order of coccidia sp . with highest level (50 %) ;followed by *Echinococcus sp*( 30%) and *Parascaris sp* showed the lowest level of prevalence ( 20%) , adult *Ascaris worm*(4) ,*pseudoparasites* plant hairs (3)

The result obtained by either direct smear or floatation method were almost the same.

## **6.2 RECOMMENDATIONS:-**

There are other carnivorous animals species in Kuku Zoo which might be infected with helminthes parasites .It is therefore we recommended that :

1-Surveillance for internal parasites , using the same method, of helminthes ova recovery for the black baked jakel and hyenas to form a complete picture of parasitic infestation in carnivorous.

2-Such faecal examination should be done routinely to make sure of parasitic picture in the carnivoures of Kuku Zoo.

3-The results , which should include the parasites of other captive animal species in the zoo should be reported the veterinary supervisor for treatment.

4-Animal attendants should be advised to follow the hygienic procedures.

5-There is need for routine faecal examination of the lion for both external and internal parasites.

6- The premises as well as the laborers should be clean to lessen the chance for transmitting parasites.

## REFERENCES:

- Smith y,*et al* .onderstepoort .J,Veters.(2006). Feacal helminth egg and oocyst counts of a small population of African lions (*Panthera leo*) in the south western Kalahari Nambia.
- Adedokun OA ,Adedokun RAM,Emikpe BO,Ohore OG,Oluwayelu DO,Ajayi OL (2002).CONCURREN fatal helminthosis and Balantidosis in red monkey (*Erythrocebus*) in Ibadan, Nigeria.Niger .Vet J.23(2):56\_59.
- Adetunji VE (2014). prevelence of gastro- intestnal parasites in primates and their keepers from two zoological gardens in Ibadan , nigeria. tSokoto J.Vet Sci.12(2) : 25-30
- Ajibad WA, Adeyemo OK,Agbede SA [2010]. Coprological survey and Invectory of animals at Obafemi Awolowo University and University of Ibadan zoological gardens. World J.Zool .5 (4) :266-271.
- Borkovcova M, kopriva J(2005) . Parasitichelminthes of Reptiles (Reptilia) , South Moraiva , Czech Republic .Parasitol .Res. 95:77-78.
- Emikpe BO ,Adeniram GA, Alaka,tiveOO, Ohore OG .,Antia RE, Ajayi OL,Omobowale OT(2007).Valvular entocarditis in a cap monkey in Ibadan ,Nigeria :a case report.Niger.Vet. J. 28(3):49-52.
- Emikpe BO ,Adeniram ,Aouade GO,Ohore OG ,Olaniyan OO, Akusu MO(2002). Fatal trichuriasis in a captive baboon ( *Papio anubis*) in Ibadan . Nigeria : A case report . Trop .Vet 20 [1]:36-39.



- Eslami A, Hossini SH (1998). Morphological characteristics of *Echinococcus* of sheep and camel origin in Iran .J.Helminthol.72:337-341.
- Doossensa E,Dornya p Boomker J ,Vercammen F ,Vercruysse T(2005). 12 month survey of the gastro-intestinal helminthes , Parasitol . 127: 303-312.
- Moudgila AD , Singla L D , singh MP (2014) . First report on molecular identification and fenbendazole resistance against Baylisascaris transfuge infection in Melursus *ursinus* (Sloth bear) .Helminthologia , 51-(4) : 262-268.
- Otegbade AC, Morenikeji OA(2014) . Gastrointestinal parasites of birds in zoological gardens in South -west Nigeria . Trop . Biomed .(1) 54-62.
- Overgaauw PA .(1997) . Prevalence of intestinal nematodes of dogs and cats in Ntherlands . Vet Quart. 19[1] : 14-17.
- Schantz PM , Kremer MH (1995) . Larval cestode infections : Cysticereosis and echinococcosis . Curr . Opin . Infect . Dis . 8:342-350.
- Soulsby E.J.L (1982) .Helminthes , arthropodas and protozoa of domesticated animal , 7 edition . Bailliere Tindall , london , UK .

•WWW.flickr.com

