

Sudan University of Science & Technology

College of graduate studies

Measurement of Normal Brainstem Diameter in
Sudanese Population using MRI

قياس ابعاد جذع الدماغ عند السوداني يابا ستخدام الرنين المغنطيسي

*A thesis submitted in partial fulfillment of the Requirement of the M.Sc Degree in
Diagnostic Radiologic Technology*

By

Rahig Ahmed Abd ElsalamElameen

Supervisor:

Dr. Caroline EdwardAyad

Associate Professor

2016

الاية

بسم الله الرحمن الرحيم

" قالوا سبحانك لا علم لنا الا ما علمتنا انك انت العليم الحكيم "

صدق الله العظيم

سورة البقره

الايه (32)

DEDICATION

To

My Mother

*A strong and gentle soul who taught me to trust in Allah,
believe in hard work and that so much could be done with*

little

My Father

*For living an honest living for us and for supporting and
encouraging me to believe in myself.*

My friends

For encouraging me to do the best in my life .

Acknowledgement

First of all ,I thank Allah the Almighty for helping me complete this research .

*I sincerely thank **Dr. Caroline Edward Ayad**,my supervisor for her continuous*

help,supervision and guidance.

Also I would like to thank the staff of NationalAlRebat hospital and Alyaa specialized

hospital For good contact ,relation and for helping me in collecting data .

Finally I would like to thank everyone who has participated in the completion of this

study.

Abstract

The brainstem is so important structure that contains many centers which control some vital processes like cardiac rhythm, sleep cycle and respiratory procedure .Also ten of the cranial nerve originate from the brainstem .

The main objective of the study to determine normal brainstem AP diameters in Sudanese population. In addition to correlate the findings with age and gender .We examined 50 subjects aged between 16-81 years in both gender(28 males and 22 females) were included in the study, all were diagnosed as normal brain MRI when the measurement was done .

MRI sagittal T1 weighted image were obtained, measurements taken For Pons, midbrain and medulla oblongata. All measurement taken in mm. Correlation between brainstem parts measurement with age were studied.

The study showed that the measurements of the brainstem structure were found to be at similar range comparing with other population. MRI had great value in the accurate measurements.

The study concluded that all the values have linear relationship with age, and no association between gender and brainstem measurement.

The study recommended that further study should be done with larger sample of population for more accurate result, volumetric measurement may give more information than linear measurement and further study should be done with more body characteristic.

List of Contents

Topics	Page
الايه	I
Dedication	II
Acknowledgment	III
Abstract(English)	IV
Abstract(Arabic)	V
List of figures	VI
List of tables	VII
Abbreviation	VIII
List of contents	X
CHAPTER ONE: Introduction	
1-1 Introduction	1
1-2 Problem of the study	2
1-3 Objectives	2
1-4 Scope of the study	3
CHAPTER TWO: Literature review	
2-1 Skull anatomy	4
2-2 Brain anatomy	5
2-3 Physiology	25
2-4 Pathology	26
2-5 MRI of the head	27
2-6 Previous study	34
CHAPTER THREE: Material and method	35
3-1 Material	35
3-2Method	36

CHAPTER FOUR :Result	
Result	38
CHAPTER FIVE: Discussion, Conclusion, Recommendation	
5-1 Discussion	41
5-2 Conclusion	43
5-3 Recommendation	44
REFERENCES	45
APPENDIX	46

List of tables

No	Table	page
2.1	Show brainstem syndrome	26
4.1	The sample according to Gender .	37
4.2	The sample according to age.	37
4.3	The mean , standard deviation,minimum and maximum of the sample variables.	38

List of figures

No	Figure	Page
2.1	Lateral view of skull	5
2.2	Brain lobes	8
2.3	Basal ganglia	10
2.4	Major white matter tracts within the tegmentum tract at the level of the inferior colliculus	19
2.5	Midbrain anatomy	20
2.6	Ventral view of brain stem	23
2.7	Dorsal view of brain stem	23
2.8	Lateral view of brain stem	24
2.9	Sagittal SE T1 weighted midline slice of the brain	30
2.10	Axial /oblique FSE T2 weighted image of the brain	31
3.1	Sagittal T1 weighting image of the brain in the midsagittal plane show the measurement of the brainstem	36
4.1	A scatter plot diagram shows the correlation between the sample age and midbrain in sagittal T1	38
4.2	A scatter plot diagram shows the correlation between the sample age and pons in sagittal T1	39
4.3	A scatter plot diagram shows the correlation between the sample age and medulla in sagittal T1	39
A	Sagittal T1 weighting image of the brain show the measurement of mid brain, Pons and medulla oblongata In the midsagittal plane .	46

Abbreviation

ACR	American college of radiology
AP	Antero posterior
CM	Centimeter
CN	Cranial nerve
CSF	Cerebrospinal fluid
CT	Computed tomography
F	Female
FLAIR	Fluid attenuated inversion recovery
FMRI	Functional magnetic resonance imaging
FOV	Field of view
FSE	Fast spin echo
M	Male
mm	Millimeter
MRA	Magnetic resonance angiography
MRI	Magnetic resonance imaging
PD	Proton density
PPN	Pednculo-pontine nucleus
RF	Radio-frequency
Sag	Sagittal
STD	Standered deviation
T	Time

Chapter One

Introduction

1.1 Introduction:

The brainstem is relatively small mass of tissue packed with motor and sensory nuclei, making it vital for normal brain function. Ten of the 12 cranial nerves originate from nuclei located in the brain stem. It is a major segment in the midbrain, pons, and medulla oblongata. Located in the central portion of the brainstem and common to all three segments is the tegmentum, an area that provides integrative functions such as complex motor patterns, aspects of respiratory and cardiovascular activity, and regulation of consciousness. The central core of the tegmentum contains reticular formation, an area containing the cranial nerve nuclei and ascending and descending tracts to and from the brain, the brain stem as a whole acts as a conduit between the cerebral cortex, cerebellum and spinal cord [Lorrie et al, 1997]

Magnetic resonance imaging (MRI) studies, predominant shrinkage was observed in the posterior vermis, the hemispheres also showed shrinkage with age. In contrast, brainstem volume does not decline with age. Only for the midbrain region have some studies reported volume loss. Regional volume loss does not only occur in physiological aging. Various hereditary and non-hereditary disorders produce distinct patterns of atrophy in cerebellum and brain stem. Precise quantification of brain volume using modern imaging techniques may reveal patterns of volume loss with specificity for certain conditions related to age or disease. These patterns may be used for differential diagnosis. The adult midsagittal diameter of the mesencephalon was reached at the age of 6 years, and decreased slightly after 45-50 years. Pontine diameter increases until the age of 20 years and did not subsequently decrease. The midsagittal and mid coronal diameters of the medulla oblongata stopped increasing at the age of 6

and 8 years respectively .number of different imaging modes can be used with imaging the brainstem; sagittal T1 and axial T2 weighting image used to measure the brainstem. T1; CSF is dark, T1 useful for visualizing anatomy .T2; CSF is bright but fat is darker than with T1. T2 is useful for visualizing pathology. PD; CSF has relatively high level of protons, making CSF appear bright. Gray matter is bright than white matter. FLAIR; useful for evaluation of white matter plaques near the ventricles it is useful in identifying demyelination (Raininko et al ,1993]

1.2 Problem of the study:

Knowledge of normal variation in size of the brainstem can be helpful in the investigation of neurodegenerative diseases.

1.3 Objective of the study:

1-3-1 General objective:

Purpose of this study is to determine brainstem AP diameter in normal Sudanese population.

1-3-2 Specific objective:

- To measure the brainstem in sagittal view.
- To correlate the measurement with patient age and gender.

1.4 The scope of the study:

This study consist of five chapters; chapter one; general introduction, which consist of an introduction, and methodology of research. chapter two; include literatures review which consists of anatomy of the skull ,anatomy of the brainstem ,general physiology of the brainstem, some pathology of the brainstem and previous

studies. Chapter three; detailed the materials and methods. Then chapter four; presents the results and chapter five presents the discussion conclusion and recommendations. Also there are the references and the appendix at the end of the study.

Chapter two

Literature Review

2.1 Skull anatomy:

The skull is the most modified part of the axial skeleton, it rest on the upper end of the vertebral column and its bony structure is divided into two parts:

2.1.1 Cranium:

The cranium is formed by a number of flat irregular bones that provide a bony protection for the brain.

It has a base upon which the brain rests and vault that surround and cover it. The periosteal inside the skull bones consist of the outer layer of Dura mater. In the mature skull the joints (sutures) between the bones are immovable (fibrous), the bones have numerous perforations through which nerves, blood and lymph vessels pass. (Lorrie et al ,1997).

2.1.2 The bones of the cranium :

1 frontal bone, 2 parietal bones, 2 temporal bones, 1 occipital bone, 1 sphenoid bone and 1 ethmoidbone.

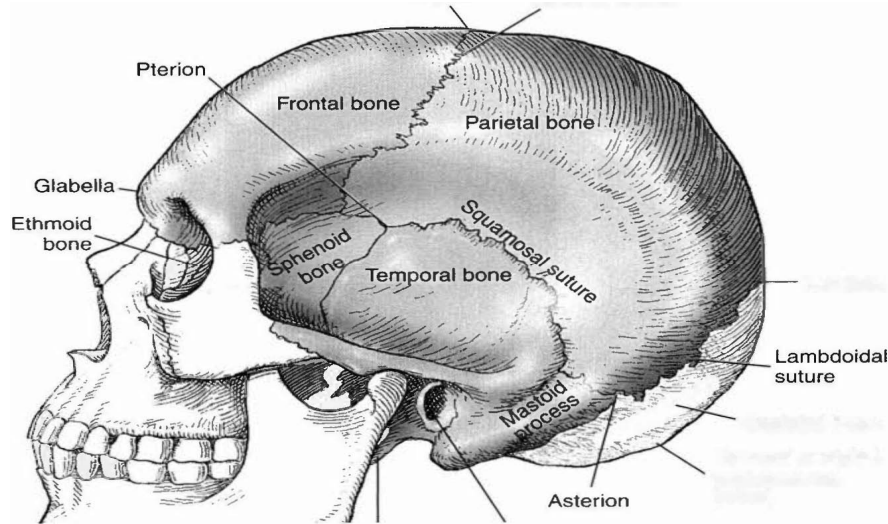


Figure (2-1): Show lateral view of skull. (Lorrie et al, 1997).

2.2 Brain anatomy:

The brain constitutes about one-fiftieth of the body weight and lies within the cranial cavity.

The brain consists of three main parts:

Cerebrum or forebrain, Cerebellum or hindbrain and Brainstem.

2.2.1 Cerebrum:

The cerebrum is the largest portion of the brain and is divided into left and right cerebral hemispheres. Each hemisphere contains neural tissue arranged in numerous folds called gyri. (Lorrie et al, 1997).

The gyri are separated by shallow grooves called sulci and by deeper grooves called fissures. The main sulcus that can be identified on CT and magnetic resonance (MR) images of the brain is the central sulcus, which divides the precentralgyrus of the

frontal lobe and postcentralgyrus of the parietal lobe. These gyri are important to identify because the precentralgyrus is considered the motor strip of the brain. Other gyri important for imaging include the cingulate, parahippocampal, and auditory (transvers gyri of Hesch). The two main fissures of the cerebrum are the longitudinal fissure and the lateral fissure (Sylvain fissure) (Lorrie et al, 1997).

The longitudinal fissure is along, deep furrow that divides the left and right cerebral hemispheres. Located in this fissure is the flax cerebri and superior sagittal sinus. The lateral fissure is a deep furrow that separated the frontal and parietal lobes from the temporal lobe, (Lorrie et al, 1997).

2.2.2 Cerebral Lobes :

The cerebral cortex of each hemisphere can be divided into four individual lobes: frontal, parietal, occipital, and temporal. These four lobes correspond in location to the cranial bones with the same name. Each lobe has critical regions, which are associated with specific functions.

The frontal lobe is the most anterior lone of the brain. The boundaries of the frontal lobe are the cenral sulcus, which separates it from the parietal lobe, and the lateral fissure, which separates it from the temporal lobe. The frontal lobe mediates a wide variety of functions such as reasoning, judgment, emotional response, planning and execution of complex actions, and control of voluntary muscle movement. The frontal lobe is also involved with the production of speech and contains the motor speech (language) center, Broca's area. Broca's area lies unilaterally on the inferior surface of the frontal lobe dominant for language, typically in the frontal gyrus.

This area is involved in the coordination or programming of motor movements for the production of speech sounds.

The parietal lobe is located in the middle portion of each cerebral hemisphere just posterior to the central sulcus. The horizontal portion of the lateral fissure separates the parietal lobe from the temporal lobe. The parietal lobe is associated with the perception of temperature, touch, pressure, vibration, pain, and taste and is involved in writing and in some aspects of reading. (Lorrie et al, 1997).

The most posterior lobe, the occipital lobe, is separated from the parietal lobe by the parieto-occipital fissure. This lobe is involved in the conscious perception of visual stimuli. The primary visual area receives input from the optic tract via the optic radiations extending from the thalamus. (Lorrie et al, 1997).

The temporal lobe is anterior to the occipital lobe and is separated from the parietal lobe by the lateral fissure. Conscious perception of auditory and olfactory stimuli are functions of the temporal lobe as well as dominance for language. Memory processing occurs via the amygdale and hippocampus, clusters of gray matter located in the parahippocampal gyrus is the auditory cortex, which can be divided into the primary and secondary auditory areas. The primary auditory area, Heschl's gyrus, receives the major auditory sensory information from the bilateral cochlea, whereas the secondary auditory area, Wernicke's area, is the center for the comprehension and formulation of speech. Deep to the temporal lobe is the cortical gray matter termed the (island of Reil), often referred to as the fifth lobe. The insula is separated from the temporal lobe by the lateral fissure and is thought to mediate the motor and sensory functions of the viscera. (Lorrie et al, 1997).

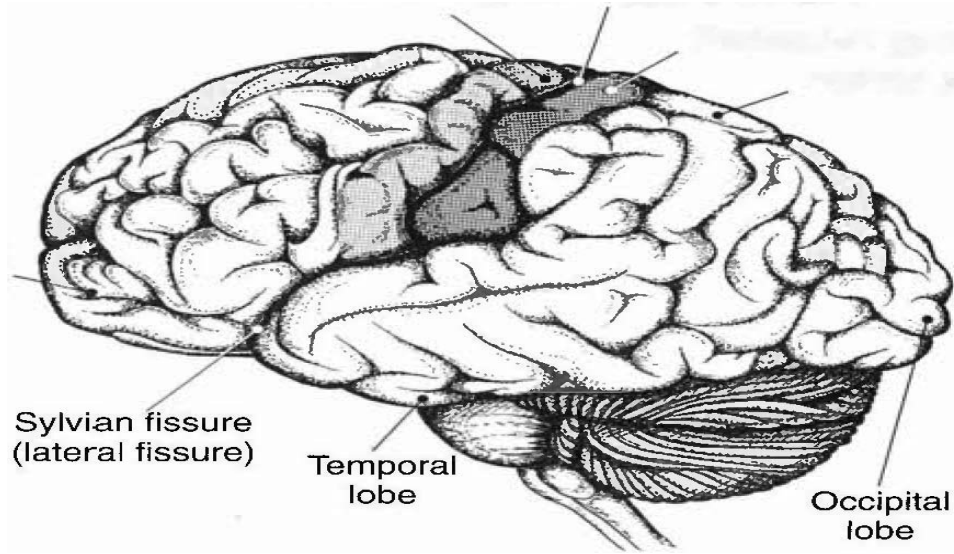


Figure (2-2): show brain lobes (Lorrie et al,1997).

2.2.3 Meninges :

The brain is a delicate organ that is surrounded and protected by three membranes called the meninges. The outermost membrane, the duramater(tough mother), is the strongest. This double-layered membrane is continuous with the preiostium of the cranium. Located between the two layers of dura mater are the meningeal arteries and the dural sinuses. The dural sinuses provide venous drainage from the brain. Folds of dura mater help to separate the structures of the brain and provide additional cushioning and support. The duralfolds includes the flax cerebri, tentorium cerebelli, and the flax cerebelli. The flax cerebri separates the cerebral hemispheres, whereas the tentorium cerebelli, which spreads out like atent, forms a partition between the cerebrum and cerebellum.(Lorrie et al, 1997).

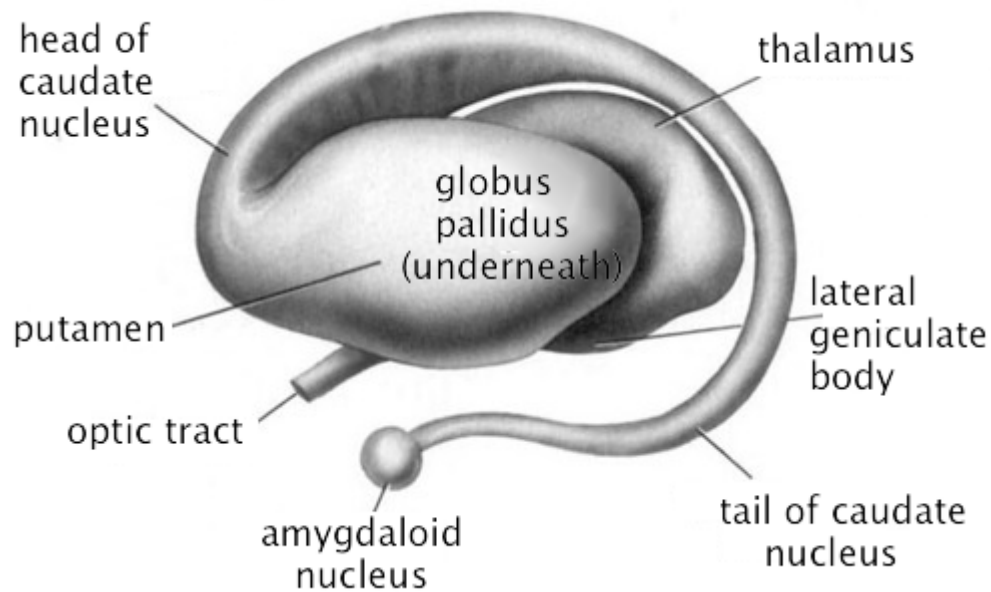
The flax cerebelli separates the two cerebellar hemispheres. The middle membrane, known as the arachnoid membrane (Spider like),is a delicate, transparent membrane that is separated from the dura mater by a potential space called the subdural space. The arachnoid membrane follows the contour of the dura mater. The inner layer, or

pia mater (delicate, tender mother), is a highly vascular layer that adheres closely to the contours of the brain. The subarachnoid space separates the pia mater from the arachnoid mater. This space contains cerebrospinal fluid that circulates around the brain and spinal cord and provides further protection to the central nervous system. (Lorrie et al, 1997).

2.2.4 Basal Nuclei :

The basal nuclei (ganglia) are a collection of subcortical gray matter consisting of the caudate nucleus, lentiform nucleus, and claustrum. Collectively, they contribute to the planning and programming of muscle action and movement. The largest basal nuclei are the caudate nucleus and lentiform nucleus. Both nuclei serve as relay stations between the thalamus and the cerebral cortex of the same side. The caudate nucleus parallels the lateral ventricle and consists of a head, body, and tail. The head causes an indentation to the frontal horns of the lateral ventricles, and the tail terminates at the amygdale in the temporal lobe. The lentiform nucleus is a biconvex lens-shaped mass of gray matter located between the insula, caudate nucleus, and thalamus. The lentiform nucleus can be further divided into the globuspallidus and the putamen. The claustrum is a thin linear layer of gray matter lying between the insula and the lentiform nucleus and is thought to be involved with the mediation of visual attention. (Lorrie et al, 1997).

Tracts of white matter separates the basal nuclei and transmit electrical impulses throughout the brain. The internal capsule is shaped like a boomerang and separates the thalamus and caudate nucleus from the lentiform nucleus. The external capsule is a thin layer of white matter that separates the claustrum from the lentiform nucleus. Another thin layer of white matter located between the claustrum and insular cortex is the extreme capsule. (Lorrie et al, 1997).



Figure(2-3)show basal ganglia(Lorrie et al,1997)

2.2.5 Diencephalon :

2.2.5.1 Thalamus :

The thalamus consists of a pair of large oval gray masses that are interconnected with most regions of the brain and spinal cord via a vast number of fiber tracts. The thalamus makes up a portion of the walls of the third ventricle and connects through the middle of the third ventricle by adhesions known as the Massa intermedia. The thalamus serves as a relay station to and from the cerebral cortex for all sensory stimuli with the exception of the olfactory nerves. (Lorrie et al, 1997).

2.2.5.2 Hypothalamus :

The hypothalamus consists of a cluster of small but critical nuclei located below the thalamus just posterior to the optic chiasm and forming the floor of the third ventricle.

Anatomically it includes the optic chiasm, mammillary bodies, infundibulum, and pituitary gland. The hypothalamus functions to integrate the activities of the automatic, endocrine, and limbic systems by helping to maintain homeostasis as it controls activities such as the regulation of temperature, appetite, sexual drive, and sleep patterns. In addition, the hypothalamus modulates the activities of the anterior and posterior lobes of the pituitary gland through the release of neurohormones that stimulates or inhibit the release of pituitary hormones. (Lorrie et al, 1997).

The pituitary (hypophysis) is an endocrine gland connected to the hypothalamus by the infundibulum. The infundibulum is a slender stalk located between the optic chiasm and the mammillary bodies. The pituitary gland is nestled in the sella turcica at the base of the brain. The protected location of this gland suggests its importance. It is sometimes called the master gland because it controls and regulates the functions of many other glands through the action of its six major types of hormones. The pituitary gland can be broken down into an anterior lobe (adenohypophysis) and a posterior lobe (neurohypophysis). (Lorrie et al, 1997).

2.2.5.2 Epithalamus :

The pineal gland, an endocrine structure, secretes the hormone melatonin that aids in the regulation of day- night cycles and reproductive functions. The pineal gland sits on the roof of the midbrain just posterior to the third ventricle and below the splenium of the corpus callosum. It is sometimes calcified, which aids in its detection on CT scans and lateral radiographs of the cranium. (Lorrie et al, 1997).

2.2.6 Cerebellum:

The cerebellum, which is referred to as the 'little brain,' attaches posteriorly to the brainstem and occupies the posterior cranial fossa. The cerebellum does not initiate

actual motor functions, it uses the brainstem to connect with the cerebrum to execute a variety of movements, including maintenance of muscle tone, posture, and balance, and coordination of movement. The cerebellum consists of two cerebellar hemispheres (lateral hemispheres). These hemispheres have an interesting appearance because the folds of gray matter give the appearance of cauliflower. A midline structure called the vermis connects the two cerebellar hemispheres. On the inferior surface of the cerebellar hemispheres are two rounded prominences called the cerebellar tonsils. Occasionally, these tonsils can be seen herniating down through the foramen magnum. Three pairs of nerve fiber tracts, the cerebellar peduncles, connect the cerebellum to the brainstem. The superior cerebellar peduncles connect the cerebellum to the midbrain. The middle cerebellar peduncles serve as attachments to the pons, and the information traveling to and from the cerebellum is routed through the cerebellar peduncles. Deep within the center of each cerebellar hemisphere is a collection of nuclei called the dentate nucleus, the largest and most lateral of the deep cerebellar nuclei. Fibers of the dentate nucleus project to the thalamus via the superior cerebellar peduncles, from here the fibers travel to the motor areas of the cerebral cortex, namely the precentral gyrus thus influencing motor activity. (Lorrie et al, 1997)

2.2.7 Brain stem:

The brainstem is a relatively small mass of packed with motor and sensory nuclei, making it vital for normal brain function. Ten of the 12 cranial nerves originate from nuclei located in the brainstem. Its major segments are the midbrain, pons, and medulla oblongata.

Located within the central portion of the brainstem and common to all three segments is the tegmentum, an area that provides integrative functions such as complex motor

patterns, aspects of respiratory and cardiovascular activity, and regulation of consciousness. The central core of the tegmentum contains the reticular formation, an area containing the cranial nerve nuclei and ascending and descending tracts to and from the brain. The brainstem as a whole acts as a conduit between the cerebral cortex, cerebellum, and spinal cord (Kathleen R, et al. 2012)

2.2.7.1 Midbrain:(mesencephalon)

The interior contents of the midbrain can be anatomically segmented in a dorsal to ventral fashion, including the tectum, tegmentum, and basis. The tectum is the most dorsal aspect of the midbrain and includes the quadrigeminal plate as well as additional gray matter and fiber tracts residing dorsal to the cerebral aqueduct. The centrally located tegmentum represents the largest portion of midbrain real estate and contains cranial nerve nuclei in addition to gray matter and fiber tracts. The remaining ventral midbrain is termed the basis and is comprised of the cerebral peduncles, substantianigra, crus cerebri, and corticobulbar fibers. The external midbrain displays distinct landmarks for easy identification. the cerebral peduncles lie along the ventral aspect of the midbrain, just superior to the pons. In addition, the quadrigeminal plate includes the superior and inferior colliculi, which are noted as two paired eminences along the dorsal surface of the midbrain. The oculomotor nerve (cranial nerve iii) can be identified along the ventral midbrain which the groove formed between the cerebral peduncles. The trochlear nerve (cranial nerve iv) emerges from the dorsal midbrain near the inferior colliculus. (Kathleen R, et al. 2012).

Level of the inferior colliculus: in the study of neuroanatomy, axial sectioning of the midbrain is commonly performed at the inferior colliculus. The inferior colliculus nuclei represent a triad of gray matter nuclei which the inferior collicular eminences, which play a significant role in the auditory pathway . these three nuclei are layered

such that the central nucleus is at the core, surrounded by the pericentral nucleus, and the more laterally placed external nucleus. The central nucleus is the dominant midbrain structure responsible for tonotopically organizing auditory information. The pericentral nucleus and external nucleus both receive auditory and nonauditory inputs to ASSIST in acousticomotor functions, such as guiding auditory attention. Afferent signals are transmitted to the inferior colliculus nuclei via the lateral lemniscuses, contralateral inferior colliculus, ipsilateral medial geniculate body, auditory cerebral cortex, and cerebellum. The tegmentum contains the majority of the midbrain white matter tracts and nuclear groups at the level of the inferior colliculus. Multiple white matter tracts course through the midbrain with continuations to the cerebral cortex, cerebellum and spinal cord. The brachium conjunctivum is the largest and most centrally located of these tracts, representing the decussation of cerebellar axons arising from the superior cerebellar peduncles. These fiber bundles continue to the thalamus and red nucleus and are involved in motor coordination. Sensory fibers course through the lateral tegmentum which include the medial lemniscuses, trigeminal lemniscuses, and spinothalamic tracts. These bundles primarily project to the thalamus. The medial lemniscuses relay information regarding proprioception and discriminative touch from the periphery and posterior columns of the spinal cord. Axons from the anterolateral portion of the spinal cord ascend through the spinothalamic tract, conveying sensations of pain and temperature. Facial sensations of pain, temperature, and touch are relayed to the thalamus via the trigeminal lemniscal tract. The medial longitudinal fasciculi are a pair of centrally located fiber tracts, controlling eye movement through connections with the oculomotor (CN III), trochlear (CN IV) and abducens (CN VI), nerves as well as the vestibulocochlear nerves (CN VIII). Multiple important nuclear groups are found within the tegmentum at this level. Just dorsal to the substantia nigra, the nucleus parabrachialis/pigmentosus is a continuation of the tegmental area of Tsai. The ventral tegmental nucleus resides

dorsal to the brachium conjunctivum and receives fibers from the mammillary bodies to assist in regulating emotion and behavior. Within close proximity, the nucleus supratrochlearis (dorsal raphe nucleus) represents the largest serotonergic nucleus within the brain. Projections from the supratrochlearis nucleus extend to the substantia nigra, basal ganglia and cerebral cortex. The dorsal tegmental nucleus is located within the periaqueductal gray matter and sends projections to the reticular formation and autonomic nuclei of the brainstem. The pedunculopontine nucleus, lateral dorsal tegmental nucleus, and parabrachial areas are cholinergic nuclei within the lateral tegmentum. The pedunculopontine nucleus (PPN) receives input from cortical, pallidal, and nigral fibers and is involved in locomotion. The PPN has also been described as a site involved in progressive supranuclear palsy. The parabrachial areas respond to visual stimuli projecting and to from the superior colliculi. The locus ceruleus is a noradrenergic nucleus with projections throughout the central nervous system, mainly through projections in the central tegmental tract, dorsal longitudinal fasciculus, and the medial forebrain bundle. (Kathleen Ruchalski and Gasser M. Hathout, 2012).

Level of the superior colliculus : The superior colliculus nuclei reside within the tectum as noted externally by the eminences of the superior colliculi. These nuclei are highly layered structures which govern ocular movements and visual reflexes through afferent connections with the cerebral cortex, retina, spinal cord, inferior colliculus, as well as several additional white matter tracts. The tegmentum is comprised of several nuclear bodies, with the red nucleus and oculomotor complex being the most notable. The red nucleus resides medially within the rostral tegmentum. Little is known about the function of the red nucleus, but its vast afferent pathways are known to include the cerebral and cerebellar cortex. Additionally, efferent projections to the spinal cord, cerebellum, reticular formation, and inferior olive have been noted. Continuations of

the previously described white matter tracts within the tegmentum at the level of the inferior colliculus are again seen at this more superior level of the superior colliculus. The oculomotor nucleus lies ventral of the periaqueductal gray matter within the medial tegmentum. Afferent projections to the oculomotor nucleus originate from the cerebral cortex, cerebellum, mesencephalon, Pons, and medulla. The oculomotor nucleus is comprised of a lateral somatic motor column and medial visceral cell column.

The lateral somatic motor column contains three subnuclei: the lateral, medial, and central subnuclei. The lateral subnucleus provides innervations to the ipsilateral inferior rectus, inferior oblique, and medial rectus muscles. The medial subnucleus supplies the contralateral superior rectus muscle. Innervations of the bilateral levatorpalpebraesuperioris is provided by the central sub nucleus.. (Lorrie et al, 1997).

The somatic and visceral fibers from these nuclei coalesce and course ventrally through the midbrain tegmentum and near the red nucleus as well as the inner portion of the cerebral peduncles. Exiting the midbrain within the interpeduncular fossa as the oculomotor nerve, these fibers travel between the superior cerebellar and the posterior cerebral arteries adjacent to the trochlear nerve. Both of these cranial nerves continue to course anteriorly within the subarachnoid space to eventually penetrate the dura into the cavernous sinus. The oculomotor nerve then divides into a superior and inferior division. The superior division innervates the superior rectus and the levatorpalpebraesuperioris muscles, governing upward gaze and lid elevation, respectively. The inferior division provides innervations to the inferior oblique, inferior rectus, and medial rectus muscles.

The inferior oblique muscle affects outward torsional gaze. The inferior rectus muscle lowers the eye, while the medial rectus muscle allows adduction. The Edinger-

Westphal nucleus resides within the visceral cell column and is located dorsal to the somatic oculomotor complex. Preganglionic axons coalesce and travel with oculomotor somatic fibers throughout the pathway to the eye. Upon entering the orbit, the parasympathetic fibers separate from the nerve to project to the ciliary ganglion. Postsynaptic fibers project to the ciliary body and iris to innervate the sphincter pupillae and ciliary muscles. The pupillary light reflex allows transmittal of light-activated afferent signals through the optic nerve to project to bilateral Edinger-Westphal nuclei. Therefore, light cast upon one eye results in bilateral and symmetric pupillary constriction, increasing lens curvature and eye convergence with near vision. (Kathleen et al,2012).

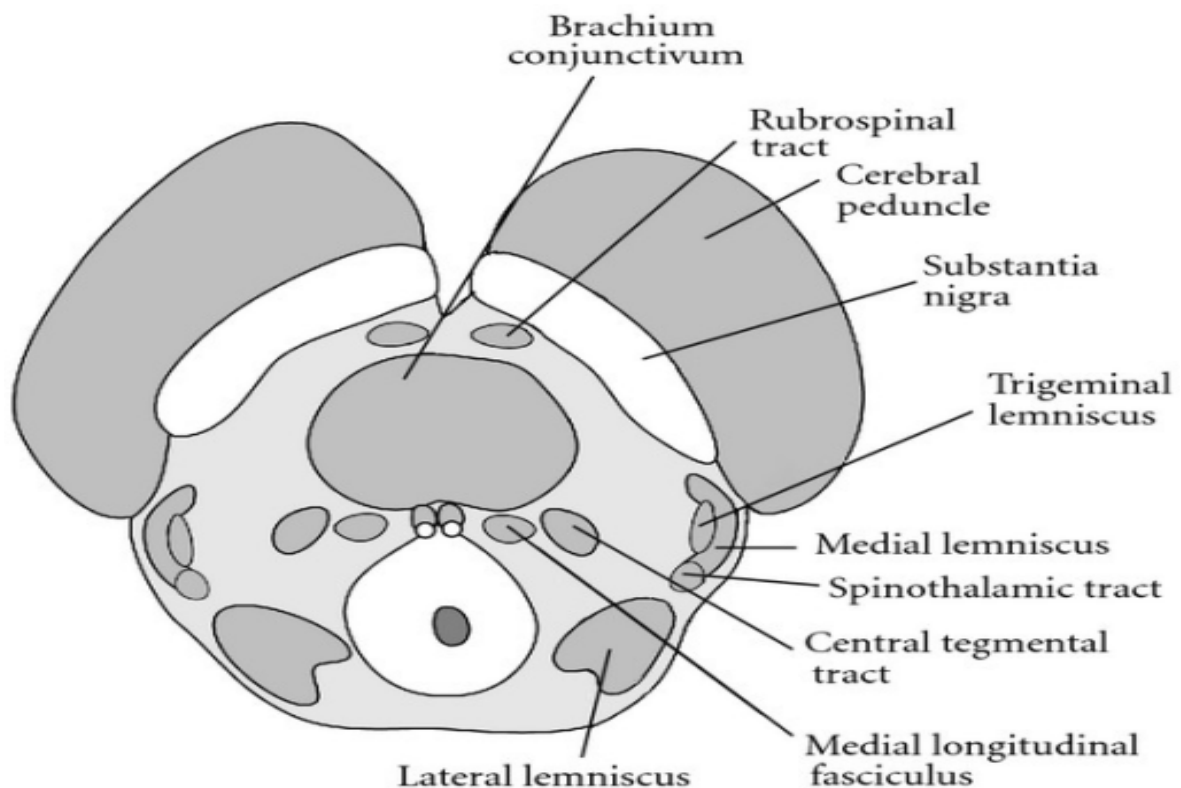
Ventral Midbrain: The ventral midbrain appears similar at both the level of the superior and inferior colliculi. Principle structures within this region include the cerebral peduncle and the substantia nigra.

The cerebral peduncle contains corticocerebellar, corticobulbar, and corticospinal fibers. The corticospinal tract occupies roughly the middle three fifths of the cerebral peduncle, with the efferent cortical motor axons arranged somatotopically from medially to laterally as arm, face, and leg. The medial and lateral aspects of the peduncle are composed of corticopontine fibers from the frontal and parietooccipital regions, respectively. These synapse in the Pons, and decussate to enter the contralateral cerebellum through the middle cerebellar peduncles. Corticobulbar fibers, destined for the cranial nerve nuclei, occupy dorsomedial position in relation to corticospinal tract.

The substantia nigra is identified as a pigmented band of tissue just dorsal to the cerebral peduncle. It is composed of two zones, a dorsal zone compacta and a ventral

zone reticulata. The substantia nigra is noted to play a role in several pathways, including motor control and reward.

Involvement of the substantia nigra has been described with Parkinson's disease, Huntington's disease, and multisystem atrophy, with each disease showing a characteristic pattern of neuronal loss. Dopaminergic neurons from the center of the zona compacta, for example, are lost in idiopathic Parkinson's disease. (Kathleen R et al, 2012).



Figure(2-4):Show major white matter tract within the segmentum at the level of the inferior colliculus.(Kathleen R, et al.2012)

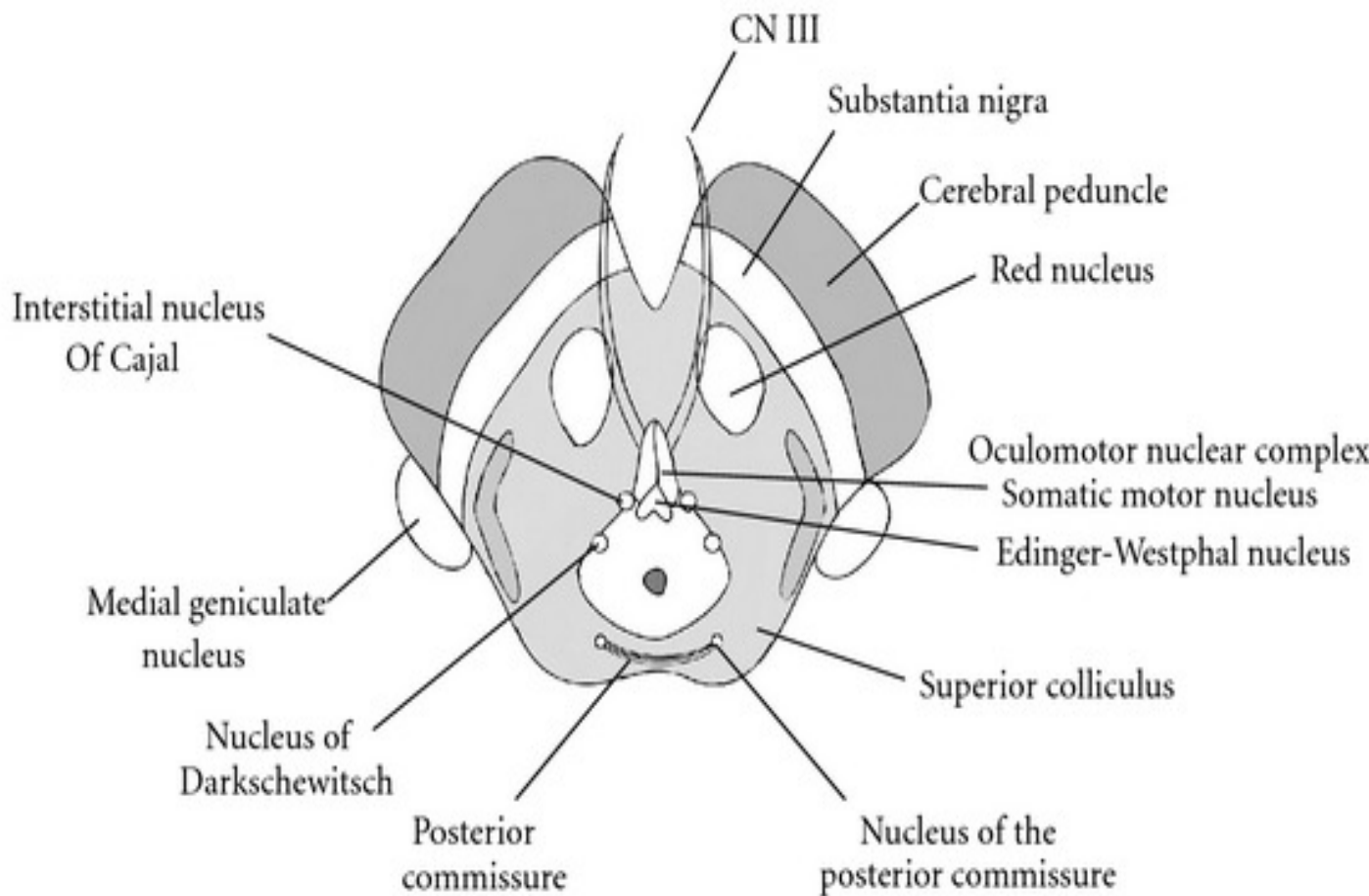


Figure (2.5): show midbrain anatomy at level of superior colliculus.(Kathleen R ,et al.2012)

2.2.7.2 Pons (Metencephalon) :

The cerebellum overlies and hides the dorsal aspect of the brainstem, but its ventral aspects, the Pons, is clearly evident. Rostrally, the superior pontine sulcus act as the boundary between the metencephalon and the midbrain and the inferior pontine sulcus as the boundary between the metencephalon and the myelencephalone. Part of the floor of the fourth ventricle is formed by the dorsal aspect of the Pons, and is

known as the pontine tegmentum, the structure that houses the nuclei of the trigeminal, abducent, facial, and vestibulocochlear nerves. Cranial nerves VI, VII, and VIII leave the brainstem at the inferior pontine sulcus, whereas the trigeminal nerve exits the brainstem through the middle cerebellar peduncle.

2.2.7.2.1 Ventral or Anterior surface of Pons :

Basilar sulcus, Midline sulcus occupied by basilar artery. Transverse running fibers on the surface: pontocerebellar fibers which continues as middle cerebellar peduncle.

Trigeminal nerve emerges at lateral part of Pons.

2.2.7.2.2 Dorsal or Posterior surface of Pons :

Hidden by cerebellum bounded laterally by superior cerebellar peduncle, median sulcus in the midline.

Paramedian elevation raised by underlying abducent nerve covered by winding fibers of facial nerve.

Internal structure of Pons :

Basilar or ventral portion contains both longitudinal and transverse fibers intermixed with pontine nuclei. Dorsal tegmental portion continuation of the reticular formation of the medulla oblongata.

2.2.7.2.3 Structure present at the level of facial nucleus :

CN VI nucleus (Abducens nerve), CN VII nucleus (Facial nerve) and CN VIII (Vestibular Nuclei).

2.2.7.2.4 Structures present at the level of middle cerebellar peduncle :

Medial lemniscuses, Lateral lemniscuses, trapezoid body, trigeminal nucleus (sensory and motor) and pontine nuclei.

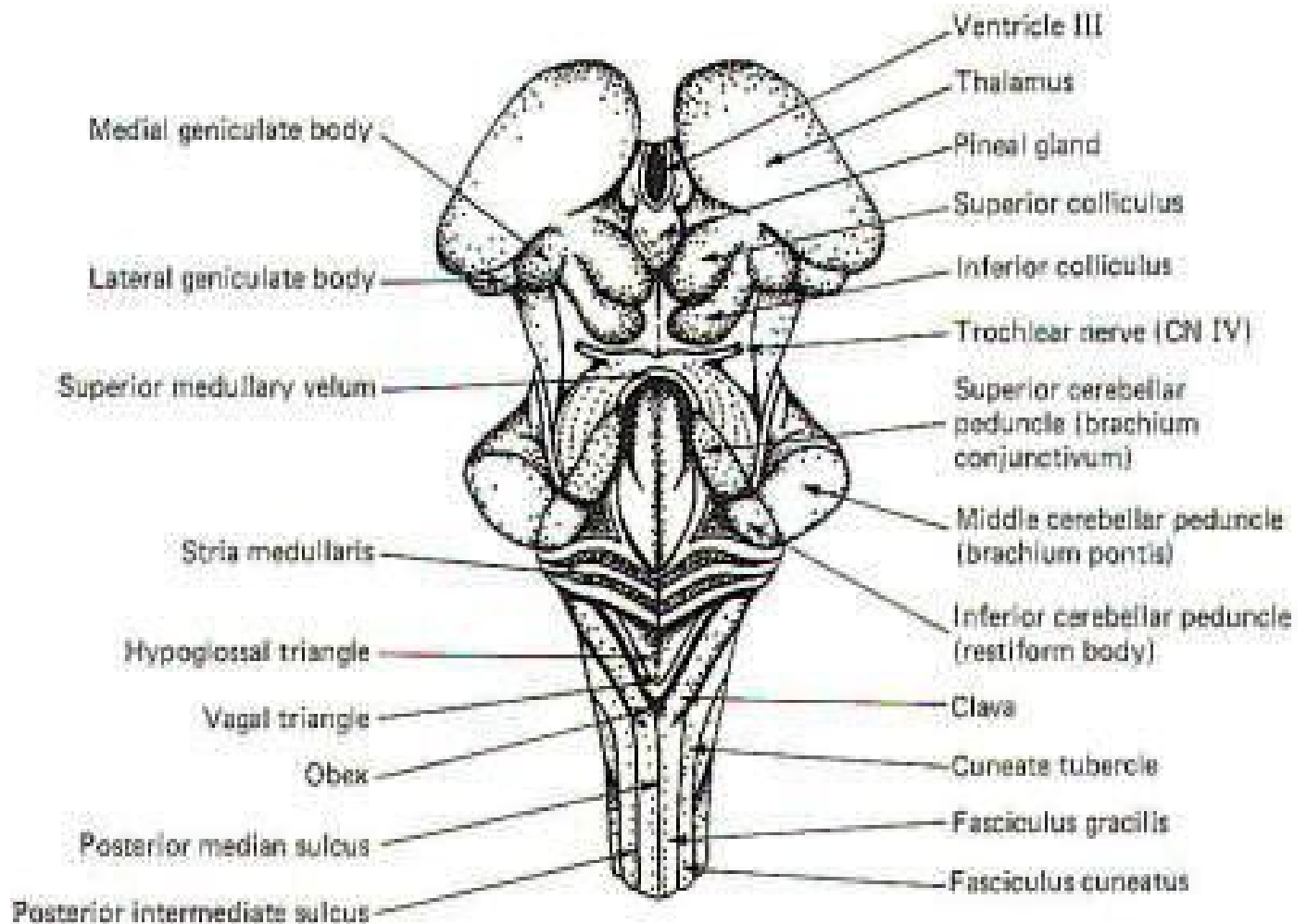
2.2.7.2.5 Structure present at the level of upper Pons :

Superior cerebellar peduncle, locus ceruleus and parabrachial nucleus.

2.2.7.3 Medulla oblongata (Myelencephalon) :

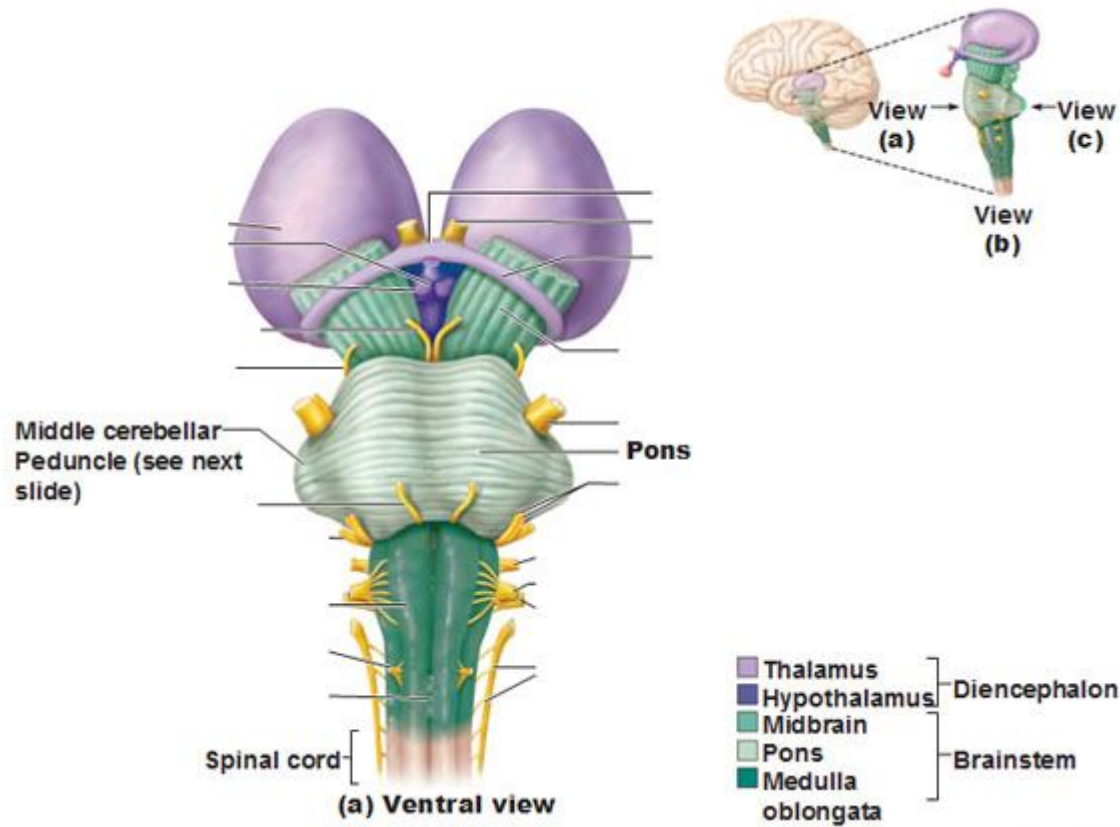
The caudal-most portion of the brainstem, the myelencephalon, also known as the medulla oblongata, extends from the inferior pontine sulcus to the spinal cord. The boundary between them is the region where the lateral walls of the fourth ventricle converge in a V shape at the midline obex (at the level of foramen magnum). The ventral surface of the myelencephalon displays the anterior median fissure, bordered on each side by the pyramids and crossed by the pyramidal decussations, connecting the right and left pyramids to each other. The olives are olive pit-shaped swellings lateral to each pyramid. The hypoglossal nerve is evident as a number of thin filaments on each side of the brainstem, arising from the anterior lateral sulcus between the pyramids and olives. The glossopharyngeal, vagus, and accessory nerve arise from the groove dorsal to the olives. The dorsal surface of the myelencephalon presents the posterior median fissure, which is the interposed between the right and left tuberculum gracilis, swellings formed by the nucleus gracilis. Just lateral to the tuberculum gracilis is another swelling, the tuberculum cuneatus, a bulge formed by the underlying nucleus cuneatus. The caudal continuation of the tuberculum gracilis is the fasciculus gracilis, and the continuation of the tuberculum cuneatus is the fasciculus cuneatus. Just lateral to the tuberculum cuneatus is another swelling, the

tuberculum cinereum, formed by the descending tract of the trigeminal nerve. (Harold Ellis et al, 2007).

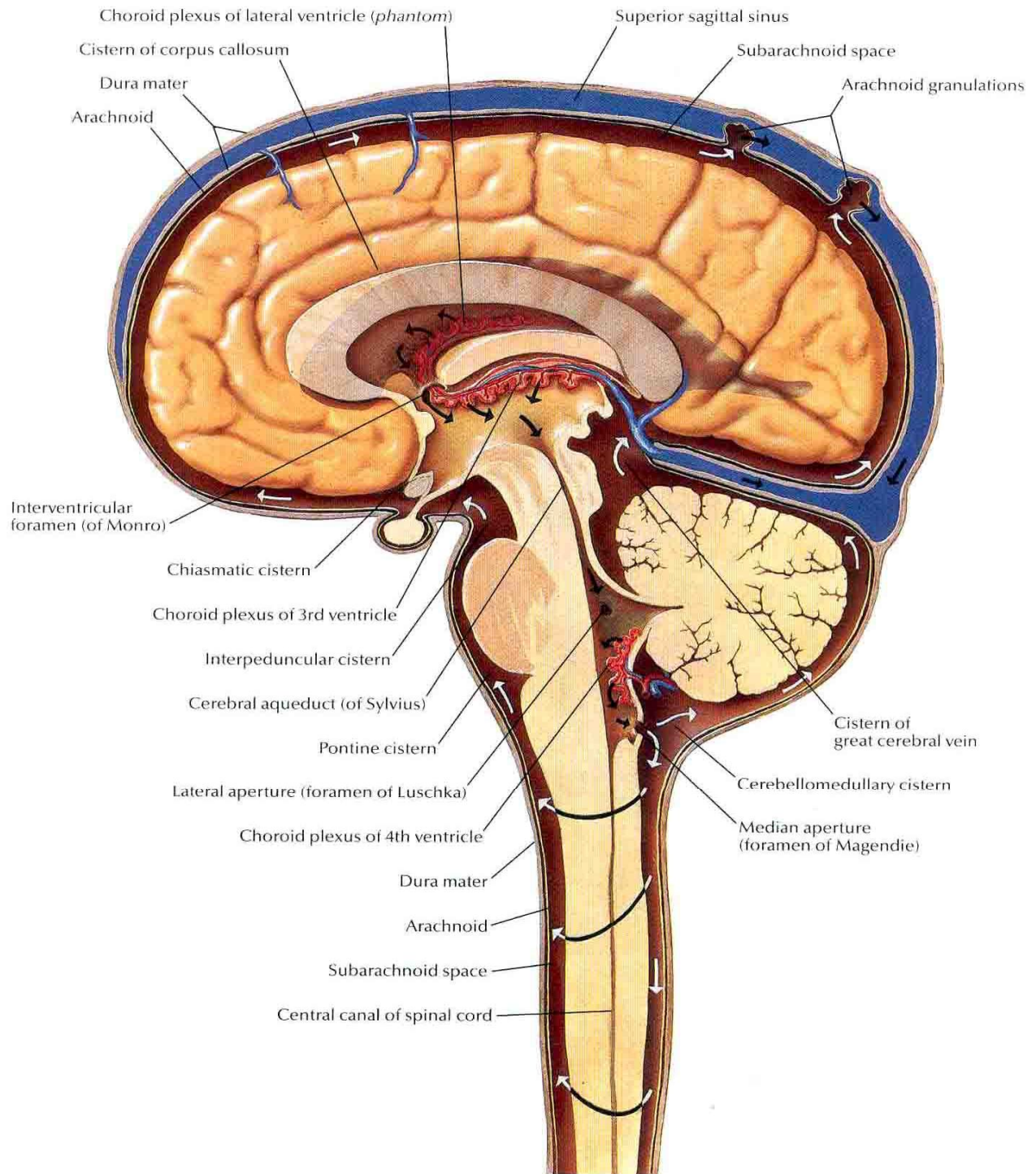


Figure(2.6): show ventral view of brain stem.(Kathleen R, et al.2012)

The Brain Stem—Pons



Figure(2.7): show dorsal view of brain stem.(Kathleen R, et al 2012).



Figure(2.8): lateral view of brain stem(Kathleen R, et al 2012).

2-3Physiology:

The Brain Stem:

The **brain stem** contains the midbrain, the pons, and the medulla oblongata . The **midbrain** acts as a relay station for tracts passing between the cerebrum and the spinal cord or cerebellum. It also has reflex centers for visual, auditory, and tactile responses. The word *pons* means “bridge” in Latin, and true to its name, the **pons** contains bundles of axons traveling between the cerebellum and the rest of the CNS. In addition, the pons functions with the medulla oblongata to regulate breathing rate and has reflex centers concerned with head movements in response to visual and auditory stimuli.

The **medulla oblongata** contains a number of reflex centers for regulating heartbeat, breathing, and vasoconstriction.

It also contains the reflex centers for vomiting, coughing, sneezing, hiccuping, and swallowing. The medulla oblongata lies just superior to the spinal cord, and it contains tracts that ascend or descend between the spinal cord and higher brain centers. (Elaine N, et al. 2014)

2-4Pathology:

Table (2.1): Show brainstem syndrome :

Named Brainstem Syndromes

Eponym	Site	Cranial Nerves	Tracts	Signs	Usual Cause
Weber	Base of Midbrain	III	Corticospinal	Oculomotor palsy with crossed hemiplegia	Vascular, tumor
Claude	Midbrain tegmentum	III	Red nucleus and Brachium Conjunctivum	Oculomotor palsy with contralateral cerebellar ataxia and tremor	Vascular, tumor
Benedict	Midbrain tegmentum	III	Red nucleus, corticospinal tract, brachium conjunctivum	Oculomotor palsy, contralateral cerebellar ataxia, corticospinal signs	Vascular, tuberculoma, tumor
Nothnagel	Midbrain tectum	Unilateral or bilateral III	Superior cerebellar peduncles	Ocular palsies, paralysis of gaze, cerebellar ataxia	Tumor
Parinaud	Dorsal Midbrain			Paralysis of upward gaze and accommodation, fixed pupils, retraction nystagmus	Pinealoma, hydrocephalus
Millard-Gubler and Raymond-Foville	Base of Pons	VII and sometimes VI	Corticospinal tract	Facial and 6th palsy, contralateral hemiplegia, sometimes gaze palsy	Vascular, tumor
Avellis	Medulla tegmentum	X	Spinothalamic, sometimes pupillary fibers	Paralysis of soft palate and vocal cord and contralateral hemianesthesia	Infarct or Tumor
Jackson	Medulla Tegmentum	X, XII	Corticospinal	Avellis plus ipsilateral tongue	Infarct or Tumor
Wallenberg	Medulla, lateral tegmentum	Spinal V, IV, X, XI	Lateral STT, Descending Pupil fibers, Spinocerebellar and olivocerebellar tracts	Ipsi V, IV, X, XI palsy, Horner's, cerebellar ataxia. Contra pain and temp	Vascular - Pica or vertebral

www.tchain.com/otoneurology/disorders/central/brainstem .

2.5 MRI of the head:

Magnetic resonance imaging (MRI) is a non-invasive medical test that helps physicians diagnose and treat medical conditions. MRI used a powerful magnetic field, radio frequency pulses and a computer to produce detailed pictures of organs, soft tissues, bone and virtually all other internal body structures. The images can examine on a computer monitor, transmitted electronically, printed or copied to a CD. Detailed MR images allow evaluating various parts of the body and determining the presence of certain disease. Currently, MRI is the most sensitive images test of the head (particularly in the brain) in routine clinical practice. It can help diagnose conditions such as :Brain tumours, Stroke, Infections, Developmental anomalies, Hydrocephalus-dilatation of fluid spaces within the brain (ventricles), causes of epilepsy (seizure), haemorrhage in selected trauma patients, certain chronic conditions, such as multiple sclerosis, Disorders of the eye and inner ear, Disorders of pituitary gland, Vascular problems, such as an aneurysm (a bubble-like expansion of the vessel), arterial occlusion (blockage) or venous thrombosis (a blood clot within a vein) also use the MR examination to detect brain abnormalities in patients with dementia, a disorder that can cause confusion or memory loss.

2.5.1 Preparations:

The patient was asked to wear a gown during the exam. Guidelines about eating and drinking before an MRI exam vary with the specific exam and also with the facility. Some MRI examination may require the patient to receive an injection of contrast material into the bloodstream. The technologist ask the patients if he have allergies of any kind, such as allergy to iodine or x-ray contrast material, drugs, food, the environment, or asthma. The contrast material most commonly used for an MRI exam

is called gadolinium. Because gadolinium does not contain iodine, it can be used safely in patients with contrast allergies. Some conditions such as severe kidney disease may prevent patient from being given contrast material for an MRI. If there is a history of kidney disease, it may be necessary to perform a blood test to determine whether the kidneys are functioning adequately. Pregnant women should not receive injections of contrast material. Claustrophobia (fear of enclosed spaces) or anxiety, the patient gives sedative prior to the scheduled examinations. Jewellery and other accessories should be removed prior to the MRI scan.

These items include: Jewellery, watches, credit cards and hearing aids, all of which can be damaged, Pins, hairpins, metal zippers and similar metallic items, which can distort MRI images, Removable dental work, Pens, pocket knives and eyeglasses and Body piercings.

In most cases, an MRI exam is safe for patients with metal implants, except for a few types: Internal (implanted) defibrillator or pacemaker, Cochlear (ear) implant, Some types of clips used on brain aneurysms and some types of metal coils placed within blood vessels.

The technologists ask the patient if he has medical or electronic devices in your body, because they may interfere with the exam or potentially pose a risk, depending on their nature and the strength of the MRI magnet. Some implanted devices require a short period of time after placement (usually six weeks) before being safe for MRI examination. Examples include but are not limited to:

Artificial heart valves, implanted drug infusion ports, implanted electronic device, including a cardiac pacemaker, Artificial limbs or metallic joints prostheses, implanted nerve stimulators and metal pins, screws, plates, stents or surgical staples.

Metal objects used in orthopaedic surgery pose no risk during MRI. However, a recently placed artificial joint may require the use of another imaging procedure.

2.5.2 Equipment :

Patient lie on a moveable examination table that slides into the center of the magnet. Some MRI units, called short-bore systems, are designed so that the magnet does not completely surround the patient; others are open on the sides (open MRI). These units are especially helpful for examination patients who are fearful of being in a closed space and for those who are very obese. The coil type was used is quadrature head coil 4-channel with the sequence sagittal T1, coronal T2, axial T1, T2 and flair.

2.5.3 Technique:

2.5.3.1 Patient positioning:

The patient lies supine on the examination couch with their head within the head coil. The head is adjusted so that the interpupillary line is parallel to the couch and the head is straight. The patient is positioned so that the longitudinal alignment light lies in the midline, and the horizontal alignment light passes through the nasion. Straps and foam pads are used for immobilization.

2.5.3.2 Suggested protocol:

-Sagittal SE/FSE/incoherent (spoiled) GRE T1:

Medium slices/gap are prescribed on each side of the longitudinal alignment light from one temporal lobe to the other. The area from the foramen magnum to the top of the head is included in the image.

L 37 mm to R 37 mm

-Axial/oblique SE/FSE PD/T2 :

Medium slices/gap are prescribed from the foramen magnum to the superior surface of the brain. Slices may be angled so that they are parallel to the anterior–posterior commissure axis. This enables precise localization of lesions from reference to anatomy atlases. Many sites have replaced the PD sequence with FLAIR. SS-FSE or SS-EPI may be a necessary alternative for a rapid examination in uncooperative patients.

-Coronal SE/FSE PD/T2:

As for Axial PD/T2, except prescribe slices from the cerebellum to the frontal lobe .

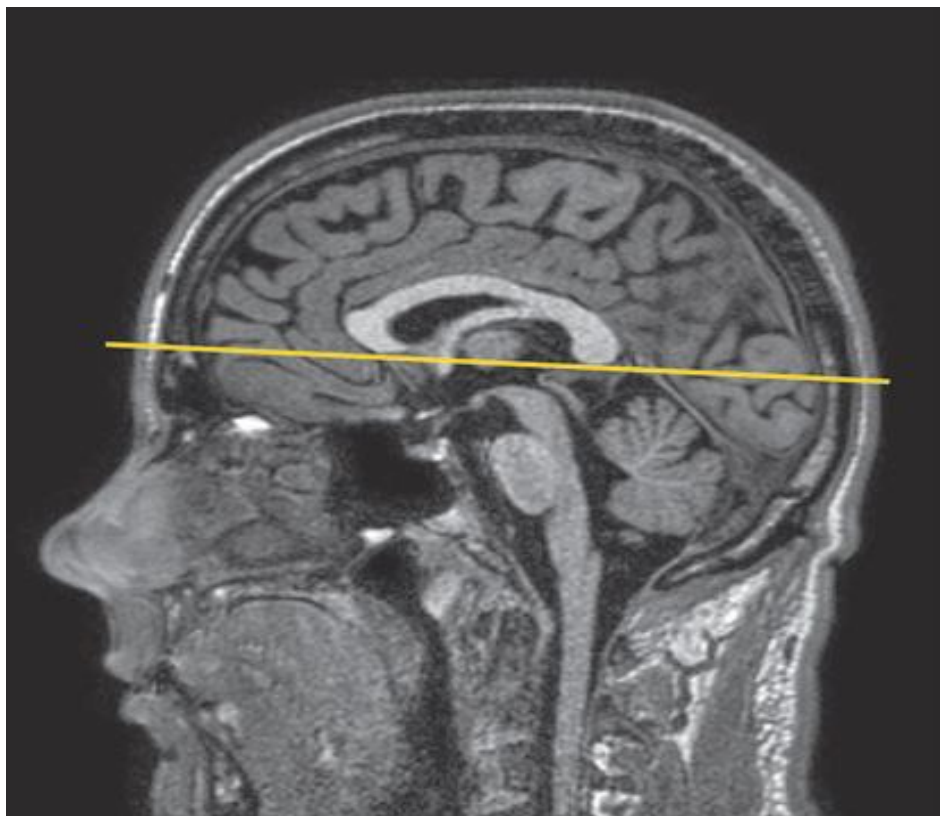

Figure (2-9): Sagittal SE T1 weighted midline slice of the brain showing the axis of the anterior and posterior commissures .

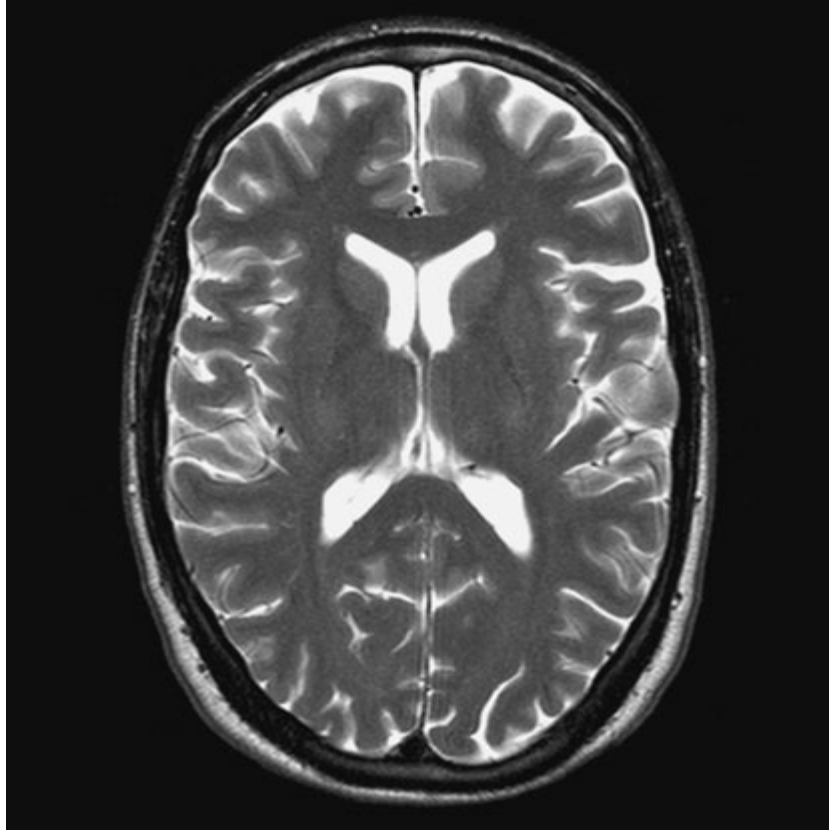


Figure (2-10) Axial/oblique FSET2 weighted image of the brain showing normal appearances.

2.5.4 Benefits VS. Risks :

Benefits :

MRI is a non-invasive imaging technique that does not involve exposure to ionizing radiation, MR images of the brain and other cranial structures are clearer and more detailed than with other imaging methods. This detail makes MRI an invaluable tool in early diagnosis and evaluation of many conditions, including tumours, MRI can help physicians evaluate the structures of the brain and can also provide functional information (fMRI) in selected cases, The contrast material used in MRI exams is less likely to produce an allergic reaction than the iodine-based contrast materials used for conventional x-ray and CT scanning, MRI is the most sensitive means to detect and

evaluate brain tumours, A variant called MR angiography (MRA) provides detailed images of blood vessels in the brain—often without the need for contrast material and MRI can detect stroke at a very early stage by mapping the motion of water molecules in the tissue. This water motion, known as diffusion, is impaired by most strokes, often within less than 30 minutes from the onset of symptoms.

Risks :

The MRI examination poses almost no risks to the average patient when appropriate safety guidelines are followed, If sedation is used, there are risks of excessive sedation. The technologist or nurse monitors your vital signs to minimize this risk, Although the strong magnetic field is not harmful in itself, implanted medical devices that contain metal may malfunction or cause problems during an MRI exam, There is a very slight risk of an allergic reaction if contrast material is injected. Such reactions usually are mild and easily controlled by medication. If you experience allergic symptoms, a radiologist or other physician will be available for immediate assistance and Nephrogenic systemic fibrosis is currently a recognized, but rare, complication of MRI believed to be caused by the injection of high doses of gadolinium contrast material in patients with very poor kidney function. Manufacturers of intravenous contrast indicate mothers should not breastfeed their babies for 24-48 hours after contrast medium is given. However, both the American College of Radiology (ACR) and the European Society of Urogenital Radiology note that the available data suggest that it are safe to continue breastfeeding after receiving intravenous contrast.

2.5.5Limitations :

Magnetic resonance imaging generally is not recommended for patient who have been actually injured; however, this is a clinical judgment. This is because traction devices and many types of life supports equipments must be kept away from the area to be

imaged. The examination takes longer than other imaging modalities (typically x-ray and CT) and the results may not be immediately available, as is often necessary in trauma situations.

2.6 Previous study :

-A study done by Raininko. in 1993 to develop a method of measuring the size of the brainstem by routine MRI and to determine brainstem dimensions in a normal population. they examined 174 subjects, aged 4 month to 86 years, with no known brain disease. Sagittal midline diameters of the mesencephalon, pons and medulla oblongata were measured on sagittal T1-weighted image.

The adult midsagittal diameters of the mesencephalon was reached at age of 6 years, and decreased slightly after 45-50 years. Pontine dimensions increased until the age of 20 years and did not subsequently decrease. The midsagittal and midcoronal diameter of the medulla oblongata stopped increasing at the ages of 6 and 8 years, respectively. Minimal reduction in the midsagittal diameter occurs after 50 helpful in the investigation of neurodegenerative diseases. (Raininko et al, 1993).

-A study found by Steele et al in 1981 presented the normal anatomy of the brain stem in adult and children by CT cisternography. Were reviewed to assess the normal anatomy of the brain stem and its surrounding cisterns.

Normal brain stem and cisternal anatomy was found to be constant and symmetrical. The review included six patients with brainstem gliomas and five patients with extraaxial masses. In these patients cisternography accurately identified mass formation and permitted the confident distinction of extra axial from intra axial masses. CT cisternography is a safe and accurate method for evaluating the anterior compartment of the posterior fossa. This procedure is particularly applicable to those cases where conventional CT yield insufficient diagnostic information.

Chapter three

Material and methods

3.1 Materials:

3.1.1 Machine:

-Neuo soft and Toshiba machine 0.3-1.5 T. with properties :

Maximum field of view : 530 (isotropic), Minimum field of view :5, Radiofrequency system (RF): synergy , Gradient system: pulsar , Patient aperture at narrowest cm width × height (couch to pole) : 60×42 total length cm :167 and couch max/min height cm :89/52

3.1.2 PATIENT:

3.1.2.1 Study design:

This study was a descriptive study.

3.1.2.2 Study area:

Sudanese population .

3.1.2.3 Place of study:

This study will be conducting in two hospitals : National Al Rebat hospital and Alyaa Specilazied hospital .

3.1.2.4 Inclusion criteria:

Normal Sudanese patients aged from 16-.81 years

3.1.2.5Exclusion criteria:

Patients with previous history of degenerative diseases, head injury and neurosurgery.

3.1.2.6 Duration of study:

This study was in period from September to December 2016.

3.1.2.7Analysis of data :

All dose parameters will registered from Data collection sheet , then used as input to the Microsoft excel and SPSS software for analysis.

3.1.2.8Sample size:

50 patients (28 male and 22 female) at age from 16-81 years old.

3.2 Method:

3.2.1 Technique:

Quadrature head coil 4-channal ,FOV =24 cm ,slice thickness =5mm ,Gap per slice :5mm,Sequences :sagittal T1coronal T2,axial T1,T2 and FLAIR . In sagittal T1:TR=542 ms .TE=15 ms . I axial T2:TR=4.5 ms .TE=110 ms .

3.2.2 Measurement:

The measurement was done in one view:

Sagittal T1at mid sagittal plane :For the midbrain measured from superior surface of the pons to the mid way between superior and inferior colliculs . For the

pons measured from anterior surface of the pons to the superior surface of the fourth ventricle. For the medulla oblongata measured from anterior to posterior at the cervicomedullary junction .

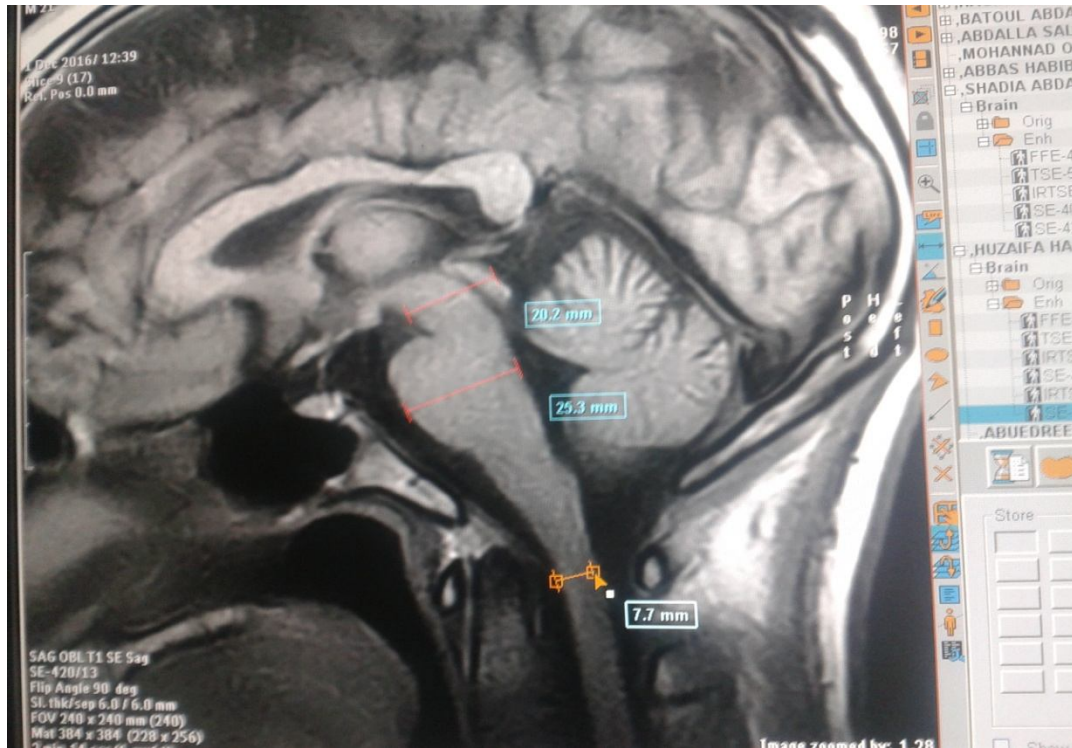


Figure (3-1) Sagittal T1 weighting image of the brain in the midsagittal plane show the measurement of the brainstem .

Chapter four

Result

Gender distribution

In this study a total of 50 patients were included the male representing 28 patients (56%) and female 22 patients representing (44%).

Table (4-1): Genderdistribution : .

Gender	Number	Percentages%
Male	28	56
Female	22	44
Total	50	100

Age distribution:

The mean and standard deviation of the male according to age (46.50,23.95) ,and mean ,standard deviation of female (41.59,18.14)

Table (4-2): Age distribution:

Age	Mean	\pm STD
Male	46.50	23.95
Female	41.59	18.14
Total	88.09	42.09

Table (4-3): The mean , standard deviation ,minimum and maximum of the sample variables.

Variable	Midbrain in sagittal T1	Pons in sagittal T1	Medulla in sagittal T1
Mean	18.07	23.18	8.07
SD	1.59	1.34	.80
Minimum	14.3	20.0	6.3
Maximum	21.8	25.3	9.4

The following figures presented the scatter plot diagrams of the sample age ,and the variables including (midbrain ,pons and medulla):

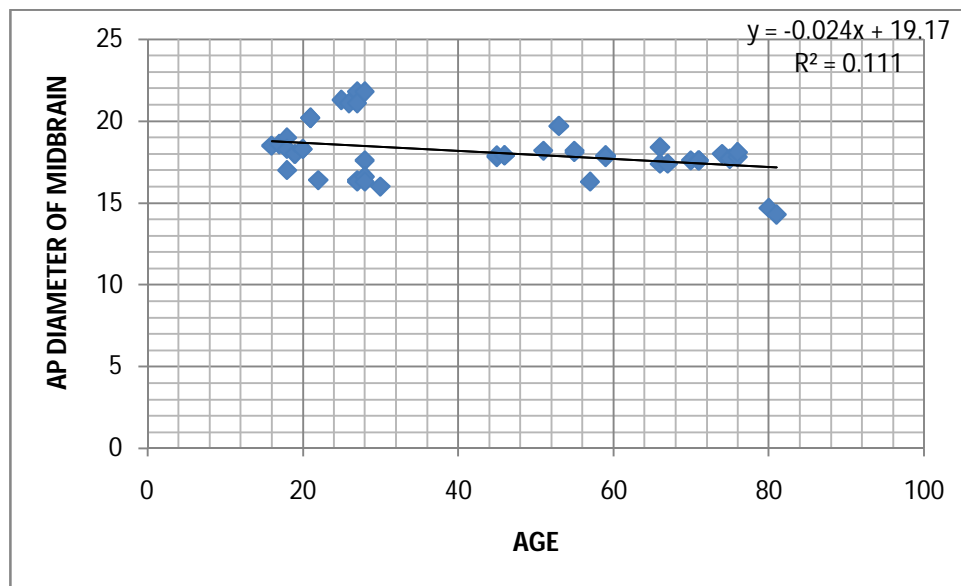


Figure (4-1)A scatter plot diagram shows the correlation between the sample age and midbrain in sagittal T1 , The diameter decrease by - 0.02 starting from 19.1 for each 20 years of age.

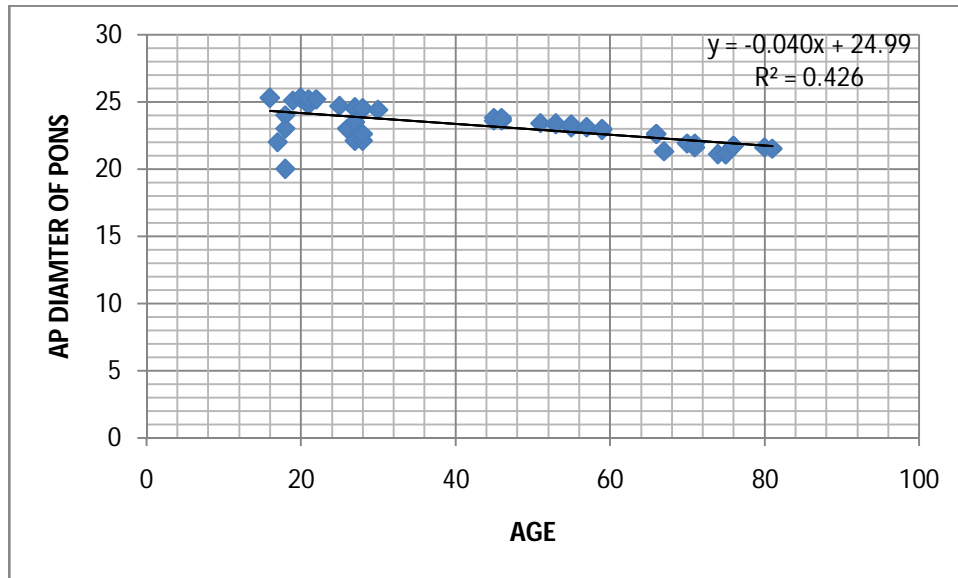


Figure (4-2):A scatter plot diagram shows the correlation between the sample age and pons in sagittal T1 ,the diameter decrease by - 0.04 starting from 24.9 for each 20 years of age .

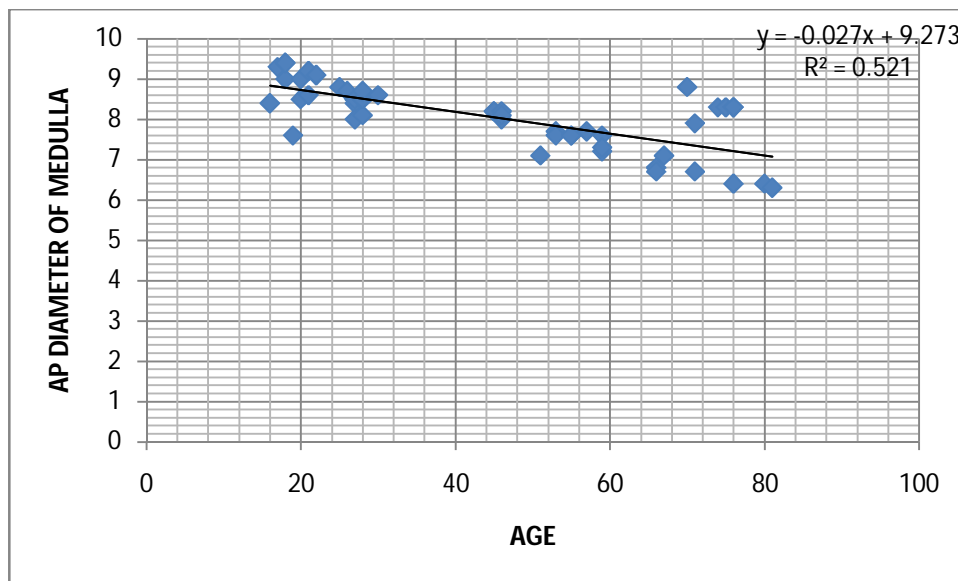


Figure (4-3) A scatter plot diagram shows the correlation between the sample age and medulla in sagittal T1 , the diameter decrease by -0.02 starting from 9.2 for each 20 years of age

Chapter five

Discussion, Conclusion and Recommendation

5.1 Discussion

-This study is aimed to evaluate normal brainstem measurement in Sudanese using MRI.to find new index for Sudanese .the study took into consideration the normal brainstem measurement correlated that with age .

-Table (2) show the sample according to age that show the mean of the male is greater than female by 4.9 and the standard deviation (STD) of the male is greater than female by 5.8 . The total mean of male and female related to age is 88.09 and the total of (STD) is 42.09 .

-Table (3) show the mean of the pons equal 23.18 greater than mean of the midbrain 18.07 and medulla 8.07 .And the standard deviation of the midbrain equal ± 1.59 is greater than (STD) of pons ± 1.34 and medulla $\pm .80$.

-Figure (4-1)A scatter plot diagram shows the correlation between the sample age and midbrain in sagittal T1 , The diameter decrease by - 0.02 starting from 19.1 for each 20 years of age .and that mean the diameter decrease with age in ,this finding agree with previous study which say the diameter decrease slightly after 45-50 years.

-Figure (4-2): A scatter plot diagram shows the correlation between the sample age and pons in sagittal T1, the diameter decrease by - 0.04 starting from 24.9 for each 20 years of age . and that mean the diameter also decrease with age increase ,that shows significant different with previous study which say the diameter increased until the age of 20 years and did not decrease .

- Figure (4-3) A scatter plot diagram shows the correlation between the sample age and medulla in sagittal T1 , the diameter decrease by -0.02 starting from 9.2 for each 20 years of age .and that mean the diameter also decrease with age increase ,this finding agree with previous study that say the diameter stopped increasing at the age of 6-8 years ,respectively ,minimal reduction occurs after 50 years .

The brainstem diameter in sagittal T1 have negative relationship with age (diameter decrease with age increase) this due to impact of several brainstem mediated functions ,for example the sleep wake cycle ,sympathetic outflow vestibular –ocular reflexes advance with age may causes shrinkage to brain stem and nerves imerge from it and this lead to hearing loss , etc.

5-2 Conclusion

The measurement of brainstem diameter for Sudanese population decrease with age .

There is no association between male and female brainstem measurement.

5-3 Recommendation:

- Further studies in measurement of brainstem with larger sample of population for more accurate results .
- Volumetric measurement may give more information than linear measurement .
- Further studies should be done with more body characteristic.

References:

Elaine N. Marieb. human anatomy and physiology .5th edition
.Hammond:OwlsBook,2014.

En.wikipedia/wiki/human-brain.

Harold Ellis,Bari M.Logan Adrian K.Dixon: Human sectional anatomy third Edition
,2007 .

[http://inforadiologie.ch/mri-sagittal-brain -tl](http://inforadiologie.ch/mri-sagittal-brain-tl) .

<http://radiologyinfo.org/en/info.cfm?PG=headm>

Lorrie et al,connie M.petersen :Sectional anatomy for imaging Professionals Second
Editions 1997;93:127 ISBN-13:978-0-323-02003-9.

R, Autti T,Vanhanen SL: The normal brainstem from infancy to old age .A
morphometric MRI study. Neuroradiology 1994; 36(5):364-368.

R. Raininko, NA C, Husain MM, Figiel GS, McDonald VM, Ellinwood EH Jr, Boyko
OB, Krishnan KR (1992) Morphometric changes of the human midbrain with normal
aging :MR and stereologic findings. AJNR 13:383-386.

Steele JR, Hoffman JC : AJR Am J Roentgenol: Measurement of normal brainstem
in adult and children by CT cisternography 1981; 136:287.

Theodore E. Keats, Christopher S. Storm, St. Louis, Missouri: Atlas of Radiologic
measurement, seventh edition 2001;27:30.

Winn RH (ed.) youmans neurological surgery. five Edition, volumes 1-4
saunders, Philadelphia, 2004.

APPENDIX

Appendices (1)

Sudan University of Sciences and Technology

College of graduate studies

Data collection sheet

No	Age	Gender	AP diameter in SAG T1		
			Midbrain	Pons	Medulla oblongata

Appendices(2)

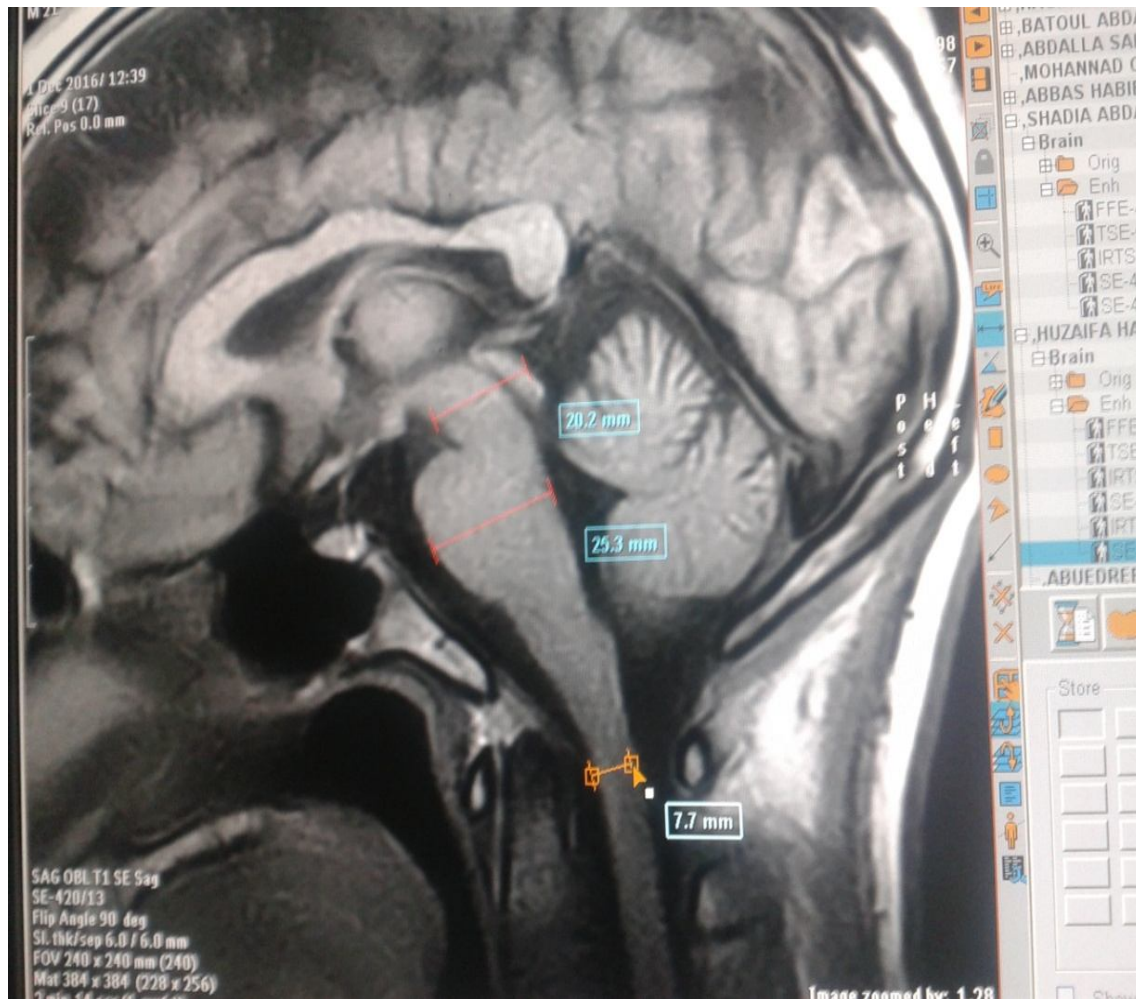


Figure A:Sagittal T1 weighting image of the brain show the measurement of mid brain, Pons and medulla oblongata In the midsagittal plane .