



**Sudan University of Science and
Technology**
**College of Postgraduate Studies and
Graduate Study**

**Assessment in Diagnosis of Schistosomiasis by
Ultrasonography**

**تقييم تشخيص البلهارسيا باستخدام التصوير بالموجات فوق
الصوتية**

**A thesis Submitted for Partial Fulfillment of the Requirement of MSD
in Medical Diagnostic Ultrasound**

:By

Fatima Elzhra Abdualla Mohamed

:Supervisor

Dr. Asma Ibrahim Ahmed Alamin

January 201



بِسْمِ اللَّهِ الرَّحْمَنِ الرَّحِيمِ

وَالْإِسْلَامِ فِيهِ لَمَجْدٌ
فَخَوَّسَ سَفِينًا

الشعراء الآية (80)

Dedication

***I am honor to dedicate this research to
the soul of my father***

***My loving family ,my husband ,mother
brothers ,and my sisters in appreciation
for their patience understanding and
never ending support***

***To super visor in this study who lit the
way for me***

***To great friends and colleagues with
whom we have spent the best time ever***

Acknowledgements

My deepest appreciation and sincerest :gratitude

To my supervisor **Dr: Asma Ibrahim** who have provided

.me with a wealth of professional joy

To all the ultrasound department, personally to Sonologist:

the director of the department for his permission &
unsparing help provided by him, also to **my tetechers in
sudan university** for their extensive & continuous teaching.
Their help and never-ending support made this work possible
..I cannot thank them enough for their efforts on this project

Abstract

The study aimed to assess the complication of schistosomiasis in Sudanese population using ultrasonography. The study conducted in Khartoum and .gazira hospital and medical centers period from March to July 2016

One hundred patient related to schistosomiasis were evaluated by ultrasonography the age group ranging between (10-70) years both gender This result show that incidence of schistosomiasis is higher in male 64% .% than female 36

Schistosomiasis is high incidence in Sudan, and there is concentration in .gazira state due to filling of area by irrigated agriculture Farmer are more vulnerable to the disease 21%. schistosoma mansoni is the most common type ,the preportal fibrosis is the first evidence of . schistosomiasis on ultrasonography evaluation 40% Ultrasound is most important tool for detection of schistosomiasis .complication

Most of schistosomiasis patient show change in liver and spleen size 80%, .gall bladder wall thickness 80% .Schistosomiasis affecting different age group

ملخص البحث

هذه الدراسة تهدف الي تقييم مضاعفات البلهارسيا لدى السودانيين باستخدام الموجات فوق الصوتية .

هذه الدراسة اجريت في بعض مستشفيات الخرطوم والجزيرة والمراكز الصحية في الفترة من ابريل حتى يوليو 2016

شملت هذه الدراسة 100 مريض من كلا الجنسين تم فحصهم بجهاز موجات فوق الصوتية تصنيع شركة الوكا تردد منخفض 3.5 ميغاهيرتز.

ووجدت الدراسة ان الاصابة عند الذكور بنسبة 64% اعلى من الاناث والاناث بنسبة 36%.

كما وجدت الدراسة ان معدل الاصابة بالبلهارسيا عالية في السودان ومركزة بنسبة عالية في ولاية الجزيرة نسبة لوجود الزراعة المروية.

اظهرت الدراسة ان البلهارسيا تصيب المزارعين بنسبة 21% اكثر من غيرهم وخاصة البلهارسيا من نوع شيستوزوما مانسوناي.

وان تليف الوريد البابي هو اول المضاعفات تشخيصا بالموجات فوق الصوتية بنسبة 40%.

معظم مرضى البلهارسيا اظهرو تغيرا في حجم الكبد والطحال بنسبة 42%, وزيادة سمك جدار المرارة بنسبة 80%.

تؤثر البلهارسيا على مختلف الفئات العمرية.

List of content

<i>i</i>	الآية
<i>ii</i>	Dedication
<i>iii</i>	acknowledgment
<i>iv</i>	Abstract
<i>v</i>	ملخص البحث
<i>vi</i>	List of content
Chapter one	
1	introduction 1-1
2	objectives 1-2
3	thesis outline 1-3
Chapter two	
5	liver anatomy 2-1-1
6	anatomy of 2-1-2 gallbladder
7	anatomy of 2-1-3 spleen
8	anatomy of 2-1-4 urinary bladder
9	physiology of 2-2-1 liver
10	physiology of gall 2-2-2 bladder
10	physiology of 2-2-3 spleen
11	physiology of 2-2-4 urinary bladder
11	pathology of liver 2-3-1
19	pathology of 2-3-2 gallbladder

22	pathology of 2-3-3 spleen
22	pathology of 2-3-4 urinary bladder
23	ultrasound 2-4-1 physics
25	ultrasound 2-4-2 technique
33	literature review(2-5-1 (schistosomiasis)
35	previous study 2-5-2
Chapter three	
37	material 3-1
38	methods 3-2
Chapter four	
39	Analysis and result

Chapter five		
53		Discussion
56		Conclusion
57		Recommendation
58		References
59		Appendices

:Introduction .1-1

Schistosomiasis, also known as bilharzias (bill-Har-zi-a) or snails fever is primary tropical parasitic disease, caused by the larvae of species of flat worms or blood flukes known as schistosomes. The name bilharias came from Theodor Bilharz, a German pathologist, who identified the worm in 1852 in Cairo. The disease in human are schistosoma mansoni, haematobium, japonicum and mekongi, schistosoma haematobium cause urinary schistosomiasis, while the others cause hepatosplenic and intestinal schistosomiasis, schistosoma mansoni had been noted by Sir Patricle Manson, a physician to the seamen's hospital in Greenwich. He noted that the eggs which were found in the faeces have a lateral spine which is different from those schistosoma haematobium. *Carol1998*

The disease is of great public health important in endemic areas. In Sudan, schistosomiasis is the most important parasitic disease after malaria. Those who are affected are the children and young adults and this is the age of learning and productivity respectively. In high endemic areas, severe schistosoma mansoni infection affects a significant proportion of the population, the disease involve the colon, liver and spleen and causes biological reactions such as splenomegaly and hepatic fibrosis in the first stage, and later portal hypertension. Sudden life-threatening hemorrhage may occur due to the rupture gastro-esophageal varices, the most common complication is portal hypertension. Ascites also may be present. Other complications of schistosoma can be present involving urinary system, central nervous system and the lungs. *Carol1998*

There are many parameters used to assess the success of investigation of schistosoma like egg-count which measure the level of infection but does not reflect the actual pathological changes occur, how fast and how far they can be reversed by treatment. Some signs of schistosoma infection may be reported by patients, such as However, these signs are not specific. Clinical examinations should include signs of anemia, liver enlargement and changes in liver and spleen consistency. Since the method for detecting liver enlargement is not standardized, the procedure used must be clearly reported. In adults, the left liver lobe is generally considered to be enlarged when palpation and / or percussion detect it more than 3cm below the xiphoid process. The right liver lobe is usually assessed in the right midclavicular line; in adults it is considered enlarged if it extends more than 2cm below the costal margin, or 12cm as assessed by combined percussion and palpation. In children, liver palpably may vary from 0-2.5cm to 0-4cm below the costal margin, depending on age. For enlargement of the spleen. Clinical examination should also look for subcutaneous collaterals and ascites. Rectal biopsies taken during rectoscopy can confirm intestinal involvement. Schistosoma eggs may be detected in microscopic examination of fresh samples. Histological examination can show whether the eggs are surrounded by an inflammatory granuloma. More invasive examinations such as colonoscopy or a barium enema can only be carried out in a hospital.

It has been suggested that ultrasound is a suitable method to obtain such information. Now ultrasound is established as a safe, rapid, non-invasive, inexpensive and less time consuming technique for assessing schistosoma and related morbidity in individuals and in community survey **Carol1998**

:Objectives .1-2

Generally .1-2-1

To determine the role of ultrasound in diagnosis of
.schistosomiasis

Specifically .1-2-2

.Evaluation of incidence of schistosoma in Sudan .1-2-2-1

.To demonstrate the complications of schistosomiasis .1-2-2-2

Thesis out line .1-8

Chapter one: introduction

.Chapter two: literature review

.Chapter three: original study and results

Chapter four: discussion, conclusion, recommendations, references and
.appendixes

Chapter two

anatomy

Liver anatomy 2-1-1

The liver, the largest gland in the body, weights approximately 1500gm and receives about 1500ml of blood per minute. The wedge-shaped organ occupies most of the right hypochondrium and epigastrium. *Chummy2005*

Lobes The liver was customarily divided by anatomists into a larger right and a smaller left lobe utilizing the line of attachment of the falciform ligament anteriorly and the fissures for the ligamentum teres and ligamentum venosum on the visceral surface. The caudate lobe, lying between the inferior vena cava and the fissure for the ligamentum venosum, and the quadrate lobe, lying between the gallbladder fossa and the fissure for ligamentum teres. *Chummy2005*

Blood supply 2-1-1-2

The liver receives blood from two sources. Arterial (oxygenated) blood is furnished by the hepatic artery, which divides into right and left branches in the porta hepatis. The right branch of the hepatic artery normally passes behind the common hepatic duct and in the liver divides into anterior and posterior sectoral branches; the left branch divides into medial and lateral sectoral branches. Sometimes the common hepatic artery arises from the superior mesenteric artery or the aorta (instead of the coeliac trunk), in which case it usually runs behind the portal vein. The right hepatic artery may arise from the superior mesenteric artery (15%) and the left hepatic artery from the left gastric artery (20%) as aberrant or accessory arteries; i.e. .they may either replace the normal branches or exist in addition to them

Venous blood is carried to the liver by the portal vein which divides in the porta hepatis into the right and left branches which in turn give sectoral branches like the arteries; this portal blood is laden with the products of digestion which have been absorbed from the alimentary canal, and which are metabolized by the liver cells. *Chummy2005*

Lymph drainage .2-1-1-3

The lymphatic of the liver drain into three or four nodes that lie in the porta hepatis (hepatic nodes). These nodes also receive the lymphatics of the gallbladder. *Chummy2005*

:Anatomy of the gallbladder 2-1-2

The gallbladder is a globular or pear– shaped viscous, about 8– 12cm in length with a capacity of about 30– 50ml and consists of three parts; fundus, body and neck. It lies in the gallbladder fossa on the visceral surface of the .(right lobe of the liver, adjacent to the quadrate lobe (Fig: 2-2

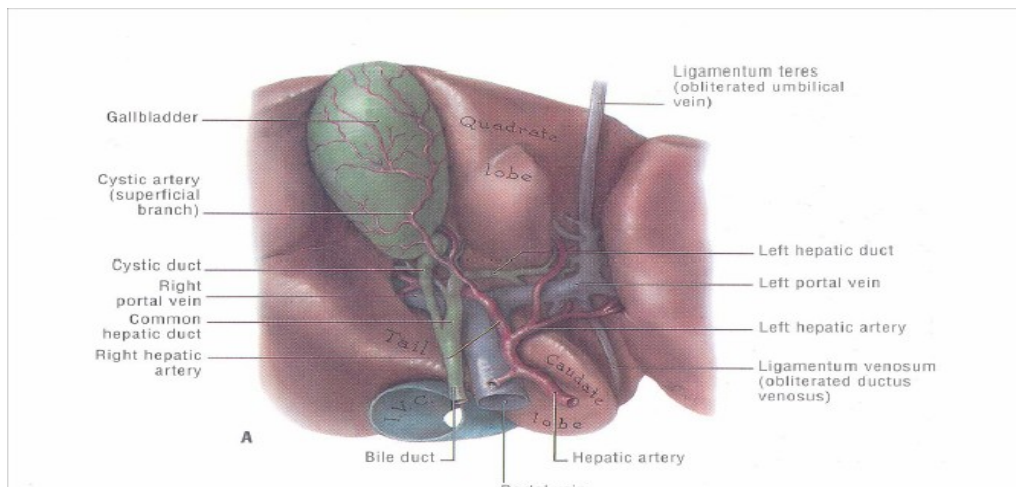


Fig: (2-2). The gallbladder. *Chummy2005*

Blood supply .2-1-2-1

The gallbladder is supplied by the cystic artery; the cystic artery is usually a branch of the right hepatic. It runs across a triangle formed by the liver, common hepatic duct, cystic duct (*Calot's triangle*) to reach the gallbladder

Venous drainage .2-1-2-2

The cystic veins join the right branch of the portal vein. The veins of the fundus and body of the gallbladder pass directly into the liver. *Sinnatam Chummy2005*

Lymph drainage .2-1-2-3

Lymphatic channels from the gallbladder drain to node in the porta hepatis to the cystic node (*in Calot's triangle at the junction of the common cystic duct*), and to node situated at the anterior boundary of the epiploic foramen, from there lymph pass to the celiac group of pancreatic nodes. *Chummy2005*

Anatomy of the spleen .2-1-3

The spleen is the largest of the lymphoid organs, lies under the diaphragm on the left side of the abdomen, and although not part of the alimentary tract .it drains to the portal venous system *Chummy2005*

It measures 1×3×5 inches, weighs 7 oz and lies between the ninth and eleventh ribs (Fig: 2-3). These are average measurements; the size of the spleen varies considerably. *Chummy2005*

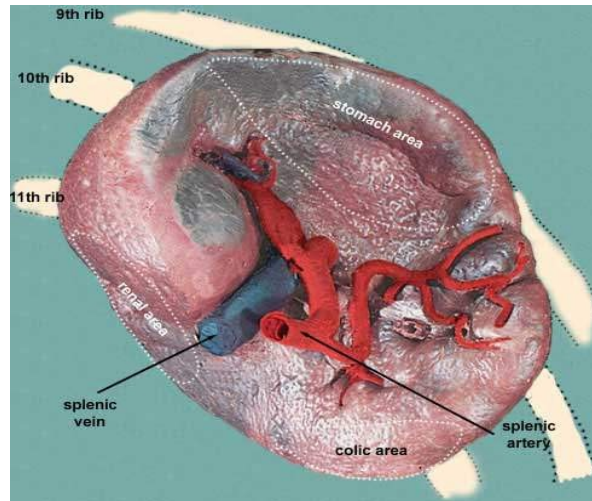


Fig: (2-3). The spleen. Chummy2005

Blood supply .2-1-3-1

The splenic artery passes between the layers of the lienorenal ligament and at the hilum divides into two or three main branches, from which five or more branches enter the spleen. Veins accompany the arteries and unite to form the splenic vein. Based on the vascular arrangement, it is possible that the spleen consists of two or three segments, with intersegmental vessels being small and scanty, but the evidence for such segmentation is not conclusive. Chummy2005

Lymph drainage .2-1-3-2

Lymph drains into several nodes lying at the hilum and thence, by way of the pancreaticosplenic nodes, to the celiac nodes. Chummy2005

Anatomy of urinary bladder .2-1-4

The bladder is made of smooth muscle arranged in whorls and spirals – the detrusor muscle. It is adapted for mass contraction, not peristalsis. The muscle is lined by a loose and readily distensible mucus membrane, surfaced by transitional epithelium. *Chummy2005*

The form and size of the bladder are the same in both sexes. The distended bladder is globular (ovoid) in both sexes, while the empty bladder is flattened from above downwards by the pressure of the overlying intestines. *Chummy2005*

Blood supply .2-1-4-1

The superior and inferior visceral arteries provide most of the arterial blood but there are small contributions to the lower part of the bladder from .the obturator, inferior gluteal, uterine and vaginal arteries

The veins of the bladder do not follow the arteries. They form a plexus that converges on the *vesicoprostatic plexus* in the groove between bladder and prostate and which drains backwards across the pelvic floor to the internal iliac veins *Chummy2005*

Lymph drainage .2-1-4-2

The lymphatics of the bladder follow the arteries backwards to internal and external iliac nodes. *Chummy2005*

Physiology .2-2

Physiology of the liver .2-2-1

The functions of the liver are so numerous that it is convenient to group them under three subheadings: vascular, secretory and metabolic functions.

2-2-1-1 Vascular functions

Storage. Since the liver blood flow is 30% of blood volume, it is one of the important reservoirs of blood in the body. In the case of strenuous exercise or hemorrhage, part of the hepatic blood is diverted towards the exercising muscles or the vital organs, respectively. ^{Ganong,2005}

Secretory functions 2-2-1-2

The liver continuously secretes bile, which, after storage and concentration in the gall-bladder, is discharged into the duodenum. ^{Ganong,2005}

Synthesis function 2-2-1-3

The liver synthesizes many useful substances such as albumin and the coagulation factors. Hepatic failure therefore results in hypoalbuminaemia and bleeding disorders. ^{Ganong,2005}

Metabolic functions 2-2-1-4

The liver has a central role in the metabolism of the major types of foodstuffs as well as substances of endogenous or exogenous origin. Details about these metabolic processes may be obtained by reference to specialized texts. ^{Joseph2006}

Physiology of the gallbladder 2-2-2

Its primary function is to store and concentrate bile, a yellow-brown digestive enzyme produced by the liver. The gallbladder is part of the biliary tract. Guyton & Hall,1996

The gallbladder serves as a reservoir for bile while it's not being used for digestion. The gallbladder's absorbent lining concentrates the stored bile. When food enters the small intestine, a hormone called cholecystokinin is released, signaling the gallbladder to contract and secrete bile into the small intestine through the common bile duct. Prof. M. A. Taher2006

Physiology of the spleen .2-2-3

Phagocytosis. The macrophages in the red pulp of the spleen phagocytose old erythrocytes, leucocytes and platelets as well as any circulating microorganism. These cells also engulf foreign materials (antigens). Taher2006

Erythropoiesis. In the human fetus the spleen is a site of red blood cell formation from the fourth month of intrauterine life. The red pulp is capable of resuming this function in adult life in myeloid leukemia and certain other disorders. Taher2006

Lymphopoiesis. The white pulp of the spleen is an important source of lymphocytes and large mononuclear cells

Immune response. When the body's immune system is responding to the presence of an antigen the macrophages in the spleen increase in number and the lymphoid tissue in the spleen also enlarges Taher2006

Physiology of the urinary bladder .2-2-4

The urinary bladder stores and controls the elimination of urine.

Micturition is a function of the peripheral autonomic nervous system,
subject to facilitation or inhibition from higher neurologic centers. ^{Joseph2006}

Pathology .2-3

Pathology of the liver .2-3-1

Congenital malformations .2-3-1-1

Cystic disease of the liver (Fig: 2-4). Congenital cysts in the liver are rare and are usually associated with cystic disease of the kidney; the latter condition, however, occurs much more commonly alone. The cysts vary greatly in size and number. ^{Palmer. S1995}

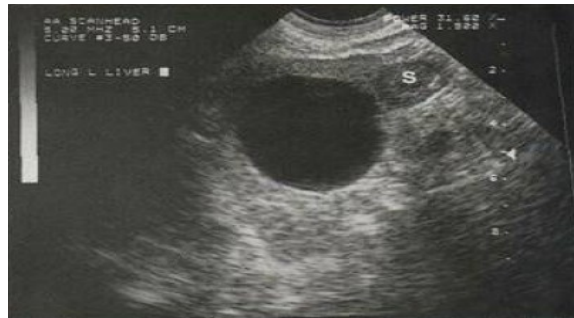
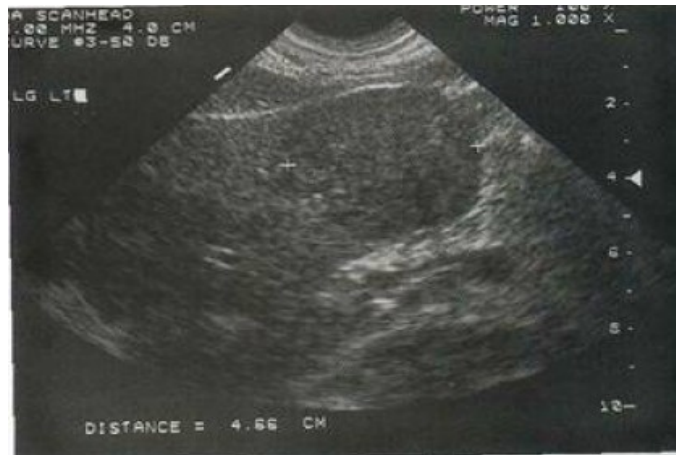
Fig: (2-4). Simple hepatic cyst. Palmer. S1995

Focal nodular hyperplasia (Fig: 2-5). This is a benign circumscribed hamartomatous lesion in which there is a focal aggregation of hyperplastic liver cell nodules separated by fibrous septa. It is usually found incidentally and may be mistaken for tumour



.Fig: (2-5). The isoechoic solid lesion indicated by the calipers is a FNH Palmer. S1995

Hepatitis .2-3-1-2

Hepatitis literally means any inflammatory lesions of the liver. In practice the term is not used for local lesions, such as an abscess, but only when there is diffuse involvement of the liver. Hepatitis may be classified on an etiological basis, and some types are best dealt with under the separate headings of alcoholic hepatitis and drug-induced hepatitis. ^{Burwin2007}

Acute viral hepatitis .2-3-2-1

This is an acute infection characterized by diffuse hepatitis with widespread liver cell necrosis. there are three well characterized viral types – hepatitis A (HAV), hepatitis B (HBV) and hepatitis D (HDV), and a less well characterized non-A: non-B group which includes A number of different viral infection. ^{Burwin2007}

Hepatitis A has an incubation period of 15-40 days, is transmitted by the faecal-oral route and occurs both endemically and as epidemics. The infective agent is a picornavirus and associated 27nm particle occur in the blood and faeces 3-4 weeks after exposure. . ^{Burwin2007}

Hepatitis B has an incubation period of 50-180days; it is most frequently transmitted by blood and blood products. Whereas transmission was at one time a hazard of blood transfusion, the screening of blood donors for serum markers of HBV has virtually eliminated this. The virus may also be present in body fluids, saliva semen and vaginal secretion and may also be transmitted by intimate physical contact including from mother to child and sexually. ^{Burwin2007}

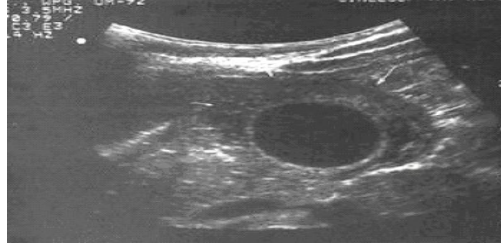


Fig: (2-6). Hepatitis B, enlarged, rounded liver border and dilated GB. ^{Burwin2007}

Hepatitis C This has an incubation period of 42-90 days, is transmitted by blood and blood products and is now the most important cause of post-transfusion hepatitis. It is prevalent among intravenous drug addicts and co-infection with HBV can occur. ^{Burwin2007}

Chronic Hepatitis .-2-3-1-3

Chronic hepatitis is defined as inflammation of the liver continuing without improvement for at least 6 months. Chronic inflammation is also a feature of alcohol-induced liver injury, long-standing biliary obstruction, Wilson's disease and other metabolic disorders ^{Burwin2007}

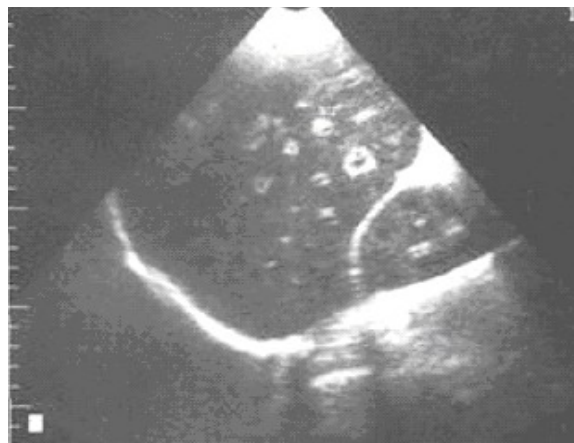

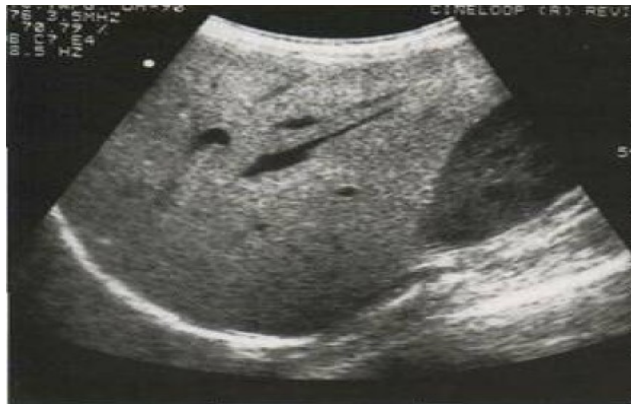Fig: (2-7). Chronic hepatitis with increased periportal brightening. ^{Burwin2007}

Alcoholic Liver Disease .2-3-1-4

The changes in the liver brought about by high alcohol consumption include fatty liver, alcoholic hepatitis, and cirrhosis. Fatty change alone is a reversible disorder, while alcoholic hepatitis is considered to be precursor of cirrhosis . Burwin2007

Alcoholic fatty liver .2-3-1-4-1

Under controlled condition alcohol administration has been shown to produce hepatic fatty change regularly in man (Fig: 2-8). After a single dose of alcohol the fatty acids which accumulate in the liver are derived form fat depots. Burwin2007



.Fig:(2-8). Fatty infiltration Burwin2007

Alcoholic hepatitis and cirrhosis .2-3-1-4-2

In contrast to our understanding of alcohol-induced fatty liver, the metabolic events that lead to the development of alcoholic hepatitis and cirrhosis are still not understood. Both the volume of alcohol and the duration of alcohol abuse are related to the development of these lesions. In alcoholic hepatitis, which is usually superimposed on a fatty liver, there is

ballooning and necrosis of hepatocytes, associated with a neutrophil polymorph reaction. The hepatitis develops a round hepatic vein branches

Burwin2007

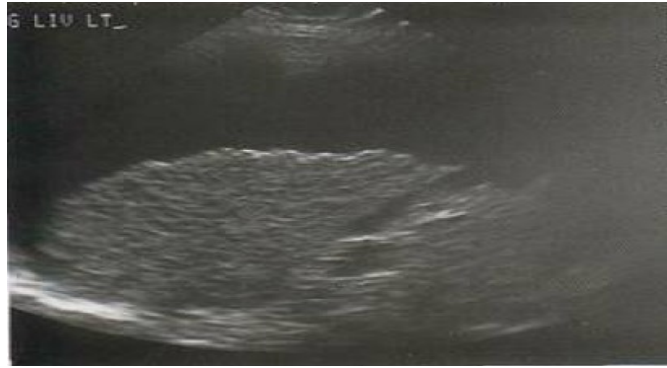
Fibrosis is an early feature, showing a pericellular distribution, and with continued liver cell loss, fibrous septa are formed. In some instances the hepatitis is severe with diffuse parenchymal involvement leading to liver failure. *Palmer. P. E. S1995*

Continuing alcoholic hepatitis results in progressive fibrosis and scarring; fibrous septa extend and form links between contiguous perivenular areas and between hepatic veins and portal tracts. The architecture is increasingly distorted and eventually a micronodular cirrhosis is established. If there is still further parenchymal cell loss and fibrosis, with accompanying nodular regeneration, the end-stage liver (Fig: 2-9) may show a mixed a macronodular cirrhosis. *Palmer. S1995*

Cirrhosis is a condition involving the entire liver in which the parenchyma is changed into a large number of nodules separated from one to another by irregular branching and anastomosing sheets of fibrous tissue.

Palmer. P. E. S1995

It is important to emphasize that the changes of cirrhosis affects the whole liver. Localized scarring, for example post-hepatic or focal nodular hyperplasia, is not included within the term cirrhosis; nor are mild degrees of more generalized hepatic fibrosis unaccompanied by loss of normal architecture as seen in *schistosomiasis*. *Burwin2007*



.Fig: (2-9). End stage cirrhosis *Burwin2007*

.Parasitic infection .2-3-1-5

Schistosomiasis: Infestation by schistosoma mansoni and schistosoma japonicum produces hepatic fibrosis. It is the most important cause of portal hypertension in endemic areas and, indeed, is the commonest cause on a worldwide basis. ^{Burwin2007}

Amoebic abscess (Fig:2-10) due to *Entamoeba histolytica* may complicate amoebic dysentery or may occur as an isolated lesion after the colonic disease has subsided. ^{Burwin2007}

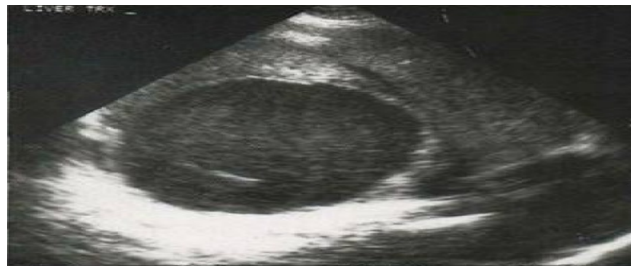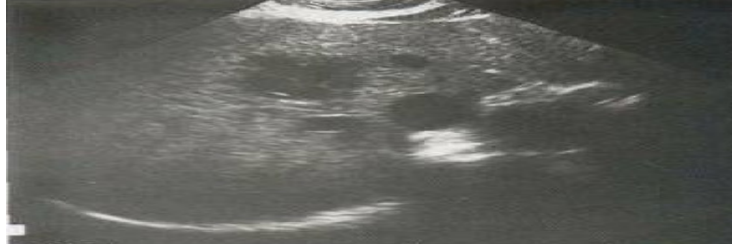


Fig: (2-10). Amoebic liver abscess. ^{Burwin2007}

Benign tumours .2-3-1-6

Benign tumours of the liver are rare, comprising approximately 5% of all hepatic neoplasms

Hemangiomas, (Fig: 2-11) usually cavernous, dark purple and sharply demarcated from the surrounding hepatic tissue, are common. Most are less than 2cm in diameter, but some are larger. They are usually superficial and may be mistaken for infarcts. ^{Burwin2007}



.Fig: (2-11). Hemangioma ^{Burwin2007}

Liver Cell Carcinoma .2-3-1-7

Liver cell carcinomas account for approximately 85% of primary malignant tumours of the liver, bile duct carcinomas for approximately 5-10% and the remainder are relatively rare tumours including

.hemangiosarcoma, hepatoblastoma, and mesenchymal tumours ^{Burwin2007}

(*Hepatocellular carcinoma* (Fig: 2-12

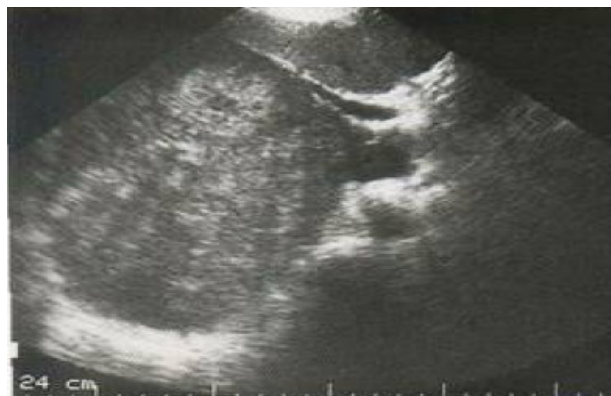

Fig: (2-12). Hepatocellular carcinoma. ^{Burwin2007}

Secondary tumours .2-3-1-8

The liver is one of the commonest sites of secondary carcinomas (Fig: 2-13) of all kinds, notably from the gastrointestinal tract, lung and breast

Burwin2007

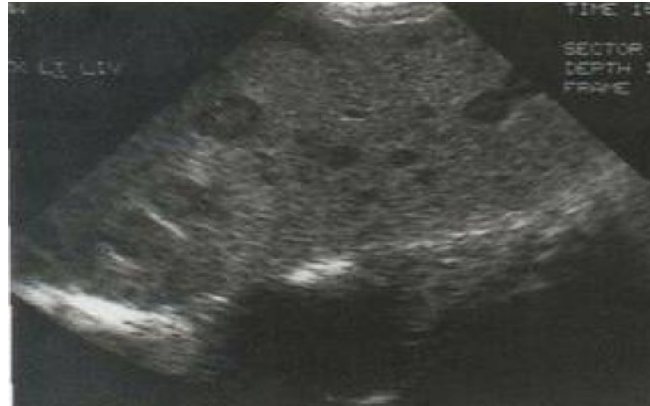


Fig: (2-13). Liver metastasis. (Bull's Eye). *Burwin2007*

Jaundice .2-3-1-9

Jaundice may develop as a complication of diseases of the gallbladder and pancreas. Jaundice is a clinical sign which is the result of yellow discoloration of the tissues with bilirubin. It is important to appreciate that jaundice and cholestasis are not synonymous terms as patients with jaundice may not be cholestatic and cholestatic patients may not be jaundiced. Jaundice generally appears first in the sclerae and when the serum bilirubin concentration reaches values of 35-50 μ mol/l generalized jaundice appears

Burwin2007

Portal hypertension .2-3-1-10

The normal portal venous pressure is 7mmHg (0.9kPa). Portal hypertension occurs when there is obstruction to the blood flow within the liver or obstruction of the portal vein itself. The obstruction may be post-sinusoidal as in cirrhosis, veno-occlusive disease, hepatic vein obstruction, alcoholic hepatitis and congestive cardiac failure or pre-sinusoidal as in *schistosomiasis*, congenital hepatic fibrosis and portal vein occlusion. Massive splenomegaly with increase splenic blood flow can also cause portal hypertension in the absence of obstruction. The effects of portal hypertension result from some of the portal blood bypassing the liver and entering the systemic veins at sites of portal-systemic anastomosis

:Portal-systemic anastomoses with varicosity of veins occur in

The lower esophagus and upper gastric fundus, between the left gastric .

;(vein (*portal*) and the azygos minor vein (*systemic*

The lower rectum and anus, between the superior hemorrhoidal (*portal*) .

;(and the middle and inferior hemorrhoidal veins (*systemic*

Pathology of the gallbladder .2-3-2

(Gallstones (cholelithiasis .2-3-2-1

Gallstones (Fig:2-14) are formed constituents of the bile-cholesterol, bile pigments and calcium salts-in various proportions, along with other organic material. They form usually in the gallbladder, but may also develop in the .extrahepatic biliary tree and occasionally within intrahepatic ducts ^{Burwin2007}

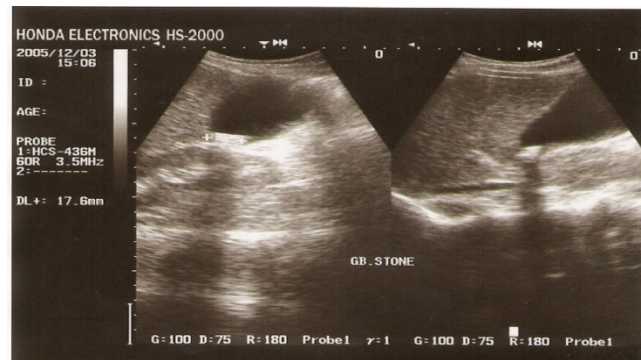


Fig: (2-14). Gallbladder stone. ^{Burwin2007}

Cholecystitis .2-3-2-2

Inflammation of the gallbladder is one of the commonest causes of abdominal pain. And frequently necessitates cholecystectomy. ^{Burwin2007}

Acute cholecystitis .2-3-2-2-1

Acute cholecystitis is nearly always associated with the presence of stones (Fig: 2-15). In the early stages of acute cholecystitis bacteria cannot usually be cultured from the gallbladder. Therefore it is thought that initial inflammation chemically induced. Obstruction to the outflow of bile by stone results in the bile becoming overconcentrated ^{Burwin2007}

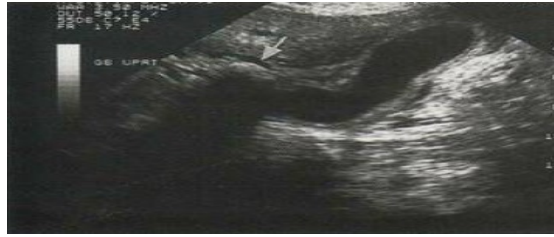

Fig: (2-15). Acute cholecystitis with impacted stone in GB neck (arrow). *Burwin2007*

chronic cholecystitis .2-3-2-2-2

This may result form repeated attacks of acute cholecystitis. In many patients, however, the disease is one of insidious onset, accompanied by dyspeptic symptoms or biliary colic. Gallstones are almost always present (Fig: 2-16). The gallbladder wall is shrunken and shows marked fibrous thickening *Burwin2007*

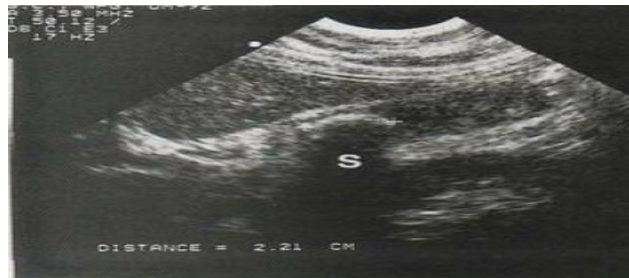

Fig: (2-16). Chronic cholecystitis. *Burwin2007*

Biliary Sludge .2-3-2-2-3

The term '**biliary sludge**' (Fig: 2-17) describes bile which is in a gel form that contains numerous crystals or microspheruliths of calcium bilirubinate granules and cholesterol crystals as well as glycoprotein. This is thought to be the mechanism whereby many cholesterol stones form. Biliary sludge is formed frequently under normal conditions, but then either dissolves or is cleared by the gallbladder and only in about 15% of patients does it persist to form cholesterol stones. *Burwin2007*

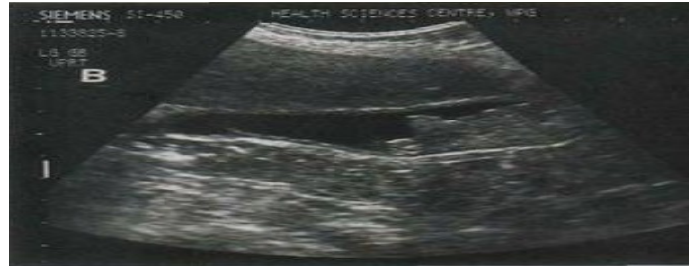

Fig: (2-17). Biliary sludge. *Burwin2007*

Adenomyomatosis.2-3-2-3

Adenomyomatosis (Fig: 2-18) is a benign condition characterized by hyperplastic changes of unknown etiology involving the gallbladder wall and causing overgrowth of the mucosa, thickening of the muscular wall, and formation of intramural diverticula or sinus tracts termed *Rokitansky–Aschoff* sinuses *Burwin2007*

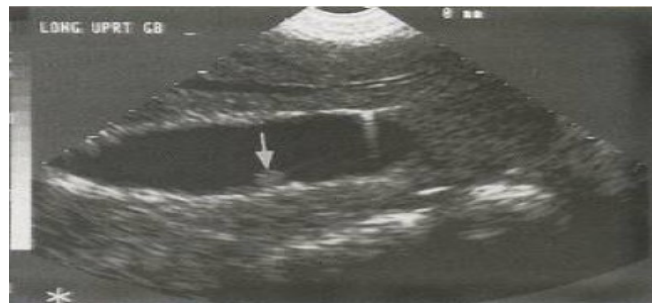

Fig: (2-18). Adenomyomatosis. *Burwin2007*

Polypoid lesions .2-3-2-4

Polypoid lesions of the gallbladder can be divided into benign and malignant categories. *Malignant polypoid* lesions include carcinoma of the gallbladder(Fig: 2-20),, *Benign polypoid* lesions of the gallbladder are divided into true tumours and pseudotumours. Pseudo tumours account for most of polypoid lesions of the gallbladder, and include polyps, hyperplasia, ..(and other miscellaneous lesions(Fig: 2-19

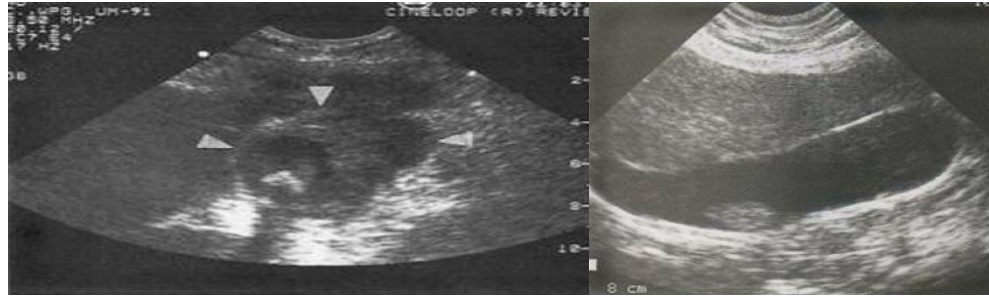

Fig: (2-19). Adenomatous polyp. Fig: (2-20). Gallbladder cancer. *Burwin2007*

Pathology of the spleen .2-3-3

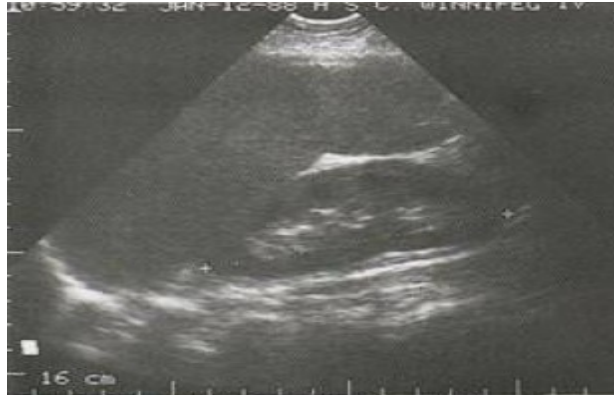Inflammatory and immunological diseases .2-3-3-1

Splenic enlargement commonly takes place when pathogenic micro-organisms – bacterial, viral, fungal or protozoal- have been present in the bloodstream for prolonged periods. The protozoal infections provide some .of the most striking examples of massive splenic enlargement. *Burwin2007*

Neoplastic states .2-3-3-2

Splenomegaly (Fig: 2-21) is a major feature of hematological tumours.

..This is especially true of the chronic leukemia. *Burwin2007*



.Fig: (2-21). Splenomegaly. *Burwin2007*

Pathology of the urinary bladder .2-3-4

Bladder calculi .2-3-4-1

These may be single or multiple: they are sometimes numerous and like coarse sand. They are now relatively uncommon in developed countries. In many cases calculi form first in the renal pelvis, especially uric acid and oxalate calculi, and pass to the bladder where they increase in size. The larger calculi vary greatly in composition and structure, but as a rule there is .a nucleus of primary stone surrounded by concentric laminae. *Burwin2007*

Cancer of the bladder .2-3-4-2

Bladder cancer fall into two major groups: superficial and invasive, according to their natural history Although the cause of bladder cancer is unknown. ^{Palmer. S1995}

Transitional cell carcinoma, nearly all tumours of the urinary tract arise .from the transitional epithelial lining

Squamous cell carcinoma, also occurs in the urinary tract: in some instances it arises from squamous metaplasia attributable to the presence of calculi and chronic infection. ^{PalmerS1995}

Ultrasound technique .2-4

Ultrasound physics .2-4-1

Medical ultrasound, also called *sonography*, is a mode of medical imaging that has a wide array of clinical applications, both as a primary modality and as an adjunct to other diagnostic procedures. The basis of its operation is the transmission of high frequency sound into the body followed by the reception, processing, and parametric display of echoes returning from ..structures and tissues within the body ^{Burwin2007}

It is technique that uses sound waves to study and treat hard– to– reach body areas; it also represents a method of obtaining images from inside the human body through the use of high frequency sound waves. In scanning with ultrasound, high– frequency sound waves are transmitted to the area of interest and the reflected sound wave echoes are recorded and displayed as a real– time visual image. No ionizing radiation (X– ray) is involved in

ultrasound imaging. Ultrasound is a useful way of examining many of the body's internal organs, including the heart, liver, gallbladder, spleen, pancreas, kidneys, urinary bladder, vagina and uterus. ^{Burwin2007}

Because ultrasound images are captured in real– time, they can show movement of internal tissues and organs, and enable operator to obtain a lot of important information. ^{Burwin2007}

Ultrasound is the name given to high– frequency sound waves, over 20000 cycles per second (20 KHz). These waves, inaudible to humans, can be transmitted in beams and are used to scan the tissues of the body. ^{Burwin2007}

Ultrasound pulses that produced by the scanners used in medical sonography are of a frequency from 2 to 10 MHz (1 MHz is 1,000,000 cycles per second). The duration of the pulse is about 1 microsecond (*a millionth of a second*) and the pulses are repeated about 1000 times per second. Different tissues alter the waves in different ways: some reflect directly while others scatter the waves before they return to the transducer as echoes. The waves pass through the tissues at different speeds (*for example, .1540 meters per second through soft tissues*). ^{Burwin2007}

The reflected ultrasound pulses detected by the transducer need to be amplified in the scanner. The echoes that come from deep within the body are more attenuated than those from the more superficial parts, and therefore require more amplification. Ultrasound scanners have controls that can alter the overall sensitivity, the "*threshold*", of the instrument, as well as change the amplification of the echoes from different depths. When working with any scanner it is necessary to achieve a balanced image, one that contains

echoes of approximately equal strengths from all depths of tissue. When the echoes return to the transducer, it is possible to reconstruct a two-dimensional map of all the tissues that have been in the beams. The information is stored in a computer and displayed on a video (television) monitor. Strong echoes are said to be of "*high intensity*" and appear as .brighter dots on the screen

The ultrasound waves are generated by a *piezoelectric transducer* which .is capable of changing electrical signals into mechanical (ultrasound) waves The same transducer can also receive the reflected ultrasound and change it back into electrical signals. Transducers are both transmitters and receivers .of ultrasound. ^{Burwin2007}

There are different modes of ultrasound; the various modes show the :retuning echoes in different ways

A- mode: With this type of ultrasound unit, the echoes are shown as peaks, and the distances between the various structures can be measured. This pattern is not usually displayed but similar information strength is used ..to build the two- dimensional of echo B- mode image ^{Burwin2007}

B- mode: This type of image shows all the tissue traversed by the ultrasound scan. The images are two- dimensional and are known as B- mode images or B- mode sections. If multiple B- mode images are watched .in rapid sequence, they become real- time images. ^{Burwin2007}

Real- time: This mode displays motion by showing the images of the part of the body under the transducer as it is being scanned. The images change with each movement of the transducer or if any part of the body is moving (for example, a moving fetus or pulsating artery). The movement is

shown on the monitor in real time, as it occurs. In most real– time units, it is possible to "freeze" the displayed image, holding it stationary so that it can .be studied and measured if necessary. ^{Burwin2007}

M– mode: Is another way of displaying motion. The result is a wavy line.

.The mode is most commonly used for cardiac ultrasound. ^{Burwin2007}

Standard protocols for ultrasound examination: *S. mansoni* .2-4-2

The investigations recommended were designed to assess periportal fibrosis, portal hypertension (dilatation of the portal and splenic veins and porto-systemic collaterals) and enlargement of the liver and spleen. In practice, the standardization of some of the suggested procedures proved to be difficult, especially in early or mild infections, owing to the complexity .of the portal tree and the variable location of lesions. ^{Burwin2007}

An additional method for assessing periportal fibrosis is proposed, comparing the observed liver texture with a series of standard reference patterns. Measurements of organ size and vein diameter should be height-adjusted, using standard reference measurements for healthy members of the .same population group. ^{Burwin2007}

Equipment.2-4-2-1

Linear, convex or sector transducers may be used to assess pathology of the liver, spleen and abdominal vessels. Visualization is usually easier with a .convex or sector probe

Measurements are more accurate using a linear probe. The protocol must always state which probe was used. ^{Burwin2007}

Preparation.2-4-2-2

.The patient should have fasted for at least 4 hours before the examination

Standard views

Longitudinal liver scans .2-4-2-3

.1a Left parasternal longitudinal view

With the abdominal aorta as reference, measure the left liver lobe from the upper to the caudal margin in the left parasternal line (PSL). This view is similar to the one used to demonstrate paraumbilical and coronary vein

..collaterals ^{Burwin2007}

.1b Right mid-clavicular view

Used to assess the size of the right liver lobe in the right midclavicular

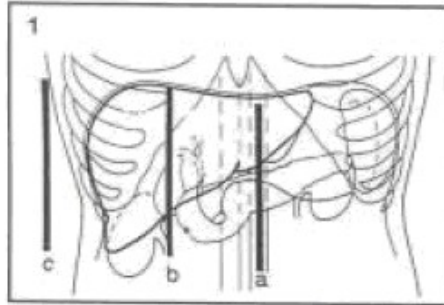
.line (MCL). ^{Burwin2007}

.1c Right anterior axillary view

The probe should be placed vertically, in a section through the right kidney as reference. This view is used to assess the echogenicity of the liver parenchyma by comparing it with the echogenicity of the kidney. A normal liver in children and adolescents is slightly less echogenic than the kidney, whereas in adults it is slightly more echogenic than the kidney parenchyma. If present, *ascites* can be seen with this view. Used to assess the size of the right liver-lobe (Fig: 2-22). ^{Burwin2007}

Substernal transverse view .2-4-2-4

Used to assess the shape of the left liver lobe and to detect the coronary vein. This is one of the views particularly useful for comparing the liver appearance with an image pattern. In this view the peripheral portal branches (of second order emerging from the left portal branch) are visualized (Fig:2 24



.Fig: (2-22). Longitudinal liver scan. *Burwin2007* .

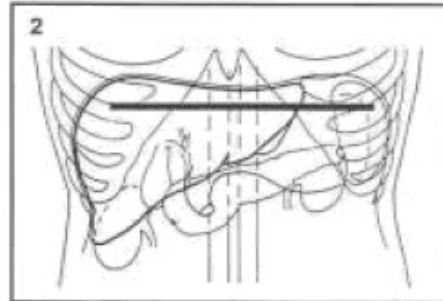


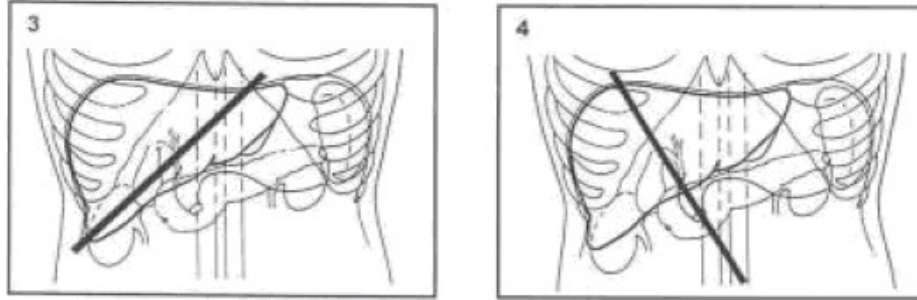
Fig: (2-23). Substernal transverse view

Subcostal transhepatic view .2-4-2-5

The probe should be placed below the right costal margin and directed cephalic. This view is used to assess the liver surface and parenchyma appearance, to detect deviation of hepatic veins, and to measure periportal wall thickening of the peripheral branch. This is another view that is particularly useful for assigning an image pattern to the picture of the liver parenchyma (Fig: 2-25). *Burwin2007*

Right oblique view .2-4-2-6

The point of reference should be where the maximum diameter of the portal vein is seen. Usually the diameter of the portal vein is measured at this position. Portal vein measurements must be performed with the patient quietly breathing, avoiding forced inspiration (Fig:2- 26). *Burwin2007*

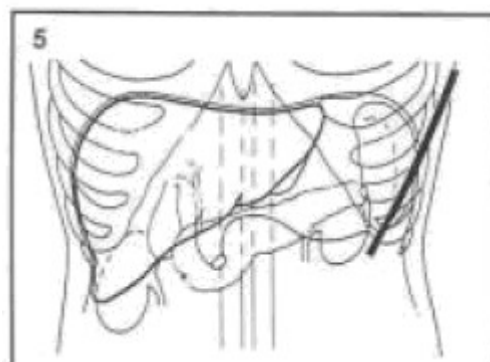


.Fig: (2-24). Subcostal transhepatic view . Fig: (2-25). Right oblique view. *Burwin2007*

Left intercostal oblique view .2-4-2-7

The probe is placed in a section through the splenic hilus as the point of reference. Splenic varices are visualized in this view

The probe is then adjusted until the major longitudinal diameter of the spleen is seen. When splenomegaly is present, spleen length usually exceeds the dimensions of the transducer. In such cases, spleen length can be assessed by marking the upper tip on the patient's abdomen, then moving the transducer downwards until the lower tip is visualized. The distance between these points can then be measured with a measuring-tape *Burwin2007*



.Fig: (2-26). Left intercostals oblique view. *Burwin2007*

2-4-2-8Examination of gall-bladder

The best position for examining the gall-bladder varies. Most frequently it is seen in view 1b. It should be demonstrated in its longitudinal section to assess shape, filling state and wall thickness. When gallbladder abnormalities are found, subjects may need to be reexamined after fasting .for 8 hours. ^{Burwin2007}

Measure the anterior wall (adjacent to the liver) is measured where it is parallel to the transducer surface, in order to avoid erroneous inclusion of the .adjacent intestinal wall in the measurement

A post-prandially contracted gall-bladder has a small or even invisible luminal cavity and a thick wavy wall consisting of two layers with different echogenicity. Echo-poor or normoechoic wall thickening may be observed in a variety of conditions (acute cholecystitis, hepatitis, hypoproteinemia, ascites irrespective of its cause). Tenderness under ultrasound guided .palpation (*ultrasonographic Murphy sign*) reveals inflammation Schistosomiasis-related gall-bladder wall thickening is usually painless and leads to echodense wall thickening, sometimes with external echogenic .protrusion. ^{Burwin2007}

Portal vein diameter Measure the internal (inner to inner) diameter of the portal vein at the entry point of the portal vein into the liver . ^{Burwin200}

Collateral veins

:Portal hypertension is indicated by the presence of the following

Presence of splenohilar varices, a splenorenal shunt, the coronary vein (synonyms: *vena coronaria ventriculi*, *vena gastrica dexter* or *sinister*, left /

right gastric vein), size 4mm or larger, gastroesophageal, pancreato-duodenal varices or an entirely recanalized paraumbilical vein

Spleen The long axis of the spleen lies along the tenth rib. Remember that the posterior aspect of any given rib is higher than its anterior extremity. Most authors suggest that the patient be scanned in the lateral decubitus (left side up) position and that the left tenth or eleventh intercostal spaces be used as access to the spleen. You will be scanning in the left coronal plane and should be able to achieve a long axis scan and by turning the transducer ninety degrees, a short axis scan. ^{Burwin200}

A 5MHz medium length transducer may be used since the spleen is a poorly attenuating structure located just behind the ribs. Sector scanners are easiest for intercostals work out many prefer the image form curvilinear transducer, in spite of the larger transducer face ^{Burwin200}

A modest inspiration will depress the diaphragm and spleen inferiorly so they can be visualized. The lower ribs may be elevated by having the patient rise the left arm over their head. Greater access may be achieved by inserting a pillow between the waist and the table. ^{Burwin200}

Standard protocols for ultrasound examination: *S. haematobium* .2-4-3

The lesions to be investigated in urinary schistosomiasis. The presence of intravesical masses and thickening of the bladder wall, dilatation of the ureter, and hydronephrosis. Proved to be relatively easy to observe.

Calcification of the bladder wall is a pathognomonic sign, but can not always be detected in early stages, since tiny calcifications may not produce distal shadowing. It was decided that only minor changes were needed in the protocols for investigating pathology due to *S. haematobium* infection.

Fissures of the renal pelvis 1 cm wide or less are no longer to be recorded as pathological, even though they may sometimes represent an early stage of

hydronephrosis. Ideally, a second examination should be made after the bladder has been voided. Attention was drawn to the fact that in pregnant women there may be some ambiguity in the interpretation of findings. Pregnancy should always be recorded, and considered as a factor in evaluating dilatation of the renal pelvis and ureters. ^{Burwin200}

Equipment Sector scanners or curved array transducers are preferable to a .linear probe for the assessment of the urinary bladder and the kidneys

Preparation Adequate bladder filling is essential to assess shape and wall irregularity. If the bladder is not well filled, the normal appearance of the wall structure may be interpreted as pathological. ^{Burwin200}

Fluids must be given 30 minutes - 1 hour before examination. Diuretics are not indicated. If any abnormality of the kidney and/or ureters is observed, a post-voiding examination of these organs should be done 30 min .– 1 hour later. Record results of post-voiding examination

Although almost pathognomonic of the disease, calcification may only be clearly seen (with conical shadow) in advanced cases. ^{Burwin200}

Residual urine Can be observed if the bladder is re-examined after voiding. To calculate the volume, measure the bladder dimensions before and after . voiding and calculate the pre-and post-voiding volumes

Residual urine is present when $> 10\%$ of the pre-voiding urine is found on post-voiding examination. ^{Burwin200}

NB: if the bladder was grossly distended before voiding residual urine will always be found. ^{Burwin200}

Schistosomiasis .-2-5-1

Primary Distribution: Scattered areas of sub-Saharan, tropical, .2-5-1-1 South, and North Africa; Middle East; West India; Central and Eastern

China; Philippine Islands and nearby islands; numerous areas of the world, with variants and locations noted below under vectors and agents. ^{Burwin200}

Agents and Vectors: Schistosomes are flatworms or blood flukes .2-5-1-2 (trematodes) carried by freshwater snails (the intermediate host). Humans pass eggs via stool or urine into the water where the parasites grow inside the snails. The parasite then leaves the snail in the form of cercaria and directly penetrates the skin of persons working, bathing, or swimming in the water. The worms then grow inside vessels, bladder, or intestines, resulting in symptoms (from the worms and retained eggs) as well as means of repeating the life cycle (Fig: 2-28) ^{Burwin200}

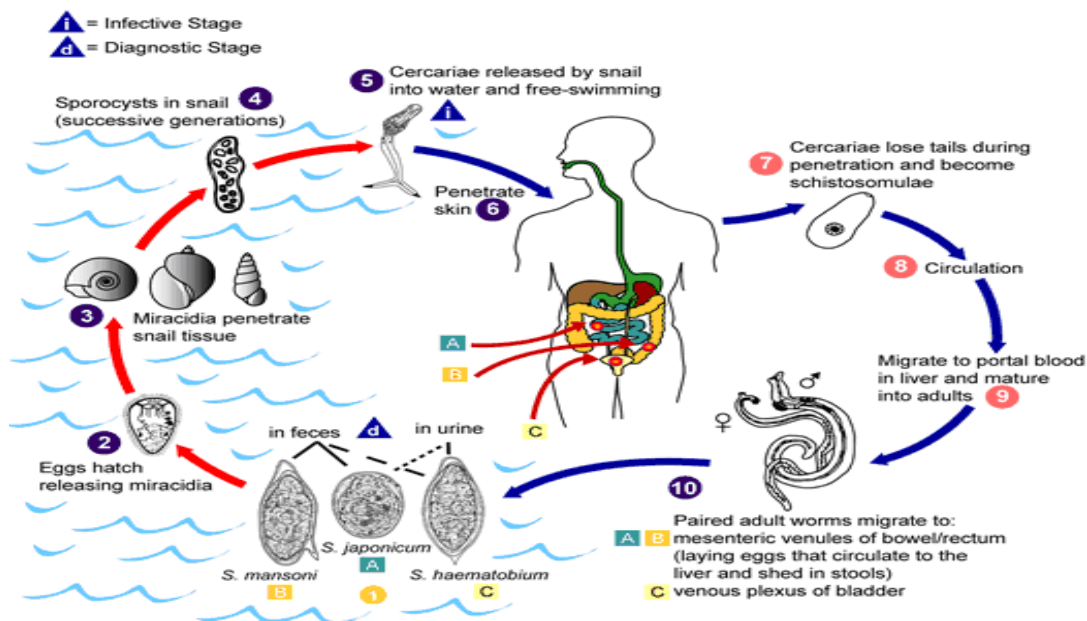


Fig: (2-28). The life cycle of schistosoma. ^{Anderson1998}

:Important species of Schistosoma are .2-5-1-3

S.mansoni is found in Africa, the Eastern Mediterranean, the .2-5-1-3-1

.Caribbean, and South America and primarily affects the liver and intestines

S.haematobium is found in Africa, the Middle East, and Eastern .2-5-1-3-2

Mediterranean and primarily affects the urinary tract. ^{Anderson1998}

S.japonica is found in Central and Eastern China, and the .2-5-1-3-3
.Philippines and nearby islands; and primarily affects the liver and intestines
S.mekongi is found in Southeast Asia and primarily affects the .2-5-1-3-4
liver and intestines. *Anderson1998*

Incubation: Symptoms of acute schistosomiasis begin about a .2-5-1-4
.month after infection

Clinical Findings Signs and Symptoms: There are several .2-5-1-5
syndromes, not all of which are evident in all infected persons. The last
(*chronic*) stage varies according to species, i.e., *S. japonica*, *S. mansoni*, and
S. mekongi primarily affect liver and intestines; while *S. haematobium*
primarily affects the urinary tract. In general, patients with chronic
schistosomiasis tend to present in developed countries with lethargy, colicky
abdominal pain, mucoid/bloody diarrhea, or dysuria and hematuria
.Anderson1998

Initial symptoms may be a pruritic, papular rash that may be caused by
schistosome species noted above or by other non-pathogenic parasites. This
rash is most likely to occur in persons who do not live in endemic areas.

Anderson1998

Acute schistosomiasis (Katayama fever - named after an area of Japan in
which schistosomiasis no longer occurs) occurs in primary infection 1-2
months after exposure to heavy cercariae loads. Acute schistosomiasis is
common in *S. japonicum* and *S. mansoni* infection. Symptoms may include
fever of several weeks duration (especially with *S. japonicum*/Asian),
headache, urticaria, cough, hepatosplenomegaly, lymphadenopathy, diarrhea,
and eosinophilia. Hematuria and dysuria are common in *S. haematobium*.
These symptoms tend to gradually diminish over several months, but may
intensify as more eggs are deposited. *Anderson1998*

Chronic hepatosplenic schistosomiasis is a consequence of eggs retained in tissue and prolonged infection - usually of > 10 years duration. The eggs provoke a delayed hypersensitive granulomatous reaction with the granuloma occupying >200 times the volume of the egg. The liver may be large or small and firm with nodularity. Fibrosis may cause portal hypertension, splenomegaly, or esophageal or gastric varices. Hematemesis and splenomegaly are common presenting symptoms, with normal liver function. In endemic areas, periportal fibrosis is common and is usually not detectable on physical exam. Periportal fibrosis and portal hypertension is associated with glomerulonephritis (proteinuria, renal failure) and pulmonary hypertension. Granulomatous tissue in the bowel results in bloody diarrhea. *Anderson1998*

Chronic genitourinary schistosomiasis is associated with chronic *S. haematobium* infection. Granulomas in the bladder mucosa result from repeated masses of eggs laid by female worms residing in the bladder. Hematuria and dysuria are common from the acute through chronic stages. Obstructive uropathy develops from granulomas blocking ureteral orifices and ureteral dilation may also occur with the end results of hydronephrosis and uremia. Bladder cancer rates are increased in endemic areas.

Anderson1998

Salmonella infection concurrent with schistosomiasis is common and is resistant to treatment unless the schistosomiasis is also treated. *Anderson1998*

Diagnosis: Note that periportal fibrosis, glomerulonephritis, and other manifestations and complications are diagnosed separately. Diagnosis of *S. japonicum* and *S. mansoni* is by the presence of ova in feces or tissue. Diagnosis of *S. haematobium* is by the presence of ova in urine or tissue. However, ova loads are not always sufficient for diagnosis, especially in

long-standing chronic illness. Immunofluorescent antibody tests and antigen detection assays are increasingly used. "Fetal head" bladder calcification

.may be shown in x-rays of patients with chronic *S. haematobium* infection

Differential Diagnosis: Any prolonged febrile illness; typhoid fever, strongyloidosis, trichuriasis; other causes of hepatic, renal, GI, or urinary tract dysfunction - including carcinoma *Anderson1998*

Previous study.2-5-2

A number of studies were held to show the use of ultrasonography in schistosoma complications. A workshop sponsored by world health organization (WHO) and Swiss Tropic Institute (STI) held in Cairo 1990 shows the protocol for ultrasound examination of schistosoma complication. In Brazil 1997, six international satellite symposiums were held to discuss .ultrasound methodology for schistosoma mansoni infection

Mustafa gafar musa march(2004) use of ultrasound to evaluate .2-5-2-1 the complication of shistosomiaseas in Khartoum teaching hospital survey 100 patient known of schistosoma mansoni 45% when noted with preportal fibroid 30% with mild portal hypertention and 26% had acsites while 74 out acsites 11% is no splenomegally 89% ith splenomegally 74%normal liver .size 18% hepatomegally

Abdo mhamed abdalla march (2011) evaluation of caudate and .2-5-2-2 right hepatic lobe ratio in patient with schistosomiasis caudate right lobe use to assessment of liver usually in case of chronic liver disease in which . there atrophy of right lobe with hypertrophy of the caudate lobe

Chapter three

material.3-1

:Study area.3-1-1

centers in Khartoum, Elmanagil and wad medani, Sudan. These centers
:include

.Khartoum Teaching Hospital

Central Police Hospital.Al–Ribat Teaching Hospital.-Military Medical

.Corp.Chinese Friendship Hospital

.Alamal National Hospital

.Elmanagil Hospital

.University Diagnostic Center

.Monis Ultrasound Clinic

Study duration.3-1-2

These investigations were done during the from January 2016 to
June 2016 and the data were collected from January to June
.2016

sampling.3-1-3

One hundred patients were investigated in different hospitals and
.diagnostic center

Clinical evaluation was carried out in all patients followed by US scanning .
attention is made to the liver, portal vein, gallbladder, spleen and urinary
.bladder

toolles.3-1-4

Ultrasound investigations were done using **Aloka SD.500, Honda electronics HS 2000, Siemens, Shimadzu SDU 350** and **Toshiba just .vision 200** with real time scanners; **3.5 MHz** transducer

methodology.3-2

:Technique.3-2-1

The patient is coming fasting at least 8 hours to reduce Powel gas lie in supine position left lateral decubitus position.by applying medical ultrasound gel to the curved linear array 2-6 MH brobe scan done in longitudinal and transverse-oblique planes. The transducer is placed in subcostal location and scanning is performed with patient in deep suspected inspiration in order to lower the liver . the best images of diaphragmatic portion of liver are usually obtained with steep cephalic angulation of transducer

3-2-2Data collection and anlysis

Data was collected using a questionnaire and stored on PC. Then analyzed .by computer program

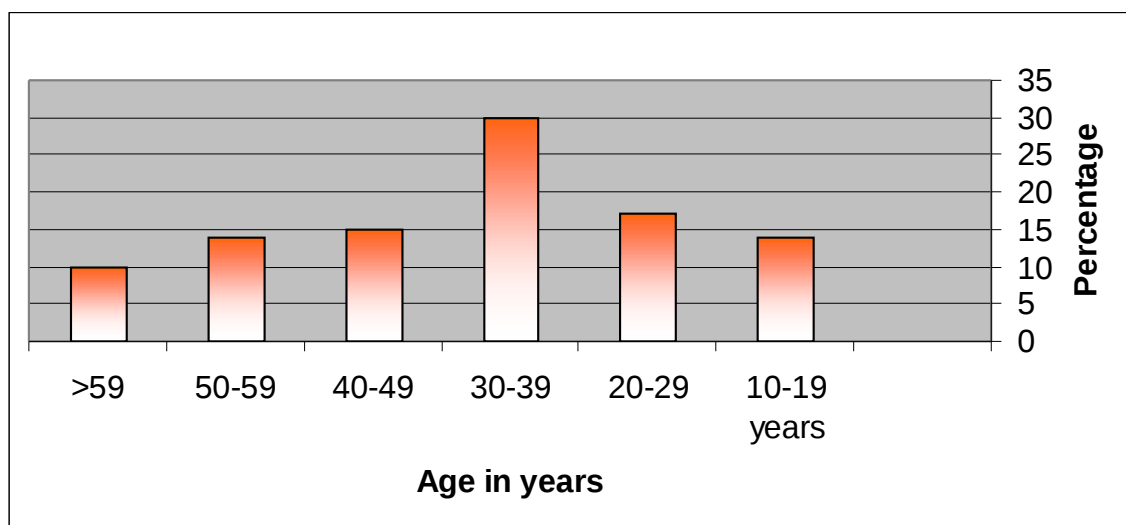
Chapter four

:Analysis and Results

.Table 4-1: Age distribution in population study

Age groups	Frequency	Percentage
years 10-19	14	14%
20-29	17	17%
30-39	30	30%
40-49	15	15%
50-59	14	14%
59<	10	10%
Total	100	100%

(N=100)



.Fig: (4-1). Age distribution in population study

.Table 4-2: Gender distribution in population study

Gender	Frequency	Percentage
Male	64	64%
Female	36	36%
Total	100	100%

(N=100)

.Fig: (4-2).Gender distribution in population study

.Table 4-3: Occupation distribution in population study

Occupation	Frequency	Percentage
Farmer	21	21%
Student	23	23%
Soldier	7	7%
Housewife	18	18%
Others	31	31%
Total	100	100%

(N=100)

.Fig: (4-3). Occupation distribution in population study

.Table 4-4: Residence distribution in population study

Residence	Frequency	Percentage
Khartoum	40	40%
Elmanagil	30	30%
Wad medani	30	30%
Total	100	100%

(N=100)

.Fig: (4-4). Residence distribution in population study

.Table 4-5: Presence of clinical finding distribution in population study

Clinical Finding	Frequency	Percentage
Positive	31	31%
Negative	69	69%
Total	100	100%

(N=100)

.Fig: (4-5). Presence of clinical finding distribution in population study

.Table4-6: Ultrasound finding distribution in population study

Ultrasound Finding	Frequency	Percentage
Normal	54	54%
Abnormal	46	46%
Total	100	100%

(N=100)

.Fig: (4-6). Ultrasound finding distribution in population study

Table 4-7: Causes of abnormalities distribution in population study

Causes of abnormalities	Frequency	Percentage
Due to schistosoma	40	86.9%
Other causes	6	13.1%
Total	46	100%

(N=46)

.Fig: (4-7). Causes of abnormalities distribution in population study

.Table 4-8: Type of ultrasound finding distribution in population study

Type of ultrasound finding	Frequency	Percentage
PPF	40	40%
PHT	29	29%
GB wall thickening	32	32%
Hepatomegaly	19	19%
Splenomegaly	34	34%
Collateral circulations	18	18%
Ascites	11	11%
UB wall changes	0	0

.Fig: (4-8). Type of ultrasound finding distribution in population study

Table 4-9: Age distribution in patients with schistosomiasis

Age groups	Frequency	Percentage
years 10-19	3	7.5%
20-29	8	20%
30-39	11	27.5%
40-49	7	17.5%
50-59	6	15%
59<	5	12.5%
Total	40	100%

(N=40)

.Fig: (4-9). Age distribution in patients with schistosomiasis

.Table 4-10: Gender distribution in patients with schistosomiasis

Gender	Frequency	Percentage
Male	28	70%
Female	12	30%
Total	40	100%

(N=40)

.Fig: (4-10). Gender distribution in patients with schistosomiasis

Table 4-11: Occupation distribution in patients with schistosomiasis

Occupation	Frequency	Percentage
Farmer	16	40%

Student	6	15%
Soldier	1	2.5%
Housewife	9	22.5%
Others	8	20%
Total	40	100%

(N=40)

.Fig: (4-11). Occupation distribution in patients with schistosomiasis

Table4-12: Residence distribution in patients with schistosomiasis

Residence	Frequency	Percentage
Khartoum	6	15%
Elmanagil	14	35%
Wad medani	20	50%
Total	40	100%

(N=40)

.Fig: (4-12). Residence distribution in patients with schistosomiasis

.Table 4-13: Clinical finding distribution in patients with schistosomiasis

Clinical Finding	Frequency	Percentage
Positive	26	65%
Negative	14	35%
Total	40	100%

(N=40)

.Fig: (4-13). Clinical finding distribution in patients with schistosomiasis

.Table 4-14: Type of ultrasound finding distribution in patients with schistosomiasis

Type of ultrasound finding	Frequency	Percentage
PPF	40	100%
PHT	27	67.5%
GB wall thickening	32	80%
Hepatomegaly	17	42.5%
Splenomegaly	28	70%
Collateral circulations	18	45%
Ascites	11	27%

UB wall changes	0	0%
-----------------	---	-----------

.Fig: (4-14). Type of ultrasound finding distribution in patients with schistosomiasis

Chapter five

Discussion, conclusion and recommendations

Discussion .5-1

In this study, one hundred patients, symptomatic or asymptomatic related to schistosomiasis were evaluated descriptively by ultrasound, checking for presence of periportal fibrosis, portal hypertension, hepatomegaly, gallbladder wall thickness, splenomegaly, ascites, collateral circulations and .urinary bladder wall changes

Age, gender, occupation and residence; these factors in relation to the presence of abnormalities related to schistosomiasis on ultrasound were .tested

In this study the age group ranging between (10-70 years), (Table: 4-1, Fig: 4-1). In the age group (10-19 years) there were 14 patients (14%), the same number of patients (14) were found in age group (50-59 years), while the age group (20-29 years) consisting of 17 patients (17%) and 30 patients (30%) found in age group (30-39 years). In addition to 15 patients (15%) in age group (40-49 years), and in the age group above 59 years there were 10 .(patients (10%

It was found that, 64 patients were male (64%) and 36 patients were .(female (36%) (Table: 4-2, Fig: 4-2

The distribution of occupation showed that, 21 patients were farmers (21%), 23 patients were students (23%), 7 patients were soldiers (7%), 18 patients were housewife (18%) and 31 patients had other occupations (Table: .(4-3, Fig: 4-3

There were 40 patients (40%) examined in Khartoum, 30 patients (30%) in Elmanagil and other 30 patients (30%) in Wad medani (Table: 4-4, Fig: 4-4).

Just 31 patients had positive clinical finding, while 69 patients had negative clinical finding (Table: 4-5, Fig: 4-5).

There were 54 patients with normal ultrasound finding, while 46 patients with abnormal finding (Table: 4-6, Fig: 4-6). These abnormalities either due to schistosoma (40 patients 86.9%) or other causes (6 patients 13.9%) (Table: 4-7, Fig: 4-7).

In sonographic evaluation, there was preportal fibrosis in 40 patients (40%), while portal hypertension was found in 29 patients (29%) and 32 patients had gallbladder wall thickening. Hepatomegaly and splenomegaly were found in 19 patients (19%) and 34 patients (34%) respectively. There was collateral circulations in 18 patients (18%), while ascites was found in 11 patients (11%) and changes of the UB wall not found (Table: 4-8, Fig: 4-8).

This study concentrated on the forty patients whom had abnormal ultrasound finding due to schistosomiasis (Table: 4-9, Fig: 4-9).

The age group of this considered number of patients (40) is ranged between 10-70 years. There were 3 patients (7.5%) found in age group 10-19 years, while the age group 20-29 years consisting of 8 patients (20%) and 11 patients (27.5%) found in age group 30-39 years. In the age groups 40-49 years, 50-59 years and above 59 years there were 7 patients (17.5%), 6 patients (15%) and 5 patients (12.5%) respectively (Table: 4-10, Fig: 4-10).

There were 28 patients (70%) male and 12 patients (30%) female (Table: 4-11, Fig: 4-11). The distribution of occupations was 16 patients (40%) farmers, 6 patients (15%) students, one patient (2.5%) soldier, 9 patients

(22.5%) housewife and 8 patients with different occupations (Table: 4-11, .(Fig: 4-11

There were 6 patients (15%) from Khartoum, 14 patients (35%) from .(Elmanagil and 20 patients (50%) from Wad medani (Table: 4-12, Fig: 4-12 Regarding the clinical finding, 26 patients (65%) had positive clinical finding, while 14 patients (35%) with negative clinical finding (Table: 4-13, .(Fig: 4-13

In sonographic evaluation, there was preportal fibrosis in 40 patients (100%), while portal hypertention was found in 27 patients (67.5%). About 32 patients (80%) had gall bladder wall thickening. Hepatomegaly and splenomegaly were found in 17 patients (42.5%) and 28 patients (70%) respectively. Collateral circulations in 18 patients (45%), while ascites was found in 11 patients (27%). The changes in the UB not found (Table: 4-14, Fig: 4-14). This agree with Mustafa gafar(2004) who found preportal . fibroids in 45% and 30% with portal hypertention

Conclusion.5-2

Schistosoma have high incidence in Sudan, and there is concentration of cases in Gezira state (Wad medani) due to filling of areas with irrigated .agricultural schemes

Farmers are the victims of the disease. schistosoma mansoni is the most common type, and periportal fibrosis is the first evidence of schistosomiasis .on ultrasound evaluation

Ultrasound is the most important tool for detection of schistosomiasis .complications

Recommendations.5-3

High incidence of the disease in Wad medani means Gezira state is
.endemic area of schistosomiasis

.High incidence in farmers, need more health culture
Ultrasound scanning should be used in every patient with schistosoma to
.clarify the complications of the disease

Conventional & Doppler ultrasounds are highly recommended for
.revealing portal hypertension

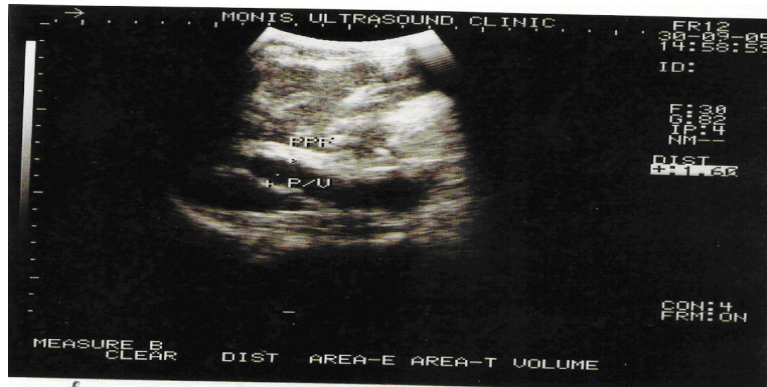
Further studies will be recommended to evaluate the ultrasound finding
.of GI tract for schistosomiasis in endemic areas

References

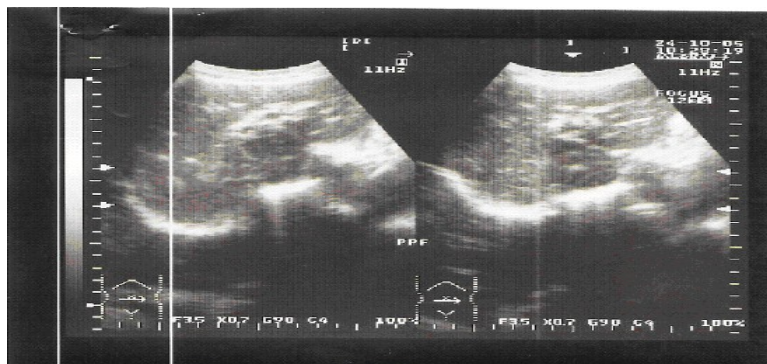
- Chummy S. Sinnatamby:*** Last's Anatomy, Regional and Applied, 10th edition, 2005, Churchill Livingstone. Chapter 5, pages: 253 – 264
- Carol Mattson Porth:*** Pathophysiology, 5th edition 1998. Chapter 30, page: 685
- Ganong,*** Review of Medical Physiology, 21st edition 2005. Chapter 26, page 504
- Guyton & Hall,*** Textbook of Medical Physiology, 9th edition, 1996, page: 267
- John Bullock. Joseph Boyle:*** Physiology, 3rd edition, page: 287
- J.R. Anderson:*** Muir's Textbook of Pathology, English Language Book Society/Edward Arnold, 12th edition. Chapters: 15, 17, and 19, pages: 647 – 741 – 891
- Prof. Qurashi M. A., Prof. Taher Osman Ali:*** Functional Human Anatomy, 1st edition, Modern Technical Center. Chapter 14, page: 172
- P. E. S. Palmer:*** Manual of Diagnostic Ultrasound, liver. WHO in Collaboration with the Federation for Ultrasound in Medicine and Biology, 1995, page: 93
- Richard S. Snell.*** Clinical Anatomy, 7th edition. Lippincott Williams & Wilkins. Chapter: 5, page: 191
- The Burwin institute of diagnostic medical ultrasound:*** Abdomen - part 2, module one 1998, page: 37

Appendices

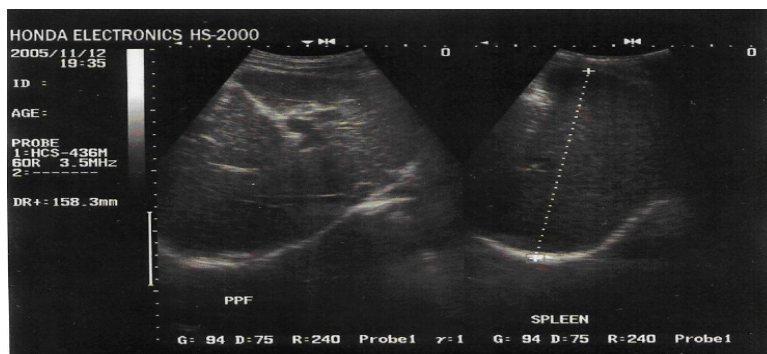
Apenndex 1 Sonographic image



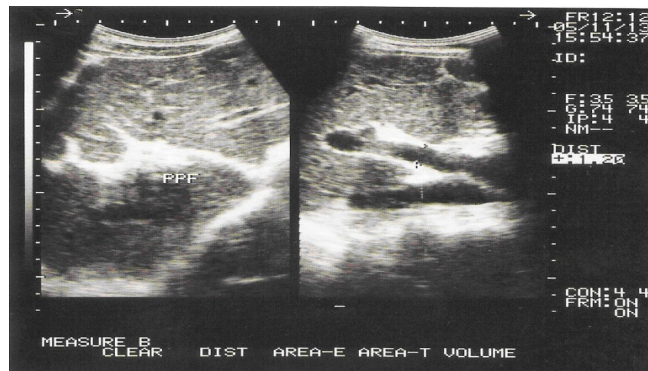
.Fig: (1) 30 years old – female with preportal fibrosis and dilated portal vein



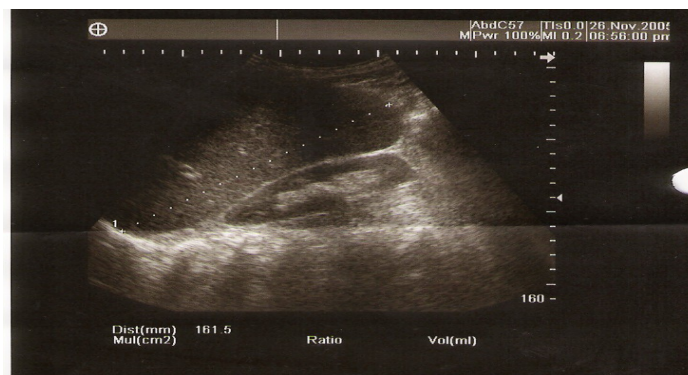.Fig: (2) 55 years old – female with preportal fibrosis



.Fig: (3) 35 years old – female with preportal fibrosis and mild splenomegaly



.Fig: (4) 35 years old – female with preportal fibrosis



.Fig: (5) 25 years old – female with moderate splenomegaly

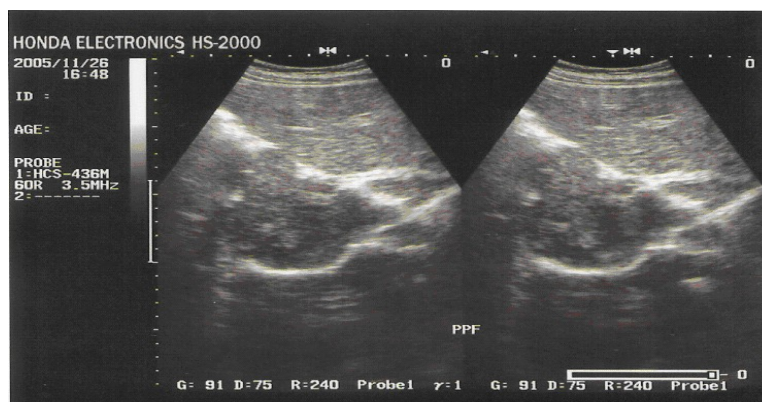


Fig: (6) 32 years old – male with preportal fibrosis

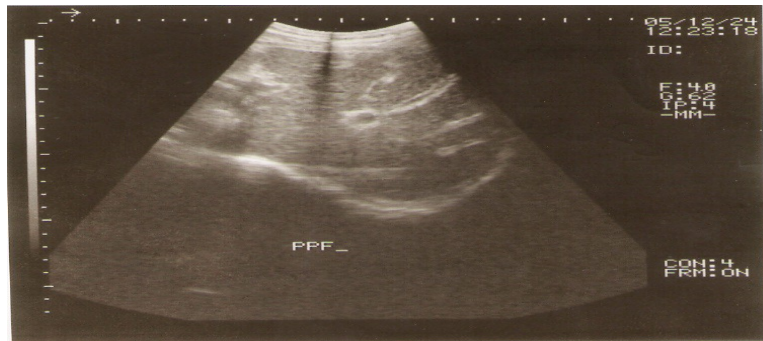
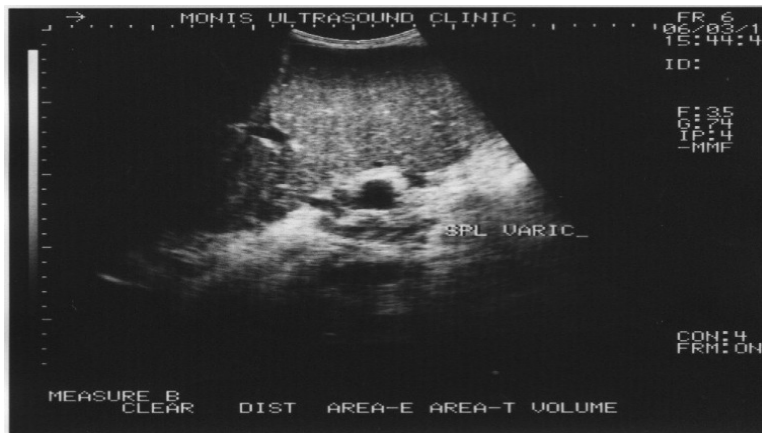


Fig:(7) 33 years old – male with PPF



.Fig: (8) 45 years old – female with marked splenomegaly and splenic varices

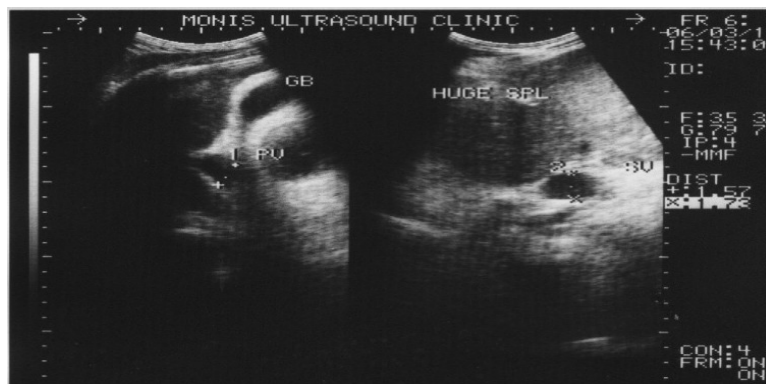


Fig: (9) 46 years old – male with marked splenomegaly, splenic varices and dilated portal vein

Apenndex 2: Data Collection Sheet

ULTRASOUND IN SCHISTOSOMIASIS

Data Collection Sheet

.....:Name

.....:Patient No:.....Date of examination

.....:Age:.....Sex

.....:Region

.....:Occupation

.....:Clinical finding

.....

.....Ultrasound transducer used

() Periportal fibrosis:.....Yes ().....No

() Portal hypertension:.....Yes ().....No

().....:No hepatomegaly

().....:Mild hepatomegaly

().....:Moderate hepatomegaly

().....:Marked hepatomegaly

() Gallbladder wall thickening:...Yes().....No

().....:No splenomegaly

().....:Mild splenomegaly

().....:Moderate splenomegaly

().....:Marked splenomegaly

()..Collaterals:.....Detected...().....Not detected

()..Ascites:.....Detected...().....Not detected

() Urinary bladder wall changes:...Yes ().....No

.....:Signature