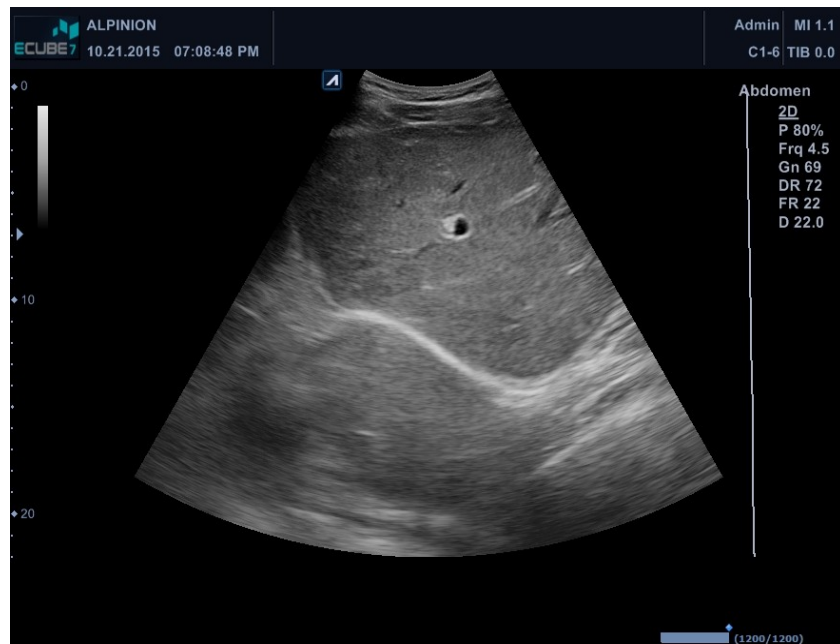
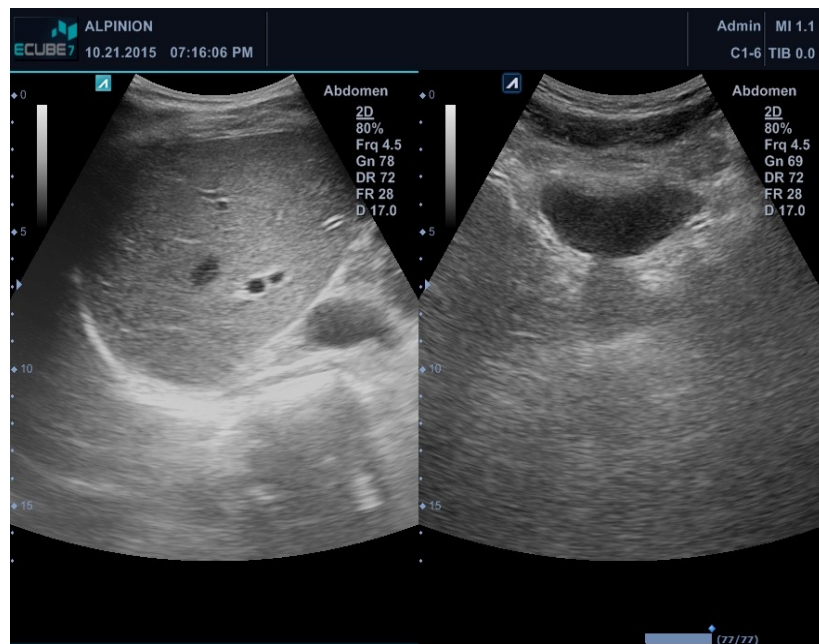


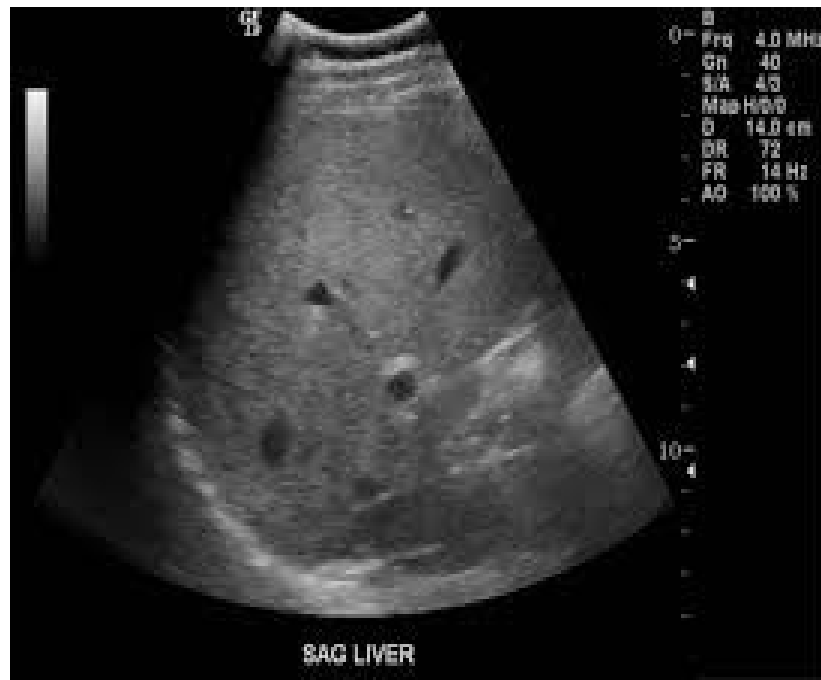:Appendices (A): Ultrasound images



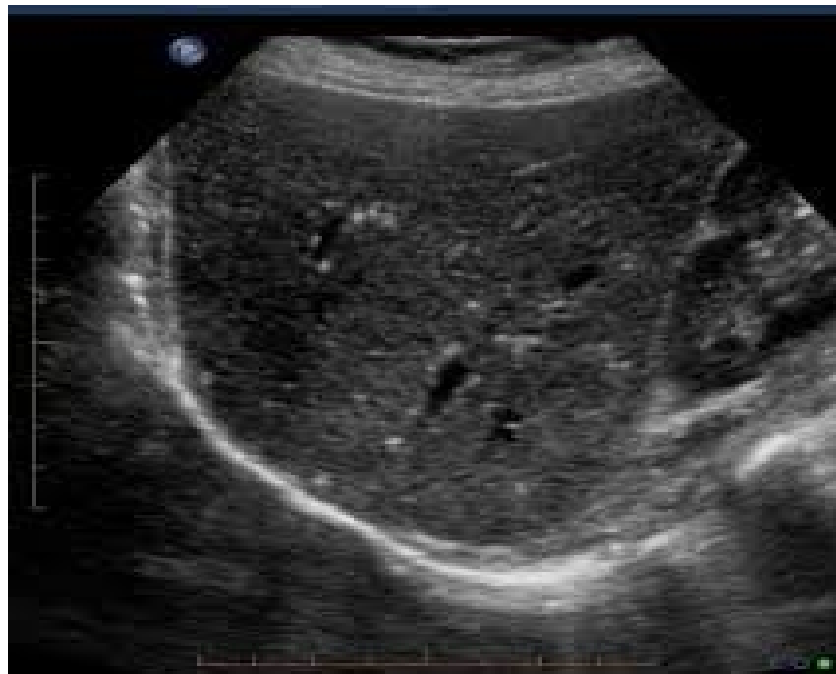Appendix (A.2). Ultrasound image of 55years male .patient of normal liver shows homogeneous echo pattern



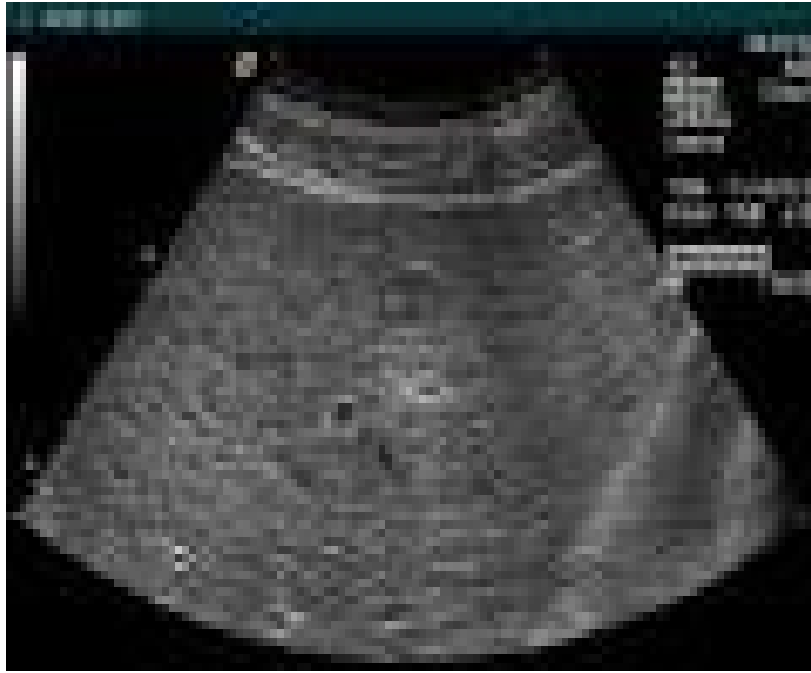Appendix (A.2). Ultrasound image of 33years male .patient of normal liver shows homogeneous echo pattern



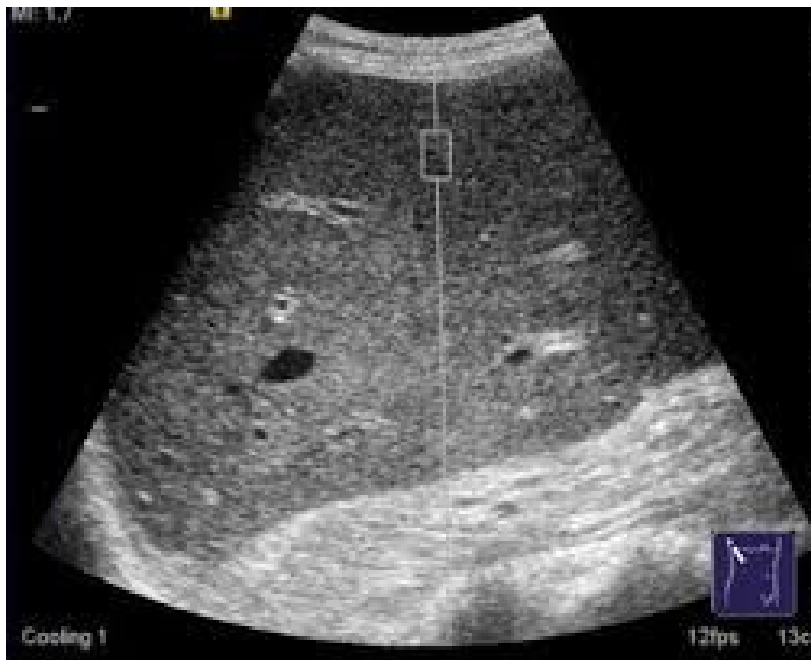Appendix (A.3). Ultrasound image of 46 years male patient with acute hepatitis (B) shows homogeneous, .enlarged liver with diffusely hypo echoic echo pattern



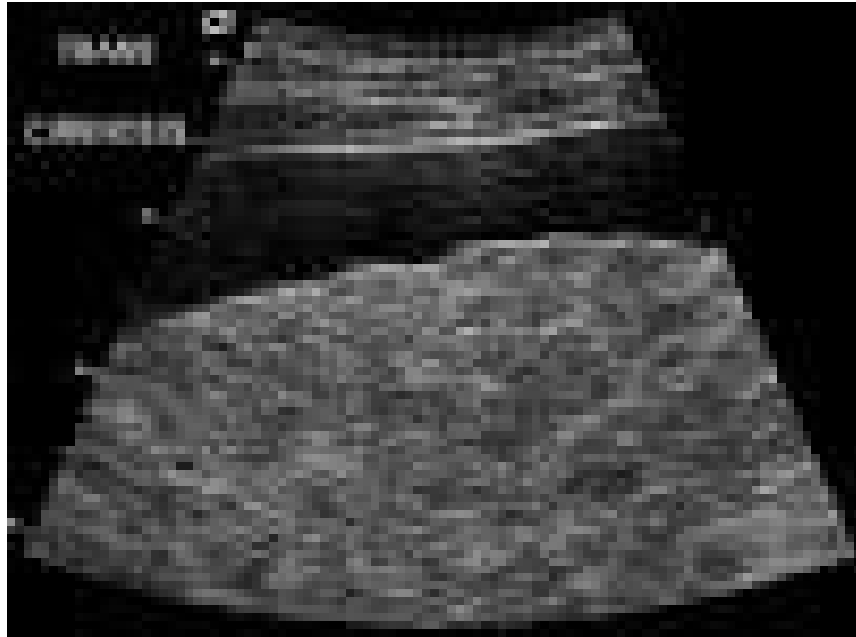Appendix (A.4). Ultrasound image of 55 years male patient with acute hepatitis (B) shows homogeneous, .enlarged liver with diffusely hypo echoic echo pattern



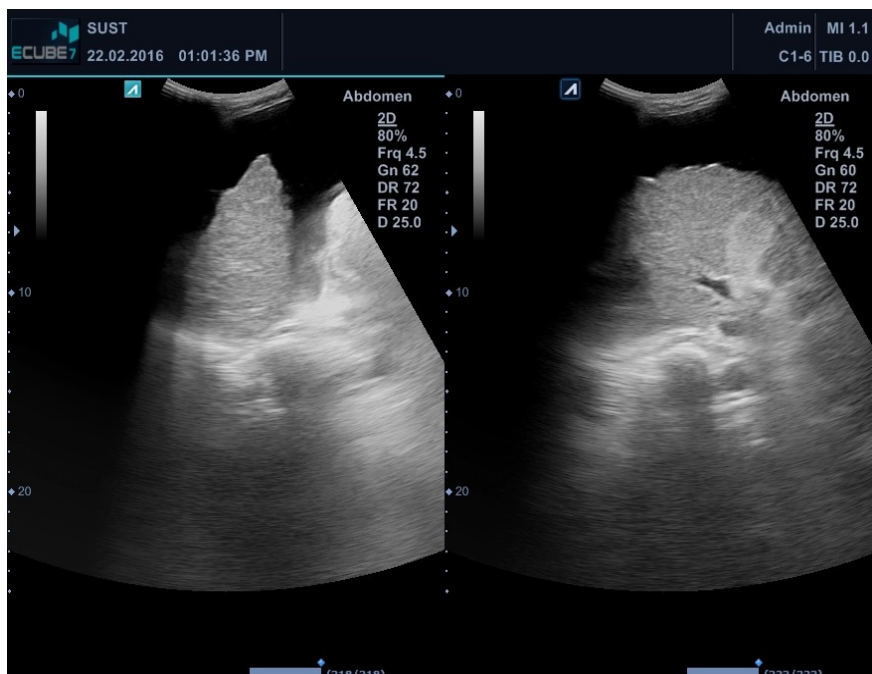
Appendix (A.5). Ultrasound image of 46 years male patient with acute hepatitis (C) shows homogeneous, .enlarged liver with diffusely hypo echoic echo pattern



Appendix (A.6). Ultrasound image of 55 years male patient with acute hepatitis (C) shows homogeneous, .enlarged liver with diffusely hypo echoic echo pattern



Appendix (A.7). Ultrasound image of 58 years male patient with Liver cirrhosis shows heterogeneous echo pattern (Coarse texture), .shrunken liver with ascites



Appendix (A.8). Ultrasound images of 26 years female patient with Liver cirrhosis shows

heterogeneous echo pattern (Coarse texture),
.irregular outlines, shrunken liver with ascites

:Appendices (B): Published Papers

:Appendices (B.1): First paper

:Appendices (B.2): Second paper