

Manual For

Clinical Examination and Making Diagnosis of Animal Diseases

Edited By

Professor. Galal Eldin Elazhari Mohammed Elhassan

Dr. Siham Elias Suliman Mohammed

College of Veterinary Medicine

Sudan University of Science and Technology

English- Arabic

Contents

Subject	No of Pages
Table of Contents	I
Tables	III
Figures	IV
Clinical Examination of the animal	1
The history	1
The environment	4
The animal	4
Routine Clinical Examination	5
General examination and inspection	5
Inspection of body regions	9
Head	9
Eye	9
Neck	9
Thorax	9
Abdomen	11
Physical examination	12
Palpation	12
Percussion	12
Auscultation	14
Examination methods	14
Temperature	14
Pulse	15
Examination of body regions	17
Head and Neck	17
Eye	18
Nostrils	19

Subject	No of Pages
Mouth	19
Cranial cervical region and neck	20
Trachea	21
Clinical examination of the lung	23
Clinical examination of the heart	26
The Clinical examination of the abdomen	28
Clinical examination of the stomach and intestine in horse	29
Clinical examination of the rumen	29
Clinical examination of the reticulum	29
Clinical examination of the abomasum	31
Clinical examination of the abdomen of dogs and cat	31
Clinical examination of the liver	32
Clinical examination of the urinary system	32
Clinical examination of the mammary gland and teats	33
Clinical examination of the lymph nodes	34
Clinical examination of the nervous system	35
Disturbance of autonomic nervous system	35
References	77

Tables

Number	Subject	No of Pages
1	Respiratory Rate	9
2	Temperature	14
3	Pulse Rate	15
4	General examination and inspection	37
5	Inspection of body regions	39
6	Physical examination	42
7	Clinical examination of body regions	43

Figures

Number	Subject	No of Pages
1	Instruments of clinical examination	54
2	Palpation (abomasums, kidneys and udders)	67-70
3	The area of percussion and auscultation of lung in cattle and equine	71-72
4	Procedure of taking body temperature	73
5	Procedure of taking pulse rate in equine	74
6	Regulation of the pulse	75
7	Examination of mucous membranes	76

Introduction

This manual comprises the different methods for making proper clinical examination of animals. It contains all the procedures for clinical inspection and physical examination which will enable the veterinarians and veterinary students to identify the natural complex alterations occurring in the affected body system.

A lot of efforts have been put in the manual to render it very easily to understand and to be with a fruitful assistance to both veterinary students and veterinarians to implement the best ways of clinical examination leading to the correct diagnosis for appropriate therapeutic management & control.

Professor. Galal Eldin Elazhari Mohammed Elhassan

Dr. Siham Elias Suliman Mohammed

Clinical Examination of the animal

This is considered as the mean for proper diagnosis. It has three aspects:

1. The history.
2. The environment.
3. The animal.

[1]. The history:

1. History-taking:

This is the most important part in clinical examination. It is (i) the mean to acquire the essential information relating to the circumstances of the immediate disease problem, (ii) the main facet to the whole procedure of clinical examination and (iii) the key for accurate diagnosis.

In history-taking the following points should be taken into consideration:

1. Personality, knowledge and ability of the animal's owner.
2. The animal's owner should be handled with diplomacy.
3. Avoid using technical terms
4. Enough time should be given to obtain detailed information.
5. Statements concern the duration of the disease should be handled with care and tested for accuracy.
6. The veterinarian should not fully depend on the owner observations in his interpretation.
7. Avoid leading questions.

The routine for accurate history-taking includes:

1) Patient data:

The owner name, postal address, telephone number, the species type, breed, sex, age, name or number, body weight, identifying marks on the patient.

2. Disease history:

This comprises:

- i. Present disease (immediate history), this relates to the sequence of events associated with the period of time that the animal has been ill.**

Specific questions should be therefore centered on:

1. Intake of food or drink.
2. Milk production.

3. Growth rate.
4. Respiration.
5. Defecation.
6. Urination.
7. Sweating.
8. Physical activity.
9. Gait.
10. Posture.
11. Voice.
12. Odour.

In group of animals additional questions should be asked, such as:

13. Behaviour of the animal before death.
14. The period of time elapsed between the first onset of the signs till recovery or death.
15. Prior surgical or medical procedure.
16. Morbidity and mortality rate (case fatality - % of affected animals that die, population mortality is % of all animals that die).
17. To assure that the case has not already received professional attention from another veterinarian.
18. Prior treatment and doses: (help in diagnosis), efficiency of treatment, significance of clinical pathological test and prescription of new treatment, drug withdrawal time.
19. Prophylactic and control measures (knowledge if any preventive or control measures have already been attempted).
20. Previous exposure and here knowledge should be noted about, if the animal is one of a group animal, is it newly introduced to the herd, is a new animal has been recently introduced to the group, is it one of the imported stock.
21. Transit animals (source of infection).
22. Culling rate (reason of culling).

ii. Previous disease (past history):

This is to obtain information of any previous disease in the same manner as stated above in the immediate history.

iii. Management history:

This includes following:

- a) Nutrition (if feed is enough to meet the nutritional requirement of the animal), if the animal grazes at pasture or hand-fed.
- b) Reproduction management and performance.
- c) Breeding history.
- d) Climate.
- e) General management (hygiene, housing, ventilation, drainage, water-troughs, exercise).

[2]. Examination of the environment:

- i. Out door environment: topography and soil type, stocking rate (population density), feed and water supply, waste disposal.
- ii. Indoor environment: level of sanitation and hygiene, inadequate ventilation, population density, quality of the floor.

[3]. The animal (Fig. 1):

Examination of the patient:

Introduction: diseases are classified into two main groups:

- 1. Inflammatory (show signs of inflammation).
- 2. Non-inflammatory (injuries, neoplasm, metabolic diseases, nutritional deficiency, obstruction).

Inflammatory disease:

Acute : Rapid course – signs are marked.

Chronic: slow course – signs are much less obvious.

Routine for clinical examination:

It is always advisable to carry all procedure for routine examination but this can be modified according to the personal choice or by the nature of the disease. In all conditions it is preferable to assess the body temperature, pulse and respiratory rate before disturbing the animal.

The routine examination consists of:

- a) General examination and inspection.
- b) Physical examination.

a) General examination and inspection

Behaviour and general appearance:

- 1. Separation from others animals.
- 2. Response to external stimuli (general demeanor).

Bright: normal responses to external stimuli.

Dullness or apathy: responses are sluggish or retarded or even depressed (febrile and toxaemic states).

Dummy: advanced degree of failure to respond to external stimuli (the animal is still in standing position. Capable of sluggish and uncoordinated movement (hepatic fibrosis in horses, listeriosis and sub acute lead poisoning in cattle).

Comma: Advanced degree of apathy, unconsciousness, no response to painful stimuli (e.g. parturient paresis).

Increased responses to external stimuli constitutes:

Mild: alert, look about constantly (slight consistent pain, defects in vision, anxiety).

Restlessness: constant movement [lying down, rolling getting up again, look round at the flank, kicking the belly, groaning or bellowing (colic in horse or contagious pyelonephritis in cattle)].

Mania: i) Vigorous licking of specific part of the body surface (bovine ketosis).

ii) Pressing forward with the head (meningitis)

iii) Compulsive walking in circles or straight line with failure to avoid obstacles.

iv) Licking or chewing inanimate objects.

Frenzy: Uncontrolled action, dangerous (acute lead poisoning, hypomagnesemic tetany, ketosis, rabies).

Fixed anxious expression is the manifestation of anxiety and where death is imminent.

[3] Eating: Inappetance may be due to abnormality in:

1) prehension; 2) mastication; 3) swallowing; 4) belching (ruminant);

5) regurgitation (ruminant).

Abnormality in prehension e.g. cerebral ataxia, osteomyelitis of cervical vertebrae, painful condition of the neck, pain in mouth.

Mastication may be slow, one-sided, incomplete (in affected mouth or teeth), periodic chewing (encephalomyelitis).

Abnormality in swallowing: inflammation, obstruction or paralysis of esophagus or pharynx.

Abnormality in regurgitation occurs e.g. in cases of esophageal or cardiac obstruction. Failure to belch – bloat.

[4] Defecation:

Difficult act: constipation, paralysis or stenosis of the rectum.

Painful act: abdominal pain, laceration of the mucocutaneous junction of the anus.

Involuntary act: diarrhea, paralysis of the sphincter.

[5] Urination:

Difficult act: obstruction.

Painful act: inflammation of the urethra or bladder.

Increase frequency and small amount: cystitis, urethritis.

Incontinence: partial obstruction of the urethra, paralysis of the sphincter.

[6] Posture:

Abnormality in posture is not necessary indication of disease, unless it is associated with other clinical signs.

1. Shifting of the weight from one limb to the other (e.g. laminitis in horse).
2. Arching the back, feet more closely together or depressing the back and feet widely apart (signs of abdominal pain mainly in horse colic).
3. Dog-setting position: in horses in case of acute gastric distension which result in pressure on the diaphragm.
4. Abduction of the elbows: pain in the chest or difficulty in breathing.
5. Rigidity and erection of the ears, restricted limbs movement, separation of the eyelids, partial elevation and rigidity of the tail: due to increased muscles tone (tetanus).
6. Lowering of the head and weakness of the limb in dogs due to loss of muscle tone.
7. Elevated head and ears pricked (listening attitude in sheep – early stage of pregnancy toxemia).
8. Head and neck extended or held to one side – painful unilateral conditions of the pharyngeal regions.
9. Lateral deviation of the head: listeriosis, coenurosis.
10. Rotation of the head: middle ear infection.
11. Sternal recumbency with head deviated towards flank region – parturient paresis in cattle.
12. Frog – like attitude: bilateral hip joint dislocation.

[7] Gait:

1. This is to be examined when the animal is involuntary movement, or.
2. The animal is led or driven at a varying spaces.

Assessment of the movement includes:

- i. Rate; ii. Range; iii. Force; iv. Direction

Abnormal limbs movement include: lameness, stiffness, shortened stride, stilted gait, exaggerated flexion, abduction, stumbling, staggering, swaying of the hind quarter, forced movement.

The disturbance in movement may be:

1. Constant.
2. Intermittent.
3. Of gradual disappearance.
4. More pronounced with exertion.

The locomotion is mainly affected by:

1. Nervous system disturbances, e.g. enzootic ataxia of calves, mycotoxins, louping ill of sheep, coenurosis, listeriosis and ketosis.
2. Diseases of musculoskeletal system (black leg, nutritional muscular dystrophy, osteodystrophy, arthritis, foot and mouth disease and foot-rot.
3. Intoxication by bacterial toxins (laminitis, metritis, mastitis).

[8] Tremors and convulsions:

These are an involuntary movement.

Tremor: persistent, repetitive twitching of the skeletal muscles (local or generalized).

Convulsions: this is a violent muscular reaction.

Clonic convulsions: repeated muscle spasms, with paddling movements of the limbs, and interspersed with period of relaxation.

Tetanic or tonic convulsions: continuous muscle spasm which may be intensified periodically to become clonic.

Epileptiform convulsions: initially mild with tendency to increase in frequency and severity.

Peripheral convulsion: this may be due to hypoxia, hypoglycemia, electrolyte imbalance.

[9] Voice:

Coarse – rabies

Weak – gut oedema

Persistent bellowing – acute pain

Soundless bellowing and yawning – rabid cattle, hepatic insufficiency

[10] Condition of the animal:

This is either thin, emaciated or obese.

[11] Conformation:

This is based on the symmetry, shape and size of the different body regions relative to other regions.

[12] Skin:

This is mainly seen at a distance:

1. Changes in hair or wool.
2. Abnormal sweating.
3. Discrete or diffuse lesions.
4. Soiling by discharge.
5. Itching.
6. Absence of normal luster of the coat.

Dry skin – chronic debilitating disease.

Alopecia – in hyperkeratosis.

Absence of sweating –anhidrosis.

Patching sweating – peripheral nerve lesions

Excessive sweating – abdominal pain.

Discrete lesions – urticarial plague, pox, ring worm.

Diffuse lesions – subcutaneous edema, hemorrhage, emphysema and enlargement of the lymph nodes.

Inspection of body regions:

This should be done as much as possible before the animal is handled so as (1) to avoid excitement; (2) some abnormalities are better seen at a distance.

1. Head:

Facial expression: rigid as in tetanus

Maniacal as in rabies or acute lead poisoning

Symmetry and configuration of bony structures:

Doming of forehead – congenital hydrocephalus

Swelling of mandible and maxillae – oestodystrophia fibrosa, sinusitis in horse, actinomycosis in cattle.

Rotation of the head – defects in vestibular apparatus

Deviation of the head – defect the medulla and cervical cord.

Opisthotonus (e.g. tetanus, encephalitis).

2. Eye: The following should be observed:

- Visible discharge.
- Protrusion of the eye ball (orbital lymphomatosis).
- Retraction of the bull (dehydration).
- Spasms of the eyelids and excessive blinking (pair or peripheral nerve involvement).
- Prolapse of nictitating membrane (tetanus).
- Dilatation of nostrils and nasal discharge.
- Excessive salivation or frothing (pain in the mouth or pharynx or tremor of the jaws muscle).
- Swelling bellow the jaw (either inflammatory as in actinobacillosis and strangles, or oedematous as in acute anaemia, protein starvation and congestive heart failure).
- Unilateral or bilateral swelling of the cheeks in calves (necrotic stomatitis).

Neck:

- i. Enlargement of the neck region may be: inflammatory, due to enlarged lymphnode, to a salivary gland enlargement, local oesophygeal distension.
- ii. Jugular vein engorgement, jugular vein pulsation, oedema.

Thorax:

1. Chest symmetry.
2. Respiration.

Respiration should be examined first at a distance, preferably when the animal is in standing possession.

Examination of respiration includes:

1. Respiratory rate (Table 1):

Horse: 8 – 10/min	dog : 15 – 30/min
Cattle : 10-30 cycle/min	Cat : 20 – 30/min
Sheep: 10-20/min	Rabbit: 30 – 45/min
Goat : 25-35/min	pig : 8 – 18/min
Camel: 2-12/min	Rat : 90 – 110/min

Polypnea – increase in respiratory rate.

Oligopnea – decrease in respiratory rate.

Apnea – complete cessation of respiratory.

Respiration can be assessed by:

1. Ribs or nostrils movement.
2. Feeling the nasal air movement.
3. Auscultation of the thorax or trachea.

2. Respiratory rhythm:

Respiratory cycle – inspiration – expiration – pause, these of equal length.

Variation in length means abnormality.

Prolonged inspiration = obstruction of the upper respiration tract.

Prolonged expiration = failure of normal lung collapse (emphysema).

Absence of pause = in most of respiratory tract diseases.

Gradual increase and then gradual decrease in depth of respiration – in advanced renal or cardiac disease.

Alternating period of hyperpnea and apnea (unequal length) – in meningitis.

Periods of apnea followed by short burst of hyperventilation – periodic breathing in electrolyte and acid-base imbalances.

3. Respiratory depth:

Reduced – pain on chest or diaphragm.

Increased – anoxia.

Hyperpnea – moderate increase in depth.

Dyspnea – labored breathing, extension of head and neck, nostrils dilatation, elbows abduction, breathing through the mouth, increased movement of the thoracic and abdominal wall, grunting may be heard.

Type of respiration:

Movement of thoracic and abdominal walls – normal respiration Abdominal – type – respiration – (acute pleurisy, paralysis of the intercostals muscle).

Thoracic-type-respiration – (peritonitis especially when there is diaphragmatic involvement).

Costo-abdominal – in horses.

Mainly costal – dog and cats.

Mainly abdominal – sheep and goat.

Chest symmetry: is seen in an infection of one lung or in ricket.

Abnormal respiratory sound:

Violet hiccough: jerky inspiration arising from sudden contraction of the diaphragm e.g. alkalosis, hypocalcaemia, hypokalaemia, hypochloraemia.

Sneezing: nasal irritation

Snoring: pharyngeal occlusion (enlargement of retropharyngeal lymph nodes).

Roaring and whistling: paralysis of intrinsic muscle of the larynx.

Wheezing: Stenosis of nasal passages.

Grunting: Forced expiration against closed glottis.

Yawning: Prolonged inspiration with mouth opened widely and soft palate raised followed by an expiration (chronic gastritis, chronic hepatitis, diseases of the brain).

Coughing: irritation of pharynx, trachea and bronchi.

Abdomen:

The following should be observed:

1. Increase in size (excess food, fluid, fat, fetus, or neoplasm).
2. Decrease in size (gaunt) (starvation, severe diarrhea, chronic diseases).
3. Umbilical hernia or infection
4. Ventral oedema (parturition, gangrenous mastitis, congestive heart failure, rupture of urethra).
5. Ruminal movement

External genitalia: observation for any abnormalities.

Limbs: posture, gait, symmetry, enlargement or distortion of bones, joints, tendons, sheath and bursae, peripheral lymph nodes and lymphatic vessels.

Physical examination:

Techniques used in physical examination:

1. Palpation (Fig. 2):

- i. Direct: handling tissues with finger
- ii. Indirect: with the probe

Aim of palpation:

1. Detection of pain
2. For certain pathological changes (size, shape, consistency, temp.).
In palpation the following terms must be used:
 - a. Resilient: when the palpated structure quickly resumes its normal shape after the application of pressure has ceased.

- b. Doughy: when pressure causes pitting which persists for a variable time (oedema).
- c. Firm: when resistant to the pressure is similar to that of normal liver.
- d. Hard: when the structure possesses bone-like consistency.
- e. Fluctuation: when undulating or wave-like consistency, produced in a structure by the application of alternate pressure.
- f. Emphysematous: when the structure is swollen and puffy and yield on pressure crepitating or crackling sound because of the presence of air or gas in the tissue.

2. Percussion:

This is done by means of striking part of the body to obtain information about the condition of the tissues particularly the deeper lying parts (vibration imported at the point of impact producing audible sounds that vary in volume, pitch on tone when reflected back). The method is usually used for examination of the thorax (lung and heart, disease of the abdominal cavity, paranasal sinuses, subcutaneous emphysema). (Fig 3).

The equipment used: pleximeter (ivory or hard wood plate), hammer with firm rubber and (plexor or hammer). In small animals percussion is performed by using both hands:

Pleximeter: middle finger of one hand.

Hammer: flexed middle finger of the other hand.

Mediate percussion: finger or pleximeter on the skin

Immediate percussion: striking directly with finger or plexor.

Percussion is of limited value in large animals because of the too large internal organs, thick muscles and subcutaneous fats.

General rules for percussion:

1. Pleximeter should be pressed firmly (no air)
2. Hand using the hammer must be in a higher level than the pleximeter and the hammer should not be held firmly and the movement should be confined to the wrist.
3. The blows should fall perpendicular.
4. Percussion should be done systematically and the blows should be no heavier than necessary.

Ballottement and fluid percussion:

Ballottement: it is interrupted, firm push-stroke which is applied to an appropriate part of the body with the object of the evoking motion in the underlying organ and so causing it to rebound onto the fingertips or the back of the partially closed hand e.g. presence of fetus.

Fluid percussion: this is for knowledge of free fluid in a body cavity, this is done by striking the surface of the body on one side and detecting the fluid wave so produced by palpation of the opposite side. This method is more effective when holding both hands in contact with the body surface below the upper level of the fluid. Percussion needs practice and thickness of the body wall must be encountered and also presence of air and gas. In thoracic area percussion over the ribs must be compared with percussion on the intercostals space.

Sound produced by percussion are classified as follows:

1. Resonant: which is characteristic of the sound emitted by air containing organ, such as the lungs when normal.
2. Tympanic: the sound produced by striking a hollow organ containing gas under pressure e.g. tympanic rumen or caecum.
3. Dull: the sound produced by a solid organ like the liver or heart or when percussion blows are struck over deep muscle masses in large animals.

Auscultation:

It is the listening to the sounds produced by the functional activity of an organ located within a particular part of the body in order to assess its condition. It is used in examination of lungs, trachea, heart and certain part of the digestive tract (Fig. 3).

Auscultation is performed by:

1. Indirect: using a stethoscope
2. Direct: placing the ear in contact with the body surface over the organ to be examined, but this method is difficult to conduct in restless animal, frictional sound in the hair coat plus the extraneous sound from the immediate environment of the animal add to the difficulty of this method. In addition the coat may be wet, also dirt, faeces, skin secretion, ectoparasites, bacteria and fungi may be present on the skin surface.

Examination methods:

These include:

1. Respiration
2. Temperature
3. Pulse

These methods (1) should be done gently and quietly and (2) the animal in standing position.

Temperature:

Internal body temperature is measured by means of clinical thermometer (36°C (97°F) to 42.5°C (108°F)).

Procedure:

1. Shake the mercury column down the lowest point to be recorded.
2. Lubricate the bulb end of the thermometer (soap or petroleum jelly).
3. Gently insert the thermometer into the rectum with a rotatory action.
4. The thermometer should be in contact with mucous membrane and left in situ for about 2 minutes (Fig. 4).

Temperature values: (Table 2).

Horse = 37.5°C (±) 1°C Silver fox= 38.9°C to 41.0°C.
Cattle = 38.5°C (±) 1°C Chinchilla= 37.0°C to 38.4°C.
Sheep = 39.5°C (±) 1°C Rabbit= 38.9°C to 40.5°C.
Camel = 36.5°C to 39°C Guinea pig= 37.5 to 39.4°C.
Dog = 37.5°C to 38°C.
Cat = 36.5°C to 39.2°C.

Physiological increase in temperature occurs in the following:

1. After feeding.
2. In forced exercise.
3. On day of parturition.
4. After exercise.
5. In local inflammation of rectum.

The physiological decrease occurs in:

1. Diarrhea.
2. Following normal defecation.
3. Flaccid anal sphincter.
4. After cold fluid enema.

Pulse:

Pulse taking besides examination of the heart and the circulating blood, enables the clinician to formulate an opinion as to the state of the cardiovascular system.

Horse: Pulse is taken mainly at the submandibular artery. It may be taken at the transverse facial artery or at the median artery at the medial aspect and the upper extremity of the foreleg (Fig. 5).

Cattle: The pulse is taken at the facial artery at the lateral aspect of the mandible, or at the transverse facial artery. The median artery is also used. The middle coccygeal artery is in use also (under the tail and 10 cm below the level of the anus).

Young calf, sheep, goat, dog and cat: The pulse is taken at the femoral artery, high up in the inguinal region on the medial aspect of the thigh.

1. Frequency of the pulse is determined by counting for 1 minute.
2. Talking of the pulse is done by placing the ball part of one or more fingers on the skin over the selected artery at the point where it overlies bone and then gentle pressure is applied till the pulse wave can be detected.

The pulse rate is affected by:


1. Species (see table 3).

Normal pulse rate (wave/minute)

Animal	Range	Pig (large)	60 - 90
Horse	28 – 40	Pig (small)	100 - 130
Calf (yearling)	70 – 80	Rabbit	120- = 250
Cattle	55 – 80	Mink	115 - 200
Calf (young)	100-120		
Sheep	70 – 90		
Dog (large)	65 – 90		
Dog (small)	90 – 120		
Cat	110-130		
Camel	30 – 50		

2. Size (higher in small animals)
3. Age (higher in the very young animals)
4. Physical condition (race horse has less frequent pulse)
5. Sex: lower pulse rate in males

6. Parturition: increase in pulse rate
7. Lactation: higher pulse rate in lactating animals
8. Excitement: increase pulse rate
9. Exercise: the increase in pulse rate varies with severity of the exercise and the fitness of the animal.
10. Posture: decrease in the pulse rate when the animal is lying down.
11. Ingestion of feed, rumination, very high or very low temperature painful conditions and fever are known to increase the pulse rate. The pulse rhythm could (i) be regular intermittence (mild degree of heart block) (**Fig. 6**).



- (ii) Irregular intermittence (no obvious cyclical pattern due to second degree heart block, ventricular premature beat and arterial fibrillation. The quality or amplitude of the pulse is assessed by noting the degree of the digital pressure required to obliterate the pulse wave in the artery. The quality of the pulse is affected by heart diseases and abnormalities in blood vessel).

Examination of body regions:

This follows examination of the pulse, temperature and respiration.

1. Head and neck: (a) Eye:

Discharge from the eye may be:

Watery = obstruction of the lacrimal gland.

Serious = early stage of inflammation.

Purulent= late stage of inflammation.

Unilateral discharge = local inflammation.

Bilateral discharge = systemic disease.

Eyelid: excessive movement = pain or in nervous irritability.

Closed lids = pain on the eye or swollen eyelid.

The membrane nictitans carried across the eye = pain in the orbit, tetanus, encephalitis.

There may be tumor in the eye lid

Conjunctiva: normal colour

Pallor = anaemia

Yellow = Jaundice

Dry = acute pain or high fever

There may be congestion, petechial haemorrhage and oedema.

Procedure for examination of conjunctiva:

It is examined by opening and gently everting each eyelid in turn with fore-finger and thumb of one hand while, at the same time, the eye ball is pushed back into the orbital cavity by pressure on the non-everted eyelid. The membrane nictitans is examined by laying the forefinger along the upper lid and pressing it gently, but firmly, against the globe of the eye with, at the same time, the thumb pressing downwards on the lower eyelid (Fig. 7).

Cornea:

Opacity is faint cloudiness = early keratitis.

Opacity is solid white = advanced keratitis.

Increased convexity = increased pressure within the eye ball (glaucoma or hypopyon).

Eye ball size:

Protrusion: when unilateral = pressure from behind the orbit (periorbital lymphoma, dislocation of the mandible, periorbital hemorrhage).

Retraction: in starvation (loss of fat), in dehydration (loss of fluid)

Abnormal eye ball movement:

Nystagmus: periodic involuntary movement. The movement can be horizontal, vertical or rotatory. This is usually caused by anoxia, lesion of the cerebellum or vestibular tract.

Restriction of movement : paralysis of the motor nerves to the orbital muscle.

Abnormal position:

Pupil: (better examined by ophthalmoscope)

Unilateral dilatation = lesion in the orbit

= diffuse lesion (encephalomyelitis)

= functional disorder (botulism, anoxia)

= peripheral blindness

Excessive constriction (miosis)= (unusual) due to over dose of organic phosphatic insecticides, parasympathetic drugs.

Test for blindness:

1. Menace reflex: This is to elicit eye preservation reflex manifested by reflex closure of the eyelid. A blow at the eye is stimulated. The reflex is absent in peripheral and central blindness.
2. Obstacle test: this is to test the ability of the animal to avoid obstacle. This test also can be done to test night-blindness (Nyctalopia) in subdued light.

A maurosis: Total blindness

Amblyopia: Partial blindness

Pupillary light reflex: (closure and dilatation of the iris). This is done with strong flash light.

Nostrils:

1. Odor of nasal breath: sweet sickly – ketosis.
2. Fetid: gangrenous pneumonia, necrosis in nasal cavity, accumulation of nasal exudates.
Constant odor with breath: originates from the respiration tract.
Sour odor with eructation: originates from alimentary tract.
Odor more strong in the oral than nasal breath: originates from the mouth breath (bad teeth, necrotic ulcers).

2. Nasal discharge:

In one nostril: local infection.

Bilateral discharge: systemic infection.

Discharge evenly mixed with blood: originate from the lower resp. tract.

Discharge unevenly mixed with blood: originate from the upper resp. tract.

Watery discharge: early inflammation.

Thick and cheesy discharge: Late inflammation.

Inflammation of the nasal cavity may include: hyperemia, allergic rhinitis, diffuse necrosis, mucosal disease, deep ulceration, glander.

Mouth: in examination of labial mucous membrane the upper and lower lips are grasped gently, lifted and turned back. Opening the mouth for examination of the oral mucosa is done by grasping the free portion of the tongue and then the whole tongue is held between the fingers and thumb, then the hand is rotated so that the thumb is uppermost. Alternatively the tongue is held in the same manner and drawn outwards on one side of the mouth so that the attached portion is pulled between the tables of the opposing molar teeth, at the same time the cheek on the opposite side are pulled outwards with the fingers at the oral commissure (horse and cattle). In dog the upper and lower jaws are each grasped by one hand and the lips are pushed into the mouth over the crowns of the molar teeth on both sides by the thumb and middle fingers while the forefingers rest against the canine teeth. Alternatively tapes can be used around both jaws just behind the canine teeth, tapes can be pulled apart and an assistant must hold both forelegs.

Gags can be used in large animals for more detailed oral cavity examination:

Stomatitis = general inflammation of the oral mucosa.

In buccal mucosa there may be: local lesions, hemorrhage, discoloration, cyanosis, pallor.

Lesions encountered in buccal mucosa can be: vesicles, erosions, ulceration.

Examination of teeth:

Delayed eruption uneven wear: mineral deficiency

Excessive wear with mottling and

pitting of the enamel: chronic flurosis

Changes in the tongue include:

Swollen -----> local edema, inflammation

Shrunk and atrophied: post inflammatory or nervous atrophy.

A metal cylindrical speculum with flash light can be used for examination of pharynx and larynx. These are examined for foreign bodies, diffuse cellulites and lymph node enlargement.

Submaxillary region is examined for:

1. Lymph node enlargement.
2. Oedema.
3. Local inflammation.

Vomiting: this should be examined for: frequency, time of its occurrence in relation to the last meal, nature of the vomited material (degree of digestion, presence of abnormal constituent as foreign bodies, blood, pus, parasites and faecal material).

Cranial cervical region and the neck:

The cranial cervical region includes:

Pharynx, soft palate, guttural pouch in equidae, parotid salivary gland, larynx, thyroid gland, parotid and pharyngeal lymph nodes.

The neck includes: oesophagus, jugular vein, trachea. All the region are examined by inspection and palpation, but larynx and trachea are examined by auscultation.

External inspection reveals: swelling (parotitis, abscess in parotid and pharyngeal lymph nodes, tumors).

Endoscopy can be used for inspection of the pharyngeal region in the opened mouth.

Enlargement of thyroid gland. Local or general enlargement of the oesophagus (oesophageal diverticulum, foreign body, stenosis or paralysis).

External palpation: is done with both hand, one on either side, stroking lightly at first and gradually increasing the pressure. The following can be noted: heat, swelling, pain.

Internal palpation of the pharynx is done in the opened mouth and administration of sedative or narcotic drugs may be useful in horses.

The rhinolaryngoscope can be used for detailed examination of the interior of the body cavity.

Trachea:

Inspection: changes in shape or position, scars.

Palpation: pain, local swelling or deformities.

Auscultation: bronchial sound, tracheal rales, stenotic or whistling sounds.

Tracheal percussion combined with the lung auscultation: normal percussion is performed in the tracheal region in the mid-neck region with a single blow, simultaneously the manner of the sound produced is observed by auscultation of the lung.

In normal lung: sounds are distant and indistinctly heard.

Consolidated areas in the lung: sounds are loud and distinct (pneumonia)

Radiology.

Oesophagus:

Inspection and palpation: abnormalities which cause changes in shape and contour.

Firm pressure on the oesophagus at almost any point along the left jugular furrow may cause eructation, regurgitation and even vomiting in diseases such as oesophagitis, dilatation, regurgitation and even vomiting in diseases such as oesophagitis, dilatation.

Stomach tube:

This is to determine whether the oesophagus is patent and whether constriction, solid food masses, foreign bodies, neoplasm or lesions causing compression stenosis are present.

The stomach tube should be lubricated before use. The head and neck should be fully extended. The patient is adequately restrained. In horse the stomach tube is usually passed through the nostrils, and in cattle and other species the tube is usually passed through the mouth with the aid of suitable gag. In dog and cat the animal may be anaesthetized.

Cough:

This usually indicates the presence of primary or secondary disease of the respiratory tract. Cough is infrequent in the early stage of inflammation, as the condition progresses cough becomes more frequent.

Induction of cough:

1. Repeated application of gentle pressure to larynx in the region of its junction with the first cartilaginous ring of the trachea (especially horse).
2. Intermittent pressure over the trachea in front of the entrance to the chest.
3. Sharp "blow" with hand, within the respiratory areas, on the thoracic wall.
4. Occlusion of the both nostrils in horse, nostrils and mouth in cattle and sheep for 30-60 seconds with hand or folded towels (induce hypoxia).

5. In small animal compression of the thorax between the hands, or lifting up a large fold of the skin from the back behind the shoulders, so that the weight of animal is almost supported. In cough it is important to know:

Frequency and periodicity:

Paroxysm: numerous cough following one after another.

Simple: protracted or of short duration as in inflammation of vocal cords, chronic alveolar emphysema.

Cough may be short as in acute bronchitis, pleurisy due to pain. In chronic tuberculosis (adhesion). In extensive pneumonia (reduced volume of expired air).

Cough may be loud, soft, croaking, wheezing whistling, barking when the soft palate vibrates. Cough is termed shallow or deep depending on the volume expelled.

Productive or moist cough: expulsion of secretion and fluids.

Non-productive or dry cough: unaccompanied by fluid movement.

Visible mucous membranes:

These includes (1) the conjunctiva (2) nose (3) mouth (4) vagina and (5) rectum.

Examination may be done at daylight, by the use of electric torch, also vaginal and rectal speculum can be used.

Changes in the mucous membranes are associated with the mucous membrane itself or with systemic diseases.

Examination is to reveal the presence or absence of:

1. Pallor (anaemia).
2. Hyperaemia (congestion): fever, colic, dyspnea.
3. Cyanosis (bluish discoloration) (myocarditis, pericarditis, mineral and plant toxin).
4. Icteric discoloration (slight yellow to lemon yellow (jaundice = hepatitis, blood parasites, leptospirosis).
5. Swelling.
6. Presence of exudates (discharge).

Clinical examination of the lung:

1. Palpation:

Painful conditions in the lungs increase the sensitivity of the chest wall (e.g. pleurisy).

2. Percussion:

- a) Resonant sound in normal lung i.e. ringing sound which indicates the presence of air containing organ.
- b) Increased resonance (exaggerated ringing, hyperresonant sound): occurs incases of pulmonary emphysema, pneumo-thorax.
- c) Abbreviated ringing (less resonant sound. Less clear and loud than the ringing sound). This occurs in cases of lung oedema.
- d) Dull sound: in pneumonia (due to hepatization, hydrothorax, passive congestion, neoplasm, collapse, subcutaneous oedema or sub-cutaneous fat).

The area of percussion and auscultation:

Triangle area on both chest area, extends from the posterior angle of scapula to last 2nd intercostal space (1st line), and to the olecranon process of ulna (2nd line). The ventral boundary of the area extends upwards and backwards from olecranon process to the 2nd last intercostals (Fig. 3).

Horse

Cow

Differentiation between decreased resonance incase of:

- | | |
|--|---|
| <p>A. Increased density of the lung:</p> <ol style="list-style-type: none"> 1. Area of dullness has an irregular outline (pneumonia) 2. Heart sound are clearly audible beyond the cardiac area 3. Auscultation reveals rales or frictional sounds. 4. On percussion over trachea, strong, loud sound are heard directly beneath chest piece of the stethoscope on the chest wall. | <p>B. Presence of fluid in the pleural sac.</p> <ol style="list-style-type: none"> 1. Area of dullness has a horizontal delimitation. Area of dullness changes with changing position of the animal (excudative pleurisy, hydrothorax). 2. Heart sounds are less distinct. 3. No frictional sounds or rales are heard. 4. Sounds heard by similar procedure are distant but strong and loud. 5. Fluid can be obtained by exploratory puncture. |
|--|---|
3. Auscultation:

1. The chest piece of the stethoscope should be held firmly against the thorax to minimize the crackling sounds caused by friction against the hair of animals' coat.
2. When coat (hair or wool) is long or matted together it is necessary, before applying the chest piece to expose the skin by separating the hair or wool.
3. The whole area of respiration (area of percussion and auscultation) should be methodically auscultated, commencing in the upper anterior, and moving horizontally backwards and then forwards again at slightly lower level, until the entire area has been explored.
4. Stethoscope should be applied to each point on the chest wall for the duration of at least one complete respiratory cycle.

Normal respiratory sounds:

This consists of two types of sounds:

- a) Bronchial sound ("ch"): This is heard better over the bronchial area which is situated on the frontal part of the triangle.
- b) Vesicular sound: "V" sound during inspiration. "F" sound during expiration. This type is audible all over the triangle.

Abnormal "adventitious" respiratory sounds:

These are heard in case of disease conditions in the bronchi, lung, pleura or diaphragm.

These sounds include:

(1) Rales (2) Emphysematous sound (3) Frictional sound.

- (1) Rales: indicates the presence of secretion of fluid; in the form of exudates, transudate, blood or aspirated fluid, in the bronchi or bronchioles.

According to the viscosity of the secretion rales can be:

- a) Moist rales: due to the low viscosity of the mucous or fluid which is set in motion by air passing over or through it. Bubbling in character (like the sound produced when air is blown from the end of narrow bore tube under water), occurs in bronchitis, bronchopneumonia, pulmonary oedema, pulmonary haemorrhage, in inhalation of fluid.
- b) Dry rales: this is heard when the air is forced through a bronchial tube which is partially constricted, either by the dry tenacious mucous or by severe swelling of the mucous membrane, the sound may be humming, rattling, whistling, cracking or squeaking. Dry rales occurs in the early stages of acute bronchitis, in chronic bronchitis, spasm of the bronchial muscle, pulmonary neoplasia or tuberculosis.

Crepitant rales: (crepitations) these are "crackling" sounds heard during late part of the inspiratory phase and occurs when:

1. The bronchial mucosa is greatly swollen.
2. Exudation has affected alveoli, so that opposing walls become adherent to one another then have to be separated by stream of inspired air. Sudden separation of the adherent mucous membrane cause the "crackling" sound (simulating rubbing a tuft of hair, held between the fingers close to the ears), occurs in bronchitis, early stage of pneumonia, during resolution stage of pulmonary inflammation and in pulmonary oedema.

Emphysematous sound:

Harsh and crackling sound, occurs during the whole of the inspiratory phase and to less extend in the expiration (crushing a sheet of soft paper into a ball). In cases of chronic alveolar emphysema (throughout the resp. cycle), acute alveolar emphysema.

Frictional sounds (normally not present):

These are associated with pleura or pericardium. Rasping or scraping sounds are heard when the costal and visceral pleurae are dry and roughened. This sound is constant and occurs with each resp. cycle (the sound like rubbing together two pieces of dry leather or by pressing a finger against the ear and scratching it with a finger nail of the other hand), occurs in early stage of pleurisy, pericarditis (pericardial frictional sounds are not related to the resp. cycle).

Further examination of the lung include:

1. Radiological examination.
2. Paracentesis.

Clinical examination of the heart:

1. Visual inspection.
2. Palpation of cardiac area.
3. Percussion.
4. Auscultation of (cardiac area) heart sounds.
5. Radiological examination.
6. Electrocardiography (E.C.G.).

1. Inspection:

During the general inspection, the so-called "apex-beat" of heart, causing movement of the chest wall during the cardiac systole over the

fifth and sixth intercostals space, particularly in the animals having thin chest wall.

2. Palpation of the cardiac area:

This is done by placing the palm of the hand over the cardiac area to assess the strength and extend of the cardiac impulse.

3. Percussion:

- a) Heart is a muscular organ, air-free: percussion= complete absolute "dullness".
- b) Cardiac area is located, approximately in the lower 2/3 of the left thoracic cavity between 3-6 pairs of ribs in the horse (situated behind the shoulder, above the level of the elbow and in size of hand-palm) and between 3-5 pairs of ribs in cattle, sheep and goats.
- c) Area of cardiac dullness can be demonstrated if percussion is carried out in the direction of the arrows.

OX Heart

- 1. First line of percussion running downwards to area of dullness
- 2. Second line of percussion running horizontally backwards from the area of cardiac dullness.
- 3. Approximate angle of the lung.
- 4. Absolute dullness area because of the sternum.
- 5. Area of relative dullness caused by the heart.

Cardiac area can be slightly increased by extending the left foreleg forwards. Area of dullness increases in cardiac hypertrophy, dilatation, pericarditis, hydropericardium, haemopericardium.

Area of dullness decreases in: over distension of the lung.

Pain during percussion: presence of acute pericarditis or pleurisy

4. Auscultation of the heart:

- a) In cardiac cycle there are two phases: (i) systole (ii) diastole.
- b) Auscultation is to determine the character of "heart sounds" and to detect the presence of abnormal sounds.
- c) The best sites for routine heart auscultation are the 4th and 5th intercostals spaces. The 1st (systolic) sound is maximal over the cardiac apex, and the 2nd (diastolic) sound is maximal over the base of the heart.
- d) Auscultation is to assess: heart rate= rhythm; intensity; abnormal sounds.

Heart rate can be mechanically altered by closure of nostrils (in horses and camels) and nostril and mouth in (cattle, sheep and goat). Similar effect is produced by applying oculo-cardiac, reflex.

Heart rate decrease in e.g. CHF, obesity, anasarca, hydropericardium, hydrothorax.

Normal Heart sounds:

These two, 1st heart sound (lubb) – loud, dull and prolonged sound (Systolic), 2nd heart sound (DUPP), sharp, short sound.

LUBB – DUPP -----► (pause) LUBB – DUPP -----► (pause) etc.

When the heart rate is increased, the sounds are not distinguishable: if slow, the 1st and 2nd sounds are recognizable:

The 1st heart sound is best heard at the 4th intercostals space, 10 cm above the sternum.

The 2nd heart sound is best heard at the level of the shoulder joint of 3rd intercostal space.

Abnormal heart sounds (adventitious sounds) MURMURS:

Cardiac murmurs replace or accompany one or both heart sounds. Murmurs could be systolic murmur, diastolytic murmur or continuous. They occur in cases of diseases of the heart muscles, heart valves, the great vessels.

The Clinical Examination of the Abdomen

Inspection:

1. To assess the relative size of the abdomen.
2. To determine the presence of localized lesions.
 - Increase in size of abdomen e.g. pregnancy, distension of rumen and stomach, neoplasm, pyometra, urine retention in dog and cats, ascitis, peritonitis, bloat, oedema on the ventral side.
 - Decrease in size (gaunt appearance): malnutrition, reduced appetite, dehydration, tissue fluid imbalance.
 - Anatomical conformation of normally projecting bones: e.g. 'knocked down' hip = calcium or phosphorous deficiency.

External palpation:

Procedure: By the use of the whole hand or closed fist, this is placed firmly in contact with the abdomen, following muscular relaxation a firm punch or jab is applied for detection of superficial pain. For deeper seated lesion pain is elicited by firm pressure. In cattle the palpated organs are rumen (motility, amount and consistency of the rumen contents), liver (when enlarged), reticulum (traumatic reticulo-peritonitis).

Palpation in horse, sheep and goat is unsatisfactory.

Palpation in dog and cat is done by the use of both hands with the fingers firmly extended together, placed on each side with thumbs pointing upwards.

Percussion: (of limited value).

Loud tympanic sound = gas – filled area.

Dull sound = solid organ.

Auscultation: for functional activity of the digestive tract.

Gurgling, murmuring or rumbling sound= normal peristalsis and segmentation movement.

Rectal examination:

1. Protective gloves and rubber gown or apron should be worn, lubricate before use, finger nail should be clipped.
2. Suitable restraint should be employed.
 - i. Enemas of warm water.
 - ii. Elevation of the animal head.

- iii. Pressure to be applied with the finger on the vertebrae in the lumbar region.
- iv. Use of sedatives or tranquilizer or induction of low epidural anaesthesia.

Clinical examination of the stomach and intestine in horse:

1. Stomach: not satisfactory, therefore stomach diseases diagnosis depends largely on the clinical signs and laboratory aids.
2. Intestine: (spasm, tympany, impaction, enteritis).
 - Inspection: distension in primary tympany.
 - Palpation: pain, increased tension.
 - Percussion: Increased response all over the abdomen = primary tympany. Localized response = secondary tympany.
 - Auscultation: the intensity or absence of peristaltic movement (loud gurgling) enteritis, spasmodic colic, early impaction or rumbling sound due to volvulus, intussusception, and strangulation or impaction of the ileocaecal valve.
 - Reduced or "absent" sound: impaction, few hours after intestinal obstruction.
 - Tinkling sounds: Intestinal tympany, local retention of gas.
 - Rectal examination: for palpation and detection of abnormal changes in rectum, small colon, large colon, caecum, small intestine. Spleen and stomach are not usually palpable, only the caudal pole of the left kidney in small horses. Other organs which can be palpated rectally include: bladder, urethra, uterus, ovaries, lymph nodes and peritoneum.

Clinical examination of the rumen:

- Inspection:
1. Gaseous distension (left paralumbar fossa).
 2. Ruminal contraction (1-3/min.).
- Palpation: this reveals: frequency, strength, cyclical pattern of rumen movement.
- Ruminal movement is reduced or absent in cases of:
1. Simple indigestion.
 2. Acute engorgement.
 3. Traumatic reticulitis.
 4. Vagus indigestion.

5. Rumenitis.
6. Actinobacillosis.
7. Neoplasia.
8. Ulceration and torsion of abomasums.

Percussion: Adds little to the results of the physical examination and for confirmation of the other methods (thickness of the abdominal wall).

Under normal condition:

Upper part = slightly tympanic
One third down the left flank – dull

Under abnormal condition:

Simple overfeeding = dullness in the left paralumbar fossa. Mild gaseous distension = tympanic sound.
Gas dispersed throughout the ingesta = Resonant sound at much lower down the abdominal wall than normal.
Severe tympany = ringing sound.

Auscultation:

Normal contractions = gurgling fluid and booming sounds

Persistent ruminal atony = high-pitched and splashing sounds in the upper part of the left flank.

Left abomasal displacement = similar sound as above but at the lower and slightly at more cranial point.

Clinical examination of the reticulum:

(opposite to 6, 7 and or even 8 ribs, mainly on the left of median plane).

Palpation:

Detection of pain especially in traumatic reticulo-peritonitis (grunt or groan or violent reactions) pressure points for detection of pain are at several areas over the abdomen:

1. Pinching of the wither.
2. Stick method.
3. Down hill.
4. Strong percussion on the reticulum (xiphoid cartilage).

Metal detector helps in the diagnosis of traumatic reticulo-peritonitis.

Auscultation:

Best done over the costochondral junction of the seventh left rib, approximately 10 cm caudal to the point of elbow.

Normal sound = swishing in character.

Reduced sound = primary disease of reticulum, rumen disease and other diseases of the alimentary tract.

Clinical examination of the abomasum:

Palpation: (firm pressure with the closed fist) done on the lateral surface of the abomasum which is related to the abdominal wall on the right side ventral to the 7th to the 10th ribs.

Palpation is for detection of pain.

Left-side abomasal displacement:

Inspection: obvious bulge (tympanic abomasum) in the cranial part of the lower left paralumbar fossa, may extend upwards.

Palpation: bulging, cylindrical organ just behind the costal arch.

Auscultation: high-pitched tinkling, pinging or splashing sounds.

This sound can be heard by finger-flick percussion with simultaneous auscultation.

Percussion, palpation and auscultation of the right-side distended abdomen reveal similar findings in case of the right-side abomasal displacement.

Rectal examination: The following can be noticed:

1. The strength and frequency of rumen contractions.
2. Nature of the contents of the rumen (fluid, solid, gas).
3. Reduction and increase in size.
4. Left and right abomasal displacement.
5. Intestinal obstruction.
6. The small nodular lesions in tuberculous peritonitis.
7. Distension of the urinary bladder and pelvic urethra.
8. Thickening of the wall of the urinary bladder.
9. Thickening of the ureter.
10. Enlargement and absence of labulation and pain in the left kidney.

Clinical examination of the abdomen of dogs and cats:

Palpation: of considerable importance. The organs involved in palpation include: the stomach, the caudal pole of the left kidney, bladder, liver.

Other methods used are inspection, percussion and auscultation.

Other examination methods of the abdominal organs in all species:

1. Absorption test,
2. Laparotomy,
3. Paracentesis,
4. Peritoneal exudates examination,
5. Radiology,
6. Faecal examination.

Clinical examination of the liver:

Physical examination methods are of limited value due to the regional position of the liver.

Palpation: (cattle, dogs and cats) is done on the liver right borders which project beyond the costal arch or xiphoid cartilage in case of hepatomegally = edge uniformly thickened and rounded (normal liver = sharp edge)

Gross enlargement of the liver may be due to:

1. Severe congestion.
2. Multiple abscessation.
3. Hydatidosis.

Percussion: is done over the dorsal part of the right costal arch area.

1. To notice the extend of the dull area overlying the liver.
2. Strong percussion or firm palpation may reveal the presence and severity of pain.

Other test:

Liver function test.

Liver biopsy.

Radiology.

Clinical examination of the urinary system:

General inspection: posture, frequency of urination and signs of pain during the act of urination.

Kidneys:

Horse: Difficult in external palpation.

Firm pressure on its area may reveal pain.

Rectal palpation: both kidneys can be palpated in small horse and only the caudal part of the left kidney in medium size horse.

Cattle: external palpation is difficult.

Rectal examination: the caudal part of the right kidney in small and medium size animal. The left kidney can be palpated rectally in most cattle. In sheep, goat, dog and cat the kidney can be externally palpated.

Palpation of the kidney to assess:

1. Local pain, 2. Relative size, 3. Shape, 4. Consistency, enlargement of the kidney in the cases of:

1. neoplasia, 2. hydronephrosis, renal tumor, 4. pyelonephritis.

Palpation of the urinary bladder becomes more possible when it is distended with urine (pain, calculi, neoplasm, thickened wall). Inspection and palpation of the penis and preputial structure for (1) local pain (2) any other abnormalities.

Special examinations of the urinary tract include:

- | | |
|------------------------|-------------------------|
| 1. Rectal examination. | 2. Catheterization. |
| 3. Urine analysis. | 4. Renal function test. |
| 5. Renal biopsy. | 6. Radiology. |

Clinical examination of the mammary gland and teats:

This includes:

1. The mammary gland and teats.
2. Supra-mammary lymph nodes.

Inspection:

In mammary gland for:

Swelling (oedema and mastitis).

Reduction in size (dry cow, chronic mastitis).

Eruptions, ulceration and superficial injury.

Rupture of the suspensory ligament (dropped udder and increase in direction and level of the teats size of the four quarter).

Palpation (both hands area used):

Increase in temperature, in acute and sub-acute consistency and texture; pain change mastitis.

Deep firm indurated + irregular lesions, chronic mastitis.

Nodular lesions (Tuberculosis).

Chronic abscessation.

Neoplasia.

Examination of the cleft between the lateral aspect of the udder and the medial aspect of the thigh (frictional dermatitis).

Examination of the teat.

Macroscopic examination of the milk is done on strip cup for:

Visible particles, colour, smell and consistency.

Blood sampling:

In blood collection the following should be observed:

1. Avoid exciting the animal.
2. Avoid too prolonged pressure when raising the superficial vein.
3. Avoid haemolysis.
4. Shave the site of the injection, clean well, apply alcohol or ether and allow to dry, when small quantity of blood is needed use the ear vein on outer surface of the pinna, when large quantity of blood is needed use:
 - a) Jugular vein (routinely used).
 - b) Milk vein.
 - c) Middle coccygeal vein or artery in cattle.
 - d) Middle cephalic (radial) or recurrent tarsal (saphenous) vein are used in dog and cat. Jugular vein is also in use.
5. The blood should be withdrawn gently to avoid collapse of the vein around the point of the needle and to avoid haemolysis.
6. Press the skin at the point of insertion before withdrawing the needle.
7. The syringe should washed out by cold water immediately after the sample has been taken.

Clinical examination of lymph nodes:

Inspection: enlargement of lymph nodes.

Palpation: size, pain, lobulation, consistency, temp., abscess formation, maturation and discharge, adhesion to the skin and surrounding tissues, number of palpable lymph nodes involved and whether the involvement is unilateral or bilateral.

Lymph nodes:

In acute inflammation: Swollen, hot, painful, indistinct lobulation.

In chronic inflammation: enlarged, painless, firm, normal temp., adherent to skin and tissues.

In pyogenic lymph node: fluctuation, hot skin, painful and swollen surrounding tissues.

Lymph nodes of importance in clinical examination:

1. Prescapular L.N.
2. Prefemoral L.N.
3. Suprammary L.N.
4. Sulmaxillary L.N.
5. Retropharyngeal L.N.
6. Posterior mediastinal L.N. (only in cattle, palpated rectally)
7. Cubital L.N. (only in horse – medial aspect of the humerus between elbow and wall of the thorax (difficult to palpate).
8. Superficial inguinal L.N., in stallion on either side of the penis

Clinical examination of the nervous system:

This is more rewarding in dog and cat. Difficult to apply to farm animals.

1. History is very important.
2. Inspection (abnormal behaviour).

A. Motor disturbances:

Paralysis = (flaccid type) muscle tone is absent and passive movement of the affected part is not actively resisted. Reflex responses, pain induced, or otherwise, are lost and visible wasting of the muscle involved soon occurs (neurogenic atrophy).

Spasm (tremor, convulsion (tetonic or tonic and clonic).

Nystagmus (these are described earlier).

Ataxia: The power of individual muscle is not affected, but there is lack of functional coordination between the several member of a group of muscles resulting in defective movement in rate, range, force and direction.

Forced movement: these are fully coordinated muscular movement caused by stimulation of motor centers and are repeated again and again, always following the same pattern.

B. Sensory disturbances (touch, sight, smell and taste).

Analgesia: absence of sensitivity. Assessed by prickling of the skin at various points with needle (lips, around the eye, wither and perineum).

Hyperaesthesia = hypersensitivity

Paraesthesia = sensory aberration – characterized by severe cutaneous pruritis, violent rubbing, scratching, biting.

Disturbances of autonomic nervous system: (involuntary activity).

This can be absent, diminished or exaggerated. Reflex arcs which could be examined include:

1. Corneal reflex:

Touching of the cornea, preferably the peripheral part with a moistened swab, or with clean hair brush or touching the medial canthus, cause the animal to blink.

2. Pupillary reflex: Shading both eyes first and then directing a pencil beam of light onto one of the eye. Normally pupil dilates in dark and rapidly becomes constricted on exposure to bright light.
3. Cutaneous reflexes: these are tested by touching or lightly prickling the skin in certain part of the body with a pin or hypodermic needle:
 - a) Flexor withdrawal reflex = pinching the inter digital fold of the skin (dog and cat) between the forefinger and thumb nail, or skin of cornea (horse and cattle). This test is carried in recumbent animal.
 - b) Anal reflex.
 - c) Cutaneous muscle reflex (panniculus): light prickling the skin starting at the tail and proceeding on each side of the vertebral column.
4. Tendon reflex (posture and gait):
 - i. Patellar reflex: (in recumbent animal). The straight patellar ligament is tapped with index finger, hammer. Under normal conditions the tapping results in forward extension of the limb.
 - ii. Hock reflex.
5. Postural reflexes (dog and cat):
 - i. Tonic neck and eye reflexes: (in animal standing with normal posture). During flexion of the neck the animal's eyes maintain their forward gaze but the forelegs are extended and the hind legs flexed.
 - ii. Supporting or placing reflexes: This is applied to foreleg or hind limbs. The animal may be tested with or without a blind fold.
 - iii. The righting reflex: blind fold the dog or cat, lay on its side and then release. Normal animal will immediately assume sternal posture and get up.

Other examination of the nervous system include: examination of the cerebrospinal fluid, radiology, electroencephalography.

General Examination and Inspection
A. Behaviour and General Appearance

Findings Test	Bright	Dullness	Dummy	Coma
Response to external stimuli (general demeanor)				
Increase response to external stimuli	Mild	Restlessness	Mania	Frenzy
Eating	Prehension	Mastication	Swallowing	Regurgitation
Defecation	Difficult (constipation)	Painful	Involuntary (diarrhea)	Faces appearance
Urination	Difficult	Painful	Increase frequency	incontinence

Findings Test	Lamenes s	Stiffness	Exaggeration flexion	Abduction	Staggering	Swaying of the hind quarter	Forced movement	
Gait								
Tremor & convulsion	Tremor	Clonic convulsion	Tetanic convulsion	Epileptiform convulsions				
Condition of the animal	Thin	Emaciated	Obese					
Conformation	Normal	Abnormal						
Posture	Shifting of the weight	Arching of the back	Dog sitting position	Abduction of the elbows	Erected ears	Abnormal head & neck position (lowered, elevated, extended, lateral deviation	Sternal recumbency + Head towards flank	frog-like attitude
Skin	Hair & wool	Sweating	Discrete lesion	Diffuse lesion	Itching	Alopecia		

B. Inspection of body regions

Test Region	Facial expression		Symmetry and configuration of bony structure		Rotation	Deviation	Opisthotonus
	Rigid	Manical	Doming of forehead	Swelling of mandible and maxillae			
Head							
Eyes	Discharge		Protrusion of eye ball		Retraction of the bulb	Spasm of the eyelid and excessive blinking	Prolapse of nictating membrane
Nostrils	Dilatation		Discharge				
Mouth	Excessive salivation		Frothy salivation				

Inspection of body regions

Findings Region	Swelling					
Jaws and cheeks	Bilateral	Unilateral				
Neck	Inflammation		Oesophygeal distension	Jugular vein enlargement	Jugular vein pulsation	Oedema
	Lymph node	Salivary gland				
Thorax	Chest symmetry		Respiration			
			Rate	Rhysm	Depth	Type
Abdomen	Increase in size		Decrease in size	Umbilical hernia	Ventral oedema	Ruminal movement

Inspection of body regions

Findings Region					
External genitala	Normal	Abnormal			
Limbs	Posture		Gait	Symmetry	Enlargement
Udder	Symmetry		Increase in size	Decrease in size	

C. Physical examination methods

Result Technique	Resilient	Doughy	Firms	Hard	Fluctuating	Emphysematous	
Palpation							
Percussion	Resonant		Tympanic		Dull		
Auscultation							

D. Clinical examination of body regions

Test Region	Discharge					
	Watery	Serious	Purulent	Unilateral	Bilateral	
Eyes						
Eyelids	Excessive movement		Closed lids		Prolapse of nictating membrane	
Conjunctiva	Normal	Pale	Yellow	Dry	Congestion	Oedema
	Faint cloudiness		Solid white		Increased convexity	
Cornea						

Clinical examination of body regions

Region	Test	Odor of nasal breath					
		Sweet	Sticky	Fetid	Constant with breath	Sour odor with eructation	Strong with oral than nasal breath
Nostrils							
Nasal discharge		Bilateral	Unilateral	Evenly mixed with blood	Unevenly mixed with blood	Watery	Thick and cheesy
Mouth		Buccal mucosa					
		Haemorrhage	Pallor	Cyanosis	Vesicles	Erosion	Ulceration

Clinical examination of body region

Region	Test	Teeth			Tongue	
		Delayed eruption uneven wear	Excessive wear mottling + pitting of enamel		Swollen	Shrunk and atrophied
Mouth						
Submaxillary region		Enlargement of lymph node	Oedema		Local inflammation	
Vomiting		True	Projectile	Frequency	Nature	Watery
Cranial cervical region and the neck	Inspection	Endoscopy		Palpation		
	Swelling	Enlargement of thyroid gland	Enlargement of oesophagus	Heat	Swelling	Pain

Clinical examination of body regions

Test Region	Inspection			Palpation			Auscultation	
	Shape	Position	Scars	Pain	Swelling	Deformities	Bronchial sound	Tracheal sound
Trachea								
Tracheal percussion + lung auscultation	Distant and indistinct (not clear)			Loud and distinct (clear)				
Oesophagus	Inspection and palpation			Stomach tube				
	Pain	Swelling	Deformities	Normal	Constriction	Blockage		
Cough	Productive (moist cough)			Non-productive (dry cough)				

Clinical examination of body regions

Test Region	Palpation	Percussion						
	Pain	Resonant sound	Increased resonant sound		Less resonant sound		Dull sound	
Lung	Sounds (Auscultation)							
	Normal lung sound			Abnormal lung and chest sound				
	Normal breath sound	Increased breath sound	Decreased or absent breath sound	Increased breath sound	Crackles	Wheezes	Pleural friction rub	Absent breath sound
Heart	Inspection		Palpation	Percussion			Auscultation	
	Apex-beat (movement of chest wall		Strength and extend of cardiac impulse	Dullness (normal	Decreased dullness	Pain	Normal sound	Abnormal sound (murmur)

Clinical examination of body regions

Test Region	Inspection				
	Increased size	Decreased size	Anatomical conformation		Localized lesion
Abdomen	Palpation			Percussion	
	Pain in internal organs	Rumen motility	Rumen contents	Loud tympanic sound	Dull sound
	Auscultation				
	Normal sound (gurgling)		Abnormal sound		
	Note				
	Rectal examination to reveal abnormalities in the palpable organs Other tests include: absorption test, laboratomy, paracentesis, peritoneal fluid tests, radiology, faecal examinations				

Clinical examination of body regions

Test Region	Inspection	Palpation		Percussion	
	Distension	Palm	Increased tension	Diffused increased resonance	Localized resonance
Stomach and intestine of horse					
	Auscultation				
	Loud gurglying or rumbling sound		Reduced or absent sound		Tinkling sound

Clinical examination of body regions

Test Region	Palpation (4 methods)	Auscultation	
	Pain	Normal (swishing sound)	Reduced sound
Reticulum: opposite to 6, 7 and 8 ribs, mainly on the left of median plane (10 cm caudal to the point of elbow)			
Abomasum: (ventral to the 7 th – 10 th rib mainly related to the right side)	Palpation		
	Pain		
Left-side abomasal displacement	Inspection	Palpation	Auscultation
	Obvious bulge (in the cranial part of the lower left paralumbar fossa)	Bulging cylindrical organ behind the costal arch	High-pitched splashing sound

Clinical examination of body regions

Test	Palpation				Percussion	
Region	Pain	Sharp edge (normal)	Uniformly thickened and round edge (abnormal)		Pain	Extension of dull area
Liver						
	Liver function		Liver biopsy		Radiology	
Urinary system	Inspection (behavior) during urination					
	Posture		Frequency of urination		Signs of pain	
Kidney	Rectal palpation in horse and cattle – external palpation in sheep, goat, dog, cat					
	Local pain		Size		Shape	Consistency
	Other tests					
	Rectal examination	Catheterization	Urine analysis	Kidney function test	Renal biopsy	Radiology

Clinical examination of body regions

Region	Test						Inspection			
	Swelling	Size		Lesions		Rapture of suspensary ligament		Direction and level of teats		
Mammary gland + teats + supramammary lymph nodes										
							Palpation			
	Temperature			Consistency & texture		Pain		Frictional dermatitis		
	Macroscopic examination of milk									
	Visible particle			Colour		Smell		Consistency		
Lymph nodes	Inspection		Palpation							
	Enlargement	Size	Pain	Lobulation	Consistency	Temperature	Abscess	Discharge	Adhesion	

Clinical examination of body regions

Test Region	History		Inspection								
			Abnormal behavior		Paralysis	Ataxia	Forced movement		Convulsion	Tremor	
Nervous system											
	Analgesia			Hyper aesthesia (hyper sensitivity)					Paraesthesia		
	Reflex areas										
	Corneal reflex	Pupilliary reflex	Cutaneous reflex				Tendon reflex		Postural reflex		
			Flexor with drawl reflex	Anal reflex	Cutaneous muscle reflex (panniculua)		Patellar reflex	Hock reflex	Tonic neck & eye reflex	Supporting or placing reflex	Righting reflex
Other test	Cerebro-spinal fluid examination			Radiology				Electro-encephalography			

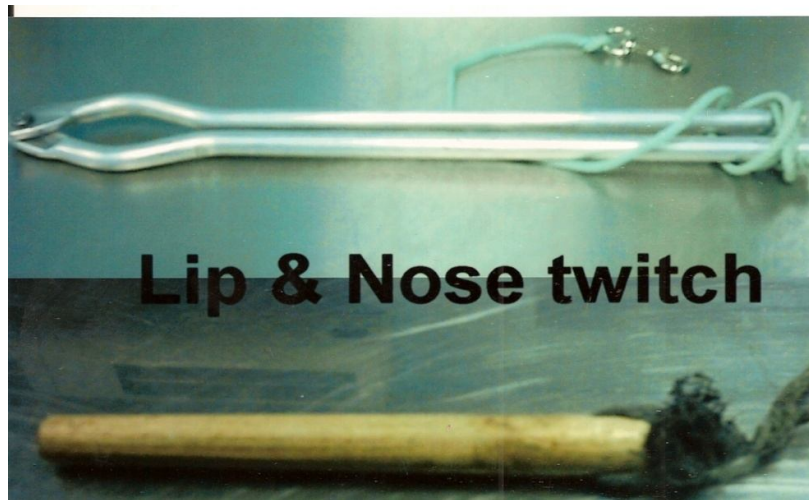
The instruments are used in the physical examination

الأدوات التي تستخدم في الفحص العضوى

Fig. (1)
1-1. Animals stocks
الزناقات



1-2. Lip and nose twitch
لواشة الانف والشفاه



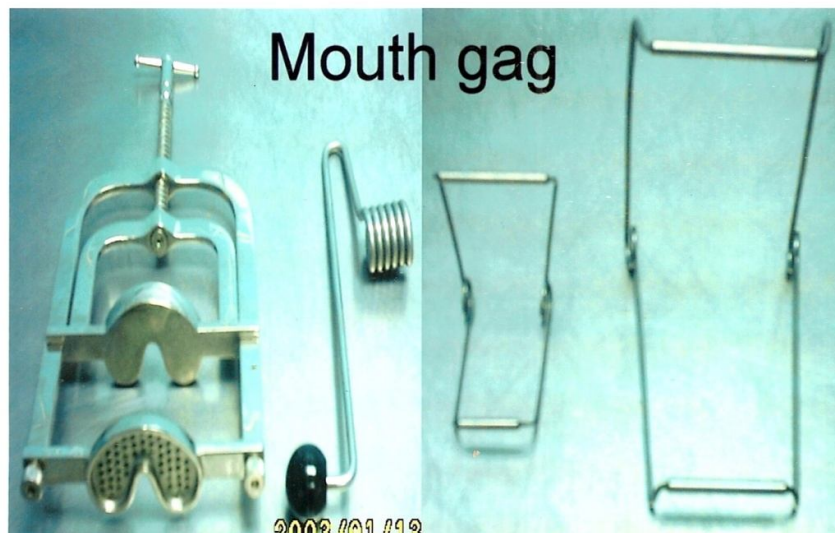1-3 .Bull leader

قائد ذكر الابقار



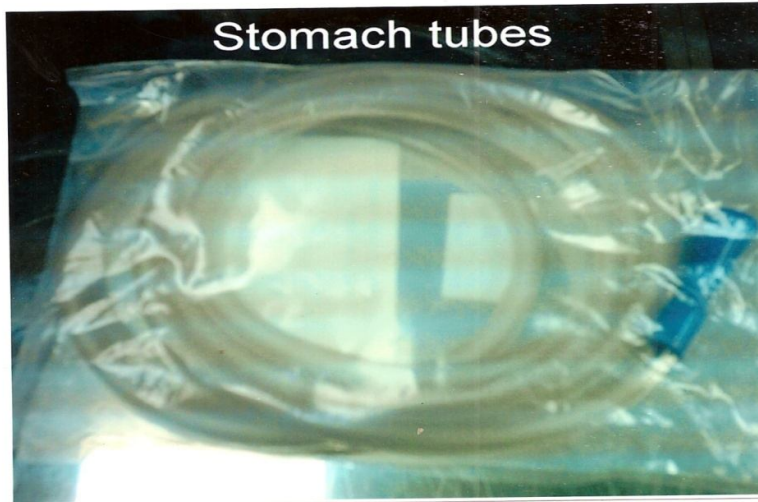
1-4. Mouth gag

فاتح الفم



1-5. Stomach tubes

انبوب المعدة




1-6. Trocar and canula

المبزل



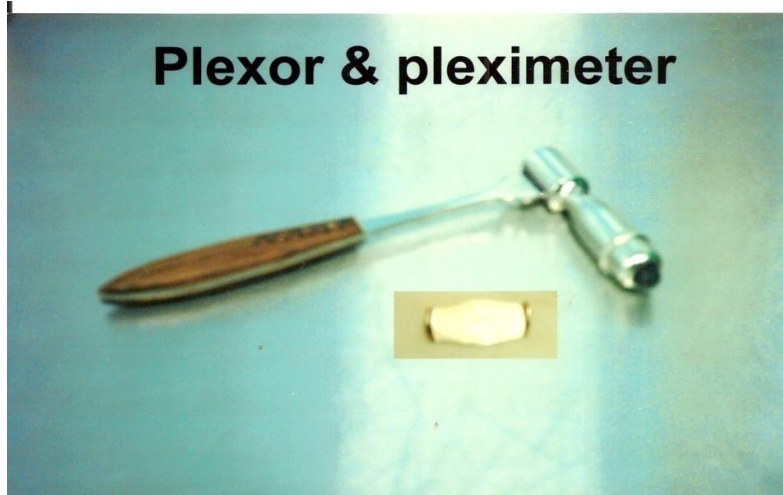
1-7. Metal detector

كاشف المعدة (تشخيص الاجسام المعدنية)



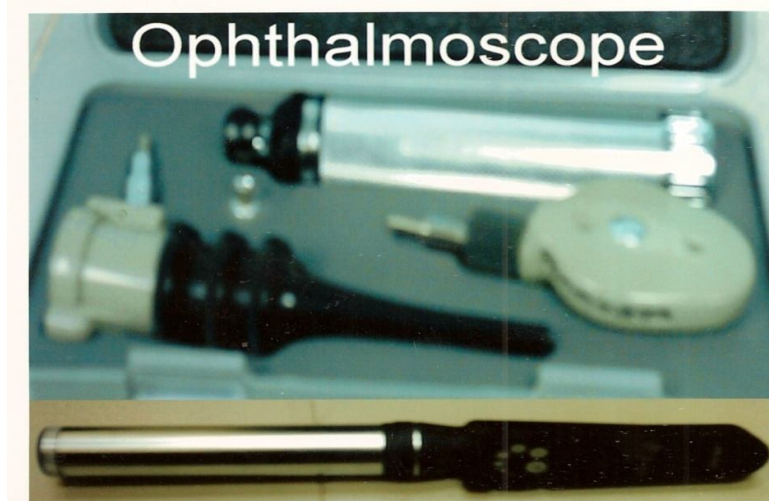
1-8. Plexor and Pleximeter

المطرقة والمطرقة



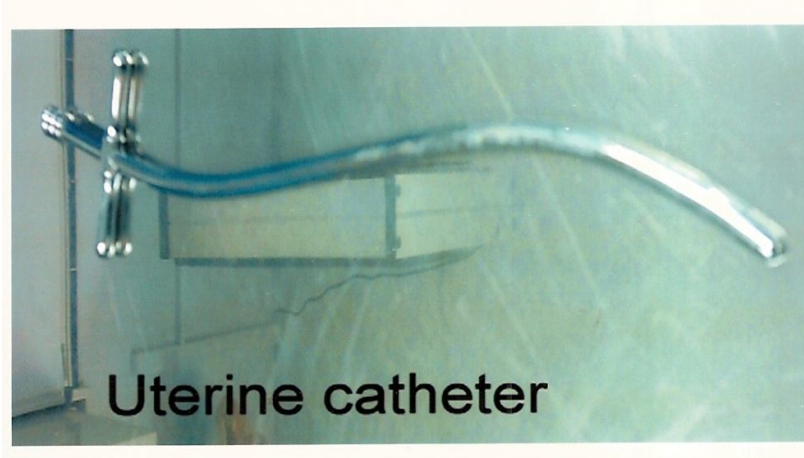
1-9. Ophthalmoscope

منظار العين



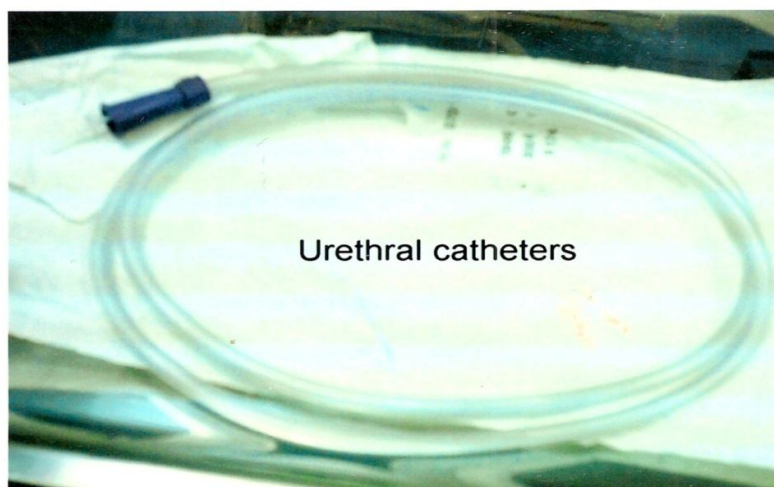
1-10. Uterine catheter

قسطرة الرحم



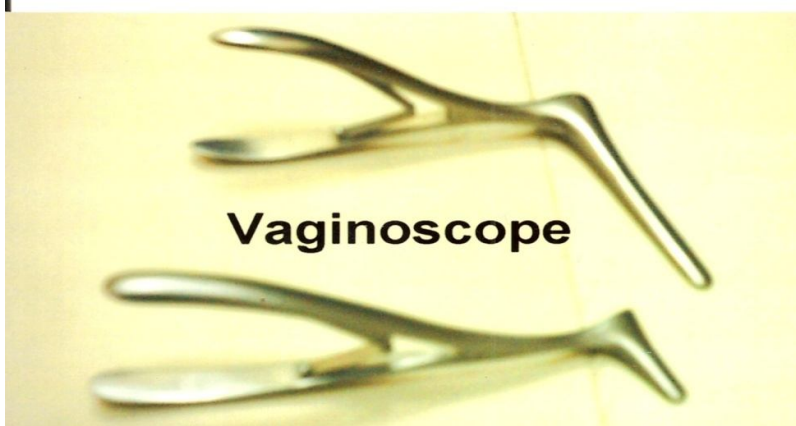
1-11. Uteral catheter

قسطرة مجرى البول



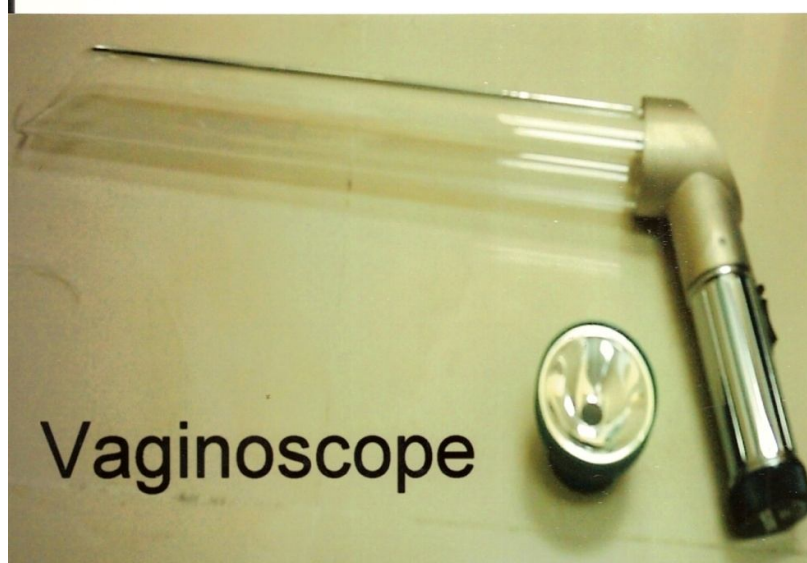
1-12. Vaginoscope

منظار الرحم




1-13. Vaginoscope

منظار الرحم



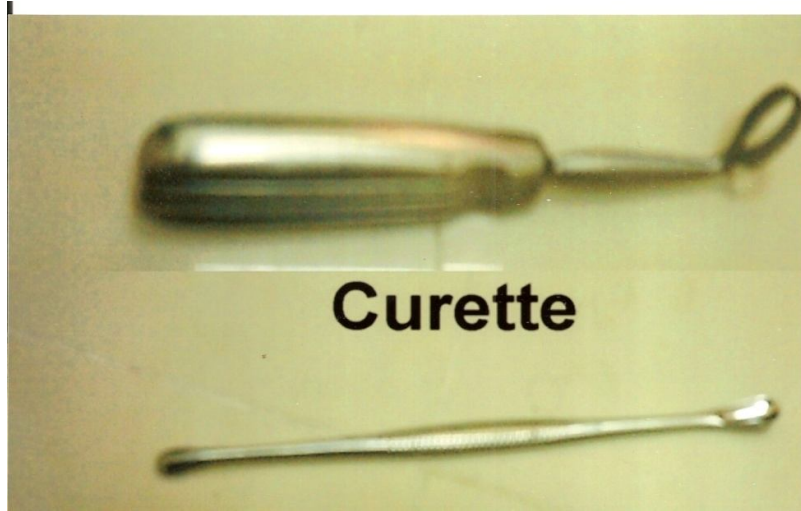
1-14. Speculum

منظار جوفى



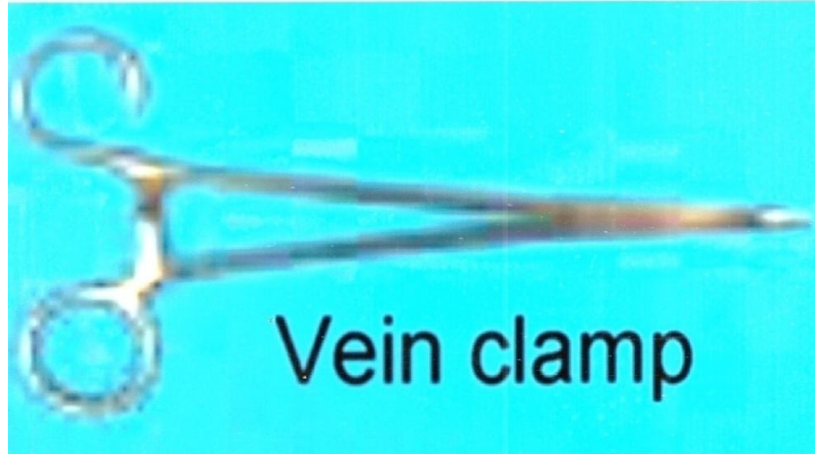
1-15. Curette

مكحنة



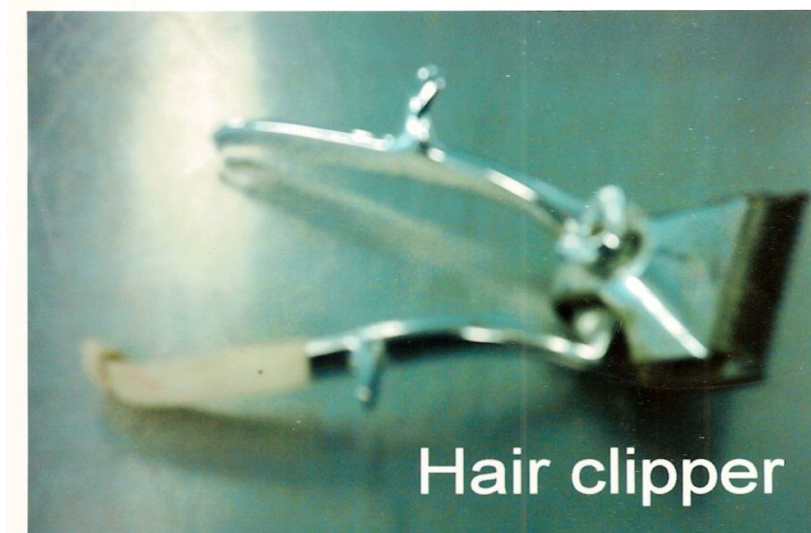1-16. Vein clamp

ملقاط الوريد



1-17. Hair clipper

مكنة حلاقة الشعر



1-18. Bulling gun

قازقة الحبوب



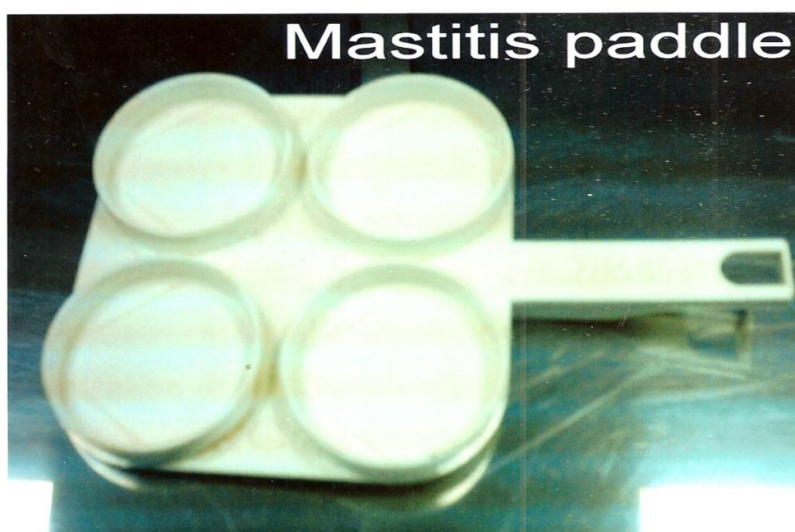1-19. Drinching gun

بنديقة تجريع السوائل



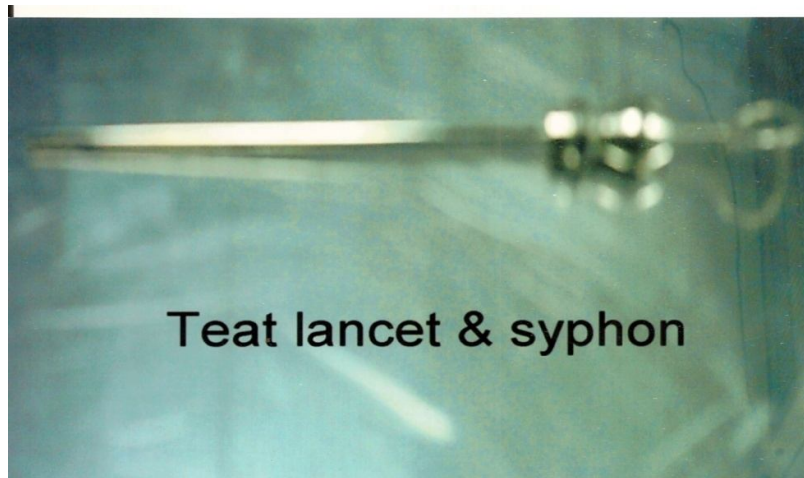
1-20. Mastitis paddle

طبق تشخيص التهاب الضرع



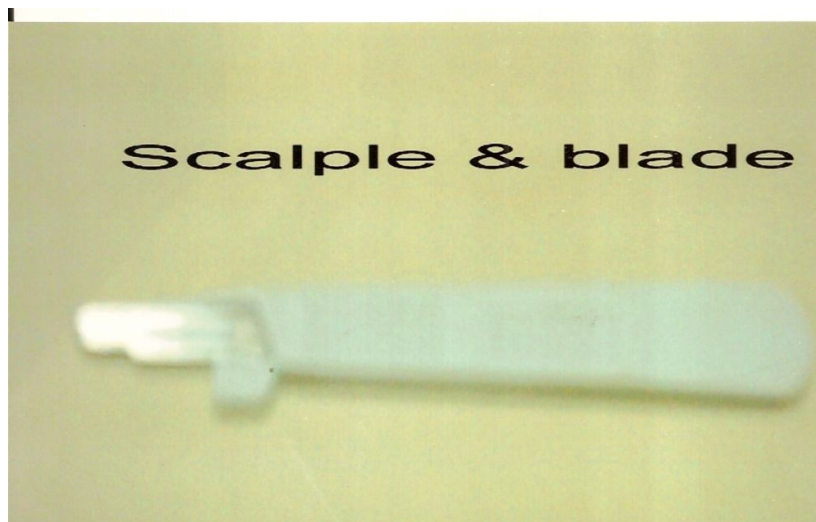
1-21. Teat lancet and siphon

مشرط حلمة الضرع والسيفون



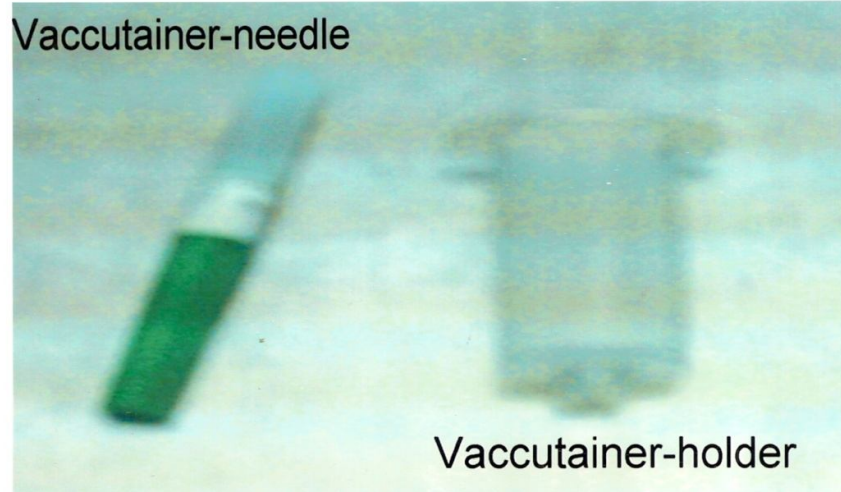
1-22. Scalple and blade

المشرط والمقبط



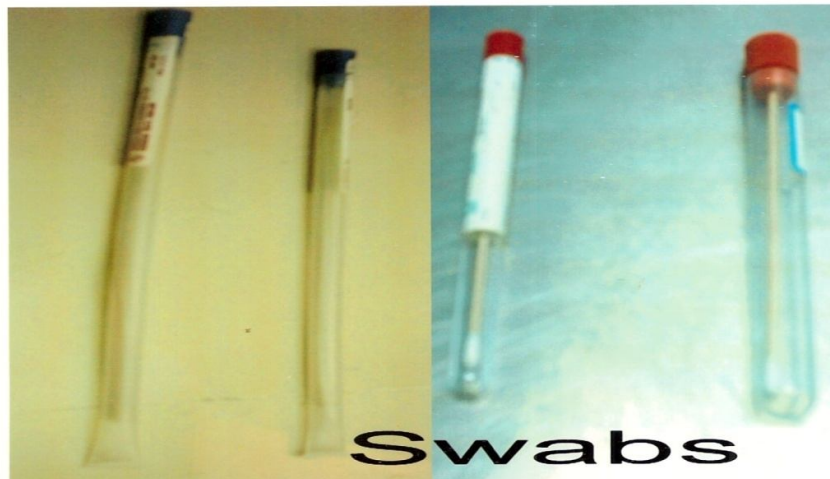1-23. Vacutainer –needle and holder

حامل الابرة المفرغ



1-24. Swabs

الماسحات



Physical examination

الفحص العضوى

Fig. (2)

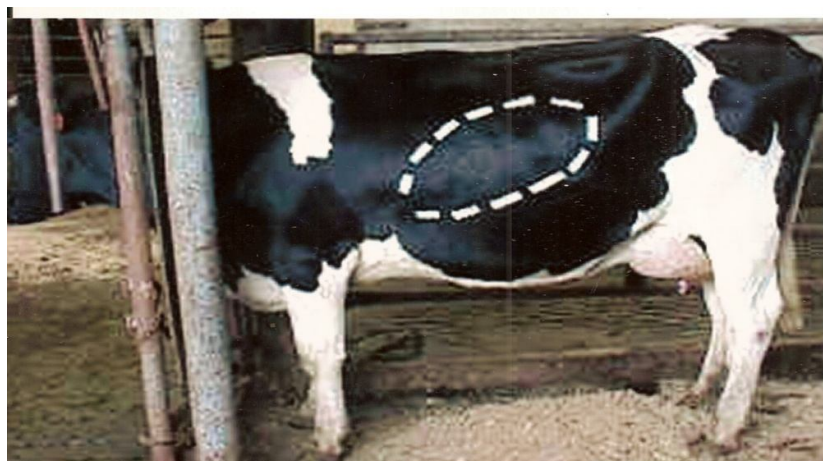2-1. An area of palpation of right abomasal displacement

منطقة جس المنفحة في الجانب الايمن



2-2. An area of palpation of left abomasal displacement

منطقة جس المنفحة في الجانب الايسر



2-3. An area of palpation of the rumen

منطقة جس الكرش



Fig.2-4 Palpation of the kidney

جس الكلية

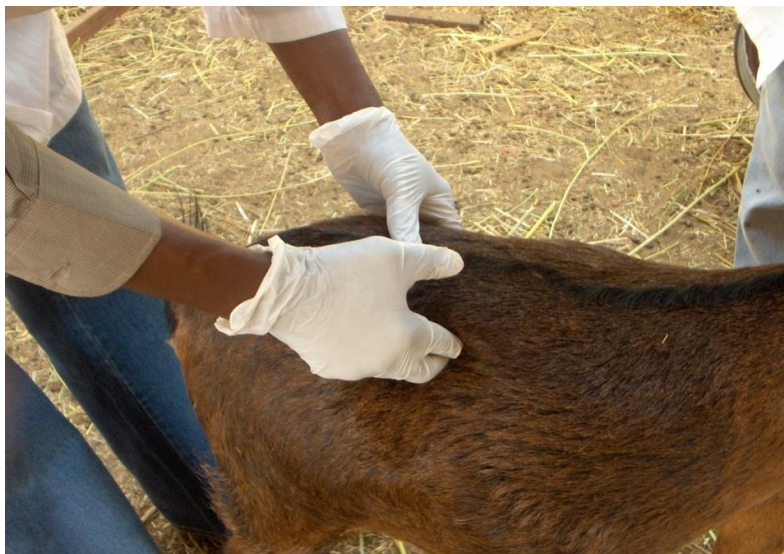

Fig.2-5 Palpation of udder

الضرع جس

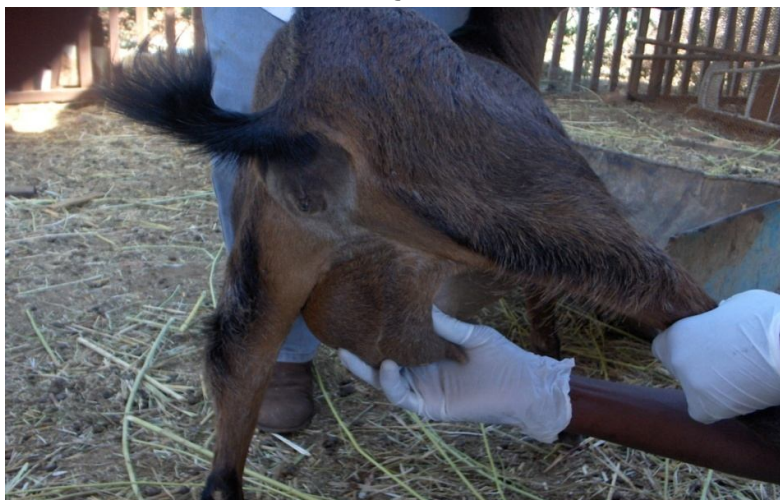

Fig. (3)

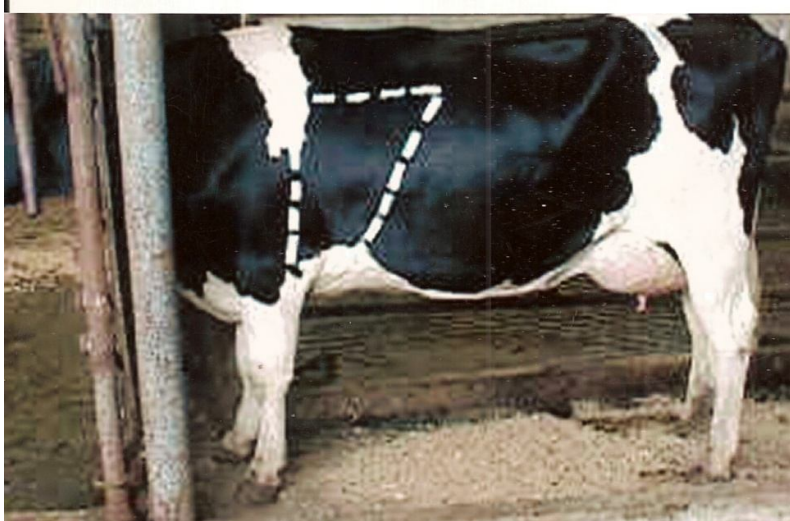3-1. An area of percussion and auscultation in bovine lung at the right side

منطقة الطرق والتسمع لرئة في الابقار في الجانب الايمن



منطقة الطرق والتسمع لرئة في الابقار في الجانب الايسر

2. An area of percussion and auscultation in bovine lung at the left side



**3-3. An area of percussion and auscultation in equine lung at the right.
side**

منطقة الطرق والتسمع لرئة فى الخيول فى الجانب الالىسر

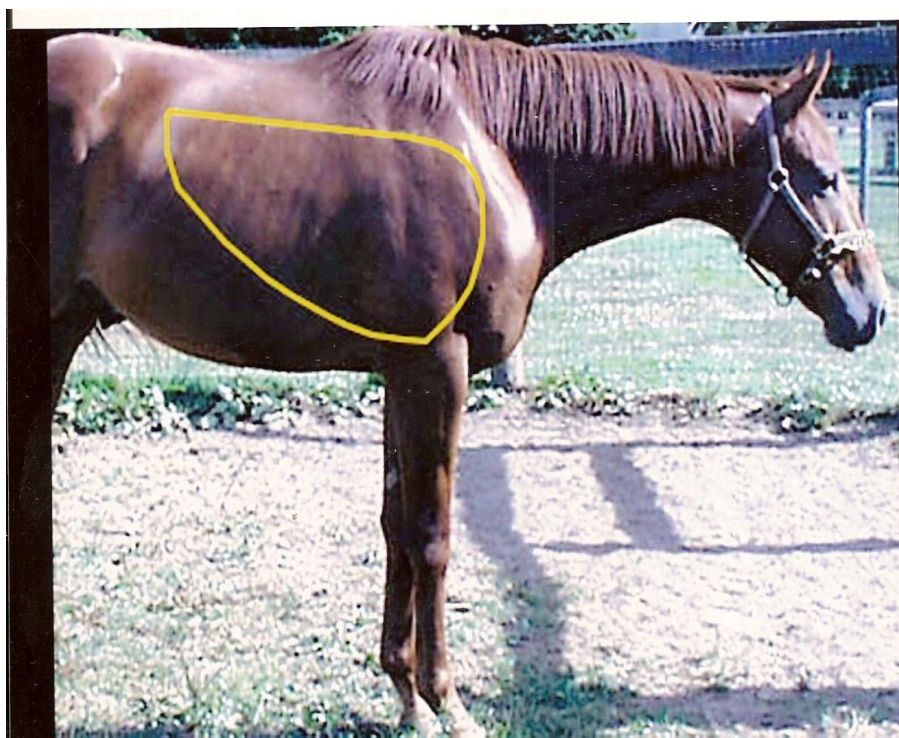

Fig. (4)
4- Procedure of taking body temperature
طريقة اخذ حرارة الجسم


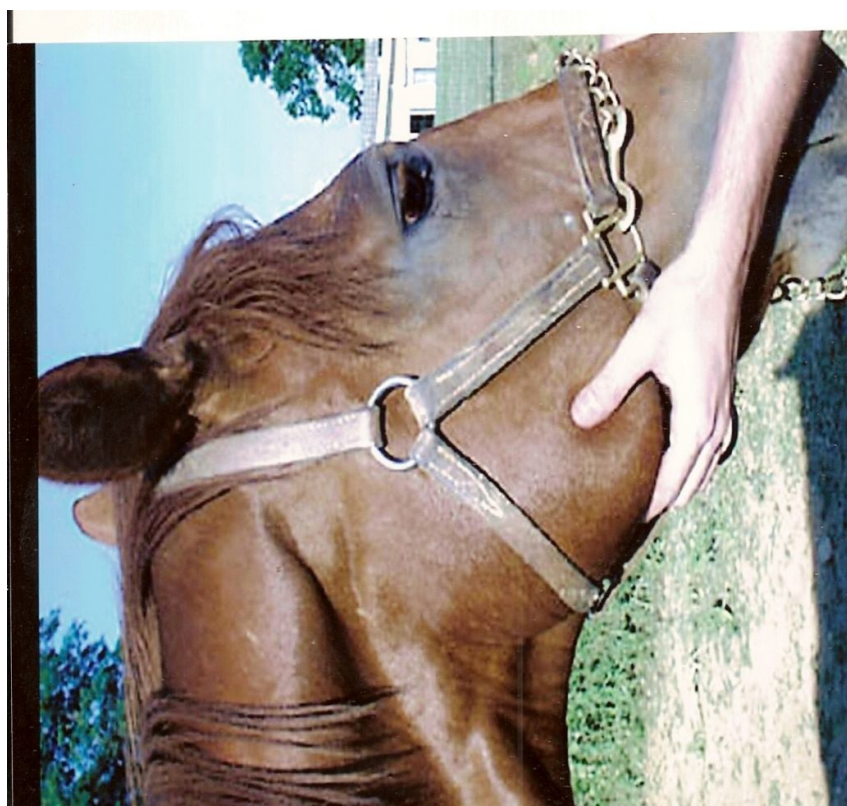


Fig. (5)

5- Procedure of taking pulse rate in equine – submandibular artery.

طريقة اخذ معدل النبض فى الخيول – الشريان تحت الفك



(Fig. 6) Regulation of the pulse

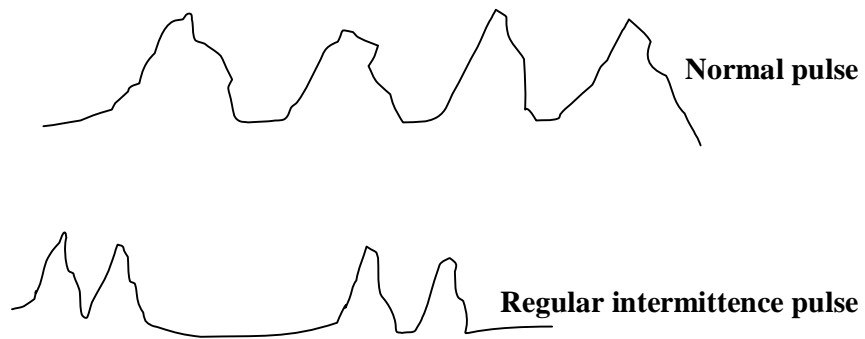
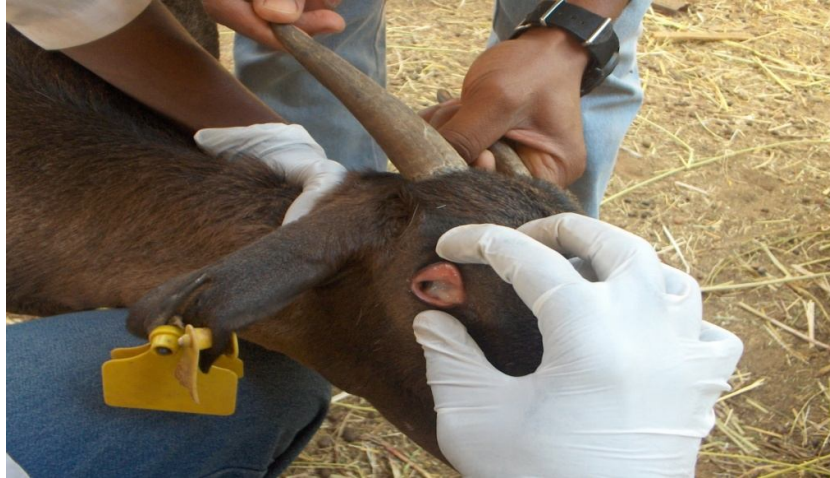
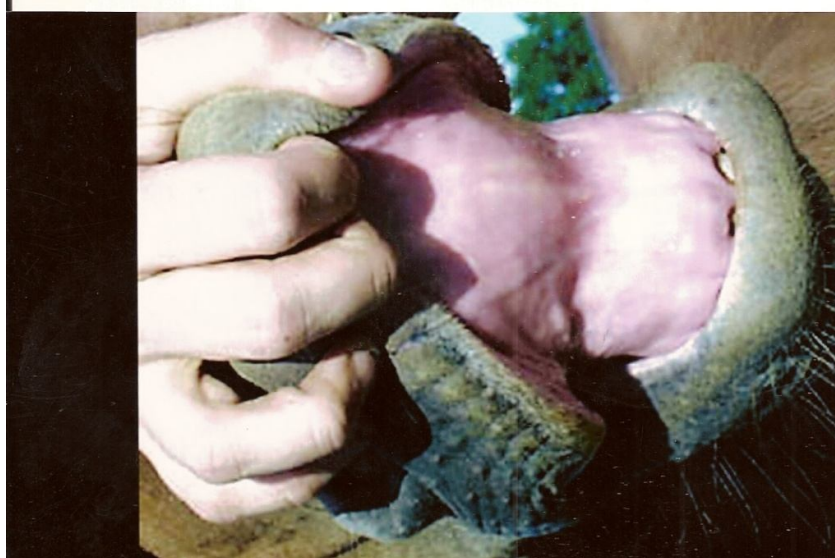
Fig. (7)
7-1. Examination of conjunctiva
فحص الملتحمة



7-2. Examination of mucous membranes – lip and gum



References

المراجع

- Kelly, W. R (1984). Veterinary clinical Diagnosis. 3rd edn .Bailliere Tindall. London. PP1- 417.
- Radostits, O.M; Gay, C.C; Hinch cliff, K.W; Constable, P.D. (2000).Veterinary Medicine 9th edn. W.B.Saunders Comp. London, USA, PP.3-39.
- قاموس متى الطبي - أنجليزي - عربي - د. يوسف متى وأحمد شفيق الخطيب (2005). الطبعة الثانية. مكتبة لبنان ناشرون - لبنان.
- مجمع العلوم البيطرية الموحد (2003) ب. محمد طه عبدالله شقدي وآخرون. صادر عن الهيئة العليا للتعليم بوزارة التعليم العالي والبحث العلمي، جمهورية السودان.