

Chapter One

:Introduction 1.1

In 1950 obstetric ultra sound has evolved into a major specialty of sonography. It has been proven to be available, cheap, safe and pain less procedure that offers invaluable information to obstetrician. Sonographic measurement of fetus provide information about fetal age and growth and detected any congenital abnormalities of the fetus. The true measure of age is the number of days since conception, term (conceptual age). Historically, pregnancies were dated by the number of days since the first day of the last menstrual period (LMP), term (menstrual age). In women with regular 28 day cycles, menstrual age is 2 weeks more than conceptual age because conception occurs approximately two weeks after Today the term most often used the LMP in such women. to date pregnancies is gestational age. Accurate knowledge of gestational age is important for a number of reasons. The timing of chorionic villous sampling in first trimester, genetic amniocentesis in the second trimester, and elective induction or cesarean delivery in the third trimester. The knowledge of the gestational age can be critical in distinguishing normal from pathologic fetal development Estimation of the gestational age by ultra sound measurement using mean sac Diameter (MSD) and

crown-rump length (CRL) in the first trimester. Many sonographic parameters have been proposed for estimating gestational age in the second and third trimester. These include several fetal measurement, Biparietal diameter (BPD), head circumference (HC), Abdominal circumference (AC), femur length (FL), and occipito frontal diameter (OFD). (Rumack Carol. M et al .(2005

Occipito frontal diameter not common used to estimate gestational age as independent parameter, but it combine with two or more fetal measurement such as BPD to measure the correct BPD and head circumference the length of occipito frontal diameter (OFD) done by measuring from the outer boarder of the occipital to the outer boarder of the frontal bone . (Sandra Hagen -Ansert .(1994

: Problem Statement 1.2

Occipito frontal diameter (OFD) measurement not used as dependent parameter for estimating gestational age & .head abnormalities

:Objectives 1.3

:General objective 1.3.1

To estimate gestational age by measuring occipito frontal diameter

:Specific objectives 1.3.2

- To estimate gestational age by occipito frontal diameter (OFD).
- To compare occipito frontal diameter measurement with Bi parietal diameter and femur length measurements.
- To compare gestation age from OFD with gestation age from LMp, BPD and FL.
- .To calculate the expected date of delivery

:Over view of the study 1.4

Chapter one included introduction and general and specific objectives

Chapter two includes: anatomy , physiology , and pathological condition .chapter three , presents methods and materials used during the study , chapter four : includes the results , chapter five : discussion , recommendation and conclusion , finally the references . and appendices are put on the last pages

Chapter Two

STAGES OF EMBRYONIC DEVELOPMENT 2-1

Carnegie staging in the development of the human embryo categorizes 23 stages.

(2-1-1-2 Fertilization and Implantation (Stages 1-3

Embryonic development commences with fertilization between a sperm and a secondary oocyte. The fertilization process requires about 24 hours and results in the formation of a zygote - a diploid cell with 46 chromosomes containing genetic material from both parents. This takes place in the ampulla of the uterine tube. The embryo's sex is determined at fertilization. An X chromosome-bearing Sperm produces an XX zygote, which normally develops into a female, whereas fertilization by a Y chromosome-bearing sperm produces an XY zygote, which normally develops into a male. The zygote passes down the uterine tube and undergoes rapid mitotic cell divisions, termed cleavage. These divisions result in smaller cells the blastomeres. Three days later, after the developing embryo enters the uterine cavity, compaction occurs, resulting in a solid sphere of 12-16 cells to form the morula. At 4 days, hollow spaces appear inside the compact morula and fluid soon passes into these cavities, allowing one large space to form and thus converting the morula into the blastocyst (blastocyst hatching). The

blastocyst cavity separates the cells into an outer cell layer, the trophoblast, which gives rise to the placenta, and a group of centrally located cells, the inner cell mass, which gives rise to both embryo and extraembryonic tissue. The zona pellucida hatches on day 5 and the blastocyst attaches to the endometrial epithelium. The trophoblastic cells then start to invade the endometrium. Implantation of the blastocyst usually takes place on day 7 in the mid portion of the body of the uterus, slightly more frequently on the posterior than on the anterior wall. (Gilbert et al 2004)

Gastrulation 2-1-2

Changes occur in the developing embryo as the bilaminar embryonic disc is converted into a trilaminar embryonic disc composed of three germ layers. The process of germ layer formation, called gastrulation, is the beginning of embryogenesis (formation of the embryo). Gastrulation begins at the end of the 1st week with the appearance of the hypoblast; it continues during the 2nd week with the formation of the epiblast and is completed during the 3rd week with the formation of intra embryonic mesoderm by the primitive streak. The three primary germ layers are called ectoderm, mesoderm, and endoderm. As the embryo develops, these layers give rise to the tissues and organs of the embryo. The blastocyst begins to become attached to the uterine lining (the endometrium). (Gilbert et al 2004)

Implantation 2-1-3

Implantation includes dissolution of the zona pellucida and adhesion between the blastocyst and the endometrium. Implantation occurs by the intrusion of trophoblastic extensions, which penetrate between apparently intact .(endometrial cells. (Gilbert et al 2004

(Second Week of Development (Stages 4 and 5 2-1-4

During the 2nd week, a bilaminar embryonic disc forms, amniotic and primary yolk sac cavities develop, and there are two layers of trophoblast

The two-layered disc separates the blastocyst cavity into two unequal parts (a smaller amniotic cavity and a larger primary yolk cavity). The thick layer of embryonic cells bordering the amniotic cavity is called the epiblast and a thin layer bordering the primary yolk cavity is called the hypoblast. The trophoblast differentiates into two layers, an inner cytotrophoblast and an outer syncytiotrophoblast. The trophoblast continues to penetrate deeper into the endometrium. At the end of the 2nd week, the site of implantation is recognized as a small elevated area of .endometrium having a central pore filled with a blood clot

(Third Week of Development (Stages 6-9 2-1-5

Formation of the primitive streak and three germ layers (ectoderm, mesoderm, and endoderm) occurs during the 3rd week. The primitive streak results from a proliferation

of ectodermal cells at the caudal end of the embryonal disc. Cells at the primitive streak proliferate to form the embryonic endoderm and mesoderm. The cephalic end of the primitive streak is the primitive node, and this cord of cells is the notochord. Thickening of ectodermal cells gives rise to the neural plate, the first appearance of the nervous system, which becomes depressed below the surface along the long axis of the embryo to form the neural groove. The neural groove deepens and its margins elevate to form the neural folds. The fusion is completed during the 4th week of development. The neural tube ultimately will give rise to the central nervous system. The cephalic end will dilate to form the forebrain, midbrain, and hindbrain. The remainder of the neural tube will become the spinal cord. The mesoderm on either side of the midline of the embryo (the paraxial mesoderm) undergoes segmentation, forming somites. The first pair of somites arises in the cervical region of the embryo at approximately day 20 of development. From there new somites appear in craniocaudal sequence, approximately three per day, until 42-44 pairs are present at the end of week 5. There are 4 occipital, 8 cervical, 12 thoracic, 5 lumbar, 5 sacral, and 8-10 coccygeal pairs. The first occipital and the last 5-7 coccygeal somites later disappear, while the remainder form the axial skeleton. During this period of development, the age of the embryo is expressed in the number of somites. Each somite differentiates into bones, cartilage, and ligaments of the

vertebral column as well as into skeletal voluntary muscles, dermis, and subcutaneous tissue of the skin. The intermediate mesoderm and the lateral mesoderm give rise to portions of the urogenital system. The lateral plate mesodermis involved in the development of pericardial, pleural, and peritoneal cavities as well as the muscle of the diaphragm. Mesoderm also forms a primitive cardiovascular system during the 3rd week of development. Blood vessel formation begins in the extra embryonic mesoderm of the yolk sac, the connecting stalk, and the chorion. Embryonic vessels develop 2 days later. The linkage of the primitive heart tube with blood vessels takes place toward the end of week 3, after which blood circulation begins. The beating heart tube begins at 17-19 days. The embryo changes shape from a disc to a tube with a cranial and a caudal end and the third germ layer, the endoderm, becomes incorporated into the interior of the embryo. The formation of chorionic villi takes place in the 3rd week. The cytotrophoblast cells of the chorionic villi penetrate the layer of syncytiotrophoblast to form a cytotrophoblastic shell, which attaches the .chorionic sac to the endometrial tissues

Fourth Week of Development (Stages 10-12: Up to Day 28, 2-1-6

(End of Blastogenesis

At this stage, the embryo measures 2-5mm). At stage 10, the embryo (at 22-24 days) is almost straight and has between 4 and 12 somites that produce conspicuous surface elevations. The neural tube is closed between the

somites but is widely open at the rostral and caudal neuropore. The first and second pairs of branchial arches .become visible

During stage 11, a slight curve is produced by folding of the head and tail. The heart produces a large ventral prominence. The rostral neuropore continues to close and optic vesicles are formed .In stage 12, three pairs of branchial arches complete closure of the rostral hemisphere and recognizable upper-limb buds on the ventral lateral body wall appear .The otic pits and the primordia of the inner ears become visible .Growth of the forebrain produces an enlargement of the head, and further folding of the embryo in the longitudinal plane results in a C-shaped curvature. Narrowing of the connection between the embryo and the yolk sac produces a body stalk containing one umbilical vein and .(two umbilical arteries.(Gilbert et al 2004

(Fifth Week of Development (Stages 13-15 2-1-7

At this stage, the embryo measures 5-10 mm in length. Rapid head growth occurs, caused mainly by rapid development of the brain. The upper limbs begin to show differentiation as the hand plates develop toward the end of this week. The fourth pair of branchial arches and the lower-limb buds are present by 28-32 days of development. Lens placodes of the eyes are visible on the sides of the head. The attenuated tail with its somites is a .characteristic feature at the beginning of week 5

(Sixth Week of Development (Stages 16 and 17 2-1-8

The crown-rump (CR) length of the embryo in this time period is 10–14 mm. At stage 16, nasal pits face ventrally, retinal pigment becomes visible, auricular hillocks appear, and the foot plate is formed. In stage 17, the C-shape of the embryo is still present. Development of finger rays and basic facial-structure formation advances . The upper lip appears when medial nasal prominences and maxillary prominences merge. The nostrils become clearly defined .and the eyes are directed more anteriorly

(Seventh Week of Development (Stages 18 and 19 2-1-9

At the end of the 7th week, the embryo attains a CR length of 20 mm. The head continues to enlarge rapidly and the trunk straightens. Elbow regions can be recognized on upper limbs, toe rays appear on the lower limbs, and the nipples become visible. Physiological herniation of the intestinal tract into the umbilical cord occurs . The intestinal loops normally return to the .abdomen by the end of the 10th week

(Eighth Week of Development (Stages 20-23 10--2-1

At this stage, the fingers are distinct but are still webbed. There are notches between the toe rays, and a scalp vascular plexus appears. Toward the end of week 8, the fingers become free and longer and the development of hands and feet approach each other. The head becomes more rounded and shows typical human characteristics. The embryo has a CR length of 20mmat the beginning of

the 8th week and is 30 mm in CR length at the end of the 8th week. All major organ systems are formed by the end of the 8th week - the completion of blastogenesis, organogenesis, and embryonic development. Then the .(fetal period begins.(Gilbert et al 2004

:Regionalization of the brain 2-1-3

The brain at the beginning of the fourth week possesses three distinct regions: the forebrain, midbrain and hindbrain (also known as the prosen-cephalon, mesencephalon and rhombencephalon, respectively).The early brain shows signs of being further divided into rather indistinct segments, known as neuromers . these can be observed most clearly in the hindbrain, where they are known as rhombomeres . These are now known to reflect underlying gene expression patterns. During the fourth week, the neural tube closes cranially and caudally and the three primary divisions give rise to a number of subsidiary structures even before the neural folds in the forebrain region fuse, lateral out pushing known as the optic sulci have formed . After fusion these form the optic vesicles , which will give rise to the retina and optic nerve. The forebrain (or prosencephalon) divides into the telencephalon cranial to the optic and the diencephalon, which extends back to the mesencephalon . the boundaries of the these regions are not always clear, but the names may help to simplify the complex task of describing the developing brain . The midbrain remains

undivided, and is given the definitive name of mesencephalon. The hindbrain (or rhombencephalon) gives rise to the metencephalon and the myelencephalon. The roof of the hindbrain also begins to thin out, in a manner which suggests that the neural tube is “ opening out, in this region . the brain and neural tube show a marked distinction between the ventral motor basal plates and the dorsal sensory alar plates. This means that alar regions lie lateral rather than dorsal to the basal regions, with only a single cell layer forming the roof. Within each of these five regions (telencephalon, diencephalon, mesencephalon, metencephalon and myelencephalon) the cavity of the neural tube expands to form the primitive ventricles. During the fourth week a ventral-facing bend begins to develop in the mesencephalic region. This is known as the cephalic flexure. At about the same time the cervical flexure appears in the region between the rhombencephalon and the spinal cord. During the fifth week, a dorsal-facing flexure appears between the metencephalon and the myelencephalon. This known as the pontine flexure . the mechanisms underlying development of these flexions remain to be elucidated, but may involve differential cell division and change of cell shape. (John McLachlan 1994

:Further development of regionalization 2.1.4

The telencephalon: From about 5 weeks a substantial pair of lobes begins to grow out from the most cranial end of the telencephalon: these are the cerebral hemispheres .

from these beginnings they will grow dorsally and caudally to cover almost completely the original brain stem. The rapid growth of the cerebral hemispheres causes folds and fissures to form on their surface. In addition to these most advanced of brain structures in terms of evolutionary status the telencephalon gives rise to the olfactory bulb and tract, which are among the most primitive.

The diencephalon: Inside the diencephalon, lying just cranial to the cephalic flexure three paired structures begin to develop, growing in from the lateral walls. These are from dorsal to ventral as the flexed tube lies the epithalamia, the thalami, and the hypothalami. The thalami bulge out into the lumen of the diencephalon. The hypothalami meet and fuse to form the definitive hypothalamus : in many cases the thalami also meet in the midline and fuse, although the lumen of the brain is not completely occluded. A downward extension of the lumen of the brain is not completely occluded. A downward extension of the diencephalon , known as the infundibulum, represent what will become the stalk and the pars nervosa of the pituitary gland.

The mesencephalon: The mesencephalon stays comparatively unaltered in gross terms during development. However, an external median groove appears in the mesencephalic roof, which is subsequently crossed at right angles by a second groove. The four quadrants thus formed represent the superior and inferior colliculi. Each of the basal plates of the mesencephalon forms two motor nuclei, which innervate the eye

musculature and the sphincter papillary muscle. Metencephalon and myelencephalon: The pontine flexure results in the roof of the metencephalon and myelencephalon adopting a rhomboidal shape rather in the way that a sharply flexed hose behaves. The edges of this rhomboid in the metencephalon will proliferate to form the cerebellum, which controls posture and movement. The basal plates of the metencephalon form three groups of motor neurons, containing the nuclei of the abducens, trigeminal and facial nerves and the nerves to the submandibular and sublingual salivary glands. The marginal layer of the basal plates forms the pons, so named because it forms a bridge between the spinal cord and the cerebellar and cerebral cortices. The myelencephalon will develop into the medulla oblongata. Motor nerve nuclei form in the basal plate and sensory nervenuclei in the alar plate. The brain and spinal cord are surrounded by mesoderm, which condenses around the brain and will eventually form three distinct layers: the pia mater next to the brain, the arachoid mater, and the outer dura mater. (John McLachlan 1994)

:Brain vesicles and cerebrospinal fluid 2.1.5

At the same time as these developments are taking place, the fluid-filled lumen of the neural tube is undergoing changes. As the cerebral hemispheres expand their central cavities also expand, and become the lateral ventricles. The cerebral hemispheres grow back and over the brain

and the lateral ventricles change shape accordingly , to adopt an extended c-shaped form. The lateral ventricles communicate with the main neural cavity via narrow openings known as the interventricular foramina of Munro. The main cavity in the region surrounded by the diencephalon is described as the third ventricle. The cavity in the mesencephalic region into the cavity of the rhombencephalon: the fourth ventricle. Before fusion of the neural tube is complete the neural cavity is continuous with amniotic cavity and amniotic fluid bathes the interior of the neural tube. When the tube has closed at both ends it is filled in the early stages with a simple filtrate of the fetal blood. Subsequently, the meningeal mesoderm above the dorsal aspect of the brain in several regions becomes richly vascularized, and from about 6 weeks special structures containing blood vessels become apparent, projecting down from the roof of the brain into the lumen of the neural tube. These are the choroid plexuses: from their membranous appearance, which was thought to resemble the true chorion, and in the fetus and adult they are major producers of cerebrospinal fluid (CSF). There are four choroid plexuses altogether, projecting into the left and right lateral ventricles and the third and fourth ventricles. During the fetal period three openings appear in the thin roof of the metencephalon, one median and two lateral. These allow CSF to pass from the lumen of the neural tube to the subarachnoid space. Arachnoid villi protrude across the

subdural space , through the dura and into the dural venous sinuses, through which CSF is reabsorbed into the venous blood, hence establishing a circulation.(John .(McLachlan 1994

: **Neurocranium 2-1-6**

The Neurocranium is most conveniently divided into two portions: The membranous part, consisting of flat bones. Which surround the brain as a vault, and The cartilaginous part, or chondrocranium, which forms bones of the base of the skull .The membranous portion of the skull is derived from neural crest cells and paraxial mesenchyme from these two sources invests the brain and undergoes membranous ossification. The result is formation of a number of flat, membranous bones that are characterized by the presence of needle like bone spicules. These spicules progressively radiate from primary ossification centers toward the periphery. With further growth during fetal and postnatal life, membranous bones enlarge by apposition of new layers on the outer surface and by simultaneous osteoclastic resorption from the inside. The cartilaginous neurocranium or chondrocranium of the skull initially consists of a number of separate cartilages. Those that lie in front of the rostral limit of the notochord, which ends at the level of the pituitary gland in the center of the sella turcica , are derived from neural crest cells. They form the prechordal chondrocranium. Those that lie posterior to this limit arise from occipital

sclerotomes formed by paraxial mesoderm and form the chordal chondrocranium. The base of the skull is formed when these cartilages fuse and ossify by endochondral (ossification). (Sandler, T.W. 2009)

:Newborn skull 2-1-7

At birth, the flat bones of the skull are separated from each other by narrow seams of connective tissue, the sutures, which are also derived from two sources: neural crest cells (sagittal suture) and paraxial mesoderm (coronal suture). At points where more than two bones meet, sutures are wide and are called fontanelles. The most prominent of these is the anterior fontanelle, which is found where the two parietal and two frontal bones meet. Sutures and fontanelles allow the bones of the skull to overlap (molding) during birth. Soon after birth, membranous bones move back to their original positions, and the skull appears large and round. In fact, the size of the vault is large compared with the small facial region. Several sutures and fontanelles remain membranous for a considerable time after birth. The bones for the vault continue to grow after birth mainly because the brain grows. Although a 5 to 7 year - old child has nearly all of his or her cranial capacity, some sutures remain open until adulthood. In the first few years after birth palpation of anterior fontanelle may give valuable information as to whether ossification of the skull is proceeding normally and whether intracranial pressure is normal. In most cases,

the anterior fontanelle closes by 18 months of age and the posterior fontanelle closes by 1 to 2 months of age.
.(Sandler, T.W.2009

:Physiology of the brain 2--2

The central nervous system contains more than 100 billion
.neurons

a typical neuron of a type found in the brain motor cortex.

Incoming
signals enter this neuron through synapses located mostly
on the neuronal dendrites, but also on the cell body. For
different types of neurons, there may be only a few
hundred or as many as 200,000 such synaptic connections
from input fibers. Conversely, the output signal travels by
way of a single axon leaving the neuron. Then, this axon
has many separate branches to other parts of the nervous
.system or peripheral body

A special feature of most synapses is that the signal
normally passes only in the forward direction (from the
axon of a preceding neuron to dendrites on cell
membranes of subsequent neurons). This forces the signal
to travel in required directions for performing specific
.(nervous functions.(Guyton et al 2006

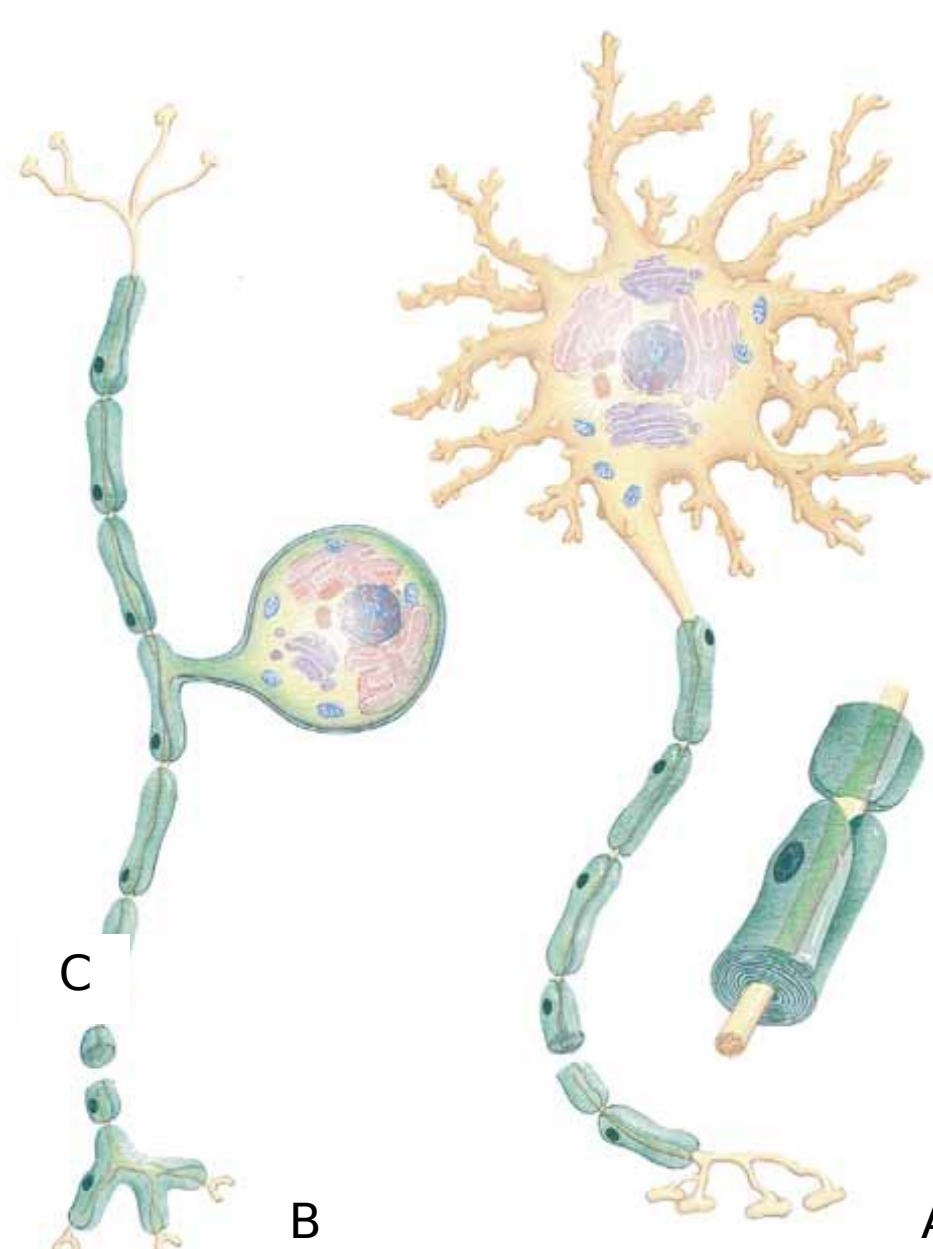


Figure (2 -1) (A) A typical sensory neuron.(B) A typical motor neuron .(C) Details of the myelin sheath and neurolemma formed by Schwann cells .(Guyston et al2006)

Sensory Part of the Nervous System—Sensory Receptors

Most activities of the nervous system are initiated by sensory experience exciting sensory receptors, whether visual receptors in the eyes, auditory receptors in the ears, tactile receptors on the surface of the body, or other kinds of receptors. This sensory experience can either cause immediate reaction from the brain, or memory of the experience can be stored in the brain for minutes, weeks, or years and determine bodily reactions at some future date. The somatic portion of the sensory system, which transmits sensory information from the receptors of the entire body surface and from some deep structures. This information enters the central nervous system through peripheral nerves and is conducted immediately to multiple sensory areas in (1) the spinal cord at all levels; (2) the reticular substance of the medulla, pons, and mesencephalon of the brain; (3) the cerebellum; (4) the thalamus; and (5) areas of the cerebral cortex. (Guyton et al 2006)

Motor Part of the Nervous System— Effectors 2-2--2

The most important eventual role of the nervous system is to control the various bodily activities. This is achieved by controlling (1) contraction of appropriate skeletal muscles throughout the body, (2) contraction of smooth muscle in the internal organs, and (3) secretion of active chemical substances by both exocrine and endocrine glands in

many parts of the body. These activities are collectively called motor functions of the nervous system, and the muscles and glands are called effectors because they are the actual anatomical structures that perform the functions dictated by the nerve signals. The skeletal motor nerve axis of the nervous system for controlling skeletal muscle contraction. Operating parallel to this axis is another system, called the autonomic nervous system, for controlling smooth muscles, glands, and other internal bodily systems; Note that the skeletal muscles can be controlled from many levels of the central nervous system, including (1) the spinal cord; (2) the reticular substance of the medulla, pons, and mesencephalon; (3) the basal ganglia; (4) the cerebellum; and (5) the motor cortex. Each of these areas plays its own specific role, the lower regions concerned primarily with automatic, instantaneous muscle responses to sensory stimuli, and the higher regions with deliberate complex muscle movements controlled by the thought processes of the brain.

Processing of Information— “Integrative” Function of the Nervous System

One of the most important functions of the nervous system is to process incoming information in such a way that appropriate mental and motor responses will occur. More than 99 per cent of all sensory information is discarded by the brain as irrelevant and unimportant. For instance, one is ordinarily unaware of the parts of the

body that are in contact with clothing, as well as of the seat pressure when sitting. Likewise, attention is drawn only to an occasional object in one's field of vision, and even the perpetual noise of our surroundings is usually relegated to the subconscious. But, when important sensory information excites the mind, it is immediately channeled into proper integrative and motor regions of the brain to cause desired responses. This channeling and processing of information is called the integrative function of the nervous system. Thus, if a person places a hand on a hot stove, the desired instantaneous response is to lift the hand. And other associated responses follow, such as moving the entire body away from the stove, and perhaps even

.(shouting with pain.(Guyton et al 2006

:Role of Synapses in Processing Information 2-2-4

The synapse is the junction point from one neuron to the next. However, it is important to point out here that synapses determine the directions that the nervous signals will spread through the nervous system. Some synapses transmit signals from one neuron to the next with ease, whereas others transmit signals only with difficulty. Also, facilitatory and inhibitory signals from other areas in the nervous system can control synaptic transmission, sometimes opening the synapses for transmission and at other times closing them. In addition, some postsynaptic neurons respond with large numbers of output impulses, and others respond with only a few. Thus,

the synapses perform a selective action, often blocking weak signals while allowing strong signals to pass, but at other times selecting and amplifying certain weak signals, and often channeling these signals in many directions rather than only one direction

Storage of Information—Memory 2-5--2

Only a small fraction of even the most important sensory information usually causes immediate motor response. But much of the information is stored for future control of motor activities and for use in the thinking processes. Most storage occurs in the cerebral cortex, but even the basal regions of the brain and the spinal cord can store small amounts of information. The storage of information is the process we call memory, and this, too, is a function of the synapses. That is, each time certain types of sensory signals pass through sequences of synapses, these synapses become more capable of transmitting the same type of signal the next time, a process called facilitation. After the sensory signals have passed through the synapses a large number of times, the synapses become so facilitated that signals generated within the brain itself can also cause transmission of impulses through the same sequences of synapses, even when the sensory input is not excited. This gives the person a perception of experiencing the original sensations, although the perceptions are only memories of the sensations. We know little about the precise mechanisms by which long-term facilitation of synapses occurs in the

memory process. Once memories have been stored in the nervous system, they become part of the brain processing mechanism for future “thinking.” That is, the thinking processes of the brain compare new sensory experiences with stored memories; the memories then help to select the important new sensory information and to channel this into appropriate memory storage areas for future use or into motor areas to cause immediate bodily responses .
.(Guyton et al 2006

Major Levels of Central Nervous System Function 2-6--2

The human nervous system has inherited special functional capabilities from each stage of human evolutionary development. From this heritage, three major levels of the central nervous system have specific functional characteristics: (1) the spinal cord level, (2) the lower brain or sub cortical level, and (3) the higher brain or cortical level

Spinal Cord Level : We often think of the spinal cord as being only a Conduit for signals from the periphery of the body to the brain, or in the opposite direction from the brain back to the body .This is far from the truth. Even after the spinal cord has been cut in the high neck region, many highly organized spinal cord functions still occur. For instance, neuronal circuits in the cord can cause (1) walking movements, (2) reflexes that withdraw portions of the body from painful objects, (3) reflexes that stiffen the legs

to support the body against gravity, and (4) reflexes that control local blood vessels, gastrointestinal movements, or urinary excretion. In fact, the upper levels of the nervous system often operate not by sending signals directly to the periphery of the body but by sending signals to the control

“centers of the cord, simply “commanding the cord centers to perform their functions. **Lower Brain**

or Sub cortical Level : Many, if not most, of what we call subconscious activities of the body are controlled in the lower areas of the brain—in the medulla, pons, mesencephalon, hypothalamus, thalamus, cerebellum, and basal ganglia. For instance, subconscious control of arterial pressure and respiration is achieved mainly in the medulla and pons. Control of equilibrium is a combined function of the older portions of the cerebellum and the reticular substance of the medulla, pons, and mesencephalon. Feeding reflexes, such as salivation and licking of the lips in response to the taste of food, are controlled by areas in the medulla, pons, mesencephalon, amygdale , and hypothalamus. And many emotional patterns, such as anger, excitement, sexual response, reaction to pain, and reaction to pleasure, can still occur after destruction of much of the cerebral cortex. **Higher**

Brain or Cortical Level: After the preceding account of the many nervous system functions that occur at the cord and lower brain levels, one may ask, what is left for the cerebral cortex to do? The answer to this is complex, but it begins with the fact that the cerebral cortex is an

extremely large memory storehouse. The cortex never functions alone but always in association with lower centers of the nervous system. Without the cerebral cortex, the functions of the lower brain centers are often imprecise. The vast storehouse of cortical information usually converts these functions to determinative and precise operations. Finally, the cerebral cortex is essential for most of our thought processes, but it cannot function by itself. In fact, it is the lower brain centers, not the cortex, that initiate wakefulness in the cerebral cortex, thus opening its bank of memories to the thinking machinery of the brain. Thus, each portion of the nervous system performs specific functions. But it is the cortex that opens a world of stored information for use by the . (mind. (Guyton et al 2006

: Pathology of the Fetal Head 3--2

The embryonic brain and spinal cord develop from the neural tube. Anomalous development of the neural tube results in neural tube defects (NTD's) of varying degrees and significance. NTD's may be either open or closed. An open defect indicates the neural tissue (brain or spinal cord) is not covered by the normal integuments or covering tissue layers such as skin and subcutaneous fat. Cranial NTD's include anencephaly, encephalocele, and cranial meningocele. Spinal NTD's include spina bifida, spinal meningocele, and meningomyelocele. Open NTD's are usually associated with elevated maternal serum and amniotic fluid alpha-fetoprotein concentrations. (Gilani (2003

Anencephaly 3-1--2

Anencephaly is defined as absence of the cranial vault and higher brain (cerebrum). Absence of the cranial vault with a variable amount of disorganized brain tissue is defined as acrania. With advancing gestational age, acrania is associated with progressive degeneration of the fetal brain such that acrania progresses to anencephaly, namely the acrania-anencephaly sequence. Although anencephaly technically means absence of the brain, functioning neural tissue (brain stem and portions of the midbrain) is usually present and the majority of fetuses grow and are born alive. Anencephaly is the most common anomaly of the neural tube and results from failure of the neural tube to

completely close at its cephalic end. Although the cranium is absent with anencephaly and acrania, the base of the skull and orbits are normally present. (Gilani,2003

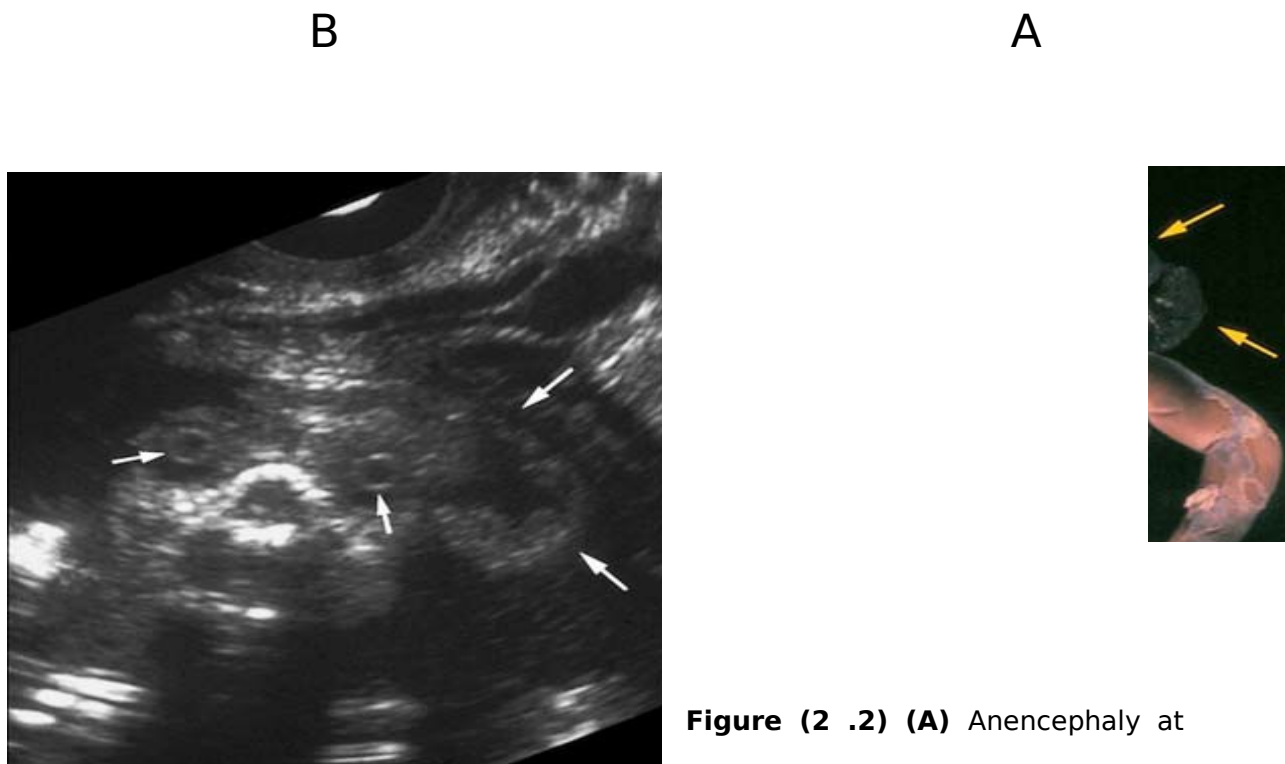


Figure (2 .2) (A) Anencephaly at 27-weeks gestation with a “beret” of brain tissue (yellow arrows) present. **(B)** Ultrasound showing the “beret” of brain tissue (large arrows) adjacent to the orbit (small arrows) on the right. (Gelbirt 2006

ENCEPHALOCELE 3-2--2

In encephalocele, the intracranial contents protrude through a bony defect of the skull. When brain tissue is in the herniated sac, it is called an encephalocele. The incidence is 0.3 to 0.6 in 1,000 live births. It may be associated with maternal rubella, hyperthermia, and

diabetes. In occipital encephalocele, the bony defect may include the foramen magnum and the posterior arch of the atlas. The brainstem is often abnormal and the spinal cord may show developmental defects. Occipital encephalocele is common in iniencephaly and in the Meckel syndrome. Encephalocele also may occur in the parietal and anterior regions. Parietal encephaloceles are usually midline, and the associated abnormalities may be an absent corpus callosum, a Dandy-Walker defect, or other brain malformations. An anterior encephalocele may be visible or externally invisible, and the amount of brain tissue present within the sac varies greatly. With all types of encephaloceles, there may be an associated microcrania .(or a hydrocephalus.(Gilbert 2004

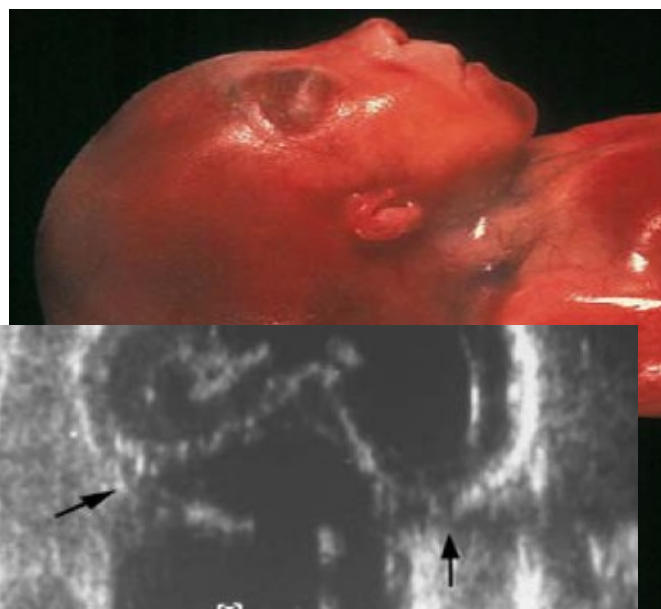
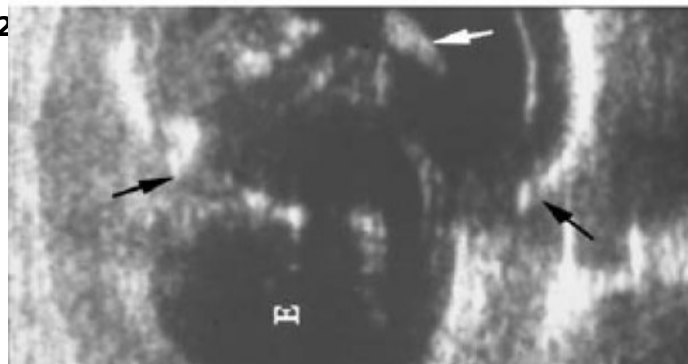


Figure (2)



Figures:(2 -4) Ultrasound of occipital encephalocele. (Black arrows, (edge of skull bonedefect; white arrow, choriod plexus). (Gilbert 2004

HYDROCEPHALUS 3-3 --2

Hydrocephalus is an increase in the amount of intraventricular cerebrospinal fluid (CSF). It is usually due to an obstruction. The incidence varies from 0.3 to 2.5 per . 1,000 live births



(Figure(2.5) 30weekfetuswithlarge hydrocephalus (Gilbert 2006

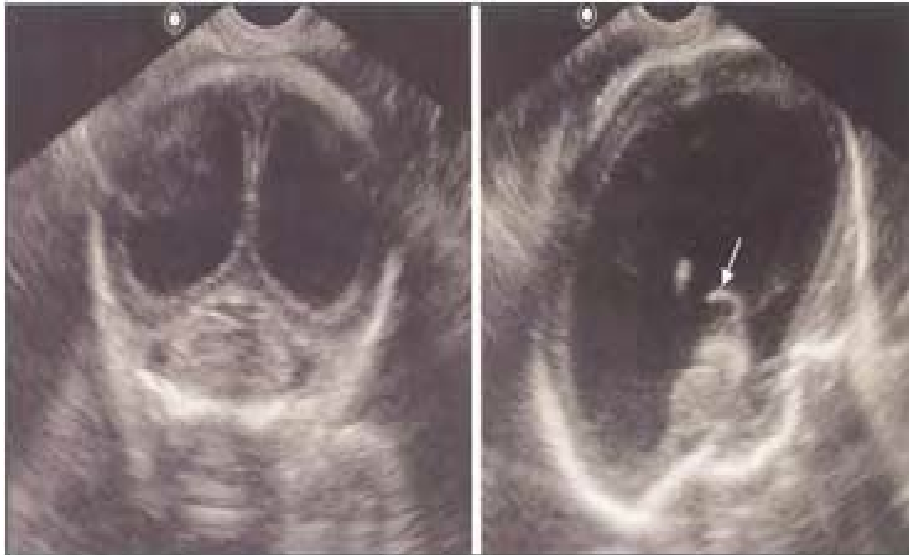

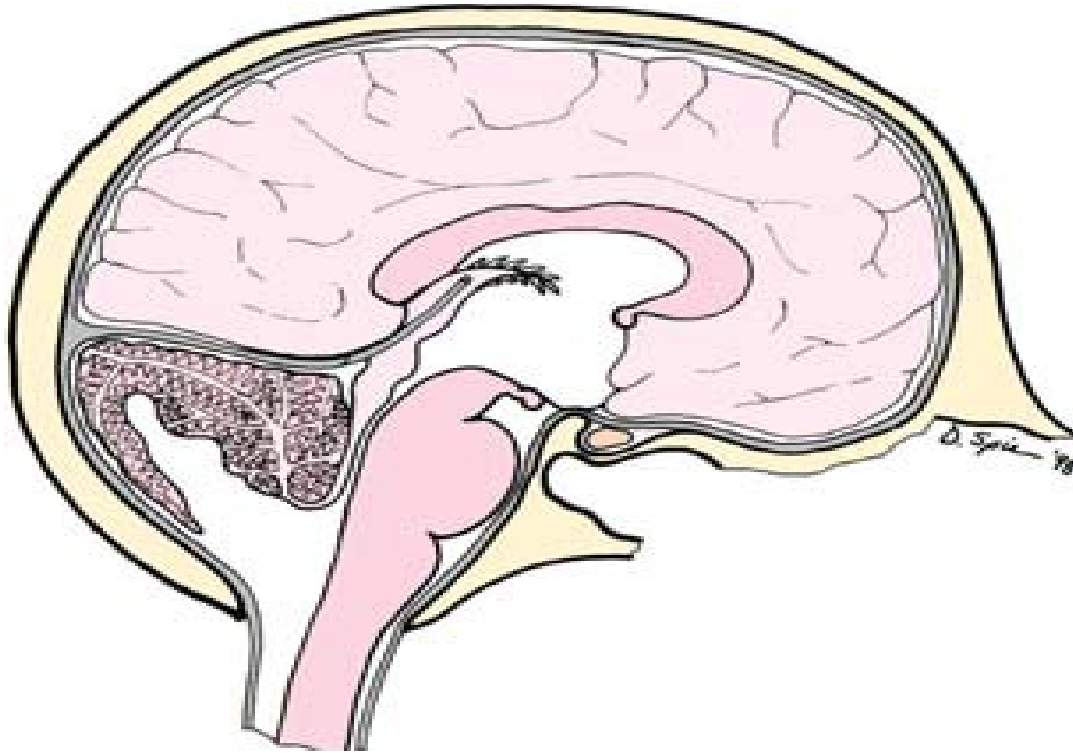
Figure (2-6) Fetal hydrocephalus at 34 weeks of gestation, (left) Coronal image. Subarachnoid space is obliterated, (right) Sagittal image. Dangling choroid plexus is demonstrated (arrow). (Asim kurja 2006)

Ex vacuo hydrocephalus, due to a loss of brain tissue, has not been described in previable fetuses. Obstruction may be at the aqueduct of Sylvius that is narrowed or malformed. There may be malformations of the hindbrain such as the Arnold- Chiari malformation, in which the cerebellar vermis protrudes through the foramen magnum and the medulla is displaced past the foramen magnum to obstruct CSF flow. This malformation is commonly seen with myelocoele and has been detected as early as the 10th week of gestation. Dandy-Walker malformation consists of hypoplastic or absent cerebellar vermis, enlarged fourth ventricle widely separating the cerebral hemispheres, and the foramina of Magendie and Luschka absent from the abnormal roof of the ventricle. Hydrocephalus can develop early in the second trimester

of pregnancy or it may not develop until after birth. It may be associated with a variety of infections or mutant genes. An X-linked recessive aqueductal stenosis occurs in about 2% of cases in which there are no other abnormalities. Hydrocephalus also may be inherited as a dominant or a multifactorial condition. It also may be part of syndromes such as achondroplasia, osteogenesis imperfecta, Hurler syndrome, or, rarely, tuberous sclerosis. .((Gilbert 2004

(DANDY-WALKER MALFORMATION (DWM 3-4-- 2

DWM includes dilation of the fourth ventricle, described as a posterior fossa cyst and hypoplasia or absent vermis .The membrane of the pseudocyst, composed of dysplastic ependyma and meninges with ectopic cerebellar tissue, is continuous with the lining of the fourth ventricle. Hydrocephalus is usually associated with DWM, a prominent occiput, and an enlarged posterior fossa. DWM is frequently associated with other CNS and/or extra-CNS abnormalities including defects of the corpus callosum, polymicrogyria, heterotopias, and malformed or ectopic inferior olives, also with Meckel and fetal alcohol .syndromes

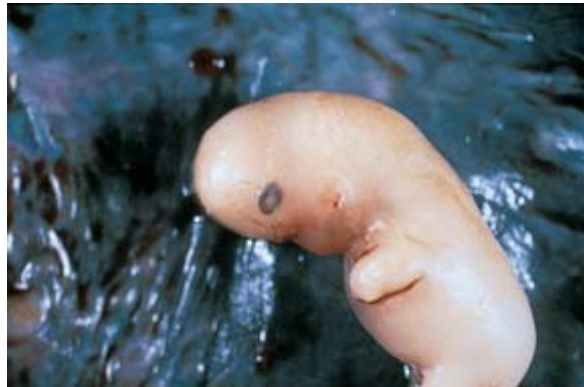

.(**Figure (2 -7)** Dandy-walker malformation (Gilbert 2006

MICROCEPHALY 3-5--2

Microcephaly is a small head, while micrencephaly is a small brain. Microcephaly is a head circumference below 3 SD. In newborns, isolated microcephaly is present in about 1 in 6,200 to 1 in 40,000 live births . In embryos with chromosome abnormalities such as trisomy 9, 13, 14, 18, 22, microcephaly is common. Microcephaly is rare in spontaneously aborted, chromosomally normal fetuses. Ultrasound intrauterine diagnosis of fetal microcephaly can be made. Primary microcephaly may be recessive, dominant, or X-linked. One hundred distinct familial syndromes with microcephaly have been documented. Twenty to 30% are estimated to be genetic. It is a common

feature in chromosomal Disorders . Secondary, acquired microcephaly may be due to maternal/fetal infections, CNS circulatory impairment, intoxication , or radiation. In intrauterine malnutrition with growth retardation, the brain .is less affected than the other organs



.(**Figure (2-8)** Embryo of 41 days with microcephaly (Gilbert 2006

(Agenesis of the Corpus Callosum (ACC 6- 3- -2

ACC may be partial or complete, and can occur as an isolated anomaly or in association with other anomalies. The most common concurrent abnormality is DWM. With standard axial views of the fetal head, the sonographic diagnosis of ACC depends more on demonstrating secondary changes associated with ACC rather than in direct observation of an absent corpus callosum. The key sonographic features of ACC in the standard axial view of the fetal head are absence of the cavum septum pellucidum and colpocephaly. Presence of the cavum

septum pellucidum excludes ACC since development of the CSP depends on formation of the corpus callosum.

Colpocephaly describes enlargement of the occipital and atrial region of the lateral ventricle resulting in a "teardrop" appearance to the lateral ventricle (large occipital horn - narrow body and anterior horn). Other sonographic features include lateral displacement of the lateral ventricles due to relative widening of the longitudinal fissure and upward displacement of the third ventricle. The best view to demonstrate the corpus callosum and make the diagnosis of ACC is the midline sagittal view. This view is usually difficult to obtain and suboptimal with standard transabdominal imaging. The best detail for this view is an endovaginal approach with the fetus in a cephalic presentation and guiding the sound beam through the anterior fontanelle. A sonographic feature of ACC in the midline sagittal view is an abnormal branching pattern of the median gyri known referred to as the sunburst pattern. Another ancillary diagnostic feature of ACC in the midsagittal view is absence of the normally detectable pericallosal artery on CD imaging. The normal pericallosal artery can be seen immediately anterior to the most anterior portion of the corpus callosum and cavum

. (septi pellucidi).(Gilani 2003

Holoprosencephaly 3-7--2

is failure of division of the prosencephalon (forebrain) resulting in varying degrees of prosencephalon midline defects classified as alobar, semilobar, and lobar. The most common form of holoprosencephaly recognized prenatally is alobar which is characterized by absence of supratentorial midline structures (falx cerebri, corpus callosum, septi pellucidi), a single, large central lateral ventricle (referred to as monoventricle), fused thalami, and a spectrum of facial abnormalities, most notably hypotelorism and median cleft lip and palate. Alobar holoprosencephaly is also frequently associated with trisomy 13. The key sonographic feature of a lobar holoprosencephaly is the enlarged monoventricular cavity with fused thalami surrounded by varying amounts of residual cerebral brain tissue and absence of the supratentorial midline structures. The shape of the monoventricular cavity is variable and depends largely on the amount and location of residual brain. The choroid plexus is usually compressed and difficult to visualize.

. (Gilani 2003 module 4

ULTRASOUND EVALUATION OF THE FETAL HEAD 2-4

The fetal head is normally evaluated in axial or oblique axial sections from the vertex to the base of the skull. The brain is surrounded by a strongly echogenic skull echo which increases in attenuation with gestational age making visualization of brain anatomy somewhat more difficult in the third trimester. The brain hemisphere closest to the transducer is typically poorly visualized due to reverberation artifacts arising from the near side skull table however most brain anomalies can be adequately evaluated. The plane of section through the maternal abdomen/uterus to obtain standard axial sections of the fetal head depends on the degree of flexion and extension of the fetal head. The plane of section through the maternal abdomen/uterus to obtain standard axial sections of the fetal head depends on the lie of the fetus and the degree of flexion and extension of the fetal head.

Brain 4-1--2

The brain develops at the cranial end of the neural tube. There are three distinct areas of development :
prosencephalon or forebrain
mesencephalon or midbrain, and rhombencephalon or hindbrain. There are several masses of gray matter, known collectively as the basal nuclei (ganglia), located

deep within the white matter of each cerebral hemisphere. Included in these basal nuclei are the caudate nucleus, the amygdaloid nucleus (located at the tip of the caudate nucleus), the lentiform nucleus, and the claustrum (a thin layer of gray matter just deep to the cortex of the insula). The band of white matter located between the basal nuclei and the thalamus is called the internal capsule. Because of their appearance, the caudate nucleus, the internal capsule, and the lentiform nucleus are sometimes referred to as the corpus striatum (striped). The basal nuclei are slightly more echogenic than the surrounding brain matter however considerably less echogenic than choroid plexus or leptomeninges. Several advanced ultrasound textbooks on fetal anatomy label various components of the brain nuclei however you do not have to know the anatomy of the basal nuclei for testing purposes.(Gilani 2003 module

.(4

Cerebrum This large area of the brain initially 2--4--2 develops as a brain structure with a very smooth contour however with increasing fetal age, the cerebral surface becomes increasingly convoluted or irregular (the formation of surface convolutions allows the cerebral cortex to increase greatly in area without the overall size of the brain becoming prohibitively large). The convoluted nature of the cerebrum is most evident on ultrasound evaluation of the brain at the end of pregnancy. The surface of the cerebrum has many rounded ridges called

gyri (singular = gyrus). Separating the gyri are deeper furrows called fissures; the shallower fissures are called sulci (singular = sulcus). The exact organization or pattern of gyri, sulci, and fissures varies only slightly from one brain to another and the location of certain sulci and fissures are constant enough to serve as surface landmarks by which each cerebral hemisphere can be divided into frontal, parietal, temporal, and occipital lobes. Each lobe is located in the same general region as the corresponding skull bones

(Corpus Callosum (CC 3--4--2

The CC is a myelinated cerebral nerve tract (white matter) which connects the cerebral hemispheres (largest fibre tract within the central nervous system). The CC is divided into a genu (anterior region), body (central region), and splenium (posterior region). Development of the CC does not begin until the 8th week and remains incomplete until about the 17th week. Development begins anteriorly and progresses posteriorly therefore partial interruption of callosal development tends to affect the posterior aspect of this large fibre tract. The CC bridges across the midline and passes just above the roof of the lateral ventricles . The longitudinal fissure and falx cerebri extend from the vertex downward to the CC. In the midline, the CC is located between the lowermost end of the longitudinal fissure and the roof of the septi pellucidi. The corpus

callosum is not detected on standard axial trans abdominal views of the fetal head however it may be visualized in midsagittal transabdominal views of the fetal head if the view can be obtained or with endovaginal imaging if the fetal head in fetuses who are in a vertex presentation. For endovaginal imaging, the anterior fontanelle is used as an acoustic window and the transducer is manipulated to .obtain sagittal and coronal views of the brain

Thalami 4--4--2

The thalami (singular = thalamus) are paired oval masses of gray matter that form the lateral walls of the third ventricle. The thalami are located deep within the cerebrum inferior to the corpus callosum and the bodies of the lateral ventricles and posterior to the cavum septi pellucidi (CSP). The thalami serve as a major sonographic landmark for image selection for the BPD and HC measurements. The paired thalami appear as an oval or heart shaped hypoechoic central structure .with the widest diameter being more anterior

Cerebral Peduncles 5--4--2

The cerebral peduncles are two small cylindrical bulges located on the ventral surface of the mesencephalon (midbrain). The cerebral peduncles are composed of nerve tracts that travel to and from the cerebral hemispheres. The cerebral peduncles are sometimes labelled in scans of .(the fetal head. (Gilani 2003

Cerebellum 6 -4 -2

The cerebellum is composed of two lateral cerebellar hemispheres connected in the midline by a structure called the **vermis**. The surface of the cerebellum consists of a thin cortex of gray matter. The cortex dips deeply below the apparent surface of the cerebellum in a manner similar to the fissures and sulci of the cerebrum, although the cerebellar indentations are more parallel, giving the appearance of a series of flattened plates. The cerebellum is a well-defined, easily evaluated structure with ultrasound in the second and third trimester. The cerebellum is best visualized with an appropriate oblique scan of the posterior fossa. The paired cerebellar hemispheres are less echogenic than the .vermis

Brain Stem 4-7--2

The medulla oblongata, the pons, and the mesencephalon together form the brain stem. The pons consists of bands of nerve fibre tracts and several nuclei. Caudally, the medulla is continuous with the spinal cord. The cavity in the medulla forms the lower portion of the fourth ventricle and continues into the spinal cord as the central canal of the cord. The brain stem is moderately echogenic. It may be identified on midsagittal or coronal scans of the fetal .skull and cervical spine

Cerebral Ventricles 8--4--2

The cerebral ventricles consist of paired lateral ventricles, third ventricle, and fourth ventricle. Each ventricle contains a network of special capillaries called **choroidplexus**. The choroid plexus (with the ependymal cells that cover them) is the site of production of cerebrospinal fluid (CSF) which circulates in the cerebral ventricles and the subarachnoid spaces which surround the brain and spinal cord. Within each cerebral hemisphere is **a lateral ventricle**. The fully developed lateral ventricle is divided into several region including the body, anterior or frontal horn, atrium or trigone, posterior or occipital horn, and temporal or inferior horn. The **atrium** of the lateral ventricles is the site of confluence of the bodies, occipital horns, and temporal horns. As viewed in a sagittal plane of **Cerebral Ventricles** the lateral ventricle, the atrium is connected anteriorly to the body, posteriorly to the occipital horn, and inferiorly to the temporal horn. The lateral ventricles are separated from each other medially by a thin vertical partition called the **septum pellucidum**. Each lateral ventricle communicates with the third ventricle by a small opening called the **foramen of Monroe** (interventricular foramen). The **third ventricle** is a narrow chamber in the diencephalon. The right and left masses of the thalamus form most of its lateral walls. The third ventricle opens into the fourth ventricle by means of the **cerebral aqueduct** (aqueduct of Sylvius). The **fourth ventricle** is a

pyramidal cavity located in the rhombencephalon (hindbrain) just ventral or anterior to the cerebellum. There are two openings in the lateral walls of the fourth ventricle called the **foramina of Luschka**. In the roof is a single opening, the **foramen of Magendie**. The ventricles communicate through these three openings with the subarachnoid space which surrounds the brain and spinal cord. The fourth ventricle is continuous with the narrow central canal that extends the length of the spinal cord.(Gilani 2003 module

.(4

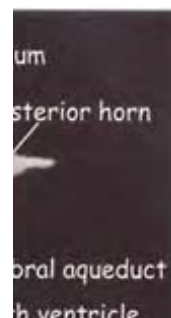

Figure (2.9) Basic anatomical knowledge of ventricular system of

.the brain

The sonographic appearance of the lateral ventricles change with growth and development of the brain. By the end of the first and the beginning of the second trimester, the ultrasound appearance of the cerebrum is dominated by the choroidfilled lateral ventricles. The anterior horns are slit-like and obliquely oriented to the midline. Echoes from the lateral wall of the anterior horns are commonly visualized and can be recognized in the BPD/HC image in the anterior third of the brain. Prior to 16 weeks of gestation, the lateral ventricles are large relative to the surrounding brain and dominate the sonographic appearance of the fetal brain. By 18 to 20 weeks, easily recognizable occipital and temporal horns are visible and the lateral ventricles have achieved their adult components. From this point onward, the lateral ventricles change in shape and proportion as influenced by brain .tissues growing adjacent to their walls

Transverse Atrial Measurement - Various parts of the ventricular system can be measured to define lateral ventricular enlargement

ventriculomegaly). Currently, **transverse measurement**)

of the atrium is the point of reference of choice for the majority of investigators. The atrial measurement should be made at or slightly caudal to the axial plane of the BPD image. The atrium is located in the posterior third of the image about halfway from the midline and the parietal skull echo. Anteriorly, the atrium is continuous with the body of the lateral ventricle . Posteriorly, the atrium is

continuous with the occipital horn, the normal occipital horn lacks choroid plexus. The medial and lateral margins of the atrium appear as sharp, well-defined specular echoes. In normal fetuses, the echogenic choroid plexus fills or nearly fills the transverse atrial diameter. When this relationship is seen, the atrium will always measure in the normal range and a measurement is technically not required although by habit and to satisfy study protocols it is usually made. The calipers should be positioned at the luminal margins, perpendicular to the at the walls of the atrium. Erroneous measurements result from poor plane selection, improper positioning of the calipers .The surrounding brain matter is very hypoechoic. The part of the brain located between the midline and the medial margin of the atrium and occipital horn is the **hippocampus** or hippocampal gyrus. Care should be taken not to mistaken the margin of the hippocampus for the medial wall of the atrium. Several investigators have published normal data for the atrial diameter. The mean diameter and SD vary somewhat between studies however according to the most recent study, the upper cutoff should be 10 mm as previously proposed (Almog '03). This cutoff represents a range of approximately 3 SDs above the pooled mean of all the published studies, corresponding to a confidence interval greater than 99%. The ventricular atrial width does not change significantly with gestational age or fetal gender . Ventriculomegaly is indicated with measurements greater than 10 mm with a

low false positive rate. The sonographic appearance of the **normal third ventricle** is variable and depends on gestational age. It can be seen in the standard BPD/HC image in over 95% of all normal fetuses examined in the second and third trimester of pregnancy. In about 40% of fetuses the third ventricle appears as a single echogenic line between the thalami, as parallel echogenic lines with a central anechoic CSF lumen in 55% of fetuses, and as two divergent lines bordering a V-shaped anechoic CSF lumen in only 5% of fetuses. Not surprisingly, the single line pattern is most common early in the second trimester. The average width (transverse diameter) of the third ventricle is relatively constant in the second trimester at approximately 1 mm; in the third trimester it enlarges and can attain a maximum transverse diameter of 1.9 mm. Pathological dilatation is indicated if the width of the third ventricle is greater than 3.5 mm. The **septum pellucidum** (pl: septi pellucidi) is a thin vertical partition which separates the lateral ventricles medially. It forms concomitantly with the corpus callosum. The **cavum septi pellucidi** is a fluid-filled space between the septi pellucidi. The cavum may or may not communicate with the lateral or third ventricles. It is typically seen as a midline anechoic box-like space in the anterior third of the fetal head. Visualization of the cavum septi pellucidi is important because it excludes complete agenesis of the corpus callosum (it does not exclude the possibility of agenesis of the posterior part of the corpus callosum). The

cavum also serves as a reliable intracranial landmark for the correct plane selection for the BPD/HC. The cavum may not be seen until about 18-20 weeks of gestation.

(Gilani 2003 module 4

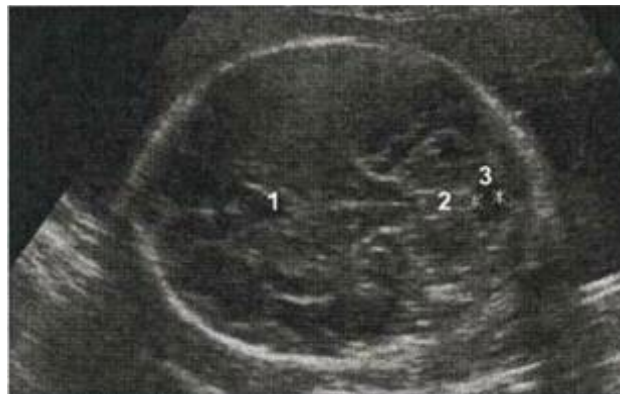

Figure (2.10): ultrasound image of the fetal head to shows 1= CSP, 2 =
(cerebellum, 3 = cisterna magna.(obstetric atlas module 2 , 2003

Skull 4-9--2

The shape and echogenicity of the fetal skull or calvarium may be abnormal and provide clues for the diagnosis of central nervous system and skeletal anomalies, and syndromes. The normal skull produces a high amplitude echo which is very echogenic compared to the brain. Diminished echogenicity of the fetal skull is most commonly seen with osteogenesis imperfecta and hypophosphatasia respectively. Abnormal skull mineralization should be suspected if the falx cerebri appears to be

as or more echogenic than the skull. Poor or absent calvarial ossification is also associated with “superb” imaging of brain anatomy due to lower sound attenuation and fewer bone-related artifacts which normally hamper good visualization of the brain nearest the transducer. The sonographer should be alerted to a mineralization abnormality if the brain is seen with unusual clarity. Other findings associated with poor mineralization of the skull include increased compressibility of the fetal head and increased acoustic transmission. Normal skull **sutures** can be seen as short breaks in the skull echo. The coronal suture is routinely seen in the BPD image between the temporal and frontal bones. The general shape of the normal fetal head in the axial plane in the 2nd/3rd trimester should appear smooth and oval (BPD/HC image). In the 1st trimester (10-14 weeks LMP), the head appears more spherical than oval since brain development and growth has not yet influenced the shape of the head. Abnormalities in the shape of the fetal head is associated with different conditions and can be very helpful in searching for anomalies, including syndromes. The following list describes the most common abnormalities in fetal head shape described in the :sonographic literature

Dolicocephaly - describes a fetal head with a relatively narrow biparietal diameter (BPD) and a long occipitofrontal

diameter (OFD). Most commonly associated with .oligohydramnios

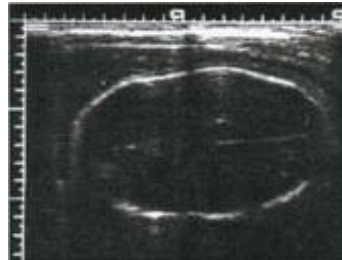

Figure (2 .11) Dolicocephaly Axial view of the fetal head at 22 weeks LMP shows a narrow head with an elongated occipitofrontal diameter.(Atlas Obstetrical
(Ultrasound Module 3

Brachycephaly - describes a fetal head which is rounder than usual. Most commonly seen with multiple pregnancy (due to intrauterine crowding), and can be a late feature .(associated with trisomy 21 (Down's syndrome

Lemon Sign - describes a fetal head with bilateral denting of the frontal bones. Most commonly associated .with spina bifida

Cloverleaf-shaped Skull - describes a trilobed appearance of the head that is believed to occur as a result of premature closure of the coronal, lambdoidal, and squamosal sutures. It is most commonly associated with thanatophoric dysplasia and homozygous achondroplasia, .both lethal skeletal limb reduction syndromes

Strawberry-Shaped Skull describes a fetal head with a normal BPD and a narrow frontal diameter. Similar to the lemon sign except no obvious concavity to the frontal .bones . Most commonly associated with trisomy 18

Spalding's sign describes a flattened and misshapen fetal head with overlapping of cranial bones. Associated . with fetal demise

Fetal Scalp- The fetal scalp is normally very thin and barely noticed (scalp thickness is normally 3 mm). In the late third trimester, fetal hair may be seen as short, .stringy echoes arising from the scalp

Scalp edema is a manifestation of fetal hydrops and is seen as scalp thickening (scalp thickness 3 mm). (Gilani .(2003 module 4

SONOGRAPHIC ESTIMATION OF GESTATIONAL AGE 5--2

Clinical Dating 2.5.1

The average duration of pregnancy is 280 days from the first day of the last menstrual period or 266 days from ovulation, based on a 28-day cycle. The estimated date of delivery (EDD) can be calculated by subtracting 3 months from the first day of the LMP and adding 7 days (this technique is referred to as Naegele's rule). The length of pregnancy increases about 1 day for each day the menstrual cycle is more than 28 days. First and second trimester ultrasound has proven helpful in accurately dating pregnancies. As previously indicated, CRL measurements are most accurate to about 12 weeks LMP. **Inaccurate pregnancy dating** can result from a first visit late in pregnancy, erroneous LMP date, oligoovulation, ultrasound dating in the 3rd trimester, recent pregnancy, recent abortion, oral contraceptive use

without resumption of menses, acute illness, intrauterine growth restriction, and drug use. By convention, the duration of pregnancy is based on menstrual dates, with the first day of the last menstrual period (LMP) being the point of reference. In women with regular 28 day cycles, ovulation and conception occurs approximately 14 days after the LMP. Embryonic or fetal age begins at conception (conceptual age) and is the term of reference for describing embryologic development by embryologists. A quick method of determining the Expected Date of Confinement (EDC) or Due Date is the use of Nägele's Rule: to the first day of the LMP, add 7 days, subtract 3 months, and add 1 year, or alternately, add 9 months and 7 days. Example: LMP is May 5, 1998; add 7 days (May 12, 1998); subtract 3 months (May 12 - 3 months = February 12, 1998); add 1 year (February 12, 1998 + 1 year = February 12, 1999); the EDC is February 12, 1999. Nagale's rule assumes a 28-day cycle, ovulation on day 14, and an average duration of pregnancy of 278 to 284 days. The continued use of menstrual dates and Nägele's rule for pregnancy dating has been questioned since early sonographic dating is clearly more reliable. There is now ample evidence that routine ultrasound dating in the first half of pregnancy in units with an ultrasound service of adequate standard results in more precise gestational age assessment than LMP alone or in combination with ultrasound. It is suggested that clinicians and sonographers should ignore even a certain last menstrual

period when determining the EDC and the related pregnancy landmarks. It is also suggested the only remaining role for the LMP should be to calculate the appropriate date when the dating scan is to be booked. A study by Nguyen et al comparing the effectiveness of BPD measurement in the 2nd trimester versus LMP supports the reliability ultrasound dating. "The conclusion of this study is that, when using a gestational calculator, one should add 282 instead of 280 days to the first day of the LMP in order to optimize the precision of the estimated term. However, it will always be unreliable for the individual patient who has not had an ultrasound scan, because the difference between term estimated from LMP and from ultrasound may be much larger than 2 days - as amply pointed out in the literature and in this study. If both LMP and ultrasound in the second trimester are available, BPD calculated gestational age should be used exclusively.

..(Gilani 2003 module3

Fetal Biometry 5-2--2

Fetal biometry is the sonographic measurement of fetal structures. There are three primary objectives for
:measuring fetal parts

To assign fetal (gestational) age. For example, if the .1
(femur length (FL
measurement is 50 mm, the mean age of the fetus is estimated to be 26.5 weeks with a range of about ± 2 weeks (2 SD); this means the fetus could be as young as .24.5 weeks or as old as 28.5 weeks

To diagnose fetal growth disorders by assessing if .2 measured fetal parts are appropriate size for gestational age or by estimating fetal weight. For example, if gestational age is established to be 23 weeks by reliable clinical or ultrasound dating, the FL should be between 35 .(mm and 47 mm (3rd and 97th percentile respectively To determine the appropriateness of the dimension of .3 fetal structures against each other (ratio) and/or against .gestational age

Confirming gestational age in the second Trimester 2-5-3

Confirmation of gestational age at the second Trimester examination is based either on a reliable menstrual history or/and on measurements obtained from an earlier and reliable ultrasound examination. In both instances the gestational age of the second examination is known. Four outcomes are possible:

1. The measurements of the BPD or HC and the FL fall within the normal range for the gestational age when plotted on appropriate charts. This confirms the previously assigned EDD based either on the LMP or the early scan.
2. Measurements of the BPD or HC and the FL fall outside the normal range for menstrual age. In this case you should consider carefully the reliability of the menstrual history/early scan: - If there is uncertainty concerning the reliability of the previously assigned EDD then, in the majority of cases, it is considered acceptable practice to reassign the EDD based on the second

trimester measurements. Estimate the gestational age from the BPD or HC using dating tables and then replot the FL for the estimated gestation. If the FL is within normal range you should then assign the new EDD from the BPD-derived or HC-derived gestational age. Your AC measurement should further confirm the ultrasound date you have assigned. If there is no reason to doubt either the optimal menstrual history (for example if the date of conception is indisputable) or the measurements from the earlier scan then the previously assigned EDD should be kept. The second trimester measurements in this case therefore indicate poor fetal growth. As early onset growth restriction is associated with chromosomal anomalies and/or poor outcome, karyotyping should be considered and the pregnancy should be monitored carefully. 3. The BPD or HC falls within normal range for the known gestational age but the FL is below the normal range. In this case you should repeat the measurements of the BPD or HC and FL and measure the TCD and AC. If all the measurements but that of the FL agree with the known gestational age, you should suspect a skeletal dysplasia or .trisomy 21

The FL falls within the normal range for known .4 gestational age but the BPD is below the normal range. Again, you should repeat the measurements of the BPD or HC and FL and also measure the TCD and AC. If the HC and BPD are both below the normal range you should look for spina bifida or microcephaly, remembering that the

majority of fetuses with spina bifida will have an abnormally shaped or absent cerebellum . If all the measurements are appropriate, with the exception of the BPD, look at the shape of the head – the most usual cause for a small BPD is dolichocephaly (narrow head) due to a breech or transverse presentation. Such circumstances emphasize why it is more appropriate to use the HC instead of the BPD with the FL to confirm the known gestational age. Some authors recommend the use of the cephalic index

$$\text{Cephalic index} = \text{BPD}/\text{OFD} = 80 \pm 5$$

An index of less than 75 is seen in cases of dolichocephaly and makes the BPD measurement unreliable for estimating gestational age. An index of more than 85 is seen in brachycephalic heads (wide and short) and also makes use of the BPD for estimating gestational age unreliable. The cephalic index is constant throughout pregnancy. (Chudleigh 2004)

Assigning gestational age for the first time in the 2-5-4 second trimester

The gestational age is calculated for both the BPD or HC and FL using dating tables. Two outcomes are possible

The gestational ages calculated from both the BPD or HC and FL dating tables agree to within 7 days. The

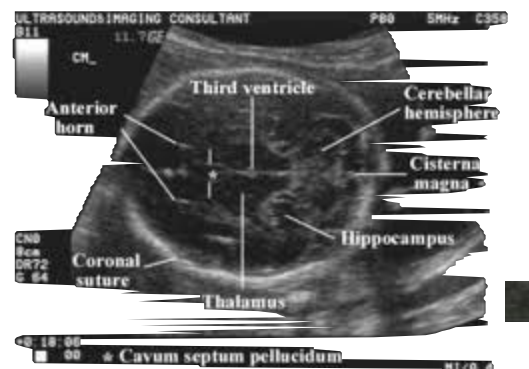
ultrasound EDD is therefore derived from the gestational age (or the average if they agree to within 7 days of each other) as calculated from the dating tables.

The gestational ages calculated from the BPD or HC and the FL dating tables differ by more than 7 days. In this case you should repeat the measurements of the BPD or HC and FL and measure the TCD and AC. If a dating table is available for the TCD then this should be used. If a dating table is unavailable then the gestational age should be calculated from the relevant growth chart: the gestational age equivalents of the TCD and AC agree with the BPD and HC then the pregnancy should be dated from the gestational age (or the average) as calculated from the BPD and HC dating tables. Having now established the gestational age, further management will depend on the severity of the FL shortening. As skeletal dysplasia and trisomy 21 are associated with FL outside the normal range, both these conditions should be considered. Less severe cases should be followed up in 2-4 weeks to confirm normal growth velocity of the FL. - If the gestational age equivalents of the TCD and AC agree with the FL then the pregnancy should be dated from the gestational age (or the average) as calculated from the FL and TCD dating tables. If all the gestational age equivalents agree, with the exception of the BPD, look at the shape of the head - the most usual cause for a small BPD is dolichocephaly (narrow head) due to a breech or transverse presentation. In such circumstances it is

appropriate to use the HC instead of the BPD together with the FL to assign the gestational age. If the BPD and HC are both below the normal range you should look for spina bifida or microcephaly, remembering that the majority of fetuses with spina bifida will have an abnormally shaped . (or absent cerebellum .(Chudleigh 2004

Biparietal Diameter 5-5--2

The biparietal diameter (BPD) is a transverse or axial image of the fetal head taken at the widest portion of the skull (corresponding to the parietal eminences); this level is characterized by the mid-to-upper thalami which serve as the major sonographic landmark for image selection . selection



Figures (2 .11) Biparital diameter 1-thalmi 2-CSP 3-3rd ventricle 4- atrium of lateral ventricle (atlas module 4

The optimal BPD image should have the following :landmarks

Thalami - appears as a hypoechoic heart or diamond-shaped area in the central region of the brain. The linear,

midline echo between the thalami represents the third ventricle (not the falx cerebri which appears as a short midline echo anteriorly and posteriorly in the BPD image). With good resolution, in older fetuses (>20 weeks), the **third ventricle** may appear as an anechoic slit-like space instead of a single, midline echo. **Falx Cerebri** - appears as a short, linear, high amplitude midline echo anteriorly and posteriorly. The falx cerebri and 3rd ventricle are very angle-dependent specular reflectors (the highest amplitude echo is seen from these structures when the incident beam is perpendicular to the reflector). **Cavum Septi Pellucidi (CSP)** - the septi pellucidi are the thin membranous septi between the bodies of the right and left lateral ventricles; the cavum is a normal developmental fluid-filled space between the two septi; the CSP appears as an anechoic, "box-like", midline structure anteriorly between the falx cerebri and the thalami; depending on the plane of section, a short linear echo may appear centrally in the posterior portion of the cavum (this linear echo appears to correspond to a structure known as the fornix). **Atrium** - (aka trigone) is where the body, occipital, and temporal horns of the lateral ventricle converge. The atria are located in the posterior one-third of the brain with the medial boundary about 1 cm from the midline; the normal atrium is filled with choroid plexus which appears as moderately echogenic tissue compared to the normal echo poor adjacent brain. Other less important structures that can be seen in the BPD image include the

anterior horns of the lateral ventricle, insula/lateral (Sylvian) fissure echo, and the ambians cistern (one of many subarachnoid spaces around the brain. The anterior horns appear as two short parallel echoes anterior and lateral to the CSP; the insula/lateral fissure appears as a high amplitude echo about 1 cm from the temporal region of the inner skull; and the ambians cistern appears as an echogenic triangular region posterior to the thalami. For ideal demonstration of intracranial anatomy and image selection, the fetal head should be in a direct occiput transverseposition. Obtaining appropriate head measurements may be difficult when the fetus is in a direct occiput anterior (face down) or posterior (face up) position. The standardized method for measurement of the BPD is outer-to-inner (O-to-I) placement of calipers. One caliper is placed on the outer edge of the near side parietal skull echo and the second caliper is placed on the inner edge of the far side parietal skull echo. The caliper axis should be perpendicular to the midline axis of the head. The scalp and hair may be seen as low amplitude soft tissue echoescontouring skull and should not be included in the BPD measurement. Medium gain setting should be used to optimize display of the skull and brain anatomy. High gain settings adversely affect the machine's spacial resolution capability whereas low gain settings provide good skull detail but poor visualization of intracranial anatomy. In general, the gain setting should be high enough to allow adequate visualization of major

intracranial landmarks (the parietal bone should measure approximately 3 mm in thickness). Several studies have shown that all major types of transducers are equally suitable for fetal head measurements. Units for BPD (also HC, AC, and FL) are centimeters (cm) or millimeters (mm). Electronic calipers may be set by the manufacturer to display either cm or mm. You should be able to convert these units from one to the other since reference charts for gestational age may be presented in either units. To convert cm to mm, multiply the value by 10 (e.g. 4.6 cm is equal to 46 mm; to convert mm to cm, divide the value by 10 (e.g. 84 mm is equal to 8.4 cm). It is generally believed there is only minimal variation in the BPD (and HC) related to factors such as race, geography, and socioeconomic status although some investigators have designed BPD charts for different populations. Inaccuracy in the BPD measurement may be related to poor image selection, caliper placement errors, abnormal head shape, and brain abnormalities affecting head size. The fetal head should not be used to estimate fetal age if there is .(evidence of cranial pathology. (Gilani 2003

The BPD is the maximum diameter of a transverse section of the fetal skull at the level of the parietal eminences. The BPD, occipitofrontal diameter (OFD) and head circumference can be measured from one of the following :two sections

Lateral ventricles view: the correct section is demonstrated in Fig 2.13, and should include the following

features

a rugby-football-shaped skull, rounded at the back ((occiput) and more pointed at the front (synciput)
a long midline equidistant from the proximal and distal skull echoes

The cavum septum pellucidum bisecting the midline one-third of the distance from the synciput to the occiput

The two anterior horns of the lateral ventricles, symmetrically placed about the midline

All or part of the posterior horns of the lateral ventricles symmetrically placed about the midline. In earlier gestations (15-20 weeks), the optimal view of the posterior horn is usually obtained in this section (see below).

At later gestations (20-24 weeks), the optimal section for visualizing the posterior horn is slightly lower than the BPD section. (chudleigh 2004)

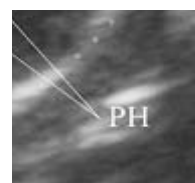


Figure (2.13) Transverse section of the fetal head demonstrating the landmarks required to measure the BPD using the lateral ventricles view. Note the rugby football shape, the centrally placed midline, the presence and position of the cavum septum pellucidum (CSP), and the appearance and position of the anterior horns (AH) of the lateral ventricles. Note the choroid plexus (ChP) within the distal posterior horn (PH) of the lateral ventricle and reverberation .(causing poor visualization of the proximal posterior horn. (chudleigh 2004

Thalami view: the correct section is demonstrated in ●

:Fig 2.14 and should include the following features

a rugby-football-shaped skull, rounded at the back ●

((occiput) and more pointed at the front (synciput

a short midline equidistant from the proximal and distal ●

skull echoes

The cavum septum pellucidum bisecting the midline ●

one-third of the distance from the synciput to the occiput

The thalami ●

.The basal cisterns ●

There is no consensus as to which section is preferable. We recommend using the lateral ventricles view because this enables the anterior and posterior horns of the lateral ventricles to be examined and the head measurements to be taken from the same section. However, the thalami view is the section of choice in the American literature and in many

departments in the United Kingdom. The BPD and HC measurements obtained from both sections are .comparable

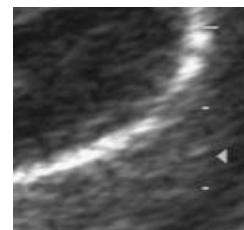


Figure (2 .14) Transverse section of the fetal head demonstrating the landmarks required to measure the BPD using the thalami view. CP, cerebral peduncles; CSP, (Cavum septum pellucidum ; TH, thalami.(chudleigh2004

Occipitofrontal Diameter 6- 2-5

The occipitofrontal diameter (OFD) may be used as an alternative measurement if the BPD is unsatisfactory because of low fetal head position. Several data for OFD measurements against gestational age have been published. The main use of the OFD is to determine head circumference from the ellipse formula when there is no tracing calipers and determination of the cephalic index

(CI). Synonyms for occipitofrontal include frontooccipital .and anteroposterior

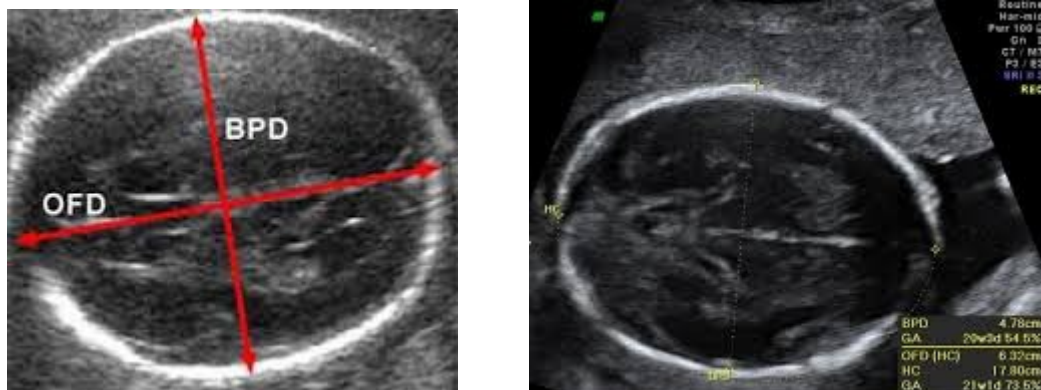


Figure (2 .15) ultrasound image for OFD measurement

(Head Circumference (HC 5-7--2

HC or head perimeter is the length of the outer perimeter of the skull made from the BPD image. The HC can be measured with electronic tracing elliptical calipers that allows the HC to be calculated electronically or it may be computed by obtaining the appropriate transverse and occipitofrontal diameters and by using the following :formula

$$HC (cm) = BPDO\text{-to-O} (cm) + OFDO\text{-to-O} (cm) \times 1.57$$

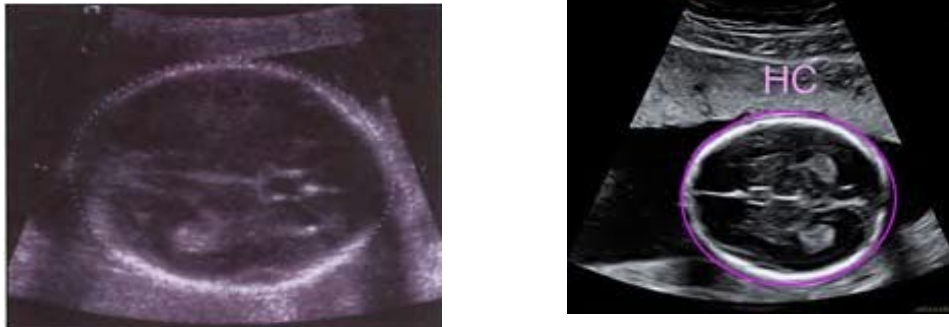

Figure (2.16)Ultrasound image demonstrating the HC measurement in a . second trimester

where, BPDo-to-o is the outer-to-outer biparietal diameter
 OFDo-to-o is the outer-to-outer occipitofrontal diameter
 1.57 is a mathematical constant (one-half of π) The **outer-to-outer BPD** is obtained by placing the near side caliper at the same position as for a regular BPD measurement, and the far side caliper is placed at the outer edge of the far side skull echo. The **outer-to-outer OFD** is obtained by placing one caliper at the outer edge of the anterior skull echo in the midline and the second caliper is placed at the outer edge of the posterior skull echo, also in the midline. Late third trimester fetuses may have head sizes that are wider than the field-of view of most sector and linear array transducers to obtain accurate HC measurements (anterior and posterior margins of the skull are cut off). Most 3.5 MHz convex array transducers will have adequate display width to measure the HC in these older fetuses. HC measurements are independent of the shape of the fetal skull and are therefore not influenced by

head shape variations such as dolicocephaly and brachycephaly. The following diagram demonstrates three fetuses of the same gestational age (33 weeks) but with different head shapes. The BPD underestimates gestational age with dolicocephaly and overestimates gestational age with brachycephaly. In contrast, the HC is the same for all three fetuses and correctly estimates .gestational age

Cephalic Index 5-8--2

Synonym - TD/OFD ratio, where TD stands for transverse head diameter (outer to- outer BPD) and outer-to-outer

OFD stands for occipitofrontal

Diameter Units - unit less ; may be expressed as a percent by multiplying the ratio by 100 What is the cephalic index?

Cephalic index (CI) is the ratio between the outer-to outer .BPD and the outer-to-outer OFD

Cephalic index has a normal range which is effectively independent of gestational age. The normal range for CI is 0.70 to 0.86 or 70 to 86 (2SD). If the measured CI falls within the normal range, this indicates a normal ratio between the transverse and occipitofrontal diameters. When the CI falls within the normal range, the BPD remains an acceptable parameter to estimate fetal age. If the CI falls outside the normal range, the BPD should not be used to estimate gestational age. A CI which falls below 0.70 or 70 indicates a fetal head with an abnormally narrow BPD relative to the OFD and is associated with

dolicocephaly, which defines a head shape with a narrow BPD in proportion to the occipitofrontal diameter (the head is oblong or sausageshaped. With dolicocephaly, the BPD underestimates gestational age. The most common cause of dolicocephaly is oligohydramnios. Other causes include multiple pregnancy (twins, triplets, etc...), breech position, and primigravida. A CI value which falls above 0.86 or 86 indicates a fetal head which is rounder than normal and is known as **brachycephaly** (a CI of 86 indicates the BPD is 88% the OFD value; if the CI was 1 or 100%, the BPD and OFD would be equal). With brachycephaly, the BPD overestimates gestational age. Brachycephaly is much less common than dolicocephaly. It is reported to be most commonly associated with multiple pregnancy. Another less common cause of brachycephaly is trisomy, most
.(often trisomy 21. **(Gilani 2003**

Corrected-BPD 2-5-9

Corrected-BPD is a formula-adjusted BPD value based on a formula that incorporates the BPD and OFD values and accounts for variations in head shape. The corrected-BPD formula is based on the standard shape of a fetal head which has an OFD to BPD ratio of 1.265 (OFD is 26.5% greater than the
.(BPD (this ratio is based on a mean CI value of 0.78 or 78

$$\text{Corrected-BPD} = \sqrt{\frac{\text{BPD} \times \text{OFD}}{1.265}}$$


For the corrected-BPD measurement, the BPD is measured in the standard fashion (O-to-I), and the OFD is measured midskull-to-midskull (not O-to-O). The corrected- BPD is an alternative technique to HC measurements. The same tables used to determine gestational age from the standard BPD are used to estimate gestational age from the corrected-BPD. HC measurements appear to be more popular than corrected-BPD although both approaches .(have equal merits.(Gilani module two 2003

(MEASURING THE FEMUR LENGTH (FL 2-5-10

Measurement is as accurate as the BPD in the prediction of gestational age. It is useful in confirming the gestational age estimated from BPD or HC measurements and can often be obtained when fetal position prevents measurement of the BPD or HC. As examination of intracranial anatomy is an important part of all ultrasound examinations, measurement of femur length should not replace that of the BPD or HC as the sole predictor of gestational age. The femur can be measured from 12 weeks to term. Measuring the femur is ideally undertaken after the AC has been measured. Slide the probe caudally from the AC section until the iliac bones are visualized. At this point, a cross-section of one or both femurs is usually

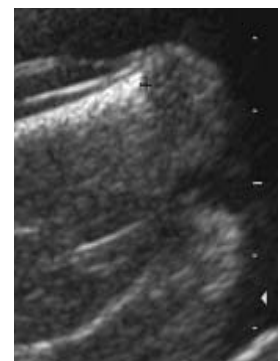seen. The upper femur should be selected for measurement. The lower femur is frequently difficult to image clearly because of acoustic shadowing from fetal structures anterior to it. Keeping the echo from the anterior femur in view, rotate the probe slowly until the full length of the femur is obtained. You might need to make a small sliding movement after each rotational movement to bring the probe back onto the femur. To ensure that you have the full length of the femur and that your section is not oblique, soft tissue should be visible beyond both ends of the femur and the bone should not appear to merge with the skin of the thigh at any point.

..(chudleigh 2004



Figure

(2.17) Measurement of the fetal
femur



Note that soft tissue is visible beyond both ends of the bone. The femur length is the distance between the caliper marker . The end-points of the femur are often difficult to define when the femur is imaged lying horizontally but are much easier to define when the bone lies at a slight angle (5-15 to the horizontal). The angle of the bone relative to the horizontal can be manipulated by dipping one end of the

probe gently into the maternal abdomen. The measurement of the femur is made from the center of the 'U' shape at each end of the bone. This represents the length of the metaphysis. It is good practice to obtain measurements from three separate images of the same femur. These should be within 1 mm of each other. As with the BPD, a growth chart should be used to determine if the FL measurement is within the normal range for the gestational age as calculated from a reliable menstrual history and/or a first trimester dating scan. In practical terms, you should measure the FL and then you should plot it on a growth chart according to the gestational age. If the measurement lies outside the normal range for the menstrual age then you must consider whether it is valid to ignore the menstrual dates and reassign an EDD based on the ultrasound measurements or whether the menstrual dates should be retained. In cases where the gestational age is unknown or the menstrual history is unreliable, estimation of gestational age should be made from a dating chart, in which the FL (independent variable) is plotted on the x-axis and the gestational age (dependent variable) is plotted on the y-axis, or from tables derived in the same manner. In practical terms, this means that, having measured the FL, you should estimate the gestational age by use of the tables. The measurement can then be plotted on the growth chart according to the gestational age derived from the dating tables. We recommend that dating charts are used in look-

up table format and that all measurements are represented graphically on growth charts. Most problems arising with measuring the FL are due to a combination of fetal movements and slow use of the freeze button. The cine loop might be useful in such situations. If the end-points of the femur cannot be adequately visualized, unfreeze the image and seek another, better image. It is very easy to under- or over estimate the FL by 3-5 mm if optimal image is measured. One or both end-points are difficult to define Dip one end of the probe gently in to the maternal abdomen, as described above. The upper femur appears straight but the lower femur appears bowed The slight bowing seen in the lower limb is a normal artifact of the imaging process. Unilateral femoral abnormalities are very rare but should always be considered as a possible, if unlikely, explanation for significant dissimilarity in the appearance of the two femurs. An experienced second opinion should be sought if necessary. Gestational age equivalents of the BPD or HC and femur disagree. The estimation of gestational age obtained from measurements of femur length should agree with that obtained from the measurement of the BPD, HC and/or the TCD. If the femur length is small (below the 5th centile) compared to the BPD or HC (on the 50th centile) and TCD then all the long bones and the plantar view of the feet should be carefully measured to exclude skeletal dysplasia. A short femur is also a minor marker for

chromosomal abnormalities, including trisom21.
.(chudleigh 2004

:previous studies 2.6

In a prospective, cross-sectional study ((Partick Royston professor ,etal1993-1997)) were obtain the data from 6557 pregnant women . criteria for exclusion from the study were as follows uncertain date of LMP,multiple pregnancy endpregnancies involving congenital malformation .Examination was carried out by many operators using 3.5MHz transducer. the OFD was measured at the level where the continuous midline echo is broken by cavum septum pellucidum in the anterior third .OFD was measured from outer to outer .In case of .OFD linear regression formula for mean and SD

$$\text{.OFD mean: OFD} = -39.08 + 5.45W - 0.001004W$$

$$\text{. SD: SD} = 1.266 + 0.1216W$$

Royston et al found minimal difference in cartels, with the exception of chitty 's OFD charts at the end of pregnancy ,OFD cartels were highrin chitty 's charts after .25-27weeks of pregnancy

In policy implements a standard obstetric chart to ensure uniform reporting of obstetric measurement across Australia and New Zealand. These charts arebased on Australian population .The data compiled by S Campbell Wester way (SCW) parameters. The quadratic regression formula used to describe the relation between BPD, FL, OFD and gestation age . $BPD = 0.371(GA)^2 + 4.69(GA) - (31.516$ ($r^2 = 0.969$

$$(OFD = 0.0665 (GA)^2 + 6.888(GA) - 49.08 (r^2 = 0.963$$

$$FL = 0.0004 (GA)^2 + 0.0032(GA)^2 + 3.1263(GA) - 29.452. (r^2 = 0.974) ((SCW _ 2007$$

In the paper of B.Priestly Shan and M.Madheswaran (2010) presents the revised estimates of various ultrasonographic markers used in practice for estimation of gestational age among singleton Indian population. In this paper fetal head measurements include BPD, which measured at the level of Thalami and cavum septi pellusidi. Measurement is to be taken from outer to inner. BPD can be considered as a most reliable from 12th to 26th week.

Fusun Varol, Ahmet Sattik, et al (2001) were found the relationship between fetal age and size, collected data from 1411 fetuses. Cross sectional measurement of each case were used for assessing the gestational age.

: Descriptive statistic of study parameter as follow

Mean ± SD	Variable
212 7.13 ±	(BPD (cm
1.91 5.8 ±	(FL (cm

Regression equations of gestational age prediction from (fetal ultrasonic measurements (13-40 weeks

R ²	Regression equation	Fetal measurement cm
0.872	GA = 2412 + 0.131BPD	BPD

$$0.927 \quad GA=11.769+1.275FL+449FL^2=0 \quad FL \\ .269FL^3$$

In a preliminary protective study to compare the fetal biometric measurement with standard growth charts for u/s ((Giorgia Buscichio ,vicenzomilite et al. 2008)). This study involving 1000 pregnant women with un complicated singleton pregnancy between 14and 42 weeks of gestation. For each measurement, regression models were fitted to estimate the mean and SD. One thousand fetuses pregnant women, between 22th and 23th weeks ,between 32th 33th weeks and at 38 week, there were significant differences , for each gestation measured OFD were longer than all parameters of existing reference .from last 30 years

Adolfo Wen Jaw Liao ,et al (2012) were established longitudinal reference ranges for fetal ultra sound biometry measurements in twin pregnancies . The data obtained from 807 un complicated twin pregnancies . The regression analysis demonstrated significant correlation for BPD , FL , OFD , with gestational age as : Long of .(BPD(r=0.98),long of OFD (r=0.98),long of FL(r= 0.99

Chapter Three

Materials and Method .3

-.Materials 3-1

:Subject 3-1-1

Fifty Sudanese pregnant women were enrolled in the study

including criteria 3.1.2

women in their second and third trimester of singleton gestation with known first day of LMP . Fetal head and .femur should be normal

-.exclusion criteria 3.1.3

- Fetus with abnormal head and femur •
- Woman in her first trimester and she was ignored the •
.first day of LMP

-.Methods .3.2

-.Machine used 3.2.1

Used mobile ultrasound machine (mindaryCD.8), with 3.5 MHz curve linear transducer and hard copy printer for . documentation

-.Technique used 3.2.2

The women were scanned while lying comfortably on her back (supine). Applied coupling agent liberally to the lower abdomen then put the transducer transversely and longitudinally to produced the best images for accurate .measurement of the fetal head and femur

-.3.2.3Measurement

BPD : taken from transverse axial image of fetal 3.2.3.1 head at the widest portion of the skull, which characterized by show of the thalami as hypoechoic heart or diamond shape, third ventricle as anechoic single midline echo, flax cerebri as hyper echoic short linear midline echo anterior and posterior , and cavum speti pellucidi as an echoic box like midline structure anterior between falx cerebri and thalami BPD was measured from outer border of the near side of the parietal bone to the inner border of the far side of the parietal bone, caliper .axis per pendicular to the midline of the head

FL: was measured the upper femur after soft tissue 3.2.3.3 seen beyond both ends of the femur bone – measured from one end to another

OFD: was measured in the same image for BPD but 3.2.3.2 it measured from outer border of the frontal bone to the .outer border of the occipital bone

:Data analysis 3.2.4

Data was analyzed by using scatter plots, linear regression and by finding correlation between expected GA and the age by BPD, FL and OFD. The significance by using paired .t test was be evaluated

Chapter Four

:Results 4.1

A total of 50 gravid women between the age 17-42 years old mean $28 \pm SD 6.7$.with singleton pregnancy were scanned from September to December 2013 by using mobile U/ S machine (mindaryDC-8) and 3.5 MHz curved transducer and hard copy print for documentation. This

chapter presented the results of analyzing the hole data
:were as follow

Table (4.1): showing mean and standard deviation of total age of pregnant women, total expected GA, GA by FL, GA by BPD, and GA by OFD, with measured FL, BPD, OFD .for each week in cm

OFD- cm	BPD- cm	FL- cm	GA -OFD	GA -BPD	GA -FL	GA- LMP	Age	
7.9	6.4	4.8	25.8	26.8	26.8	26.2	28.0	Mean
2.4	2.1	1.9	7.1	7.6	7.5	7.7	6.7	SD

Figure(4.1): is scatter plot used to show the relation between the expected GA calculated from LMP in the **X** axis and measured OFD by (cm) in **Y** axis with linear . regression

Figure (4.2): Is scatter plot used to show the relation between the expected GA calculated from LMP in **X** axis . and GA by OFD in **Y** axis with linear regression

Table (4.2): shows the correlations between expected GA, .and GA by FL ,GA by BPD and GA by OFD

Correlations					
GA_OF D	GA_BP D	GA_FL	GALMP		
**952.	**991.	**990.	1	Pearson Correlati on	GALMP
000.	000.	000.		Sig. (2- (tailed	
**958.	**992.	1	**990.	Pearson Correlati on	GA_FL
000.	000.		000.	Sig. (2- (tailed	
**967.	1	**992.	**991.	Pearson Correlati on	GA_BP D
000.		000.	000.	Sig. (2- (tailed	
1	**967.	**958.	**952.	Pearson Correlati	GA_OF D

				on	
	000.	000.	000.	Sig. (2- (tailed	
Correlation is significant at the 0.01 level (2- .** .(tailed					

Figure (4.3): Is scatter plot used to show the relation between the expected GA calculated from LMP in **X** axis .and measured BPD by cm in **Y** axis with linear regression

Figure (4.4): Is scatter plot used to show the relation between the expected GA calculated from LMP in **X** axis .and GA by BPD in **Y** axis with linear regression

Figure (4.5): is scatter plot used to show the relation between the expected GA calculated from LMP in **X** axis . and GA by FL in **Y** axis with linear regression

Figure (4.6): Is scatter plot used to show the relation between the expected GA calculated from LMP in the X axis and measured FL by cm in Y axis with linear .regression

Chapter Five

:Discussion 5-1

This study had been conducted in Haj Alsafi educational hospital, to estimate gestation age by OFD, for 50 gravid women in second and third trimester at age between 17-42 years old, checking for antenatal routine ultra sound examination.

This study found mean \pm SD of maternal age in which equal 28 ± 6.7 , which has no effect in assess the gestation age by OFD; the expected GA of fetuses were between (13-39.4) weeks had mean \pm SD (26.2 ± 7.7); also GA by FL had mean \pm SD = (28.8 ± 7.7) and mean \pm SD of FL (cm) equal (4.8 ± 1.9), also BPD GA equal (26.8 ± 7.6) and mean \pm SD of BPD (Cm) equal (6.4 ± 2.1), and GA by OFD had mean \pm SD equal (25.8 ± 7.1) all means \pm SD see (table (4.1).

This study found a linear relation between expected GA and OFD in centimeter in which the OFD increased by factor of 0.305 for each week of expected GA.

There was also correlation seen when using paired sample correlating method between expected GA and OFD in centimeter in which $R^2 = 0.932$ see figure (4.1) ; also found correlation between expected GA and gestational age which calculated from OFD in which OFD increased by factor of 0.88 for each week of expected gestational age see linear equation figure (4.2). That means the OFD was reliable parameter for assessing gestational age.

There was also correlation when using paired sample correlation method between expected GA and GA by OFD in which $r = 0.952$ see table (4.3), additional, the paired t-test show significant correlation between expected GA and OFD GA at 0.01 level (2-tailed) that means strong .relation between OFD and expected GA

This study also found correlation between the GA calculated from OFD and gestation calculated from BPD in which $r = 0.967$, and correlation between gestation age calculated from OFD and gestation age from FL in which $r (= 0.958$ see table (4.3

This study found that the OFD as method for assessing GA in relation to other common parameters (BPD , FL) was an accurate method it gave the same result according to LMP. This study agree to result of (Scamp bell Wester Way" SCW" 2007) from Australian population, was obtained the relation between BPD, OFD, FL and gestation age by using :quadratic regression formula as follow

$$.(BPD = 0.371 (GA)^2 + 4.69 (GA) - 31.546 (r^2 = 0.96$$

$$(OFD = 0.0665(GA)^2 + 6.888(GA) - 4.908 (r^2 = 0.963$$

$$FL = 0.0004 (GA)^2 + 0.0032 (GA)^2 + 3.12631 (GA) - 29.452 ((r^2 = 0.974$$

We observed that OFD to GA reliable and accurate till (25-30) week of GA figure (4-2). This result was match result of Royston et al 1997, were found bigger different in OFD .chart after 25-27 week of pregnancy

This study found minimal different from the study of Fusun warol- Ahmet Sattic, et al 2010 were used cross sectional measurement for assessing the GA and descriptive statistic of the study parameters, were found mean \pm SD for BPD (cm) equal 7.1 ± 2.12 and for FL (cm) equal 5.8 ± 1.91 . also regression equation of gestation age prediction from fetal ultrasonic measurements (13-40 weeks) as GA from BPD $R^2 = 0.872$ and GA from FL $R^2 = 0.927$, this .different due to large sample

:Conclusion 5.2

Estimation of gestational age is very important to •
obtain accurate fetal age and evaluate the fetal growth. This study found significant correlation between GA and GA calculated from OFD at the 0.01 .level ((2tailed)) in which $r=0.952$

The study also found linear regression between GA •
by weeks and measured of OFD by cm in which $R^2=0.93$. Thus OFD was increased by 0.30 cm per .each week of gestation age

:Recommendations .5.3

1. Ultrasound is an operator dependent so that he need
.well training

Ultra sound is important modality to assess .2
gestational age , we had to use many possible
.parameters

strongly recommend the use of OFD parameter along .3
. with BPD and FL for estimation of gestational age

:Suggestion for future works 5-4

A multi-institutional standardized study should be conduct
as there is serious need for locally recorded standard for
fetal measurement and estimation of gestational age that
knowledge's the diversity of Sudanese population and
.ethnic groups

Appendix : Images

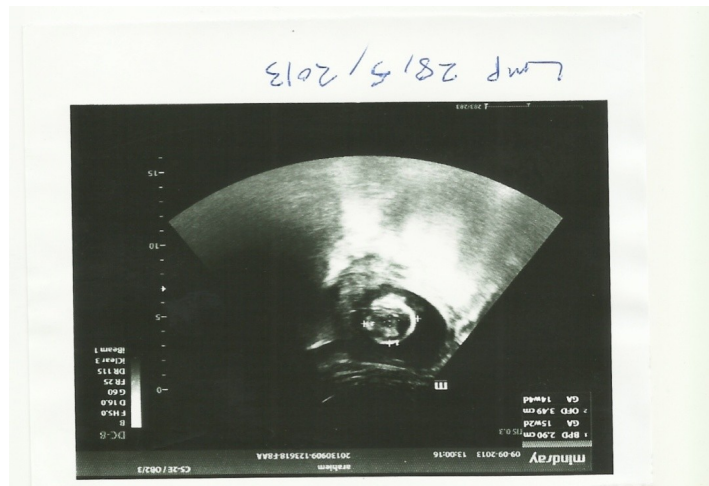

Image (1): shows measurement of BPD = 2.90cm for 15 weeks + 2 days GA, and measurement of OFD = 3.49 cm for 14 weeks +4 days GA. Maternal age = 28 years old, LMP .28.5.2013



Image (2): shows measurement of BPD = 7.43cm for 29 weeks + 6 days GA , measurement of OFD = 9.34 cm for 28 weeks +4 days GA, and FL = 5.54 cm for 29 weeks + 1 . days.Maternal age =37 years old ,LMP 5.4.2013



Image (3): shows measurement of BPD = 3.73cm for 17 weeks + 3 days GA, measurement of OFD = 4.13 cm for .16 weeks GA .Maternal age 40 years old, LMP 21.6.2013

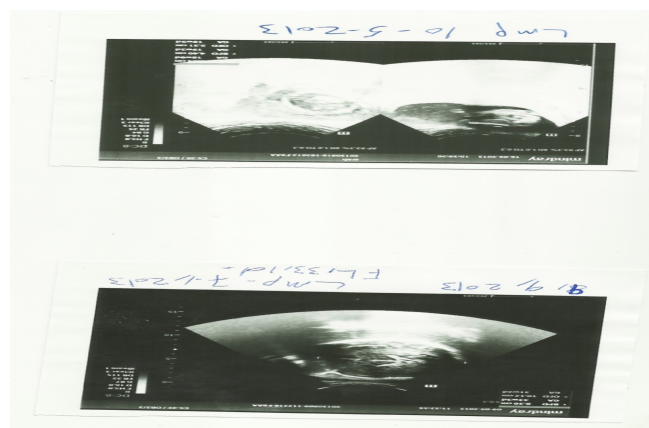


Image (4): shows measurement of BPD = 4.40cm for 19 weeks + 2 days GA , measurement of OFD = 5.31 cm for 18 weeks+5 days GA and FL = 2.04 cm for 18 weeks. .Maternal age 26 years old, LMP 10. 5.2013

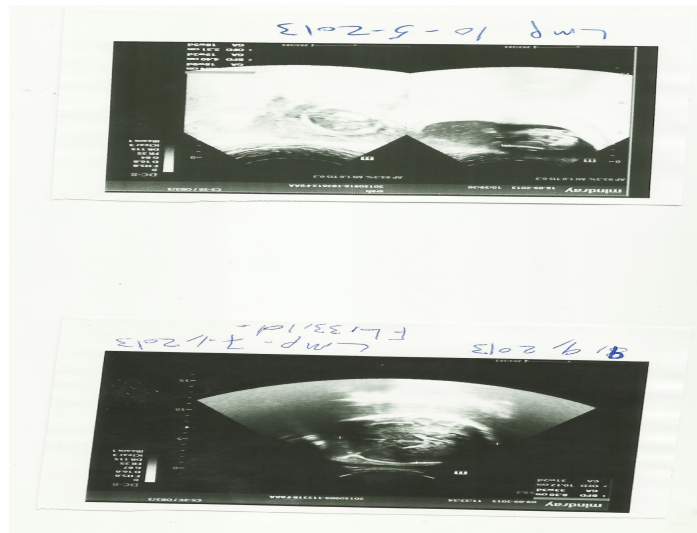
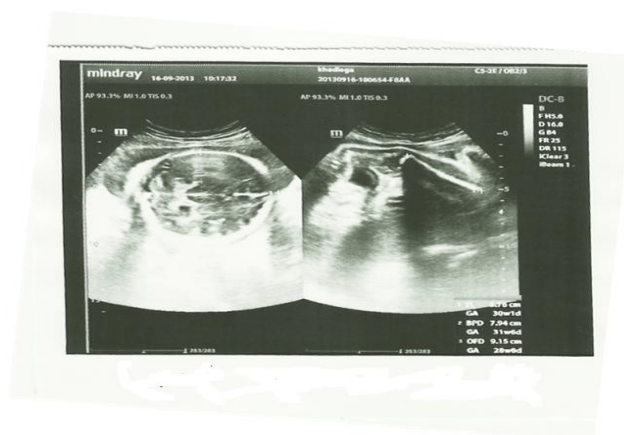


Image (5): shows measurement of BPD = 8.30 cm for 33 weeks + 3 days GA , measurement of OFD = 10.12 cm for 31 weeks+2 days GA. Maternal age 21 years old , LMP 7.1.2013



Image(6): show measurement of BPD = 7.94 cm for 31 weeks + 6 days GA, measurement of OFD = 9.15 cm for 28 weeks and FL = 5.76 cm for 30 weeks +1 day GA.
 .Maternal age 22years old ,LMP12.2.2013

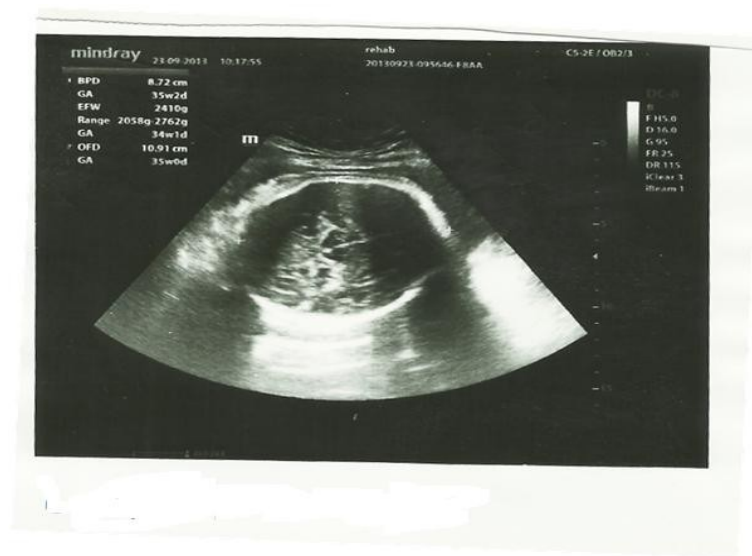


Image (7): shows measurement of BPD = 8.72 cm for 35 weeks + 2 days GA , measurement of OFD 10.91 cm for 35 weeks GA. Maternal age 27 years old , LMP 5.2.2013

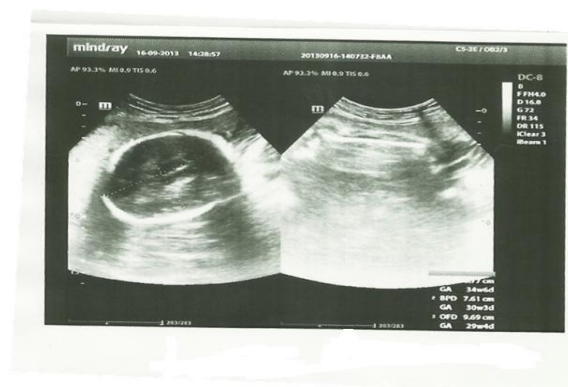


Image (8): shows measurement of BPD = 7.61 cm for 30 weeks + 3days GA , measurement of OFD 6.69 cm for 29 weeks + 3days GA

weeks + 4 days GA. and FL = 34 weeks +6 days GA.
.Maternal age 22years old ,LMP10.2.2013

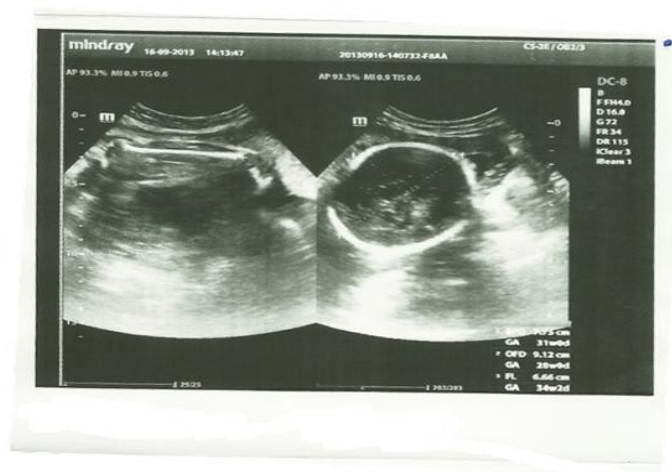

Image (9): shows measurement of BPD = 7.75 cm for 31 weeks GA , measurement of OFD 9.12 cm for 28 weeks GA. and FL = 6.66 cm for 34 weeks +2 days GA. Maternal .age 21 years old ,LMP 3.2.2013

:References

Ansert. Hagen sandaral , text book of diagnostic ultra -
.sonography . 4th edition. 1994-by mosby , in corporatal

Asim Kurjak, frank A chervenak, Donald school text -
book of ultrasound in obstetrics and gynecology.
.Partheron publishing group,2006

British journal of obstetric, and gynacology February -
.1999. Voll06, pp126/135

Chudleighht, and thilaganathan B. 2004 , obstetric -
ultrasound how why and when 3rd edition , Elsevier,
.Churchill living stone, 2004

Enid gilbert-barness, , FRCPA, FRCpath Dsci(hc) and -
Diane Debich-spicer, Embryo and fetal pathology, color
atals with ultrasound correlation - published in usa by
.combridge university press, newyork, 2004

Gilani S.A, printed (2003) obstetricultra sound. -
Guidelines and protocol, for medical diaanostic

ultrasound , Burwin institute of ultrasound, module four
and two

Guyton A.C., and hallj, E., 2006, text book of medical -
physiology, 11th editon, Elsevier inc. pliladelphia,
.Pennsylvania

International journal of advanced science and -
.technology vol17, April, 2010

Journal of prenatal medicine.2008 Jan-Mar, 2(1):11-13 -

John Mc Lachlan, medical embryology Addison - Wesly -
.(1994

Rumack,. Diagnostic ultrasound third edition - Elsevier -
.Mosby, inc 2005

Sandler,T.W, lang man's medical embrydogy -lippinctt -
.Williams and wilkins 2009 eleven editions

www.asum.co Au/new site on normal ultra sonic fetal -
.metal measurement - 2007

.Yonsei medical journal vol 42. No 3. p 299-303.2001 -

