

# **Chapter one**

## **Introduction**

### **1.1 Introduction:**

Abdominal aorta is the largest artery in the abdominal cavity. As part of the aorta, it is a direct continuation of the descending aorta (of the thorax). The abdominal aorta begins at the level of the diaphragm, crossing it via the aortic hiatus, technically behind the diaphragm, at the vertebral level of T12. It travels down the posterior wall of the abdomen, anterior to the vertebral column. It thus follows the curvature of the lumbar vertebrae, that is, convex anteriorly. The peak of this convexity is at the level of the third lumbar vertebra (L3). It runs parallel to the inferior vena cava, which is located just to the right of the abdominal aorta, and becomes smaller in diameter as it gives off branches. This is thought to be due to the large size of its principal branches.

[[http://en.wikipedia.org/wiki/Abdominal\\_aorta](http://en.wikipedia.org/wiki/Abdominal_aorta)]

Knowledge of the normal aortic diameter in Sudanese would be useful in management of patients presenting with aortic aneurysms.

Most abdominal aneurysms are diagnosed during a routine physical examination or on X-ray when being tested for other health concerns. Once an aneurysm is suspected, the following imaging tests may be used to determine size, location of the aneurysm, and treatment options.

An ultrasound scan is the easiest way to detect an AAA. This is a painless test. The size of the aneurysm can also be measured by ultrasound

A more detailed scan, such as a CT scan, is sometimes done. This may be done if your doctor needs to know whether the aneurysm is affecting any of the arteries that come off the aorta. For instance, if the aneurysm involves the section of the aorta where the arteries to the kidneys branch off, surgeons need to know this information if they plan to operate.

Magnetic resonance imaging this permits imaging of the aorta comparable to that obtained with CT and ultrasonography, without subjecting the patient to dye load or ionizing radiation.

Angiogram: test in which a thin tube (catheter) is inserted into a blood vessel and a contrast dye is injected to make the blood vessels visible on the X-ray. This is rarely used to diagnose an abdominal aortic aneurysm but may be used to aid in the treatment of an aneurysm.

## **1.2 Problem of the study:**

It is important to know the normal diameter of abdominal aorta throughout the body so that clinicians are able to determine when an aorta becomes aneurysmal. However, there are no previous studies on the normal diameter of abdominal aorta in the Sudanese people.

## **1.3 Objectives of the Study:**

### **1.3.1 General objective:**

To evaluation of abdominal aortic diameters in the Sudanese people using computed tomography.

### **1.3.2 Specific Objectives:**

- To characterize of the normal abdominal aorta diameter.
- To measure of the abdominal aorta from T12 to L3 vertebral levels in Sudanese.
- To correlate between the aortic diameters and age, gender, height, weight, body mass index (BMI), and body surface area (BSA).
- To find and index of normal abdominal aorta diameters in Sudanese.
- 

### **1.4 Significance of the study:-**

This study will improve the knowledge about normal appearance of aorta in-order to predict the presence of aneurysm and reach the quick diagnosis and treatment.

### **1.5 Overview of the study:**

This study consisted of five chapters, chapter one an introduction which, includes ; problem of study also contain general, specific objectives and significant of the study. Chapter two includes back ground and literature review about role of CT images to measurement abdominal aorta diameters and other modalities might be use. Chapter three describe the methodology will be use in this study. Chapter four include result of presentation of finding of study; finally chapter five include discussion, conclusion and recommendation.

## **Chapter two**

### **Literature review**

#### **2.1 Aorta anatomy:**

The aorta Is the main blood vessel in the human body. As blood is pumped from the heart, it passes across the aortic valve, and then through the aorta, where it is then distributed through a system of smaller arteries. As the aorta travels through the body, each portion has a different name based on its location and each section supplies different organ systems or areas of the body. The aorta first leaves the heart and brings blood towards the head as the ascending aorta. As the aorta turns towards the left side of the body, it gives off branches to the upper body and the brain as the aortic arch. The aorta next travels down the chest, where it is called the descending aorta. The descending aorta continues through the abdomen as the abdominal aorta, where it supplies the abdominal organs before dividing to provide arteries for each leg (the iliac arteries). [Ashley.2011]

##### **2.1.1 Structure of the Aorta:**

###### **2.1.1.1 Aortic root:**

The aortic root may be defined as the portion of the left ventricular outflow tract which supports the leaflets of the aortic valve, delineated by the sinotubular ridge superiorly and the bases of the valve leaflets inferiorly. It comprises the sinuses, the aortic valve leaflets, the commissures, and the interleaflet triangles. The sinuses are expanded portions of the aortic root which are confined proximally by the attachments of the valve leaflets and distally by the sinotubular junction. They

are named according to the coronary arteries arising from them—right, left, and non-coronary. [ Underwood, 2000]

#### **2.1.1.2 Ascending aorta:**

Is the first part of the aorta, and begins at the aortic valve - located obliquely just to the left of the midline at the level of the the third intercostal space. It terminates as it exits the fibrous pericardium and reaches the sternomanubrial joint, where it becomes the aortic arch. It normally has only two branches, the right coronary artery and the left coronary artery. These arise from the right and left aortic sinuses (of Valsalva) respectively, which are out-pouchings of the aortic wall above each cusp of the aortic valve. Immediately above the three aortic sinuses, the normal tubular configuration of the aorta is attained - at the sinotubular junction. (Standring,2008)

#### **2.1.1.3 Aortic arch:**

The most common aortic arch branching pattern in humans consists of 3 great vessels originating from the arch of the aorta. The first branch is the innominate artery, which branches into the right subclavian artery and the right common carotid artery. The second branch in the most common pattern is the left common carotid artery, and the last branch is the left subclavian artery. The final configuration of the aortic arch and its branches is probably related to different growth rates in the various arteries and the associated “migration” and “merging” of the branches. left common carotid artery origin is moved to the right and merges with the origin of the innominate artery. (Lippert,1985)

#### **2.1.1.4 Thoracic aorta:**

Is contained in the posterior mediastinal cavity. It begins at the lower border of the fourth thoracic vertebra where it is continuous with the aortic arch, and ends in front of the lower border of the twelfth thoracic vertebra, at the aortic hiatus in the diaphragm where it becomes the abdominal aorta. At its commencement, it is situated on the left of the vertebral column; it approaches the median line as it descends; and, at its termination, lies directly in front of the column. It is in relation, anteriorly, from above downward, with the root of the left lung, the pericardium, the esophagus, and the diaphragm; posteriorly, with the vertebral column and the azygos vein; on the right side, with the hemiazygos veins and thoracic duct; on the left side, with the left pleura and lung. The esophagus, with its accompanying plexus of nerves, lies on the right side of the aorta above; but at the lower part of the thorax it is placed in front of the aorta, and, close to the diaphragm [Atlas et al, 2006].

#### **2.1.1.5 Abdominal aorta:**

The abdominal aorta lies slightly to the left of the midline of the body. It is covered, anteriorly, by the lesser omentum and stomach, behind which are the branches of the celiac artery and the celiac plexus; below these, by the lienal vein(splenic vein), the pancreas, the left renal vein, the inferior part of the duodenum, the mesentery, and aortic plexus. Posteriorly, it is separated from the lumbar vertebræ and intervertebral fibrocartilages by the anterior longitudinal ligament and left lumbar veins. On the right side it is in relation above with the azygos vein, cisterna chyli, thoracic duct, and the right crus of the diaphragm—the last separating it from the upper part of the inferior vena cava, and from the right celiac ganglion; the inferior vena cava is in contact with the aorta below. On the

left side are the left crus of the diaphragm, the left celiac ganglion, the ascending part of the duodenum, and some coils of the small intestine.  
[en.wikipedia.org/wiki/Abdominal\_aorta]

## **2.1.2 Branches of the Abdominal Aorta:**

### **2.1.2.1 Celiac Artery:**

The celiac also known as the celiac trunk, or truncuscoeliacus The first major branch of the abdominal aorta, the celiac trunk is responsible for supplying oxygenated blood to the stomach, spleen, liver, esophagus, and also parts of the pancreas and duodenum. Along with the superior and inferior mesenteric arteries, it is one of three anterior branches of the abdominal aorta, the largest artery in the abdominal cavity. The celiac trunk is one of the most important arteries in the abdominal area as it is essential for the proper functioning of many major organs that would otherwise be unable to receive sufficient quantities of blood from other arteries. This is because the three anterior arteries of the abdominal aorta are separate and cannot substitute for each other There are three main divisions of the celiac trunk: the left gastric artery, the common hepatic artery, and the splenic artery. [ Ayush ,et al]

### **2.1.2.2 Superior Mesenteric Artery (SMA):**

Is a large vessel which supplies the whole length of the small intestine, except the superior part of the duodenum; it also supplies the cecum and the ascending part of the colon and about one-half of the transverse part of the colon. It arises from the front of the aorta, about 1.25 cm. below the celiac artery, and is crossed at its origin by the lienal vein and the neck of the pancreas. It passes downward and forward, anterior to the processusuncinatus of the head of the pancreas and inferior

part of the duodenum, and descends between the layers of the mesentery to the right iliac fossa, where, considerably diminished in size, it anastomoses with one of its own branches, viz., the ileocolic. In its course it crosses in front of the inferior vena cava, the right ureter and Psoas major, and forms an arch, the convexity of which is directed forward and downward to the left side, the concavity backward and upward to the right. It is accompanied by the superior mesenteric vein, which lies to its right side, and it is surrounded by the superior mesenteric plexus of nerves.( Gray ,1918)

#### **2.1.2.3 Middle Suprarenal Artery:**

Are two small vessels which arise, one from either side of the abdominal aorta, opposite the superior mesenteric artery. They pass laterally and slightly upward, over the crura of the diaphragm, to the suprarenal glands, where they anastomose with suprarenal branches of the inferior phrenic and renal arteries. [Gray ,1918]

#### **2.1.2.4 Renal Artery:**

Are two large trunks, which arise from the side of the aorta, immediately below the superior mesenteric artery. Each is directed across the crus of the diaphragm, so as to form nearly a right angle with the aorta. The right is longer than the left, on account of the position of the aorta; it passes behind the inferior vena cava, the right renal vein, the head of the pancreas, and the descending part of the duodenum. The left is somewhat higher than the right; it lies behind the left renal vein, the body of the pancreas and the lienal vein, and is crossed by the inferior mesenteric vein. Before reaching the hilus of the kidney, each artery divides into four or five branches; the greater number of these lie between the renal vein and

ureter, the vein being in front, the ureter behind, but one or more branches are usually situated behind the ureter.(Gray ,1918)

#### **2.1.2.5 Gonadal Artery:**

The term gonadal artery is a generic term for a paired artery, with one arising from the abdominal aorta for each gonad. Specifically, it can refer to the testicular artery in males and the ovarian artery in females.[ Gray ,1918]

#### **2.1.2.6 Lumbar Artery:**

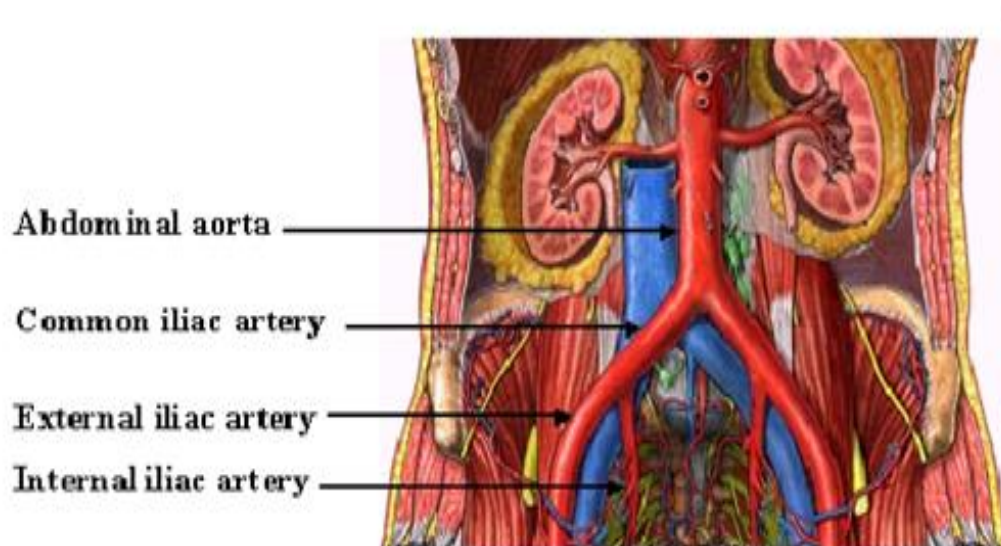
Are in series with the intercostals. They are usually four in number on either side, and arise from the back of the aorta, opposite the bodies of the upper four lumbar vertebræ. A fifth pair, small in size, is occasionally present: they arise from the middle sacral artery. They run lateralward and backward on the bodies of the lumbar vertebræ, behind the sympathetic trunk, to the intervals between the adjacent transverse processes, and are then continued into the abdominal wall. The arteries of the right side pass behind the inferior vena cava, and the upper two on each side run behind the corresponding crus of the diaphragm. The arteries of both sides pass beneath the tendinous arches which give origin to the Psoas major, and are then continued behind this muscle and the lumbar plexus. They now cross the Quadratuslumborum, the upper three arteries running behind, the last usually in front of the muscle. At the lateral border of the Quadratuslumborum they pierce the posterior aponeurosis of the Transversusabdominis and are carried forward between this muscle and the Obliquusinternus. They anastomose with the lower intercostal, the subcostal, the iliolumbar, the deep iliac circumflex, and the inferior epigastric arteries. (Gray ,1918)

### **2.1.2.7 Inferior Mesenteric Artery:**

Supplies the left half of the transverse part of the colon, the whole of the descending and iliac parts of the colon, the sigmoid colon, and the greater part of the rectum. It is smaller than the superior mesenteric, and *arises* from the aorta, about 3 or 4 cm. above its division into the common iliacs and close to the lower border of the inferior part of the duodenum. It passes downward posterior to the peritoneum, lying at first anterior to and then on the left side of the aorta.(Gray ,1918)

### **2.1.2.8 Common Iliac:**

The common iliac artery originates from the abdominal aorta. The aorta is the main trunk of the systemic arteries in the cardiovascular system. This system carries oxygenated blood from the heart to the other areas of the body and back. At the fourth lower lumbar vertebral body the aorta ends by dividing into the right and left common iliac arteries. The two arteries travel below and to one side for about four to five centimeters towards the edge of the pelvis. It splits into an internal and external iliac artery at the level of the pelvic inlet. The internal iliac artery supplies the pelvic organs including the urinary bladder, the man's prostate gland, and the woman's uterus and vagina. The external iliac artery through - the femoral artery supplies the thigh - the popliteal artery supplies the knee area and the anterior and posterior tibial arteries supply the area below the knee including the feet and toes. The common iliac artery is a paired structure, meaning there is one on the right and one on the left of the body. [Avenue,2006]



**Figure 2-1 Show inferior branches abdominal aorta**

[Avenue,2006]

## 2.2 Physiology:

The double circulatory system of blood flow refers to the separate systems of pulmonary circulation and the systemic circulation in amphibians, birds and mammals (including humans.) In contrast, fishes have a single circulation system. For instance, the adult human heart consists of two separated pumps, the right side with the right atrium and ventricle (which pumps deoxygenated blood into the pulmonary circulation), and the left side with the left atrium and ventricle (which pumps oxygenated blood into the systemic circulation). Blood in one circuit has to go through the heart to enter the other circuit. Blood circulates through the body two to three times every minute.

### **2.2.1 The Pulmonary Circuit:**

Pulmonary circulation is the movement of blood from the heart to the lungs for oxygenation, then back to the heart again . Oxygen-depleted blood from the body leaves the systemic circulation when it enters the right atrium through the superior and inferior venae cavae. The blood is then pumped through the tricuspid valve into the right ventricle. From the right ventricle, blood is pumped through the pulmonary valve and into the pulmonary artery. The pulmonary artery splits into the right and left pulmonary arteries and travel to each lung. At the lungs, the blood travels through capillary beds on the alveoli where respiration occurs , removing carbon dioxide and adding oxygen to the blood. The alveoli are air sacs in the lungs that provide the surface for gas exchange during respiration. The oxygenated blood then leaves the lungs through pulmonary veins, which returns it to the left atrium, completing the pulmonary circuit. Once entering the left heart, the blood flows through the bicuspid valve into the left ventricle. From the left ventricle, the blood is pumped through the aortic valve into the aorta to travel through systemic circulation, delivering oxygenated blood to the body before returning again to the pulmonary circulation.[[www.boundless.com](http://www.boundless.com)]

### **2.2.2 The Systemic Circuit:**

Systemic circulation is the movement of blood from the heart through the body to provide oxygen and nutrients, and bringing deoxygenated blood back to the heart. Oxygen-rich blood from the lungs leaves the pulmonary circulation when it enters the left atrium through the pulmonary veins. The blood is then pumped through the mitral valve into the left ventricle. From the left ventricle, blood is pumped through the aortic valve and into the aorta, the body's largest artery. The aorta arches and branches into major arteries to the upper body before passing through the diaphragm, where it branches further into arteries which supply the lower parts of

the body. The arteries branch into smaller arteries, arterioles, and finally capillaries. Waste and carbon dioxide diffuse out of the cell into the blood, while oxygen in the blood diffuses out of the blood and into the cell. The deoxygenated blood continues through the capillaries which merge into venules, then veins, and finally the venae cavae, which drain into the right atrium of the heart. From the right atrium, the blood will travel through the pulmonary circulation to be oxygenated before returning again to the system circulation. Coronary circulation, blood supply to the heart muscle itself, is also part of the systemic circulation. [www.boundless.com]

## **2-3 Pathology:**

### **2.3.1 Abdominal aortic stenosis (AAS):**

Abdominal aortic stenosis (AAS) refers to abnormal narrowing of the aorta anywhere along its course in the abdomen. The aorta enters the abdomen through the thoracic hiatus at the level of the 12th thoracic vertebra in front of the spinal cord and terminates as the right and left iliac arteries. Stenosis can result from congenital or acquired lesions. AAS produces a bottleneck effect, where there is hypertension above the lesion and hypotension below and can often be diagnosed based on the difference in blood pressure between the upper and lower extremities. Symptoms can be divided into three categories based on the major groups of arteries supplied by the abdominal aorta. (Heather, 2011)

### **2.3.2 Atherosclerosis:**

Atherosclerosis appears to play a major role in diseases of the aortic arch, descending thoracic, and abdominal aorta. Atherosclerosis can result in weakening of the aortic wall, making it prone to aneurysm formation or dissection. The development of aortic atherosclerosis is associated with traditional cardiac risk factors of smoking, hypertension, hyperglycemia, and atherogenic lipoproteins. Atherosclerosis can also lead to the formation of complex atheromatous plaques, which are prone to embolization, resulting in cerebral and peripheral arterial occlusive events.[ Mary ,2014]

### **2.3.3 Aortic regurgitation:**

Aortic regurgitation (AR) is the diastolic flow of blood from the aorta into the left ventricle (LV). Regurgitation is due to incompetence of the aortic valve or any disturbance of the valvular apparatus (eg, leaflets, annulus of the aorta) resulting in the diastolic flow of blood into the left ventricular chamber. Aortic regurgitation may be a chronic disease process or it may occur acutely, presenting as heart failure. The most common cause of chronic aortic regurgitation used to be rheumatic heart disease, but presently it is most commonly caused by bacterial endocarditis. In developed countries, it is caused by dilation of the ascending aorta (eg, aortic root disease, aortoannulorectasia). Acute aortic regurgitation is associated with significant morbidity, which can progress from pulmonary edema to refractory heart failure and cardiogenic shock. (Stanley, 2014)

### **2.3.4 Aortic dissection**

Aortic dissection is defined as separation of the layers within the aortic wall. Tears in the intimal layer result in the propagation of dissection (proximally or distally) secondary to blood entering the intima-media space. Mortality is still high despite advances in diagnostic and therapeutic modalities. Aortic dissection can be rapidly fatal, with many patients dying before presentation to the emergency department or before diagnosis is made in the ED. Acute aortic dissection can be treated surgically or medically. In surgical treatment, the area of the aorta with the intimal tear is usually resected and replaced with a Dacron graft. Endovascular repair is emerging as the preferred treatment for descending aortic dissection. (Mary, 2014)

### **2.3.5 Abdominal aortic aneurysm(AAA):**

Abdominal aortic aneurysm (also known as AAA, pronounced "triple-a") is a localized dilatation (ballooning) of the abdominal aorta exceeding the normal diameter by more than 50 percent, and is the most common form of aortic aneurysm. Approximately 90 percent of abdominal aortic aneurysms occur infrarenally (below the kidneys), but they can also occur pararenally (at the level of the kidneys) or suprarenally (above the kidneys). Such aneurysms can extend to include one or both of the iliac arteries in the pelvis. [Upchurch, 2006]

Abdominal aortic aneurysms occur most commonly in individuals between 65 and 75 years old and are more common among men and smokers. They tend to cause no symptoms, although occasionally they cause pain in the abdomen and back (due to pressure on surrounding tissues) or in the legs (due to disturbed blood flow). The major complication of abdominal aortic aneurysms is rupture, which is life-threatening, as large amounts of blood spill into the abdominal cavity, and can lead to death within minutes. (Upchurch, 2006)

Surgery is recommended when the aneurysm is large enough ( $>5.5$  cm in diameter). With newer procedures, surgical risk is minimal – much less than the risk of rupture. Open surgery is a viable option to stents, particularly when one chooses to avoid the issues associated with routine stent replacement or early failure. A stent consists of a stainless steel mesh liner inserted through the groin and put in place with endoscopic tools, then spread with a balloon-like device to hold the stent in place. Yearly CT scans are necessary to determine if the mesh tube stents have failed and require replacement.(Chadi,2012)

#### **2.3.5.1 Classification:**

Abdominal aortic aneurysms are commonly divided according to their size and symptomatology. An aneurysm is usually defined as an outer aortic diameter over 3 cm (normal diameter of the aorta is around 2 cm). If the outer diameter exceeds 5.5 cm, the aneurysm is considered to be large. A ruptured AAA is a clinical diagnosis involving the presence of the triad of abdominal pain, shock and a pulsatile abdominal mass. If these conditions are present, indicating AAA rupture, no further clinical investigations are needed before surgery.(Bown, 2002)

#### **2.3.5.2 Signs and symptoms:**

The vast majority of aneurysms are asymptomatic. However, as abdominal aortic aneurysms expand, they may become painful and lead to pulsating sensations in the abdomen or pain in the chest, lower back, or scrotum. The risk of rupture is high in a symptomatic aneurysm, which is therefore considered an indication for surgery. The complications include rupture, peripheral embolization, acute aortic occlusion, and aortocaval (between the aorta and inferior vena cava) or aortoduodenal (between the aorta and the duodenum) fistulae. On physical examination, a palpable abdominal mass can be noted. Bruits can be present in case of renal or visceral arterial stenosis. (Fauci ,2008)

The clinical manifestation of ruptured AAA usually includes excruciating pain of the lower back, flank, abdomen and groin. The bleeding usually leads to a hypovolemic shock with hypotension, tachycardia, cyanosis, and altered mental status. The mortality of AAA rupture is up to 90%. 65–75% of patients die before they arrive at hospital and up to 90% die before they reach the operating room. The bleeding can be retroperitoneal or intraperitoneal, or the rupture can create an aortocaval or aortointestinal (between the aorta and intestine) fistula. (Brown LC,1999)

### **2.3.5.3 Risk factors for an AAA:**

It's not known exactly what causes the aortic wall to weaken, although increasing age and being male are known to be the biggest risk factors. One study found that people aged over 75 are seven times more likely to be diagnosed with an AAA than people under 55 years old. Men are around six times more likely to be diagnosed with an AAA than women. Described below other risk factors :

#### **2.3.5.3.1 Smoking:**

Research has found that smokers are seven times more likely to develop an AAA than people who have never smoked. The more you smoke, the greater your risk of developing an AAA. People who regularly smoke more than 20 cigarettes a day may have more than 10 times the risk of non-smokers. The risk may increase because tobacco smoke contains harmful substances that can damage and weaken the wall of the aorta. [Jonathan.2014]

#### **2.3.5.3.2 Atherosclerosis:**

Atherosclerosis is a potentially serious condition where arteries become clogged up by fatty deposits, such as cholesterol. An AAA is thought to develop because these deposits (called plaques) cause the aorta to widen in an attempt to keep blood flowing through it. As it widens, it also gets weaker. Smoking, eating a high-fat diet and high blood pressure all increase your risk of developing atherosclerosis.[ Jonothan.2014]

#### **2.3.5.3.3 High blood pressure:**

As well as contributing to atherosclerosis, high blood pressure (hypertension) can place increased pressure on the aorta's wall.[ Jonothan.2014]

#### **2.3.5.3.4 Family history:**

Having a family history of AAAs means that you have an increased risk of developing one. One study found that people who had a brother or sister with an AAA were eight times more likely to develop one than people whose siblings were unaffected.[ Jonothan.2014]

### **2.4 Previous studies:**

Jasper, et al, 2014 their study established normal diameters for the suprarenal and infrarenal abdominal aorta measured at T12 and L3 vertebral levels in the Indian population and to study the variation in aortic diameters with age, sex, height, weight, body mass index (BMI), and body surface area (BSA). All patients who underwent helical contrast-enhanced computed tomography (CT) scans of the abdomen for non-cardiovascular reasons were recruited. The mean diameters at T12 and L3 vertebral levels in men were  $19.0 \pm 2.3$  and  $13.8 \pm 1.9$  mm and in women  $17.1 \pm 2.3$  and  $12.0 \pm 1.6$  mm, respectively. The aortic diameter

progressively increased in caliber with increasing age of the patients and was smaller in women than men. A significant positive correlation was found in men between the suprarenal and infrarenal aortic diameters and weight, BSA, and BMI. In women, this correlation was significant in the infrarenal aorta but not in the suprarenal aorta. A brief comparison of data between Indian and Western population showed that the values obtained were less than published elsewhere. (Jasper et al, 2014)

Joh, et al, 2013 their studied to determine the normal reference diameters of the abdominal aorta and iliac arteries by ultrasound in the Korean population. The mean diameters of male/female were 2.20/2.11 ( $p < 0.001$ ) at suprarenal, 2.04/1.90 ( $p < 0.001$ ) at renal, 1.90/1.79 ( $p < 0.001$ ) at infrarenal, 1.22/1.17 ( $p < 0.001$ ) at right iliac and 1.47/1.15 ( $p = 0.097$ ) at the left iliac, respectively. There was a significantly larger diameter in the male population. The diameter of each level increased with age. (Joh et al, 2013)

Study done by Sariosmanoglu et al, 2002 to determine the normal values for aortic diameters and the prevalence of aortic dilatation by ultrasonography examination in a mixed Turkish population. The mean age was 48  $\pm$  16 years (range, 6-88 years). The mean aortic diameter in the whole group was 19.0  $\pm$  3.9 mm (10-45 mm) at the subdiaphragmatic level and 15.7  $\pm$  3.6 mm (9-65 mm) at the aortic bifurcation level. The mean subdiaphragmatic aortic diameter was 18  $\pm$  3 mm in females and 19  $\pm$  4 mm in males. The mean aortic diameter at the bifurcation level was 15  $\pm$  3 mm in females and 16  $\pm$  4 mm in males. An aortic bifurcation diameter  $> 30$  mm was encountered in 0.67% of the population. This ratio increased to 1.8% in patients over 55 years of age, regardless of sex. In this national study, the subdiaphragmatic aortic diameters were similar to mean values reported in the world literature. The mean aortic bifurcation diameters were

generally lower when compared with the literature, which may be due to difficulties in standardization of the measurements. (Sariosmanoglu et al , 2002)

Study done by Sonesson et al,1994 to determine the relevance of abdominal aortic dilatation, knowledge of the normal aortic diameter and its relation to age, sex and body size. The infrarenal aorta was found to increase steadily in diameter throughout life. From about 25 years the diameter was larger in males than in females ( $p < 0.01$ ) though this difference vanished if corrected for differences in body surface area. Significant correlations were found between aortic diameter and weight ( $r = 0.84$ ,  $p < 0.001$ ), height ( $r = 0.77$ ,  $p < 0.001$ ) and body surface area ( $r = 0.83$ ,  $p < 0.001$ ). Age followed by body surface area were the factors most influencing aortic diameter in both males ( $r = 0.92$ ,  $p < 0.001$ ) and females ( $r = 0.94$ ,  $p < 0.001$ ). Nomograms predicting aortic diameters in relation to age, sex, and body surface area are presented. (Sonesson et al , 1994)

Study done by Rogers et al,2013 to define normal aortic diameters in asymptomatic men and women in a community-based cohort and to determine the association between aortic diameters and traditional risk factors for cardiovascular disease. For men, the average diameters were 19.3 mm for the infrarenal abdominal aorta (IRA), and 18.7 mm for the lower abdominal aorta (LAA). For women, the average diameters were 16.7 mm for the IRA, and 16.0 mm for the LAA. Average diameters of the thoracic and abdominal aorta by computed tomography are larger in men compared with women, vary significantly with age and body surface area, and are associated with modifiable cardiovascular disease risk factors, including diastolic blood pressure and cigarette smoking. (Rogers et al, 2013 )

Finally study done by Wanhainen et al ,2008 to determine the optimal dividing-line between normal aorta and aneurysm for different aortic segments in 70-year-old

men and women by means of whole-body magnetic resonance imaging Two hundred thirty-one subjects (116 men), randomly recruited from a population-based cohort study, were included. The smallest outer diameter (dia) was measured on the axial survey scan on six predefined aortic segments: (1) ascending aorta, (2) descending aorta, (3) supraceliac aorta, (4) suprarenal aorta, (5) largest infrarenal abdominal aorta, and (6) aortic bifurcation Relative aortic dia were calculated by dividing a given aortic dia by the suprarenal aortic dia. The dividing-line between normal aorta and aneurysm at different aortic segments was estimated by taking the mean dia +2 SD and/or mean ratio of the aortic segment to the suprarenal aorta +2 SD. The mean dia of the six segments were 4.0 cm (SD 0.4), 3.2 cm (0.3), 3.0 cm (0.3), 2.8 cm (0.3), 2.4 cm (0.5), and 2.3 cm (0.3) in men. The corresponding dia in women were 3.4 cm (0.4), 2.8 cm (0.3), 2.7 cm (0.3), 2.7 cm (0.3), 2.2 cm (0.3), and 2.0 cm (0.2). For men the suggested dividing-line (dia and ratio) between normal aorta and aneurysm for the ascending aorta is 4.7 cm dia and 1.8 ratio, for the descending aorta 3.7 cm dia and 1.5 ratio, and for the infrarenal aorta is 3.0 cm dia and 1.1 ratio. The corresponding dividing-lines for women are 4.2 cm dia and 1.7 ratio, 3.3 cm dia and 1.3 ratio, and 2.7 cm dia and 1.0 ratio. (Wanhainen et al ,2008)

Table 2.1 shows similar previous studies done for measurement diameter of abdominal aorta:

Author	Race	Mean		Modalities
		M	F	
A Jasper, 2014	Indian	T12:19.0± 2.3 L3: 13.8 ± 1.9	T12:17.1± 2.3 L3:12.0 ± 1.6	CT
Joh H 2013	Korean	T12:2.20 L2:1.90	T12 :2.11 L2:1.79	Ultrasound
Sariosmanoglu N, 2002	Turkish	T12:19±4 mm L3:16±4 mm	T12: 18± 3 mm L3: 15± 3 mm	Ultrasound
Rogers IS, 2013	-	L2:19.3 mm L3:18.7 mm	L2: 16.7 mm L3: 16.0 mm	-

## **Chapter three**

### **Materials and methods**

The methodology section of this thesis described the design of the study, the setting where it took place, the sampling design that was used, and the instruments that were involved in data collection, and also the procedures that were followed for data collection. The statistics that were used for data analysis and a description of the way in which data were analyzed are also discussed.

### **3.1 Materials**

#### **3.1.1 Study sample:**

Total samples of 100 patients in the study, their ages were between (18 -80) years old. Both genders were include 43were males and 57were females. All patient with cardiovascular disease were excluded and patient without cardiovascular include.

#### **3.1.2 Area and duration of the study:**

The study had been carried out during the period from July 2014 up to November 2014 in Modern Medical Center and Military Hospital.

#### **3.1.3 Machines used:**

In Modern Medical Center CT scanner used GE high speed dual sensation with KVP 120.

In Military Hospital CT scanner used Toshiba 64 slices.

### 3.2 Methods of scanning:

CT scan was done started from lower chest to symphysis pubis in the most cases contrast media (omnipaque) to delivered into the body through the venous system the dose (70-100) according to patient weight and hospital polices with delay 30se -40 se ,the rate of injection 2 -3- ml/s . The technical exposures factors that were used in this study were 120 Kv, 100 mA, 10 mm increments, 5 - 10 mm slice thickness with identical reconstruction index and a rotation time 1.5 sec.

#### 3.2. 1 Methods of measurements:

**All the measurements done for** abdominal aorta diameters were obtained from the distant between the aorta lumens .

All images of study are measurement to transverse abdominal aorta diameters In axial CT abdominal with contrast between two borders of aorta at levelesT12,L1,L2and L3 the method show in figure (3.1)

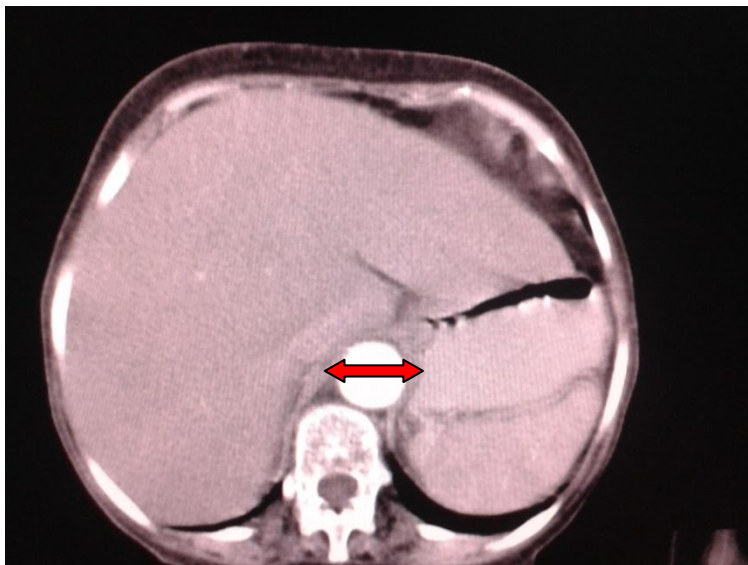


Figure 3.1: Show method of transverse abdominal aorta measurement.

### **3.3Data analyzes:**

The data were analyzed using Excel programme and SPSS version 16 for significances of tests was used. Frequency tables mean and standard deviations were presented.

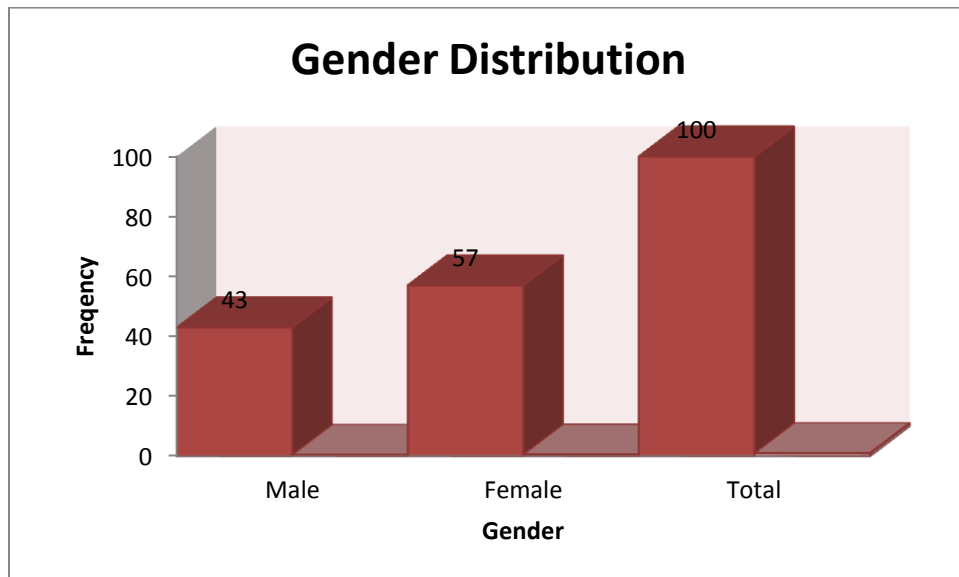
## Chapter Four

### Results

The following tables and figures presented the data obtained from 100 patients who were examined for axial CT abdomen, the aorta width was measured at four levels and the vertebra at the same level was also measured as reference value, patients age weight, height, BMI, BSA have also been measured. The data was analyzed using Excel programme and SPSS version 16 for significances of tests was used. Frequency tables mean and standard deviations were presented.

*Table 4.1 the patient classification according to gender*

Gender	Frequency	Percentages%
Male	43	43%
Female	57	57%
Total	100	100%

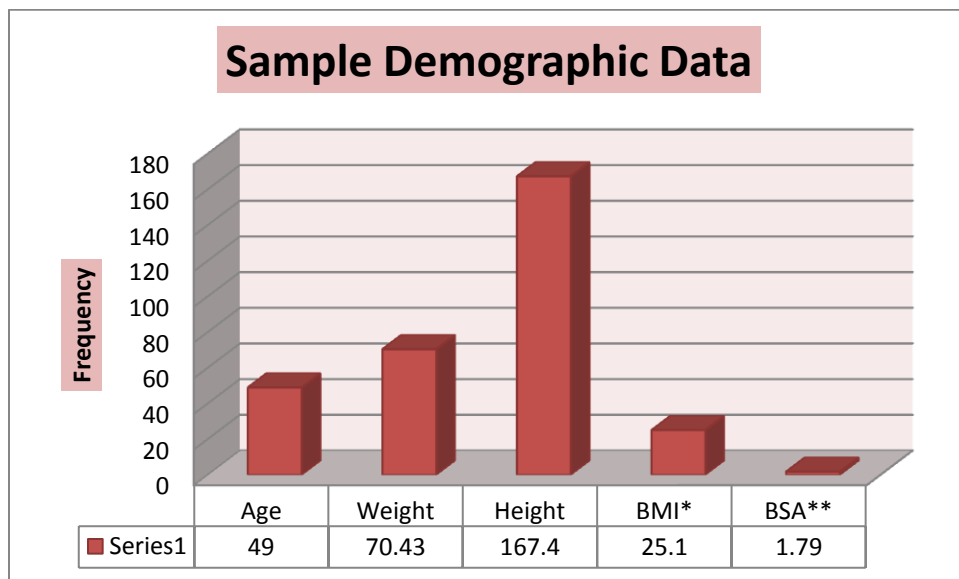


*Figure4.1 The gender distribution*

**Table 4.2 The Sample Demographic Data(Males and Females)**

	Age	Weight	Height	BMI*	BSA**
<b>Mean</b>	49	70.43	167.4	25.1	1.79
<b>STDV</b>	±15	±10.29	±5.99	±3.47	±0.14

\*BMI stands for Body mass Index taken by dividing the weight /height square, BSA\*\* stands for body surface areas taken by  $(\text{Height (cm)} \times \text{Weight (kg)} / 3600)^{1/2}$ .



**Figure 4.2 The sample demographic Data**

**Table 4.3 the Correlation between the variables including aorta transverse diameter (ATD) and the vertebra transverse diameter(VTD) at the same level(Males and Females).**

Variables	ATD*	Vertebra	ATD	Vertebra	ATD	Vertebra	ATD	Vertebra
	T12	T12	L1	L1	L2	L2	L3	L3
<b>Mean</b>	1.99	3.7	1.79	3.81	1.59	4.0	1.49	4.19
<b>STDV</b>	±0.25	±0.32	±0.24	±0.28	±0.19	±0.28	±0.16	±0.26
<b>P value</b>	0.023**		0.019**		0.059**		0.047**	

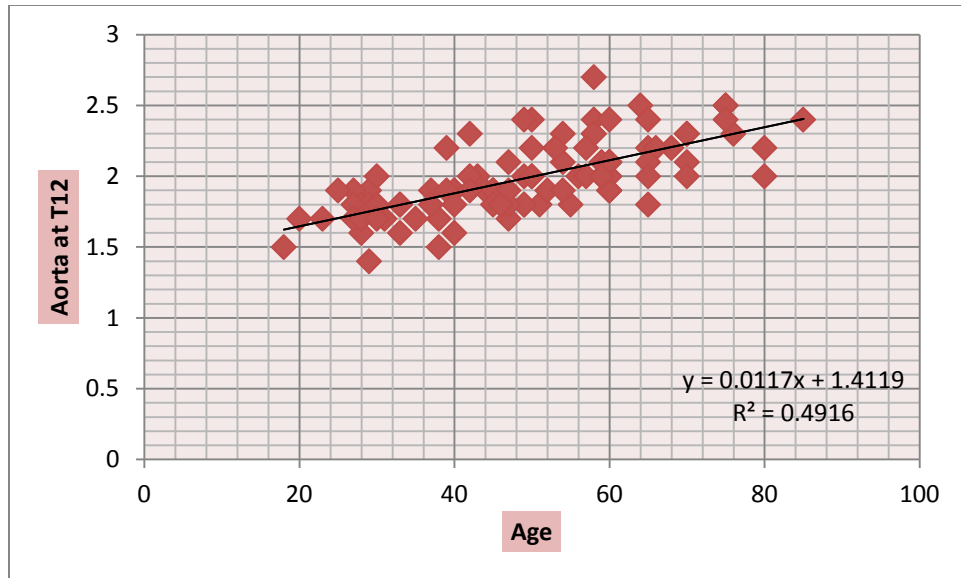
\*ATD stands for aorta transverse diameter

\*\*Correlations are significant at  $P=0.05$

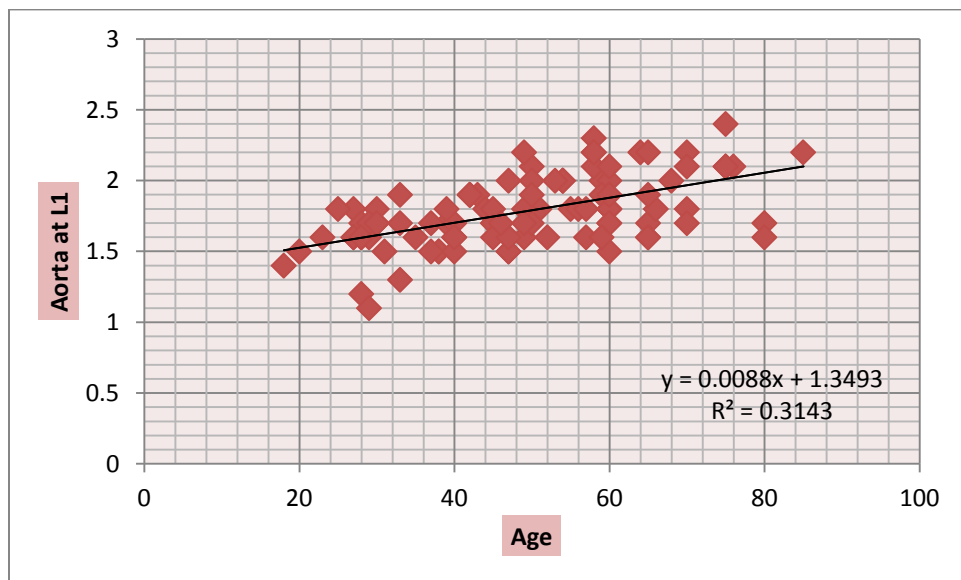
**Table 4.4The mean and Standard Deviation and P-value between the variables including Weight, Height BMI, BSA, aorta transverse diameter (ATD) and the vertebra transverse diameter(VTD) at the same level(Males and Females).**

Gender	weight	Height	BMI	BSA	ATD (T12)	ATD (L1)	ATD (L2)	ATD (L3)	VTD (T12)	VTD (L1)	VTD (L2)	VTD (L3)
<b>Female</b>	70.57	165.5	25.65	1.77	1.89	1.69	1.5	1.45	3.60	3.72	3.92	4.09
	±9.9	±4.6	±3.4	±0.1	±0.2	±0.2	±0.1	±0.1	±0.3	±0.3	±0.3	±0.2
<b>Males</b>	70.23	169.88	24.25	1.80	2.1	1.91	1.68	1.54	3.79	3.91	4.12	4.30
	±11.8	±17.1	±4.0	±0.2	±0.3	±0.3	±0.2	±0.2	±0.5	±0.4	±0.5	±0.4
<b>P-value</b>	0.230	0.238	0.054*	0.283	0.214	0.254	0.100	0.044*	0.109	0.219	0.095	0.006*

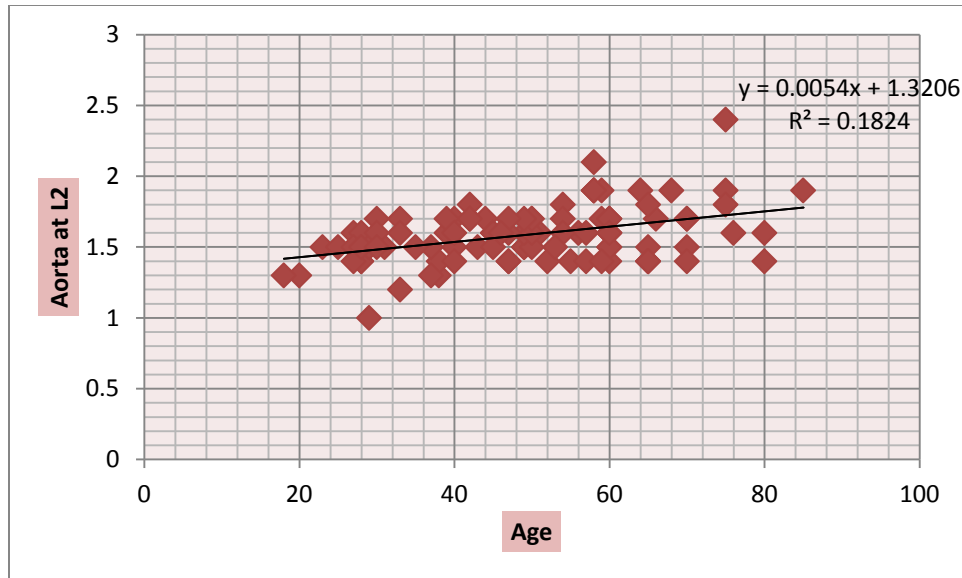
\*Correlations are Significant at  $P=0.05$



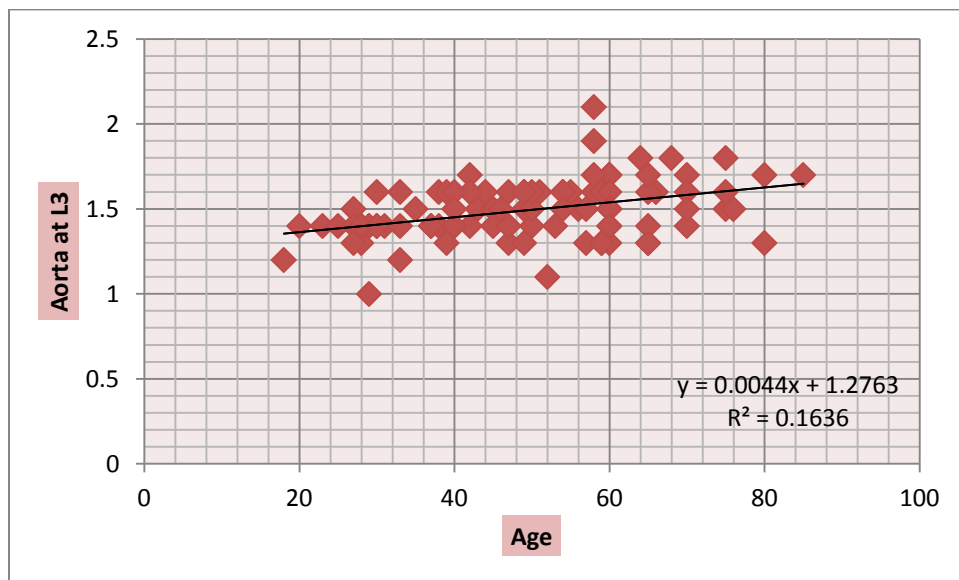
***Figure 4.3 A scatter plot diagram shows a linear relationship between the subjects age and Aorta transverse diameter(ATD)at T12,as the age increases the ATD was also increase by 0.011 starting from 1.4  $R^2=0.491$***



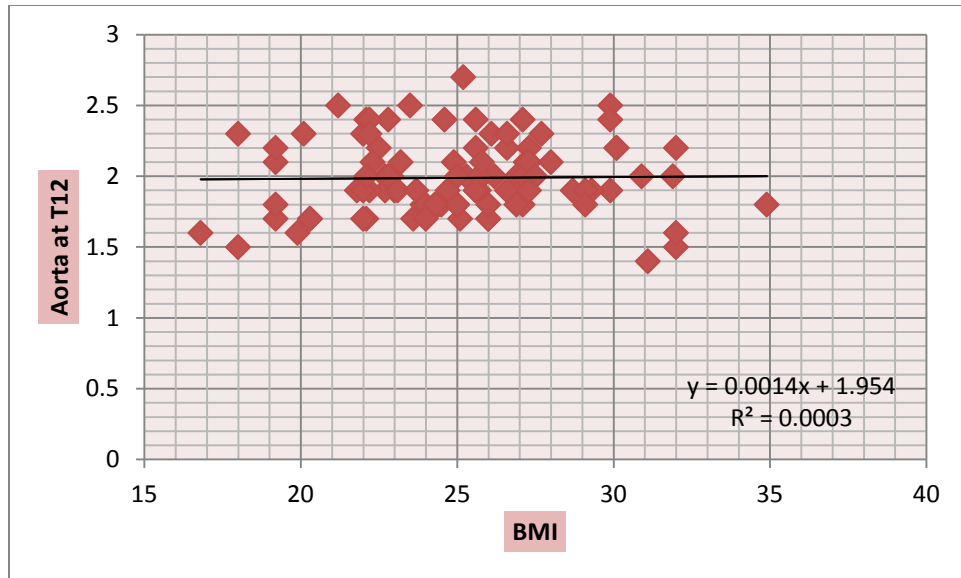
***Figure 4.4 A scatter plot diagram shows a linear relationship between the subjects age and Aorta transverse diameter(ATD)at L1,as the age increases the ATD was also increase by 0.008 starting from 1.3  $R^2=0.314$***



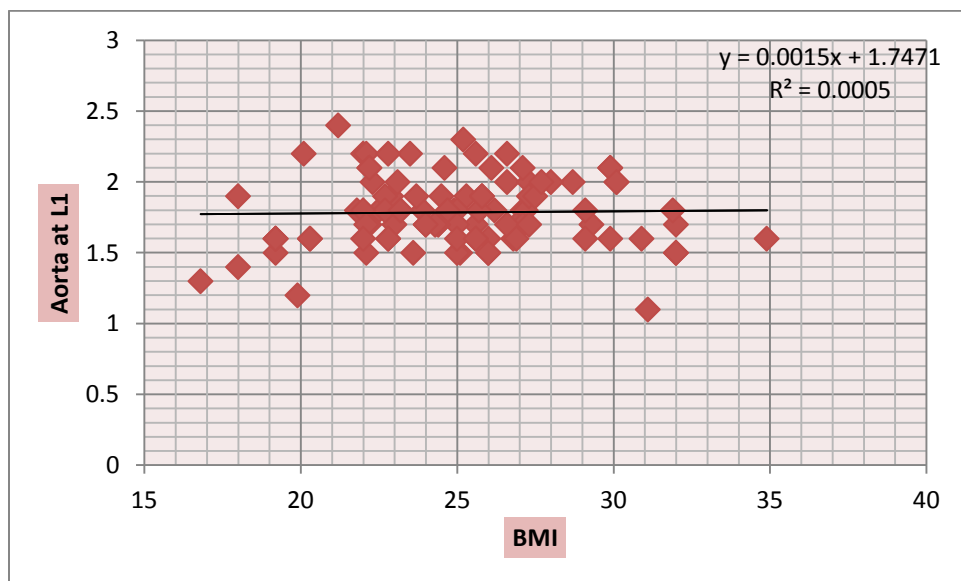
**Figure 4.5** A scatter plot diagram shows a linear relationship between the subjects age and Aorta transverse diameter(ATD)at L2,as the age increases the ATD was also increase by 0.005 starting from 1.3  $R^2=0.182$



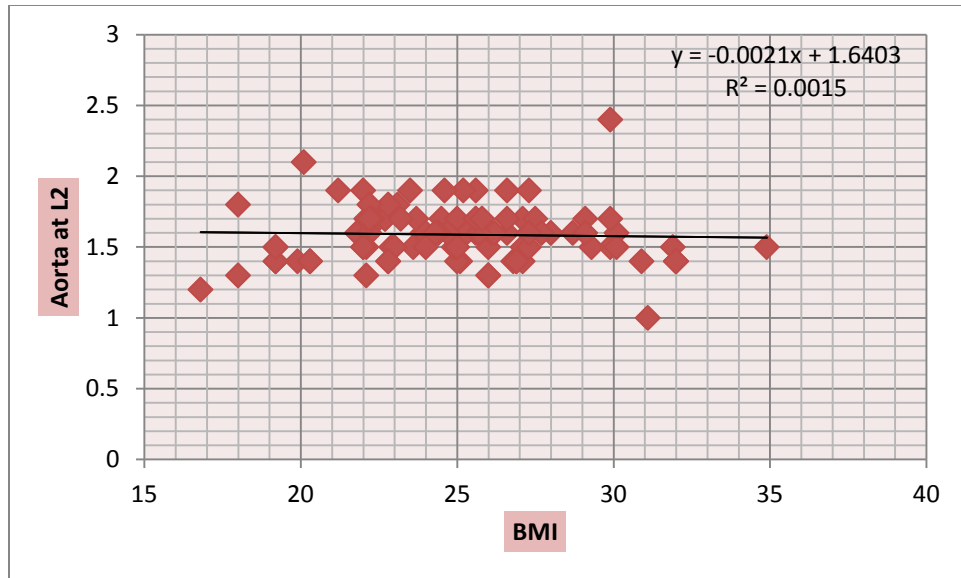
**Figure 4.6** A scatter plot diagram shows a linear relationship between the subjects age and Aorta transverse diameter(ATD)at L3,as the age increases the ATD was also increase by 0.004starting from 1.3  $R^2=0.163$



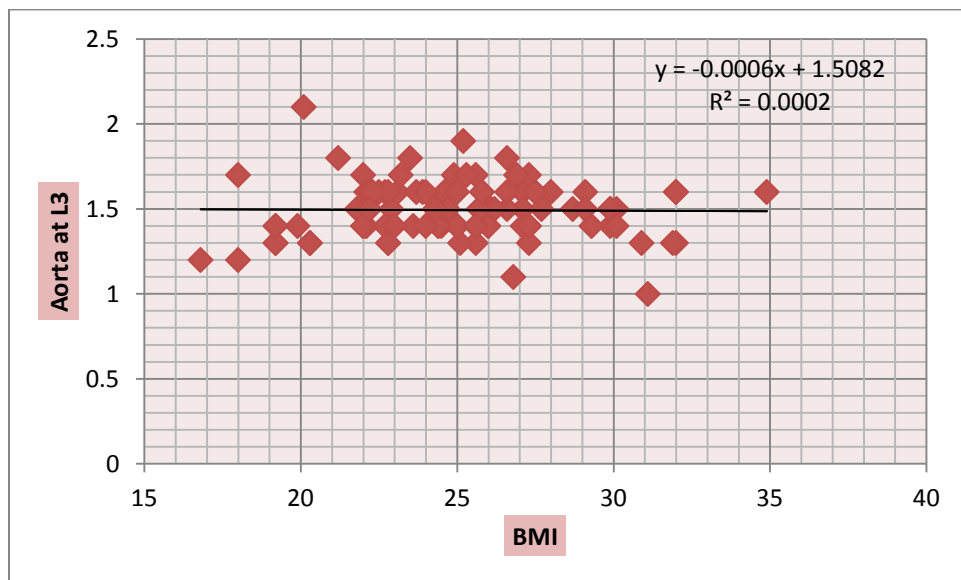
**Figure 4.7** A scatter plot diagram shows a linear relationship between the subjects BMI and Aorta transverse diameter(ATD)at T12,as the BMI increases the ATD was also increase by 0.001 starting from 1.9  $R^2=0.000$



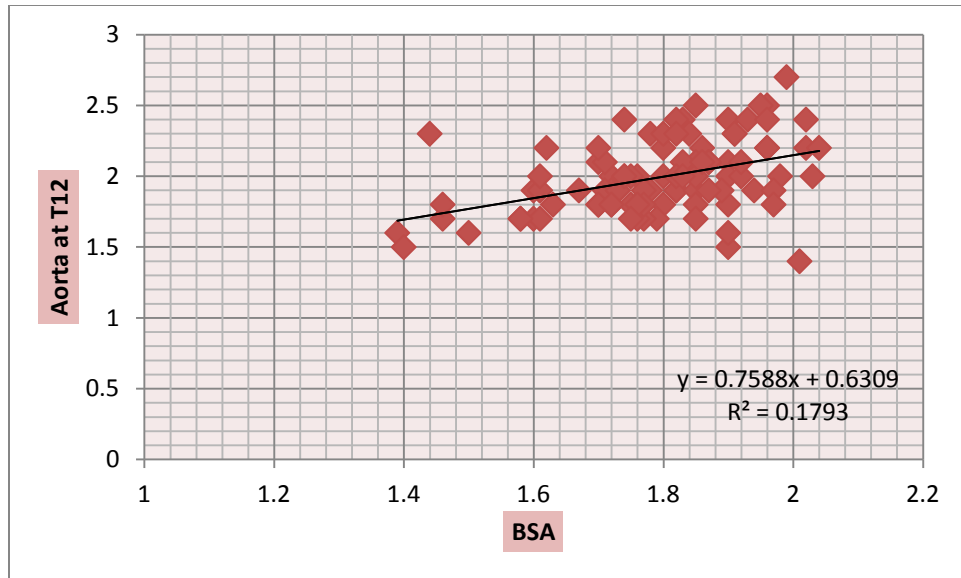
**Figure 4.8** A scatter plot diagram shows a linear relationship between the subjects age and Aorta transverse diameter(ATD)at L1,as the BMI increases the ATD was also increase by 0.001 starting from 1.7  $R^2=0.000$



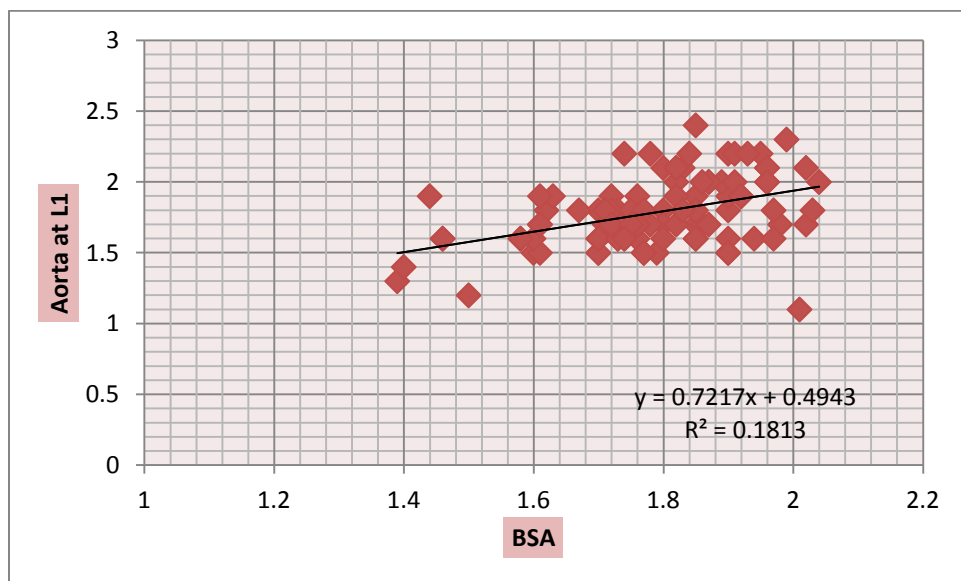
**Figure 4.9** A scatter plot diagram shows a linear relationship between the subjects BMI and Aorta transverse diameter(ATD)at L2,as the BMIincreases the ATD decreases by 0.002 starting from 1.6 $R^2=0.001$



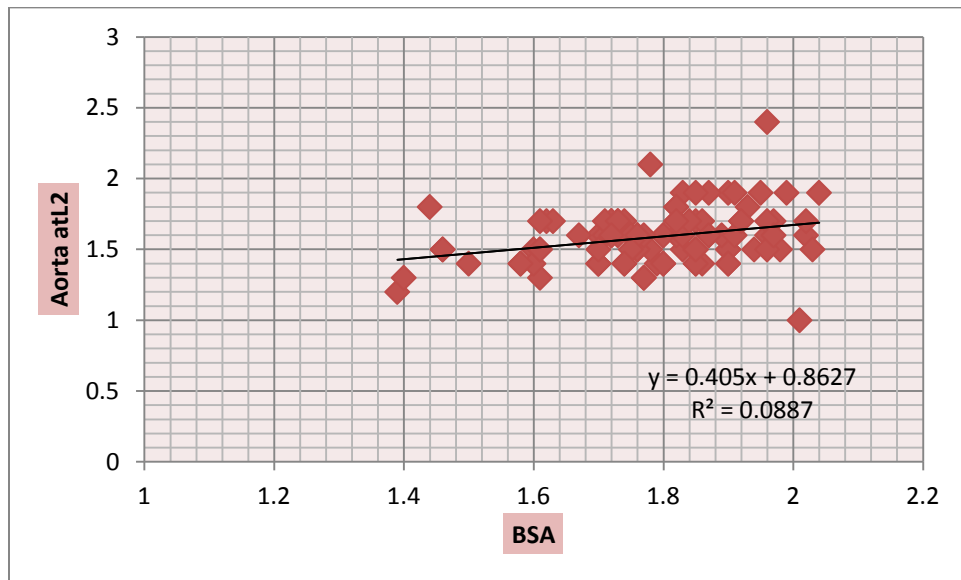
**Figure 4.10** A scatter plot diagram shows a linear relationship between the subjects BMI and Aorta transverse diameter(ATD)at L3,as the BMIincreases the ATD decreases by 0.000 starting from 1.5 $R^2=0.000$



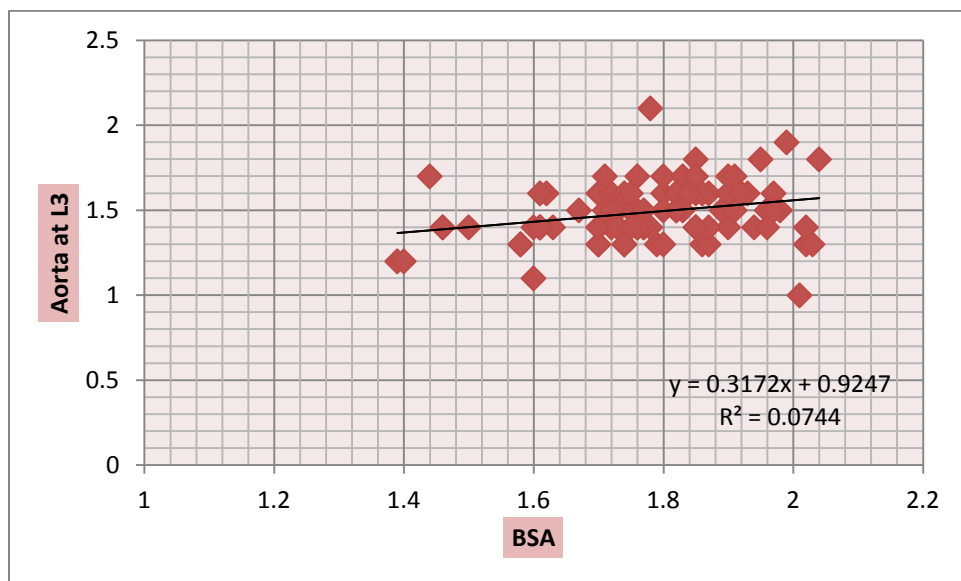
**Figure 4.11** A scatter plot diagram shows a linear relationship between the subjects BSA and Aorta transverse diameter(ATD)at T12,as the BSAincreases the ATD increases by 0.76starting from 0.6 $R^2=0.179$



**Figure 4.12** A scatter plot diagram shows a linear relationship between the subjects BSA and Aorta transverse diameter(ATD)at L1,as the BSAincreasesthe ATD increases by 0.72starting from 0.5 $R^2=0.18$



*Figure 4.13A scatter plot diagram shows a linear relationship between the subjects BSA and Aorta transverse diameter(ATD)at L2,as the BSAincreases the ATD increases by 0.4starting from 0.9 $R^2=0.09$*



*Figure 4.14 A scatter plot diagram shows a linear relationship between the subjects BSA and Aorta transverse diameter(ATD)at L3,as the BSAincreases the ATD increases by 0.3starting from 0.9 $R^2=0.07$*

## Chapter five

### (Discussion, conclusions and recommendation)

#### 5.1 Discussion:

This study is attempting to establish normal diameters for abdominal aorta at different vertebral levels in the Sudanese patient and to study the variation in aortic diameter according to age, sex, BSA, height, body weight, and body mass index (BMI).

This study was performed on 100 patients. The data collected for patients age (18-80) years old. The results showed that the normal transverse abdominal aorta diameter were correlated with patient age, body mass index (BMI), and body surface area (BSA)

The study showed that mean transverse diameter of abdominal aorta at level of T12 was  $(1.99 \pm 0.25)$ cm ,the mean transverse diameter of abdominal aorta at level of L1 was  $(1.79 \pm 0.24)$ cm ,the mean transverse diameter of abdominal aorta at level of L2 was  $(1.59 \pm 0.19)$ cm ,the mean transverse diameter of abdominal aorta at level of L3 was  $(1.49 \pm 0.16)$ cm for both males and females.

The study showed that mean transverse diameter of abdominal aorta at level of T12 was  $(1.89 \pm 0.2)$ cm in females and  $(2.1 \pm 0.3)$ cm in males ,mean transverse diameter of abdominal aorta at level of L1 was  $(1.69 \pm 0.2)$ cm in females and  $(1.91 \pm 0.3)$ cm in males , mean transverse diameter of abdominal aorta at level of L2 was  $(1.5 \pm 0.1)$ cm in females and  $(1.68 \pm 0.2)$ cm in males , mean transverse diameter of abdominal aorta at level of L3 was  $(1.45 \pm 0.1)$ cm in females and  $(1.54 \pm 0.2)$ cm in males.

These measurement compared to study done by A Jasper,2014 in Indian population by CT found the mean abdominal aorta diameter at level T12 was  $(1.71 \pm 2.3) / (1.9 \pm 2.3)$  In females / males which was lower than Ours study by  $(0.18) / (0.2)$  and level L3 was  $(1.2 \pm 1.6) / (1.9 \pm 2.3)$  in females/males which was lower than Ours study by  $(0.49) / (0.16)$  this different may be due to racial differences and patient habits. Another study done by JOH JH,2013,in Korean population by ultrasound found was  $(1.90) / (2.04)$  In female / male at renal which was higher than Ours study by  $(0.21) / (0.13)$  and was  $(1.79) / (1.90)$  In female / male at infrarenal which was higher than Ours study by  $(0.34) / (0.36)$  this different may be due to smaller sample size in our study and different method of measurement . In another study done by Sariosmanoglu N, 2002 in Turkish population by ultrasound found  $(1.8 \pm 3) / (1.9 \pm 4)$  cm In female / male which lower than Ours study by  $(0.09) / (0.02)$  and the bifurcation level  $(1.5 \pm 3) / (1.6 \pm 4)$  In female / male which was higher than Ours study by  $(0.05) / (0.06)$  the different may be due to different height, size of body and methods of measurement.

The selection of the vertebral because of the fact that it was considered as references.

In this study a linear relationship between the subjects age and Aorta transverse diameter (ATD) at T12, as the age increases the ATD was also increase by 0.011 starting from 1.4  $R^2=0.491$  as presented in figure 4.3 .at L1,as the age increases the ATD was also increase by 0.008 starting from 1.3  $R^2=0.314$  as presented in figure 4.4 .at L2,as the age increases the ATD was also increase by 0.005 starting from 1.3  $R^2=0.182$  as presented in figure 4.5. at L3,as the age increases the ATD was also increase by 0.004 starting from 1.3  $R^2=0.163$  as presented in figure 4.6.

Increase in abdominal aorta diameter with age and males higher than females similar to study done by A Jasper, 2014 in Indian population the aortic diameter progressively increased in caliber with increasing age of the patients and was smaller in women than men.

In this study a linear relationship between the subjects BMI and Aorta transverse diameter(ATD) at T12,as the BMI increases the ATD was also increase by 0.001 starting from 1.9  $R^2=0.000$  as presented in figure 4.7 .at L1,as the BMI increases the ATD was also increase by 0.001 starting from 1.7  $R^2=0.000$  as presented in figure 4.8 .at L2,as the BMI increases the ATD decreases by 0.002 starting from 1.6 $R^2=0.001$  as presented in figure 4.9.at L3,as the BMI increases the ATD decreases by 0.000 starting from 1.5 $R^2=0.000$  as presented in figure 4.10 .

In this study a linear relationship between the subjects BSA and Aorta transverse diameter(ATD) at T12,as the BSA increases the ATD increases by 0.76starting from 0.6 $R^2=0.179$  as presented in figure 4.11.at L1,as the BSA increases the ATD increases by 0.72starting from 0.5 $R^2=0.18$  as presented in figure 4.12.at L2,as the BSA increases the ATD increases by 0.4starting from 0.9 $R^2=0.09$  as presented in figure 4.13 .at L3,as the BSA increases the ATD increases by 0.3starting from 0.9 $R^2=0.07$  as presented in figure 4.14 .

linear relationship between the subjects BSA and Aorta transverse diameter but not Significant and not similar to study done by Sonesson B, 1994 correlations were found between aortic diameter and body surface area ( $r = 0.83$ ,  $p < 0.001$ )

Regarding the result the Technologist shroud be aware of the normal measurement for Sudanese. Their result should not exceed that level were increasing this may consider as aneurysm.

## **5.2Conclusion:**

The study conclude that the normal transverse abdominal aorta diameter in Sudanese patient by CT abdomen with contrast was found the mean transverse diameter of abdominal aorta at levels of T12, L1, L2and L3 in females were  $(1.89\pm0.2)$ ,  $(1.69\pm0.2)$ ,  $(1.5\pm0.1)$ ,  $(1.45\pm0.1)$  cm and in males were  $(2.1\pm0.3)$ ,  $(1.91\pm0.3)$ ,  $(1.68\pm0.2)$ ,  $(1.54\pm0.2)$  cm respectively.

Linear relationship between the patient age ,BMI and BSA with Aorta transverse diameter(ATD) at T12,L1,L2,L3 level .

The males abdominal aorta diameter higher than females diameter in all vertebral levels.

Sudanese abdominal aorta diameter index was different from the previous study.

## **5.3Recommendation:**

Further study in evaluation of normal abdominal aorta diameter with larger sample of Sudanese population for more accurate results is needed.

Using of other imaging modalities like ultrasound and MRI to confirm the result.

To study the abdominal aorta diameter in patient with, hypertension,diabetes or another risk factor .

## References :

- Ashley Avenue, Charleston, 2011, Your Aorta
- Bown MJ, Sutton AJ, Bell PR, Sayers RD (June 2002). "A meta-analysis of 50 years of ruptured abdominal aortic aneurysm repair". *The British Journal of Surgery* 89 (6): 714–30
- Brown LC, Powell JT (September 1999). "Risk Factors for Aneurysm Rupture in Patients Kept Under Ultrasound Surveillance". *Annals of Surgery* 230 (3): 289–96.
- Chadi SA et al (2012). "Trends in management of abdominal aortic aneurysms". *J VascSurg* 55 (4): 924–8.
- [en.wikipedia.org/wiki/Abdominal\\_aorta](http://en.wikipedia.org/wiki/Abdominal_aorta)
- Fauci, Anthony (2008-03-06). "242". *Harrison's Principles of Internal Medicine* (17 ed.). McGraw-Hill Professional.
- Goldman, Lee. *Goldman's Cecil Medicine* (24th ed. ed.). Philadelphia: Elsevier Saunders.
- Heather Gloria, 2011, Abdominal Aorta Stenosis Symptoms available from: <http://www.livestrong.com/article/66443-abdominal-aorta-stenosis-symptoms>.
- Henry Gray, 1918, *Anatomy of the Human Body*, Twentieth
- Jasper A<sup>1</sup>, Harshe G, Keshava SN, Kulkarni G, Stephen E, Agarwal S, 2014, Evaluation of normal abdominal aortic diameters in the Indian population using computed tomograph
- Jonathan Earnshaw, National Director of the NHS AAA Screening Programme, outlines the main risk factors for developing an abdominal aortic aneurysm.
- Lippert H, Pabst R, 1985, *Aortic arch. In: Arterial Variations in Man: Classification and Frequency*. Munich, Germany: JF Bergmann-Verlag,

- Mary C Mancini, MD, PhD; Chief Editor: John Geibel, MD, DSc, MA, 2014, Aortic dissection
- Rogers IS<sup>1</sup>, Massaro JM, Truong QA, Mahabadi AA, Kriegel MF, Fox CS, Thanassoulis G, Isselbacher EM, Hoffmann U, O'Donnell CJ, 2013, Distribution, determinants, and normal reference values of thoracic and abdominal aortic diameters by computed tomography
- Sariosmanoglu N<sup>1</sup>, Ugurlu B, Karacelik M, Tuzun E, Yorulmaz I, Manisali M, Oto A, Besim A, Oto O, 2002, A multicentre study of abdominal aorta diameters in a Turkish population
- Saum A Rahimi, MD, FACS; Chief Editor: Vincent Lopez Rowe, MD, 2014, Abdominal Aortic Aneurysm
- Sonesson B<sup>1</sup>, Länne T, Hansen F, Sandgren T, 1994, Infra renal aortic diameter in the healthy person
- Standring S, 2008, Gray H. Gray's Anatomy, The Anatomical Basis of Clinical Practice. Churchill Livingstone.
- Stanley S Wang, MD, JD, MPH; Chief Editor: Richard A Lange, MD, 2014, Aortic Regurgitation
- Upchurch GR, Schaub TA (2006). "Abdominal aortic aneurysm". Am Fam Physician 73 (7)
- Wanhainen A<sup>1</sup>, Themudo R, Ahlström H, Lind L, Johansson L, 2008, Thoracic and abdominal aortic dimension in 70-year-old men and women--a population-based whole-body magnetic resonance imaging (MRI) study
- [www.boundless.com](http://www.boundless.com)
- Yacoub MH, Kilner PJ, Birks EJ, et al. The aortic outflow and root: a tale of dynamism and crosstalk. Ann Thorac Surg 1999;68:S37-43.



## ***Data collecting sheet (questionnaire)***

- NO ☐
- **Patient data:**
  - Patient name .....
  - Age ☐ - Sex ☐
  - Weight ☐ - Height ☐
  - body mass index (BMI) ☐
  - body surface area (BSA) ☐
- **Abdominal aorta measurment:**
  - T12 ☐ - L1 ☐
  - L2 ☐ - L3 ☐
- **Vertbra size :**
  - T12 : AP ☐ Transverse ☐
  - L1 : AP ☐ Transverse ☐
  - L 2 : AP ☐ Transverse ☐
  - L 3 : AP ☐ Transverse ☐